

Expert **CONSULT**

Activate at [expertconsult.com](http://expertconsult.com)

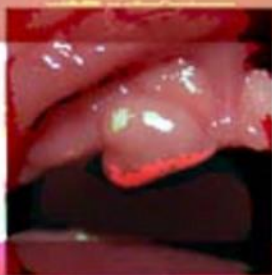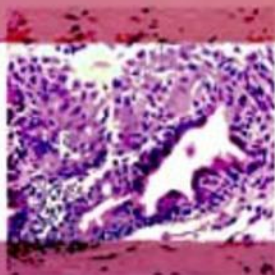
Searchable Full  
Text Online

Sook-Bin Woo

*with histopathology illustrations by Phillip H. McKee*

# ORAL PATHOLOGY

A COMPREHENSIVE ATLAS and TEXT



ELSEVIER  
SAUNDERS

*Don't Forget Your Online Access to*

**ExpertConsult.com**

## ***Mobile. Searchable. Expandable.***

**ACCESS** it on any Internet-ready device

**SEARCH** all Expert Consult titles you own

**LINK** to PubMed abstracts

### **ALREADY REGISTERED?**

1. Log in at expertconsult.com
2. Scratch off your Activation Code below
3. Enter it into the "Add a Title" box
4. Click "Activate Now"
5. Click the title under "My Titles"

### **FIRST-TIME USER?**

1. **REGISTER**
  - Click "Register Now" at expertconsult.com
  - Fill in your user information and click "Continue"
2. **ACTIVATE YOUR BOOK**
  - Scratch off your Activation Code below
  - Enter it into the "Enter Activation Code" box
  - Click "Activate Now"
  - Click the title under "My Titles"

For technical assistance:  
email [online.help@elsevier.com](mailto:online.help@elsevier.com)  
call 800-401-9962 (inside the US)  
call +1-314-995-3200 (outside the US)

Activation Code

# ExpertConsult.com



# **ORAL PATHOLOGY:**

A COMPREHENSIVE ATLAS AND TEXT

This page intentionally left blank

# ORAL PATHOLOGY:

A COMPREHENSIVE ATLAS AND TEXT

## **Sook-Bin Woo, DMD, MMSc**

Associate Professor

Department of Oral Medicine, Infection, and Immunity

Harvard School of Dental Medicine

Boston, Massachusetts

Director of Clinical Affairs

Division of Oral Medicine and Dentistry

Consultant Pathologist

Department of Pathology

Brigham and Women's Hospital

Boston, Massachusetts

Co-Director

Center for Oral Pathology

Strata Pathology Services Inc.

Lexington, Massachusetts

**SAUNDERS**





Copyright © 2012 by Saunders, an imprint of Elsevier Inc.

All rights reserved. No part of this publication may be reproduced or transmitted in any form or by any means, electronic or mechanical, including photocopying, recording, or any information storage and retrieval system, without permission in writing from the publisher. Details on how to seek permission and further information about the Publisher's permissions policies and our arrangements with organizations such as the Copyright Clearance Center and the Copyright Licensing Agency can be found at our website: [www.elsevier.com/permissions](http://www.elsevier.com/permissions).

This book and the individual contributions contained in it are protected under copyright by the Publisher (other than as may be noted herein).

**Notices**

Knowledge and best practice in this field are constantly changing. As new research and experience broaden our understanding, changes in research methods, professional practices, or medical treatment may become necessary.

Practitioners and researchers must always rely on their own experience and knowledge in evaluating and using any information, methods, compounds, or experiments described herein. In using such information or methods, they should be mindful of their own safety and the safety of others, including parties for whom they have a professional responsibility.

With respect to any drug or pharmaceutical products identified, readers are advised to check the most current information provided (i) on procedures featured or (ii) by the manufacturer of each product to be administered, to verify the recommended dose or formula, the method and duration of administration, and contraindications. It is the responsibility of practitioners, relying on their own experience and knowledge of their patients, to make diagnoses, to determine dosages and the best treatment for each individual patient, and to take all appropriate safety precautions.

To the fullest extent of the law, neither the Publisher nor the authors, contributors, or editors assume any liability for any injury and/or damage to persons or property as a matter of products liability, negligence, or otherwise, or from any use or operation of any methods, products, instructions, or ideas contained in the material herein.

**Library of Congress Cataloging-in-Publication Data**

Woo, Sook-bin.

Oral pathology : a comprehensive atlas and text / Sook-Bin Woo. – 1st ed.  
p. ; cm.

Includes bibliographical references.

ISBN 978-1-4377-2226-0 (hardback : alk. paper)

I. Title.

[DNLM: 1. Mouth Diseases--pathology--Atlases. WU 17]  
616.3'1-dc23

2011048710

*Executive Content Strategist:* William Schmitt  
*Senior Content Specialist:* Katie DeFrancesco  
*Publishing Services Manager:* Anne Altepeter  
*Senior Project Manager:* Doug Turner  
*Designer:* Ellen Zanolle

Printed in the People's Republic of China

Last digit is the print number: 9 8 7 6 5 4 3 2 1

Working together to grow  
libraries in developing countries

[www.elsevier.com](http://www.elsevier.com) | [www.bookaid.org](http://www.bookaid.org) | [www.sabre.org](http://www.sabre.org)

**ELSEVIER** BOOK AID International Sabre Foundation

This book is dedicated to my parents, who believe that education will lift us all,  
and to John, Sook-Yee, Chi-kan, Roger, I-Hwei, and Sarah.

This page intentionally left blank



# PREFACE

This book is written for the general pathologist, the dermatopathologist, the dermatologist with an interest in pathology, residents in training, and other medical and dental specialists interested in understanding the clinicopathologic correlations of oral disease. For clinicians using this book, two appendixes provide information on how to manage mucosal disease.

The objective is to present specific histologic criteria for the diagnosis of inflammatory conditions, cysts, and tumors seen in the oral cavity; illustrate the spectrum of histologic findings, correlating them with the clinical manifestations; and provide histologic differential diagnoses for these entities. This is particularly important in understanding inflammatory mucosal diseases that are relapsing or remitting, in which the histologic findings depend greatly on the stage of the disease, the site of the biopsy, and whether lesions have been treated. The chapter on diagnosis of oral dysplasia discusses not only the conventional cytologic criteria of dysplasia but also the architectural features that are often overlooked.

I have the great advantage of working with clinicians who in this digital age often send their biopsy specimens accompanied by photographs and radiographs of the lesions. I also see many patients in my clinical practice on whom I have performed biopsies. Correlating the clinical appearance of lesions with the histopathology facilitates a better understanding of how mucosal diseases evolve and how subtle and varied histopathologic findings may be.

As with any other textbook or atlas, page limitations required that I be selective in choosing the conditions

and appropriate references to be included. Many references are now readily identified and downloaded via the Internet. Nevertheless, I hope that you will find this atlas informative and useful in your practice of pathology.

## Acknowledgments

I am indebted to my colleagues and friends who contributed slides and images for this atlas, and to the many clinicians who contribute cases to our biopsy service, thereby supporting the graduate oral and maxillofacial pathology training program at the Harvard School of Dental Medicine. Some of the cases came to me through my participation in continuing competency programs provided by the Armed Forces Institute of Pathology and the American Board of Oral and Maxillofacial Pathology, and from continuing education seminars that I attended at our annual academy meetings. Grateful thanks are due also to my colleagues at the Ohio State University, Columbus, Ohio; Oral Pathology Laboratories, Queens, New York; and colleagues in Guatemala with whom I exchange study sets. This endeavor would have been less than what it is without the patients who generously shared their stories and insights about their diseases and whose images appear within these pages; it is an honor to care for them. All the photomicrographs were taken by the incomparable Dr. Phillip McKee.

**Sook-Bin Woo, DMD, MMSc**

This page intentionally left blank

# CONTENTS

- 1 ■ INTRODUCTION** 1
  - Anatomy 1
  - Teeth 1
  - Diagnosis and Management 2
  - Some Basic Guidelines 2
  
- 2 ■ DEVELOPMENTAL AND CONGENITAL CONDITIONS** 7
  - DIFFUSE WHITE LESIONS 7
    - White Sponge Nevus (Cannon White Sponge Nevus) 7
    - Hereditary Benign Intraepithelial Dyskeratosis 9
    - Darier Disease (Keratosis Follicularis) and Warty Dyskeratoma 10
  - NODULAR OR TUMOR-LIKE LESIONS 11
    - Fordyce Granules, Sebaceous Hyperplasia, and Adenoma 11
    - Congenital Granular Cell Tumor (Congenital Granular Cell Epulis) 13
    - Osseous and Cartilaginous Choristomas 14
    - Gingival Fibromatosis 15
    - Gastrointestinal and Brain Heterotopias 17
    - Lymphangioma of the Alveolar Ridge in Neonates 19
    - Lingual Thyroid 19
    - Leiomyomatous Hamartoma 20
  - CYSTIC LESIONS 20
    - Oral Lymphoepithelial Cyst (Benign Lymphoepithelial Cyst) 20
    - Epidermoid (Epithelial Inclusion) and Dermoid Cysts 23
    - Palatal and Gingival Cysts of the Neonate 25
      - Cyst of the Incisive Papilla 25
    - Nasolabial Cyst (Nasoalveolar Cyst) 26
  
- 3 ■ NONINFECTIOUS PAPILLARY LESIONS** 28
  - Inflammatory Papillary Hyperplasia of the Palate 28
  - Verruciform Xanthoma 30
  - Juvenile Localized Spongiotic Gingival Hyperplasia 33
  
- 4 ■ BACTERIAL, VIRAL, FUNGAL, AND OTHER INFECTIOUS CONDITIONS** 35
  - Actinomycosis 35
  - Candidiasis (Candidosis) 38
  - Infectious Granulomatous Inflammation 42
  - Herpesvirus Infections 45
    - Herpes Simplex Virus Infection 45
    - Hairy Leukoplakia 48
    - Cytomegalovirus Infection 51
    - Human Papillomavirus–Related Benign Lesions 53
    - Syphilis 61
  
- 5 ■ FIBROUS, GINGIVAL, LIPOCYTIC, AND MISCELLANEOUS TUMORS** 63
  - FIBROUS LESIONS 63
    - Fibroma (“Bite” or “Irritation” Fibroma, Fibroepithelial or Fibrovascular Polyp) and Giant Cell Fibroma 63
  - GINGIVAL MASSES 68
    - Reactive/Inflammatory Gingival Nodules 68
    - Diffuse/Multifocal Gingival Hyperplasia 76
  - GINGIVAL CYST OF THE ADULT 79
  - PERIPHERAL (EXTRAOSSEOUS) ODONTOGENIC NEOPLASMS 82
    - Peripheral Odontogenic Fibroma 82
    - Peripheral Ameloblastoma 84
    - Peripheral Calcifying Cystic Odontogenic Tumor 86
  - METASTASES TO THE GINGIVA 87
  - DENTURE-ASSOCIATED INFLAMMATORY FIBROUS HYPERPLASIA (EPULIS FISSURATUM) 88
  - LIPOCYTIC LESIONS 90
    - Lipoma 90
  - OTHER UNCOMMON TUMORS 94
    - Myofibroma 94
  - TUMORS OF UNCERTAIN HISTOGENESIS 97
    - Ectomesenchymal Chondromyxoid Tumor of the Tongue 97
    - Solitary Fibrous Tumor 100
    - Oral Focal Mucinosis 103
  
- 6 ■ VASCULAR, NEURAL, AND MUSCLE TUMORS** 106
  - VASCULAR LESIONS 106
    - Pyogenic Granuloma 106
    - Varix (Venous Lake) and Venous Malformation (Venous Anomaly) 109
    - Caliber-Persistent Labial Artery 114
    - Kaposi Sarcoma 115
    - Lymphatic Malformation (Lymphangioma Circumscriptum) 117
  - NEURAL TUMORS 119
    - Traumatic Neuroma 119
    - Neurofibroma 121
    - Schwannoma 123
    - Solitary Circumscribed Neuroma (Palisaded Encapsulated Neuroma) 125
    - Granular Cell Tumor 127



- Subgemmal Neurogenous Plaque (Subepithelial Nerve Plexus) 129
- MUSCLE TUMORS 131
- Leiomyoma and Angioleiomyoma (Vascular Leiomyoma) 131
- Adult Rhabdomyoma 134
- Embryonal Rhabdomyosarcoma 135
- 7 ■** ULCERATIVE AND INFLAMMATORY CONDITIONS 137
- ULCERATIVE CONDITIONS 137
- Recurrent Aphthous Ulcers and Traumatic Ulcers 137
- Traumatic Ulcerative Granuloma with Stromal Eosinophils, Eosinophilic Ulcer of Tongue 140
- NONSPECIFIC INFLAMMATORY CONDITIONS 143
- Nonspecific Irritant Contact Stomatitis 143
- Frictional Blisters 145
- Chronic Gingivitis 145
- Foreign Body Gingivitis 148
- 8 ■** IMMUNE-MEDIATED, AUTOIMMUNE, AND GRANULOMATOUS CONDITIONS 150
- GRANULOMATOUS INFLAMMATION 150
- Foreign Body Granulomas 150
- Orofacial Granulomatosis and Crohn Disease 154
- PYOSTOMATITIS VEGETANS 157
- IMMUNE-MEDIATED CONDITIONS 158
- Benign Migratory Glossitis (Migratory Stomatitis; Geographic Tongue, Erythema Areata Migrans) 158
- Nonspecific Hypersensitivity Reactions 160
- Erythema Multiforme 161
- Plasma Cell Orificial Mucositis (Plasma Cell Stomatitis, Mucous Membrane Plasmacytosis) 163
- Lichen Planus/Lichenoid Mucositis 165
- AUTOIMMUNE CONDITIONS 173
- Mucous Membrane Pemphigoid 173
- Pemphigus Vulgaris 177
- Paraneoplastic Pemphigus 180
- Lupus Erythematosus 181
- Wegener Granulomatosis 183
- 9 ■** PIGMENTED LESIONS 185
- EXOGENOUS PIGMENTATION 185
- Amalgam Tattoo 185
- Graphite Tattoo 188
- Medication-Induced Pigmentation 189
- MELANOCYTIC LESIONS 191
- Oral Melanotic Macule 191
- Postinflammatory Hypermelanosis 193
- Melanoacanthosis (Melanoacanthoma) 196
- Oral Melanocytic Nevus 198
- Dysplastic Melanocytic Nevus and Mucosal Melanoma 203
- NEUROECTODERMAL PIGMENTATION 207
- Melanotic Neuroectodermal Tumor of Infancy 207
- 10 ■** REACTIVE KERATOTIC LESIONS (NONLEUKOPLAKIAS) 210
- WHITE LESIONS 210
- REACTIVE LESIONS 210
- Leukoedema 210
- Contact Desquamation 213
- FRictionAL/FACTITIAL KERATOSES 214
- Morsicatio Mucosae Oris (Morsicatio Buccarum, Pathominia Mucosae Oris) 214
- Benign Alveolar Ridge (Frictional) Keratosis (Oral Lichen Simplex Chronicus) 218
- Nonspecific Benign Reactive Keratoses 221
- TOBACCO-RELATED LESIONS 223
- Smokeless Tobacco Lesion 223
- Nicotinic Stomatitis (Stomatitis Nicotina) 226
- SUBMUCOUS FIBROSIS 227
- 11 ■** LEUKOPLAKIA, ORAL DYSPLASIA, AND SQUAMOUS CELL CARCINOMA 230
- Leukoplakia, Erythroplakia, and Dysplasia 230
- Human Papillomavirus–Associated Apoptotic Dysplasia 241
- Squamous Cell Carcinoma 243
- Conventional Infiltrating Squamous Cell Carcinoma 244
- Sarcomatoid Squamous Cell Carcinoma 247
- Basaloid Squamous Cell Carcinoma 250
- Human Papillomavirus–Associated Oropharyngeal and Tonsillar Nonkeratinizing Squamous Cell Carcinoma 252
- Adenoid Squamous Cell Carcinoma 254
- Adenosquamous Cell Carcinoma 256
- Verrucous Carcinoma 257
- Papillary Squamous Cell Carcinoma 259
- Cuniculate Carcinoma (Carcinoma Cuniculatum) 262
- 12 ■** INFLAMMATORY SALIVARY GLAND DISORDERS 264
- Mucocele 264
- Salivary Duct Cyst (Salivary Retention Cyst, Sialocyst) 270
- Sialolith (Salivary Calculus) 272
- Cheilitis Glandularis (Stomatitis Glandularis, Cheilitis Glandularis Apostematosa) 275
- Necrotizing Sialometaplasia 276
- Subacute Necrotizing Sialadenitis 278
- Autoimmune Sialadenitis 280
- Adenomatoid (Acinar) Hyperplasia 283
- Sclerosing Polycystic Adenosis 284
- 13 ■** SALIVARY GLAND NEOPLASMS 286
- BENIGN SALIVARY GLAND NEOPLASMS 286
- Pleomorphic Adenoma and Myoepithelioma 286
- Canalicular Adenoma 293
- Cystadenoma, Papillary or Otherwise 295
- Sialadenoma Papilliferum 298
- Intraductal Papilloma 299

- Inverted Ductal Papilloma 300
- MALIGNANT SALIVARY GLAND NEOPLASMS 301
- Mucoepidermoid Carcinoma 301
- Adenoid Cystic Carcinoma 305
- Polymorphous Low-Grade Adenocarcinoma 309
- Acinic Cell Adenocarcinoma 313
- Clear Cell Adenocarcinoma (Hyalinizing) 316
- Adenocarcinoma, Not Otherwise Specified 318
  
- 14 ■ ODONTOGENIC CYSTS 320**
  - ODONTOGENIC CYSTS 320
  - INFLAMMATORY CYSTS 320
  - Apical and Lateral Radicular Cyst and Periapical Granuloma 320
  - Mandibular Buccal Bifurcation Cyst 327
  - DEVELOPMENTAL CYSTS 328
  - Dentigerous Cyst (Follicular Cyst) 328
  - Lateral Periodontal Cyst 333
  - Orthokeratinized Odontogenic Cyst 335
  - Odontogenic Cyst in a Globulomaxillary Location 337
  - Primordial Cyst 338
  - Glandular Odontogenic Cyst 338
  
- 15 ■ ODONTOGENIC TUMORS 340**
  - EPITHELIAL TUMORS WITHOUT ECTOMESENCHYME 340
  - Keratocystic Odontogenic Tumor (Odontogenic Keratocyst) 340
  - Ameloblastoma 345
  - Calcifying Epithelial Odontogenic Tumor (Pindborg Tumor) 351
  - Adenomatoid Odontogenic Tumor 353
  - Squamous Odontogenic Tumor 355
  - Ameloblastic Carcinoma 357
  - Primary Intraosseous Squamous Cell Carcinoma 358
  - Clear Cell Odontogenic Carcinoma 360
  - MIXED EPITHELIAL AND ECTOMESENCHYMAL TUMORS 362
  - Calcifying Cystic Odontogenic Tumor (Calcifying Odontogenic Cyst, Gorlin Cyst) and Dentinogenic Ghost Cell Tumor 362
  - Ameloblastic Fibroma 365
  - Ameloblastic Fibro-odontoma 368
  - Odontoma 370
  - MESENCHYMAL TUMORS 373
  - Central Odontogenic Fibroma 373
  - Odontogenic Myxoma 375
  - Granular Cell Odontogenic Tumor 377
  - Cementoblastoma 379
  
- 16 ■ NONODONTOGENIC INTRAOSSEOUS LESIONS 382**
  - Tori and Exostoses 382
  - Fibro-osseous Lesions 385
  - Paget Disease of Bone (Osteitis Deformans) 396
  - Central Giant Cell Granuloma (Aggressive and Nonaggressive Giant Cell Lesion, Central Giant Cell Lesion, Central Giant Cell Reparative Granuloma) 398
  - Cherubism 401
  - Desmoplastic Fibroma 402
  - Osteosarcoma (Osteogenic Sarcoma) 403
  - Chondrosarcoma 407
  - Plasma Cell Myeloma (Multiple Myeloma) 411
  - Langerhans Cell Histiocytosis 416
  - Osteonecrosis and Osteomyelitis 417
  - Myospherulosis (Spherulocytosis, Spherulocystic Disease of Skin) 422
  - Hematopoietic Bone Marrow Defect (Osteoporotic Bone Marrow Defect) 423
  - NONODONTOGENIC CYSTS AND CYSTLIKE LESIONS 424
  - Nasopalatine Duct (Incisive Canal) Cyst 424
  - Surgical Ciliated Cyst (Postoperative Maxillary Cyst) 426
  - Median Palatal (Palatine) Cyst 427
  - Aneurysmal Bone Cyst 428
  - Simple Bone Cyst (Traumatic Bone Cyst, Idiopathic Bone Cavity) 430
  - Stafne Bone Cavity (Lingual Salivary Gland Depression) 431
  
- APPENDIX A 433
- APPENDIX B 435

This page intentionally left blank



# 1

# INTRODUCTION

## CHAPTER CONTENTS

Anatomy 1

Teeth 1

Diagnosis and Management 2

Some Basic Guidelines 2

Pathology of the oral cavity affects the following structures: (1) the mucosa, (2) the salivary glands, and (3) the jaw bones. Lesions may extend into the oropharynx, sinuses, and the skin. As such, the scope of practice of oral and maxillofacial pathology overlaps with head and neck pathology, dermatopathology, and orthopedic pathology. The oral cavity is also the primary site for the development of lymphomas and many soft tissue tumors, and is also sometimes the location of metastatic tumors. This atlas focuses on pathology that is frequently seen in the oral cavity.

Unlike the skin, mucosal lesions in the oral cavity may manifest only in a limited number of ways—erythematous, white (from keratosis or underlying fibrosis), yellow (from fibrinous exudate), papillary, diffuse or nodular swelling, mass, erosive or vesicobullous, and pigmented. It is important for the pathologist to be familiar with clinical presentations of mucosal disease because this affects the final diagnosis and is particularly important for keratotic lesions, leukoplakias, and mucosal disease.

## ANATOMY

The oral mucosa varies clinically and histologically from site to site, and can be divided into keratinized and nonkeratinized mucosa (Fig. 1-1). Knowledge of clinical aspects of oral disease must be correlated with oral anatomy: for example, recurrent aphthous ulcers occur primarily on the nonkeratinized mucosa, whereas recurrent herpes simplex infections occur almost exclusively on the keratinized mucosa in immune-competent patients. The tongue dorsum but not ventrum is specialized for gustatory, masticatory, and deglutition functions. Taste buds are present within fungiform (dorsum), circumvallate (8 to 14 on the posterior dorsum), and foliate (posterior lateral tongue) papillae but not within filiform papillae (Fig. 1-2). The oral mucosa contains no submucosa per se because there is no muscularis mucosa or any other clearly recognizable histologic landmark that separates mucosa from submucosa. As such, the terms *papillary*, *superficial*, and *deep lamina propria* are preferable to *submucosa*. In general, the

epithelium of the oral cavity is much thicker than that of the skin (Table 1-1; Figs. 1-3 to 1-9). Muscle is present fairly superficially on the tongue and slightly deeper on the buccal and labial mucosa. Minor salivary glands are predominantly mucous, although serous acini and demilunes are frequently seen (Fig. 1-10); they are present everywhere in the mouth except on the attached gingiva and tongue dorsum. Serous salivary glands with a smaller mucous component are frequently encountered on the anterior ventral (glands of Blandin-Nuhn) and posterior lateral and dorsal (glands of von Ebner) tongue, often invested in muscle. Lingual tonsils are located on the posterior dorsum and posterior lateral tongue.

## TEETH

Teeth are made up mostly of tubular dentin that is capped by a thin shell of very hard but brittle enamel in the tooth crown. The tooth root is surrounded by a thin layer of cementum. The periodontal membrane (made up mainly of type I collagen) attaches to the cementum on one side and the alveolar bone on the other, allowing for slight movement of teeth within the bone (Fig. 1-11).

Enamel (ectodermal in nature) is 96% mineral (hydroxyapatite crystals) and 4% organic material and water. The organic material consists of noncollagenous proteins called amelogenins (90%), enamelin, and ameloblastin. Mature tubular dentin is composed of 70% inorganic material, 20% organic material, and 10% water. The organic base is composed of 90% collagen (mainly type I), dentin matrix, and bone matrix proteins such as osteocalcin, osteopontin, and bone sialoprotein. Dentin is deposited by the odontoblast (of neural crest derivation) and wraps around an odontoblastic process that traverses the entire thickness of the dentin from the pulp where the odontoblast resides, to the enamel or cementum. Cementum is closest to bone in composition with 45% to 50% hydroxyapatite and 50% collagen and noncollagenous matrix proteins. Type I collagen constitutes 90% of the nonmineral portion of cementum.

**TABLE 1-1** Histology of Oral Mucosa at Different Sites

Site	Appearance
Nonkeratinized (thick) Buccal mucosa Labial mucosa	Buccal and labial mucosa are contiguous and similar (see Fig. 1-3) 15–20 layers of keratinocytes Broad, tapered rete ridges Loose fibrovascular tissue in the lamina propria or corium; muscle at the base
Nonkeratinized (intermediate) Nonattached gingiva	Nonattached gingiva Intermediate between buccal mucosa and floor of mouth
Nonkeratinized (thin) Floor of mouth Ventral tongue Soft palate/fauces	Floor of mouth and ventral tongue are contiguous and similar to soft palate (see Fig. 1-4) 10–15 layers of keratinocytes Short or poorly formed rete ridges Ventral tongue in the anterior and posterior often contains serous salivary glands (glands of Blandin-Nuhn and von Ebner, respectively) (see Fig. 1-5)
Keratinized Hard palatal mucosa Attached gingiva	Hard palatal mucosa and attached gingiva are similar (see Fig. 1-6) Thin layer of orthokeratin with thin granular layer 15–20 layers of keratinocytes Gingiva has more tapered, slender rete ridges Dense fibrous tissue and periosteum at the base Hard palatal mucosa often has fatty tissue investing neurovascular bundles and minor salivary glands Gingiva may contain rests of odontogenic epithelium (rests of Serres) (see Fig. 1-7)
Keratinized and specialized Tongue dorsum	Moderate-to-thick layer of parakeratin Filiform papillae are keratin spires surrounded by bacterial colonies (see Fig. 1-8) 20–30 layers of keratinocytes Fungiform, circumvallate, and foliate papillae are fibrovascular polypoid structures containing taste buds (see Fig. 1-9) Posterior dorsum and lateral tongue contain lingual tonsils. Skeletal muscle is superficial

## Tooth Numbering System and Nomenclature

There are three commonly used nomenclatures for tooth identification. In the American Dental Association (ADA) system each tooth is identified by one number (#1 to #32 starting from the right maxillary third molar moving clockwise) (Fig. 1-12). Palmer's notation (used mainly by the British) and the system adopted by the Federation Dentaire Internationale (FDI) use a single number for each of the eight teeth in a quadrant (starting from the central incisor [#1] moving posteriorly to the third molar [#8]). In the FDI system, a qualifier is added for the specific quadrant in which the tooth is located (quadrants 1 to 4 clockwise starting from the right maxilla); quadrant 1 is right maxilla, 2 is left maxilla, 3 is left mandible, and 4 is right mandible. For example, tooth #12 by the ADA system is the left maxillary first premolar or bicuspid. By Palmer's notation, this is designated left upper 4 or  $\underline{4}$ , and by the FDI system it is tooth 24 (quadrant 2, tooth #4).

The terms *facial*, *buccal*, and *labial* refer to the aspect of the gingiva or teeth that are in contact with the labial or buccal mucosa and oriented outwards. Conversely, the terms *palatal* and *lingual* are used for aspects that are oriented inwards toward the palate or the tongue.

## DIAGNOSIS AND MANAGEMENT

Small macules, papules, or nodules should be excised with a shave biopsy or an elliptical wedge excision. For larger lesions, biopsies using a 3 to 5 mm skin punch provide tissue that is easy to orient for processing; primary closure with one to two sutures is readily achieved (Fig. 1-13). However, the mucosa of the hard palate and gingiva abut directly on the periosteum, and it is difficult to obtain primary closure. The use of silver nitrate or aluminum chloride to control hemostasis is preferable. For the purposes of the clinician, Appendixes A and B at the end of the book provide the most commonly used medications for definitive treatment of mucosal disease and agents for topical pain control.

## SOME BASIC GUIDELINES

The histopathologic features of inflammatory mucosal disorders depend on the stage at which the lesion is biopsied (evolving or resolving) and whether it has been treated. The “typical” or “classic” histology for many inflammatory conditions are seen in untreated fully-evolved lesions. As such, a range of histopathologic features is presented for common inflammatory lesions.

Dysplastic conditions are probably the most challenging, because the clinical appearance of the lesion plays an important role in the accurate diagnosis of dysplasia. To this end, clinicians are encouraged to send a photograph of the lesion with the biopsy. Many dysplastic oral lesions show architectural rather than cytologic evidence of dysplasia. These concepts are covered in depth in Chapter 11.

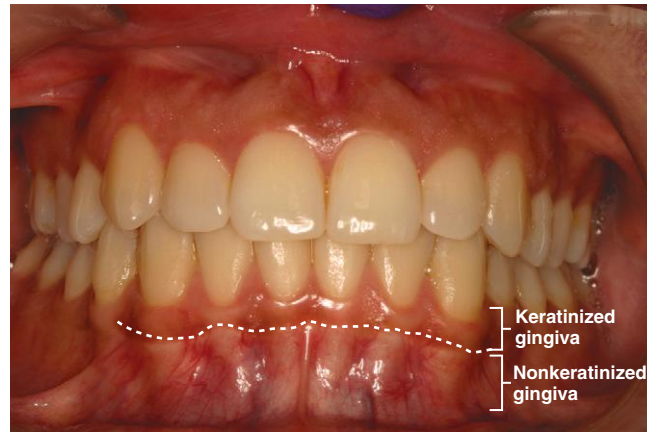
The teeth and salivary glands are adnexa of the oral cavity in the same way that hair and sweat glands are

skin adnexa. As such, there are histologic similarities between odontogenic, salivary gland, skin adnexal, and breast neoplasms. The diagnosis of odontogenic cysts and tumors and many bone-forming lesions can be accurately rendered only if radiographic images are

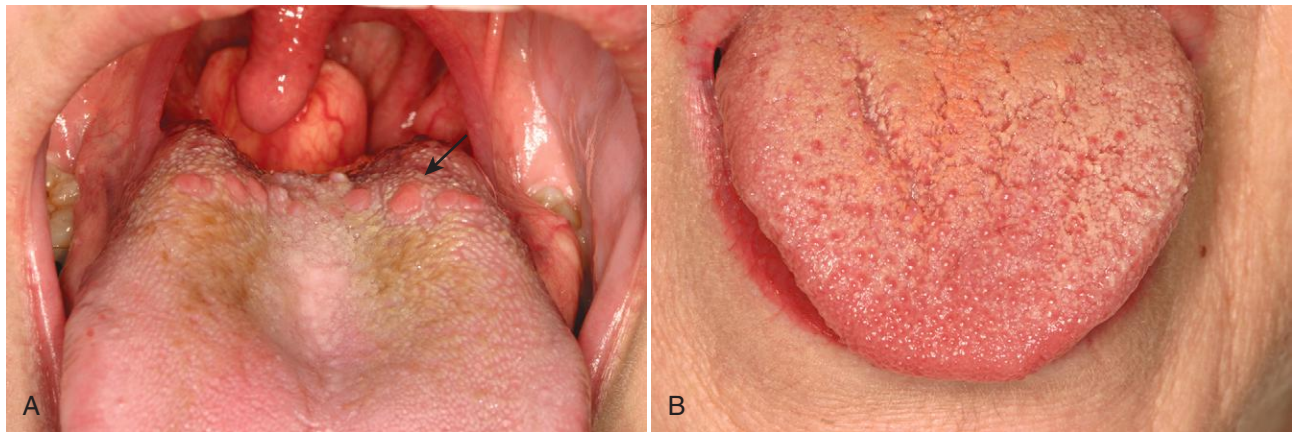
provided and this is particularly true for fibrous lesions.

#### REFERENCE

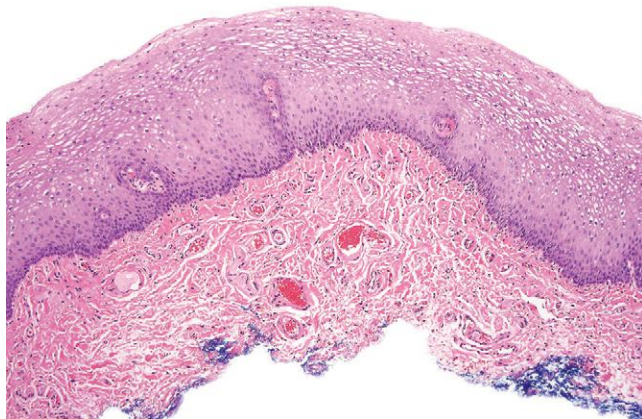
Nanci A. *Ten Cate's Oral Histology: Development, Structure and Function*. 7th ed. St. Louis: Mosby; 2008.



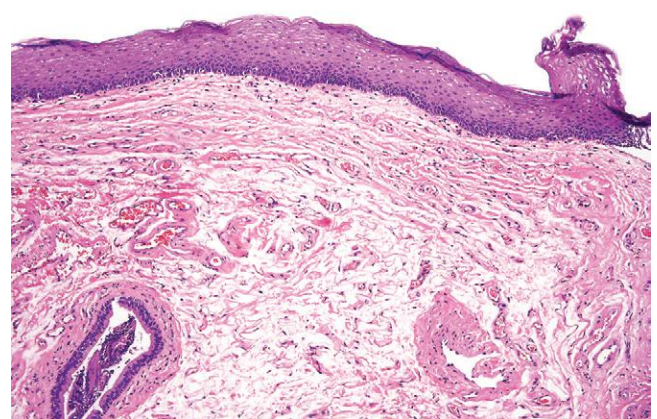
**FIGURE I-1.** Gingival mucosa showing marginal and attached gingiva (keratinized) and nonattached gingiva (nonkeratinized).



**FIGURE I-2. A,** Tongue showing filiform (generalized "fur") and circumvallate papillae (arrow), as well as epiglottis. **B,** Tongue with inflamed fungiform papillae.

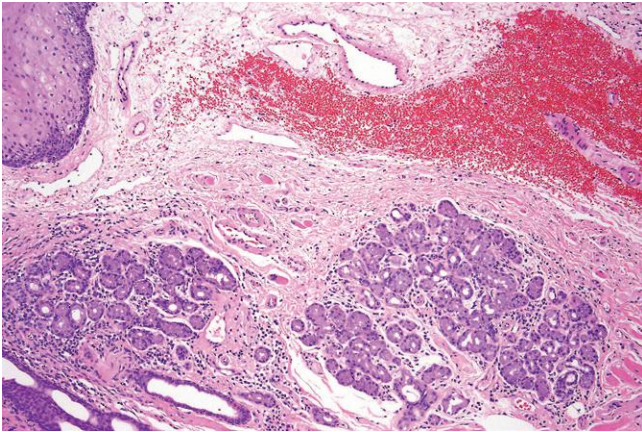


**FIGURE I-3.** Normal buccal mucosa: nonkeratinized stratified squamous epithelium 15 to 20 cells thick; perinuclear halos are present because of glycogen.

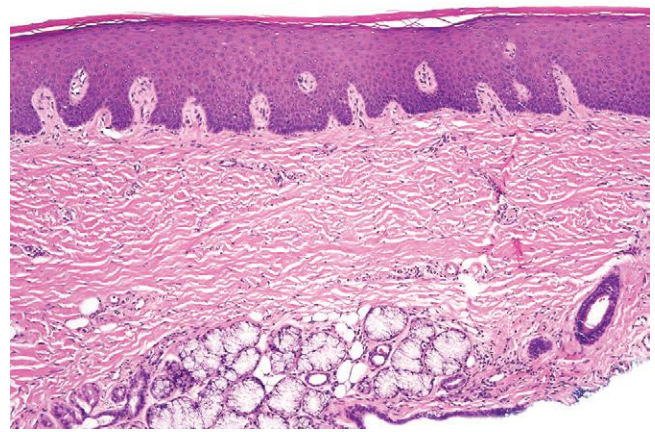


**FIGURE I-4.** Normal floor of mouth: thin, stratified squamous epithelium with poorly formed rete ridges.

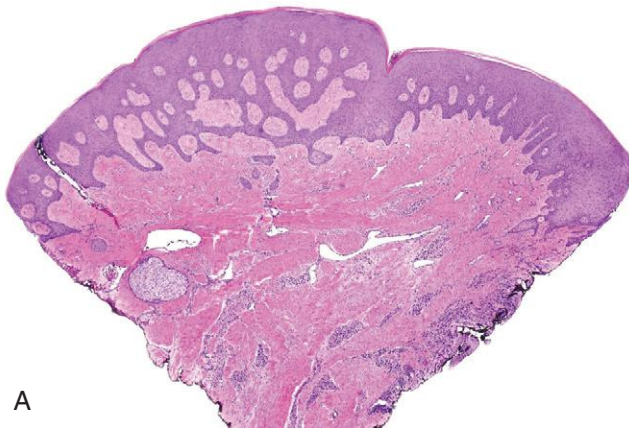



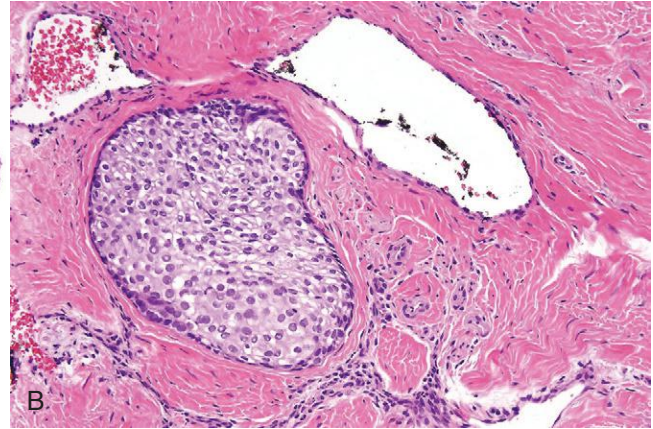
**FIGURE I-5.** Mostly serous glands of von Ebner in the posterior tongue.



**FIGURE I-6.** Normal mucosa of hard palate: thin layer of orthokeratin, epithelium 15 to 20 cells thick, dense lamina propria, and salivary glands.

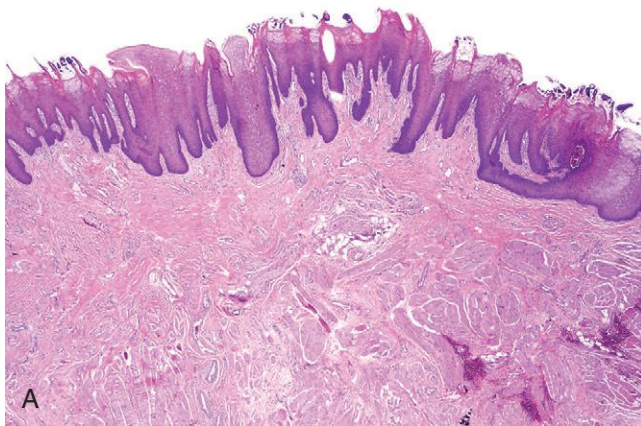


A

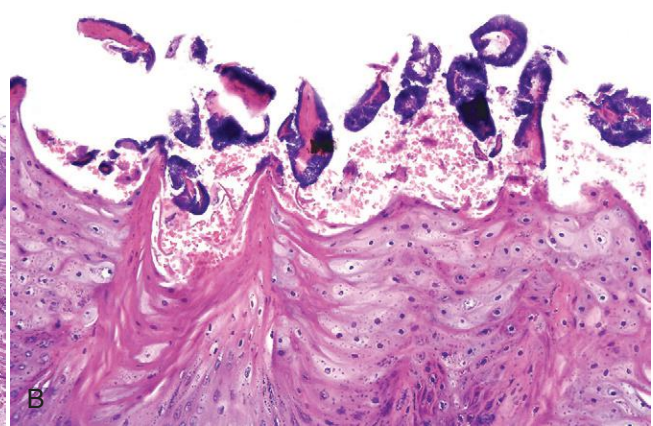


B

**FIGURE I-7. A,** Odontogenic rest of Serres in the gingiva. **B,** Odontogenic rest of Serres: rest contains many clear cells.



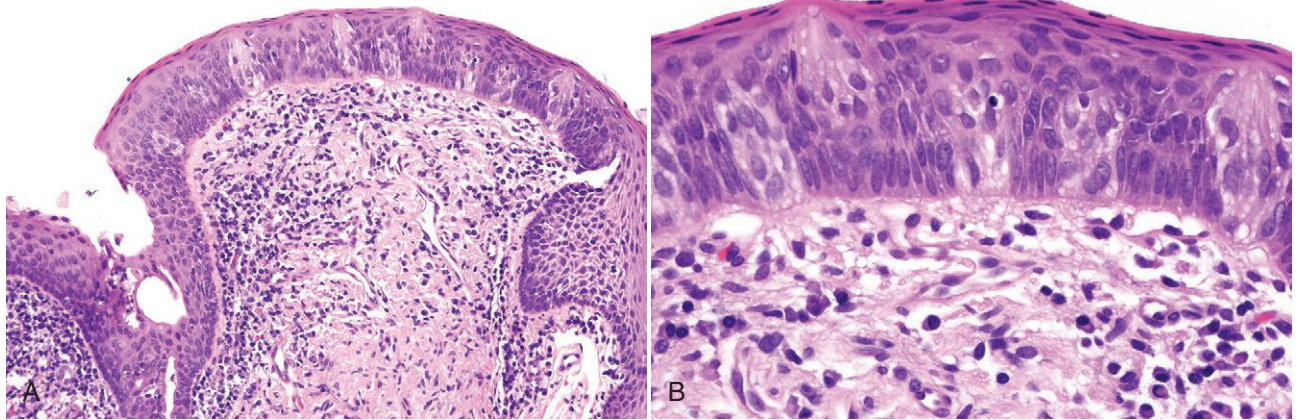
A



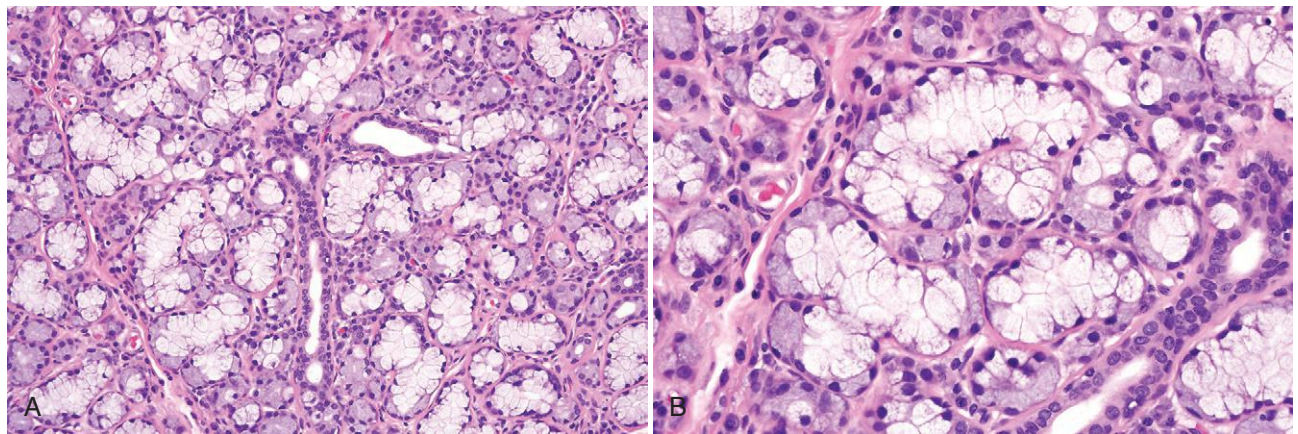
B

**FIGURE I-8. A,** Tongue dorsum: thick parakeratinized epithelium with abundant muscle. **B,** Tongue dorsum: parakeratotic surface and filiform papillae with bacterial colonies.

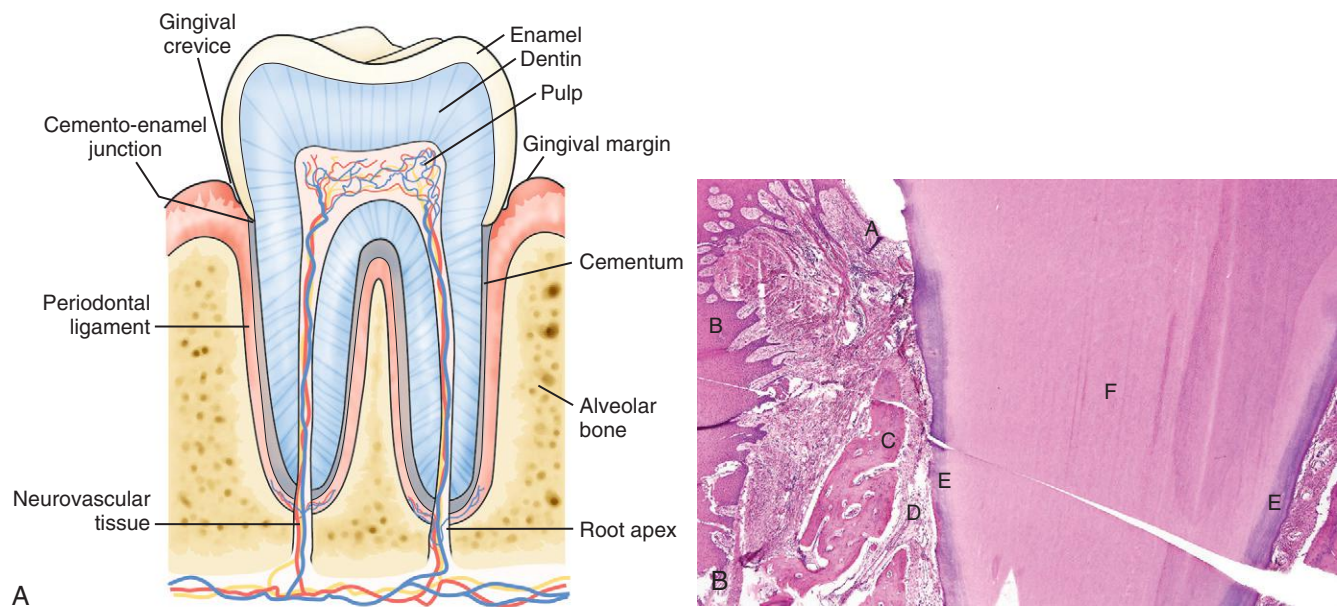




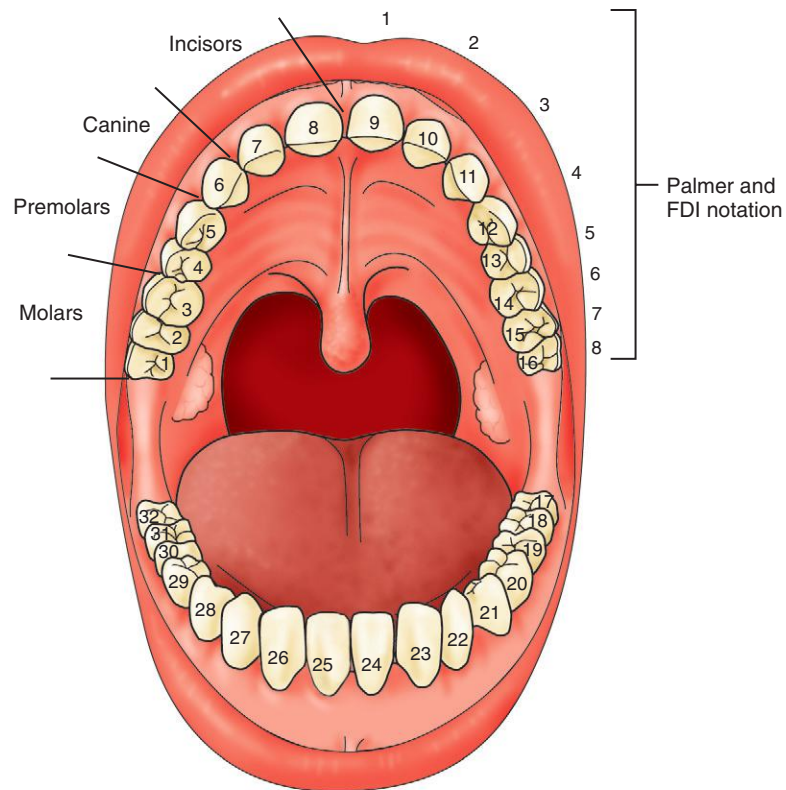
**FIGURE I-9.** **A,** Taste buds: fungiform papilla with taste buds in epithelium and many nerve fibers in the lamina propria. **B,** Taste buds: flask-shaped clusters of sustentacular and gustatory sensory cells.



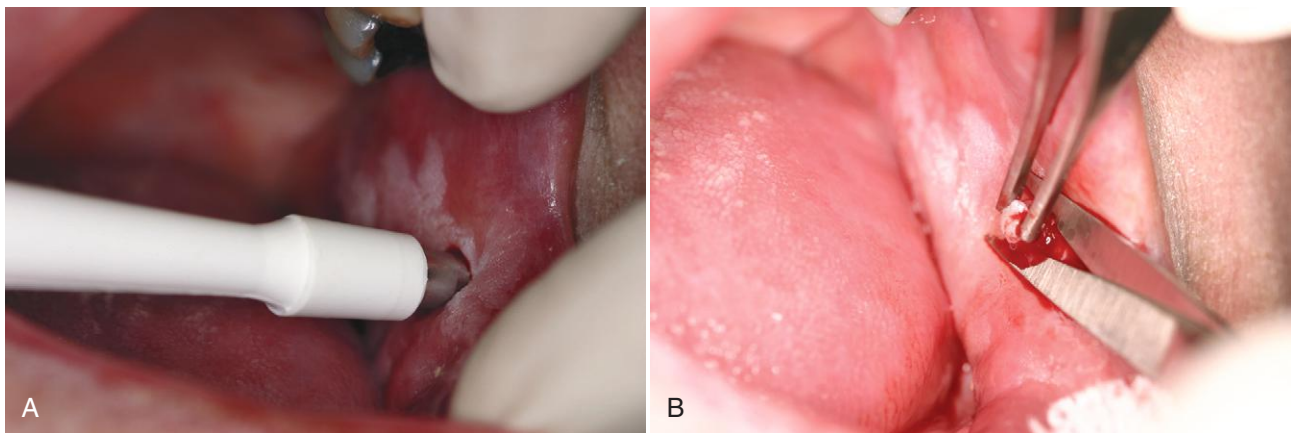
**FIGURE I-10.** **A,** Mucous glands of the lower lip with some serous acini. **B,** Serous acinar cells in caplike demilune arrangement over mucous acini.



**FIGURE I-11.** **A,** Diagram of a tooth in bone. **B,** Tooth showing crevicular epithelium (A), surface epithelium (B), alveolar bone (C), collagenous periodontal ligament (D), cementum (E), and dentin (F).



**FIGURE I-12.** Tooth numbering system: #1 to #32 (American Dental Association); #1 to #8 (Palmer notation and Federation Dentaire Internationale system [FDI]).



**FIGURE I-13.** **A**, Punch biopsy: inserting the skin punch. **B**, Punch biopsy: cutting the tissue at the base.



# 2

# DEVELOPMENTAL AND CONGENITAL CONDITIONS

## CHAPTER CONTENTS

### DIFFUSE WHITE LESIONS 7

White Sponge Nevus (Cannon White Sponge Nevus) 7

Hereditary Benign Intraepithelial Dyskeratosis 9

Darier Disease (Keratosis Follicularis) and Warty Dyskeratoma 10

### NODULAR OR TUMOR-LIKE LESIONS 11

Fordyce Granules, Sebaceous Hyperplasia, and Adenoma 11

Congenital Granular Cell Tumor (Congenital Granular Cell Epulis) 13

Osseous and Cartilaginous Choristomas 14

Gingival Fibromatosis 15

Gastrointestinal and Brain Heterotopias 17

Lymphangioma of the Alveolar Ridge in Neonates 19

Lingual Thyroid 19

Leiomyomatous Hamartoma 20

### CYSTIC LESIONS 20

Oral Lymphoepithelial Cyst (Benign Lymphoepithelial Cyst) 20

Epidermoid (Epithelial Inclusion) and Dermoid Cysts 23

Palatal and Gingival Cysts of the Neonate 25

Cyst of the Incisive Papilla 25

Nasolabial Cyst (Nasoalveolar Cyst) 26

## Diffuse White Lesions

Diffuse white developmental conditions are often dyskeratotic lesions and represent oral manifestations of genodermatoses. Oral lesions seen in dyskeratosis congenita are usually oral dysplasias/leukoplakias; oral lesions of pachyonychia congenita are rarely biopsied. Oral lesions of hereditary mucoepithelial dysplasia, a condition of defective expression of cytoskeleton-junctional elements, presents as erythematous mucosa.

### WHITE SPONGE NEVUS (CANNON WHITE SPONGE NEVUS)

#### Clinical Findings

- Usually noted in first 2 decades of life but persist throughout life; may remit and exacerbate
- White-to-gray, folded, painless, edematous, and spongy appearance of buccal mucosa (most common), tongue, labial mucosa, and floor of mouth; may have esophageal and genital involvement (Fig. 2-1)

#### Etiopathogenesis and Histopathologic Features

This is a rare, autosomal dominant conditions resulting from a mutation of the helical domain on K4 (chromosome 12q) and K13 (chromosome 17q) leading to keratin instability and abnormal tonofilament aggregation.

- Variable parakeratosis, benign epithelial hyperplasia with “spongy appearance” caused by cytoplasmic vacuolation (from glycogen) and not true spongiosis; minimal to no inflammation (Fig. 2-2, A and B)
- Perinuclear eosinophilic condensations of keratin and dyskeratotic cells *sine qua non* for diagnosis (see Fig. 2-2, C); rare cases with epidermolytic hyperkeratosis

#### Differential Diagnosis

- Leukoedema morsicatio mucosae oris exhibit keratinocytic edema but do not exhibit perinuclear keratin condensations.
- Hereditary benign intraepithelial dyskeratosis (see later) has “cell-within-a-cell” structures.

## Management and Prognosis

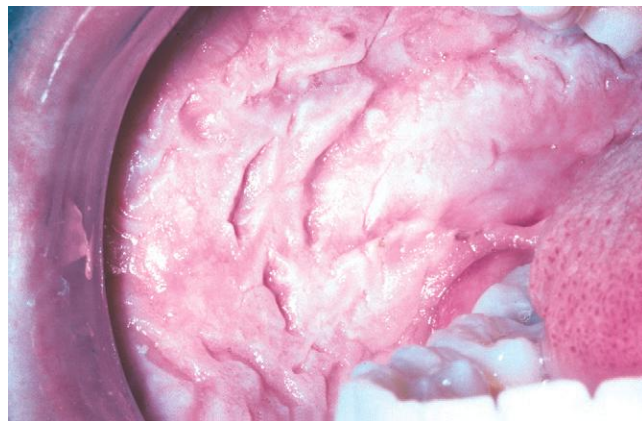- No treatment is required usually; some cases respond to antibiotic therapy.

## REFERENCES

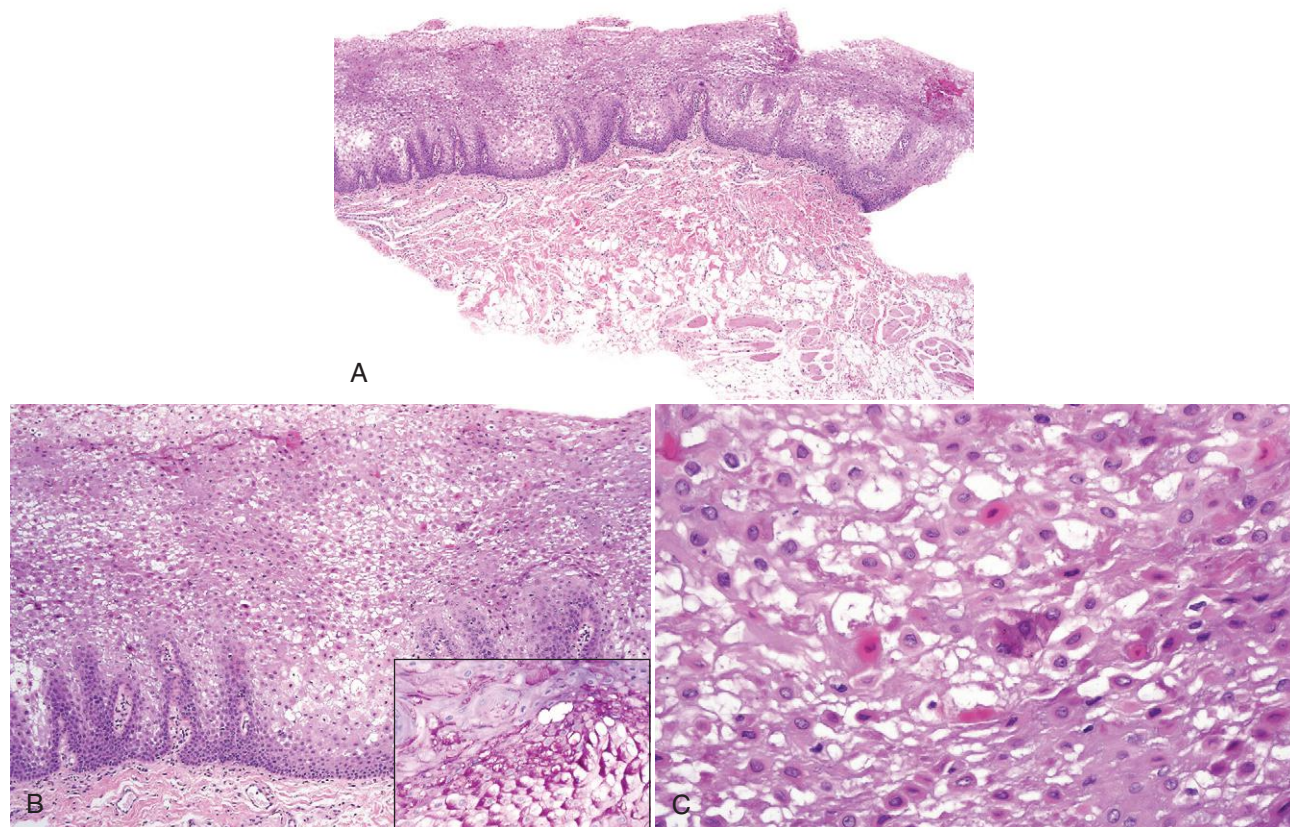
- Aloi FG, Molinero A. White sponge nevus with epidermolytic changes. *Dermatologica*. 1988;177:323-326.
- Atkinson JC, Harvey KE, Domingo DL, et al. Oral and dental phenotype of dyskeratosis congenita. *Oral Dis*. 2008;14:419-427.
- Boralevi F, Haftek M, Vabres P, et al. Hereditary mucoepithelial dysplasia: clinical, ultrastructural and genetic study of eight patients and literature review. *Br J Dermatol*. 2005;153:310-318.
- Lourenco SV, Boggio PA, Fezzi FA, et al. Dyskeratosis congenita—report of a case with emphasis on gingival aspects. *Pediatr Dermatol*. 2009;26:176-179.
- Morris R, Gansler TS, Rudisil MT, Neville B. White sponge nevus. Diagnosis by light microscopic and ultrastructural cytology. *Acta Cytologica*. 1988;32:357-361.
- Otobe IF, de Sousa SO, Matthews RW, Migliari DA. White sponge naevus: improvement with tetracycline mouth rinse: report of four cases. *Clin Exp Dermatol*. 2007;32:749-751.
- Pradeep AR, Nagaraja C. Pachyonychia congenita with unusual dental findings: a case report. *Oral Surg Oral Med Oral Pathol Oral Radiol Endod*. 2007;104:89-93.
- Rugg EL, McLean WH, Allison WE, et al. A mutation in the mucosal keratin K4 is associated with oral white sponge nevus. *Nat Genetics*. 1995;11:450-452.
- Terrinoni A, Candi E, Oddi S, et al. A glutamine insertion in the 1A alpha helical domain of the keratin 4 gene in a familial case of white sponge nevus. *J Invest Dermatol*. 2000;114:388-391.

Treister N, Lehmann LE, Cherrick I, et al. Dyskeratosis congenita vs. chronic graft versus host disease: report of a case and a review of the literature. *Oral Surg Oral Med Oral Pathol Oral Radiol Endod*. 2004;98:566-571.

Witkop CJ Jr, White JG, King RA, et al. Hereditary mucoepithelial dysplasia: a disease apparently of desmosome and gap junction formation. *Am J Hum Genet*. 1979;31:414-427.



**FIGURE 2-1.** White sponge nevus: diffuse, boggy, white fissured plaque of buccal mucosa. (From Neville BW, Damm DD, Allen CM, Bouquot JE: *Oral and Maxillofacial Pathology*, 3rd ed. Philadelphia: WB Saunders; 2009.)



**FIGURE 2-2.** White sponge nevus. **A**, Benign epithelial hyperplasia with pale “spongy” appearance. **B**, Intracellular vacuolation and dyskeratosis sparing basal cells; inset shows PAS-positive, diastase-labile intracytoplasmic granules typical for glycogen. **C**, Perinuclear condensations and cytoplasmic vacuolation (not spongiosis).



## HEREDITARY BENIGN INTRAEPITHELIAL DYSKERATOSIS

### Clinical Findings

- Associated with Haliwa Indians in North Carolina and their descendants (usually on East Coast of the United States); diagnosed in first 2 decades of life
- Oral mucosa with thickened painless, diffuse, folded spongy white plaques similar to white sponge nevus
- Eye lesions present as gelatinous plaques on bulbar conjunctiva in perilimbal location

### Etiopathogenesis and Histopathologic Features

Hereditary benign intraepithelial dyskeratosis is an autosomal dominant condition resulting from a duplication on chromosome 4q35.

- Hyperparakeratosis and acanthosis; dyskeratotic “tobacco” cells (because of their brown color seen in Papanicolaou stains) in upper epithelium in a typical cell-within-a-cell appearance (Fig. 2-3)

### Differential Diagnosis

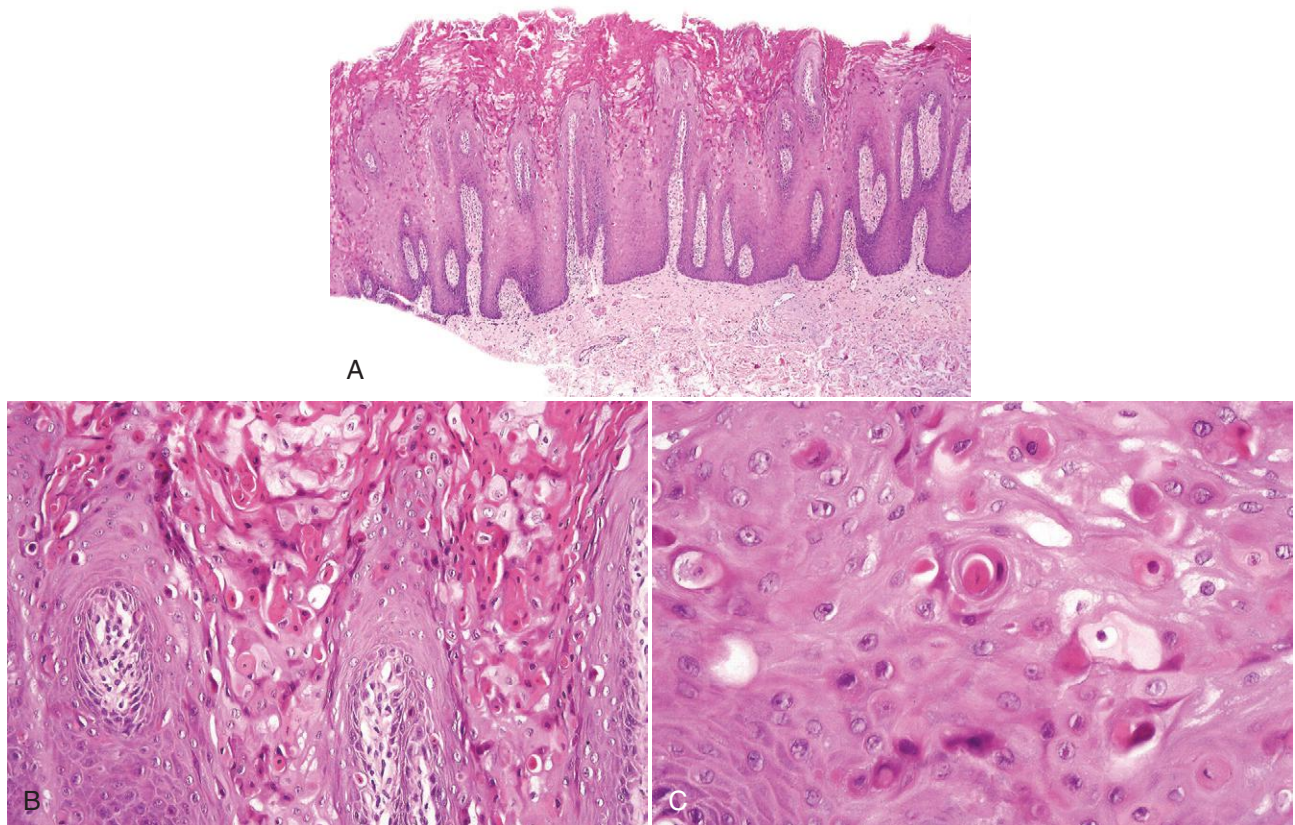
- White sponge nevus (see earlier) shows perinuclear keratin condensations.
- Darier disease or warty dyskeratoma is acantholytic with dyskeratosis without the cell-within-a-cell appearance.

### Management and Prognosis

- No treatment is effective.

### REFERENCES

- Allingham RR, Seo B, Rampersaud E, et al. Duplication in chromosome 4q35 is associated with hereditary benign intraepithelial dyskeratosis. *Am J Hum Genet.* 2001;68:491-494.
- Cummings TJ, Dodd LG, Eedes CR, Klintworth GK. Hereditary benign intraepithelial dyskeratosis: an evaluation of diagnostic cytology. *Arch Pathol Lab Med.* 2008;132:1325-1328.
- Haisley-Royster CA, Allingham RR, Klintworth GK, Prose NS. Hereditary benign intraepithelial dyskeratosis: report of two cases with prominent oral lesions. *J Am Acad Dermatol.* 2001;45:634-636.
- Jham BC, Mesquita RA, Aguiar MC, Carmo MA. Hereditary benign intraepithelial dyskeratosis: a new case? *J Oral Pathol Med.* 2007;36:55-57.



**FIGURE 2-3.** Hereditary benign intraepithelial dyskeratosis. **A**, Hyperparakeratosis and benign papillary epithelial hyperplasia. **B**, Prominent dyskeratosis within the superficial keratinocytes. **C**, Dyskeratotic cells with “cell-within-a-cell” morphology.

## DARIER DISEASE (KERATOSIS FOLLICULARIS) AND WARTY DYSKERATOMA

### Clinical Findings

- Darier disease characterized by white, painless, keratotic papules (seen in mild disease) or plaques and cobblestoning of the mucosa (seen in more severe disease) in 10% to 50% of patients with skin disease (Fig. 2-4); onset in first and second decade; lesions on palate, gingiva or tongue; skin findings invariably present; up to one third of cases with parotid or submandibular swelling likely because of strictures and obstruction
- Warty dyskeratoma: isolated white, warty papule usually of the palate or gingiva

### Etiopathogenesis and Histopathologic Features

Darier disease is an autosomal dominant disorder associated with a mutation of ATP2A2 gene (on chromosome 12q) involved in cytoplasmic calcium transport that is required for proper functioning of desmosomes and keratin formation, resulting in dyscohesion. Warty dyskeratoma is of unknown etiology but has the same histology.

- Often umbilicated/crateriform hyperkeratosis, elongated, slender rete ridges 3 to 8 cells wide, and suprabasilar acantholysis with villous-like projections of

connective tissue papillae rimmed by basal cells; dyskeratotic cells with dark nuclei in the form of slender grains (needle-shaped) or *corps ronds* (round) may not be prominent; variable chronic inflammation (Fig. 2-5)

### Differential Diagnosis

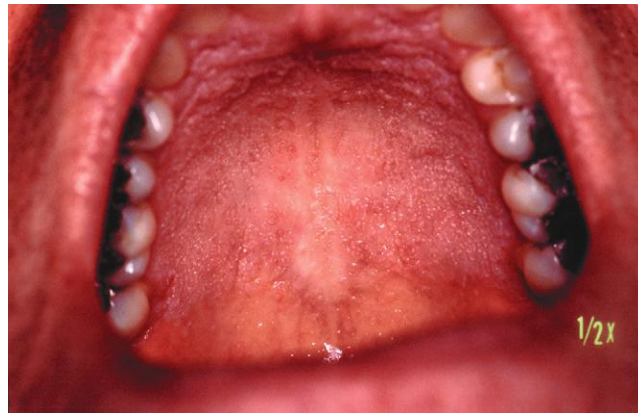- Pemphigus shows acantholytic cells, no dyskeratosis, and positive direct immunofluorescence studies.
- Pyostomatitis vegetans shows suprabasilar clefting, no dyskeratosis, and many eosinophils.

### Management and Prognosis

- Darier disease is managed with topical steroids, whereas warty dyskeratoma is excised.

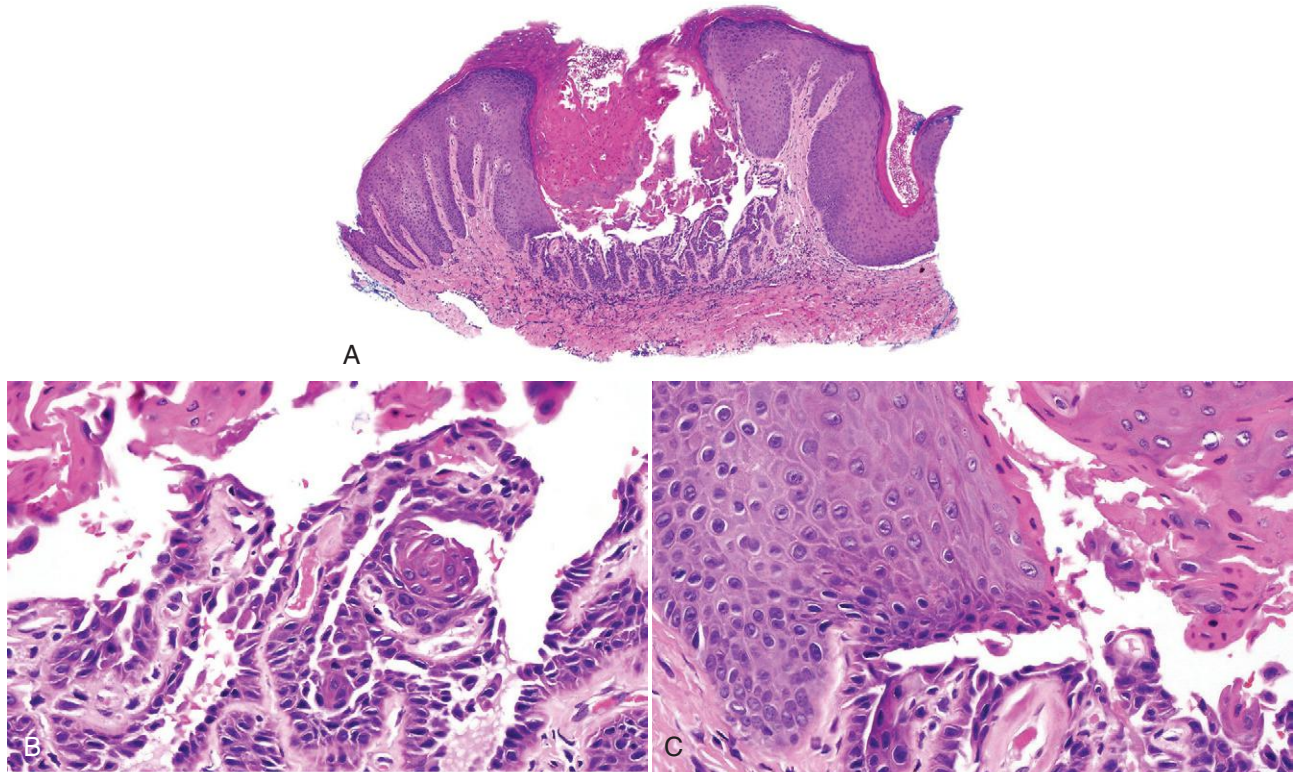
### REFERENCES

- Adams AM, Macleod RI, Munro CS. Symptomatic and asymptomatic salivary duct abnormalities in Darier's disease: a sialographic study. *Dentomaxillofac Radiol.* 1994;23:25-28.
- Burge SM, Wilkinson JD. Darier-White disease: a review of the clinical features in 163 patients. *J Am Acad Dermatol.* 1992;27:40-50.
- Frezzini C, Cedro M, Leao JC, Porter S. Darier disease affecting the gingival and oral mucosal surfaces. *Oral Surg Oral Med Oral Pathol Oral Radiol Endod.* 2006;102:e29-33.
- Macleod RI, Munro CS. The incidence and distribution of oral lesions in patients with Darier's disease. *Br Dent J.* 1991;171:133-136.
- Sakuntabhai A, Ruiz-Perez V, Carter S, et al. Mutations in ATP2A2, encoding a Ca<sup>2+</sup> pump, cause Darier disease. *Nat Genet.* 1999; 21:271-277.
- Zunt SL, Tomich CE. Oral focal acantholytic dyskeratosis. *J Dermatol Surg Oncol.* 1990;16:510-515.



**FIGURE 2-4.** Darier disease: diffuse, pebbly white papules on the hard palate. (From Frezzini C, Cedro M, Leao JC, Porter S. Darier disease affecting the gingival and oral mucosal surfaces. *Oral Surg Oral Med Oral Pathol Oral Radiol Endod.* 2006;102:e29-e33.)





**FIGURE 2-5.** Warty dyskeratoma. **A**, Crateriform architecture with keratin plug. **B**, Villous-like projections and suprabasilar acantholysis. **C**, Corps ronds and grains.

## Nodular or Tumor-Like Lesions

### FORDYCE GRANULES, SEBACEOUS HYPERPLASIA, AND ADENOMA

#### Clinical Findings

- Fordyce granules: 1 to 3 mm yellowish papules or macules on the posterior buccal mucosa, vermilion of lips, usually bilateral and symmetric, present in 80% of population (Fig. 2-6)
- Sebaceous hyperplasia and adenoma: larger yellowish papules and nodules at same sites as Fordyce granules
- Sebaceous choristoma: usually midline of tongue in area of foramen cecum

#### Etiopathogenesis and Histopathologic Features

Fordyce granules are considered normal and these can become hyperplastic and adenomatous.

- Fordyce granules: mature sebaceous glands open onto the mucosa via duct; sebocytes have central nuclei and vacuolated cytoplasm; hair and *Demodex folliculorum* have been reported (Fig. 2-7).
- Hyperplasia: at least 15 lobules (this number is somewhat arbitrary); ducts lined by low cuboidal to columnar epithelium (Figs. 2-8 and 2-9).

- Adenoma: proliferation of germinative cells at the periphery of the lobules

#### Differential Diagnosis

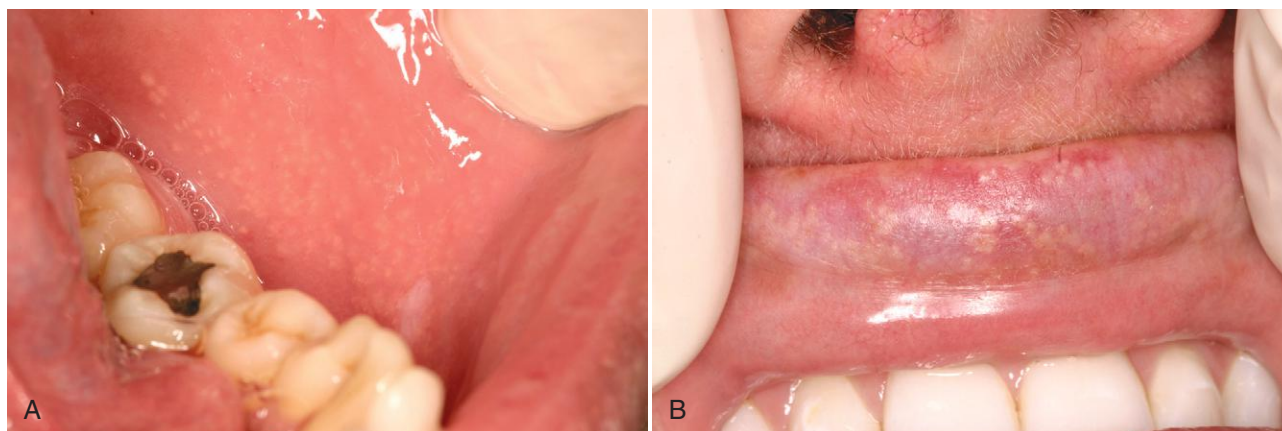
- Salivary gland neoplasms with sebaceous cells are encapsulated tumors with only foci of sebaceous differentiation.

#### Management and Prognosis

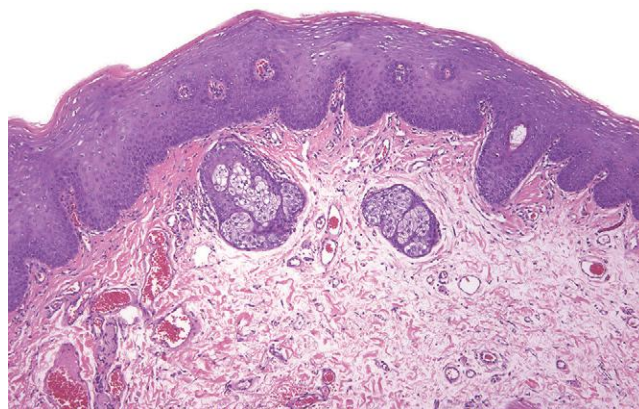- Excision of sebaceous hyperplasia and adenoma is curative.

#### REFERENCES

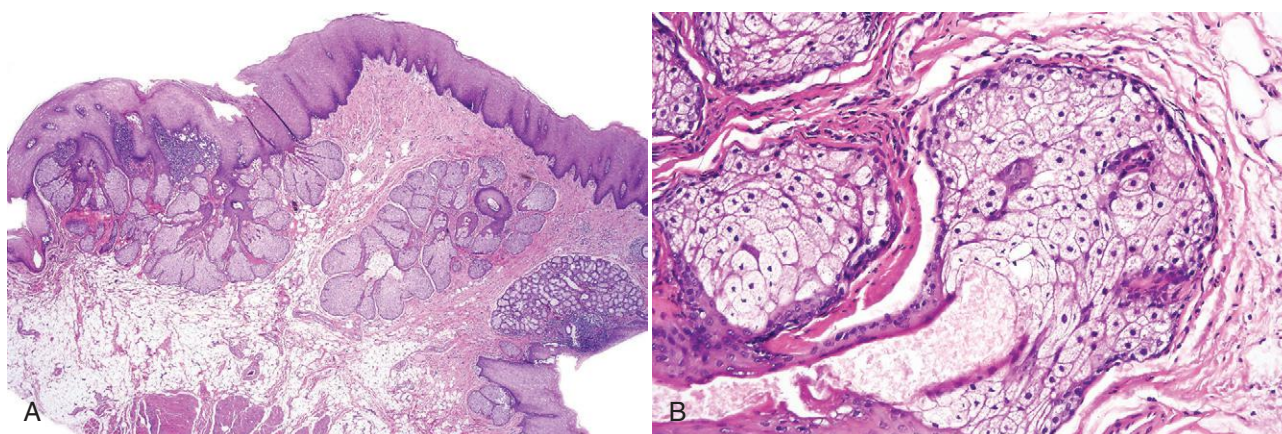
- Azevedo RS, Almeida OP, Netto JN, et al. Comparative clinicopathological study of intraoral sebaceous hyperplasia and sebaceous adenoma. *Oral Surg Oral Med Oral Pathol Oral Radiol Endod.* 2009;107:100-104.
- Daley TD. Intraoral sebaceous hyperplasia. Diagnostic criteria. *Oral Surg Oral Med Oral Pathol Oral Radiol Endod.* 1993;75:343-347.
- Franklin CD, Underwood JC. Demodex infestation of oral mucosal sebaceous glands. *Oral Surg Oral Med Oral Pathol.* 1986;61:80-82.
- Izutsu T, Kumamoto H, Kimizuka S, Ooya K. Sebaceous adenoma in the retromolar region: report of a case with a review of the English literature. *Int J Oral Maxillofac Surg.* 2003;32:423-426.
- Kaminagakura E, Andrade CR, Rangel AL, et al. Sebaceous adenoma of oral cavity: report of case and comparative proliferation study with sebaceous gland hyperplasia and Fordyce's granules. *Oral Dis.* 2003;9:323-327.



**FIGURE 2-6.** Fordyce granules. **A**, Yellow papules on the left buccal mucosa. **B**, Yellow papules on the upper vermillion.

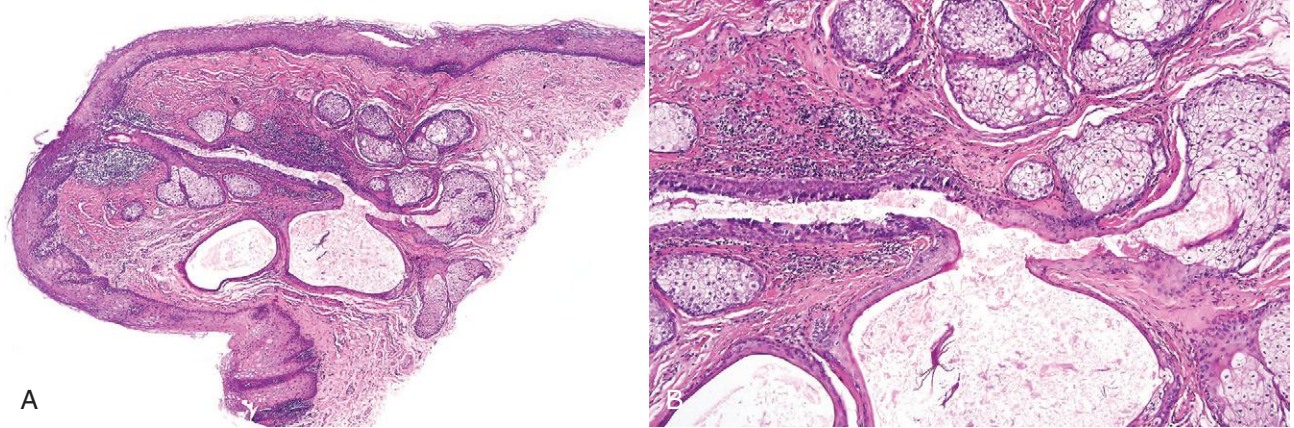


**FIGURE 2-7.** Fordyce granule: two sebaceous glands in the lamina propria.



**FIGURE 2-8.** Sebaceous hyperplasia. **A**, Many lobules of sebaceous glands in the lamina propria without hyperplasia of germinative layer. **B**, Mature sebocytes without proliferation of germinative cells, and secretions in duct.





**FIGURE 2-9.** Sebaceous hyperplasia. **A**, Lobular proliferation of sebaceous glands with ducts opening into the oral cavity. **B**, Cystically dilated ducts and mature sebocytes.

## CONGENITAL GRANULAR CELL TUMOR (CONGENITAL GRANULAR CELL EPULIS)

### Clinical Findings

- Pink, pedunculated mass on the alveolar ridge in newborn; 10:1 female predilection; 3:1 predilection for the maxillary ridge mucosa (Fig. 2-10); synchronous lesions may be present; some regress; rarely manifest on the extralingival sites such as the tongue

### Etiopathogenesis and Histopathologic Features

Congenital granular cell tumor is a mesenchymal tumor and exhibits subplasmalemmal dense bodies, pinocytotic vesicles containing precollagenous material, and intracytoplasmic laminin and fibronectin, suggesting myofibroblastic differentiation.

- Sheets of cells with pale, granular cytoplasm, well-defined cell borders and nuclei with dispersed chromatin and small nucleoli; prominent arborizing vessels; S-100 negative but CD68, NK1/C3, and PGP9.5 positive (Fig. 2-11); 40% are neuron-specific enolase (NSE)-positive

- Atrophic epithelium with no pseudoepitheliomatous hyperplasia

### Differential Diagnosis

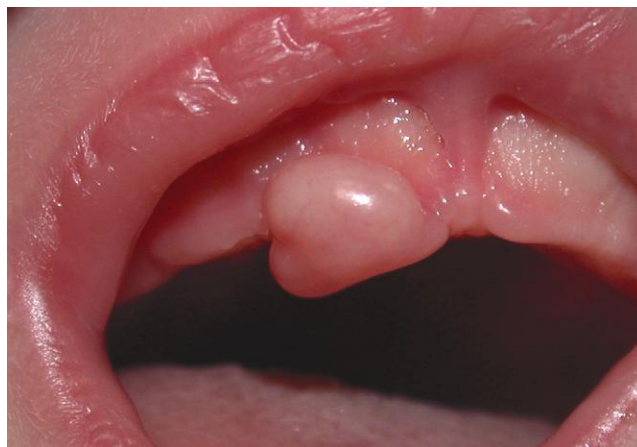- Conventional granular cell tumor is positive for S-100 protein.
- Primitive polypoid granular cell tumor shares the same immunohistochemical profile.

### Management and Prognosis

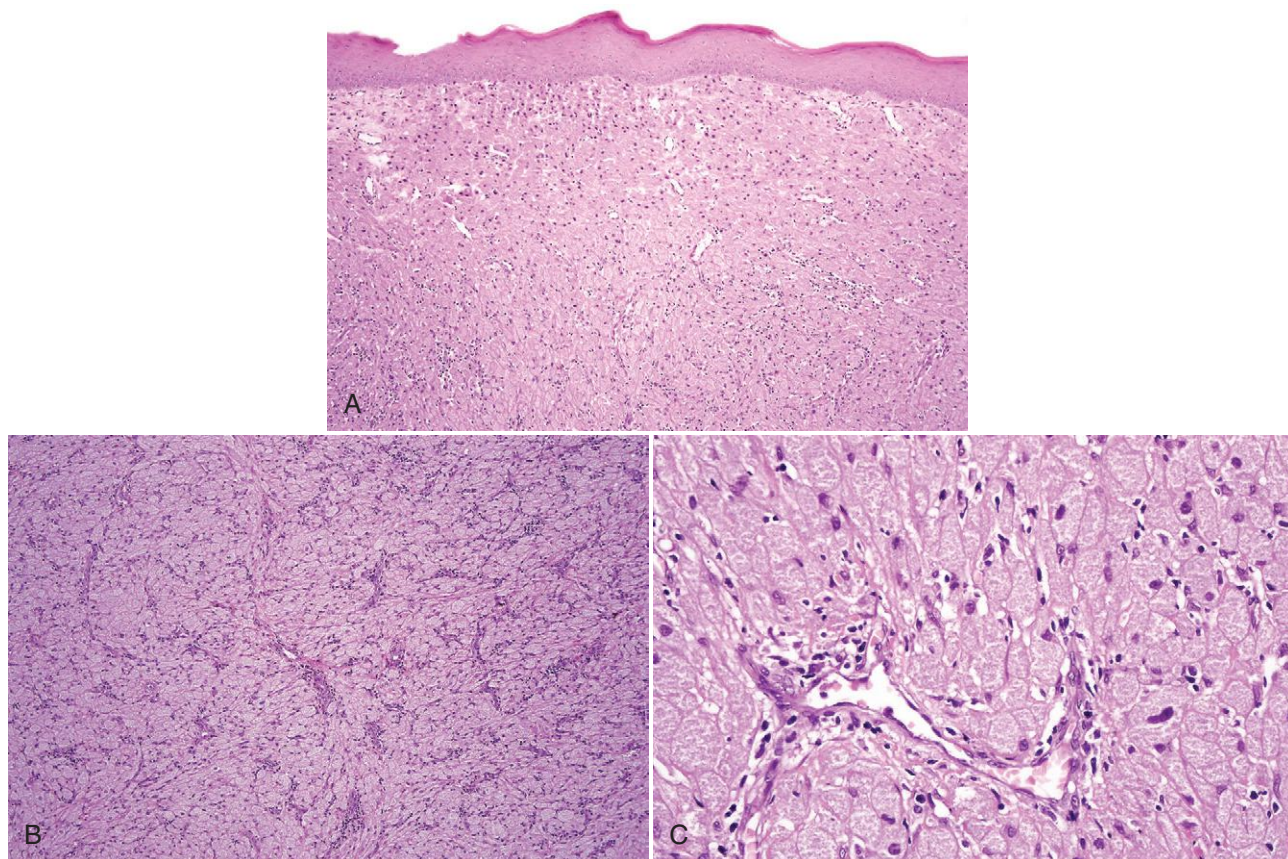
- Excision is curative.

### REFERENCES

- Damm DD. Investigation into the histogenesis of congenital epulis of the newborn. *Oral Surg Oral Med Oral Pathol.* 1993;76:205-212.
- Kupers AM, Andriessen P, van Kempen MJ, et al. Congenital epulis of the jaw: a series of five cases and review of literature. *Pediatr Surg Int.* 2009;25:207-210.
- Lack EE, Worsham GF, Callihan MD, et al. Gingival granular cell tumors of the newborn (i.e., congenital "epulis"): a clinical and pathologic study of 21 patients. *Am J Surg Pathol.* 1981;5:37-46.
- Vered M, Dobriyan A, Buchner A. Congenital granular cell epulis presents an immunohistochemical profile that distinguishes it from the granular cell tumor of the adult. *Virchows Arch.* 2009; 454:303-310.



**FIGURE 2-10.** Congenital granular cell tumor presenting as gingival mass. (Courtesy of Dr. Bonnie Padwa, Harvard School of Dental Medicine, Boston, Mass.)



**FIGURE 2-11.** Congenital granular cell tumor: **A**, Sheets of granular cells with no epithelial hyperplasia. **B**, Sheets of granular cells with many arborizing vessels. **C**, Cells with granular cytoplasm, defined cell borders, and small nuclei with inconspicuous nucleoli.

## OSSEOUS AND CARTILAGINOUS CHORISTOMAS

### Clinical Findings

- Osseous choristoma: pedunculated mass or nodule usually midline of posterior tongue (>90% of cases) near the foramen cecum; usually in young adults with female predilection (3 to 5:1)
- Cartilaginous choristoma: nodule in lateral tongue (>80% of cases) in adults

### Etiopathogenesis and Histopathologic Features

Possible etiologies include metaplastic bone or cartilage formation from trauma, developmental malformation from pluripotent stem cells in the soft tissues, or ossification of branchial arch remnants.

- Osseous choristoma: discrete proliferation of mature lamellar bone is evident (sometimes with mature adipose or hematopoietic tissue) (Fig. 2-12).
- Cartilaginous choristoma: mature hyaline cartilage with spindle cell proliferation or primitive mesenchyme, salivary gland tissue, or bone may be present.

### Differential Diagnosis

- Myoepithelioma with abundant bone and cartilage production will show a prominent spindle cell proliferation. (See Benign Salivary Gland Neoplasms in Chapter 16)
- Metaplastic cartilage is often seen in denture-related fibrous hyperplasias in the maxillary vestibule and in the nasopalatine duct area.
- Myositis ossificans shows distinct “zoning” phenomenon with many plump osteoblast-like cells.

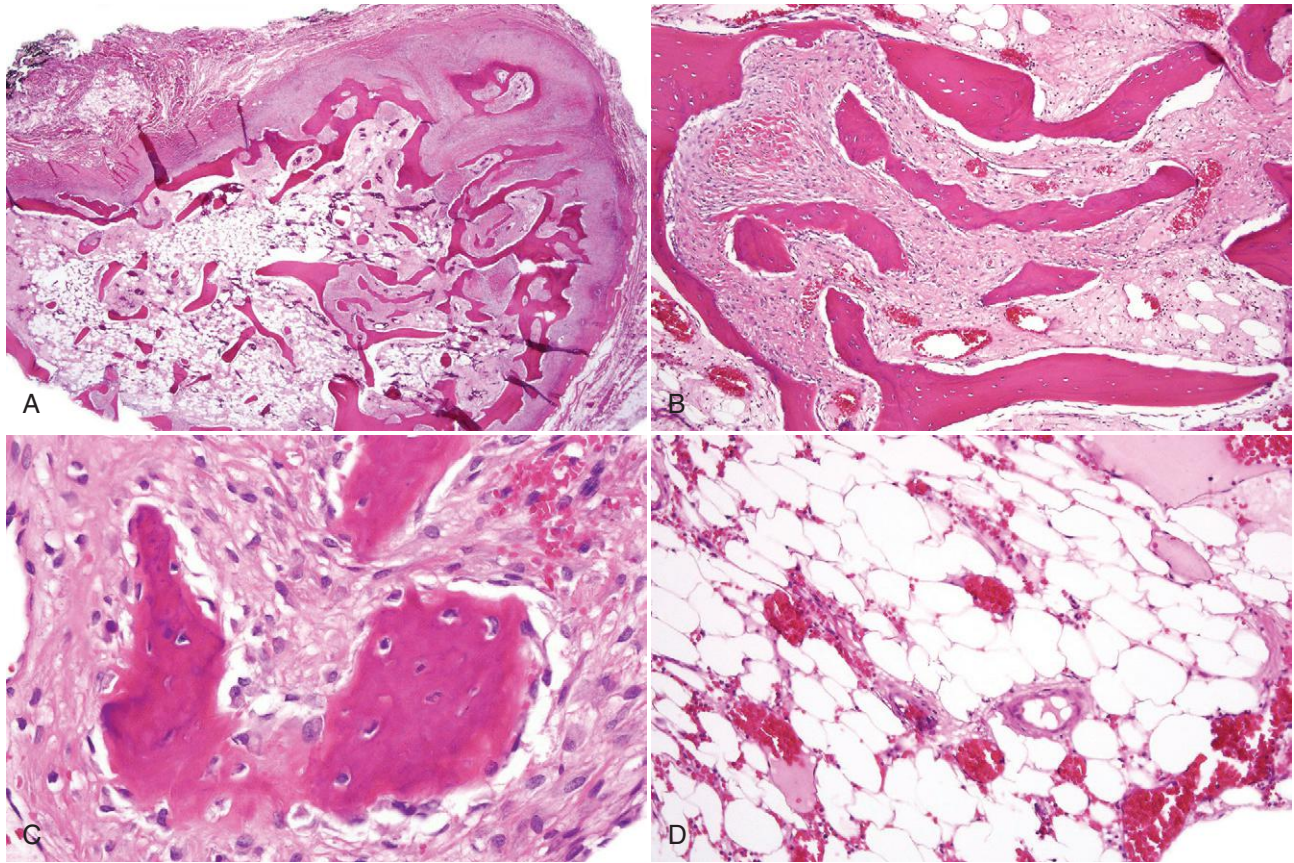
### Management and Prognosis

- Excision is curative.

### REFERENCES

- Chou LS, Hansen LS, Daniels TE. Choristomas of the oral cavity: a review. *Oral Surg Oral Med Oral Pathol.* 1991;72:584-593.
- Kamburoglu K, Ozen T, Sencimen M, et al. Osseous choristoma of the submandibular region: case report. *Dentomaxillofac Radiol.* 2009;38:489-492.
- Krolls SO, Jacoway JR, Alexander WN. Osseous choristomas (osteomas) of intraoral soft tissues. *Oral Surg Oral Med Oral Pathol.* 1971;32:588-595.
- Tohill MJ, Green JG, Cohen DM. Intraoral osseous and cartilaginous choristomas: report of three cases and review of the literature. *Oral Surg Oral Med Oral Pathol.* 1987;63:506-510.





**FIGURE 2-12.** Osteolipomatous choristoma. **A**, Encapsulated mass of cellular fibrous tissue, viable lamellar bone, and mature fat. **B**, Cellular areas consist of fibrous tissue containing many plump fibroblasts and woven bone. **C**, Bone with osteoclasts. **D**, Mature lipocytes are present.

## GINGIVAL FIBROMATOSIS

### Clinical Findings

- Diffuse overgrowth of densely fibrous gingival tissue of the mandible and/or maxilla occurs, usually in the first decade of life during eruption of permanent teeth (Fig. 2-13).
- Localized versions occur especially in area of the maxillary tuberosity, bilaterally.
- Gingival fibromatosis is associated with some syndromes (such as Zimmerman-Laband and Rutherford syndromes); syndromic patients may also be taking medications used to control seizures (e.g., phenytoin) and these can aggravate the gingival hyperplasia.

### Etiopathogenesis and Histopathologic Features

The gene for the nonsyndromic, autosomal dominant form is localized to chromosome 2p and inherited in an autosomal dominant or recessive manner. There is increased production and reduced metabolism of collagen and ground substance, possibly because of reduced matrix metalloproteinase activity mediated by transforming growth factor beta-1.

- Proliferation of densely collagenized fibrous tissue in short fascicles with benign, plump, stellate-shaped fibroblasts; generally paucicellular (Fig. 2-14)

### Differential Diagnosis

- Inherited systemic hyalinosis (mild form formerly known as juvenile hyaline fibromatosis and more severe form, infantile systemic hyalinosis) is an autosomal recessive condition and manifests with fibrous skin nodules, bone lesions, and joint contractures; gingival overgrowths consist of densely hyalinized, paucicellular stromal deposits that resemble chondroid material or amyloid; there is a mutation in the ANTXR2 gene (formerly capillary morphogenesis factor-2 gene) mapped to chromosome 4q21 (Fig. 2-15).
- Myofibromatosis usually is more cellular with longer sweeping fascicles of collagen; clinically, lesions are discrete.

### Management and Prognosis

- Excision and recontouring help esthetics; maintenance of good oral hygiene (with use of antimicrobial oral rinses) reduces severity of recurrence.



## REFERENCES

Breen GH, Addante R, Black CC. Early onset of hereditary gingival fibromatosis in a 28-month-old. *Pediatr Dent.* 2009;31:286-288.

Casavecchia P, Uzel MI, Kantarci A, et al. Hereditary gingival fibromatosis associated with generalized aggressive periodontitis: a case report. *J Periodontol.* 2004;75:770-778.

Coletta RD, Graner E. Hereditary gingival fibromatosis: a systematic review. *J Periodontol.* 2006;77:753-764.

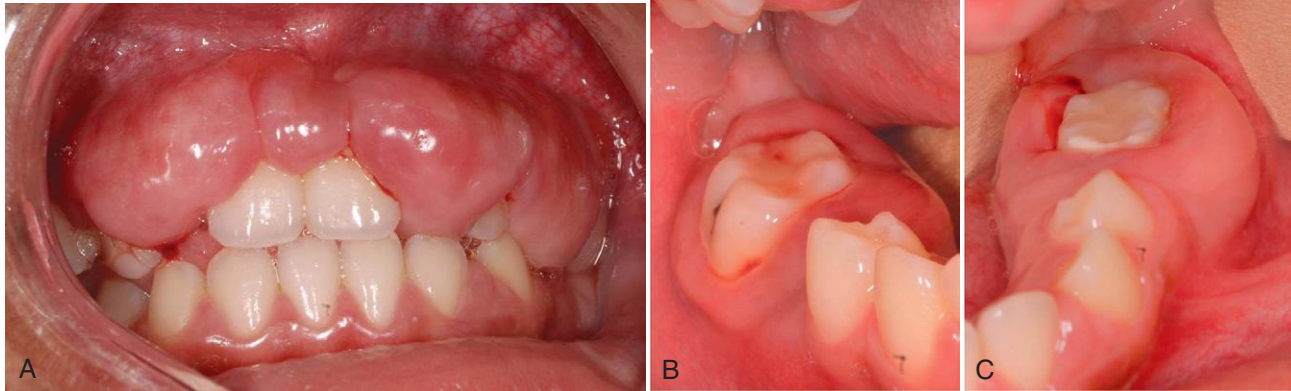
Dowling O, Difeo A, Ramirez MC, et al. Mutations in capillary morphogenesis gene-2 result in the allelic disorders juvenile hyaline

fibromatosis and infantile systemic hyalinosis. *Am J Hum Genet.* 2003;73:957-966.

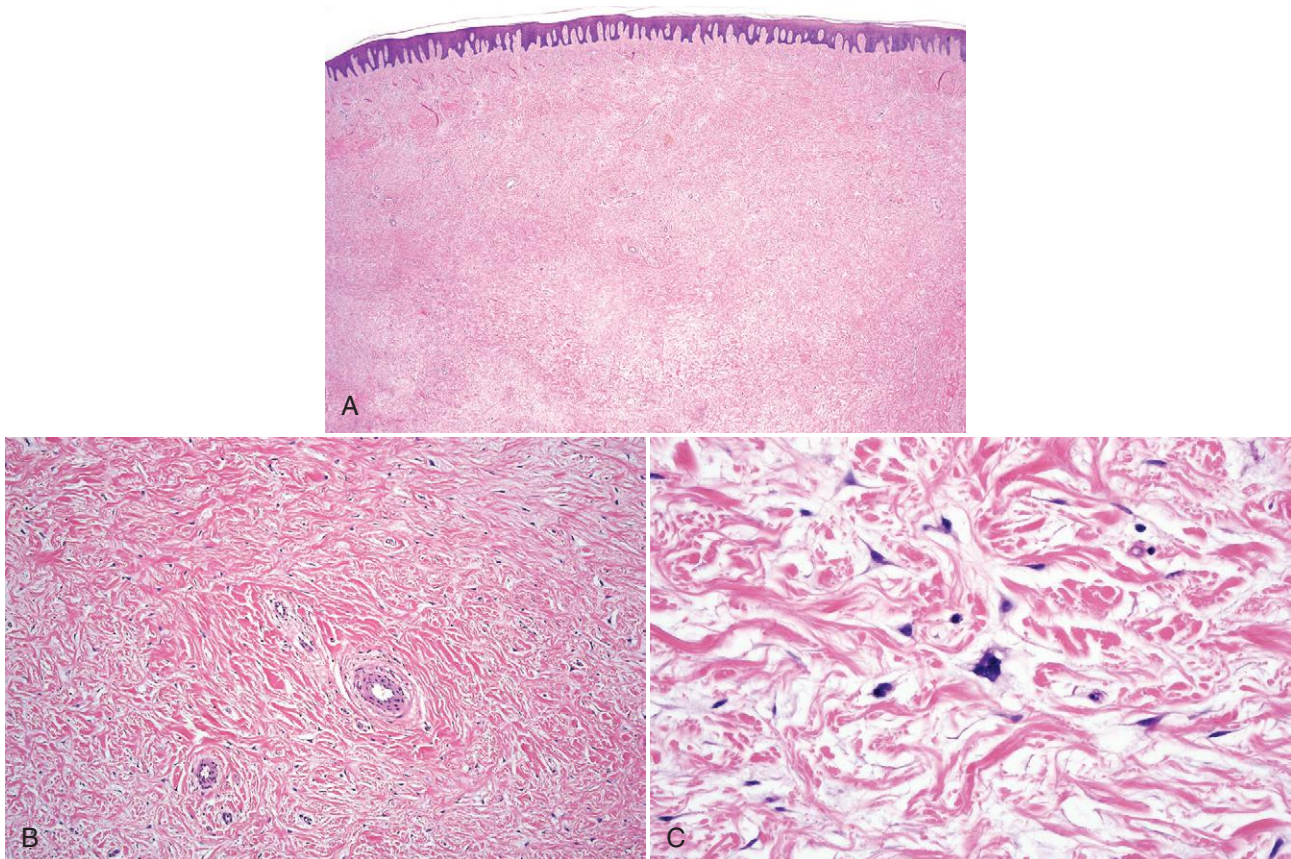
Hart TC, Pallos D, Bozzo L, et al. Evidence of genetic heterogeneity for hereditary gingival fibromatosis. *J Dent Res.* 2000;79:1758-1764.

Muniz ML, Lobo AZ, Machado MC, et al. Exuberant juvenile hyaline fibromatosis in two patients. *Pediatr Dermatol.* 2006;23:458-464.

Shieh JT, Swidler P, Martignetti JA, et al. Systemic hyalinosis: a distinctive early childhood-onset disorder characterized by mutations in the anthrax toxin receptor 2 gene (ANTRX2). *Pediatrics.* 2006;118:e1485-1492.

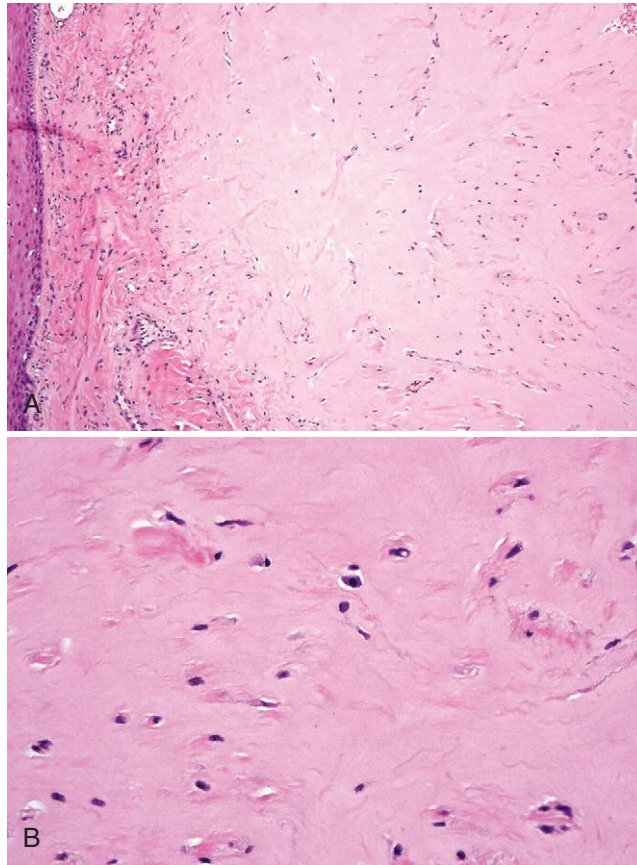


**FIGURE 2-13.** Gingival fibromatosis. **A**, Culky symmetric overgrowth of maxillary gingiva. **B**, Overgrowth of right mandibular gingiva. **C**, Overgrowth of left mandibular gingiva. (Courtesy of Nalton Ferraro DMD, MD, Children's Hospital Boston, Boston, Mass.)



**FIGURE 2-14.** Gingival fibromatosis. **A**, Marked proliferation of dense fibrocollagenous tissue without epithelial hyperplasia. **B**, Dense collagen with spindled and stellate fibroblasts. **C**, Stellate-shaped and multinucleated fibroblasts.





**FIGURE 2-15.** Inherited systemic hyalinosis. **A**, Amorphous, eosinophilic deposits in the gingiva. **B**, Plump fibroblasts in chondroid-like material.

## GASTROINTESTINAL AND BRAIN HETEROTOPIAS

### Clinical Findings

- Mass in the tongue or floor of mouth in infants or neonates, often in the midline, near the foramen cecum associated with sinus tracts

### Etiopathogenesis and Histopathologic Features

Heterotopias are likely caused by entrapped or displaced gastrointestinal tissues.

- Gastrointestinal heterotopia: lined by epithelium typical for the cardiac, fundic, or pyloric regions of the stomach with parietal and Paneth cells; some are lined by colonic and/or ciliated epithelium; pancreatic tissue may be identified (Fig. 2-16)

- Brain heterotopia: astrocytes, oligodendrocytes, ependymal tissue, choroid plexus-like tissue and, rarely, neuronal tissue identified (Fig. 2-17)

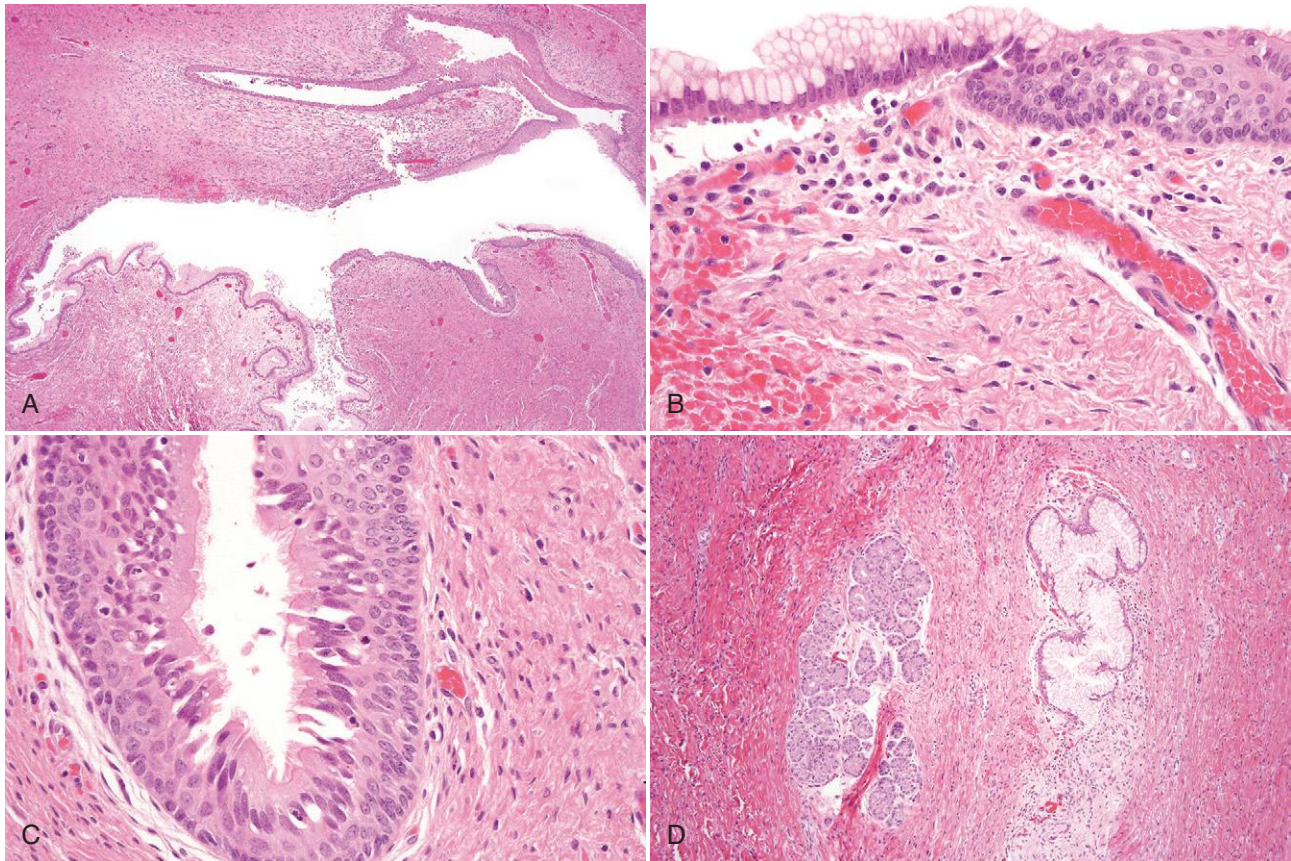
### Management and Prognosis

- Excision is curative.

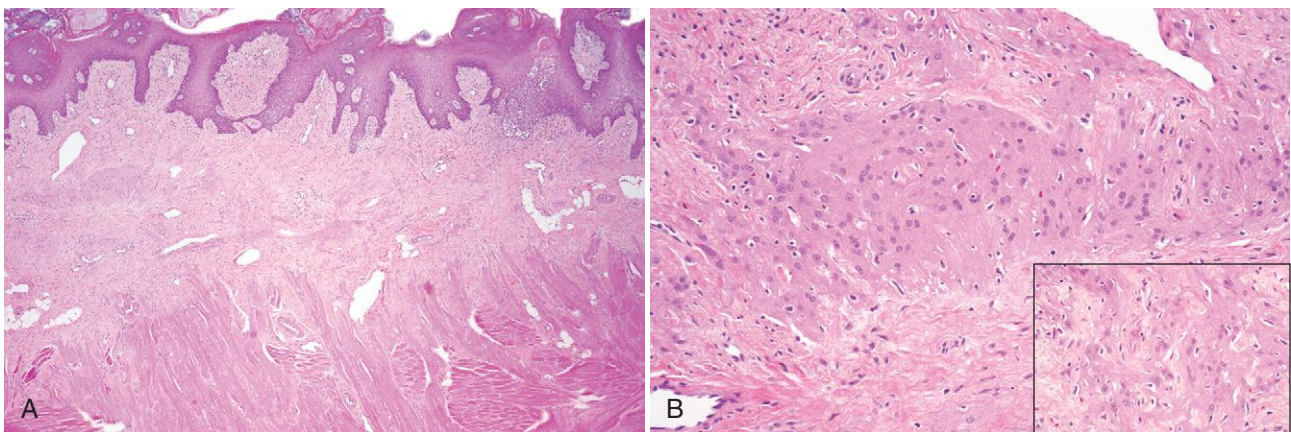
### REFERENCES

- Chou LS, Hansen LS, Daniels TE. Choristomas of the oral cavity: a review. *Oral Surg Oral Med Oral Pathol.* 1991;72:584-593.
- Khunamornpong S, Yousukh A, Tananuvat R. Heterotopic gastrointestinal and pancreatic tissue of the tongue: a case report. *Oral Surg Oral Med Oral Pathol Oral Radiol Endod.* 1996;81:576-579.
- Lui B, Korman B. Congenital oral heterotopic gastrointestinal cyst: case report and review of the literature. *J Otolaryngol Head Neck Surg.* 2008;37:E151-154.
- Sun LS, Sun ZP, Ma XC, Li TJ. Glial choristoma in the oral and maxillofacial region: a clinicopathologic study of 6 cases. *Arch Pathol Lab Med.* 2008;132:984-988.





**FIGURE 2-16.** Heterotopic gastrointestinal cyst. **A**, Cyst lined by uniformly thin epithelium with mucous cells. **B**, Transition between stratified squamous and mucous cells (resembling gastric lining). **C**, Ciliated epithelium also common. **D**, Islands of pancreatic tissue. (**A**, Courtesy of Dr. Lee Slater, Scripps Institute, San Diego.)



**FIGURE 2-17.** Heterotopic brain tissue. **A**, Pale epithelioid cells lying within the tongue mucosa above skeletal muscle. **B**, Glial tissue (inset).



## LYMPHANGIOMA OF THE ALVEOLAR RIDGE IN NEONATES

### Clinical Findings

- Four percent of infants, almost exclusively black infants
- Dome-shaped, 3- to 4-mm, bluish, fluid-filled nodules in the posterior maxillary and mandibular alveolar ridge; usually multiple lesions present

### Etiopathogenesis and Histopathologic Features

Etiopathogenesis is unknown and is more likely to represent lymphatic ectasia.

- Typical endothelium-lined spaces filled with amorphous eosinophilic material; may see odontogenic rests

### Differential Diagnosis

- Indistinguishable from lymphatic malformation or lymphangioma circumscriptum found in older patients

### Management and Prognosis

- No treatment; resolves by 6 months of age

### REFERENCES

- FitzGerald K, Barry S, Fleming P. Alveolar lymphangioma in infants: report of two cases. *J Ir Dent Assoc.* 2009;55:144-145.
- Friend GW, Harris EF, Mincer HH, et al. Oral anomalies in the neonate, by race and gender, in an urban setting. *Pediatr Dent.* 1990;12:157-161.
- Wilson S, Gould AR, Wolff C. Multiple lymphangiomas of the alveolar ridge in a neonate: case study. *Pediatr Dent.* 1986;8:231-234.

## LINGUAL THYROID

### Clinical Findings

- Occurs in first to second decade, and fifth to sixth decade with female predilection (7:1); can lead to dysphagia and dyspnea; up to 25% of patients are hypothyroid
- Detectable soft mass between foramen cecum and epiglottis in midline posterior to the circumvallate papillae

### Etiopathogenesis and Histopathologic Features

This may represent remnants of thyroid tissue or an entire undescended thyroid; nuclear scans show presence of thyroid tissue.

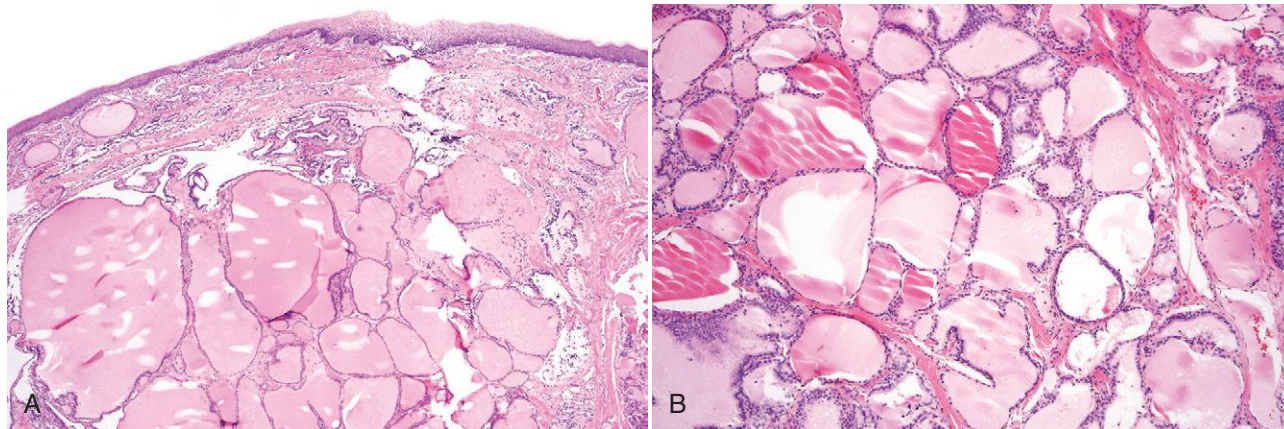
- Mature or embryonic thyroid epithelium with microfollicular, macrofollicular, or adenomatous changes (Fig. 2-18); may be associated with thyroglossal duct

### Management and Prognosis

- If this represents undescended thyroid, removal leads to hypothyroidism and requires repletion.
- Follicular, papillary, and medullary carcinomas have been reported.

### REFERENCES

- Chou LS, Hansen LS, Daniels TE. Choristomas of the oral cavity: a review. *Oral Surg Oral Med Oral Pathol.* 1991;72:584-593.
- Diaz-Arias AA, Bickel JT, Loy TS, et al. Follicular carcinoma with clear cell change arising in lingual thyroid. *Oral Surg Oral Med Oral Pathol.* 1992;74:206-211.
- Kamat MR, Kulkarni JN, Desai PB, Jussawalla DJ. Lingual thyroid: a review of 12 cases. *Br J Surg.* 1979;66:537-539.
- Rahbar R, Yoon MJ, Connolly LP, et al. Lingual thyroid in children: a rare clinical entity. *Laryngoscope.* 2008;118:1174-1179.
- Yaday S, Singh I, Singh J, Aggarwal N. Medullary carcinoma in a lingual thyroid. *Singapore Med J.* 2008;49:251-253.



**FIGURE 2-18.** Lingual thyroid. **A**, Mass of thyroid tissue with overlying oral epithelium. **B**, Normal thyroid follicles filled with colloid. (A, Courtesy of Dr. Harry Kozakewich, Harvard Medical School, Boston, Mass.)

## LEIOMYOMATOUS HAMARTOMA

### Clinical Features

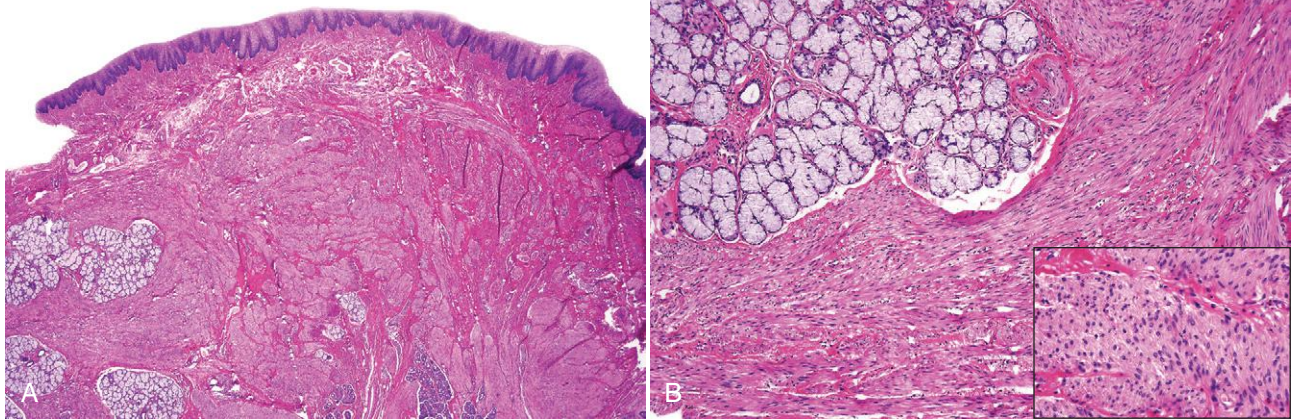
- Soft, painless polypoid mass usually on the tongue and anterior maxilla/palate (area of the nasopalatine foramen)

### Etiopathogenesis and Histopathologic Features

- Nonencapsulated proliferation of fusiform and spindle smooth muscle cells that express HHF-35, smooth muscle actin, and desmin but not S-100 protein (Fig. 2-19)

### Management and Prognosis

- Excision is curative.



**FIGURE 2-19.** Leiomyomatous hamartoma of tongue. **A**, Mass of spindle cells within the tongue. **B**, Spindled smooth muscle cells with pale eosinophilic cytoplasm surround salivary glands.

## Cystic Lesions

### ORAL LYMPHOEPITHELIAL CYST (BENIGN LYMPHOEPITHELIAL CYST)

#### Clinical Findings

- Usually occurs in third to fourth decade; yellowish, painless, soft nodule of the soft palate or tonsillar pillars, floor of mouth, or posterior tongue; filled with cheesy, keratinaceous material (Fig. 2-20, A)

#### Etiopathogenesis and Histopathologic Features

Lymphoepithelial cysts may arise from entrapped embryonic epithelial remnants of surface epithelium or salivary ducts, or from blocked crypts of lingual or ectopic tonsils. They are histologically indistinguishable from parotid lymphoepithelial cysts often seen in patients with HIV infection (see Fig. 2-20, B).

- Lining is composed of parakeratotic, uniformly thin (5 to 10 cells) stratified squamous epithelium often with prominent lymphocyte exocytosis, surrounded partially or completely by a mantle of lymphocytes that may exhibit germinal centers; lumen filled with

keratinaceous material; infrequently mucous cells or respiratory epithelium is present (Figs. 2-21 and 2-22).

#### Differential Diagnosis

- Hyperplastic lingual tonsils are not as obviously cystic, although blockage of the crypt opening often leads to retention of secretions, and the two may become indistinguishable (Figs. 2-23 and 2-24).
- Salivary duct cysts do not exhibit a lymphocytic mantle.
- Epithelial inclusion cysts are orthokeratotic and do not exhibit a lymphocytic mantle.

#### Management and Prognosis

- Excision is curative.

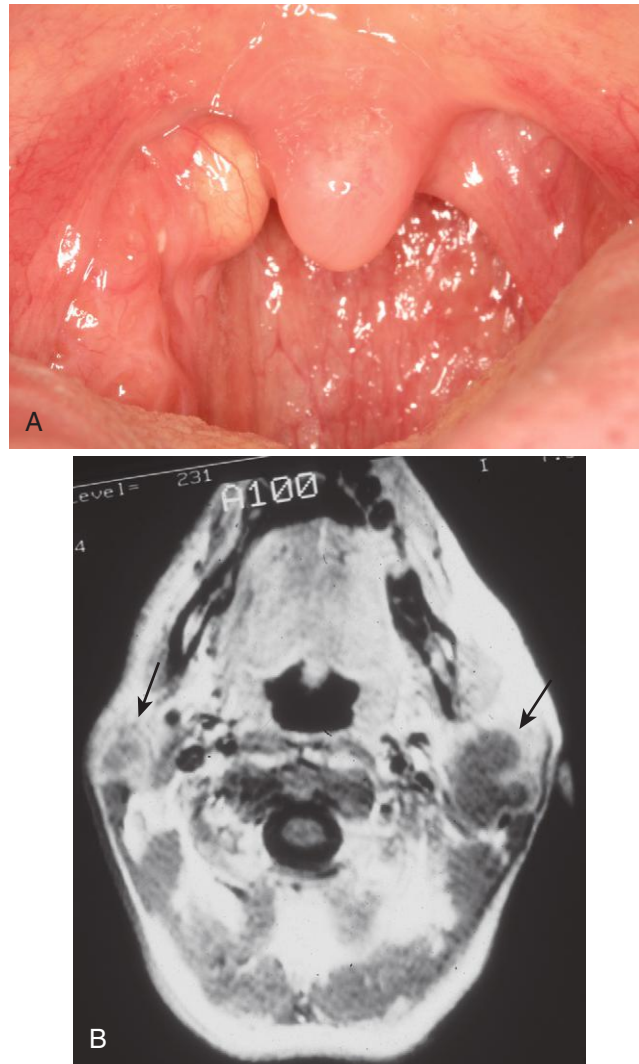
#### REFERENCES

- Buchner A, Hansen LS. Lymphoepithelial cysts of the oral cavity. A clinicopathologic study of thirty-eight cases. *Oral Surg Oral Med Oral Pathol.* 1980;50:441-449.
- Chaudhry AP, Yamane GM, Scharlock SE, et al. A clinico-pathological study of intraoral lymphoepithelial cysts. *J Oral Med.* 1984;39:79-84.
- Wu L, Cheng J, Maruyama S, et al. Lymphoepithelial cyst of the parotid gland: its possible histopathogenesis based on clinicopathologic analysis of 64 cases. *Hum Pathol.* 2009;40:683-692.

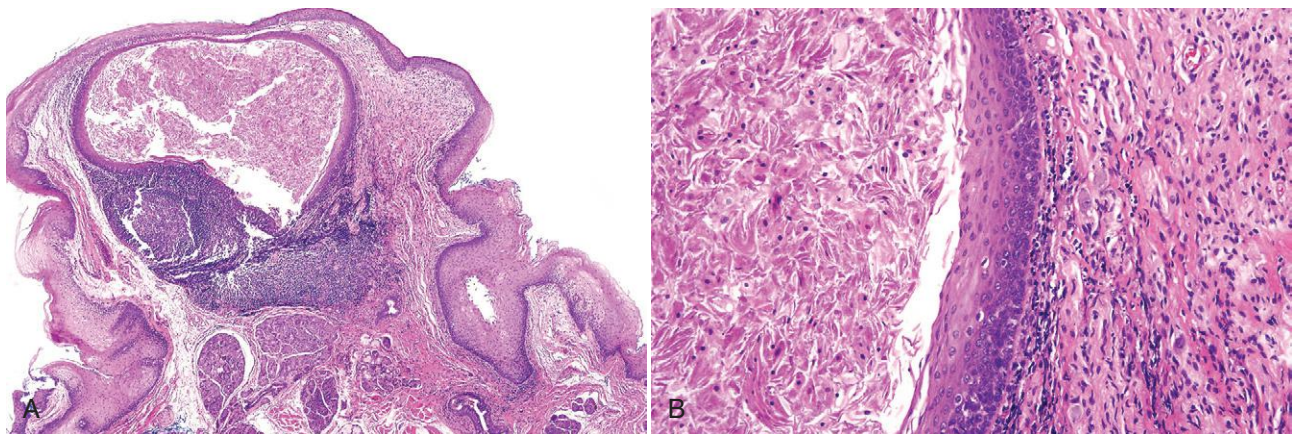
#### REFERENCES

- de Faria PR, Batista JD, Duriguetto AF Jr, et al. Giant leiomyomatous hamartoma of the tongue. *J Oral Maxillofac Surg.* 2008;66:1476-1480.
- Nava-Villalba M, Ocampo-Acosta F, Seamanduras-Pacheco A, Aldape-Barrios BC. Leiomyomatous hamartoma: report of two cases and review of the literature. *Oral Surg Oral Med Oral Pathol Oral Radiol Endod.* 2008;105:e39-45.
- Semba I, Kitano M, Mimura T. Gingival leiomyomatous hamartoma: immunohistochemical and ultrastructural observations. *J Oral Pathol Med.* 1993;22:468-470.
- Takeda Y, Satoh M, Nakamura S, Matsumoto D. Congenital leiomyomatous epulis: a case report with immunohistochemical study. *Pathol Int.* 2000;50:999-1002.



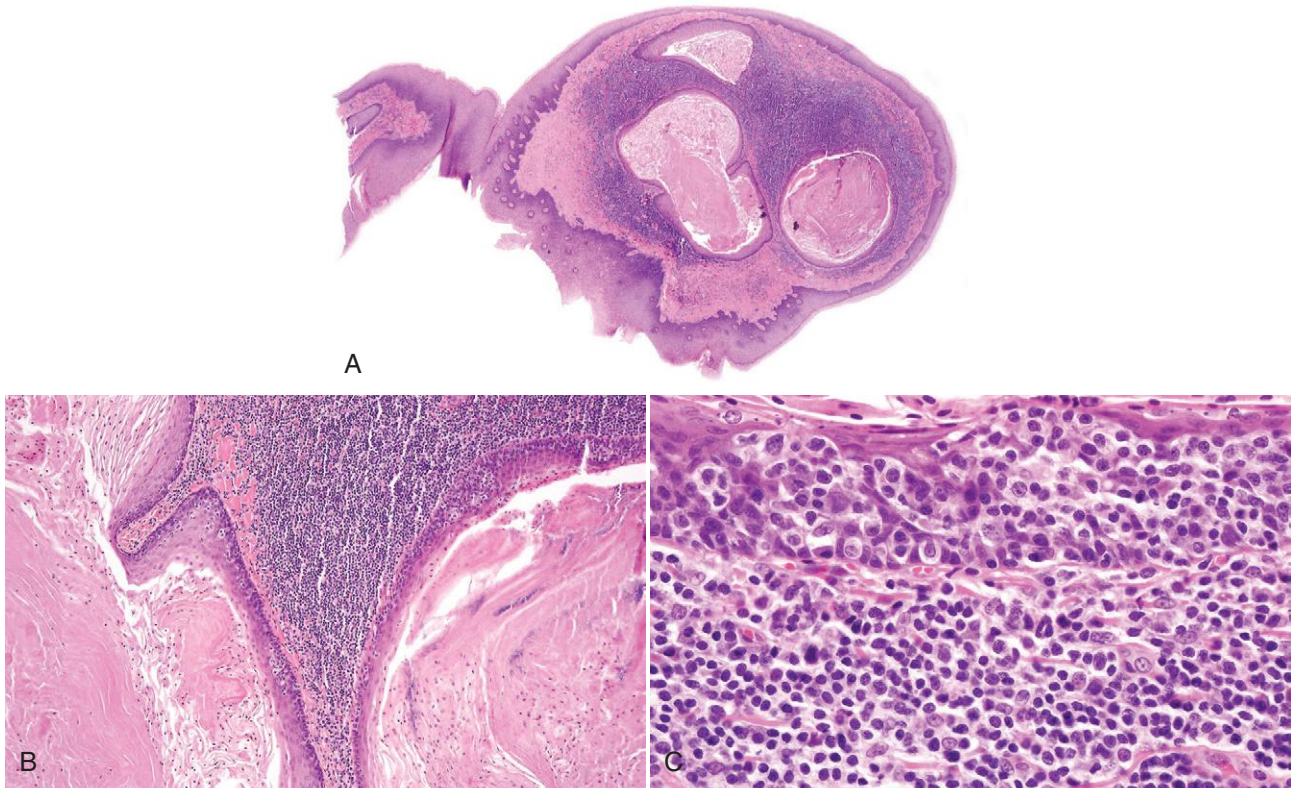


**FIGURE 2-20.** **A**, Lymphoepithelial cyst of the right tonsillar pillar. **B**, Lymphoepithelial cyst, bilateral of the parotid (*arrows*) in a patient with HIV/AIDS.

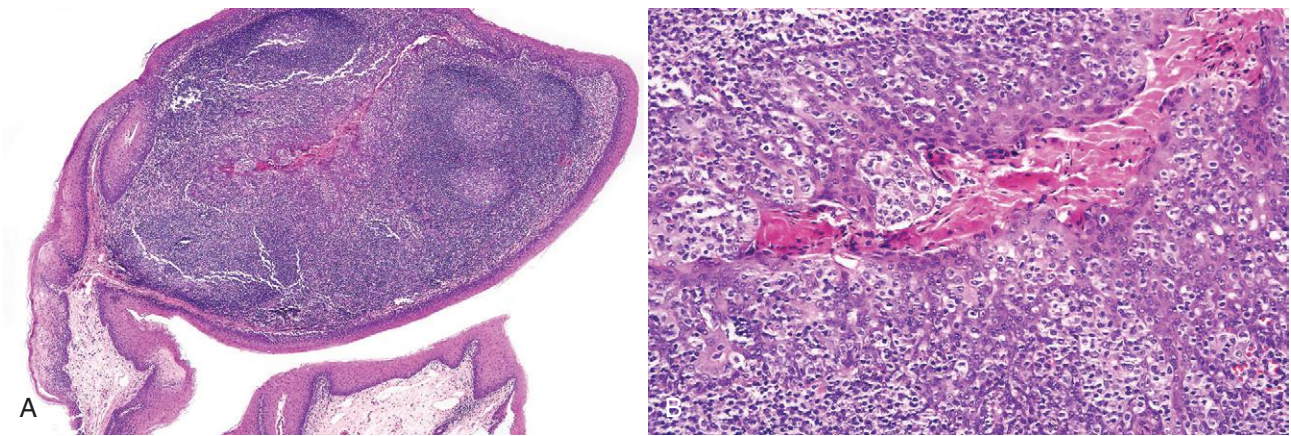


**FIGURE 2-21.** Oral lymphoepithelial cyst. **A**, Raised nodule composed of a cyst filled with keratin and partially surrounded by lymphoid tissue. **B**, Cyst lined by parakeratotic stratified squamous epithelium; note ganglion-like cells surrounded by neural tissue typical for a subgemmal neurogenous plaque.



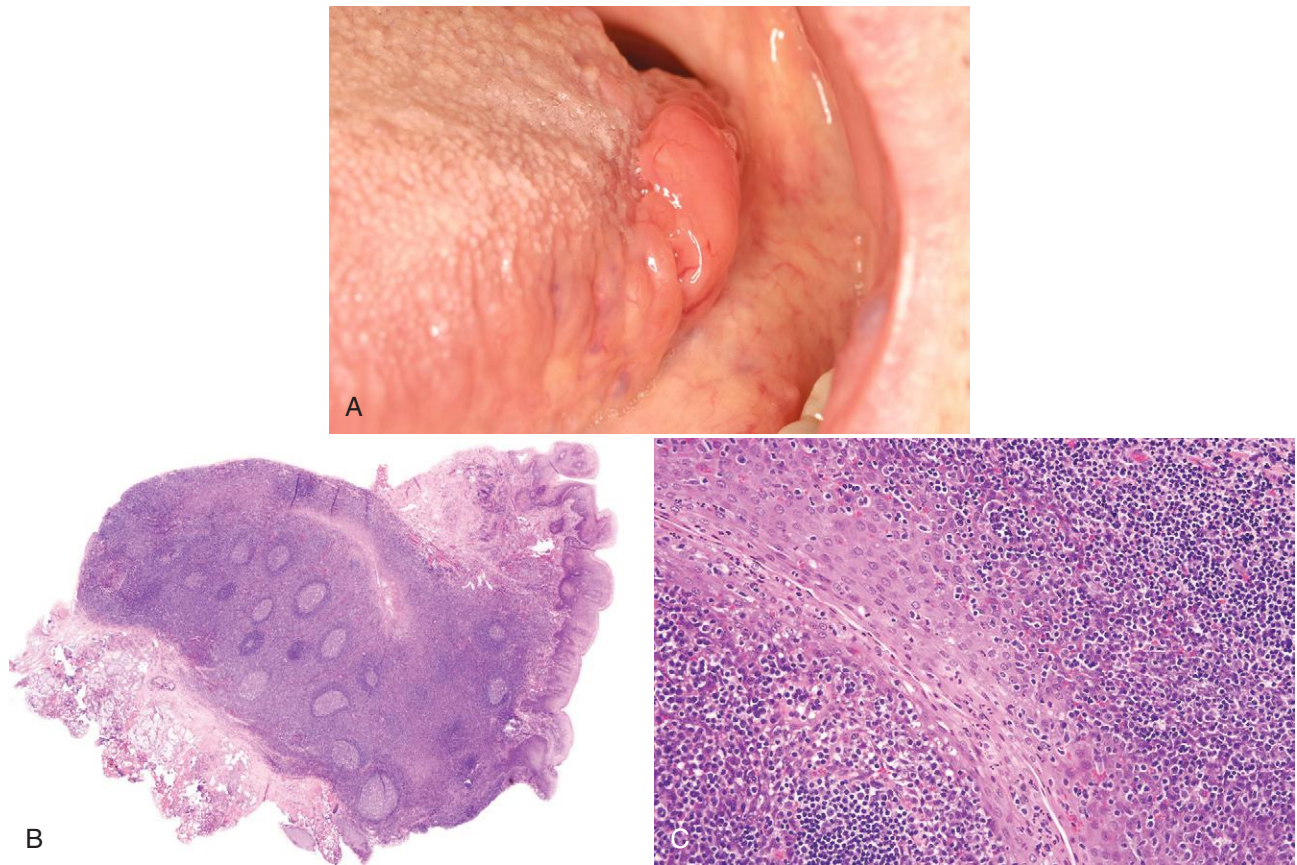


**FIGURE 2-22.** Oral lymphoepithelial cyst. **A**, Convoluted cyst almost entirely surrounded by lymphocytes appearing multicystic. **B**, Cyst lined by uniformly thin parakeratotic stratified squamous epithelium. **C**, Parts of the cyst lining exhibit marked lymphocyte exocytosis.



**FIGURE 2-23.** Hyperplastic lingual tonsil. **A**, Crypt surrounded by lymphoid tissue exhibiting follicular hyperplasia. **B**, Parakeratin in crypt and marked lymphocyte exocytosis.





**FIGURE 2-24.** Hyperplastic lingual tonsil. **A**, Sessile protuberance in the posterior-lateral tongue. **B**, Benign follicular hyperplasia of lymphoid tissue surrounding a crypt. **C**, Crypt epithelium exhibits prominent leukocyte exocytosis similar to lymphoepithelial cyst.

## EPIDERMOID (EPITHELIAL INCLUSION) AND DERMOID CYSTS

### Clinical Findings

- Dome-shaped, doughy, painless yellow nodules and masses, usually in the midline of floor of mouth in children and young adults; may be congenital; often located above the geniohyoid or between the geniohyoid and mylohyoid; slight male predilection (3:1); rare cases on the buccal mucosa (Fig. 2-25)

### Etiopathogenesis and Histopathologic Features

The epithelium arises from displaced epithelium or entrapped epithelial rests during embryonic fusion. It is similar to the epidermal inclusion cyst of the skin.

- Epidermoid cyst (most common): lined by orthokeratinized stratified squamous epithelium 5 to 10 cells thick with lumen filled with keratin (Fig. 2-26); rupture results in foreign body granulomatous reaction
- Dermoid cyst: similar to epidermoid cyst but contains hair follicles, sebaceous glands, or eccrine structures (Fig. 2-27)

### Differential Diagnosis

- If tissue from all three germ layers is present, diagnosis is teratoid cyst.

- Gingival cyst of the newborn has similar histology but is located on the gingiva; gingival cyst of the adult is infrequently keratinizing.
- Dermoid tumors are solid tumors usually located on the soft palate, covered by skin with adnexal structures—often with a mesodermal component (known as a “hairy polyp”).

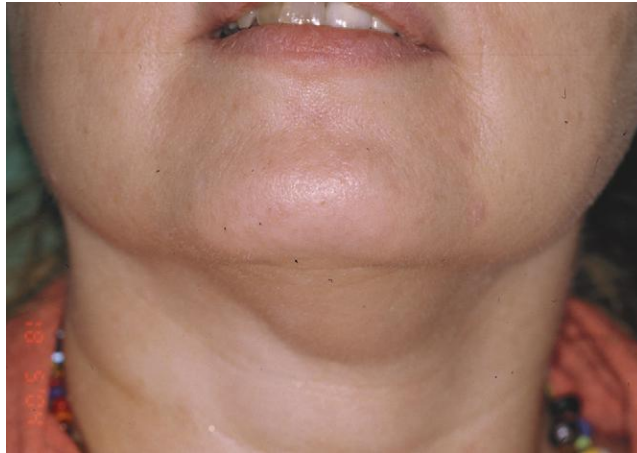### Management and Prognosis

- Excision is curative.

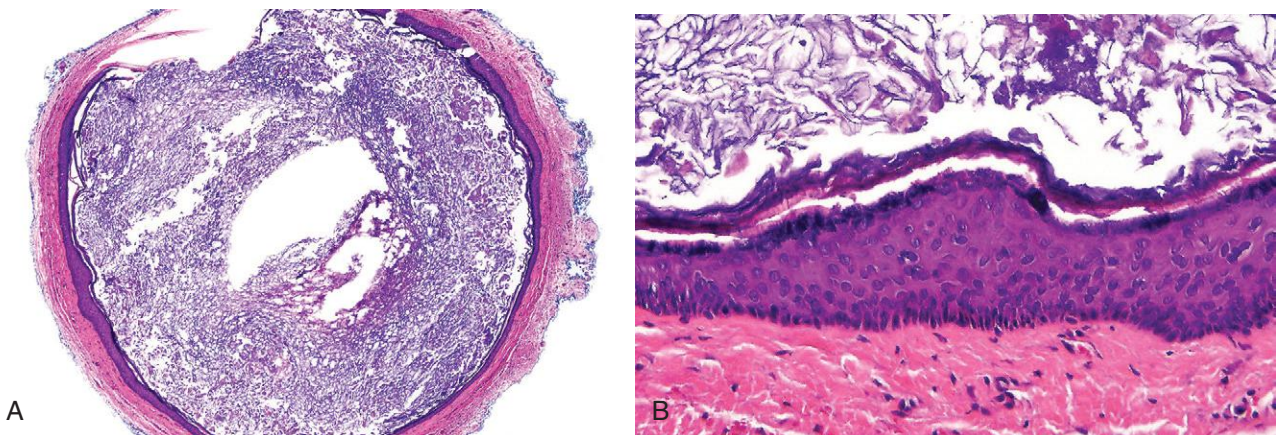
### REFERENCES

- Coppit GL 3rd, Perkins JA, Manning SC. Nasopharyngeal teratomas and dermoids: a review of the literature and case series. *Int J Pediatr Otorhinolaryngol.* 2000;52:219-227.
- Kelly A, Bough Jr ID, Luft JD, et al. Hairy polyp of the oropharynx: case report and literature review. *J Pediatr Surg.* 1996;31:704-706.
- Longo F, Maremonti P, Mangone GM, et al. Midline (dermoid) cysts of the floor of the mouth: report of 16 cases and review of surgical techniques. *Plast Reconstr Surg.* 2003;112:1560-1565.
- Oygur T, Dursun A, Uluoglu O, Dursun GA. Oral congenital dermoid cyst in the floor of the mouth of a newborn. The significance of gastrointestinal-type epithelium. *Oral Surg Oral Med Oral Pathol.* 1992;74:627-630.
- Rajayogeswaran V, Eveson JW. Epidermoid cyst of the buccal mucosa. *Oral Surg Oral Med Oral Pathol.* 1989;67:181-184.

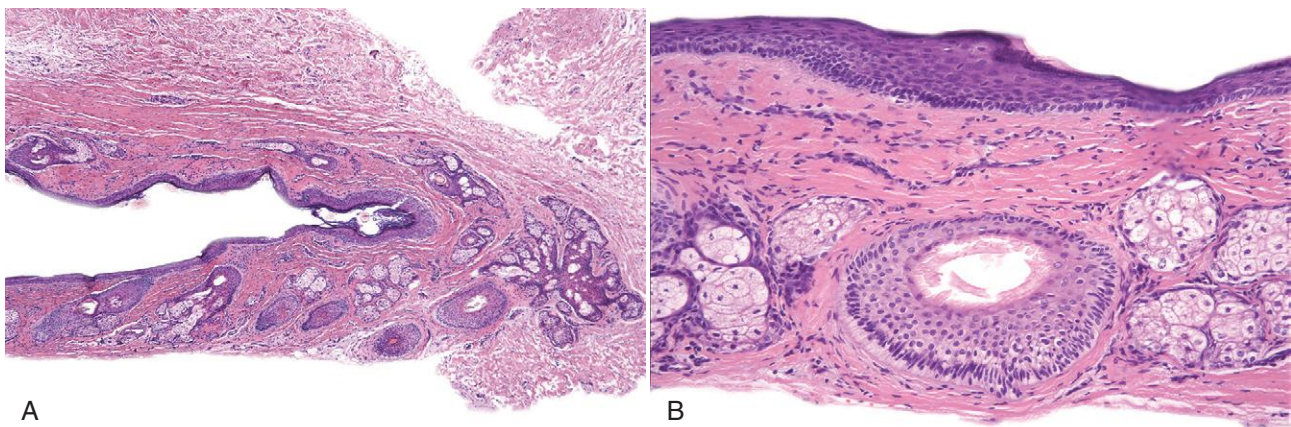




**FIGURE 2-25.** Dermoid cyst: soft tissue swelling located beneath the mylohyoid.



**FIGURE 2-26.** Epidermoid cyst. **A**, Cyst lined by orthokeratinized stratified squamous epithelium and filled with keratin. **B**, Cyst lined by orthokeratinized stratified squamous epithelium that is uniformly thin with prominent granular cell layer.



**FIGURE 2-27.** Dermoid cyst. **A**, Cyst with pilosebaceous units in the wall. **B**, Lining is orthokeratinized stratified squamous epithelium that is uniformly thin with granular layer and pilosebaceous units in the wall.



## PALATAL AND GINGIVAL CYSTS OF THE NEONATE

### Clinical Findings

- Yellowish milia-like papules on the midline of the palate, junction of hard and soft palate, or gingiva in newborn with a frequency of 10% to 70% (Fig. 2-28).

### Etiopathogenesis and Histopathologic Features

Cysts in the midline of the palate (Epstein pearls) and gingiva (original Bohn nodules) are likely epithelial inclusion cysts formed from entrapped embryonic epithelium during fusion of palatal shelves and dental lamina rests, respectively. The ones at the junction of the hard and soft palate, sometimes also referred to as Bohn nodules are likely caused by blocked excretory salivary ducts, rather than use eponyms, it is preferable

to refer to these as palatal or gingival cysts of the neonate.

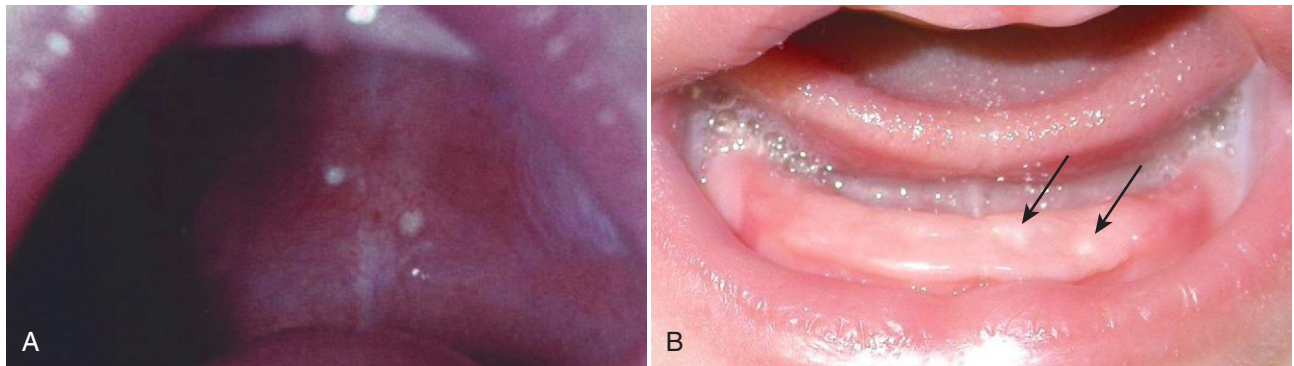
- Simple cysts lined by three to five layers of stratified squamous epithelium, often filled with keratin

### Management and Prognosis

- Biopsy not indicated because they usually exteriorize on their own.

### REFERENCES

- Friend GW, Harris EF, Mincer HH, et al. Oral anomalies in the neonate, by race and gender, in an urban setting. *Pediatr Dent.* 1990;12:157-161.
- George D, Bhat SS, Hegde SK. Oral findings in newborn children in and around Mangalore, Karnataka State, India. *Med Princ Pract.* 2008;17:385-389.
- Paula JD, Dezan CC, Frossard WT, et al. Oral and facial inclusion cysts in newborns. *J Clin Pediatr Dent.* 2006;31:127-129.



**FIGURE 2-28.** **A**, Palatal cysts of the newborn: milia-like yellow papules of the palate. **B**, Gingival lamina cyst of the newborn: cysts of the left mandibular ridge in a patient with a cleft lip (arrows). (**A**, Courtesy of Dr. Bonnie Padwa, Harvard School of Dental Medicine, Boston, Mass; **B**, Courtesy of Dr. Catherine Flaitz, The University of Texas Dental Branch at Houston, Tex.)

## CYST OF THE INCISIVE PAPILLA

### Clinical Findings

- Swelling, usually less than 1 cm, of the incisive papilla without underlying bone involvement (Fig. 2-29)

### Etiopathogenesis and Histopathologic Features

Epithelium likely derives from rests of the nasopalatine duct within soft tissues.

- Cyst lined by ciliated, pseudostratified columnar epithelium with mucous cells, flattened low cuboid epithelium, or two to five layers of nonkeratinized stratified squamous epithelium; neurovascular bundles may or may not be present; minimal inflammation (Figs. 2-30 and 2-31)

### Differential Diagnosis

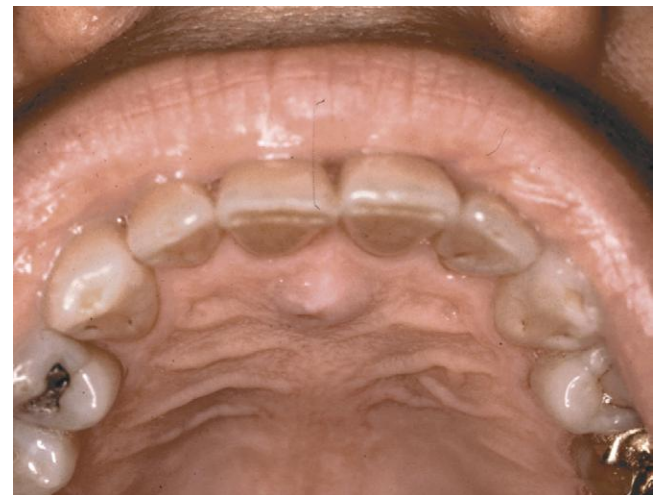- Nasopalatine duct cyst has similar histology but is present within bone (see Chapter 16).

### Management and Prognosis

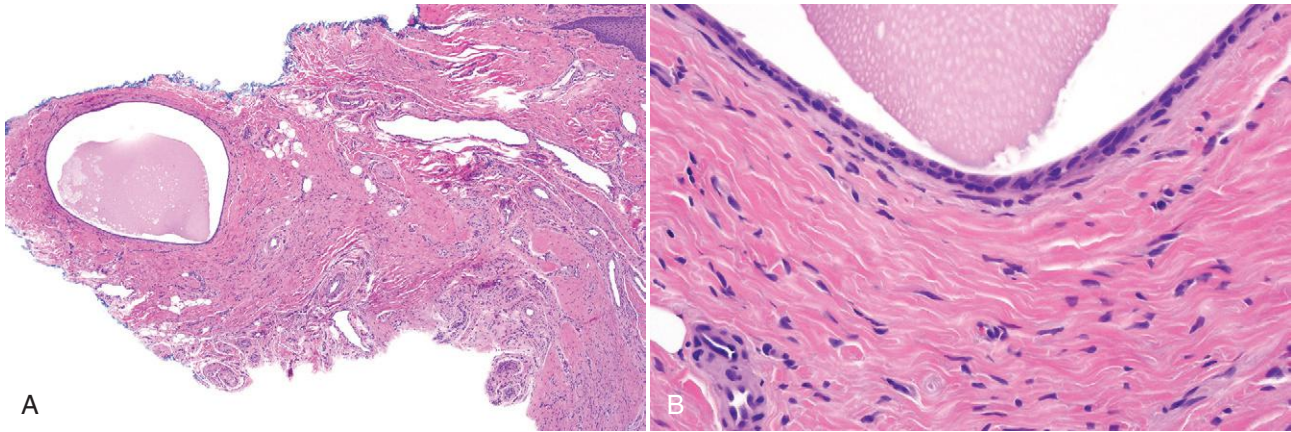
- Excision is curative.

### REFERENCE

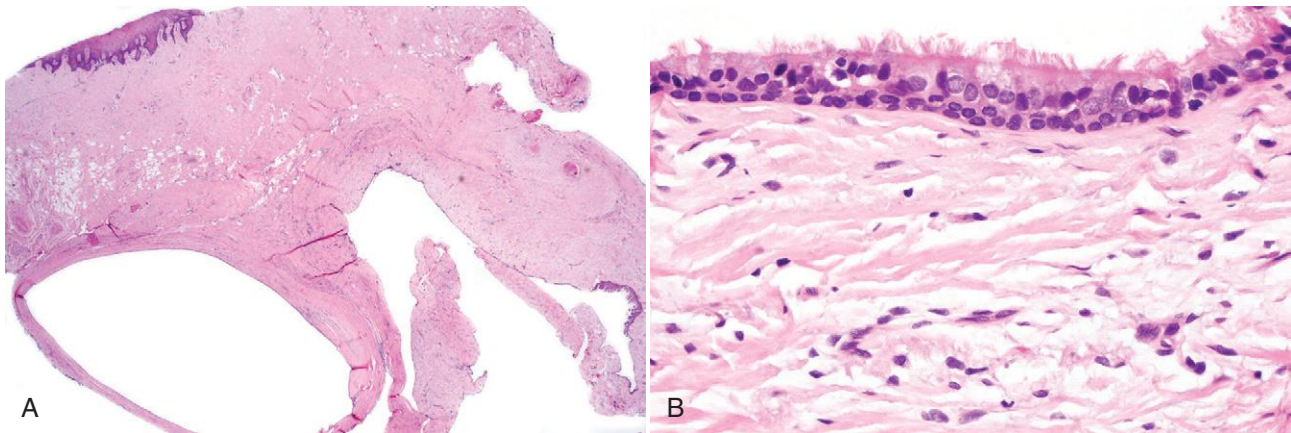
- Brown FH, Houston GD, Lubow RM, Sagan MA. Cyst of the incisive (palatine) papilla. Report of a case. *J Periodontol.* 1987;58:274-275.



**FIGURE 2-29.** Cyst of the incisive papilla: sessile, soft papule on the incisive papilla.



**FIGURE 2-30.** Cyst of the incisive papilla. **A**, Cyst within the deep lamina propria with surrounding fibrous tissue containing neurovascular bundles. **B**, Cyst is lined by two to three layers of flattened cuboidal cells.



**FIGURE 2-31.** Cyst of the incisive papilla. **A**, Cyst within the deep lamina propria. **B**, Cyst is lined by pseudostratified columnar and ciliated epithelium with mucous cells.

## NASOLABIAL CYST (NASOALVEOLAR CYST)

### Clinical Findings

- A 2:1 female predilection in patients in the fifth decade; soft, painless fluctuant swelling of the upper labial mucosa in the area of the nasolabial fold

### Etiopathogenesis and Histopathologic Features

Epithelium is derived from remnants of the nasolacrimal duct.

- Cyst lined by low cuboidal to columnar ciliated epithelium with mucous cells, nonkeratinized stratified squamous epithelium, or a mixture of both (Fig. 2-32)

### Differential Diagnosis

- Epithelial inclusion cysts of the skin are keratinizing.

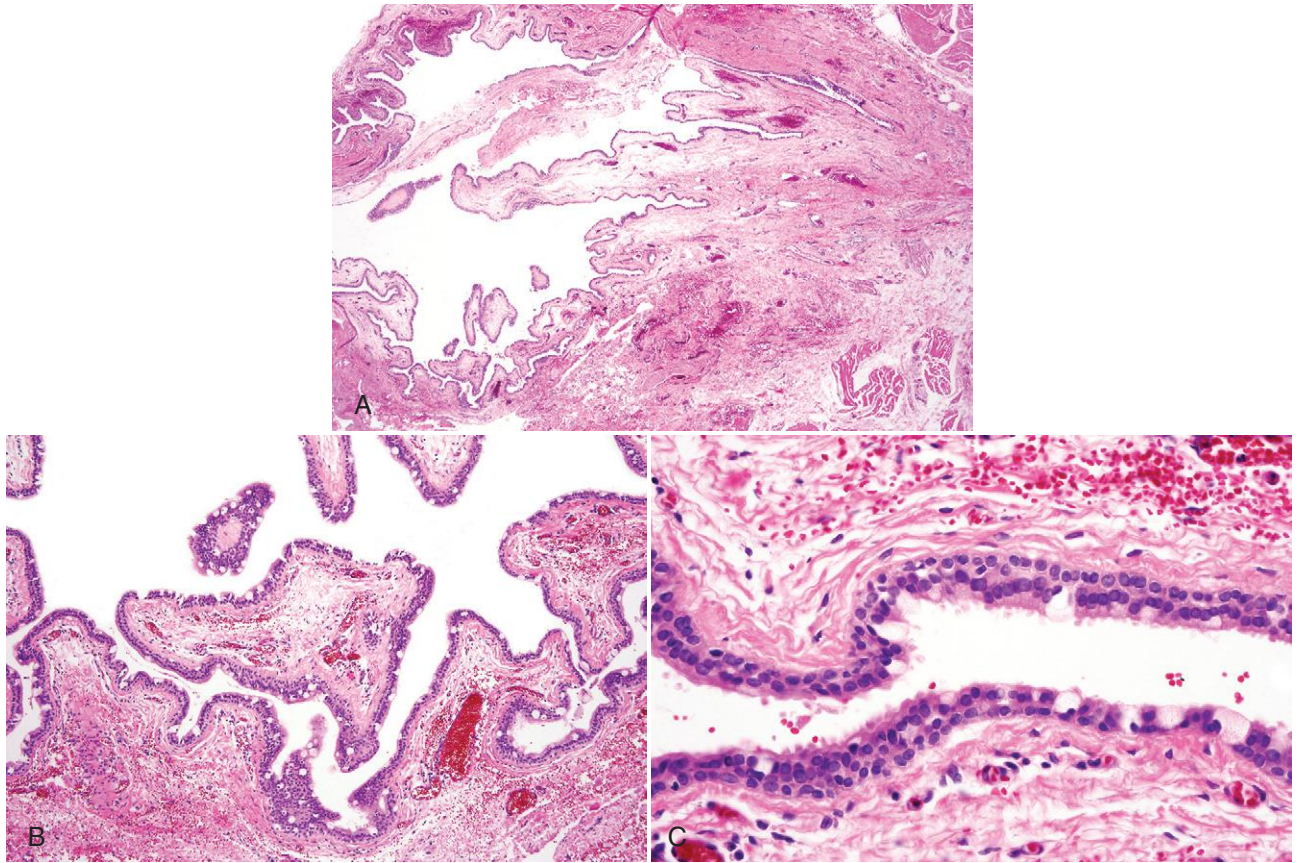
### Management and Prognosis

- Excision is curative.

### REFERENCES

- Lee J, Christmas PI. Bilateral nasolabial cysts: a case report. *N Z Dent J*. 2009;105:43-46; quiz 65.
- Pereira Filho VA, Silva AC, Moraes M, et al. Nasolabial cyst: case report. *Braz Dent J*. 2002;13:212-214.
- Ramos TC, Mesquita RA, Gomez RS, Castro WH. Transnasal approach to marsupialization of the nasolabial cyst: report of 2 cases. *J Oral Maxillofac Surg*. 2007;65:1241-1243.
- Yuen HW, Julian CY, Samuel CL. Nasolabial cysts: clinical features, diagnosis, and treatment. *Br J Oral Maxillofac Surg*. 2007;45:293-297.





**FIGURE 2-32.** Nasolabial cyst. **A**, Cyst lined by uniformly thin epithelium within the connective tissue and close to muscle. **B**, Cyst lined by uniformly thin epithelium containing mucous cells. **C**, Ciliated columnar and cuboidal epithelium with mucous cells.

# 3

# NONINFECTIOUS PAPILLARY LESIONS

## CHAPTER CONTENTS

Inflammatory Papillary Hyperplasia of the Palate 28

Verruciform Xanthoma 30

Juvenile Localized Spongiotic Gingival Hyperplasia 33

## INFLAMMATORY PAPILLARY HYPERPLASIA OF THE PALATE

### Clinical Findings

- Papillary hyperplasia of the palate usually occurs in adults wearing dentures; it is occasionally seen in patients with high-arched palates and mouth-breathing habit (with adenoidal facies); may be sensitive, especially if associated with erythematous candidiasis, because denture may act as a fomite; dryness from mouth-breathing also predisposes to candidiasis (Fig. 3-1).
- Pebbly excrescences appear on the palatal vault in a diffuse, symmetric distribution.
- Papillary lesions associated with human papillomavirus infection are discussed in Chapter 4.

### Etiopathogenesis and Histopathologic Features

Chronic irritation from the denture or from mouth-breathing leads to reactive hyperplasia of tissues.

- There is proliferation of fibrous tissue in nodules with variable lymphoplasmacytic infiltrate; overlying epithelium may be hyperplastic and exhibit spongiosis

and leukocyte exocytosis; pseudoepitheliomatous hyperplasia may be seen (Figs. 3-2 to 3-4).

- Presence of spongiotic pustules should always raise suspicion for candidiasis and a periodic acid–Schiff (PAS) stain with diastase should be performed.

### Differential Diagnosis

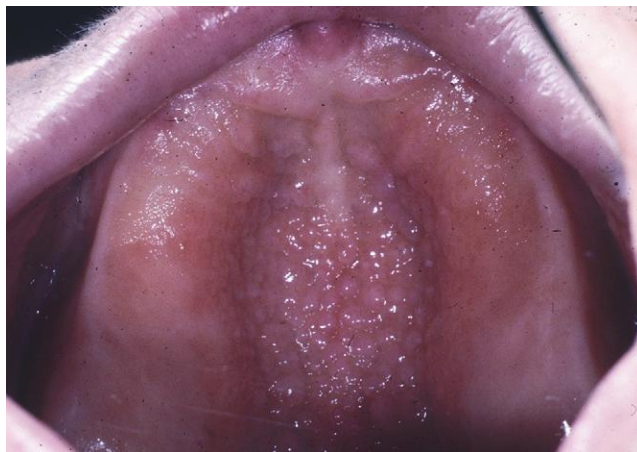- Inflamed squamous papilloma is usually single and pedunculated.

### Management and Prognosis

- Excise or ablate lesions with scalpel or laser and relines or remake denture; lesions may recur if denture continues to fit poorly.
- Treat candidiasis with topical antifungals (e.g., nystatin or clotrimazole troches) or systemic therapy (e.g., fluconazole).

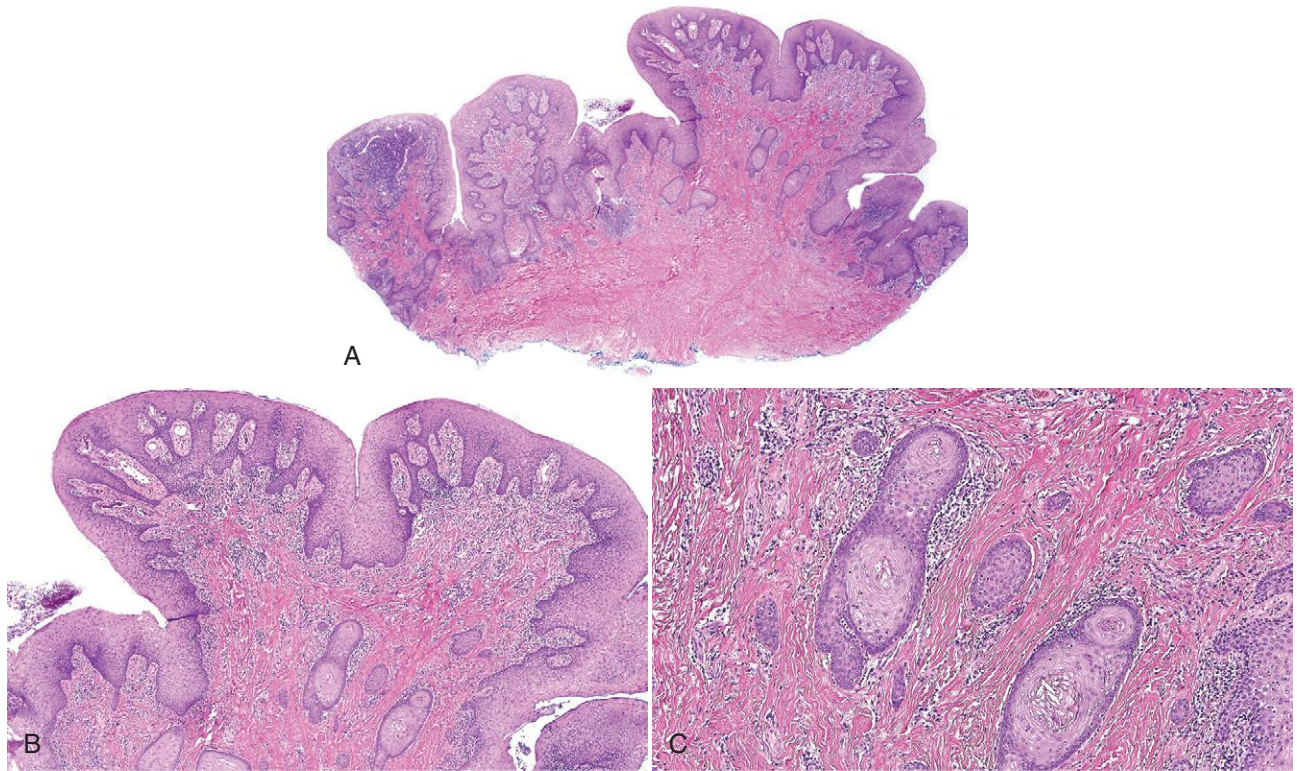
### REFERENCES

- Canger EM, Celenk P, Kayipmaz S. Denture-related hyperplasia: a clinical study of a Turkish population group. *Braz Dent J.* 2009; 20:243-248.
- Kaplan I, Vered M, Moskona D, et al. An immunohistochemical study of p53 and PCNA in inflammatory papillary hyperplasia of the palate: a dilemma of interpretation. *Oral Dis.* 1998;4:194-199.

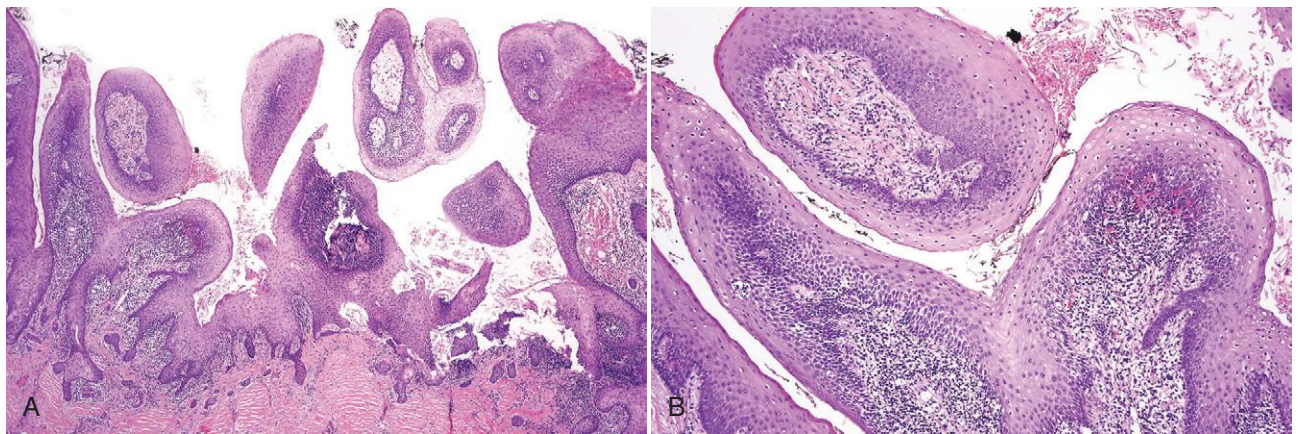


**FIGURE 3-1.** Inflammatory papillary hyperplasia of the palate. (Courtesy of Dr. Sadru Kabani, Boston, Mass.)

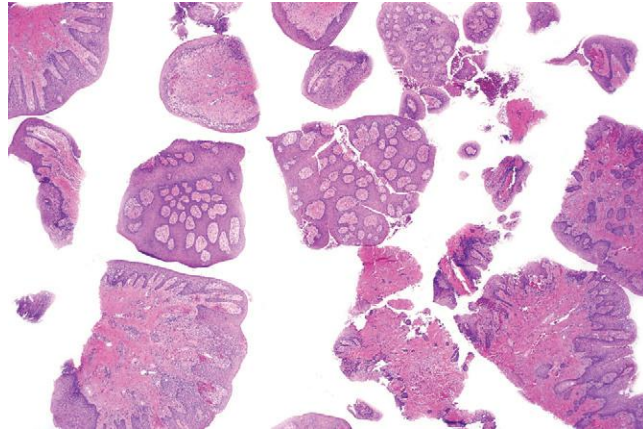




**FIGURE 3-2.** Inflammatory papillary hyperplasia of palate. **A**, Papillary proliferation of fibrous tissue and epithelium. **B**, Fibroepithelial and pseudoepitheliomatous hyperplasia with chronic inflammation. **C**, Islands of benign epithelial cells.



**FIGURE 3-3.** Inflammatory papillary hyperplasia of palate. **A**, Papillary proliferation of fibrous tissue and epithelium. **B**, Papillary structures, spongiosis, and chronic inflammation.



**FIGURE 3-4.** Inflammatory papillary hyperplasia, curretted specimen.

## VERRUCIFORM XANTHOMA

### Clinical Findings

- Discrete and localized nontender plaque with a pebbly, warty appearance; may appear yellowish or mucosa colored; located on the keratinized tissues of the hard palate, gingiva, or tongue in adults (Fig. 3-5)
- Associated with diseases characterized by damage to the epithelium such as lichen planus, pemphigus vulgaris, epidermolysis bullosa, and chronic graft-versus-host disease

### Etiopathogenesis and Histopathologic Features

This is a reactive lesion believed to be a histiocytic response to products of epithelial breakdown.

- Benign papillary proliferation of stratified squamous epithelium is seen with rete ridges, generally of the same length and confluent at the bases (Figs. 3-6, A and 3-7, A); infrequently, lesions have a flat surface (Fig. 3-8, A).
- Hyperparakeratosis with bright orange-eosinophilic hue, parakeratin plugs, and keratin squames on the surface and within crypts; neutrophilic exocytosis and spongiosis often present; foamy macrophages (positive for CD68) fill the lamina propria (Fig. 3-9; see

Figs. 3-6 to 3-8); when inflamed, keratin may be minimal (Fig. 3-10).

### Differential Diagnosis

- Verrucous hyperplasia (a dysplastic lesion) will show significant cytologic atypia, bulbous rete ridges, and usually an endophytic growth pattern.

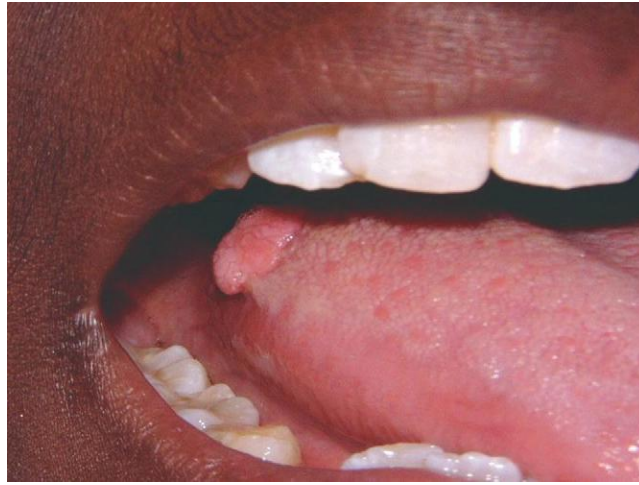### Management and Prognosis

- Excision is treatment of choice; lesion tends not to recur even if incompletely excised.

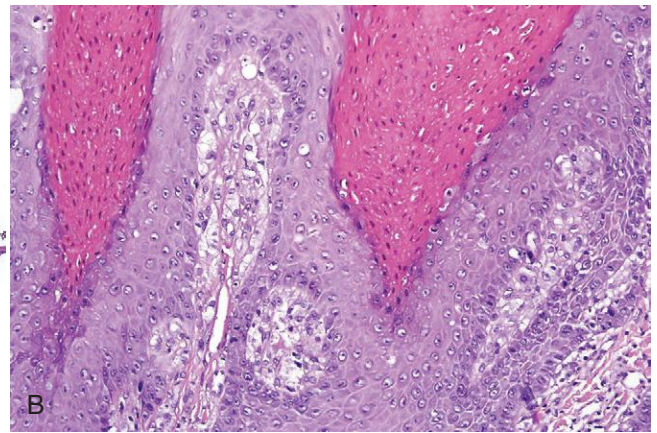
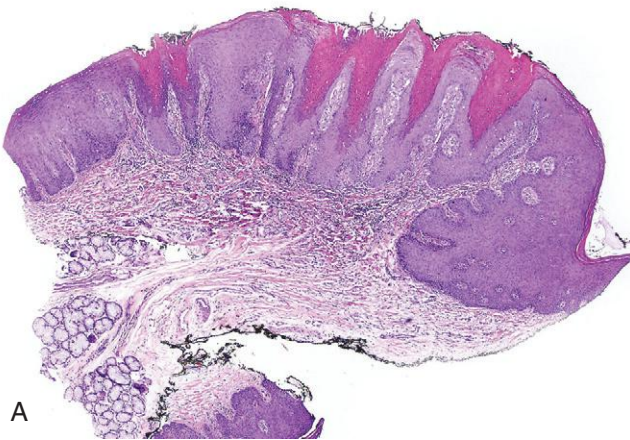
### REFERENCES

- Miyamoto Y, Nagayama M, Hayashi Y. Verruciform xanthoma occurring within oral lichen planus. *J Oral Pathol Med.* 1996;25:188-191.
- Mohsin SK, Lee MW, Amin MB, et al. Cutaneous verruciform xanthoma: a report of five cases investigating the etiology and nature of xanthomatous cells. *Am J Surg Pathol.* 1998;22:479-487.
- Neville B. The verruciform xanthoma. A review and report of eight new cases. *Am J Dermatopathol.* 1986;8:247-253.
- Shafer WG. Verruciform xanthoma. *Oral Surg Oral Med Oral Pathol.* 1971;31:784-789.
- Shahrabi Farahani S, Treister NS, Khan Z, Woo SB. Oral verruciform xanthoma associated with chronic graft-versus-host disease: a report of five cases and a review of the literature. *Head Neck Pathol.* 2011;5:193-198.
- Zegarelli DJ, Aegarelli-Schmidt EC, Zegarelli EV. Verruciform xanthoma. A clinical, light microscopic, and electron microscopic study of two cases. *Oral Surg Oral Med Oral Pathol.* 1974;38:725-734.

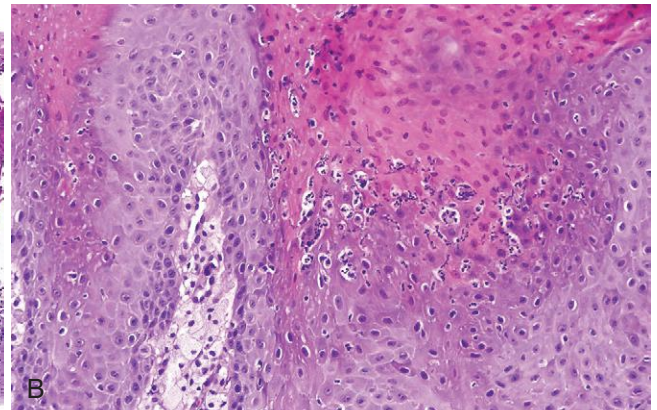
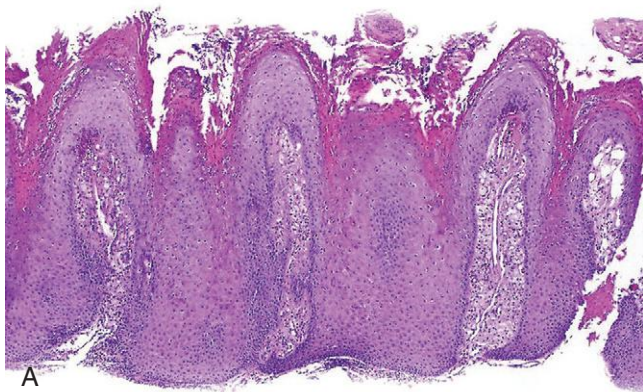




**FIGURE 3-5.** Verruciform xanthoma: papillary nodule of the right lateral tongue. (Reprinted with permission from Shahrabi Farahani S, Treister NS, Khan Z, Woo SB. Oral verruciform xanthoma associated with chronic graft-versus-host disease: a report of five cases and a review of the literature. *Head Neck Pathol.* 2011;5:193-198.)

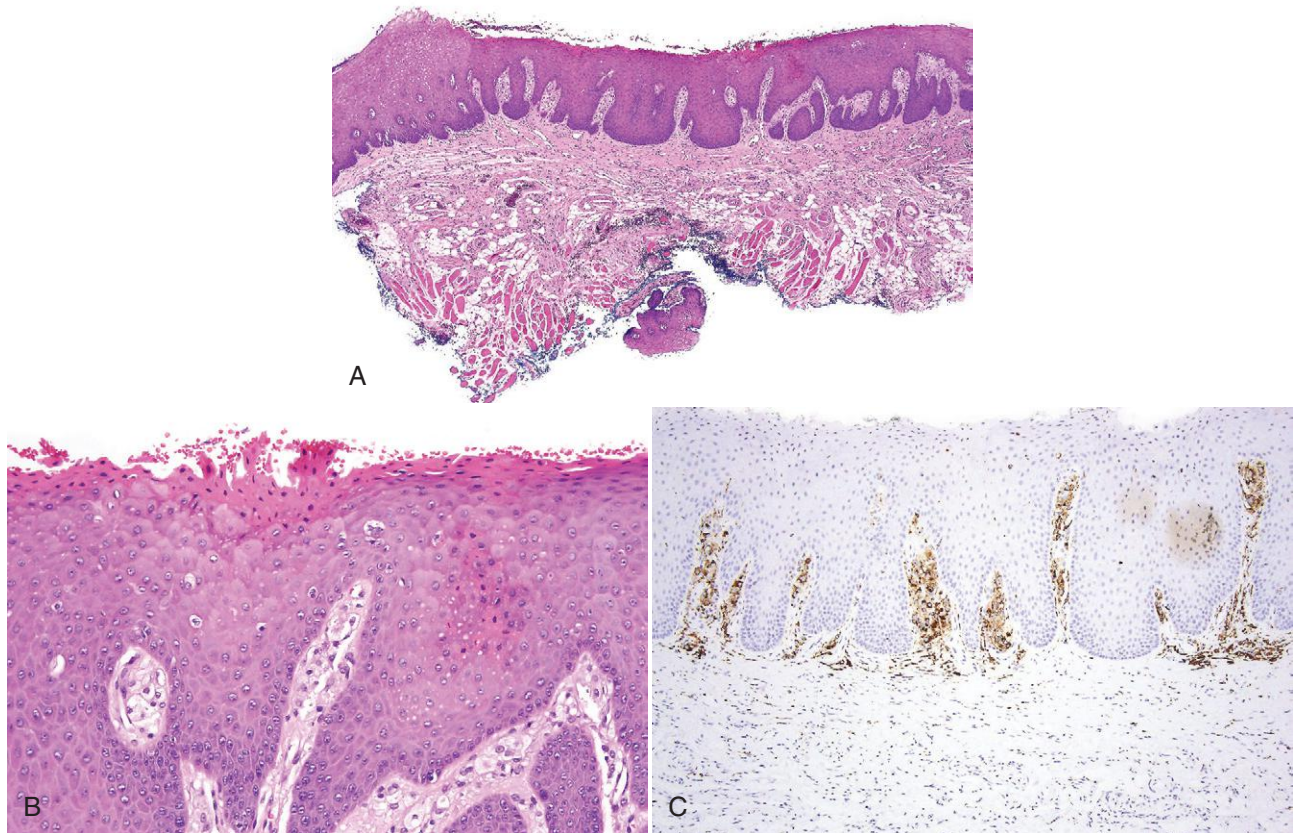


**FIGURE 3-6.** Verruciform xanthoma. **A**, Bright eosinophilic keratin, parakeratin plugs, and papillary epithelial proliferation. **B**, Compact parakeratosis and foamy macrophages.

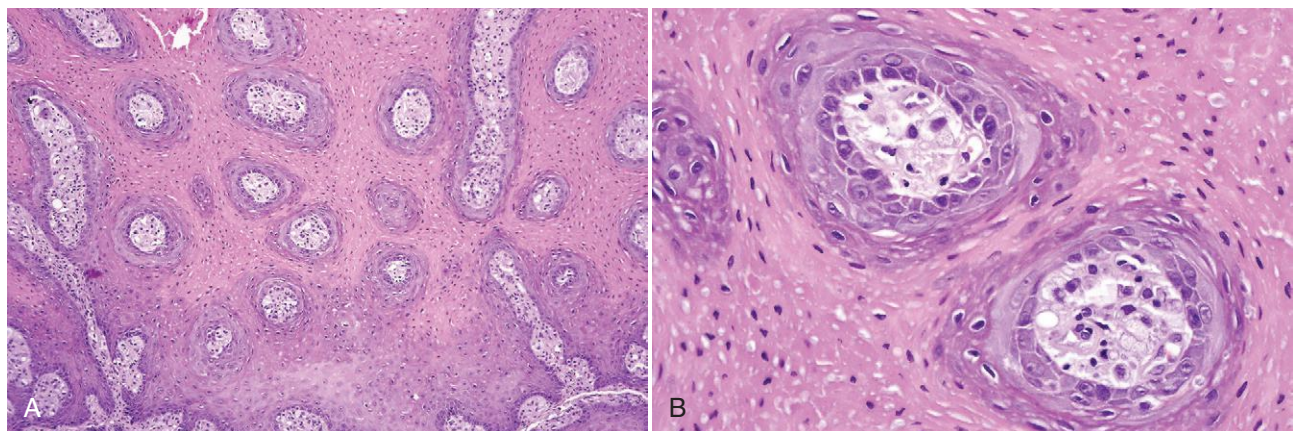


**FIGURE 3-7.** Verruciform xanthoma. **A**, Hyperparakeratosis, papillary epithelial hyperplasia, keratin squames, and rete ridges of equal length. **B**, Parakeratin within crypts and spongiosis.



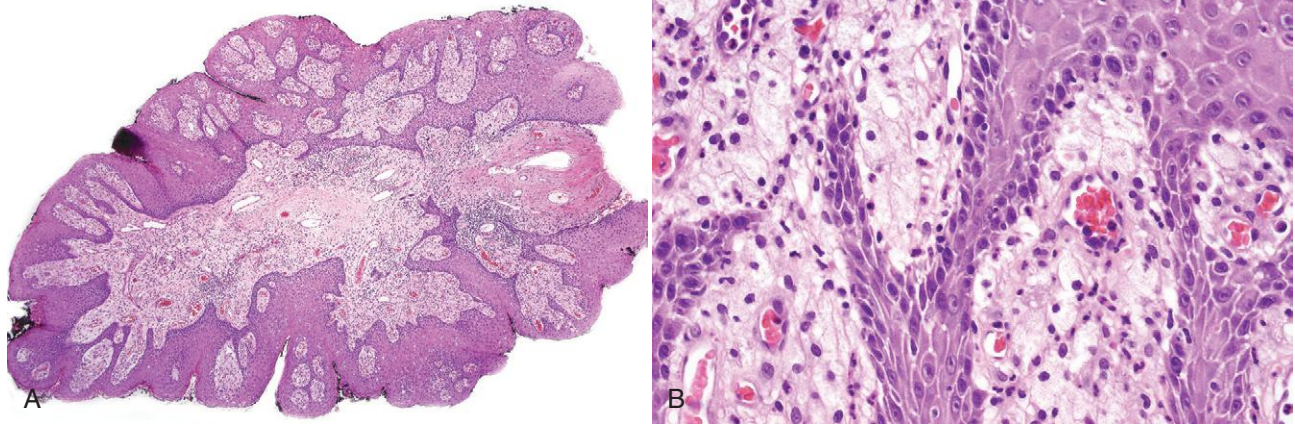


**FIGURE 3-8.** Verruciform xanthoma. **A**, Hyperparakeratosis and acanthosis without papillomatosis. **B**, Hyperparakeratosis, dyskeratosis, and xanthoma cells. **C**, CD68-positive macrophages in the papillary lamina propria.



**FIGURE 3-9.** Verruciform xanthoma. **A**, Sectioned tangentially (i.e., *en face*) with brightly eosinophilic parakeratin. **B**, Xanthoma cells in lamina propria.





**FIGURE 3-10.** Verruciform xanthoma. **A**, Papillary epithelial hyperplasia with minimal parakeratosis and chronic inflammation. **B**, Foamy macrophages and inflammatory cells.

## JUVENILE LOCALIZED SPONGIOTIC GINGIVAL HYPERPLASIA

### Clinical Findings

- Greater than 90% occur between 5 to 15 years of age mostly on the maxillary (84%) anterior facial gingiva; 15% of patients have orthodontic hardware on the teeth.
- It appears as an erythematous, often pebbly, easily bleeding, nontender plaque, less than 1 cm, on the marginal gingiva; may be multifocal (Fig. 3-11).

### Etiopathogenesis and Histopathologic Features

This is a reactive lesion likely related to trauma and local irritation; unclear if the epithelial proliferation is crevicular or junctional in nature.

- Benign usually pedunculated, papillary (may be subtle) proliferation of nonkeratinized stratified squamous epithelium; prominent spongiosis and

leukocyte exocytosis; dilated vessels with variable numbers of plasma cells (Fig. 3-12)

- Epithelium positive for CK19

### Differential Diagnosis

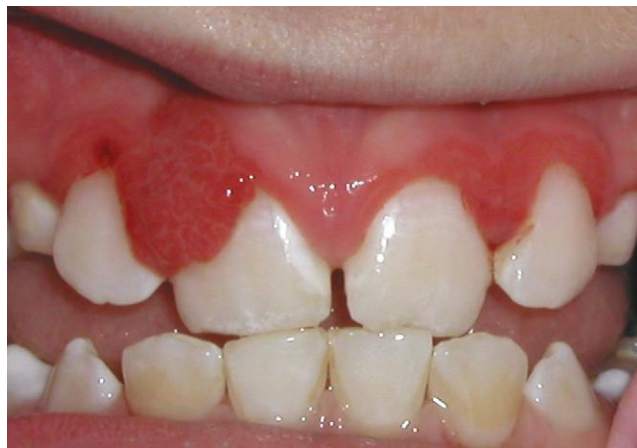- Lesions may represent inflamed squamous papilloma (gingiva is a common location for this and age group is also supportive) (Fig. 3-13).

### Management and Prognosis

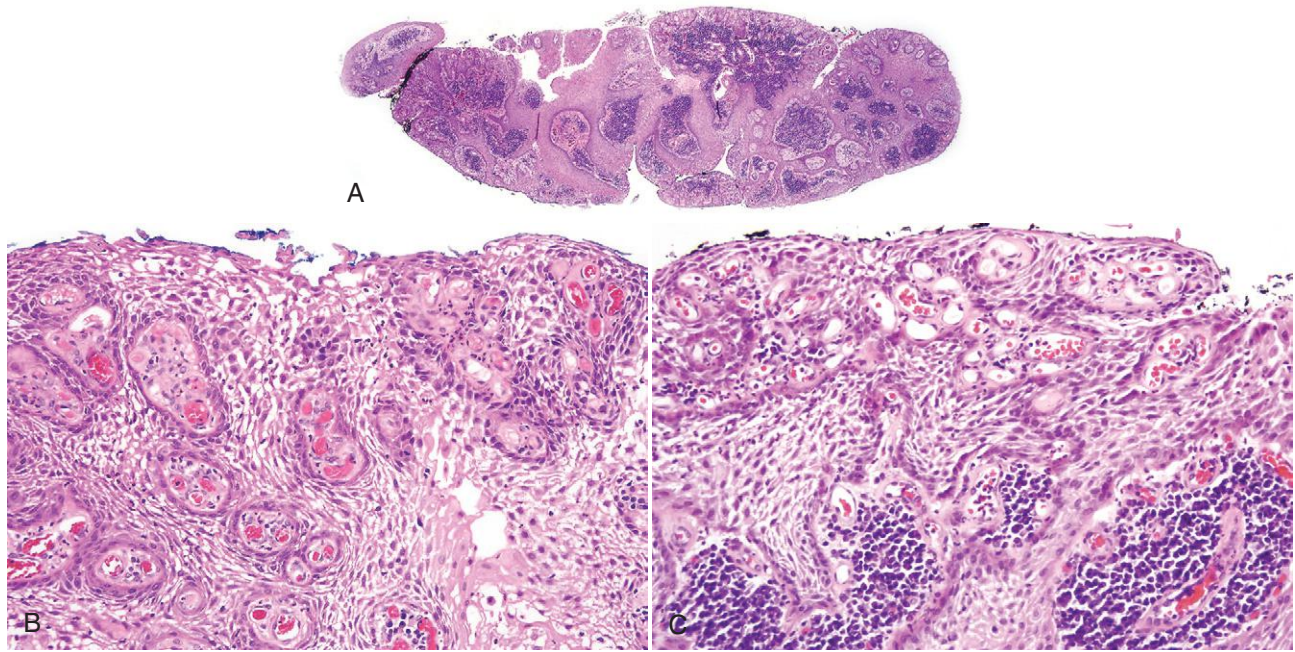
- Excision is treatment of choice and lesion is unlikely to recur.

### REFERENCES

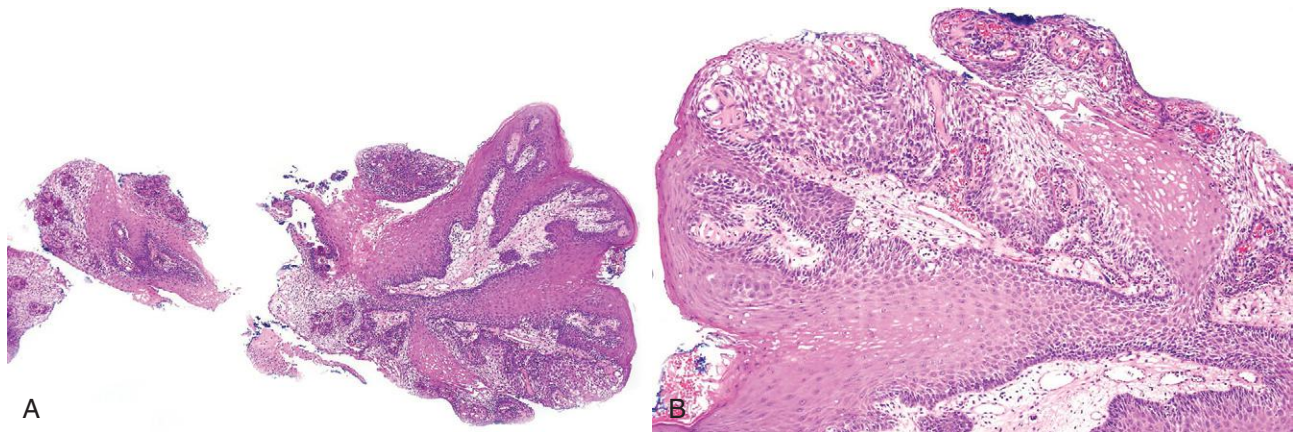
- Chang JY, Kessler HP, Wright JM. Localized juvenile spongiotic gingival hyperplasia. *Oral Surg Oral Med Oral Pathol Oral Radiol Endod.* 2008;106:411-418.
- Darling MR, Daley TD, Wilson A, Wysocki GP. Juvenile spongiotic gingivitis. *J Periodontol.* 2007;78:1235-1240.



**FIGURE 3-11.** Juvenile localized spongiotic gingival hyperplasia with diffuse gingival inflammation. (Courtesy of Dr. Harvey Kessler, Baylor College of Dentistry, Dallas, Tex.)



**FIGURE 3-12.** Juvenile localized spongiotic gingival hyperplasia. **A**, Papillary proliferation of nonkeratinized stratified squamous epithelium with marked inflammation. **B**, Marked spongiosis and leukocyte exocytosis with dilated vessels within fibrovascular cores. **C**, Papillomatosis, hyalinized fibrovascular cores, and many plasma cells.



**FIGURE 3-13.** **A**, Papilloma associated with juvenile localized spongiotic gingival hyperplasia. **B**, Transition between intact noninflamed papilloma and spongiotic lesion.



# 4

# BACTERIAL, VIRAL, FUNGAL, AND OTHER INFECTIOUS CONDITIONS

## CHAPTER CONTENTS

Actinomycosis	35
Candidiasis (Candidosis)	38
Infectious Granulomatous Inflammation	42
Herpesvirus Infections	45
Human Papillomavirus–Related Benign Lesions	53
Syphilis	61

Any infection that occurs in any other part of the body may manifest in the mouth, including mycobacterial, treponemal, and bartonellal infections, although they are uncommon and rarely occur initially in the mouth. In many parts of the world, mycobacterial and syphilitic infections are on the rise. Polymicrobial bacterial infections in the mouth are the most common and are generally not subject to biopsy because most of these are related to dental caries and periodontal infections. Actinomycosis is one bacterial infection that is seen on biopsy with some frequency.

## ACTINOMYCOSIS

There are five common areas of involvement—cervical-facial, pulmonary, ileocecal, genitourinary, and central nervous system. The less well known and yet fairly common infection involving the jawbones and oral soft tissues is discussed here.

### Clinical Findings

- Actinomycosis most often manifests as a periapical radiolucency, painful or painless, in a root canal-treated or grossly carious tooth (Fig. 4-1, A); it may also be associated with impacted teeth, periodontitis, or around dental implants; 80% of cases are asymptomatic; approximately 20% involve the soft tissues only; mandibular tooth infection may lead to cutaneous fistula (see Fig. 4-1, B).
- Sinus tract (known as gingival parulis) and suppuration are always present; yellowish “sulfur granules” representing masses of bacteria may be noted during biopsy.
- Presence of actinomycetes colonies in the absence of actinomycotic infection may predispose patients to obstructive tonsillar hypertrophy.

### Etiopathogenesis and Histopathologic Features

*Actinomyces* are gram-positive microaerophilic, obligate, or facultative filamentous bacteria. There are several species, such as *A. odontolyticus*, *A. israelii*, *A. naeslundii*,

*A. gerencseriae*, and *A. viscosus*. They cause suppurative lesions and enter the bone through a preexisting sinus tract or through a carious tooth.

- Abundant granulation tissue with abscesses, chronic inflammation; masses of sulfur granules are composed of a round-to-ovoid masses of filamentous bacteria with a peripheral eosinophilic rim often with eosinophilic radiating “clubs” or fringe and clinging neutrophils (Figs. 4-2, 4-3, A-C); bacteria gram-positive and argyrophilic (see Fig. 4-3, D, E); concomitant apical radicular or dentigerous cyst or periapical granuloma often present
- Clumps of actinomycetes alone without the eosinophilic fringe not sufficient for the diagnosis (see later)

### Differential Diagnosis

- Actinomycotic colonies are a common component of dental plaque and do not represent actinomycosis in the absence of suppuration and clinical signs (see Chapter 7).
- Masses of actinomycotic organisms are often found on the surface of exposed bony sequestra, especially in bisphosphonate-associated osteonecrosis of the jaws (see Chapter 16).

### Management and Prognosis

- Curettage, 2 to 3 weeks of antibiotics (e.g., amoxicillin, doxycycline, or clindamycin), and removal of the original source of infection (such as carious or impacted tooth) is curative; prolonged antibiotic therapy is not indicated for conventional periapical actinomycosis.

### REFERENCES

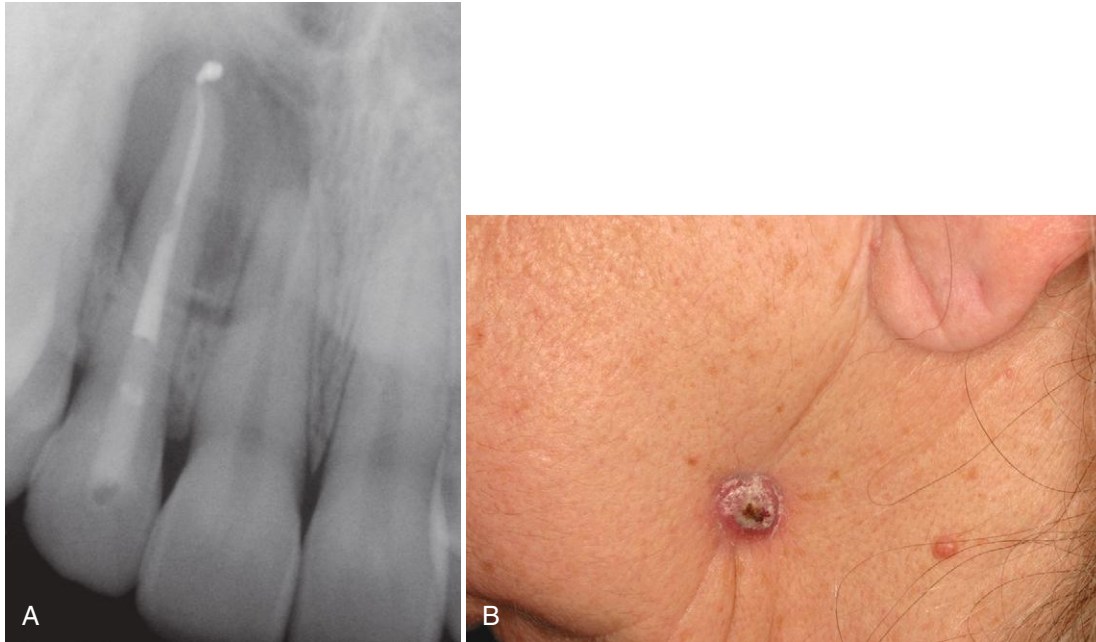
- Aldred MJ, Talacko AA. Periapical actinomycosis. *Oral Surg Oral Med Oral Pathol Oral Radiol Endod.* 2003;96:386.
- Brook I. Actinomycosis: diagnosis and management. *South Med J.* 2008;101:1019-1023.
- Kaplan I, Anavi K, Anavi Y, et al. The clinical spectrum of *Actinomyces*-associated lesions of the oral mucosa and jawbones: correlations with histomorphometric analysis. *Oral Surg Oral Med Oral Pathol Oral Radiol Endod.* 2009;108:738-746.

LeCorn DW, Vertucci FJ, Rojas MF, et al. In vitro activity of amoxicillin, clindamycin, doxycycline, metronidazole, and moxifloxacin against oral *Actinomyces*. *J Endod*. 2007;33:557-560.

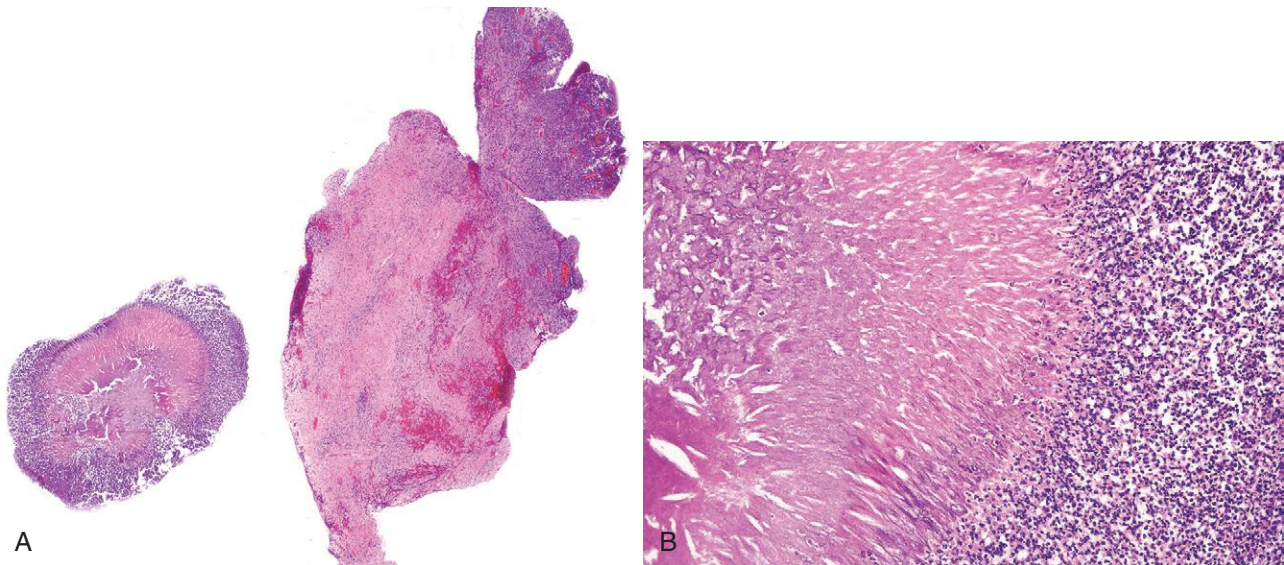
Ozgursoy OB, Kemal O, Saatci MR, Tulunay O. Actinomycosis in the etiology of recurrent tonsillitis and obstructive tonsillar hypertrophy: answer from a histopathologic point of view. *J Otolaryngol Head Neck Surg*. 2008;37:865-869.

Tang G, Samaranayake LP, Yip HK, et al. Direct detection of *Actinomyces* spp. from infected root canals in a Chinese population: a study using PCR-based, oligonucleotide-DNA hybridization technique. *J Dent*. 2003;31:559-568.

Xia T, Baumgartner JC. Occurrence of *Actinomyces* in infections of endodontic origin. *J Endod*. 2003;29:549-552.

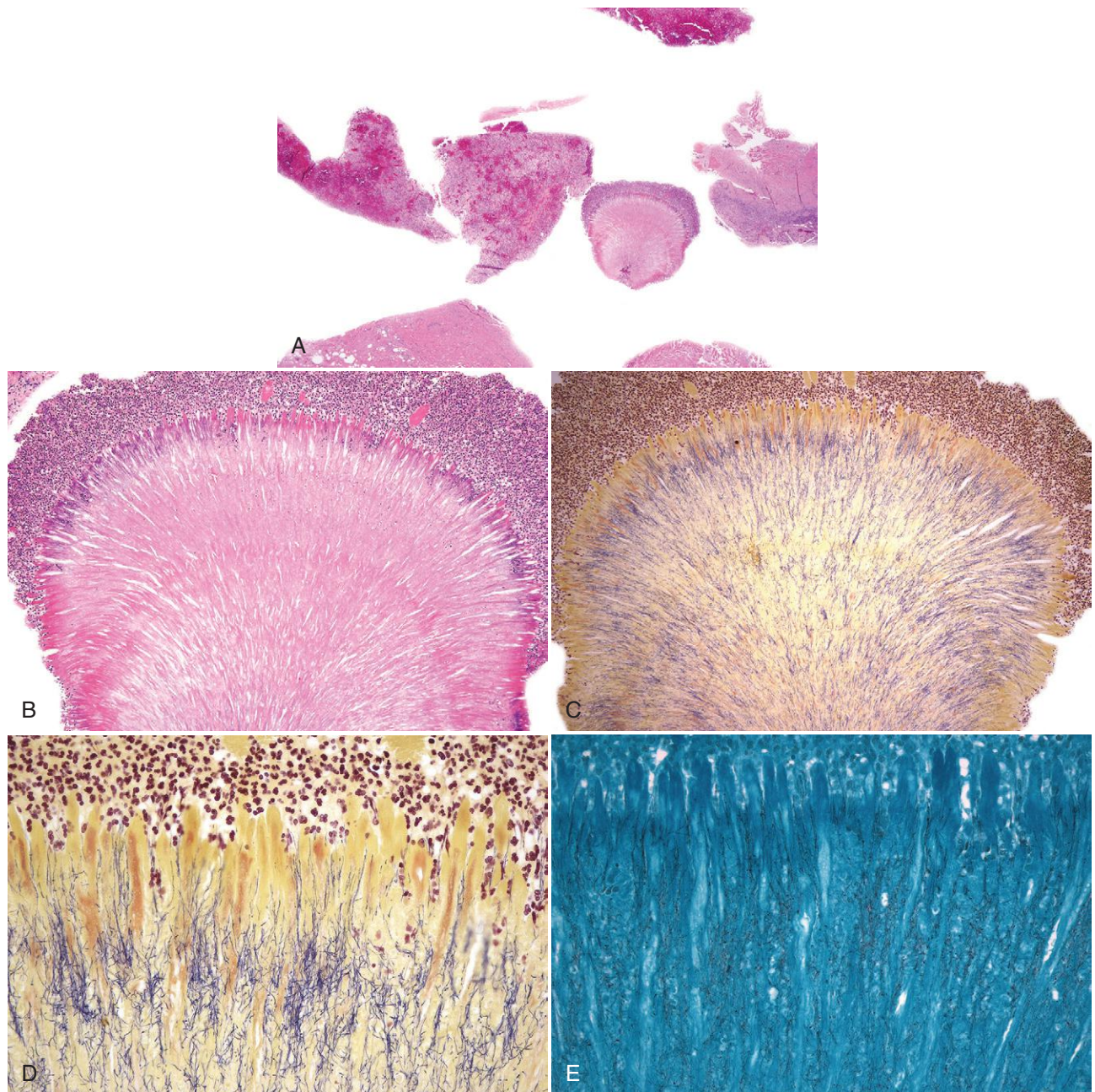


**FIGURE 4-1.** **A**, Periapical actinomycosis manifesting within an apical radicular cyst after root canal therapy. **B**, Actinomycosis from a carious mandibular molar resulting in cutaneous sinus tract. (**A**, Courtesy of Dr. Michael Joseph, private practice, Worcester, Mass.)



**FIGURE 4-2.** Periapical actinomycosis. **A**, Granulation tissue and sulfur granule. **B**, Sulfur granule with peripheral eosinophilic radiating morphology and suppuration.





**FIGURE 4-3.** Periapical actinomycosis. **A**, Periapical granuloma and sulfur granule. **B**, Sulfur granule with typical radiating morphology and suppuration. **C**, Sulfur granule (Brown and Brenn stain). **D**, Sulfur granule containing numerous gram-positive filamentous bacteria. **E**, Sulfur granule containing slender argyrophilic filaments (methenamine silver stain).

## CANDIDIASIS (CANDIDOSIS)

This is the most common fungal infection in the mouth.

### Clinical Findings

- Thrush or pseudomembranous candidiasis: curdy white papules and plaques that may or may not wipe off; usually sore or sensitive and has erythematous areas (Fig. 4-4, A and B)
- Erythematous candidiasis: sensitive erythematous area often outlined by the shape of a denture; also as linear erythematous gingivitis in patients with HIV/AIDS (see Fig. 4-4, C and D)
- Angular cheilitis: pain, cracking, fissuring, and maceration of corners of mouth (usually bilateral); seen in denture wearers where dentures do not adequately support soft tissues; also in vitamin B<sub>12</sub> and iron deficiencies (see Fig. 4-4, E)
- Hyperplastic candidiasis: white plaques seen in mucocutaneous disease, endocrinopathies, and immunosuppression; common on the commissures bilaterally; often associated with hairy leukoplakia (see later)
- Median rhomboid glossitis: erythematous, ovoid, or rhomboid raised area of the midline dorsum of tongue anterior to the circumvallate papillae (see Fig. 4-4, F)
- Candidiasis on the tongue dorsum: often associated with concomitant “kissing” lesions on the palate (see Fig. 4-4, G and H)

### Etiopathogenesis and Histopathologic Features

Lesions are caused by *Candida albicans* or other species when the flora in the mouth is altered because of hyposalivation, use of antibiotics or corticosteroids, and immunosuppression. Because *Candida* is a commensal in approximately 20% of the population, a positive culture in and of itself is not diagnostic for candidiasis. Scraping the lesion and use of either potassium hydroxide or standard cytology stains to identify hyphae is diagnostic, as is a biopsy.

- Epithelial hyperplasia (often psoriasiform) with parakeratosis, neutrophilic exocytosis and spongiotic pustules, reactive epithelial atypia, vascular ectasia, and

variable lymphocytic infiltrates (Fig. 4-5, A-C); candidal hyphae and/or conidia seen in the periodic acid–Schiff (PAS) stain with diastase digestion or methenamine silver stain (see Fig. 4-5, A inset); possible epithelial atrophy noted (Fig. 4-6)

- Median rhomboid glossitis: loss of filiform papillae and presence of median raphe, normal hyalinized band in the midline of tongue, sometimes misdiagnosed as amyloid deposition (Fig. 4-7)

### Differential Diagnosis

- Epithelial dysplasia with secondary candidiasis exhibits significant epithelial atypia and may be difficult to differentiate from candidiasis with reactive atypia (see Fig. 4-6, B); however, effective treatment completely resolves candidiasis without dysplasia.
- Spongiotic pustules are also seen in:
  - Benign migratory glossitis/stomatitis
  - Edge of ulcer or erosions
  - Oral psoriasis (see relevant sections)
- *Geotrichum candidum* (causing geotrichosis) form short septate hyphae.

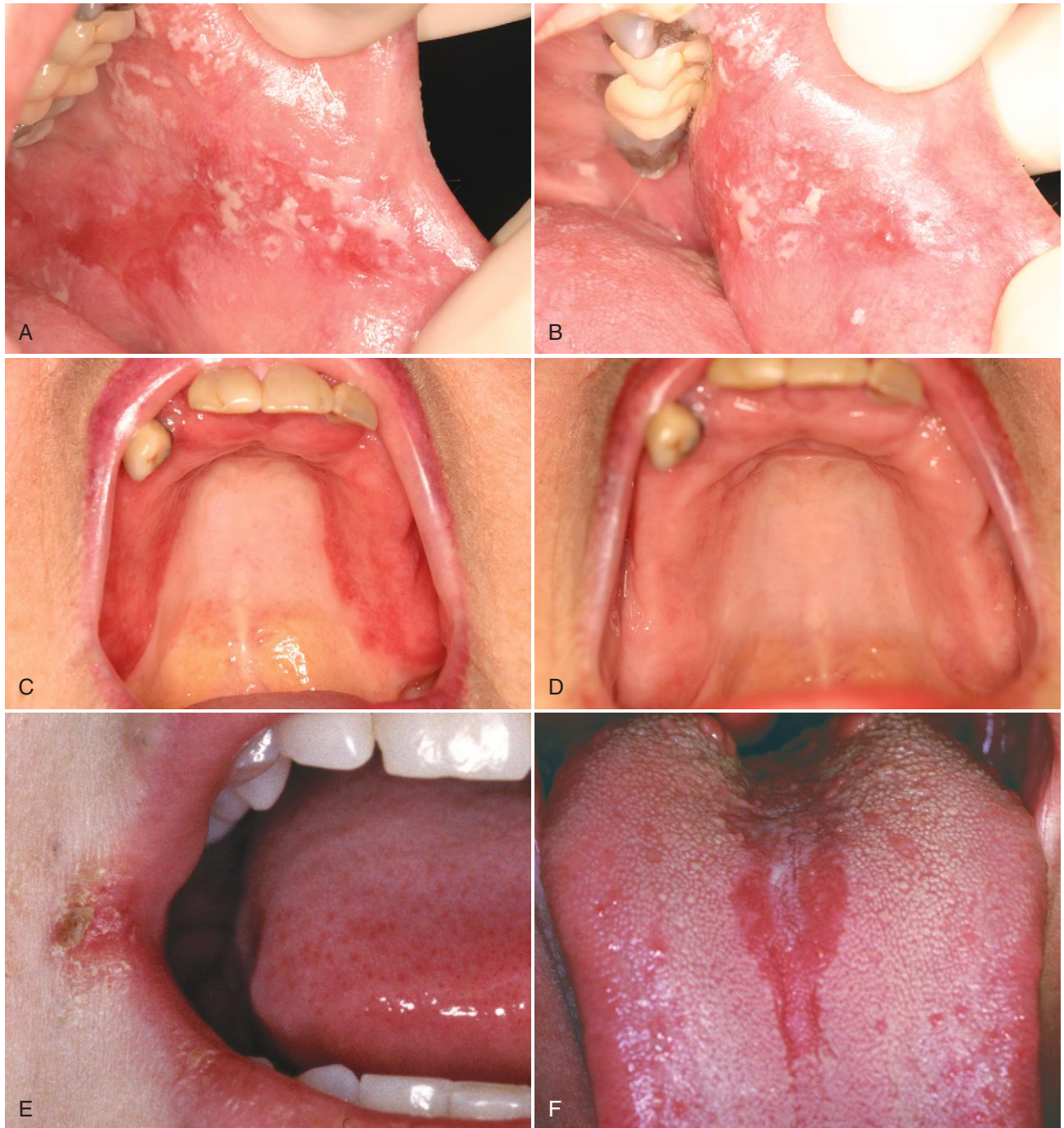### Management and Prognosis

- See Appendix B.
- *Staphylococcus aureus* is present in up to 30% of patients with angular cheilitis; concomitant topical erythromycin is helpful if lesions are recalcitrant.

### REFERENCES

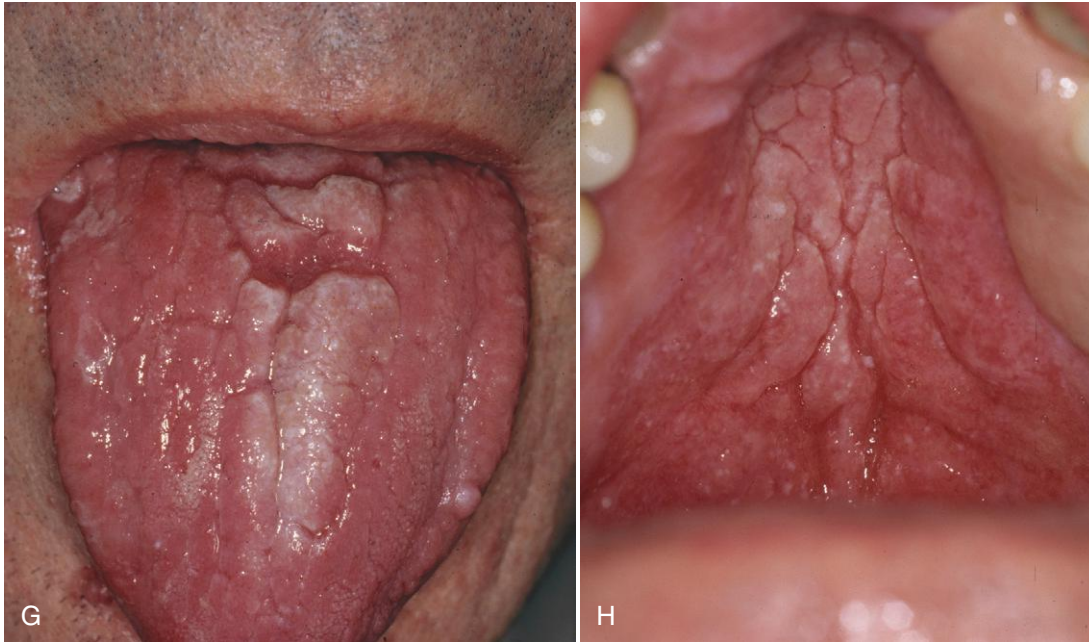
- Akpan A, Morgan R. Oral candidiasis. *Postgrad Med J.* 2002;78:455-459.
- Bonifaz A, Vazquez-Gonzalez D, Macias B, et al. Oral geotrichosis: report of 12 cases. *J Oral Sci.* 2010;52:477-483.
- Dias AP, Samaranayake LP. Clinical, microbiological and ultrastructural features of angular cheilitis lesions in Southern Chinese. *Oral Dis.* 1995;1:43-48.
- Pienaar ED, Young T, Holmes H. Interventions for the prevention and management of oropharyngeal candidiasis associated with HIV infection in adults and children. *Cochrane Database Syst Rev.* 2010;11:CD003940.
- Sitheequ MA, Samaranayake LP. Chronic hyperplastic candidosis/candidiasis (candidal leukoplakia). *Crit Rev Oral Biol Med.* 2003;14:253-267.
- Wright BA. Median rhomboid glossitis: not a misnomer. *Oral Surg Oral Med Oral Pathol.* 1978;46:806-814.



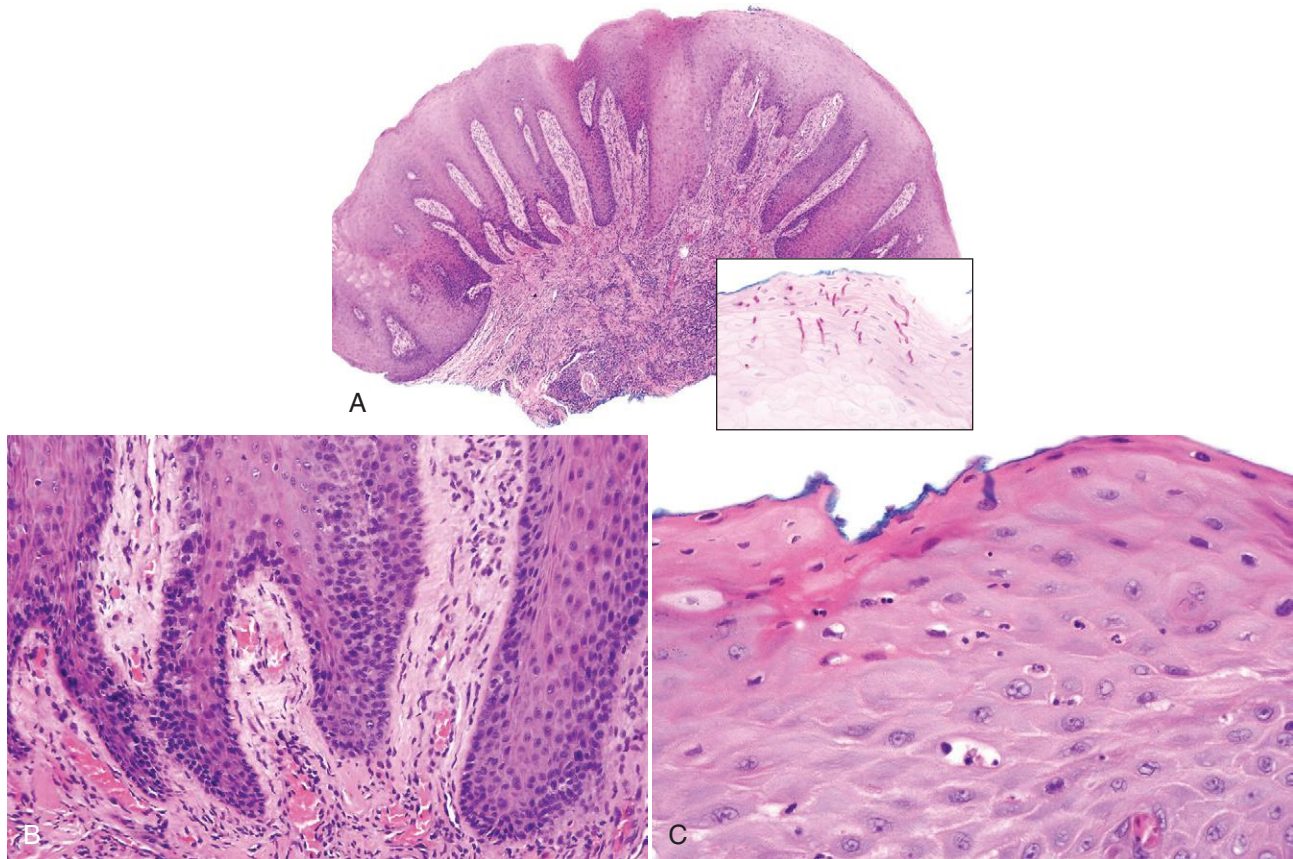


**FIGURE 4-4.** **A**, Pseudomembranous candidiasis: white plaques and erythema. **B**, Pseudomembranous candidiasis: lesion in **A** scrapes off. **C**, Erythematous candidiasis: erythema in the outline of denture. **D**, Erythematous candidiasis: same patient as in **C** after treatment with nystatin and triamcinolone paste applied to denture. **E**, Angular cheilitis. **F**, Median rhomboid glossitis. *Continued*



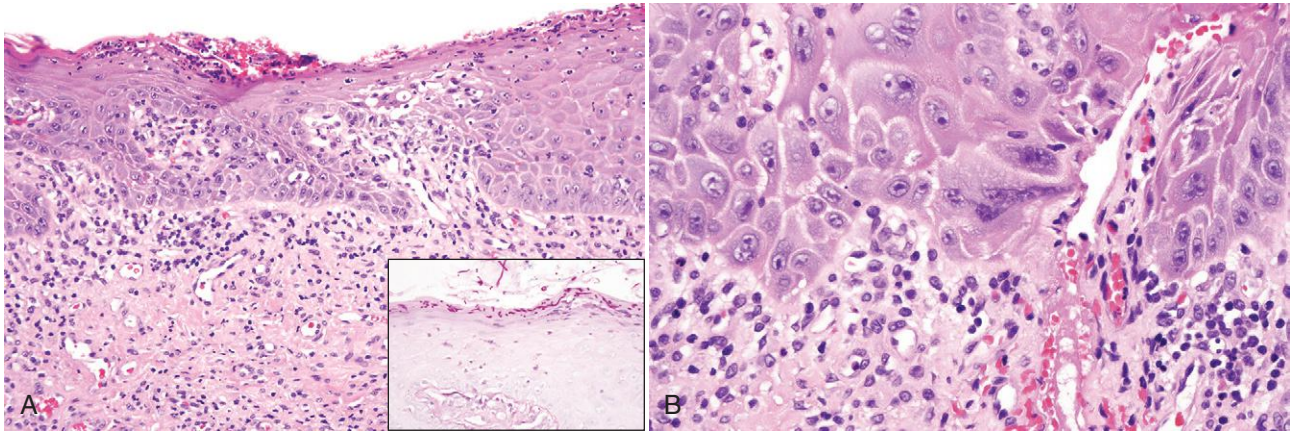


**FIGURE 4-4, cont'd.** **G**, Candidiasis presenting as "kissing lesion" on the tongue dorsum. **H**, Same patient as in **G** with palatal candidiasis.

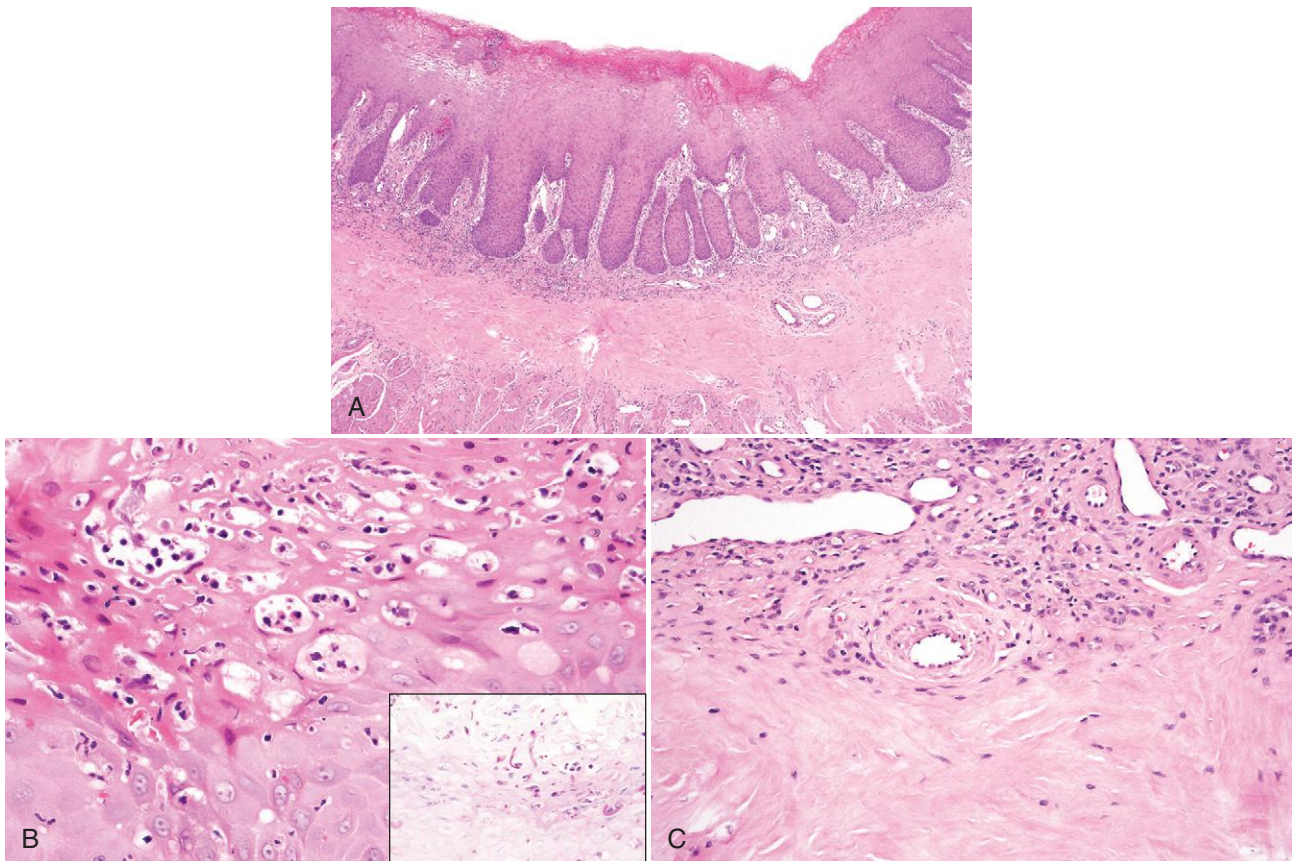


**FIGURE 4-5.** Candidiasis. **A**, Psoriasiform epithelial hyperplasia with chronic inflammation; periodic acid–Schiff (PAS) stain with diastase reveals candidal hyphae (*inset*). **B**, Mild reactive epithelial atypia. **C**, Neutrophilic exocytosis and early spongiotic pustules.





**FIGURE 4-6.** Candidiasis. **A**, Epithelial atrophy, spongiotic pustules, and chronic inflammation; periodic acid–Schiff (PAS) stain with diastase reveals candidal hyphae (*inset*). **B**, Reactive epithelial atypia with multinucleated epithelial cells.



**FIGURE 4-7.** Median rhomboid glossitis. **A**, Atrophy of filiform papillae, psoriasiform epithelial hyperplasia and hyaline median raphe. **B**, Spongiotic pustules; periodic acid–Schiff (PAS) stain with diastase reveals candidal hyphae (*inset*). **C**, Densely hyalinized median raphe.

## INFECTIOUS GRANULOMATOUS INFLAMMATION

### Clinical Findings

- Concomitant systemic or skin involvement is usually noted and history is very important in the diagnosis.
- Ulcerated and indurated, granular, vegetating nodules of the palate and gingiva are common oral presentations, and there is usually concomitant lung, nodal, and skin disease; immunocompromised patients are particularly susceptible to disseminated disease.
- Coccidioidomycosis caused by *Coccidioides immitis* is endemic in California and the southwest United States.
- Histoplasmosis caused by *Histoplasma capsulatum* is endemic to the Ohio-Mississippi Valley and is found in the soil and in bird and bat droppings; patients taking tumor necrosis factor- $\alpha$  inhibitors are prone to contracting this infection, as well as coccidioidomycosis in endemic areas.
- Paracoccidioidomycosis caused by *Paracoccidioides brasiliensis*, a soil saprophyte, is common in South America where 80% to 90% of cases are chronic (Fig. 4-8).
- Phycomycoses (order Mucorales, genera *Rhizopus*, *Absidia*, *Mucor*, and *Rhizomucor*) and aspergillosis (*Aspergillus fumigatus* or *A. flavus*) appear black, necrotic and/or fungating, resembling malignancy; rhinocerebral phycomycosis is increasing in frequency and is often seen in patients with diabetes (especially if ketoacidotic), neutropenia, malignancy, and post-organ transplantation; mortality rate is 60% to 90%; aspergillosis appears similar but tends to affect immunocompromised patients (such as those with leukemia) rather than those with diabetes; both primarily affect the palate and maxilla, and vascular involvement leads to necrosis.

### Etiopathogenesis and Histopathologic Features

- Coccidioidomycosis: pseudoepitheliomatous hyperplasia with granulomatous inflammation and budding organisms (Fig. 4-9)
- Histoplasmosis is a granulomatous inflammation, sometimes with necrosis (Fig. 4-10).

- Zygomycosis is a necrotic lesion with hyphal forms invading blood vessels; ribbon-like organisms, with right-angle branching (Fig. 4-11) are evident.
- Aspergillosis is similar to zygomycosis but organisms are slender and show acute-angle branching (Fig. 4-12); must be differentiated from mycetoma or “fungus ball” within the sinus that does not invade the soft tissues (Fig. 4-13).
- Identification of the organism using immunohistochemical stains; correlation with the clinical presentation, serology, and other tests are crucial if no organisms are found.

### Differential Diagnosis

- A search for foreign bodies must always be undertaken.
- Sarcoidosis produces nonnecrotizing granulomas, as does Crohn disease.

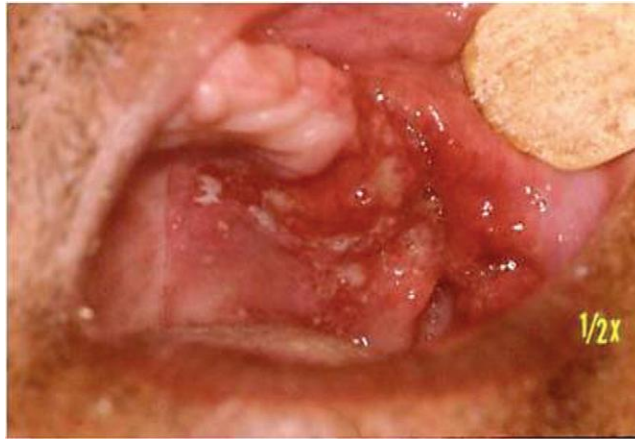### Management

- Appropriate antimicrobial therapy such as with itraconazole, voriconazole, posaconazole, and amphotericin B

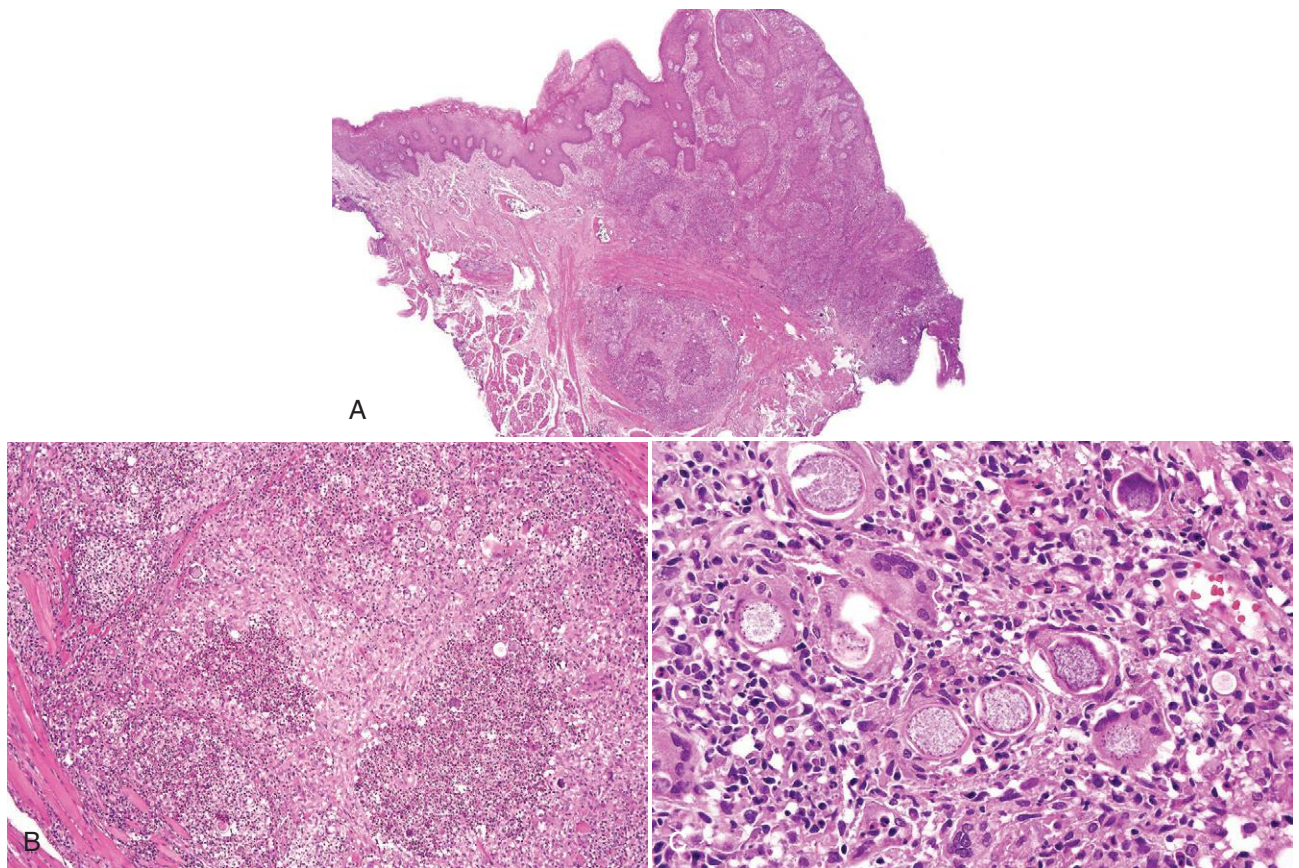
### REFERENCES

- Bonifaz A, Macias B, Paredes-Farrera F, et al. Palatal zygomycosis: experience of 21 cases. *Oral Dis.* 2008;14:569-574.
- Cho H, Lee KH, Colquhoun AN, Evans SA. Invasive oral aspergillosis in a patient with acute myeloid leukaemia. *Aust Dent J.* 2010;55:214-218.
- Greenberg RN, Scott LJ, Vaughn HH, Ribes JA. Zygomycosis (mucormycosis): emerging clinical importance and new treatments. *Curr Opin Infect Dis.* 2004;17:517-525.
- Hernandez SL, Lopez De Blanc SA, Sambuelli RH, et al. Oral histoplasmosis associated with HIV infection: a comparative study. *J Oral Pathol Med.* 2004;33:445-450.
- Karimi K, Wheat LJ, Connolly P, et al. Differences in histoplasmosis in patients with acquired immunodeficiency syndrome in the United States and Brazil. *J Infect Dis.* 2002;186:1655-1660.
- Marques SA. Fungal infections of the mucous membrane. *Dermatol Ther.* 2010;23:243-250.
- McKee P, Calonje E, Granter S, eds. *Pathology of the Skin.* 3rd ed. Philadelphia: Saunders; 2005.
- Neville BW DD, Allen CM, Bouquot J. *Oral and Maxillofacial Pathology.* 5th ed. Philadelphia: Saunders; 2009.
- Parish JM, Blair JE. Coccidioidomycosis. *Mayo Clin Proc.* 2008;83:343-348; quiz 8-9.
- Roden MM, Zaoutis TE, Buchanan WL, et al. Epidemiology and outcome of zygomycosis: a review of 929 reported cases. *Clin Infect Dis.* 2005;41:634-653.
- Smith JA, Kauffman CA. Endemic fungal infections in patients receiving tumour necrosis factor-alpha inhibitor therapy. *Drugs.* 2009;69:1403-1415.



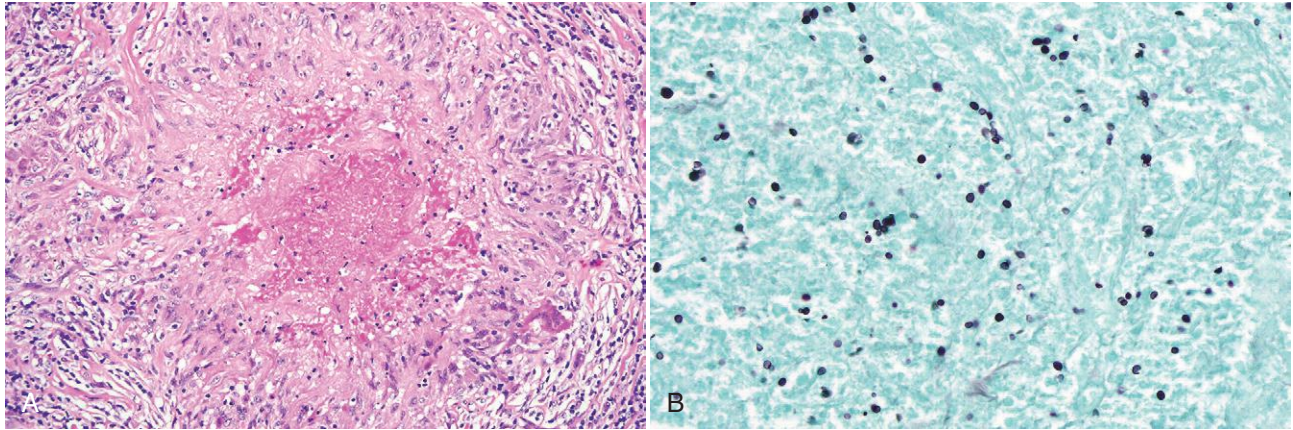


**FIGURE 4-8.** Oral paracoccidioidomycosis: ulcerated and erythematous lesion of palate. (Courtesy of Dr. Roman Carlos, Guatemala City, Guatemala.)

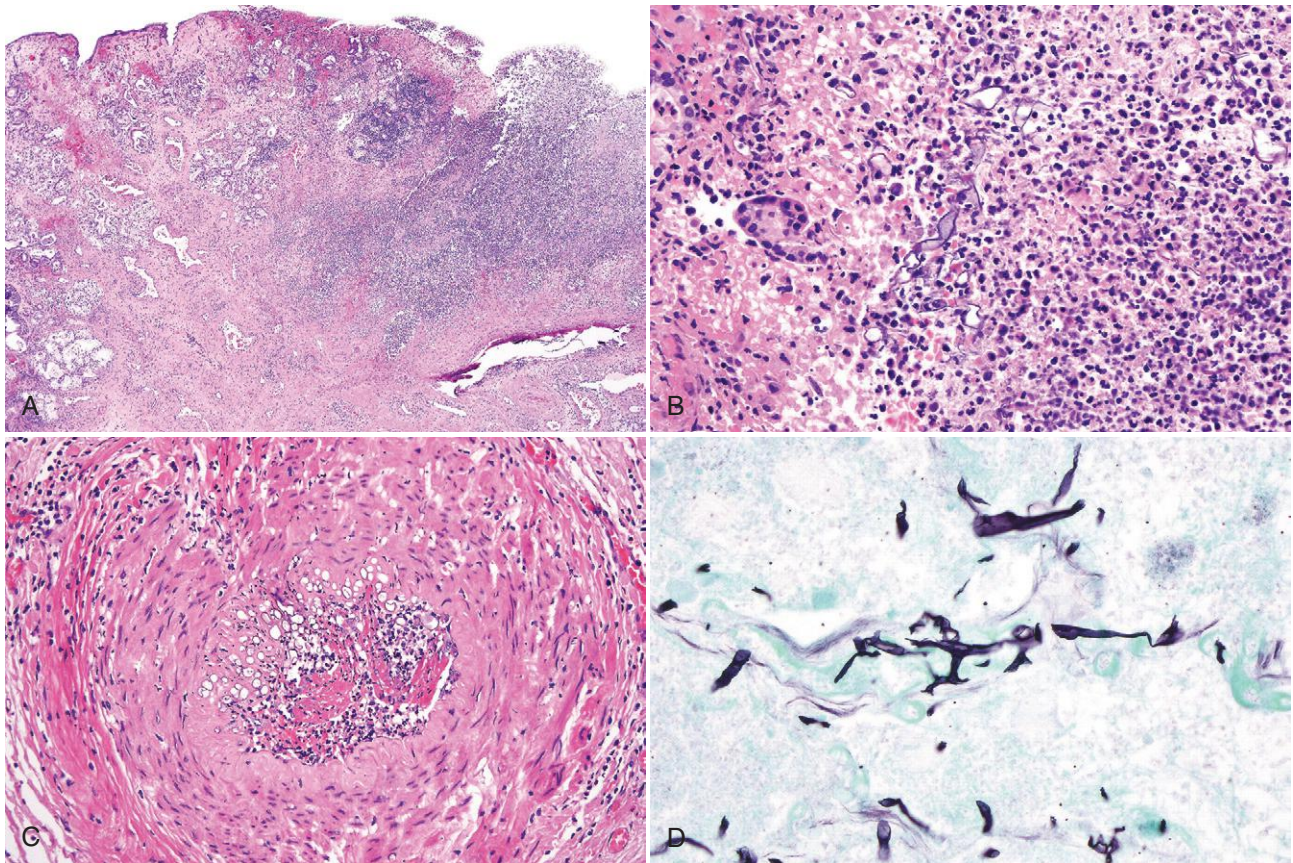


**FIGURE 4-9.** Oral coccidioidomycosis. **A**, Pseudoepitheliomatous hyperplasia and granulomatous inflammation within the muscle. **B**, Necrotizing granulomatous inflammation with many coccidioidal spherules. **C**, Granulomas with large spherules containing hundreds of endospores. (A, Courtesy of Dr. Roman Carlos, Guatemala.)



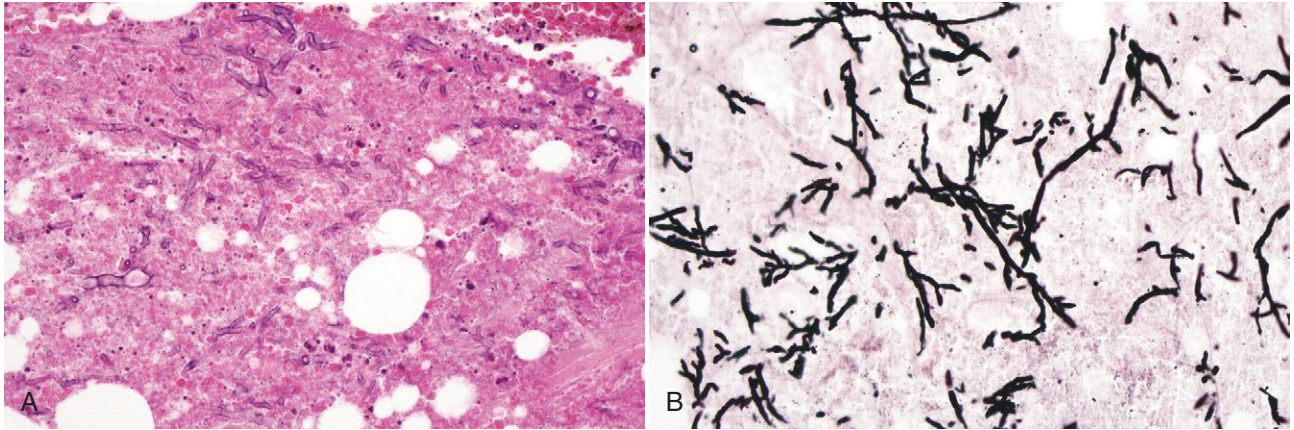


**FIGURE 4-10.** Histoplasmosis. **A**, Necrotizing granulomatous inflammation. **B**, Ovoid-to-round, silver-positive organisms (methenamine silver stain). (Courtesy of Dr. Dan Milner, Harvard Medical School, Boston, Mass.)

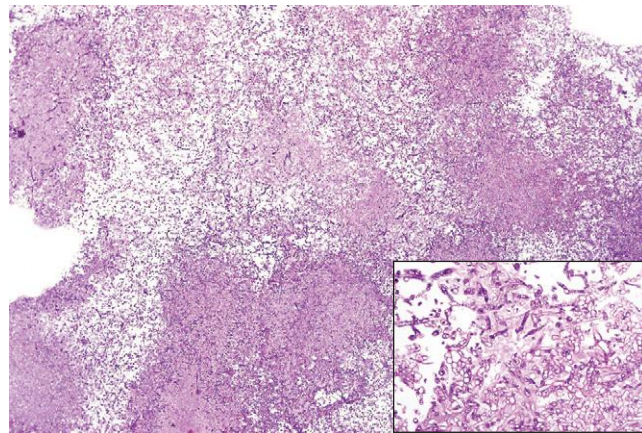


**FIGURE 4-11.** Zygomycosis. **A**, Sinus mucosa exhibiting areas of necrosis and ulceration. **B**, Ribbon-like fungi within area of necrosis. **C**, Artery with fungi within the wall. **D**, Ribbon-like organism with right-angled branching (methenamine silver stain).





**FIGURE 4-12.** Aspergillosis. **A**, Fungi within area of necrosis. **B**, Fungal hyphae with acute-angled branching (methenamine silver stain). (**A**, Courtesy of Dr. Dan Milner, Harvard Medical School, Boston, Mass.)



**FIGURE 4-13.** Mycetoma: mass of fungi within the sinus, not in the soft tissues (*inset*).

## HERPESVIRUS INFECTIONS

Table 4-1 shows the eight herpesviruses pathogenic in humans. All herpesviruses establish latency after a primary infection that may be subclinical or may exhibit only mild constitutional symptoms. Most adults in the United States are seropositive for many of the herpesviruses.

### HERPES SIMPLEX VIRUS INFECTION

#### Clinical Findings

- Primary herpetic gingivostomatitis: acute onset of painful coalescent ulcers on any mucosal surface but frequently on the labial mucosa, tongue, and gingiva; associated with viral prodrome, malaise, and fever; may be herpes simplex virus (HSV)-1 or -2; usually in children and young adults (Fig. 4-14, *A and B*)
- Recrudescence infection in healthy hosts: herpes labialis (e.g., fever blisters or cold sores) on the lip or on the keratinized mucosa of the hard palate and attached gingiva (see Fig. 4-14, *C-E*); painful, coalescent 2- to 3-mm ulcers; often induced by injury (e.g., sunburn) or trauma (e.g., after dental procedures)

- Recrudescence infection in immunocompromised hosts: ulcers anywhere on the oral mucosa may appear aphthous-like if on the nonkeratinized mucosa; often biopsied (see Fig. 4-14, *F*)
- Careful interpretation of positive cultures, because asymptomatic shedding (induced by trauma, illness, or stress) is a frequent occurrence
- At least 50% of cases of erythema multiforme are induced by HSV reactivation.

#### Etiopathogenesis and Histopathologic Features

- HSV and varicella zoster virus are DNA viruses that are destructive to epithelial cells; latency is established in sensory ganglia and periphery at mucosa.
- Multinucleated giant epithelial cells at the edge of the ulcer exhibit “nuclear molding” and acute and chronic inflammation (Fig. 4-15); nuclei contain “ground glass” amphophilic Cowdry inclusions.
- A biopsy of only the center of the ulcer without epithelium may not show viral inclusions and cannot be presumed negative for herpes simplex infection; it should be viewed as inadequate for diagnosis.

### Differential Diagnosis

- Varicella zoster virus has a similar cytopathic effect but clinically tends to be unilateral; culture and immunohistochemical studies differentiate between the two (Fig. 4-16).
- Inflammatory reactions may contain multinucleated giant epithelial cells, but these have dispersed chromatin, no Cowdry inclusions, prominent nucleoli, and abundant cytoplasm without nuclear molding.

### Management and Prognosis

- Primary infections or recrudescence infections in immunocompromised patients: hydration, supportive care, pain control, systemic acyclovir (low bioavailability), valacyclovir, or famciclovir

- Herpes labialis: 1- or 2-day treatment with valacyclovir or famciclovir, topical acyclovir, penciclovir, or docosanol; use of sunscreen to prevent recrudescence herpes labialis caused by sun damage

### REFERENCES

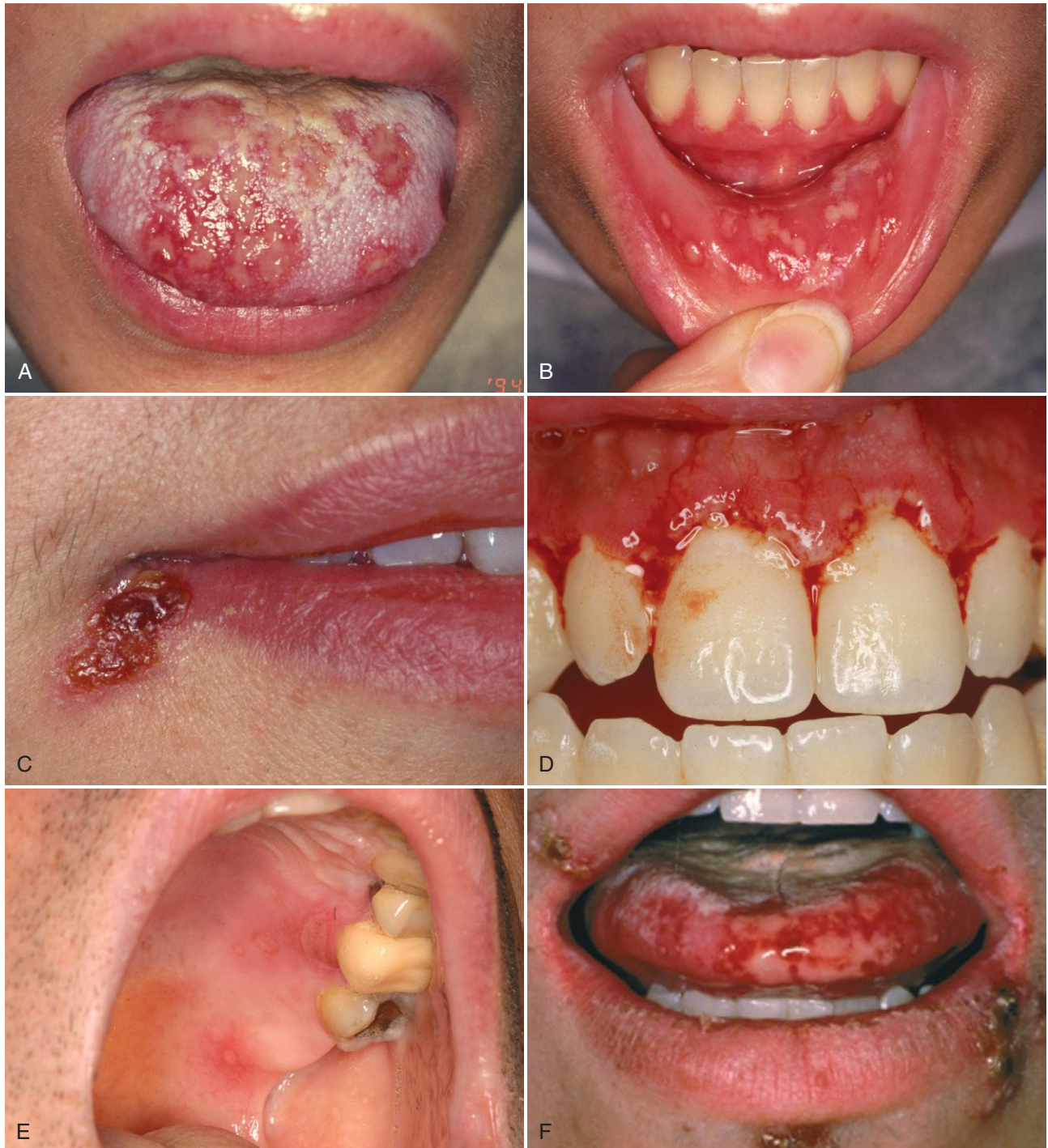- Elad S, Zadik Y, Hewson I, et al. A systematic review of viral infections associated with oral involvement in cancer patients: a spotlight on Herpesviridae. *Support Care Cancer*. 2010;18:993-1006.
- Eisen D. The clinical characteristics of intraoral herpes simplex virus infection in 52 immunocompetent patients. *Oral Surg Oral Med Oral Pathol Oral Radiol Endod*. 1998;86:432-437.
- Weathers DR, Griffin JW. Intraoral ulcerations of recurrent herpes simplex and recurrent aphthae: two distinct clinical entities. *J Am Dent Assoc*. 1970;81:81-87.
- Woo SB, Lee SF. Oral recrudescence herpes simplex virus infection. *Oral Surg Oral Med Oral Pathol Oral Radiol Endod*. 1997;83:239-243.
- Woo SB, Challacombe SJ. Management of recurrent oral herpes simplex infections. *Oral Surg Oral Med Oral Pathol Oral Radiol Endod*. 2007;103(suppl):S12 e1-8.

**TABLE 4-1** Herpesvirus Infections

Herpesvirus Type	Disease Manifestation in the Oral Cavity
HHV-1 HSV-1 Alpha virus	Primary herpetic gingivostomatitis or genital herpes; recrudescence herpes stomatitis or herpes labialis; genital herpes
HHV-2 HSV-2 Alpha virus	Although usually found on skin and mucosa below the waist, may also be found in the mouth with lesions identical to those of HSV-1
HHV-3 Varicella-zoster virus Alpha virus	Primary infection is chickenpox; recrudescence infection is facial or oral shingles along distribution of trigeminal nerve, usually unilateral; skin shingles
HHV-4 Epstein-Barr virus Gamma virus	Hairy leukoplakia in patients with HIV/AIDS, organ transplant recipients or other immunocompromised host Infectious mononucleosis, Burkitt lymphoma, nasopharyngeal carcinoma, central nervous system lymphoma, posttransplantation lymphoproliferative disorder, Hodgkin lymphoma Epstein-Barr virus–positive mucocutaneous ulcer in immunosuppressed host
HHV-5 Cytomegalovirus Beta virus	Oral ulcers, penetrating; may be bystander noted in other ulcerative lesions Infectious mononucleosis–like syndrome, retinitis, gastroenteritis, hepatitis, pneumonitis
HHV-6 Beta virus	No oral findings Roseola infantum, exanthema subitum
HHV-7 Beta virus	No oral findings Roseola infantum, exanthema subitum
HHV-8 Kaposi sarcoma herpesvirus Gamma virus	Oral, skin and visceral Kaposi sarcoma Primary effusion lymphoma, multicentric Castleman disease

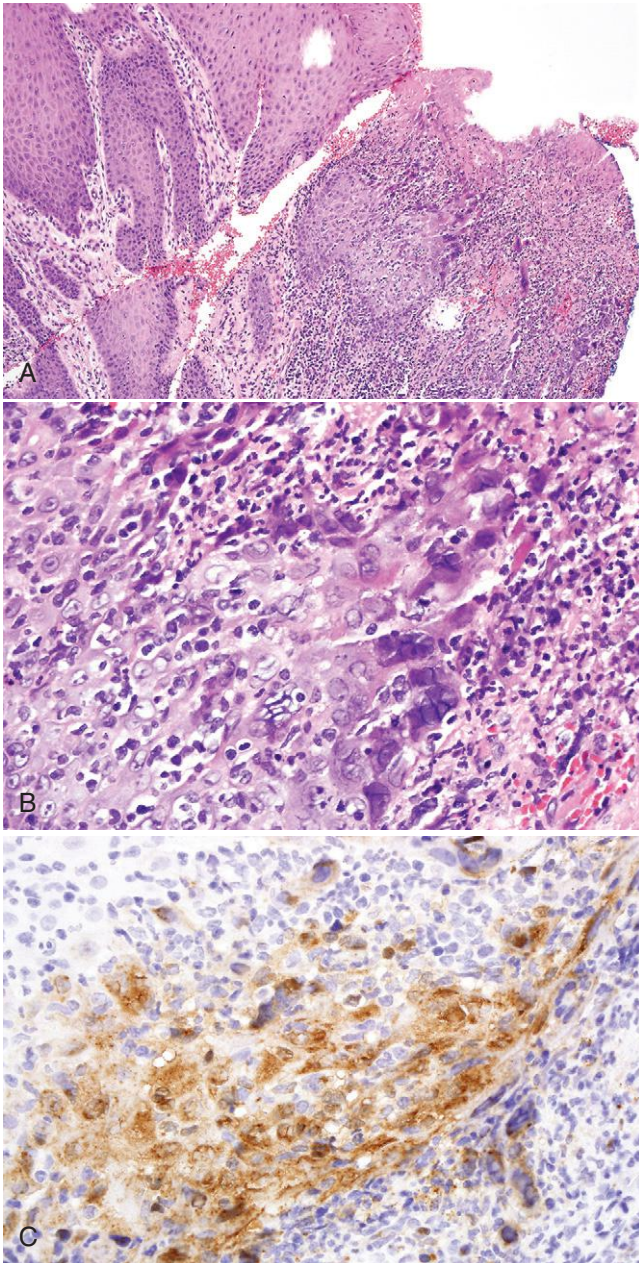
HHV, human herpes virus; HSV, herpes simplex virus; HIV/AIDS, human immunodeficiency virus/acquired immunodeficiency syndrome.





**FIGURE 4-14.** Herpes simplex virus. **A**, Primary infection with coalescent ulcers on tongue dorsum. **B**, Same patient as in **A** with ulcers on the nonkeratinized labial mucosa and marginal gingiva. **C**, Recrudescence herpes simplex virus: herpes labialis in immunocompetent host. **D**, Recrudescence herpes simplex on the attached gingiva in immunocompetent host. **E**, Recrudescence herpes simplex on the hard palatal mucosa. **F**, Recrudescence herpes simplex virus ulcer of the ventral tongue and skin in a patient with cancer.





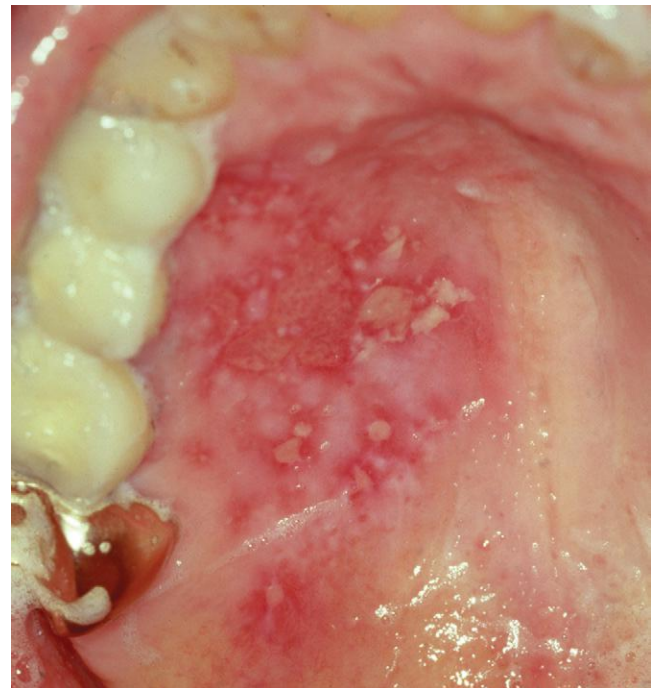
**FIGURE 4-15.** Herpes simplex virus (HSV). **A**, Oral mucosa with ulceration. **B**, Multinucleated epithelial cells with nuclear molding and Cowdry inclusions. **C**, Immunoperoxidase study confirms the presence of HSV-1.

### HAIRY LEUKOPLAKIA

Hairy leukoplakia is highly predictive of positive HIV status. The term *leukoplakia* as used in this context does not connote any tendency to dysplasia or malignancy.

#### Clinical Findings

- White, painless, linear, or plaquelike lesion usually of the lateral border of tongue; classically, white lines run perpendicular to the long axis of the tongue (Fig. 4-17)
- Seen in immunocompromised individuals, especially those with HIV/AIDS with low CD4 count and in



**FIGURE 4-16.** Recrudescence of varicella zoster infection: oral shingles exhibiting coalescent ulcers of the right side of the palate.

organ transplant recipients; rare cases have been reported in healthy patients

#### Etiopathogenesis and Histopathologic Features

Entry of virus from peripheral blood lymphocytes (reservoir for the virus) into the epithelium, followed by reactivation of the virus, leads to appearance of hairy leukoplakia.

- Variable hyperparakeratosis with or without bacterial colonization (factitial keratosis); candidal hyphae and/or conidia present—often in the absence of spongiotic pustules



- Sharp demarcation of parakeratin from the subjacent ballooned superficial keratinocytes; virally infected cells show “beading” of chromatin along nuclear membrane; Cowdry inclusion (“ground glass” amphophilic nuclear mass consisting of virions) fills the center of the nucleus (Figs. 4-18, A-C and 4-19); such findings are also seen in exfoliative cytology.
- Confirmation is nuclear positivity by in situ hybridization for Epstein-Barr encoded RNA (EBER), Epstein-Barr nucleic acid (EBNA), and latent membrane protein (LMP) (see Fig. 4-18, D).
- Electron microscopy confirms herpesvirus-sized particles in the center of the nucleus with chromatin margination at periphery (Fig. 4-20).

#### Differential Diagnosis

- Factitial/frictional keratoses from bite trauma do not show chromatin margination and are negative for Epstein-Barr virus (EBV) by in situ hybridization (Fig. 4-21).

#### Management and Prognosis

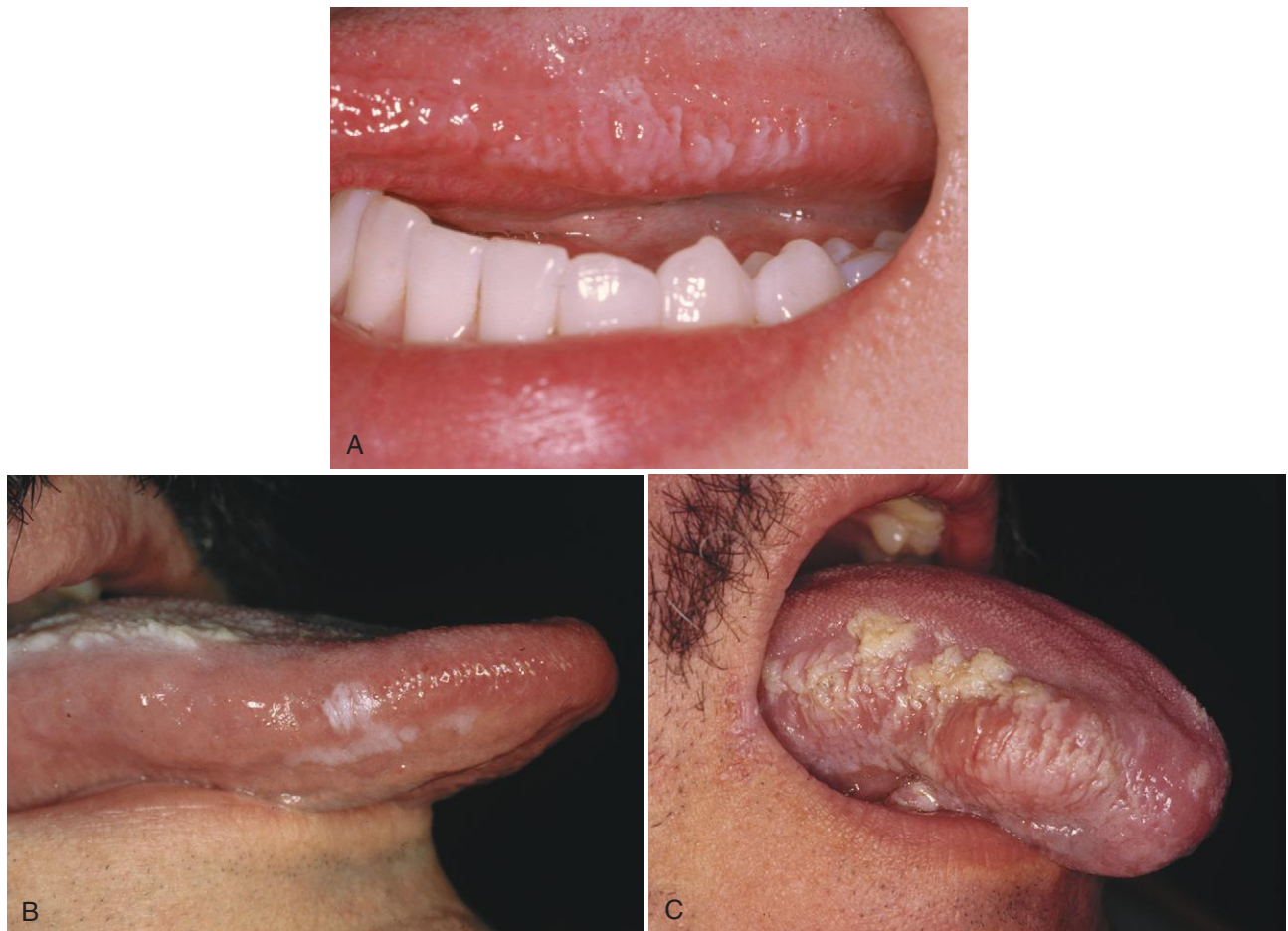- Adjustment of antiretroviral therapy or reduction of immunosuppressive therapy if post-organ

transplantation may resolve lesions; candidiasis should be treated.

- Cases may resolve with a combination of topical anti-herpetic medications (such as 1% penciclovir or 5% acyclovir cream/ointment) and 25% podophyllin resin.
- Treatment with valacyclovir reduces recurrence of disease in 67% of patients.
- Hairy leukoplakia may be first indication of HIV-positive status.

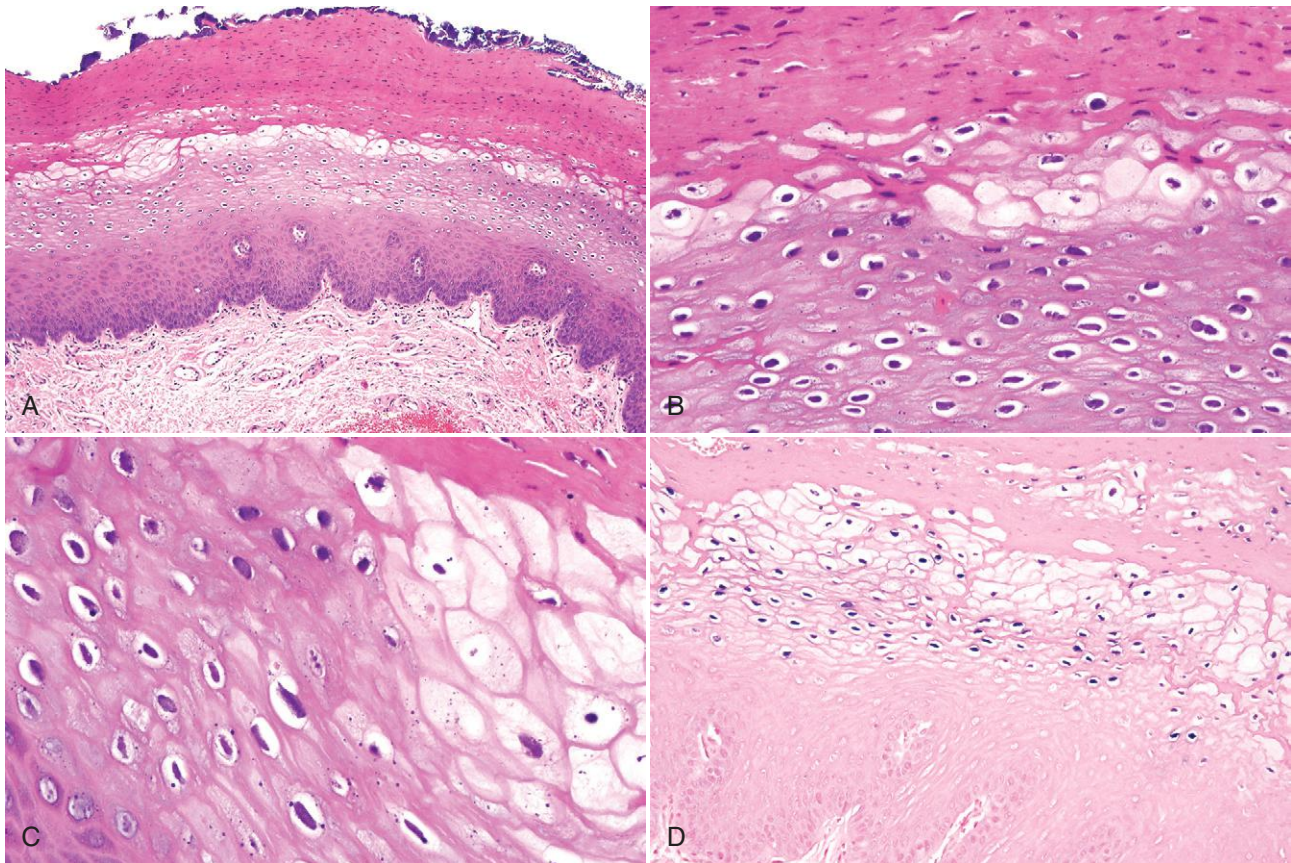
#### REFERENCES

- Bhayat A, Yengopal V, Rudolph M. Predictive value of group I oral lesions for HIV infection. *Oral Surg Oral Med Oral Pathol Oral Radiol Endod.* 2010;109:720-723.
- Casiglia J, Woo SB. Oral hairy leukoplakia as an early indicator of Epstein-Barr virus-associated post-transplant lymphoproliferative disorder. *J Oral Maxillofac Surg.* 2002;60:948-950.
- Fraga-Fernandez J, Vicandi-Plaza B. Diagnosis of hairy leukoplakia by exfoliative cytologic methods. *Am J Clin Pathol.* 1992;97:262-266.
- Moura MD, Haddad JP, Senna MI, et al. A new topical treatment protocol for oral hairy leukoplakia. *Oral Surg Oral Med Oral Pathol Oral Radiol Endod.* 2010;110:611-617.
- Walling DM, Etienne W, Ray AJ, et al. Persistence and transition of Epstein-Barr virus genotypes in the pathogenesis of oral hairy leukoplakia. *J Infect Dis.* 2004;190:387-395.

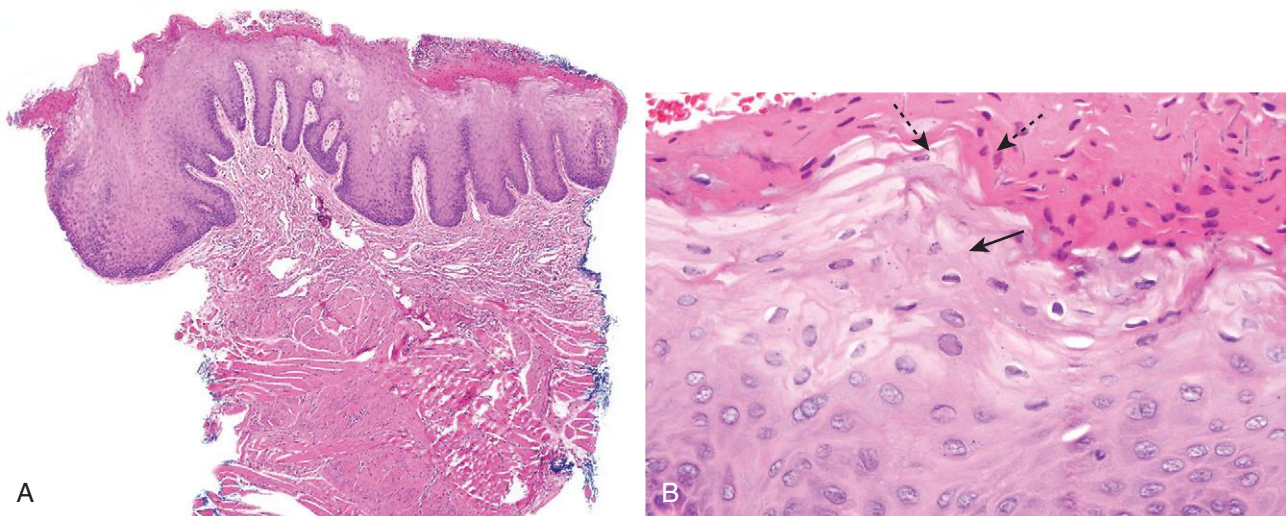


**FIGURE 4-17.** Hairy leukoplakia. **A**, Typical vertical fissures on lateral border of tongue. **B**, White plaque on lateral and ventral tongue. **C**, White plaque and fissures with hyperplastic candidiasis.



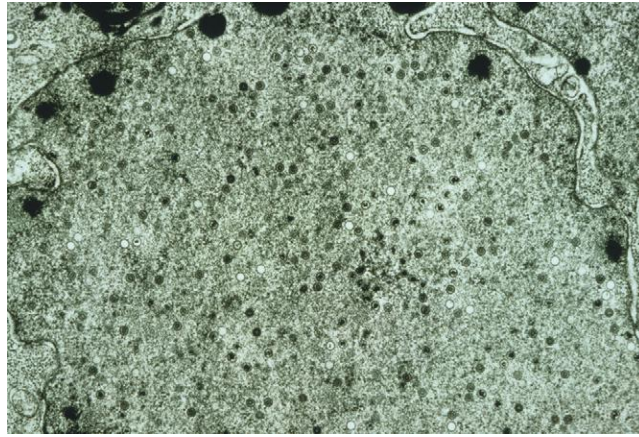


**FIGURE 4-18.** Hairy leukoplakia. **A**, Oral mucosa with sharply demarcated band of pale, ballooned cells with overlying factitial/frictional hyperparakeratosis. **B**, Cells with perinuclear halos and Cowdry inclusions. **C**, Cells with perinuclear halos and Cowdry inclusions. **D**, In situ hybridization study positive for nuclear Epstein-Barr virus.

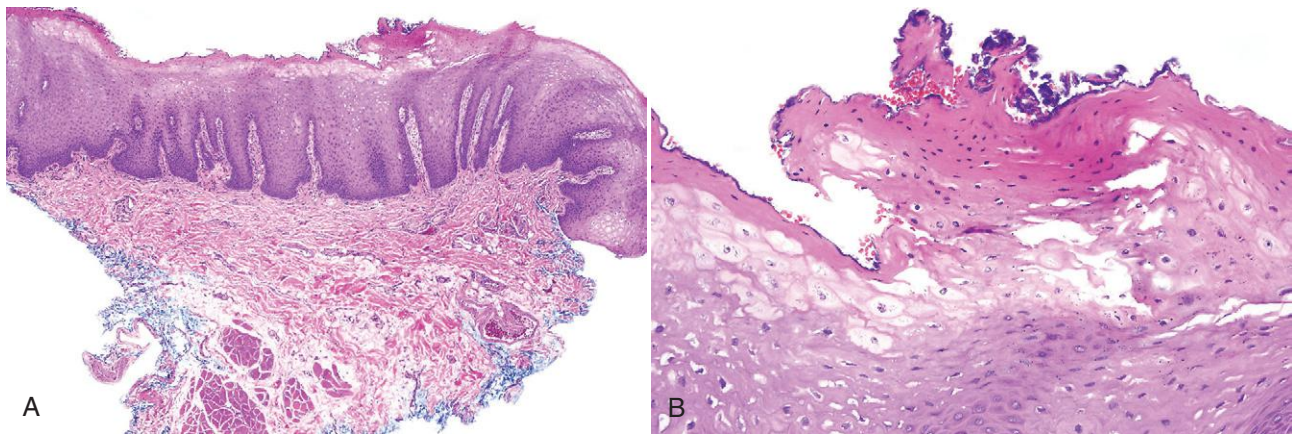


**FIGURE 4-19.** Hairy leukoplakia. **A**, Oral mucosa with a less-well-demarcated band of ballooned cells. **B**, Candidal colonization without spongiotic pustules, peripheral condensation of chromatin (dashed arrows), and Cowdry inclusions (solid arrow).





**FIGURE 4-20.** Hairy leukoplakia: electron photomicrograph showing peripheral condensation of chromatin (“beading”) and nucleus filled with virions that constitute the Cowdry inclusion.



**FIGURE 4-21.** Frictional/factitial keratosis. **A**, Oral mucosa with band of pale cells. **B**, No evidence of Cowdry inclusions or chromatin margination.

## CYTOMEGALOVIRUS INFECTION

### Clinical Findings

- Large, usually solitary, painful ulcer on the oral mucosa (Fig. 4-22) that is often nonspecific appearing; antigenemia may be present
- Seen in immunocompromised individuals, especially those with HIV/AIDS or who are organ transplant recipients

### Etiopathogenesis and Histopathologic Features

Cytomegalovirus infects monocytes, endothelial cells, and fibroblasts in the deep lamina propria; it may also represent an incidental finding (“passenger”) in an ulcer caused by another agent such as herpes simplex virus and may be seen in clinically normal skin; latency is established within endothelial cells, T cells, monocytes, and stromal cells.

- Mucosal ulceration; large, ballooned cells within the endothelium or mesenchymal cells in the connective tissue; “owl-eye” nuclei with prominent nucleoli

(Fig. 4-23); dark pink granules present in cytoplasm (Fig. 4-24, A-C); confirmation with in situ hybridization (see Fig. 4-24, D); biopsies must be of sufficient depth for this condition to be adequately ruled out

- Presence of antigenemia alone not sufficient for the diagnosis

### Differential Diagnosis

- EBV-associated mucocutaneous ulcers contain a polymorphous infiltrate characterized by atypical Hodgkin-like cells or Reed-Sternberg-like cells with background B cells that are CD30 and EBER positive, as well as many T cells; some cases show clonal immunoglobulin gene rearrangement and others show clonal and restricted T cell patterns; some lesions regress and others relapse and remit.

### Management and Prognosis

- Ganciclovir or valganciclovir are the treatments of choice.
- Immunosuppressive regimens are reduced.

## REFERENCES

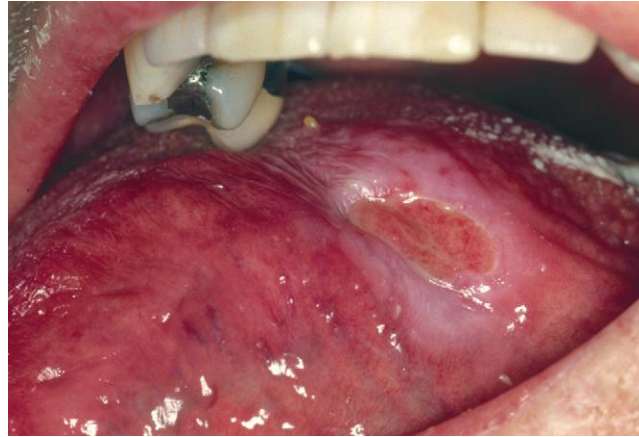
Dauden E, Fernandez-Buezo G, Fraga J, et al. Mucocutaneous presence of cytomegalovirus associated with human immunodeficiency virus infection: discussion regarding its pathogenetic role. *Arch Dermatol.* 2001;137:443-448.

Dojcinov SD, Venkataraman G, Raffeld M, et al. EBV positive mucocutaneous ulcer—a study of 26 cases associated with various sources of immunosuppression. *Am J Surg Pathol.* 2010;34:405-417.

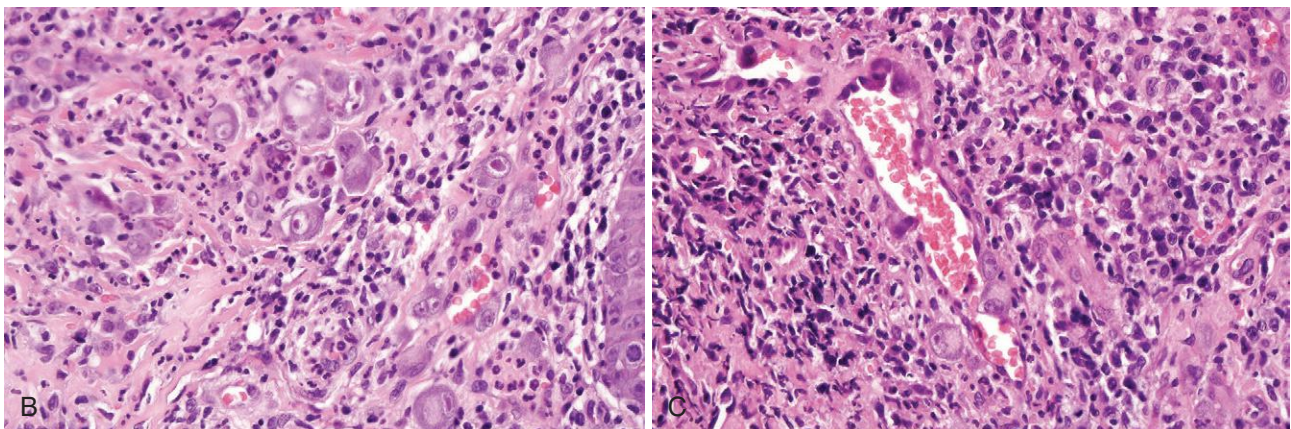
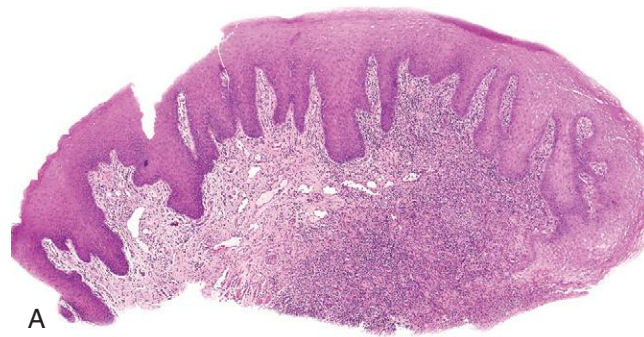
Eid AJ, Razonable RR. New developments in the management of cytomegalovirus infection after solid organ transplantation. *Drugs.* 2010;70:965-981.

Meer S, Altini M. Cytomegalovirus co-infection in AIDS-associated oral Kaposi's sarcoma. *Adv Dent Res.* 2006;19:96-98.

Tarkan JL, Woo SB, Pavlakis M, et al. Spotting the owl: surreptitious cytomegalovirus disease in a renal transplant recipient. *Clin Transplant.* 2008;22:391-395.

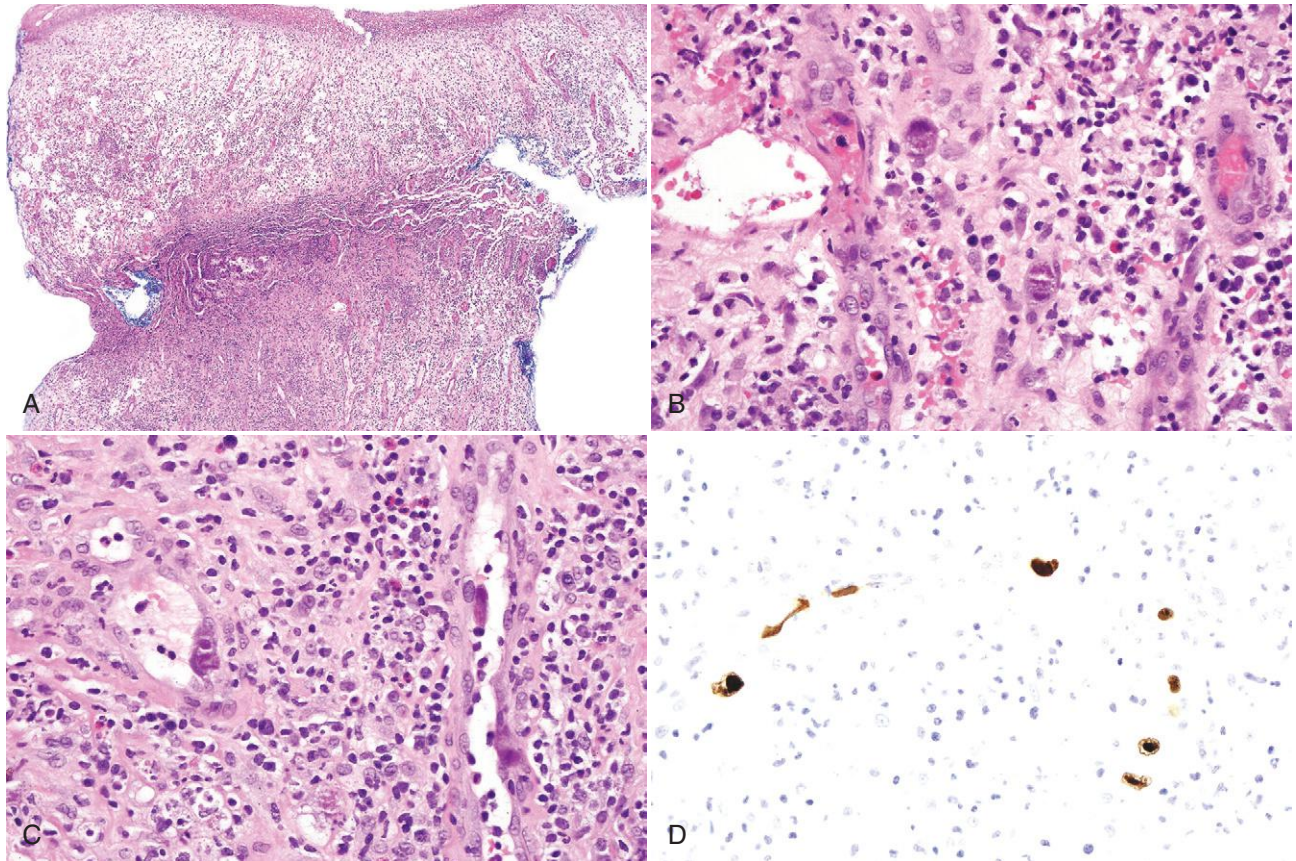


**FIGURE 4-22.** Cytomegalovirus-infected ulcer of the left ventral tongue.



**FIGURE 4-23.** Cytomegalovirus infection. **A**, Ulcerated oral mucosa (ulcer at bottom). **B**, Ballooned cells with large nuclei and prominent red nucleoli ("owl eye"). **C**, Involvement of endothelium by cytomegalovirus.





**FIGURE 4-24.** Cytomegalovirus infection. **A**, Oral mucosa with extensive ulceration. **B**, Infected cells with dark pink granules. **C**, Involvement of endothelium by cytomegalovirus. **D**, In situ hybridization positive for cytomegalovirus.

## HUMAN PAPILLOMAVIRUS–RELATED BENIGN LESIONS

Squamous papilloma, verruca vulgaris, condyloma acuminatum, and Heck disease are discussed together because of similarities in clinical presentation and histopathology.

### Clinical Findings

- Painless, exophytic, papillary/verrucous, white or pink, sessile or pedunculated growths appear on the mucosa usually in young patients.
- Squamous papillomas are often seen on the soft palate or tongue, white or pink; verruca vulgaris is often on the gingiva, lips, and palate and is almost always white (Fig. 4-25, *A* and *B*).
- Condylomata are single or multiple, papular or papillary, and often seen in immunocompromised hosts (Fig. 4-25, *C-E*).
- Lesions in Heck disease are papular and multiple, often seen in the young (first and second decade) living in crowded conditions in South and Central America with a prevalence of up to 13%; it is also common in Africa, the middle East, in patients with

HIV/AIDS, and sporadically in North America (see Fig. 4-25, *F*).

### Etiopathogenesis, Histopathologic Features, and Differential Diagnosis

These are related to human papillomavirus infection; in situ hybridization and polymerase chain reaction (PCR) studies to subtype the viruses have allowed these to be characterized more accurately.

- See Table 4-2 and Figures 4-26 to 4-36.

### Differential Diagnosis

- Acanthosis nigricans has similar histology to squamous papilloma or condyloma without involvement by human papillomavirus; patients have visceral malignancy (Fig. 4-37).

### Management and Prognosis

- Excision is the treatment of choice if lesions are solitary; viral particles have been identified in laser plumes.
- Imiquimod may be useful for vermilion lesions, but it is difficult to keep localized for intraoral applications.

**TABLE 4-2** Histopathologic Features and Differential Diagnosis for Squamous Papilloma, Verruca Vulgaris, and Condyloma Acuminatum

Condition	HPV Subtype*	Histopathologic Features	Differential Diagnosis
Squamous papilloma (see Figs. 4-25 to 4-29)	6, 11	Papillary epithelial proliferation in thin ribbons with variable keratosis Soft palate and ventral tongue lesions may show prominent keratinocyte edema with minimal keratin; inflammation often leads to spongiosis and loss of keratin Basal cell hyperplasia often present; koilocytes not always present Fibrovascular cores edematous or hyalinized	Giant cell fibroma has stellate-shaped, giant and multinucleated fibroblast-like cells Papillary epithelial dysplasia exhibits significant cytologic atypia that is not reactive in nature
Verruca vulgaris (see Figs. 4-30 to 4-32)	1, 2, 4, 57	Papillary epithelial proliferation with thick orthokeratin, large kerato-hyaline granules and axial inclination of peripheral rete ridges Koilocytes usually present Inflammation may lead to significant reactive atypia, parakeratosis, and dyskeratosis (especially lip and cutaneous lesions)	Irritated seborrheic keratosis may look similar but with more basaloid cells Inverted follicular keratosis tends to follow orientation of hair follicle
Condyloma acuminatum (see Figs. 4-33 to 4-35)	6, 11	Papillary form—papillary epithelial proliferation with little keratin and large bulbous rete ridges †Koilocytes always seen; basal cell hyperplasia often present Papular form—epithelial hyperplasia without papillary features forming bulbous rete ridges Koilocytes and mitosoid bodies (karyorrhectic cells with coarse, fragmented chromatin) often present	Verrucous hyperplasia is broad-based with marked hyperkeratosis and bulbous rete ridges with variable cytologic atypia/dysplasia Verrucous carcinoma has an endophytic as well as exophytic growth pattern and is hyperparakeratotic Papular form is indistinguishable from Heck disease without HPV subtyping
Heck disease (see Fig. 4-36)	13, 32, 55	Similar to papular form of condyloma acuminatum (see earlier)	Indistinguishable from condyloma acuminatum without HPV subtyping

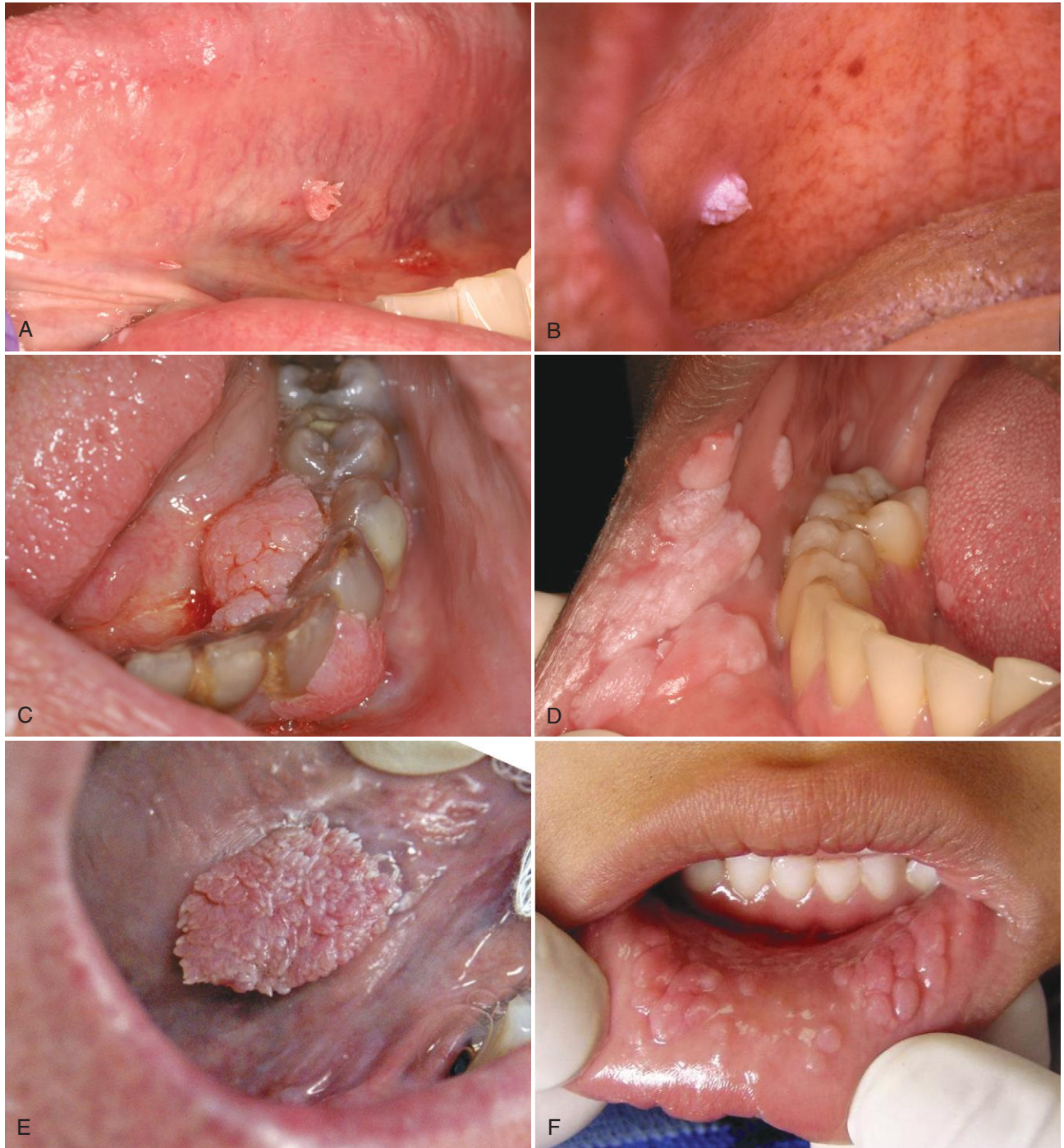\*Not seen in every case.

†Koilocytes exhibit irregular, twisted nuclear outlines and nuclear hyperchromatism; perinuclear halos alone are not sufficient for the diagnosis.  
HPV, human papillomavirus.

## REFERENCES

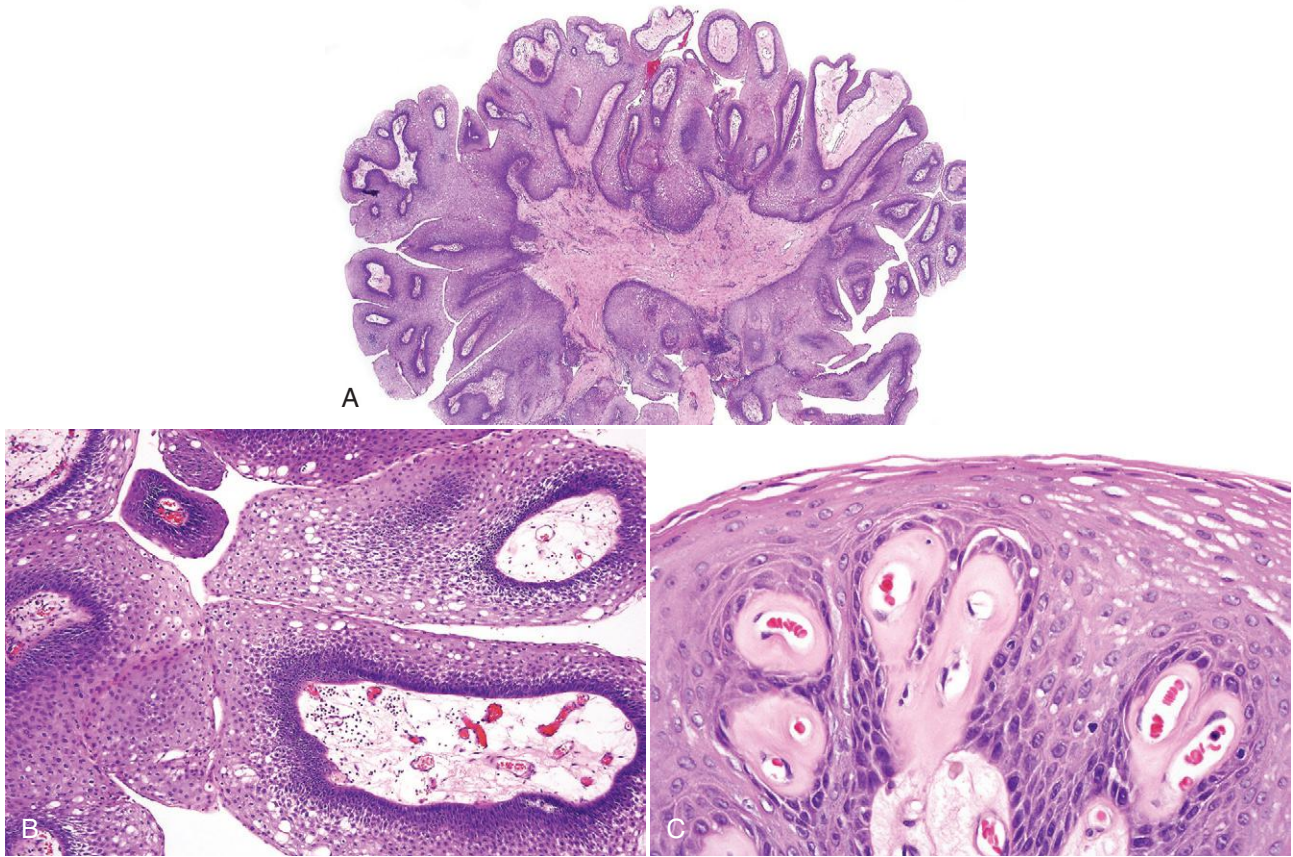
- Abbey LM, Page DG, Sawyer DR. The clinical and histopathologic features of a series of 464 oral squamous papillomas. *Oral Surg Oral Med Oral Pathol.* 1980;49:419-428.
- Anderson KM, Perez-Montiel D, Miles L, et al. The histologic differentiation of oral condyloma acuminatum from its mimics. *Oral Surg Oral Med Oral Pathol Oral Radiol Endod.* 2003;96:420-428.
- Cuberos V, Perez J, Lopez CJ, et al. Molecular and serological evidence of the epidemiological association of HPV 13 with focal epithelial hyperplasia: a case-control study. *J Clin Virol.* 2006;37:21-26.
- Damm DD, Roddy SC, White DK. Diffuse oral papillomatosis with corrugated lesions of skin. *Oral Surg Oral Med Oral Pathol Oral Radiol Endod.* 2008;106:630-636.
- Gonzalez LV, Gaviria AM, Sanclemente G, et al. Clinical, histopathological and virological findings in patients with focal epithelial hyperplasia from Colombia. *Int J Dermatol.* 2005;44:274-279.
- Syrjanen S. Human papillomavirus infections and oral tumors. *Med Microbiol Immunol.* 2003;192:123-128.
- Zunt SL, Tomich CE. Oral condyloma acuminatum. *J Dermatol Surg Oncol.* 1989;15:591-594.



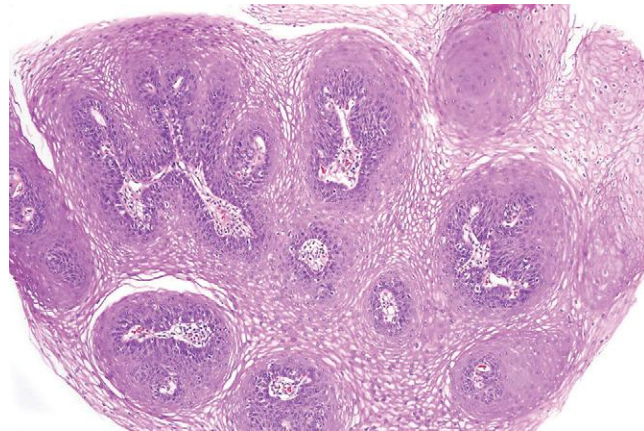


**FIGURE 4-25.** **A**, Squamous papilloma of the left ventral tongue. **B**, Verruca vulgaris of the right hard palate mucosa. **C**, Condyloma acuminatum (one of many) in a patient after lung transplantation. **D**, Condyloma acuminata in a patient with HIV/AIDS. **E**, Condyloma acuminatum in a healthy patient. **F**, Heck disease in a patient from Guatemala. (**A**, Courtesy of Dr. Mark Lerman, Lecturer, Harvard School of Dental Medicine, Boston, Mass; **B**, Courtesy of Dr. John Lovas, Dalhousie University, Halifax, Nova Scotia, Canada; **D**, Courtesy of Dr. Mark Lerman, Harvard School of Dental Medicine, Boston, Mass; **E**, Courtesy of Dr. Sherwin Kershman, private practice, Houston, Tex; **F**, Courtesy of Dr. Roman Carlos, Guatemala City, Guatemala.)



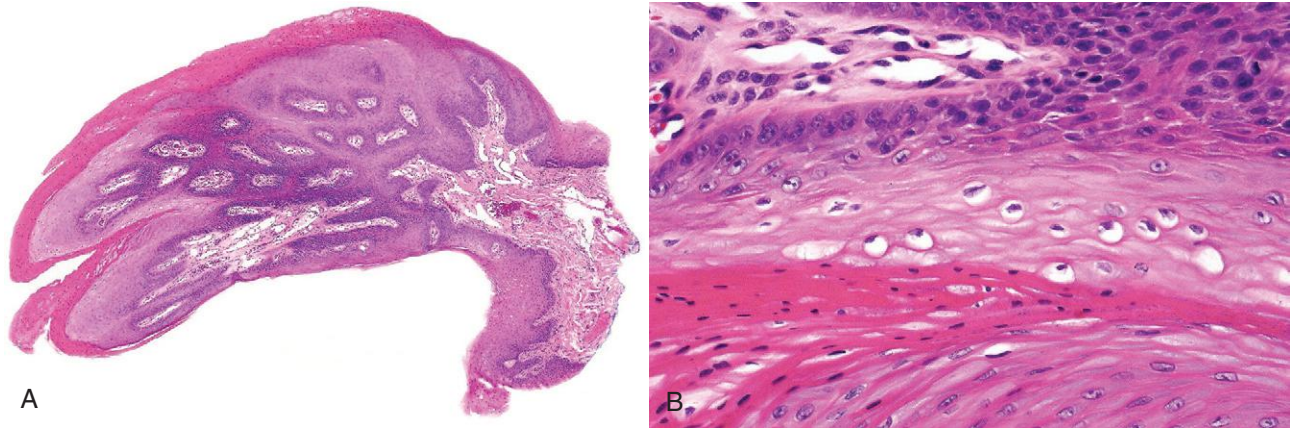


**FIGURE 4-26.** Squamous papilloma. **A**, Lesion of soft palate typically with little keratin. **B**, Basal cell hyperplasia and edematous fibrovascular cores. **C**, Fibrovascular cores with hyalinization.

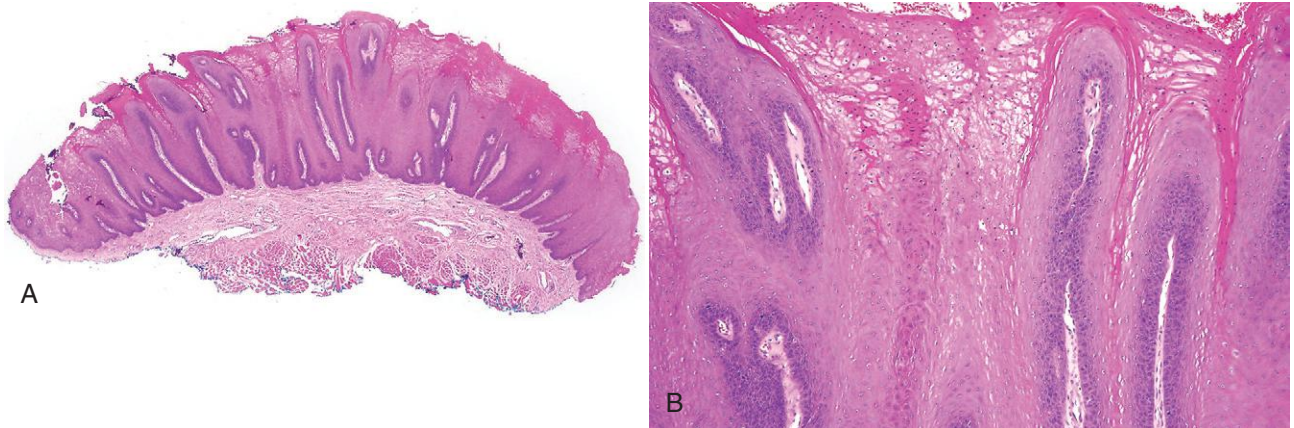


**FIGURE 4-27.** Squamous papilloma: lesion of soft palate with koilocytes in *upper right* and prominent keratinocytic edema.

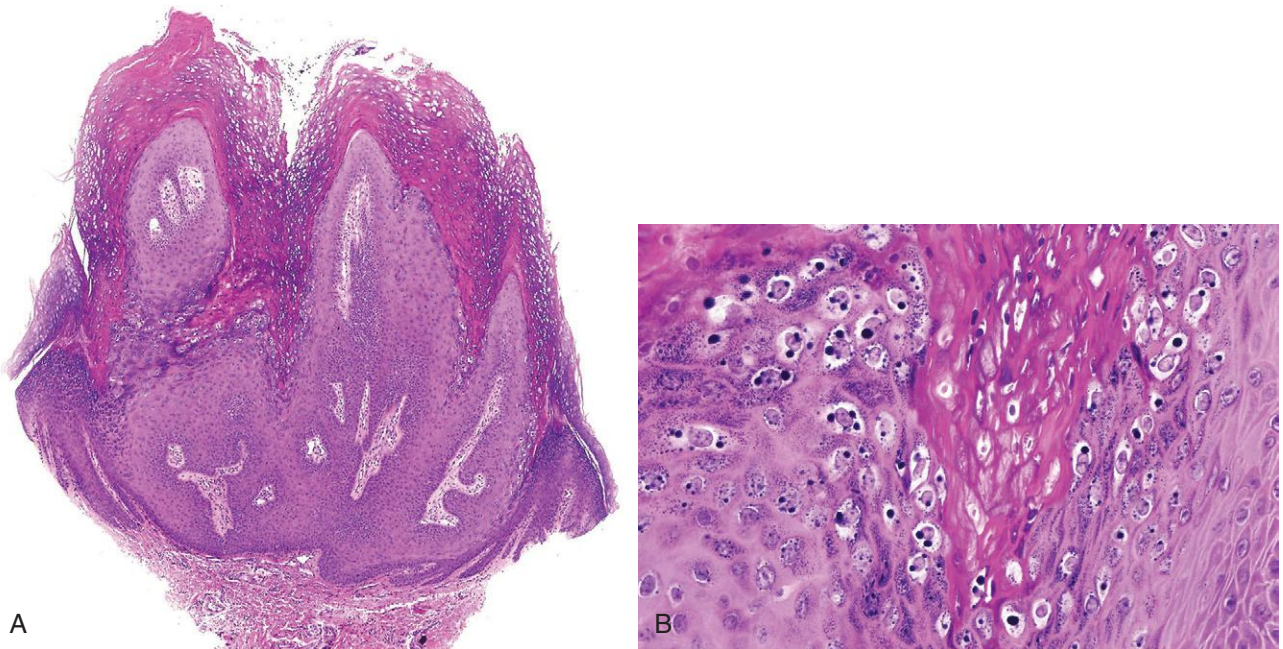




**FIGURE 4-28.** Squamous papilloma. **A**, Lesion of tongue with marked parakeratosis. **B**, Parakeratosis and koilocytes present.

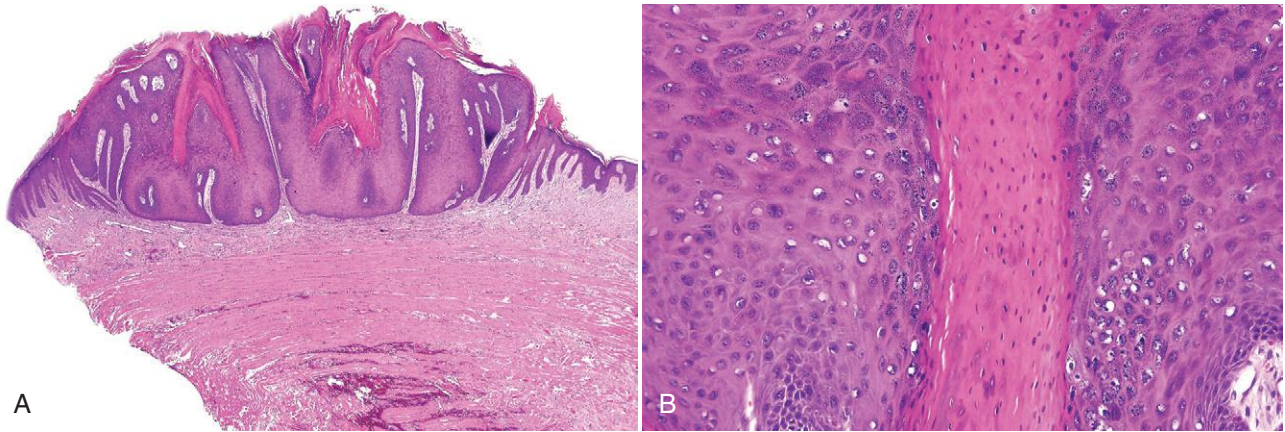


**FIGURE 4-29.** Squamous papilloma. **A**, Lesion of tongue that is broad based with axial inclination of rete ridges. **B**, Marked parakeratosis and papillary epithelial hyperplasia.

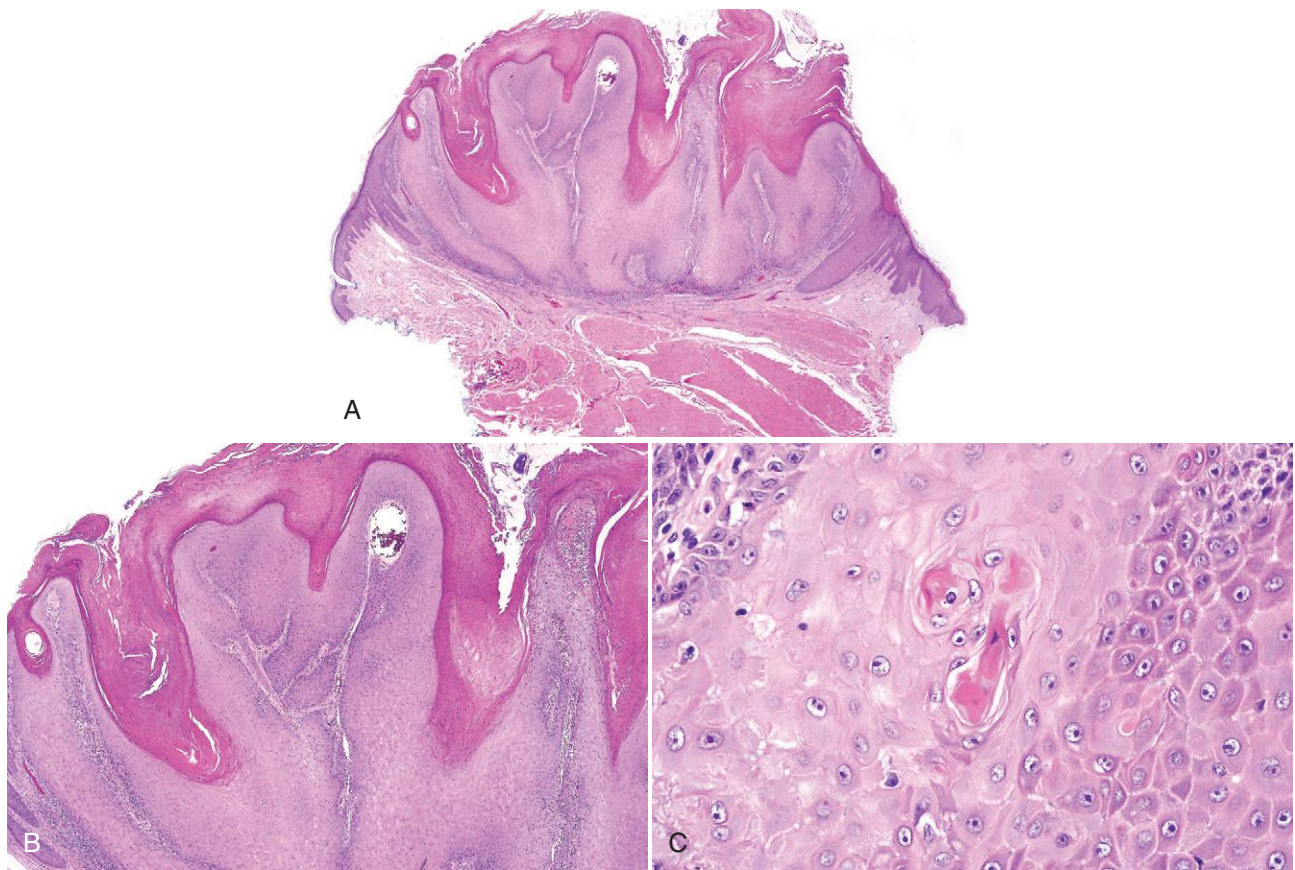


**FIGURE 4-30.** Verruca vulgaris. **A**, Papillary epithelial proliferation with axial inclination of rete ridges. **B**, Large kerato-hyaline granules.



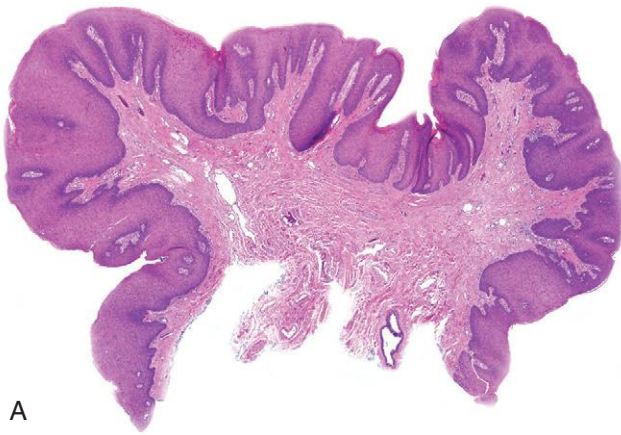

**FIGURE 4-31.** Traumatized verruca vulgaris. **A**, Papillary epithelial proliferation and bulbous rete ridges with axial inclination. **B**, Parakeratosis and small kerato-hyaline granules.

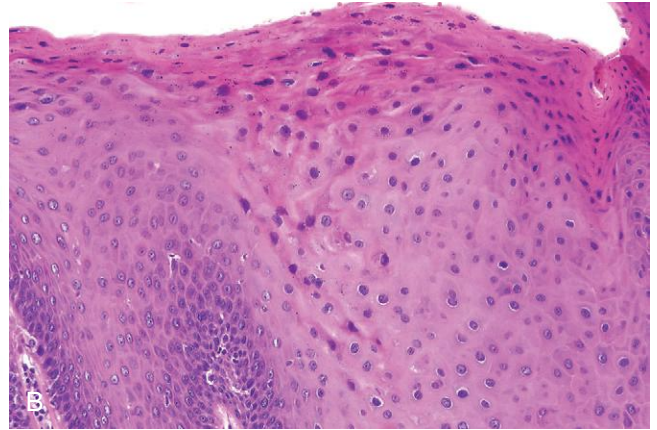


**FIGURE 4-32.** Traumatized and inflamed verruca vulgaris. **A**, Papillary epithelial proliferation with bulbous rete ridges with axial inclination. **B**, Epithelial proliferation with parakeratosis and spongiotic pustules in upper right. **C**, Reactive epithelial atypia and dyskeratosis.

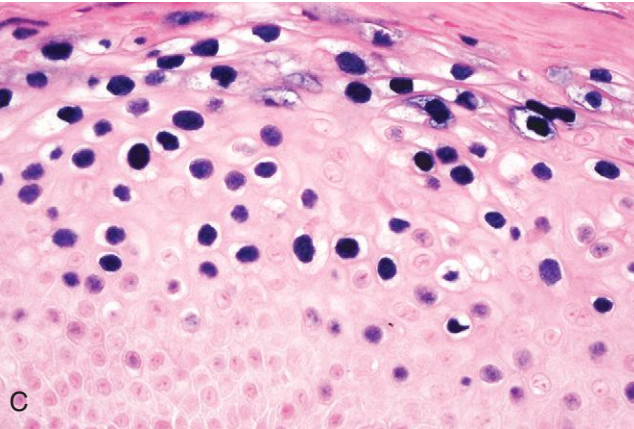




A

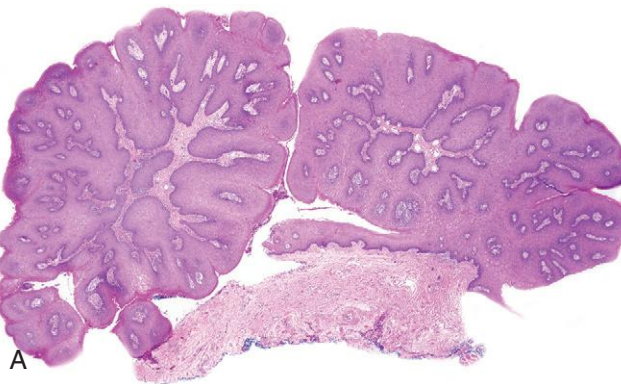


B

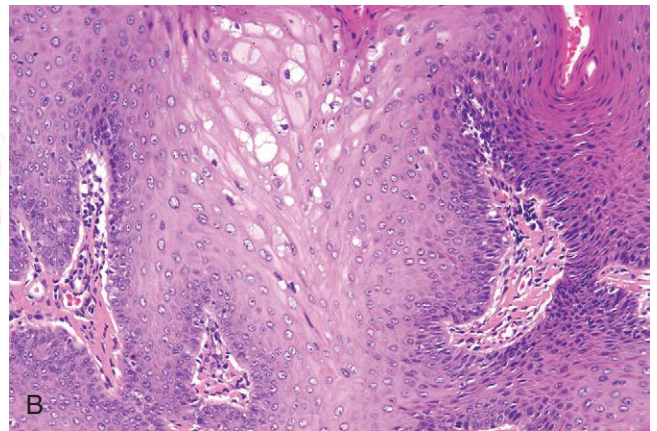


C

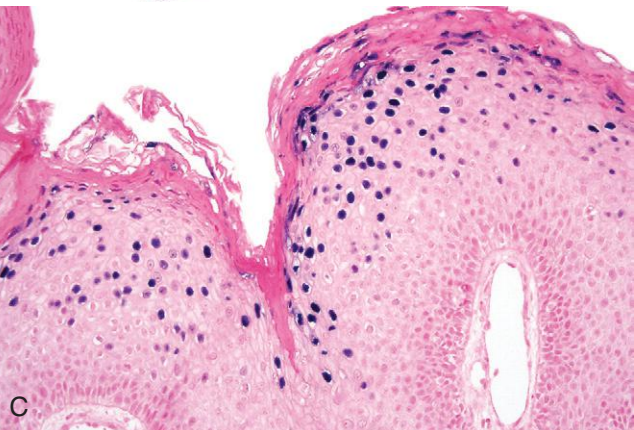
**FIGURE 4-33.** Condyloma acuminatum. **A**, Papular type. **B**, Koilocytes containing smudgy chromatin without significant perinuclear halos. **C**, In situ hybridization shows positivity for low-risk human papillomavirus subtypes.



A



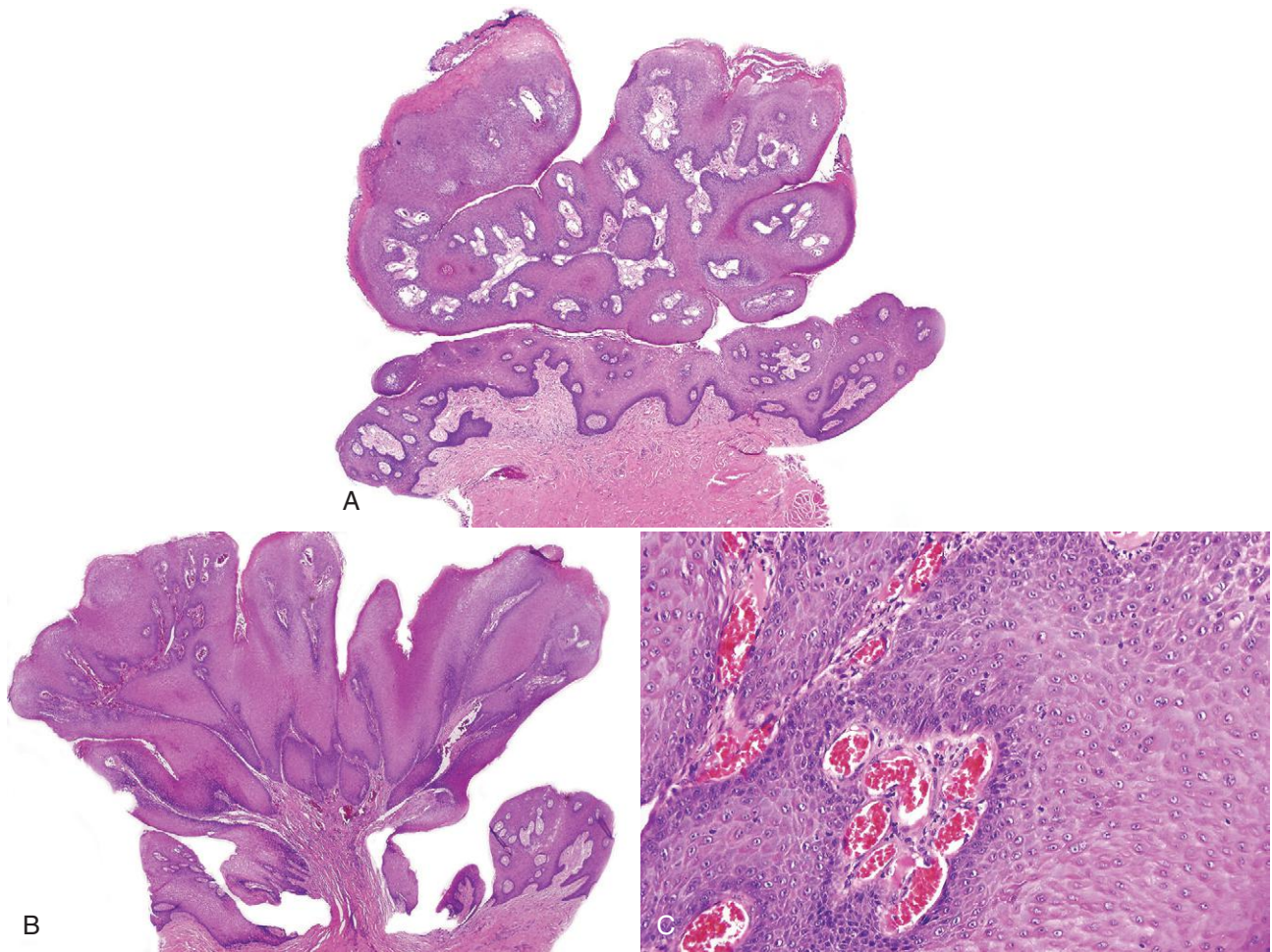
B



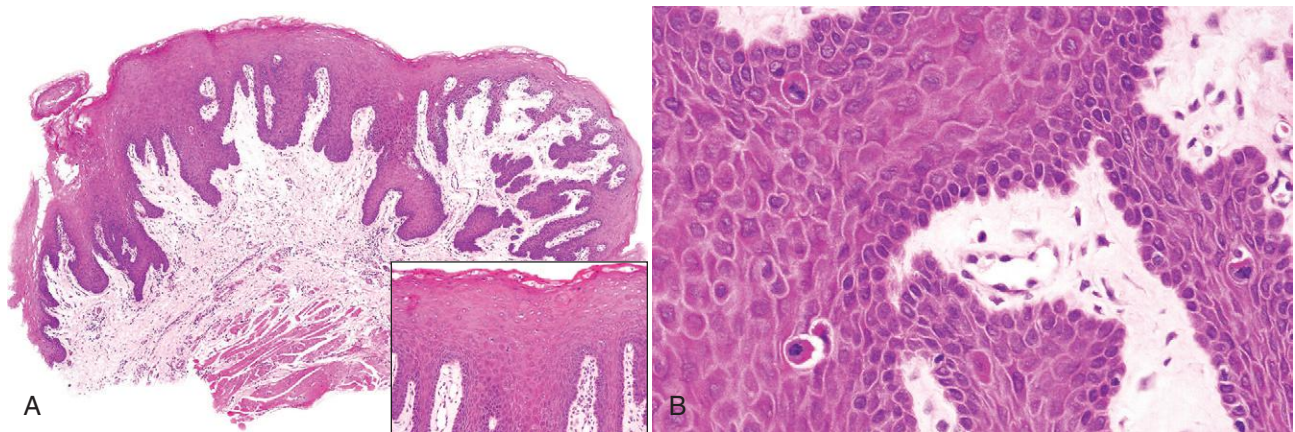
C

**FIGURE 4-34.** Condyloma acuminatum. **A**, Papillary type. **B**, Mild basal cell hyperplasia and subtle koilocytes. **C**, In situ hybridization positive for low-risk human papillomavirus subtypes.



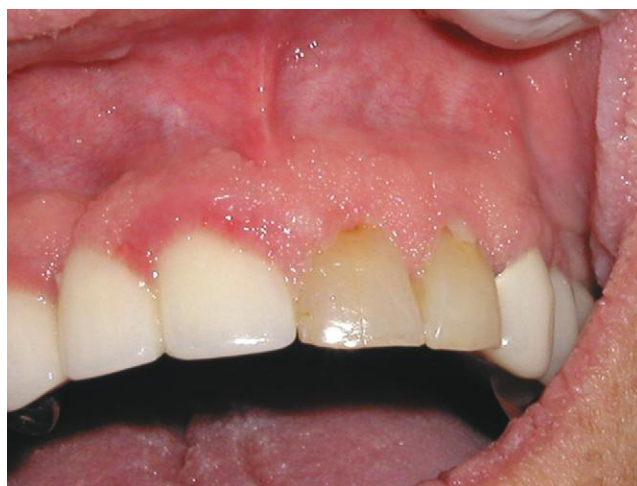

**FIGURE 4-35.** Condyloma acuminatum, traumatized. **A**, Pedunculated lesion with parakeratosis. **B**, Another section of the lesion from **A** showing bulbous rete ridges. **C**, Basal hyperplasia with atypia.



**FIGURE 4-36.** Heck disease. **A**, Benign epithelial hyperplasia with koilocytes and mitosoid bodies (inset). **B**, Karyorrhectic mitosoid bodies.





**FIGURE 4-37.** Acanthosis nigricans: diffuse papillomatosis of the anterior maxillary facial gingiva. (From Damm DD, Roddy SC, White DK. Diffuse oral papillomatosis with corrugated lesions of the skin. *Oral Surg Oral Med Oral Pathol Oral Radiol Endod.* 2008;106:630-636.)

## SYPHILIS

### Clinical Findings

- A resurgence of this condition within the past 2 decades has been noted, especially in men who have sex with men.
- Primary lesion (chancre) occurs within 2 to 8 weeks at site of inoculation, and the most common extra-genital site is the mouth, where it appears as a painless ulcer (Fig. 4-38, A).
- Secondary syphilis occurs within 2 to 12 weeks as a result of hematogenous spread and manifests as grayish plaques in the mouth, usually soft palate and tongue (“mucous patch”) and an erythematous skin rash mimicking other conditions (see Fig. 4-38, B); condyloma latum occurs on the skin and genitalia.
- In one third of patients, untreated syphilis results in tertiary lesions that are granulomatous (gumma); syphilitic endarteritis of organs results in organ-specific disease.
- Congenital syphilis is typified by deafness, notched incisors, “mulberry molars,” rhagades, and interstitial keratitis.

### Etiopathogenesis and Histopathologic Features

The spirochete responsible for this sexually transmitted disease is *Treponema pallidum*.

- Primary and secondary lesions: epithelium exhibits spongiosis and leukocyte exocytosis and may be hyperplastic or atrophic; lymphoplasmacytic infiltrate in the lamina propria in a subepithelial band and around blood vessels that may show endarteritis (Fig. 4-39, A-D); thin, threadlike, “cork-screw” organisms can be identified with Warthin-Starry, modified Steiner, or Dieterle stain, or by immunohistochemistry (see Fig. 4-39, E).

- Tertiary lesions consist of granulomatous inflammation that does not usually show the presence of the organism, except with PCR.
- Screening tests that evaluate for the presence of antibodies include the Venereal Disease Research Laboratory (VDRL) and rapid plasma reagin tests; confirmation is achieved with fluorescent treponemal antibody-absorption test, *Treponema pallidum* particle agglutination assay, microhemagglutination, or PCR; other tests include dark-field microscopy.

### Differential Diagnosis

- Identification of the organism is the key to diagnosis because the mucosal inflammatory lesion appears nonspecific.

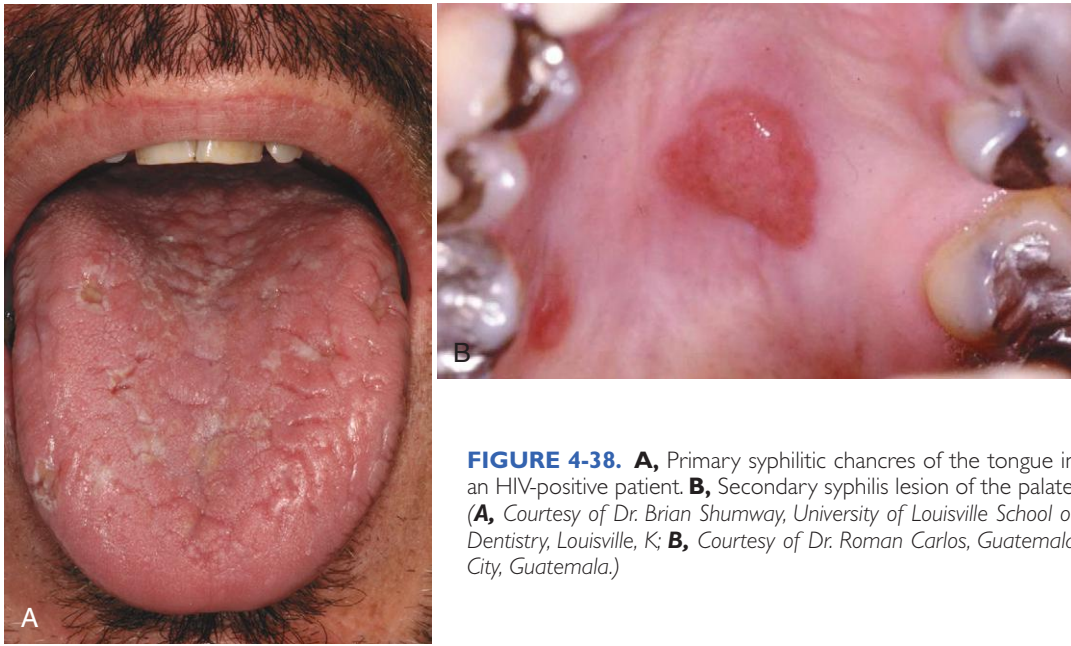
### Management

- Intramuscular penicillin G is the treatment of choice; tetracycline, doxycycline, and azithromycin are effective.

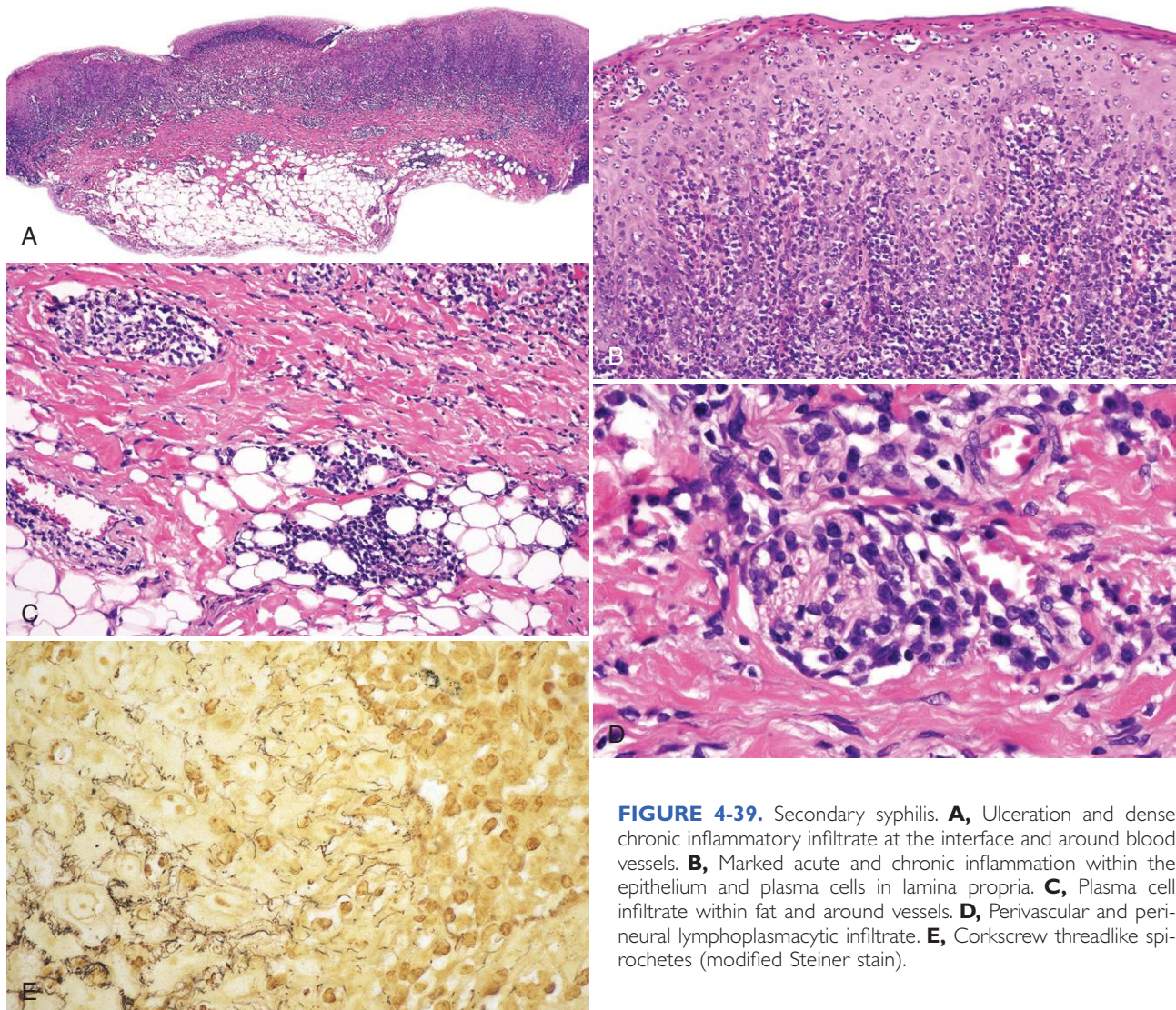
### REFERENCES

- Barrett AW, Villarreal Dorrego M, Hodgson TA, et al. The histopathology of syphilis of the oral mucosa. *J Oral Pathol Med.* 2004;33:286-291.
- Ficarra G, Carlos R. Syphilis: the renaissance of an old disease with oral implications. *Head Neck Pathol.* 2009;3:195-206.
- Hoang MP, High WA, Molberg KH. Secondary syphilis: a histologic and immunohistochemical evaluation. *J Cutan Pathol.* 2004;31:595-599.
- Liu H, Rodes B, Chen CY, Steiner B. New tests for syphilis: rational design of a PCR method for detection of *Treponema pallidum* in clinical specimens using unique regions of the DNA polymerase I gene. *J Clin Microbiol.* 2001;39:1941-1946.
- Murrell GL. Secondary syphilis oral ulcer. *Otolaryngol Head Neck Surg.* 2009;140:942-943.
- Primary and Secondary Syphilis—United States, 2003-2004. <http://www.cdc.gov/mmwr/preview/mmwrhtml/mm5510a1.htm>. 2006.
- Shumway BS, Islam NM, Kapoor R, et al. Clinico-pathologic conference: case 3. *Head Neck Pathol.* 2009;3:286-289.





**FIGURE 4-38.** **A,** Primary syphilitic chancres of the tongue in an HIV-positive patient. **B,** Secondary syphilitic lesion of the palate. (**A,** Courtesy of Dr. Brian Shumway, University of Louisville School of Dentistry, Louisville, K; **B,** Courtesy of Dr. Roman Carlos, Guatemala City, Guatemala.)



**FIGURE 4-39.** Secondary syphilis. **A,** Ulceration and dense chronic inflammatory infiltrate at the interface and around blood vessels. **B,** Marked acute and chronic inflammation within the epithelium and plasma cells in lamina propria. **C,** Plasma cell infiltrate within fat and around vessels. **D,** Perivascular and perineural lymphoplasmacytic infiltrate. **E,** Corkscrew threadlike spirochetes (modified Steiner stain).



# 5

# FIBROUS, GINGIVAL, LIPOCYTIC, AND MISCELLANEOUS TUMORS

## CHAPTER CONTENTS

### FIBROUS LESIONS 63

Fibroma (“Bite” or “Irritation” Fibroma, Fibroepithelial or Fibrovascular Polyp) and Giant Cell Fibroma 63

### GINGIVAL MASSES 68

Reactive/Inflammatory Gingival Nodules 68

Diffuse/Multifocal Gingival Hyperplasia 76

### GINGIVAL CYST OF THE ADULT 79

### PERIPHERAL (EXTRAOSSEOUS) ODONTOGENIC NEOPLASMS 82

Peripheral Odontogenic Fibroma 82

Peripheral Ameloblastoma 84

Peripheral Calcifying Cystic Odontogenic Tumor 86

### METASTASES TO THE GINGIVA 87

DENTURE-ASSOCIATED INFLAMMATORY FIBROUS HYPERPLASIA (EPULIS FISSURATUM) 88

### LIPOCYTIC LESIONS 90

Lipoma 90

### OTHER UNCOMMON TUMORS 94

Myofibroma 94

### TUMORS OF UNCERTAIN HISTOGENESIS 97

Ectomesenchymal Chondromyxoid Tumor of the Tongue 97

Solitary Fibrous Tumor 100

Oral Focal Mucinosis 103

## Fibrous Lesions

### FIBROMA (“BITE” OR “IRRITATION” FIBROMA, FIBROEPITHELIAL OR FIBROVASCULAR POLYP) AND GIANT CELL FIBROMA

#### Clinical Findings

- Dome-shaped nodule or papule; may be white/keratotic, mucosa-colored or ulcerated and is seen in areas readily traumatized by biting (i.e., buccal mucosa, lateral tongue, and lower labial mucosa) or on gingiva (where plaque accumulates) (Fig. 5-1, A-D).
- Variant giant cell fibroma has a papillary surface and is usually located on gingiva or tongue (see Fig. 5-1, E).
- Sclerotic fibromas may be seen as focal sporadic lesions or in patients with tuberous sclerosis, associated with loss of heterozygosity of the PTEN gene.

#### Etiopathogenesis and Histopathologic Features

Fibroma is a reactive fibrosis and scarring (similar to a hypertrophic scar on the skin) from bite trauma and is not a true neoplasm.

- Nodular proliferation of fibrous tissue is associated with variable vascularity, hyperparakeratosis or orthokeratosis, ulceration, inflammation, epithelial hyperplasia, or atrophy (Figs. 5-2 and 5-3); variable myxoid/mucinous change (Fig. 5-4); or entrapment of muscle (Fig. 5-5).
- Sclerotic fibroma (also called storiform collagenoma) has dense, hyalinized bands of keloidal collagen with a slight storiform pattern and stellate and fusiform fibroblasts with clefts between collagen fibers; lesions are occasionally positive for factor XIIIa and CD34 (Fig. 5-6).
- Giant cell fibroma exhibits papillary surface, epithelial hyperplasia forming spiky rete ridges; giant,

stellate, multinucleated fibroblast-like cells that sometimes show cytoplasmic positivity for smooth muscle actin suggesting differentiation toward myofibroblasts; and keloid-like dense collagen. Mast cells are often present (Figs. 5-7 and 5-8) similar to fibrous papule of the nose.

- Fibromas of the anterior hard palate often contain cartilage and branches of the nasopalatine neurovascular bundle (Fig. 5-9).

#### Differential Diagnosis

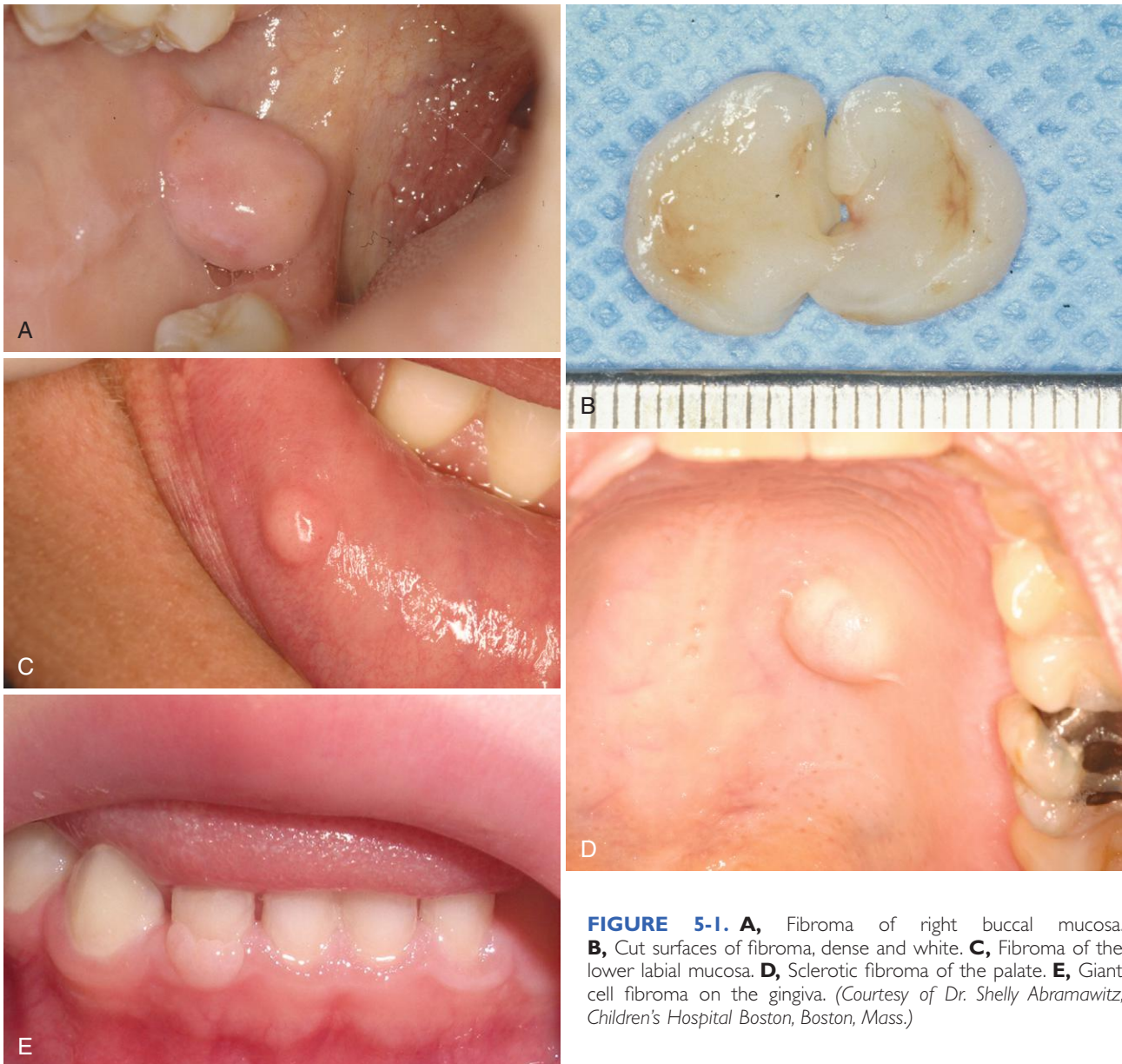- These may be indistinguishable from end-stage mucocele on lower lip or end-stage pyogenic granuloma.
- Sclerotic solitary fibrous tumors are positive for CD34 and may be difficult to differentiate from sclerotic fibroma if areas of more classic vascular proliferation are not present.

#### Management and Prognosis

- Excision is curative, although continued irritation and trauma may lead to recurrence.

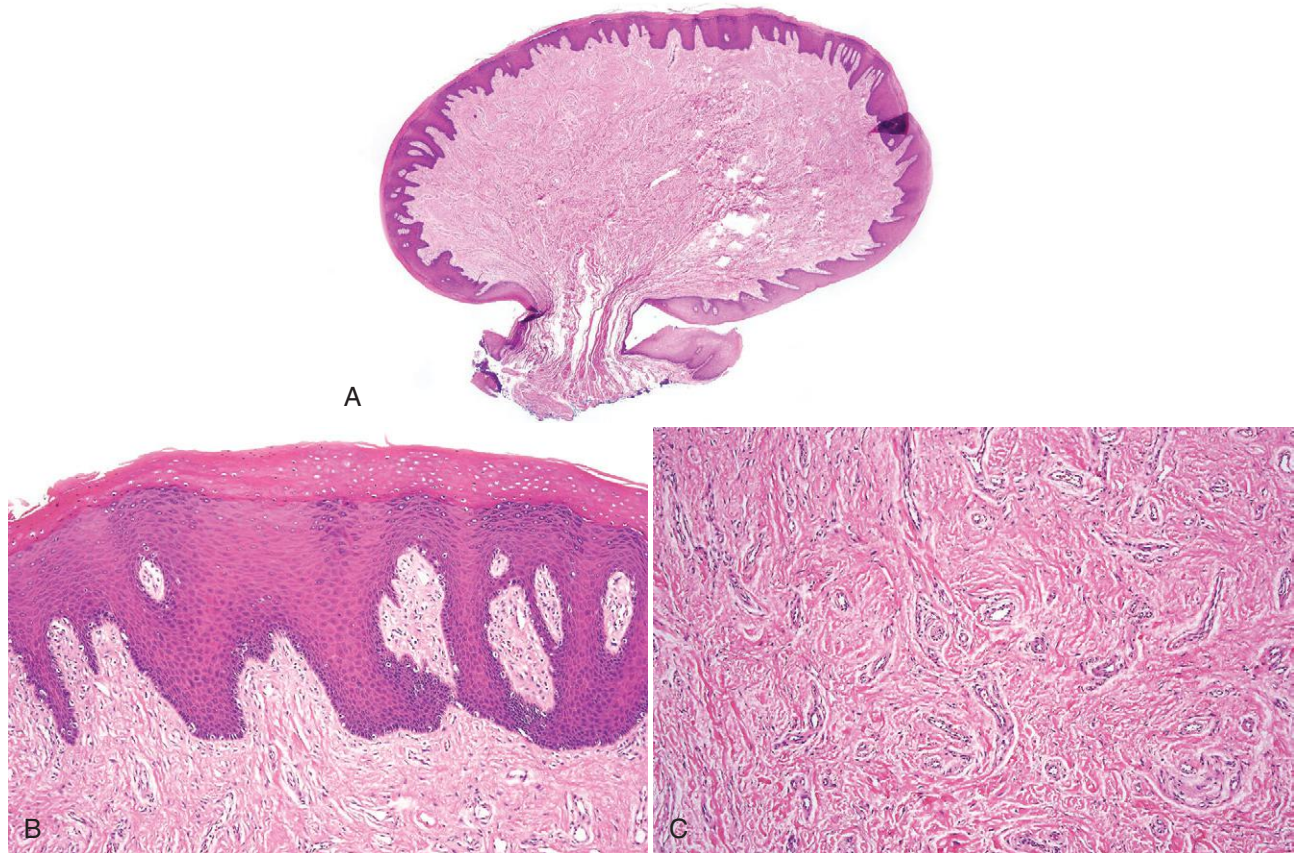
#### REFERENCES

- Alawi F, Freedman PD. Sporadic sclerotic fibroma of the oral soft tissues. *Am J Dermatopathol.* 2004;26:182-187.
- Fernandez-Flores A. Solitary oral fibromas of the tongue show similar morphologic features to fibrous papule of the face: a study of 31 cases. *Am J Dermatopathol.* 2010;32:442-447.
- Houston GD. The giant cell fibroma: a review of 464 cases. *Oral Surg Oral Med Oral Pathol.* 1982;53:582-587.
- Magnusson BC, Rasmusson LG. The giant cell fibroma. A review of 103 cases with immunohistochemical findings. *Acta Odontol Scand.* 1995;53:293-296.
- Metcalf JS, Maize JC, LeBoit PE. Circumscribed storiform collagenoma (sclerosing fibroma). *Am J Dermatopathol.* 1991;13:122-129.
- Rapini RP, Golitz LE. Sclerotic fibromas of the skin. *J Am Acad Dermatol.* 1989;20:266-271.

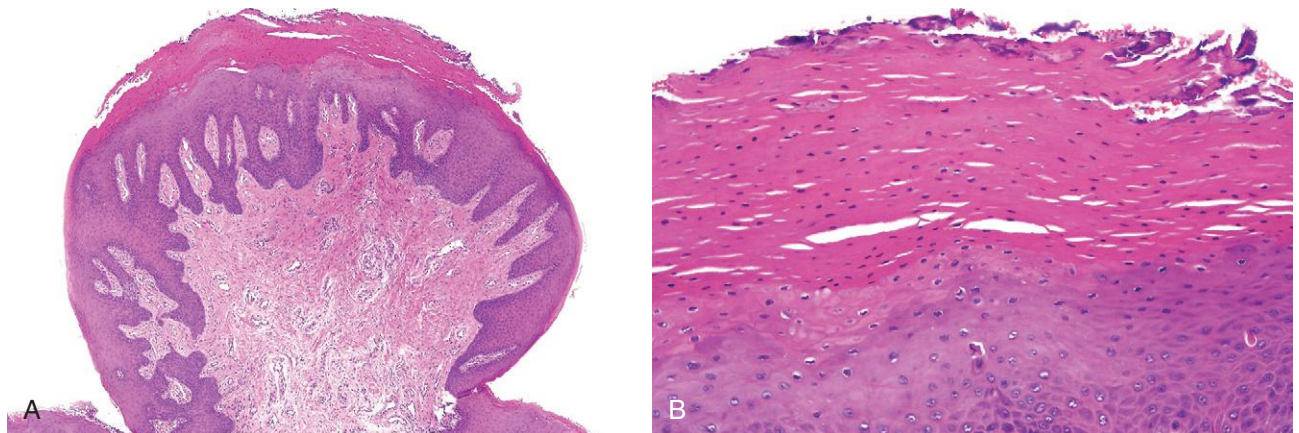


**FIGURE 5-1.** **A,** Fibroma of right buccal mucosa. **B,** Cut surfaces of fibroma, dense and white. **C,** Fibroma of the lower labial mucosa. **D,** Sclerotic fibroma of the palate. **E,** Giant cell fibroma on the gingiva. (Courtesy of Dr. Shelly Abramowitz, Children's Hospital Boston, Boston, Mass.)



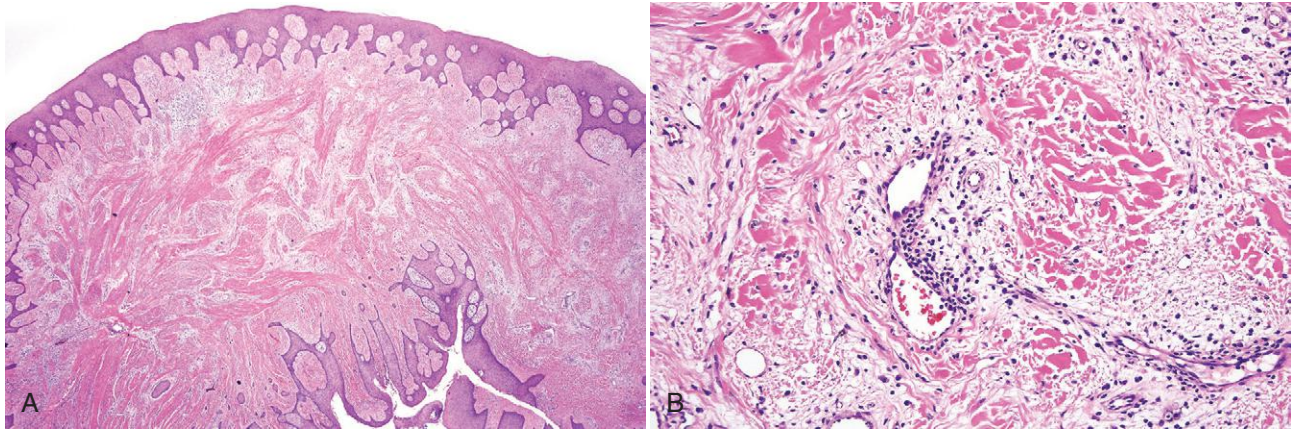


**FIGURE 5-2.** **A**, Fibroma with frictional keratosis. **B**, Hyperorthokeratosis with wedge-shaped granulosi typical for lichen simplex chronicus. **C**, Dense collagen with scattered blood vessels.

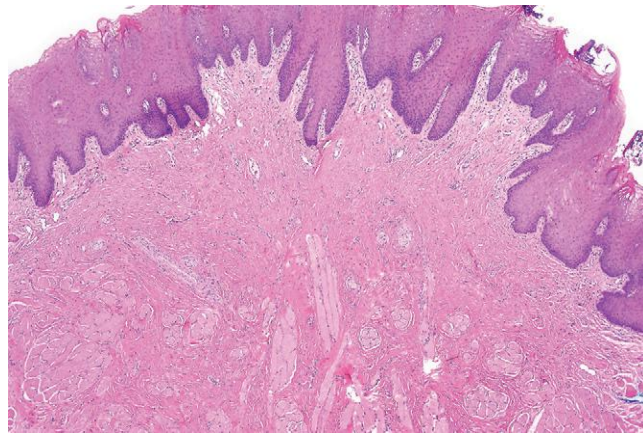


**FIGURE 5-3.** **A**, Fibroma with frictional keratosis. **B**, Hyperparakeratosis and bacterial colonies typical for frictional/factitial keratosis.

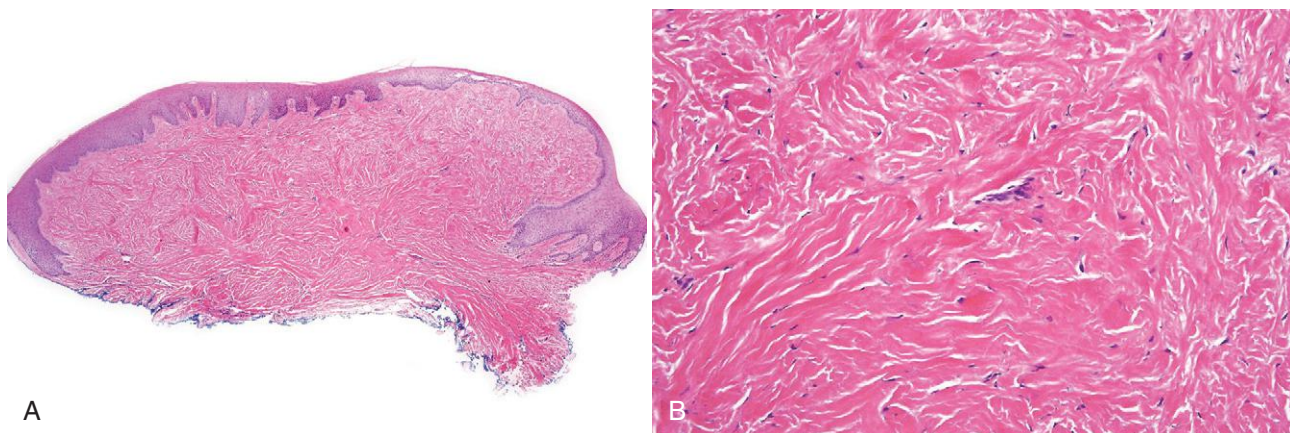




**FIGURE 5-4.** **A,** Fibroma with focal myxoid/mucinous change. **B,** Areas of dense collagen interspersed with myxoid/mucinous areas and mild chronic inflammation.

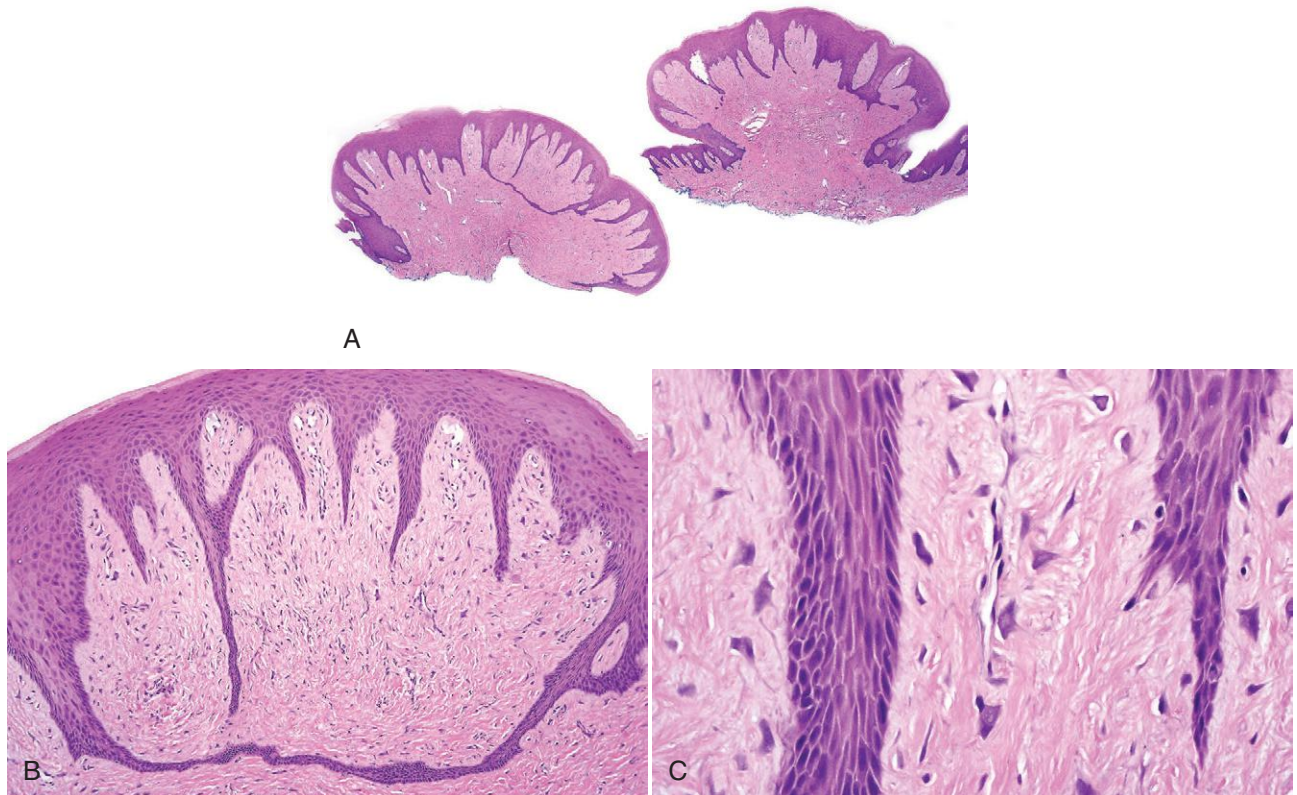


**FIGURE 5-5.** Tongue fibroma/scar with entrapment of muscle.

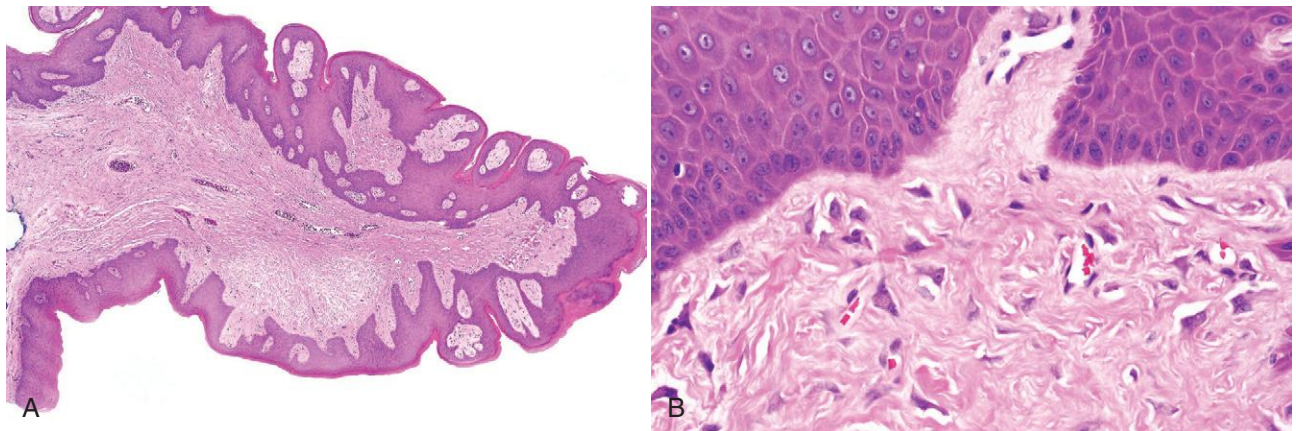


**FIGURE 5-6.** Sclerotic fibroma. **A,** Dense, hyalinized collagen and epithelial collarette. **B,** Stellate and fusiform fibroblasts in keloid-like collagen.

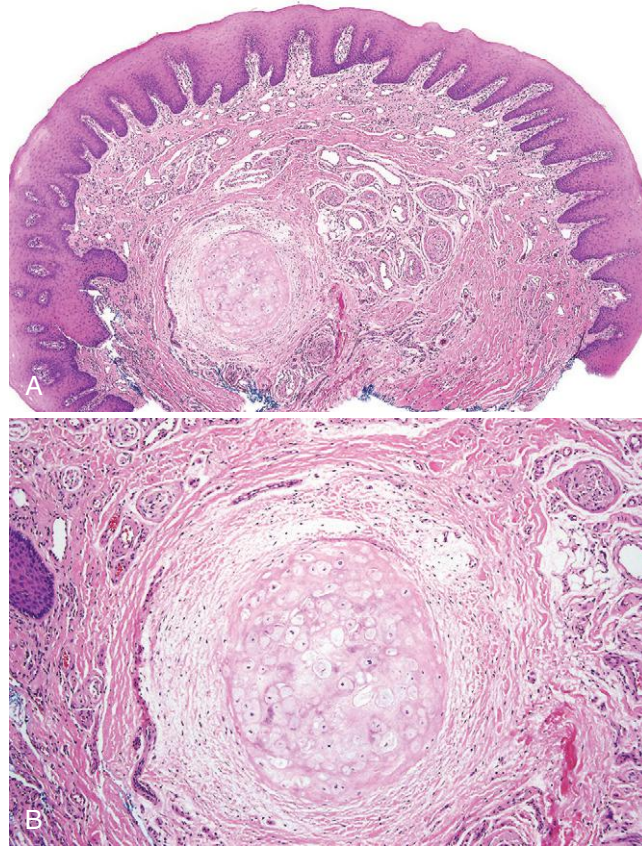




**FIGURE 5-7.** Giant cell fibroma. **A**, Fibrous nodules with undulating, bosselated surface. **B**, Epithelial hyperplasia forming spiky rete ridges. **C**, Stellate and multinucleated fibroblast-like cells.



**FIGURE 5-8.** Giant cell fibroma. **A**, Fibrous nodule with papillary surface. **B**, Giant and binucleate fibroblast-like cells and dense collagen.



**FIGURE 5-9.** Fibroma of anterior palate. **A**, Nodule containing hyaline cartilage and neurovascular bundles. **B**, Mature hyaline cartilage.

## Gingival Masses

Classification is as follows:

- Reactive/inflammatory gingival nodules, solitary or diffuse
- Peripheral (extraosseous) odontogenic cysts and tumors
- Soft tissue tumors (such as nerve sheath or smooth muscle tumors, discussed in [Chapter 6](#))
- Extension of intrabony lesions into the gingiva
- Metastatic tumors to the gingiva

### REACTIVE/INFLAMMATORY GINGIVAL NODULES

#### Clinical Findings

- Young patients in second to fourth decades; nodular masses on the marginal gingiva, often maxillary anterior region; pink, erythematous, dusky purple, or ulcerated; may be painful and, if vascular, will bleed; underlying bone may show “saucerization” of bone (especially with giant cell granuloma) ([Fig. 5-10](#))

- Peripheral giant cell granulomas least common; tend to occur in older adults
- Parulis (“gum-boil”) occurs on the attached gingiva; has a punctum and underlying tract that leads to the infected tooth (see later)
- Up to 5% of pregnancies associated with gingival pyogenic granulomas (granuloma gravidarum)

#### Etiopathogenesis and Histopathologic Features

Pluripotent cells in the gingival tissues when traumatized or irritated (usually by accumulation of dental calculus or bacterial plaque, rough edges of restorations, or presence of implants) differentiate toward endothelial cells, fibroblasts, osteoblasts, or osteoclast-like cells, giving rise to four distinct histologic entities or combinations thereof. Estrogen and progesterone causes overexpression of vascular endothelial growth factor in granuloma gravidarum. See [Table 5-1](#) and [Figures 5-11 to 5-19](#) for histopathologic features.



**TABLE 5-1** Reactive Gingival Nodules

Diagnosis	Histopathology
Fibroma (fibrovascular hyperplasia/polyp)	<ul style="list-style-type: none"> <li>Nodule of fibrous tissue with scattered vessels and variable edema and inflammation; crevicular epithelium with underlying plasma cells often seen (see Figs. 5-11 and 5-12)</li> </ul>
Giant cell fibroma	<ul style="list-style-type: none"> <li>In giant cell fibroma, stellate and multinucleated fibroblast-like cells are present (see Fibroma section)</li> </ul>
Pyogenic granuloma	<ul style="list-style-type: none"> <li>Lobular or nonlobular proliferation of endothelial cells and small, dilated capillaries; often ulcerated and inflamed (see Fig. 5-13, A)</li> <li>Endothelial cells show reactive atypia—focal “hobnail” pattern, enlarged nuclei with prominent nucleoli, some mitotic activity (see Fig. 5-13, B and C)</li> <li>May see fibrosis depending on stage of organization (see Fig. 5-14)</li> </ul>
Peripheral ossifying fibroma (fibroma with osseous prosoplasia)	<ul style="list-style-type: none"> <li>Cellular proliferation of spindled fibroblast-like cells with ovoid nuclei that have dispersed chromatin, inconspicuous nucleoli; sometimes only subtle osteoid deposits or focal calcifications are present (see Fig. 5-15, A and B)</li> <li>Osteoid, woven bone, or cementum droplets laid down by spindle cells although osteoblastic rimming sometimes seen (see Figs. 5-15, C and D, and 5-16)</li> <li>May see clusters of multinucleated giant cells similar to peripheral giant cell granuloma (see Fig. 5-17)</li> <li>Bone morphogenetic protein identified in the spindled fibroblast-like cells</li> </ul>
Peripheral giant cell granuloma	<ul style="list-style-type: none"> <li>Proliferation of mononuclear and multinucleated giant cells (osteoclast-like or foreign body type) usually in sheets; giant cells contain 10-20 nuclei in a central location; mitoses may be seen in mononuclear cells; fresh hemorrhage and hemosiderin deposits, especially beneath the grenz zone (see Figs. 5-18, 5-19)</li> <li>May see concomitant osseous prosoplasia similar to peripheral ossifying fibroma</li> </ul>

- Parulis consists of a mass of edematous granulation tissue with many acute and chronic inflammatory cells and tracts lined by neutrophils (Figs. 5-20 to 5-22); they are often mistaken for mucoceles (which do not occur on the attached gingiva).

### Differential Diagnosis

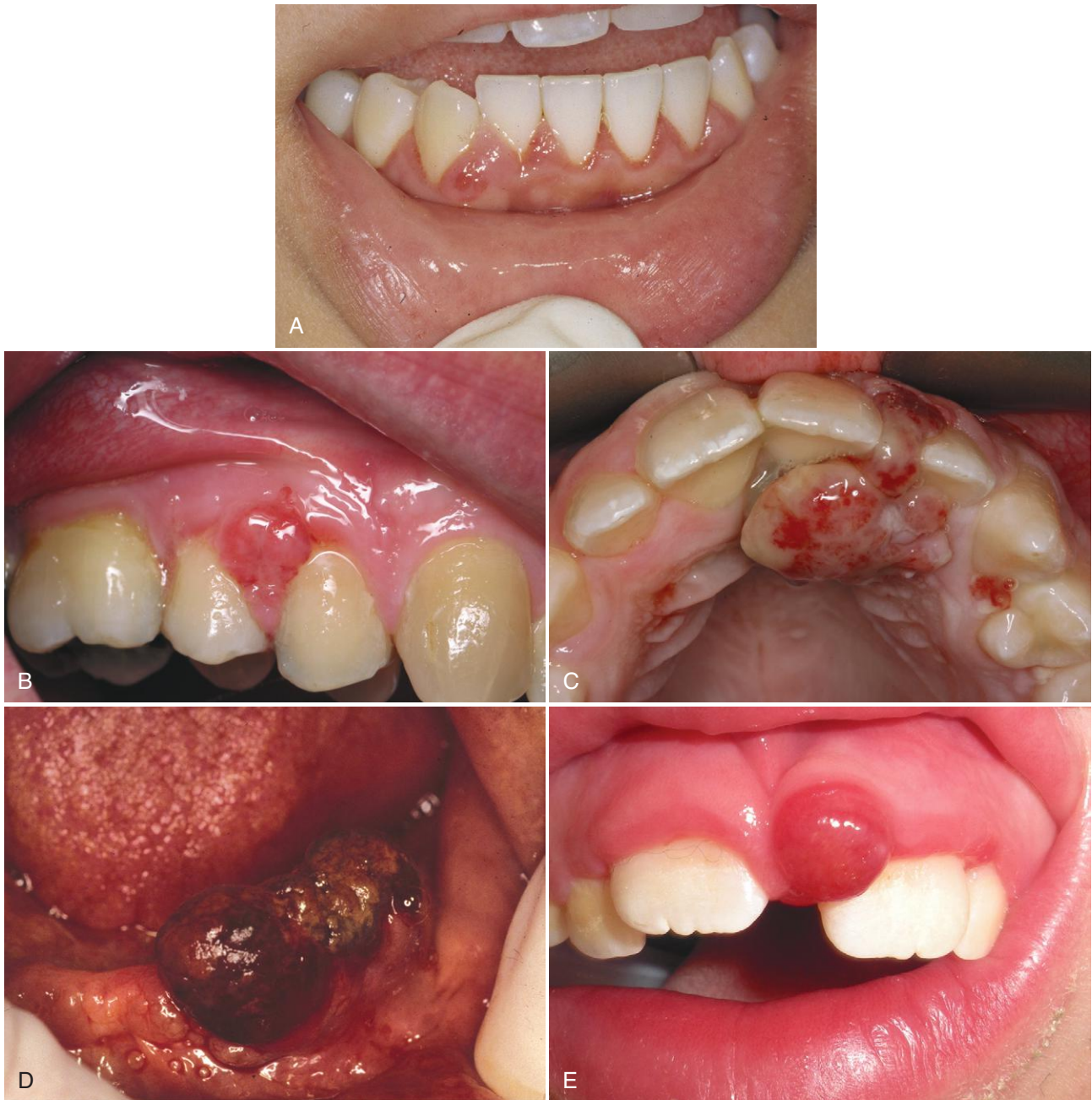- True infantile hemangiomas show a lobular proliferation of endothelial cells and capillaries that are positive for glucose transporter-1 (GLUT-1) (Fig. 5-23)
- Peripheral odontogenic fibroma produces dentinoid rather than cementum or osteoid and epithelial islands are always present, distinguishing this from peripheral ossifying fibroma (see later).
- Aggressive central (intraosseous) giant cell granulomas may erode through bone; radiographs differentiate them from peripheral (extraosseous) lesions.

### Management and Prognosis

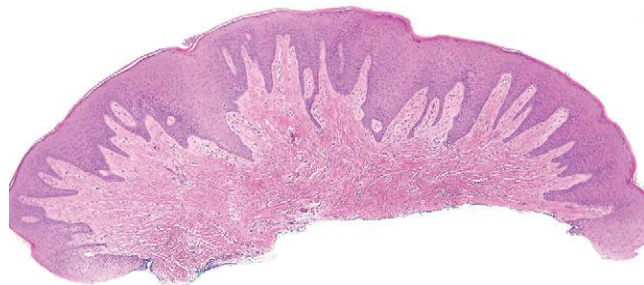
- Excision is treatment of choice, although if underlying irritating factors such as dental plaque are not removed, the recurrence rate is up to 15%.
- Granuloma gravidarum may resolve postpartum but may also sclerose and become a gingival fibroma.

### REFERENCES

- Buchner A, Hansen LS. The histomorphologic spectrum of peripheral ossifying fibroma. *Oral Surg Oral Med Oral Pathol.* 1987;63:452-461.
- Buchner A, Shnaiderman-Shapiro A, Vered M. Relative frequency of localized reactive hyperplastic lesions of the gingiva: a retrospective study of 1675 cases from Israel. *J Oral Pathol Med.* 2010;39:631-638.
- Carvalho YR, Loyola AM, Gomez RS, Araujo VC. Peripheral giant cell granuloma. An immunohistochemical and ultrastructural study. *Oral Dis.* 1995;1:20-25.
- Epivatianos A, Antoniadis D, Zaraboukas T, et al. Pyogenic granuloma of the oral cavity: comparative study of its clinicopathological and immunohistochemical features. *Pathol Int* 2005;55:391-397.
- Giunta JL. Gingival fibrous nodule. *Oral Surg Oral Med Oral Pathol Oral Radiol Endod.* 1999;88:451-454.
- Gordon-Nunez MA, de Vasconcelos Carvalho M, Benevenuto TG, et al. Oral pyogenic granuloma: a retrospective analysis of 293 cases in a Brazilian population. *J Oral Maxillofac Surg.* 2010;68:2185-2188.
- Hirshberg A, Kozlovsky A, Schwartz-Arad D, et al. Peripheral giant cell granuloma associated with dental implants. *J Periodontol.* 2003;74:1381-1384.
- Katsikeris N, Kakarantza-Angelopoulou E, Angelopoulos AP. Peripheral giant cell granuloma. Clinicopathologic study of 224 new cases and review of 956 reported cases. *Int. J Oral Maxillofac Surg.* 1988;17:94-99.
- Ono A, Tsukamoto G, Nagatsuka H, et al. An immunohistochemical evaluation of BMP-2, -4, osteopontin, osteocalcin and PCNA between ossifying fibromas of the jaws and peripheral cemento-ossifying fibromas on the gingiva. *Oral Oncol.* 2007;43:339-344.
- Yuan K, Wing LY, Lin MT. Pathogenetic roles of angiogenic factors in pyogenic granulomas in pregnancy are modulated by female sex hormones. *J Periodontol.* 2002;73:701-708.

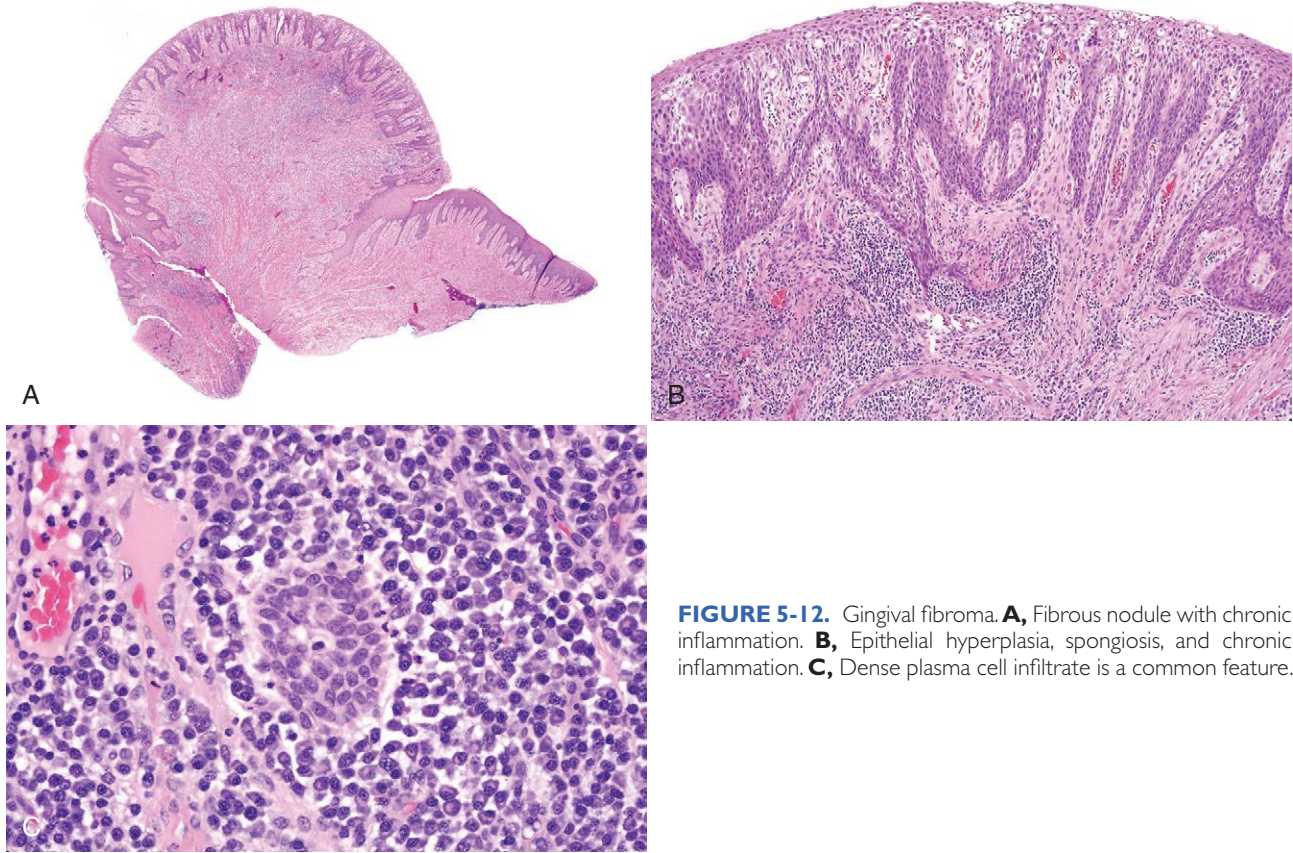


**FIGURE 5-10.** **A,** Gingival fibroma with ulceration. **B,** Peripheral ossifying fibroma. **C,** Pyogenic granuloma with ulceration. **D,** Pyogenic granuloma of the mandibular ridge at extraction sites. **E,** Peripheral giant cell granuloma. (**B,** Courtesy of Dr. Ian Cole, private practice, North Andover, Mass.; **C,** Courtesy of Dr. Jeffrey Freedman, private practice, Lexington, Mass.; **E,** Courtesy of Dr. Shelly Abramowitz, Children's Hospital Boston, Boston, Mass.)

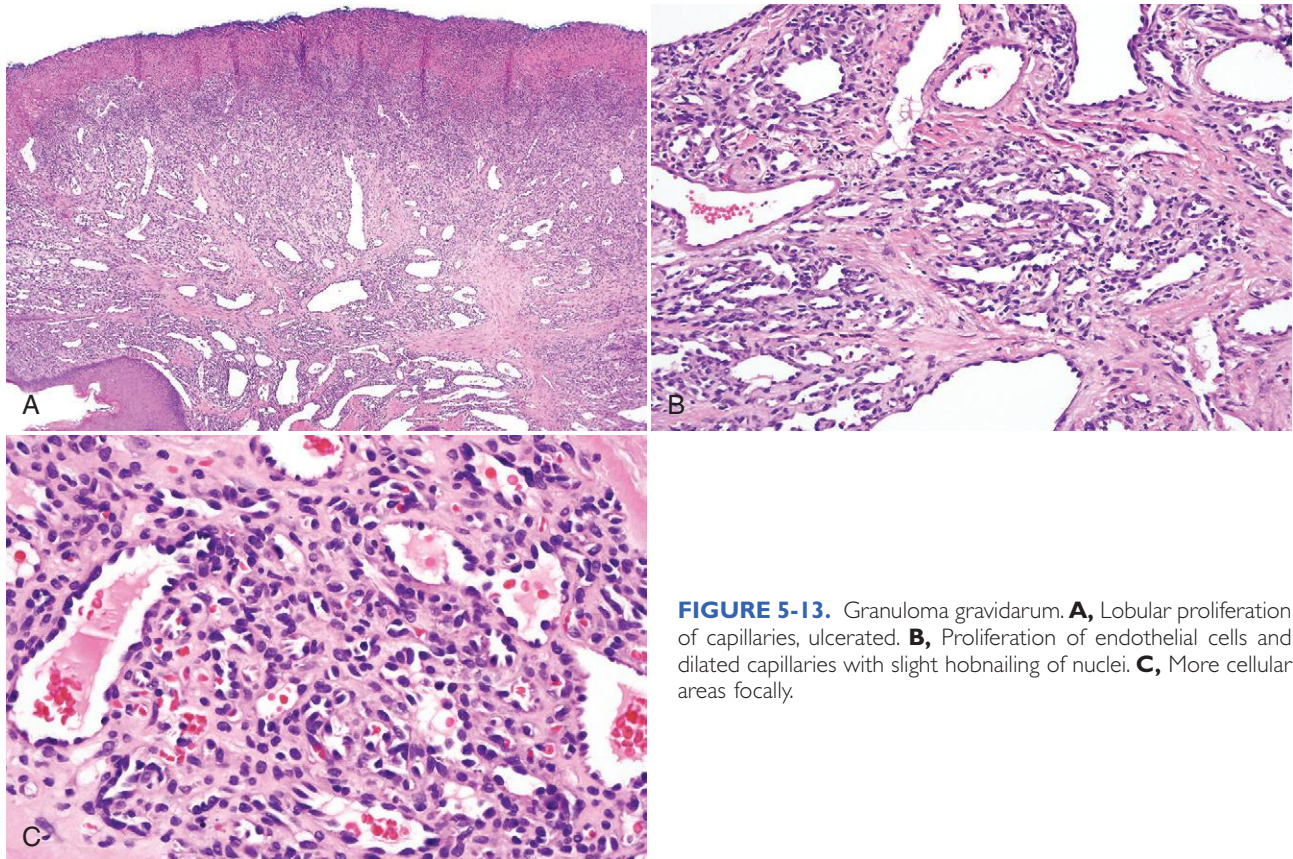


**FIGURE 5-11.** Gingival fibroma with minimal inflammation.



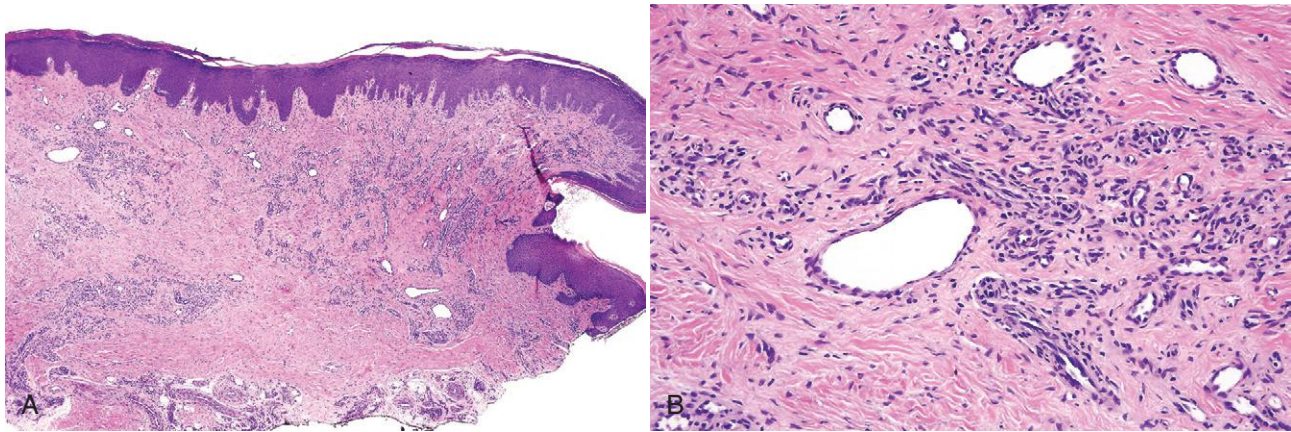


**FIGURE 5-12.** Gingival fibroma. **A**, Fibrous nodule with chronic inflammation. **B**, Epithelial hyperplasia, spongiosis, and chronic inflammation. **C**, Dense plasma cell infiltrate is a common feature.

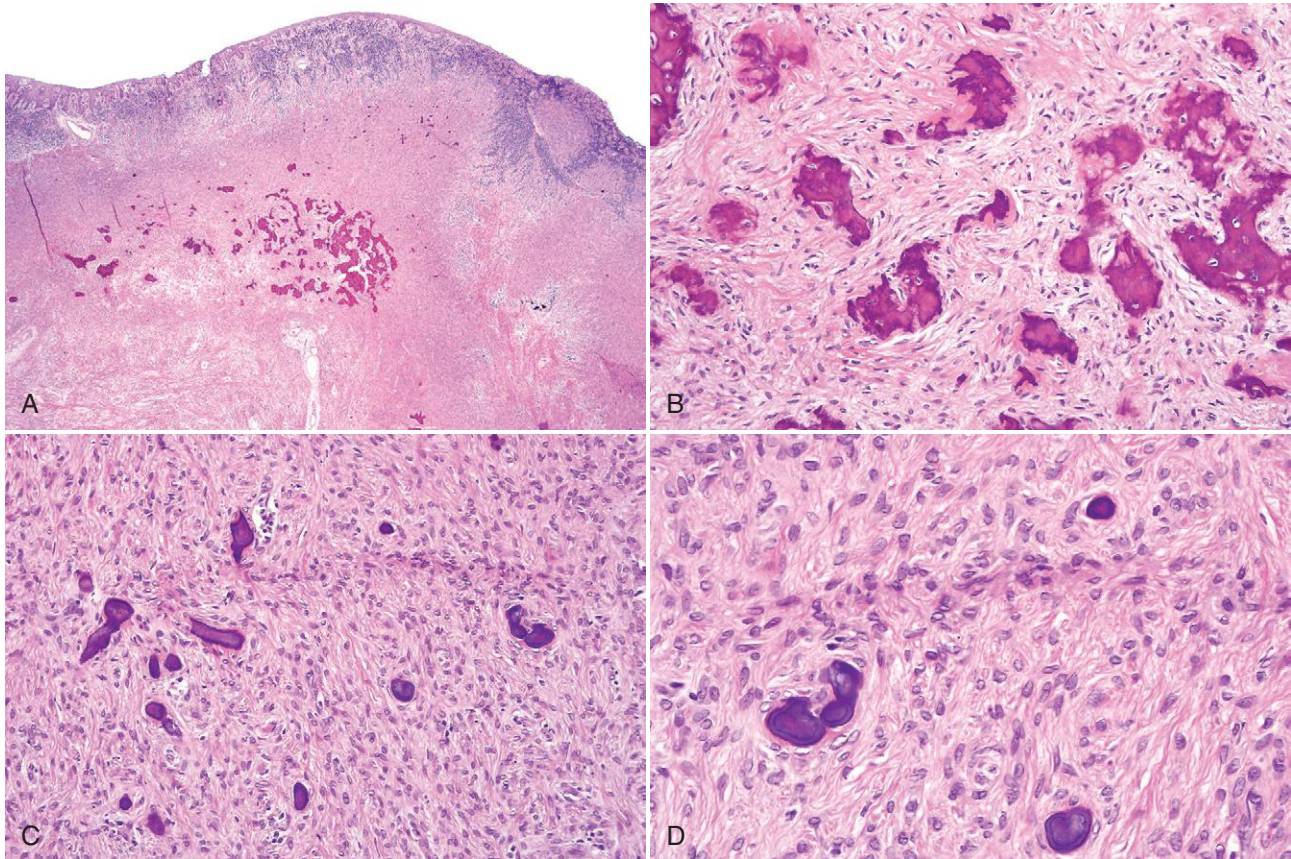


**FIGURE 5-13.** Granuloma gravidarum. **A**, Lobular proliferation of capillaries, ulcerated. **B**, Proliferation of endothelial cells and dilated capillaries with slight hobnailing of nuclei. **C**, More cellular areas focally.



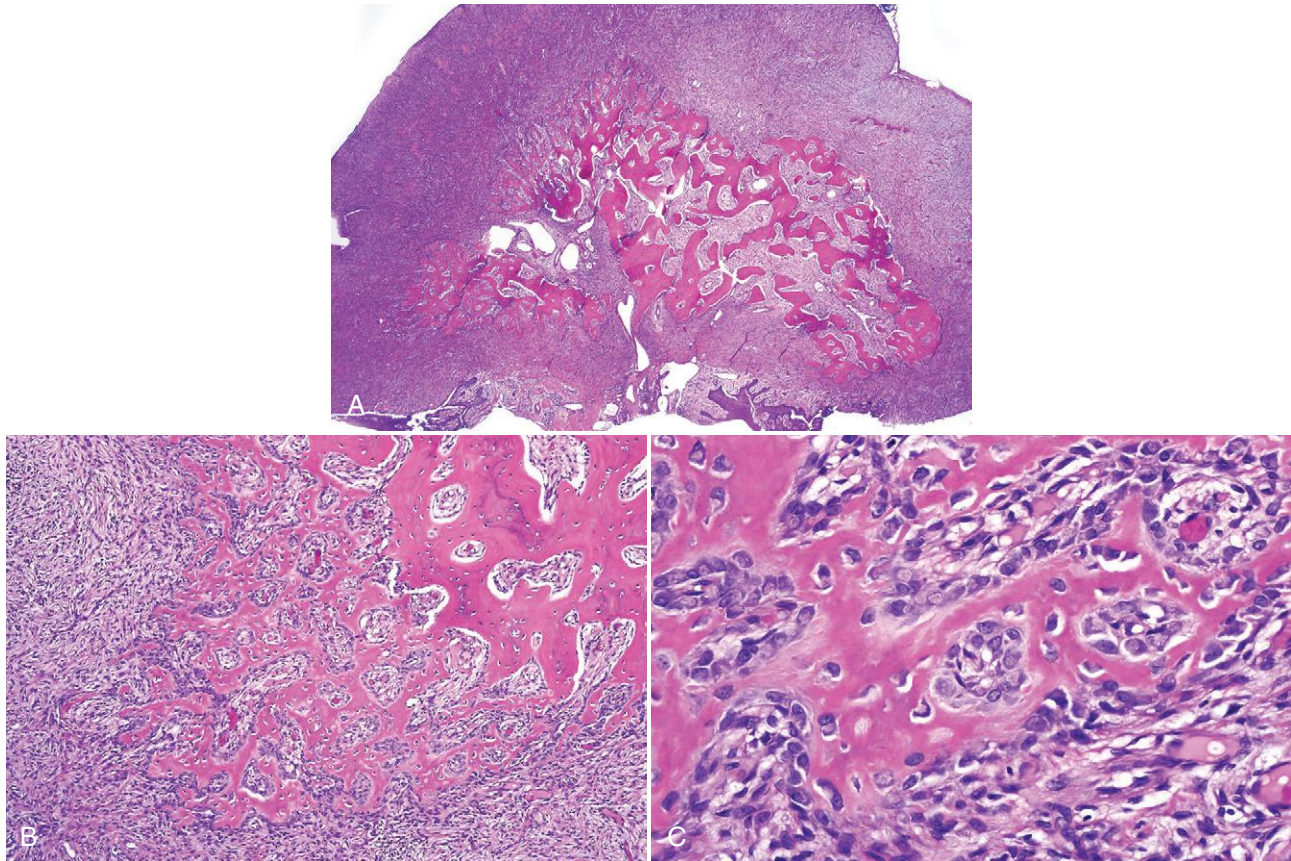


**FIGURE 5-14.** Pyogenic granuloma, sclerosing. **A**, Vague lobular pattern with intervening fibrous tissue. **B**, Fibrous tissue insinuates between and replaces endothelial cells and vessels.

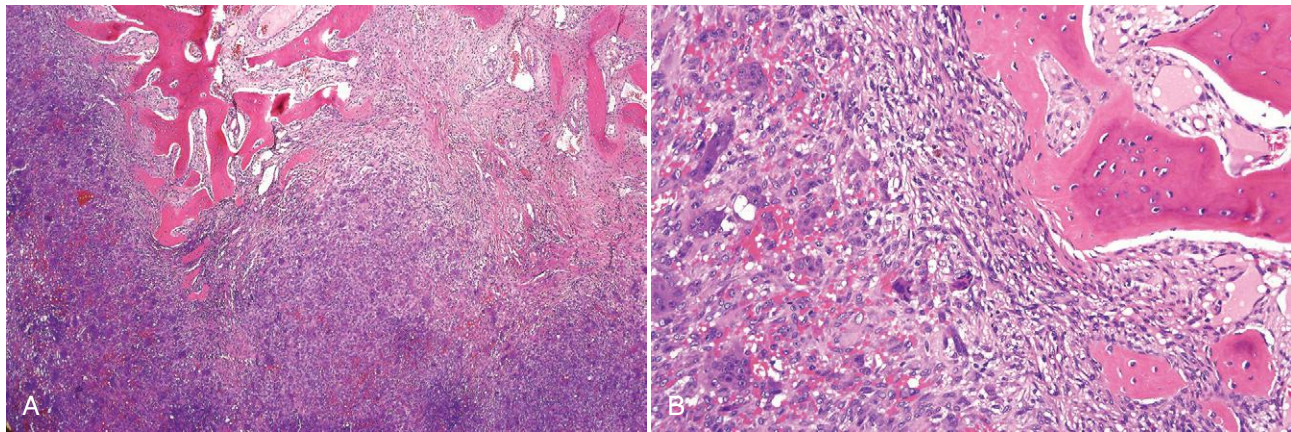


**FIGURE 5-15.** Peripheral ossifying fibroma. **A**, Mass of cellular fibrous tissue with superficial cementum deposition and bone deeper in the tissue. **B**, Cellular proliferation of fibroblast-like spindle cells with deposition of woven bone with osteoid rim. **C**, Deposition of cementum droplets. **D**, Cementum droplets with eosinophilic rim.



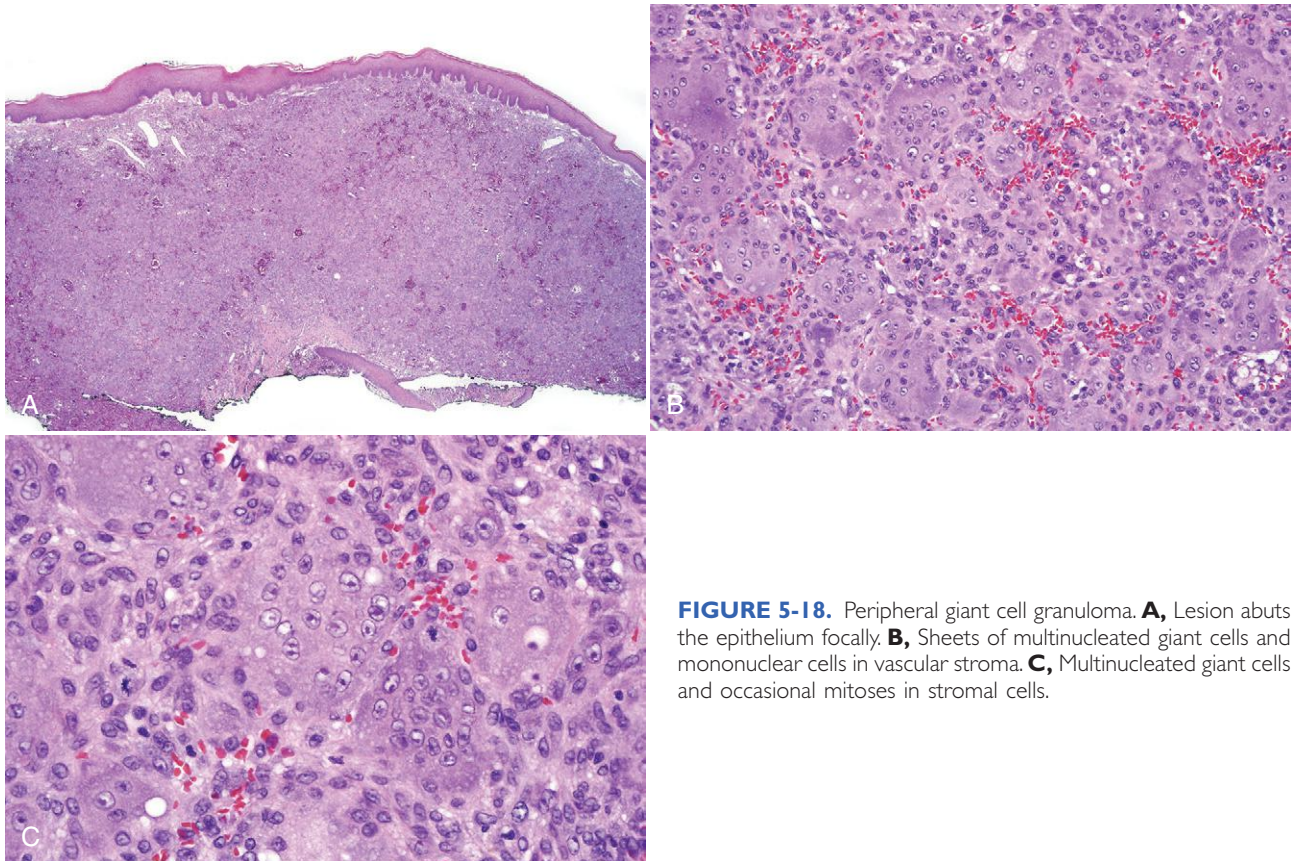


**FIGURE 5-16.** Peripheral ossifying fibroma. **A,** Nodule of fibrous tissue with abundant bone. **B,** Cellular proliferation of spindle cells forming osteoid and woven bone. **C,** Osteoid rimmed by layers of osteoblasts.

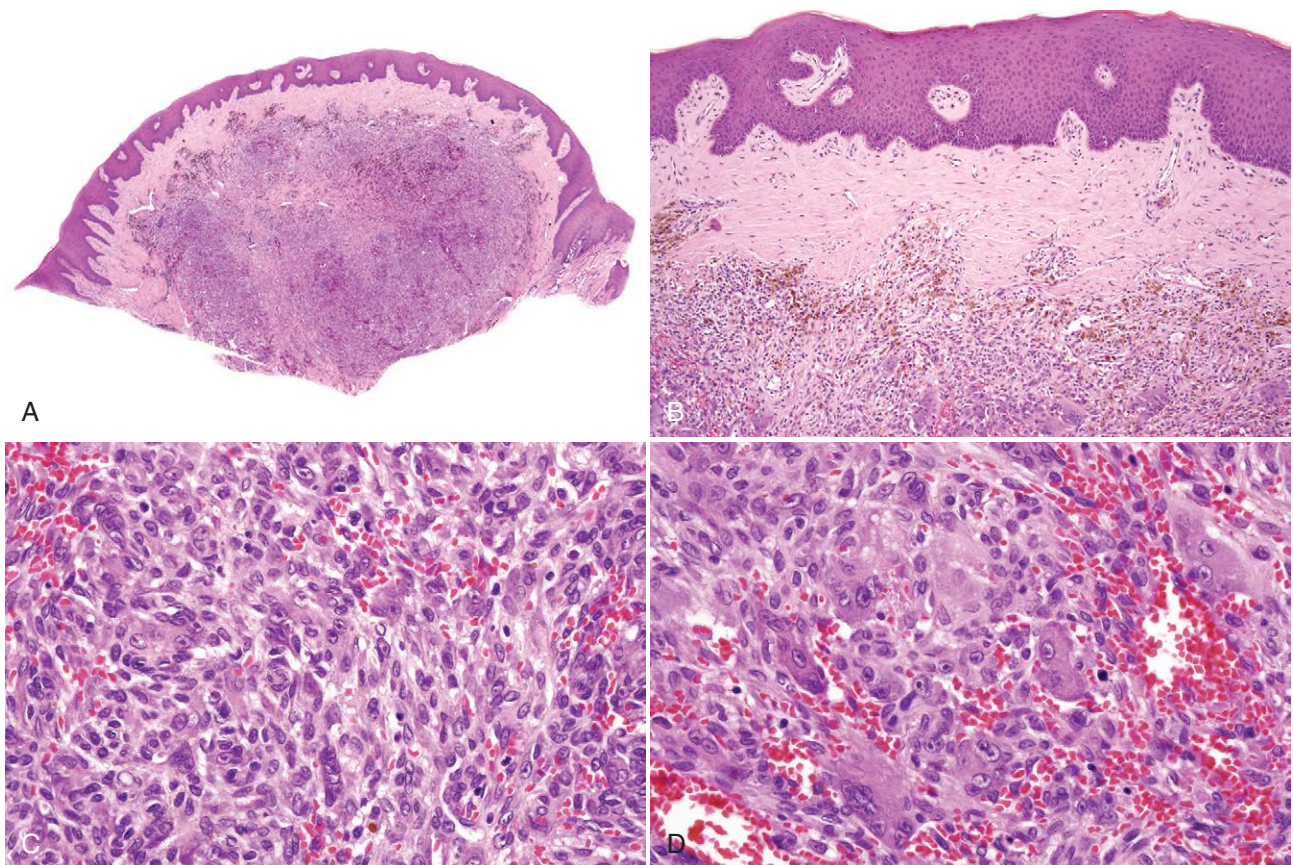


**FIGURE 5-17.** Peripheral ossifying fibroma and peripheral giant cell granuloma. **A,** Sheets of giant cells and woven bone. **B,** Woven bone formation and clusters of osteoclast-like giant cells.



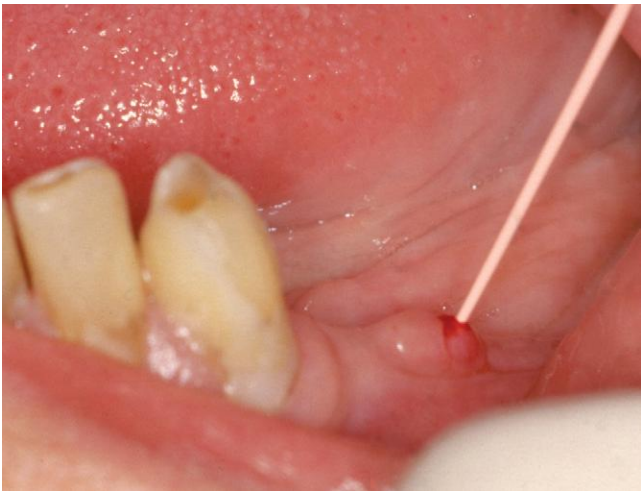

**FIGURE 5-18.** Peripheral giant cell granuloma. **A**, Lesion abuts the epithelium focally. **B**, Sheets of multinucleated giant cells and mononuclear cells in vascular stroma. **C**, Multinucleated giant cells and occasional mitoses in stromal cells.

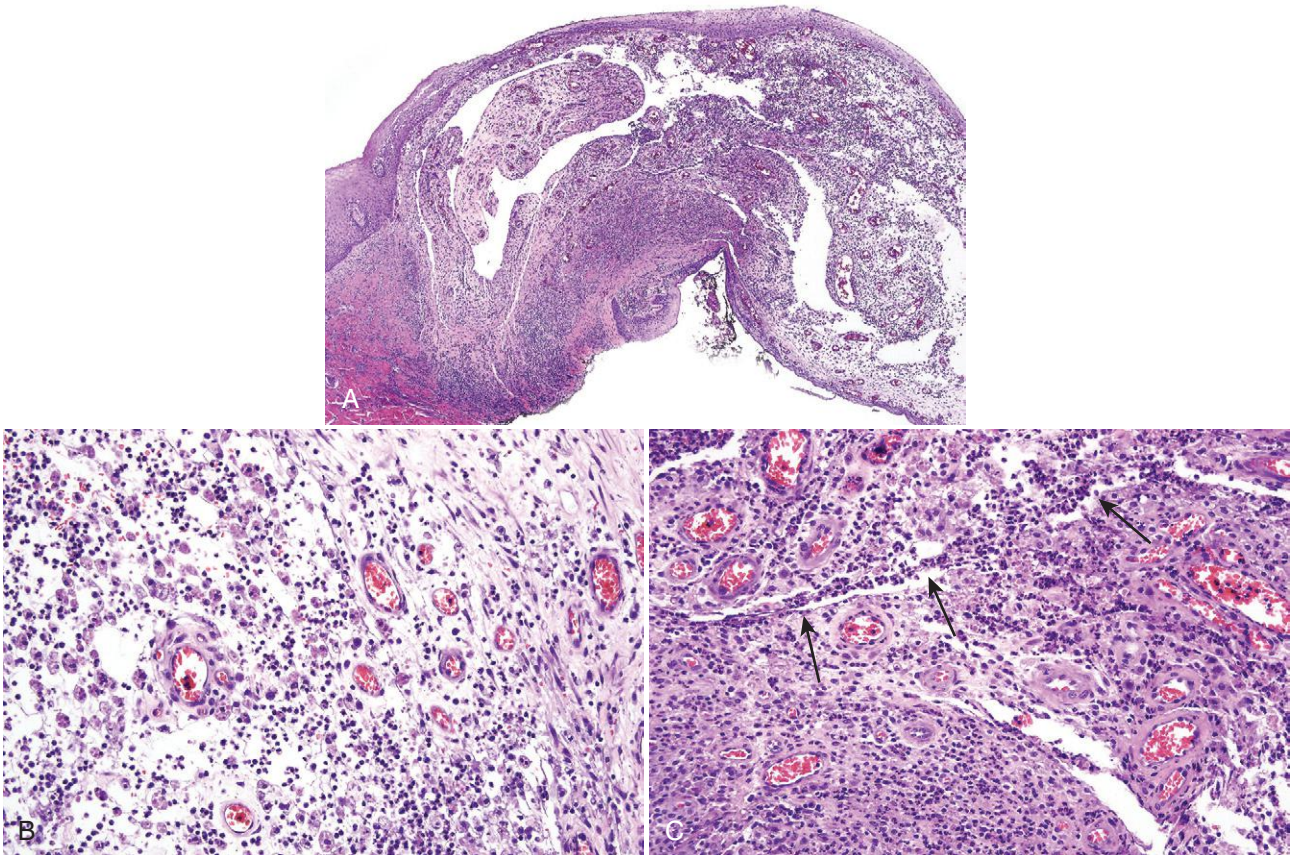


**FIGURE 5-19.** Peripheral giant cell granuloma. **A**, Grenz zone present. **B**, Hemociderin just beneath the Grenz zone. **C**, Mixture of multinucleated giant cells and spindled mononuclear cells with hemorrhage. **D**, Multinucleated giant cells and spindled mononuclear cells.



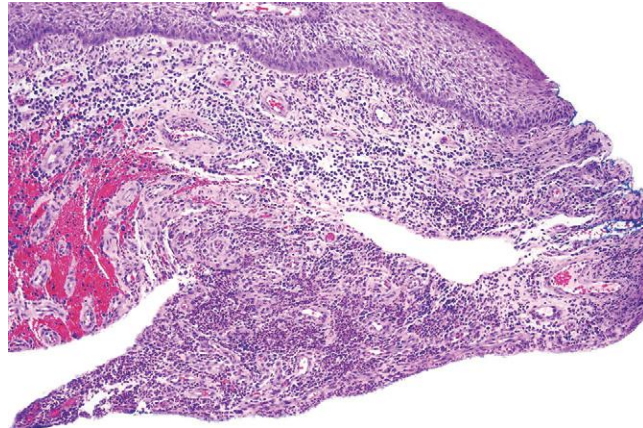


**FIGURE 5-20.** Parulis of the gingiva with gutta percha tracer.

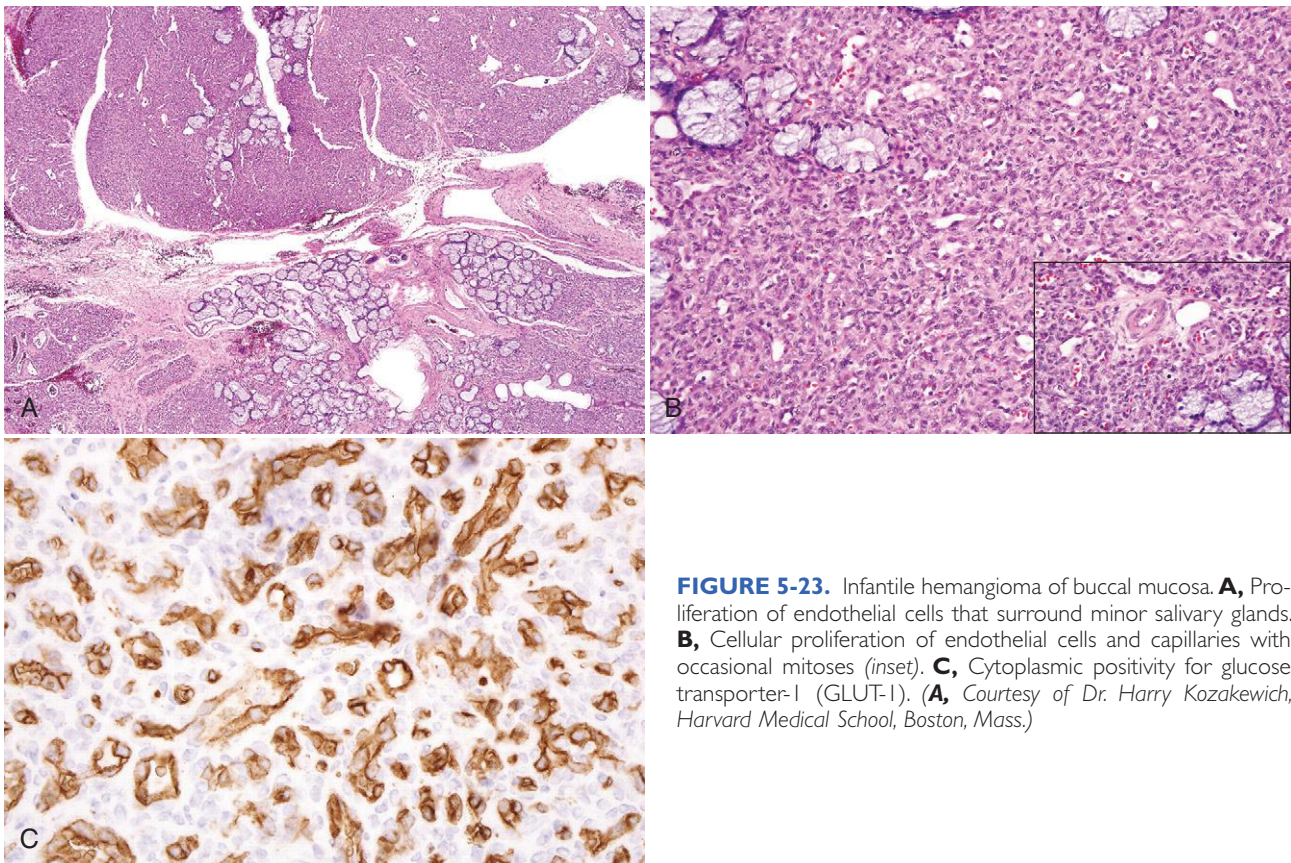


**FIGURE 5-21.** Parulis. **A**, Edematous granulation tissue with linear spaces/tracts. **B**, Edematous granulation tissue with foamy macrophages and acute and chronic inflammation, often misdiagnosed as mucocele. **C**, Tract filled with neutrophils (arrows).





**FIGURE 5-22.** Parulis with linear tracts that communicate with the mucosal surface.



**FIGURE 5-23.** Infantile hemangioma of buccal mucosa. **A**, Proliferation of endothelial cells that surround minor salivary glands. **B**, Cellular proliferation of endothelial cells and capillaries with occasional mitoses (*inset*). **C**, Cytoplasmic positivity for glucose transporter-1 (GLUT-1). (**A**, Courtesy of Dr. Harry Kozakewich, Harvard Medical School, Boston, Mass.)

## DIFFUSE/MULTIFOCAL GINGIVAL HYPERPLASIA

### Clinical Findings

- Seen in patients with poor oral hygiene and hormonal changes (e.g., puberty and pregnancy), and in patients on medications such as phenytoin, valproic acid, calcium channel blockers, and cyclosporine
- Diffuse, often slightly nodular enlargement of the gingiva of varying severity (Fig. 5-24, *A* and *B*); leukemic infiltrates may have a similar clinical appearance (see Fig. 5-24, *C*)

### Etiopathogenesis and Histopathologic Features

Bacterial plaque induces the proliferation of fibroblasts, and hormones such as progesterone exacerbate this; medications cause a reduction in metalloproteinases, leading to accumulation of matrix.

- Fibrovascular and epithelial proliferation with variable chronic inflammation usually plasmacytic; cytoid bodies sometimes are present if there is prominent spongiosis (Figs. 5-25 and 5-26).
- “Test-tube” rete ridges have been reported in patients on phenytoin and also are seen in patients with conventional non-medication-associated gingival hyperplasia.



### Differential Diagnosis

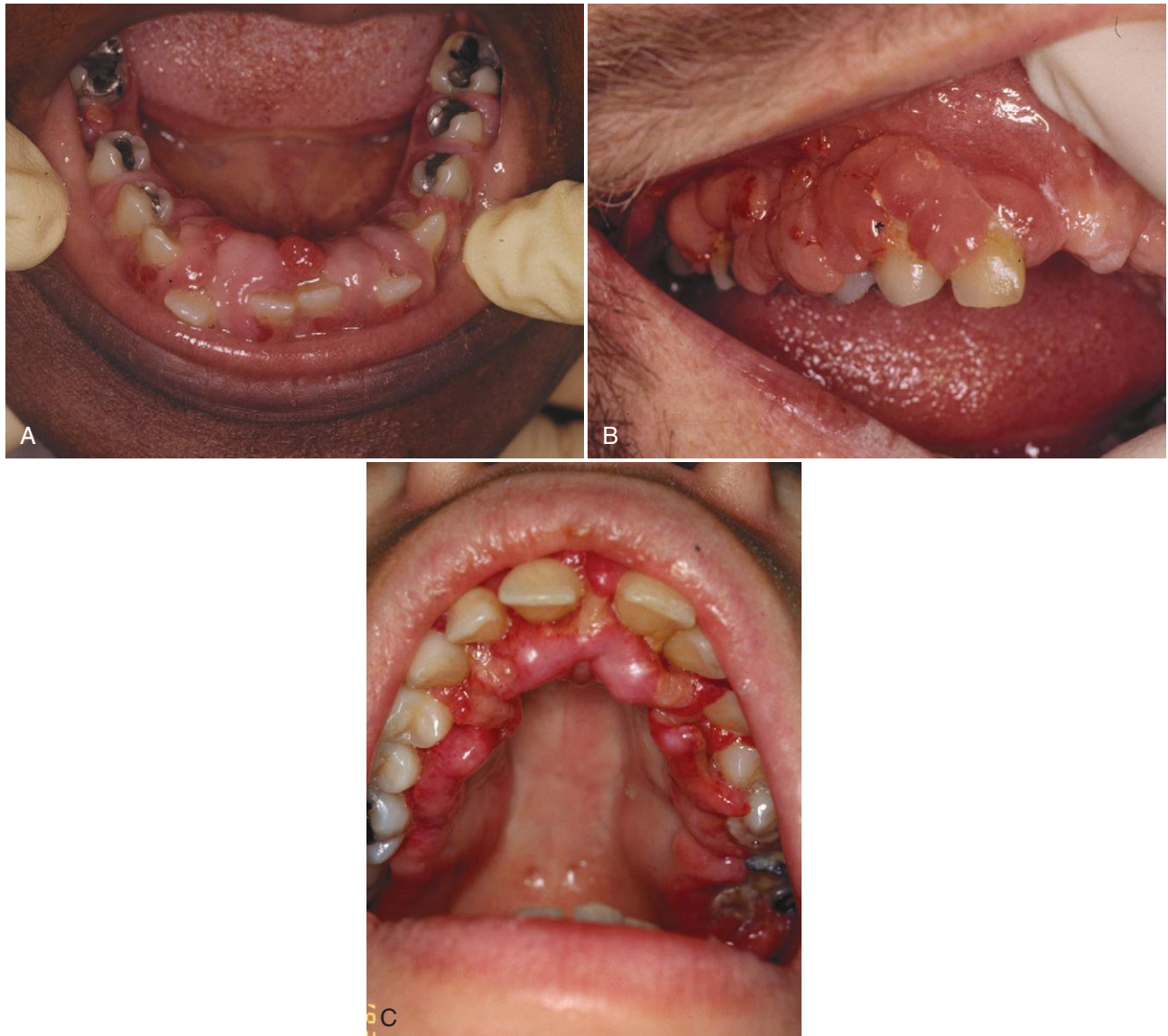- Presence of an atypical infiltrate should raise suspicion for acute myeloid or monocytic leukemia.
- Presence of pools of eosinophilic material (fibrin that is positive with phosphotungstic acid-hematoxylin) that fills the lamina propria should raise suspicion for ligneous gingivitis/periodontitis, a disorder of plasminogen activator deficiency (Figs. 5-27 and 5-28).

### Management and Prognosis

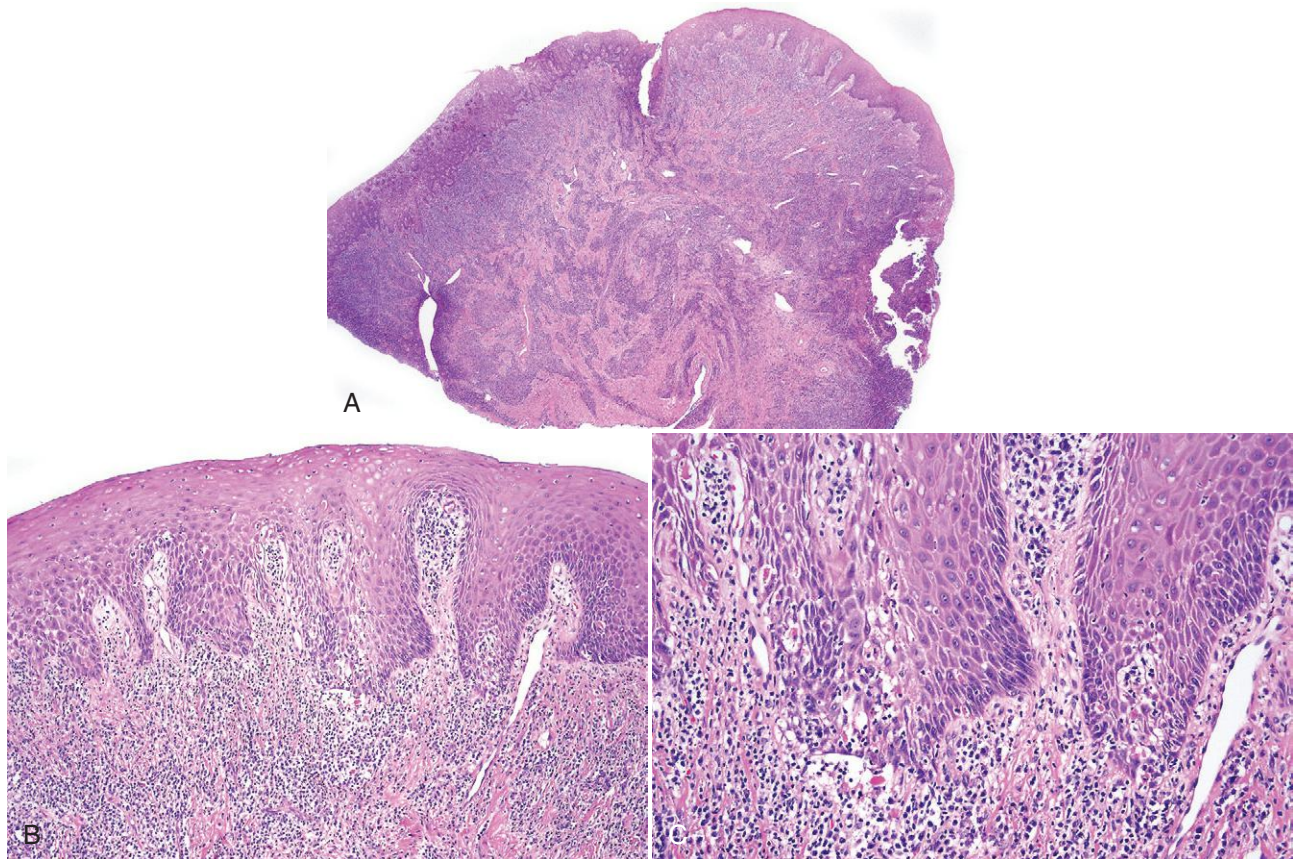
- Excision of hyperplastic tissue, maintenance of good oral hygiene, use of 0.12% chlorhexidine oral rinse, and low-dose doxycycline (20 mg) may reduce recurrence.

### REFERENCES

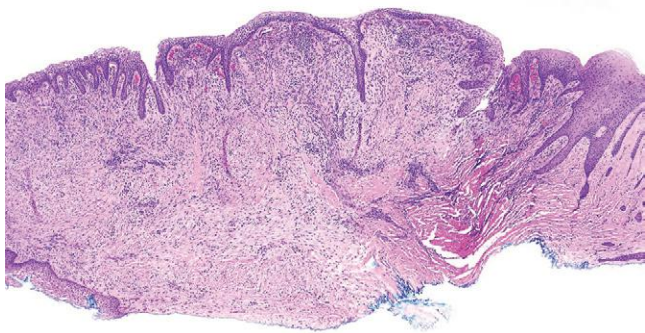
- Fine G, Bauer K, Al-Mohaya M, Woo SB. Successful treatment of ligneous gingivitis with warfarin. *Oral Surg Oral Med Oral Pathol Oral Radiol Endod.* 2009;107:77-80.
- Gunhan O, Gunhan M, Berker E, et al. Destructive membranous periodontal disease (ligneous periodontitis). *J Periodontol.* 1999;70:919-925.
- Kataoka M, Kido J, Shinohara Y, Nagata T. Drug-induced gingival overgrowth—a review. *Biol Pharm Bull* 2005;28:1817-1821.
- Neville BW, Damm DD, Allen CM, Bouquot J. *Oral and Maxillofacial Pathology.* 5th ed. Philadelphia: Saunders; 2009.
- Wright HJ, Chapple IL, Matthews JB. TGF-beta isoforms and TGF-beta receptors in drug-induced and hereditary gingival overgrowth. *J Oral Pathol Med.* 2001;30:281-289.



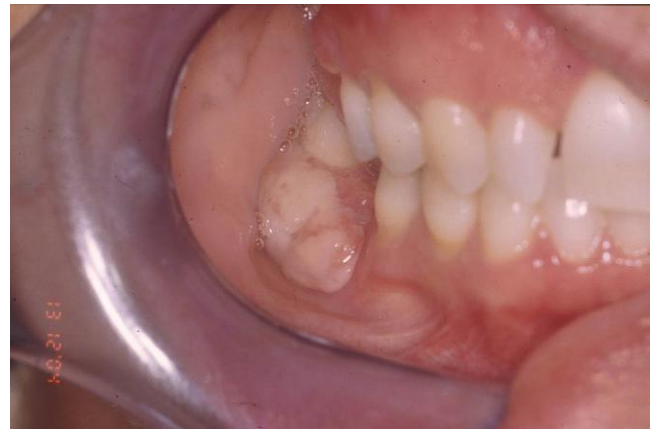**FIGURE 5-24.** **A**, Diffuse gingival hyperplasia secondary to phenytoin use. **B**, Diffuse gingival hyperplasia secondary to nifedipine and cyclosporine use (postrenal transplantation). **C**, Diffuse gingival enlargement from leukemic infiltrate.



**FIGURE 5-25.** Gingival fibrous hyperplasia. **A**, Fibrous tissue with marked chronic inflammation. **B**, Benign epithelial hyperplasia with spongiosis. **C**, Cytoid bodies present with many plasma cells.

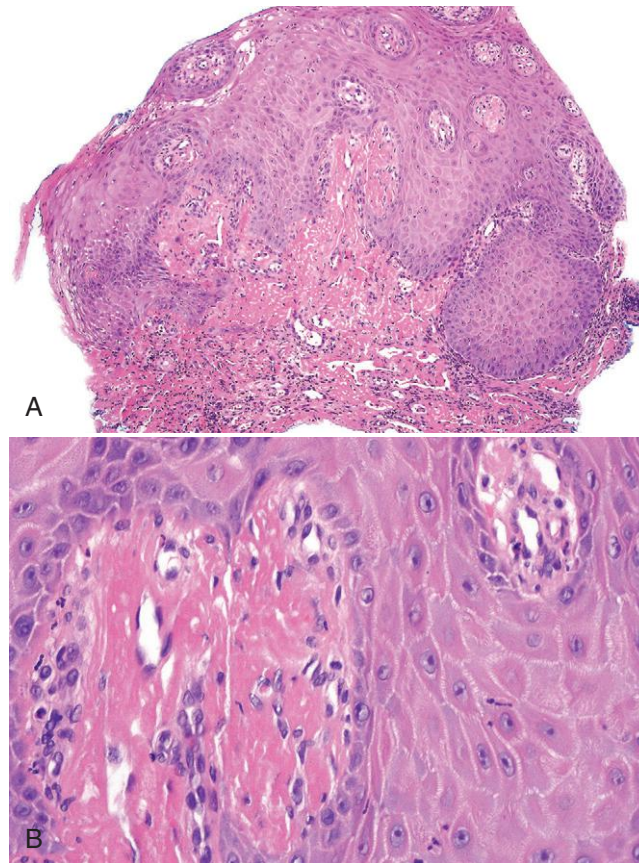


**FIGURE 5-26.** Gingival fibrous hyperplasia: epithelial atrophy and chronic inflammation.



**FIGURE 5-27.** Lincuous gingivitis manifesting as one of several ulcerated gingival nodules.





**FIGURE 5-28.** Liginous gingivitis/periodontitis. **A**, Lamina propria filled with eosinophilic fibrinous material. **B**, Eosinophilic fibrinous material fills the lamina propria.

## Gingival Cyst of the Adult

### Clinical Findings

- Usually in the fifth or sixth decade, bluish, slightly fluctuant, dome-shaped nodule on the attached or nonattached gingiva/alveolar mucosa of the mandibular canine-premolar area (80%); some cases bilateral (Fig. 5-29)

### Etiopathogenesis and Histopathologic Features

Gingival cyst of the adult forms from cystic degeneration of rests of dental lamina (rests of Serres) in the gingiva (Fig. 5-30).

- Lined by nonkeratinized low cuboidal or squamous epithelium usually two to four cells thick; often see epithelial plaques containing glycogen-rich clear cells sometimes with a swirling architecture (Figs. 5-31 to 5-33)
- Rarely, gingival cyst of the adult may have features of odontogenic keratocyst with parakeratosis and palisading of the basal cells; hyaline Rushton bodies may be present (Figs. 5-34 and 5-35)

### Differential Diagnosis

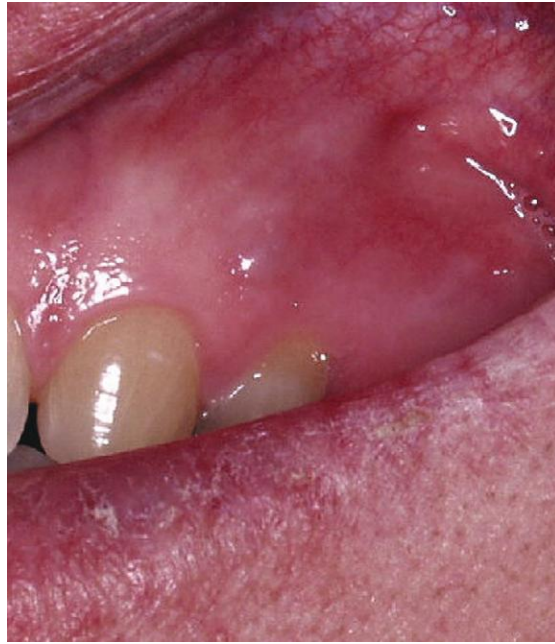- Sialocyst may occur on nonkeratinized gingiva/alveolar mucosa; often has thicker lining (5 to 10 cells), mucous cells, ciliated cells, or oncocytes and does not show epithelial plaques with clear cells.
- Odontogenic keratocyst that has eroded through bone and manifests in the soft tissues must be ruled out by a radiograph if parakeratin is present in the gingival cyst of the adult.

### Management and Prognosis

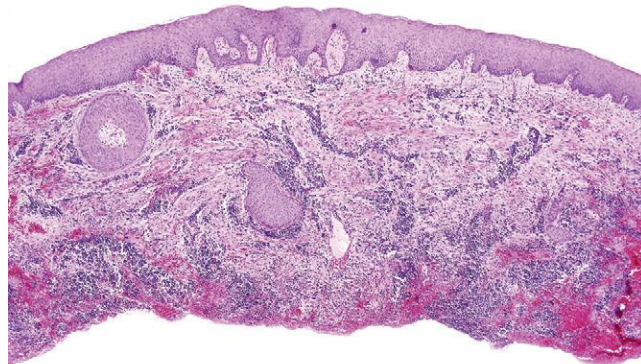
- Excision is the treatment of choice for the adult form.

### REFERENCES

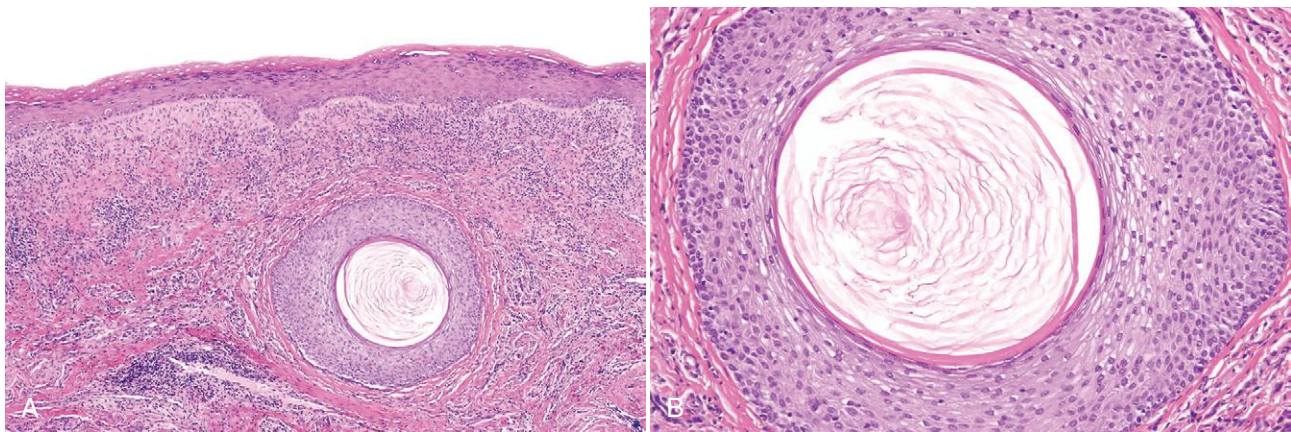
- Bell RC, Chauvin PJ, Tyler MT. Gingival cyst of the adult: a review and a report of eight cases. *J Can Dent Assoc.* 1997;63:533-535.
- Chi AC, Owings JR Jr, Muller S. Peripheral odontogenic keratocyst: report of two cases and review of the literature. *Oral Surg Oral Med Oral Pathol Oral Radiol Endod.* 2005;99:71-78.
- Giunta JL. Gingival cysts in the adult. *J Periodontol.* 2002;73:827-831.
- Kelsey VW, Kalmar JR, Tatakis DN. Gingival cyst of the adult: regenerative therapy of associated root exposure. A case report and literature review. *J Periodontol.* 2009;80:2073-2081.
- Preston RD, Narayana N. Peripheral odontogenic keratocyst. *J Periodontol.* 2005;76:2312-2315.



**FIGURE 5-29.** Small gingival cyst of the adult appearing as slight dome-shaped lesion.

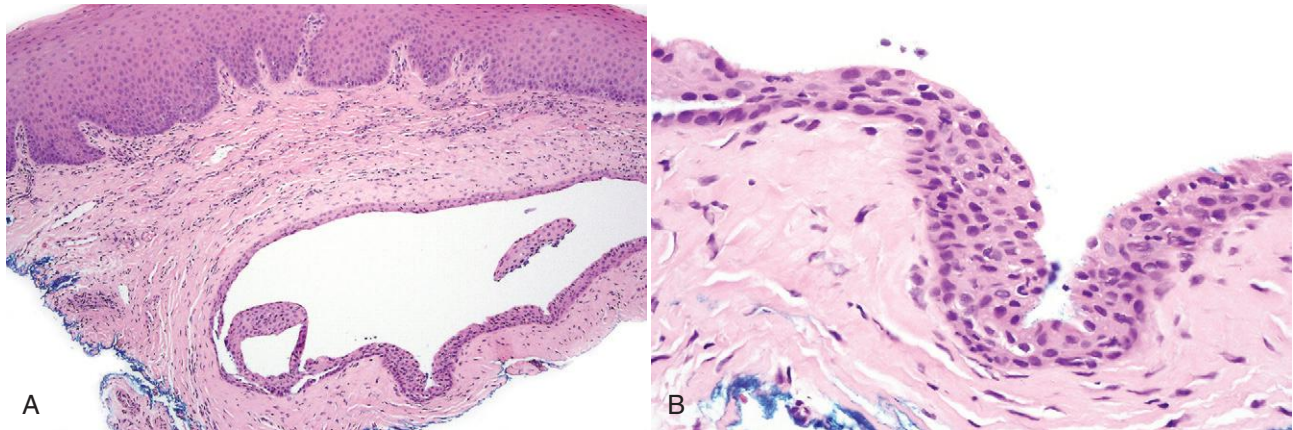


**FIGURE 5-30.** Rests of Serres, one with early cystic degeneration.

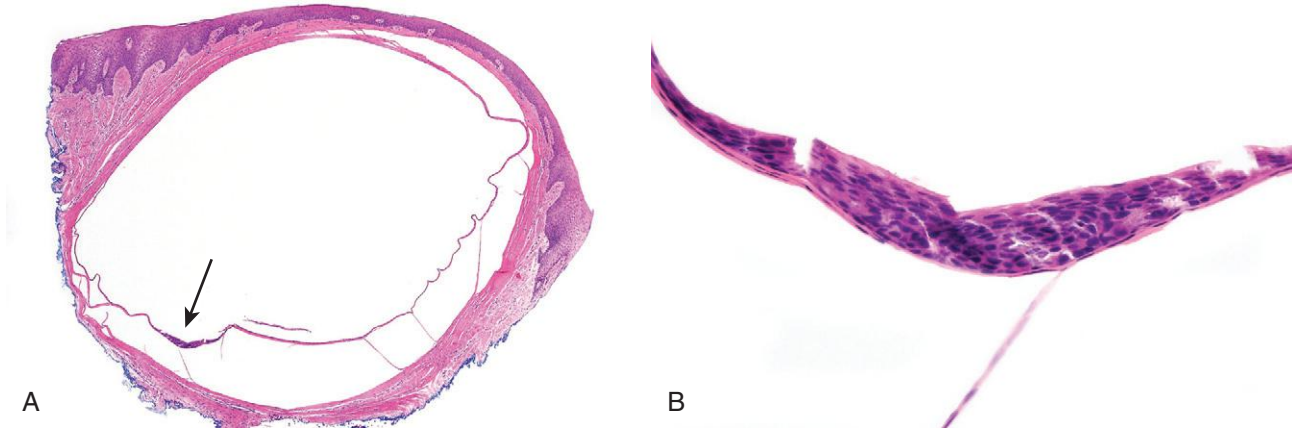


**FIGURE 5-31.** Early gingival cyst of the adult. **A**, Cystic degeneration of a rest of Serres. **B**, Presence of pale and clear cells and orthokeratinization.

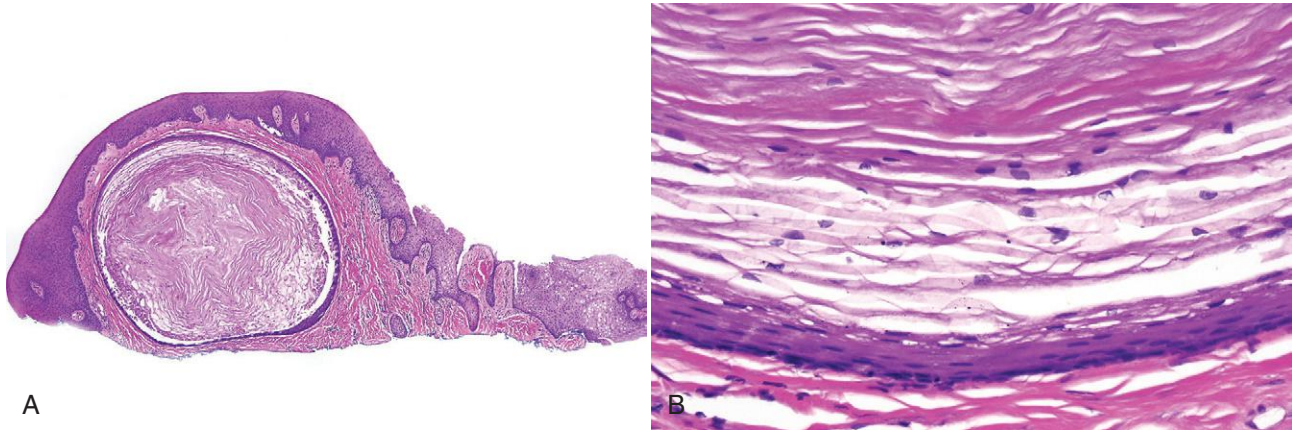




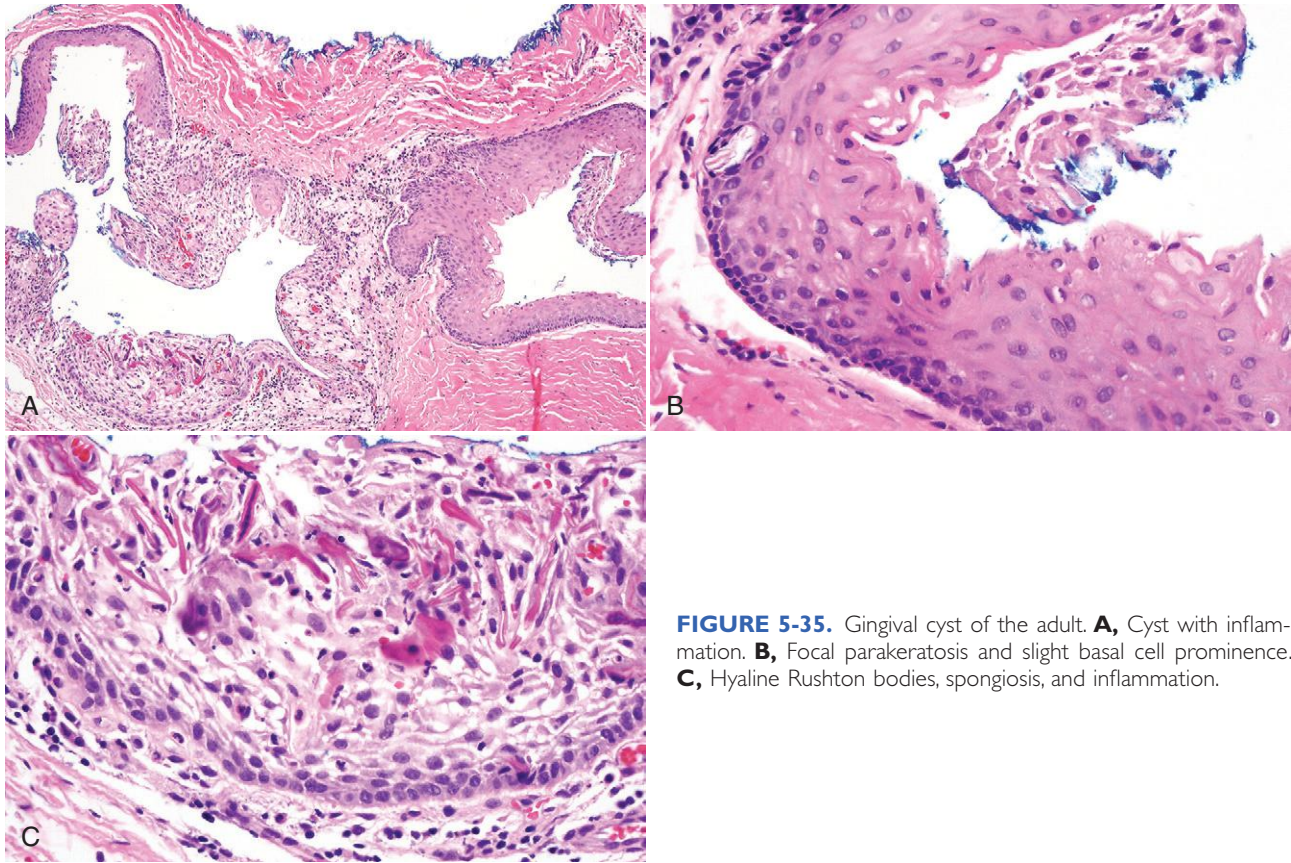
**FIGURE 5-32.** Gingival cyst of the adult. **A**, Uniformly thin lining of squamous epithelium and epithelial plaques. **B**, Epithelial plaques.



**FIGURE 5-33.** Gingival cyst of the adult. **A**, Overlying epithelium is attenuated; uniformly thin epithelial lining and epithelial plaque (arrow). **B**, Focal epithelial plaque.



**FIGURE 5-34.** Gingival cyst of the adult. **A**, Cyst filled with keratin. **B**, Parakeratosis without basal cell nuclei palisading.



**FIGURE 5-35.** Gingival cyst of the adult. **A**, Cyst with inflammation. **B**, Focal parakeratosis and slight basal cell prominence. **C**, Hyaline Rushton bodies, spongiosis, and inflammation.

## Peripheral (Extrasosseous) Odontogenic Neoplasms

Although any odontogenic neoplasm may appear on the gingiva (peripheral or extrasosseous lesions), the ones seen most frequently include the peripheral odontogenic fibroma (approximately 50% of all cases), peripheral ameloblastoma, and peripheral calcifying cystic odontogenic tumor. Even odontomas may occur in an extrasosseous site. Please see [Chapter 15](#) for further discussion of these entities within the bone.

### Clinical Findings

- All odontogenic neoplasms manifest as nondescript sessile nodules or masses on the gingiva that may be ulcerated if traumatized, similar to reactive gingival nodules (see earlier).

### Etiopathogenesis and Histopathologic Features

Odontogenic neoplasms likely arise from stem cells within odontogenic rests or from pluripotent cells in the basal layer of the surface epithelium.

## PERIPHERAL ODONTOGENIC FIBROMA

- Equal distribution exists between maxilla and mandible with 60% to 75% of cases around the incisors/cuspids; adults in the second and fourth decades are affected.

- Cellular proliferation of fibroblast-like spindle cells is present with scattered islands and strands of odontogenic epithelium, some of which may contain clear cells with or without slight palisading of the basal cell nuclei ([Fig. 5-36](#)); overlying epithelial proliferation often is present.
- Calcifications manifest in 60% of cases and take the form of osteoid, cementum-like material, or eosinophilic, amorphous dentinoid (resembles acellular osteoid or sometimes cementum) often adjacent to odontogenic epithelium ([Fig. 5-37](#)); stroma is collagenized and may be myxoid/mucinous.
- Epithelial islands may be so abundant the term *odontogenic gingival epithelial hamartoma* applies; association with giant cell granuloma is a rare occurrence.
- Significant numbers of granular cells in the stroma raises the diagnosis of peripheral granular cell odontogenic tumor.

### Differential Diagnosis

- Peripheral ossifying fibroma has osteoid and cementum and no epithelial islands.
- Fibrous hyperplasia or fibroma may have detached islands of epithelium from tips of rete ridges but lack clear cells.
- Peripheral (extrasosseous) dentinogenic ghost cell tumor contains basaloid epithelial cells and ghost cells.



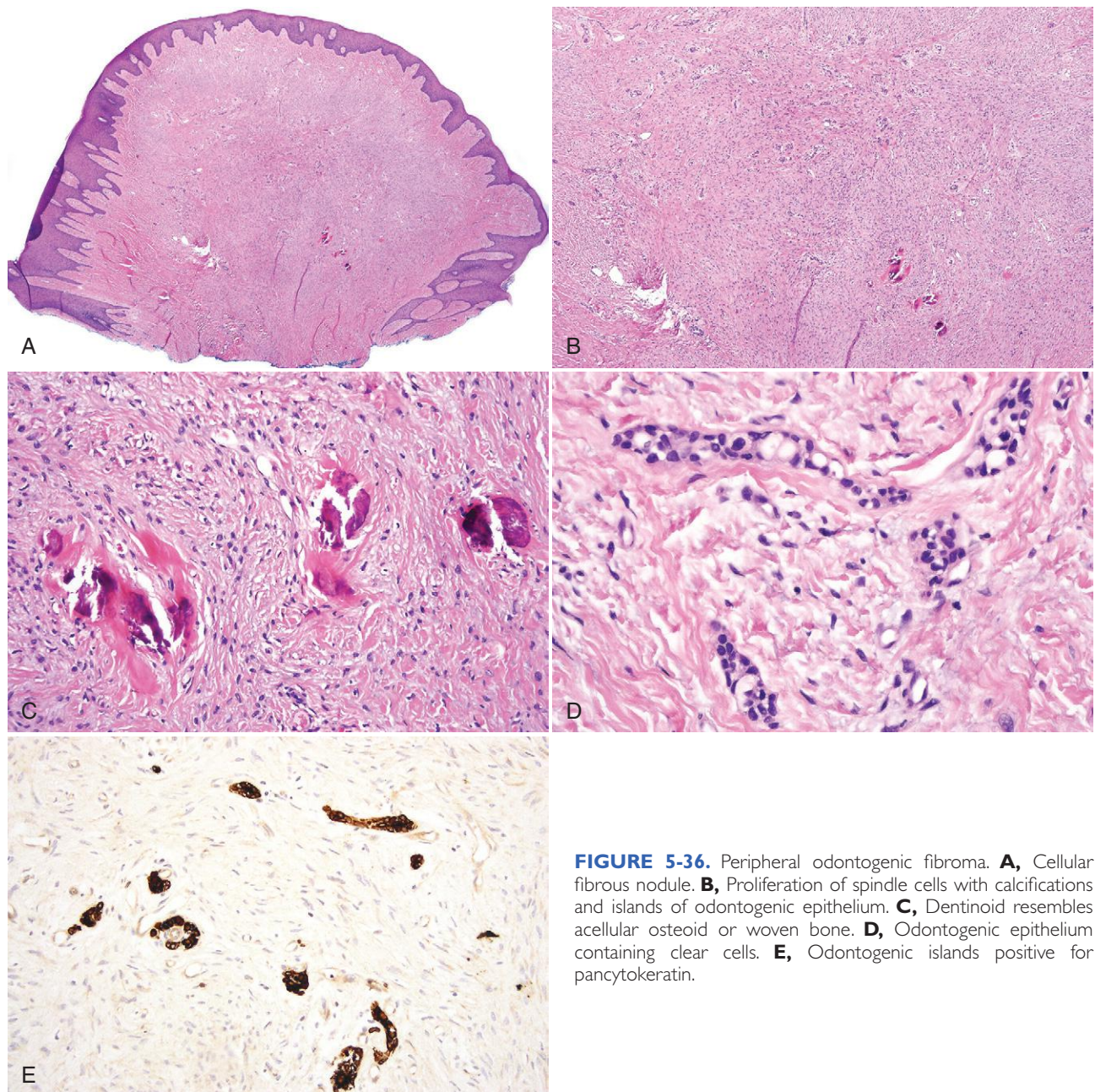
### Management and Prognosis

- Excision is the treatment of choice.
- Peripheral odontogenic fibroma may recur in 50% of cases; budding and deep extensions of rete ridges may be associated with higher recurrence.

### REFERENCES

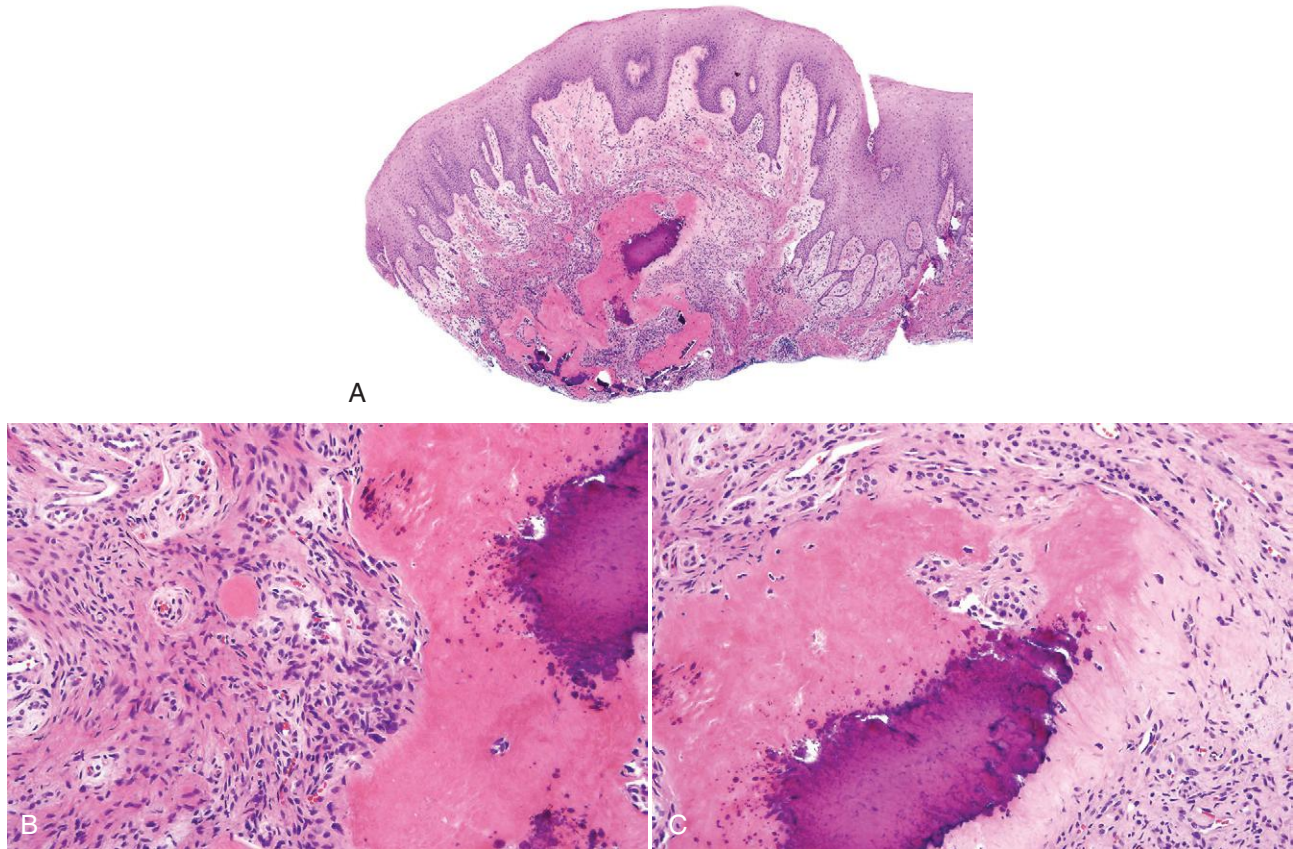
- Buchner A, Merrell PW, Carpenter WM. Relative frequency of peripheral odontogenic tumors: a study of 45 new cases and comparison with studies from the literature. *J Oral Pathol Med.* 2006;35:385-391.
- Ficarra G, Sapp JP, Eversole LR. Multiple peripheral odontogenic fibroma, World Health Organization type, and central giant cell granuloma: a case report of an unusual association. *J Oral Maxillofac Surg.* 1993;51:325-328.

- Ide F, Obara K, Mishima K, et al. Peripheral odontogenic tumor: a clinicopathologic study of 30 cases. General features and hamartomatous lesions. *J Oral Pathol Med.* 2005;34:552-557.
- Ide F, Mishima K, Saito I, Kusama K. Rare peripheral odontogenic tumors: report of 5 cases and comprehensive review of the literature. *Oral Surg Oral Med Oral Pathol Oral Radiol Endod.* 2008;106:e22-e28.
- Rinaggio J, Cleveland D, Koshy R, et al. Peripheral granular cell odontogenic fibroma. *Oral Surg Oral Med Oral Pathol Oral Radiol Endod.* 2007;104:676-679.
- Ritwik P, Brannon RB. Peripheral odontogenic fibroma: a clinicopathologic study of 151 cases and review of the literature with special emphasis on recurrence. *Oral Surg Oral Med Oral Pathol Oral Radiol Endod.* 2010;110:357-363.
- Siar CH, Ng KH. Clinicopathological study of peripheral odontogenic fibromas (WHO-type) in Malaysians (1967-95). *Br J Oral Maxillofac Surg.* 2000;38:19-22.



**FIGURE 5-36.** Peripheral odontogenic fibroma. **A**, Cellular fibrous nodule. **B**, Proliferation of spindle cells with calcifications and islands of odontogenic epithelium. **C**, Dentinoid resembles acellular osteoid or woven bone. **D**, Odontogenic epithelium containing clear cells. **E**, Odontogenic islands positive for pancytokeratin.





**FIGURE 5-37.** Peripheral odontogenic fibroma. **A**, Spindle cell proliferation and prominent dentinoid formation. **B**, Spindle cell proliferation and paucicellular dentinoid. **C**, Islands of benign odontogenic epithelium present.

## PERIPHERAL AMELOBLASTOMA

- Fifth to sixth decades (older than intraosseous ameloblastoma), usually in the mandible, premolar/molar region
- Proliferation of islands of epithelium with palisading and reverse polarization of the basal cell nuclei (this may be subtle); often seen in continuity with overlying epithelium; center of the islands may show stellate reticulum-like areas or be squamous; no mitotic activity unless traumatized (Figs. 5-38 and 5-39); often CK19 positive
- Stroma collagenized with minimal desmoplasia although peripheral desmoplastic ameloblastoma has been reported

### Differential Diagnosis

- Extremely important to rule out (with radiographs) an intraosseous (central) ameloblastoma that has eroded through the cortical bone and lies in the gingiva because peripheral ameloblastomas are not locally aggressive lesions, whereas intraosseous ones are.
- Odontogenic gingival epithelial hamartoma is likely an epithelium-rich variant of the peripheral

odontogenic fibroma and shows bland-appearing epithelium without peripheral palisading.

- Extrasosseous squamous odontogenic tumors are rare and do not show palisading or reverse polarization of peripheral cells.
- Basaloid squamous cell carcinoma shows significant epithelial atypia and synchronous conventional squamous cell carcinoma.

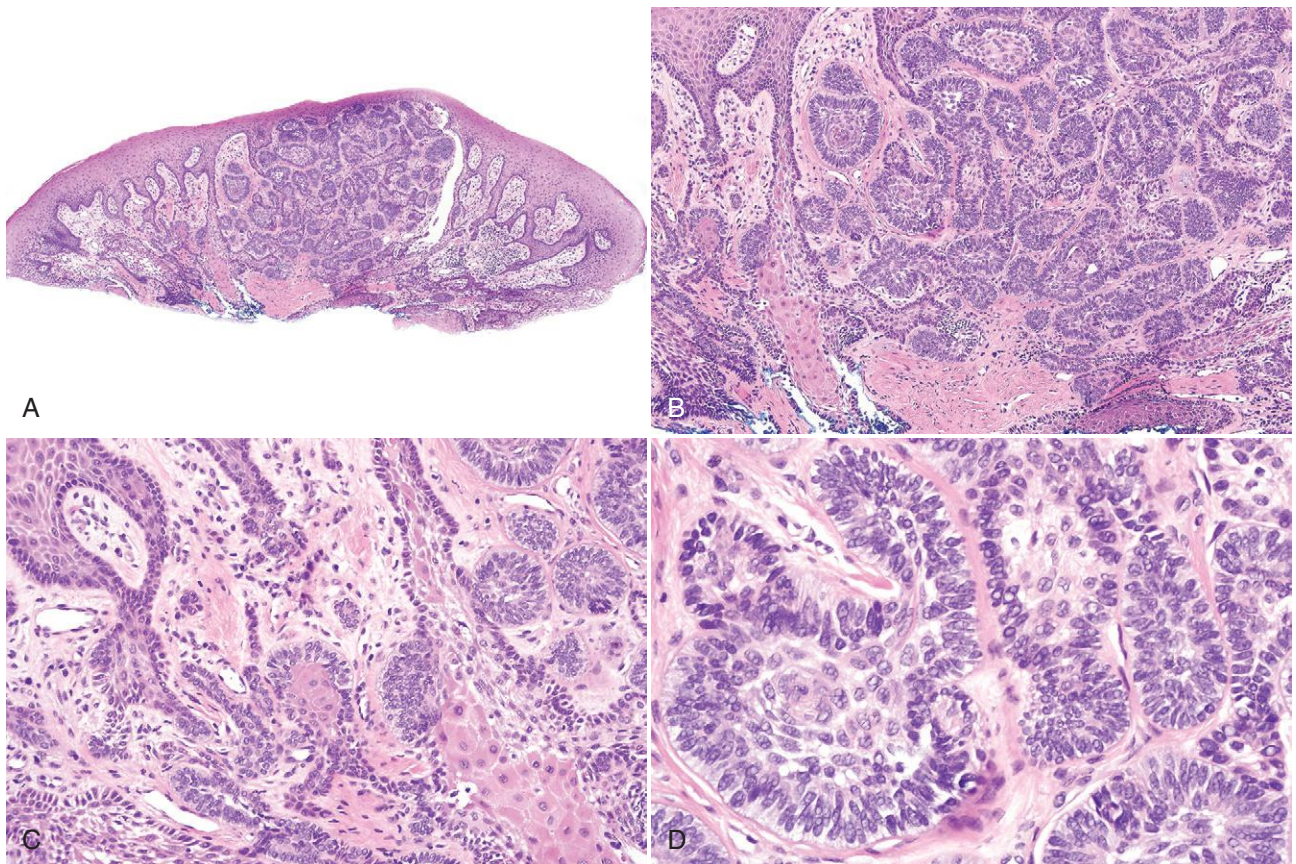
### Management and Prognosis

- Excision is curative; not locally aggressive unlike intraosseous lesions

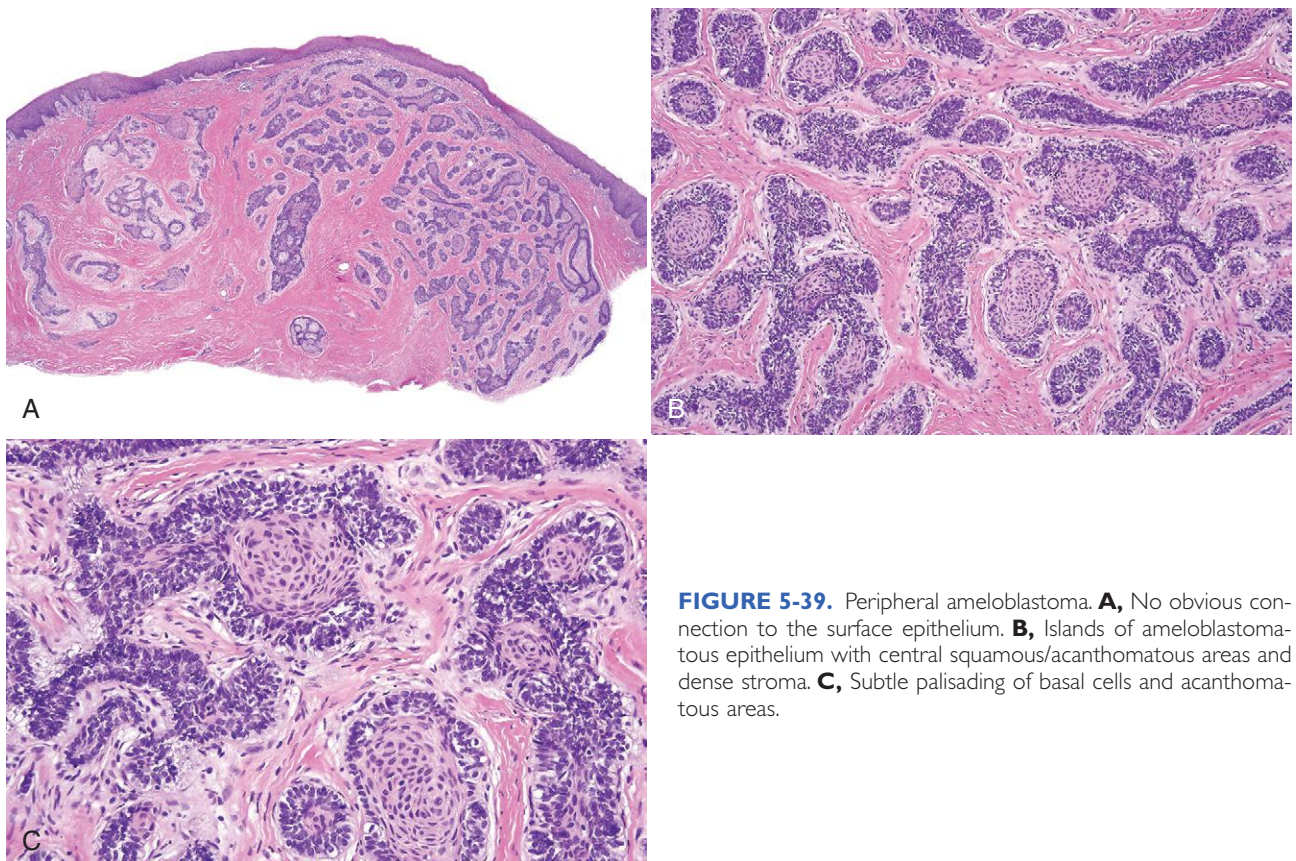
### REFERENCES

- Ide F, Mishima K, Miyazaki Y, et al. Peripheral ameloblastoma in-situ: an evidential fact of surface epithelium origin. *Oral Surg Oral Med Oral Pathol Oral Radiol Endod.* 2009;108:763-767.
- Isomura ET, Okura M, Ishimoto S, et al. Case report of extragingival peripheral ameloblastoma in buccal mucosa. *Oral Surg Oral Med Oral Pathol Oral Radiol Endod.* 2009;108:577-579.
- Kishino M, Murakami S, Yuki M, et al. A immunohistochemical study of the peripheral ameloblastoma. *Oral Dis.* 2007;13:575-580.
- Philipsen HP, Reichart PA, Nikai H, et al. Peripheral ameloblastoma: biological profile based on 160 cases from the literature. *Oral Oncol.* 2001;37:17-27.





**FIGURE 5-38.** Peripheral ameloblastoma. **A**, Follicular pattern of epithelial proliferation. **B**, Proliferation of basaloid cells in continuity with surface epithelium. **C**, Epithelial islands contain stellate reticulum-like and acanthomatous areas. **D**, Palisading and reverse nuclear polarization of basal cells.



**FIGURE 5-39.** Peripheral ameloblastoma. **A**, No obvious connection to the surface epithelium. **B**, Islands of ameloblastomatous epithelium with central squamous/acanthomatous areas and dense stroma. **C**, Subtle palisading of basal cells and acanthomatous areas.



## PERIPHERAL CALCIFYING CYSTIC ODONTOGENIC TUMOR

- May be either cystic or solid (dentinogenic ghost cell tumor) (see Chapter 15 for a more detailed description).
- Solid variant shows proliferation of basaloid cells that may be ameloblastoma-like, ghost cells, and dentinoid, an amorphous eosinophilic calcified material that resembles acellular woven bone; ghost cells often elicit a foreign body reaction (Figs. 5-40 and 5-41)

### Differential Diagnosis

- Peripheral ameloblastoma does not exhibit ghost cell formation or deposits of dentinoid.
- Peripheral odontogenic fibroma contains small islands and cords of epithelium without ghost cell

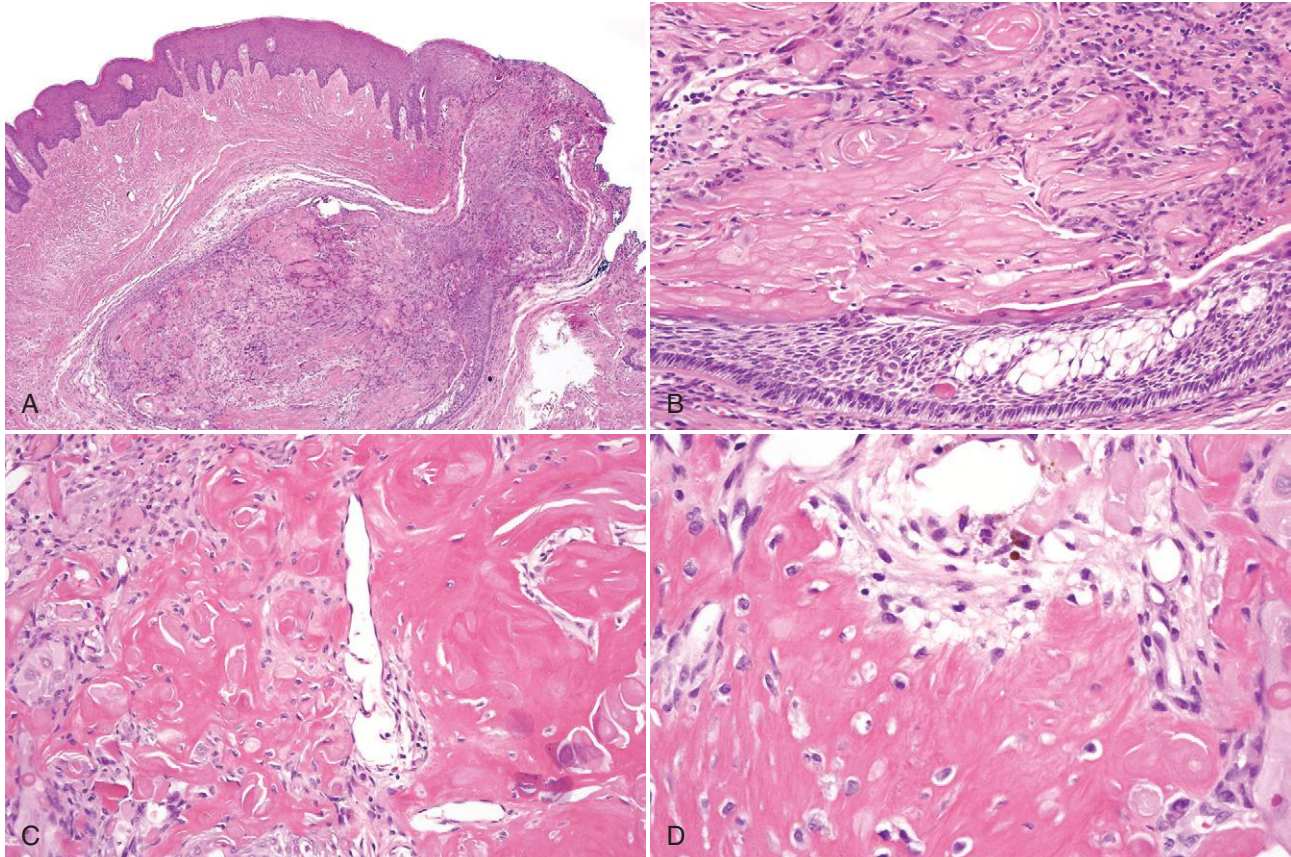
formation, although there may be small deposits of dentinoid.

### Management and Prognosis

- Excision is curative.

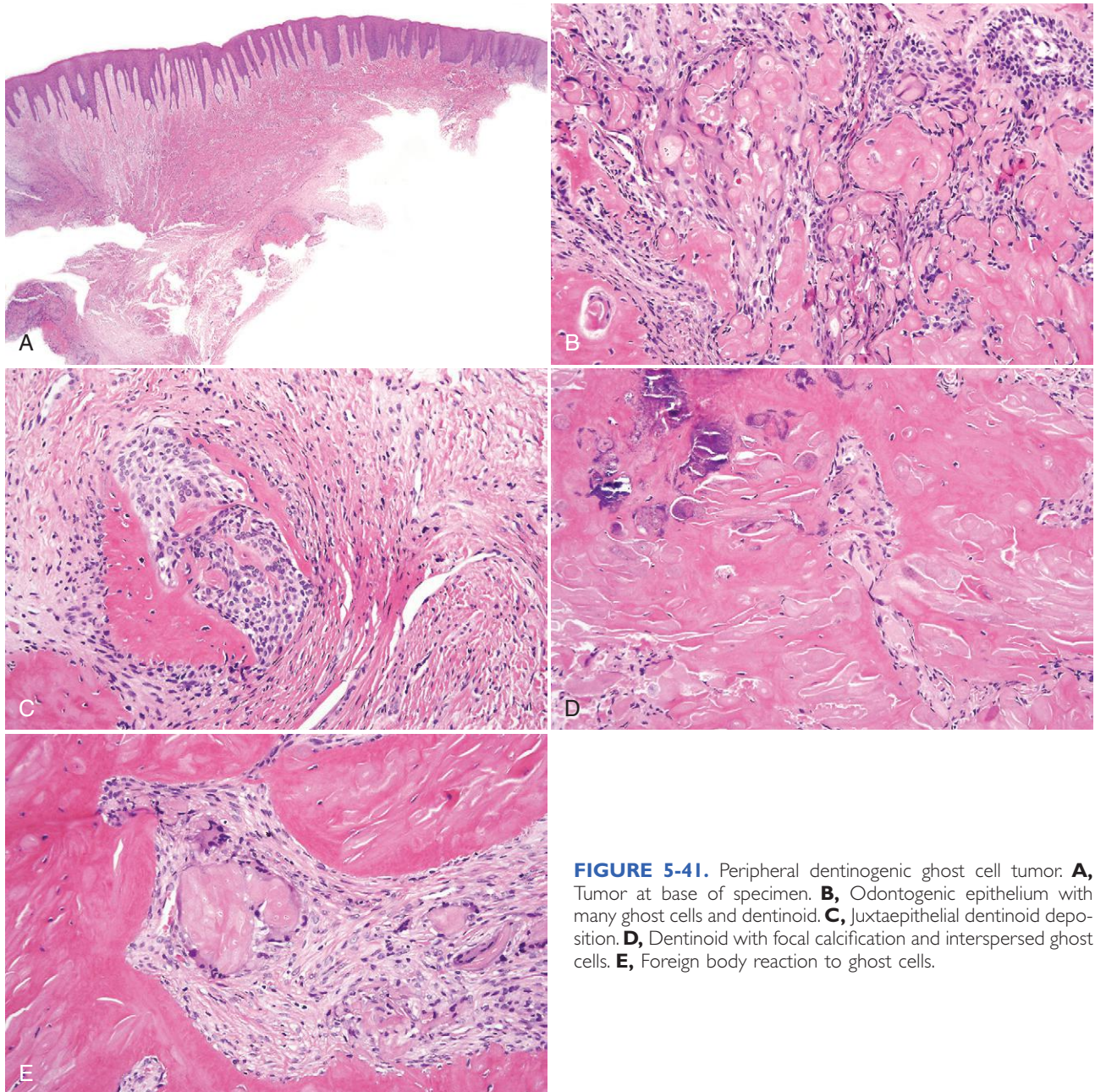
### REFERENCES

- Buchner A, Merrell PW, Hansen LS, Leider AS. Peripheral (extraosseous) calcifying odontogenic cyst. A review of forty-five cases. *Oral Surg Oral Med Oral Pathol.* 1991;72:65-70.
- Candido GA, Viana KA, Watanabe S, Vencio EF. Peripheral dentinogenic ghost cell tumor: a case report and review of the literature. *Oral Surg Oral Med Oral Pathol Oral Radiol Endod.* 2009;108:e86-90.
- Curran AE. Peripheral odontogenic tumors. *Oral Maxillofac Surg Clin North Am.* 2004;16:399-408.



**FIGURE 5-40.** Peripheral dentinogenic ghost cell tumor. **A**, Tumor in continuity with the surface epithelium. **B**, Resembles ameloblastoma with reverse polarization of nuclei, stellate reticulum-like areas, but with ghost cells. **C**, Ghost cells associated with surrounding dentinoid deposition. **D**, Dentinoid resembles woven bone; melanin present.





**FIGURE 5-41.** Peripheral dentinogenic ghost cell tumor. **A**, Tumor at base of specimen. **B**, Odontogenic epithelium with many ghost cells and dentinoid. **C**, Juxtaepithelial dentinoid deposition. **D**, Dentinoid with focal calcification and interspersed ghost cells. **E**, Foreign body reaction to ghost cells.

## Metastases to the Gingiva

Two thirds of metastases to the oral cavity occur to the jawbones (80% in the mandible) and one third to the soft tissues, with the gingiva being the most common site, followed by the tongue.

### Clinical Findings

- Rapidly enlarging mass on the gingiva in older patients; in 25% to 60% of cases, metastasis may be first indication that a malignancy is present.

### Etiopathogenesis and Histopathologic Features

The most common primary sites for such metastases are lung, breast, prostate, kidney, and colon/rectum (Fig. 5-42).

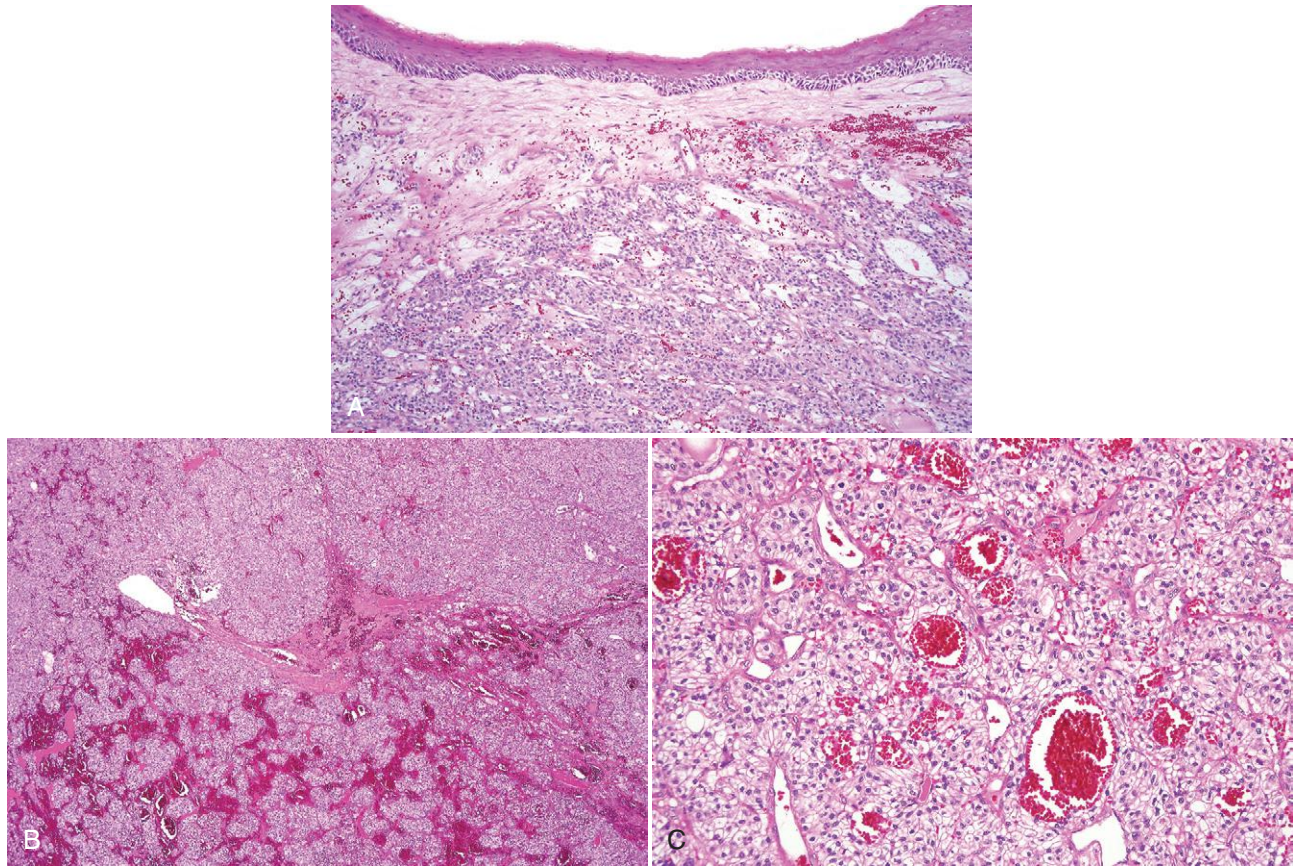
### Management and Prognosis

- Generally poor prognosis with low 1-year survival

### REFERENCES

- D'Silva NJ, Summerlin DJ, Cordell KG, et al. Metastatic tumors in the jaws: a retrospective study of 114 cases. *J Am Dent Assoc.* 2006;137:1667-1672.
- Hirshberg A, Shnaiderman-Shapiro A, Kaplan I, Berger R. Metastatic tumours to the oral cavity—pathogenesis and analysis of 673 cases. *Oral Oncol.* 2008;44:743-752.





**FIGURE 5-42.** Metastatic renal cell carcinoma to the gingiva. **A**, Tumor present within the gingival mucosa. **B**, Tumor forms large lobules with nested tumor cells and abundant fresh hemorrhage. **C**, Nests of clear cells surrounded by dilated vessels.

### Denture-Associated Inflammatory Fibrous Hyperplasia (Epulis Fissuratum)

The term *epulis* refers to any mass on gingiva—inflammatory, neoplastic, or cystic—and is nonspecific.

#### Clinical Findings

- Linear mass of tissue along the flange of a denture in the maxillary or mandibular buccal vestibule/sulcus or floor of mouth, often with a fold in which denture flange rests; denture is loose and poor fitting (Fig. 5-43) (see also Chapter 3)

#### Etiopathogenesis and Histopathologic Features

- Fibrous tissue proliferates in reaction to trauma from movement of denture on the mucosa
- Fibroepithelial proliferation with a fissured or papillary architecture; variable vascularity and chronic

inflammatory infiltrate (usually lymphocytic) that tends to be subepithelial; traumatic neuroma and myositis often present (Figs. 5-44 and 5-45)

- Ulceration and pseudoepitheliomatous hyperplasia not uncommon; presence of spongiotic pustules necessitates a periodic acid–Schiff (PAS) stain with diastase digestion for identification of *Candida*
- Cartilaginous metaplasia sometimes seen

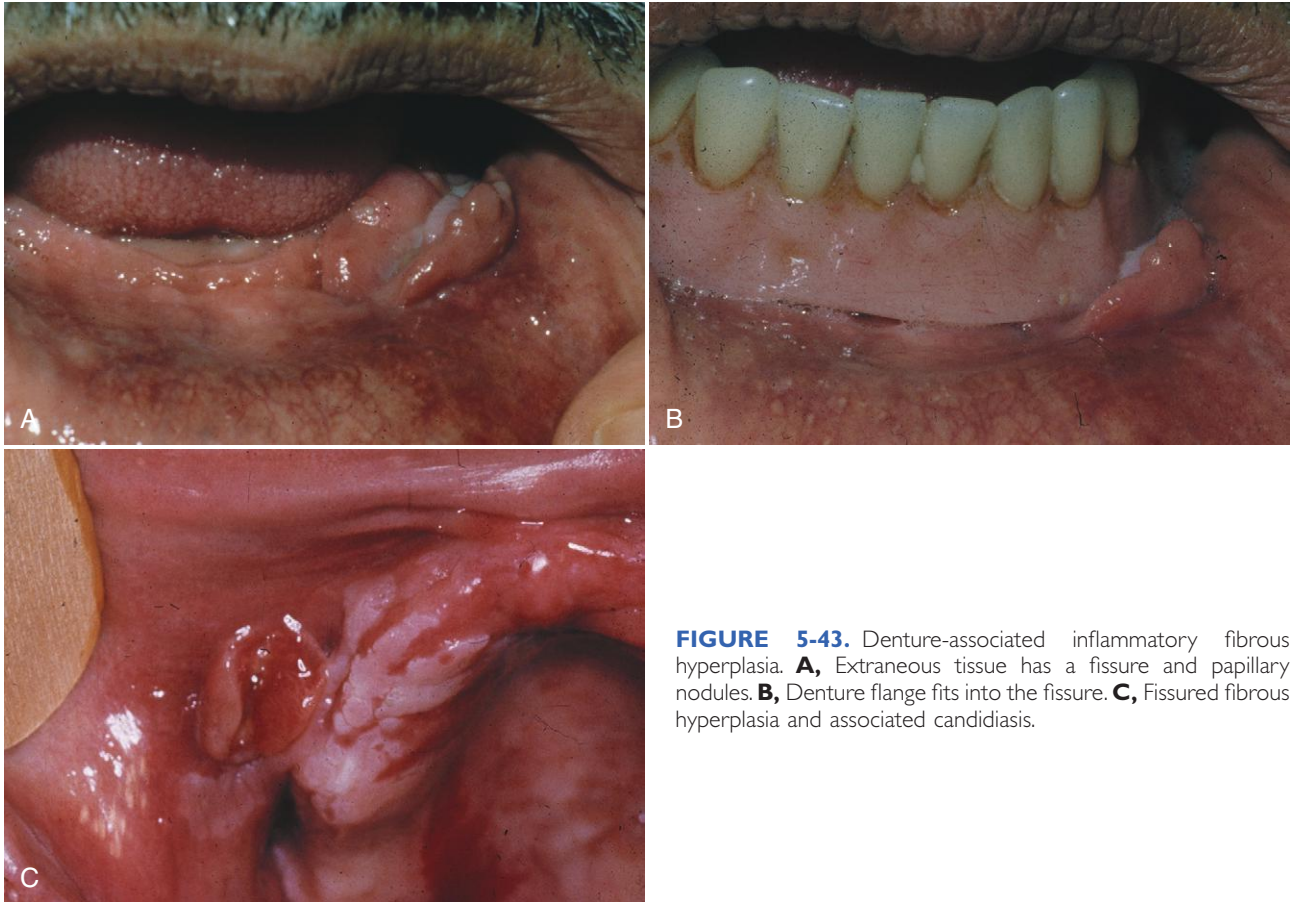#### Management and Prognosis

- Excision is curative if the denture is also relined or remade to reduce trauma to tissues.
- Treatment for candidiasis must include decontamination of the denture (see Appendix B).

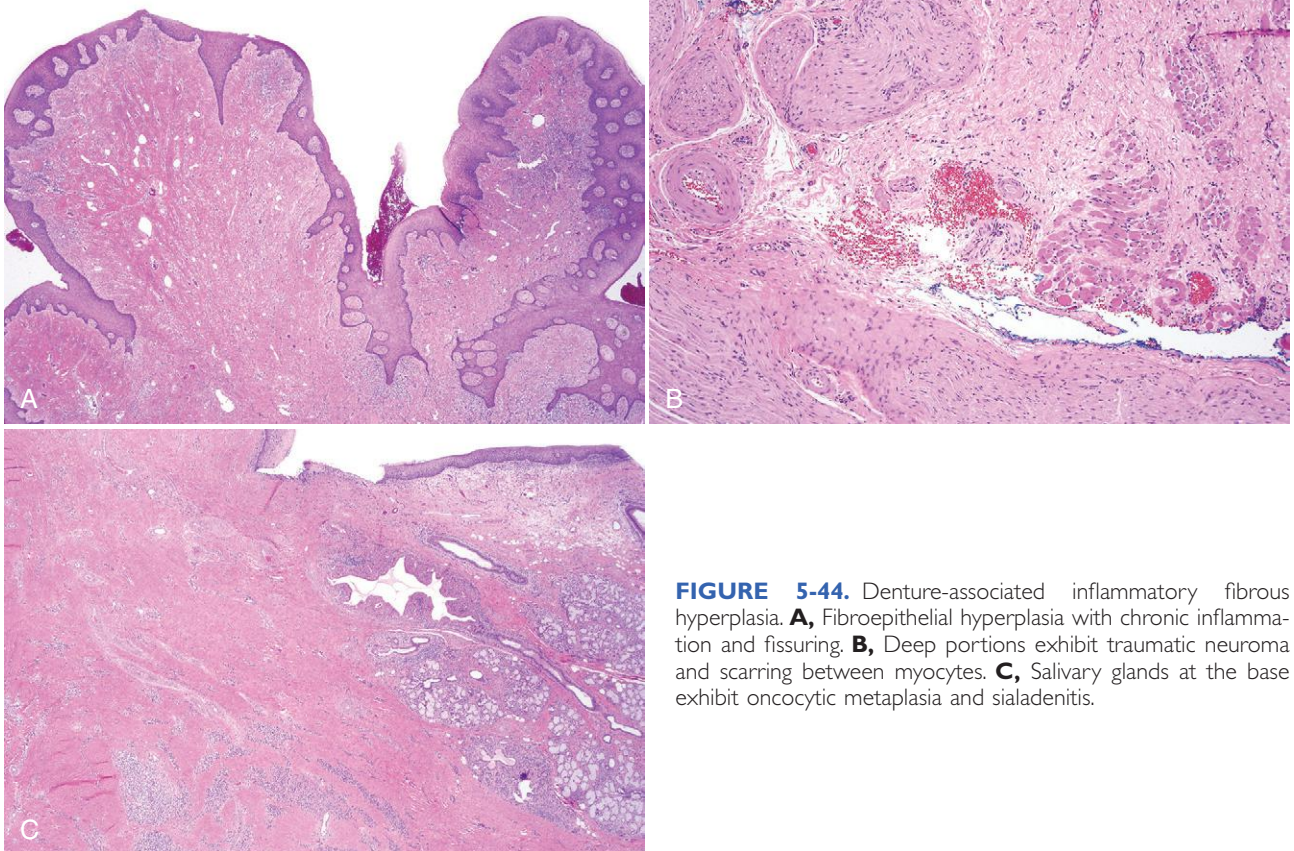
#### REFERENCE

Canger EM, Celenk P, Kayipmaz S. Denture-related hyperplasia: a clinical study of a Turkish population group. *Braz Dent J*. 2009;20:243-248.



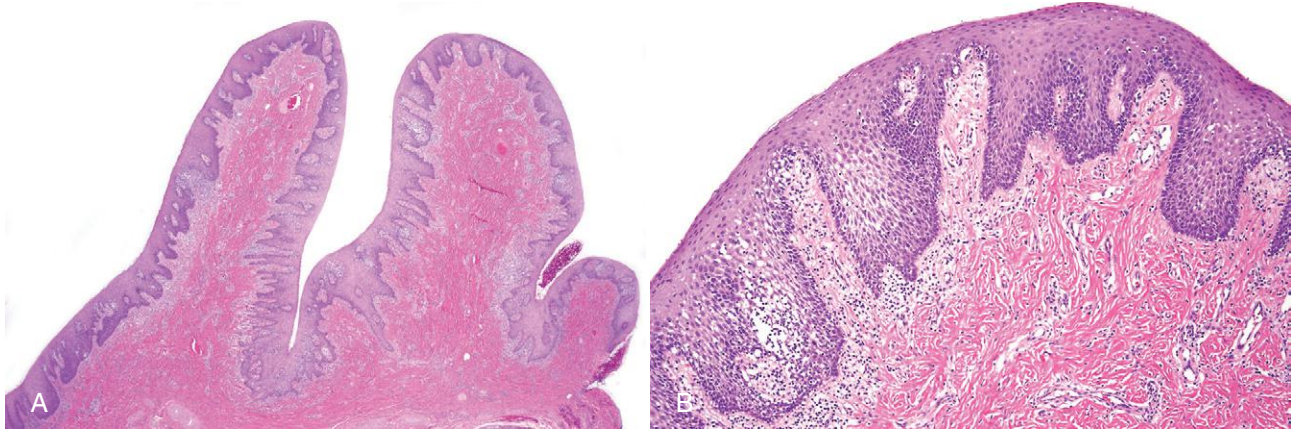


**FIGURE 5-43.** Denture-associated inflammatory fibrous hyperplasia. **A**, Extraneous tissue has a fissure and papillary nodules. **B**, Denture flange fits into the fissure. **C**, Fissured fibrous hyperplasia and associated candidiasis.



**FIGURE 5-44.** Denture-associated inflammatory fibrous hyperplasia. **A**, Fibroepithelial hyperplasia with chronic inflammation and fissuring. **B**, Deep portions exhibit traumatic neuroma and scarring between myocytes. **C**, Salivary glands at the base exhibit oncocytic metaplasia and sialadenitis.





**FIGURE 5-45.** Denture-associated inflammatory fibrous hyperplasia. **A**, Fibroepithelial hyperplasia with chronic inflammation and fissuring. **B**, Chronic inflammation usually within and beneath the epithelium.

## Lipocytic Lesions

### LIPOMA

#### Clinical Findings

Yellowish soft nodule often on the buccal mucosa and tongue, although any site may be involved; affects adults in the fifth and sixth decades (Fig. 5-46)

#### Etiopathogenesis and Histopathologic Features

Most so-called lipomas of the buccal mucosa represent herniation of the buccal fat pad (Fig. 5-47). True neoplasms arise from stem cells differentiating toward lipocytes and often show mutation in chromosome 12q.

- Unencapsulated lobules of mature lipocytes are sometimes separated by collagenized fibrous septa; lipocytes have evenly sized lipid vacuoles with no nuclear atypia; bone or cartilage prosoplasia may be present (indistinguishable from osteolipomatous or chondrolipomatous choristomas (Figs. 5-48 and 5-49); the terms *lipofibroma* and *fibrolipoma* are sometimes used, depending on whether fibrous or lipomatous tissue predominates.
- Spindle cell lipomas are true lipocytic neoplasms that are fairly common in the oral cavity, may show mutations in chromosome 13 or 16, and exhibit proliferation of spindle cells with scattered lipocytes, ropey or wiry collagen, mast cells, and dilated vessels (Figs. 5-50 and 5-51, A and B); cells are CD34 positive (see Fig. 5-51, C); the term *myxoid lipomas* is no longer used; pleomorphic lipoma is a variant of spindle cell lipoma with floret-type multinucleated cells.

#### Differential Diagnosis

- Lipocytes may represent prosoplastic tissue in other lesions such as pleomorphic adenoma and solitary fibrous tumor.
- Degenerative changes in fatty tissue may mimic lesions of atypical lipomatous tumor, and intramuscular lipomas may appear to be pseudoinvasive (Fig. 5-52).

- Atypical lipomatous tumor (well-differentiated liposarcoma of the oral cavity) affects adults in the fifth to seventh decades, occurs on the tongue or buccal mucosa, and contains lipoblasts that exhibit variation in the size of lipid vacuoles, nuclear hyperchromatism, and atypia (that may be subtle) (Fig. 5-53); MDM2 and CDK4 genes are almost always amplified; 10% to 20% recur.

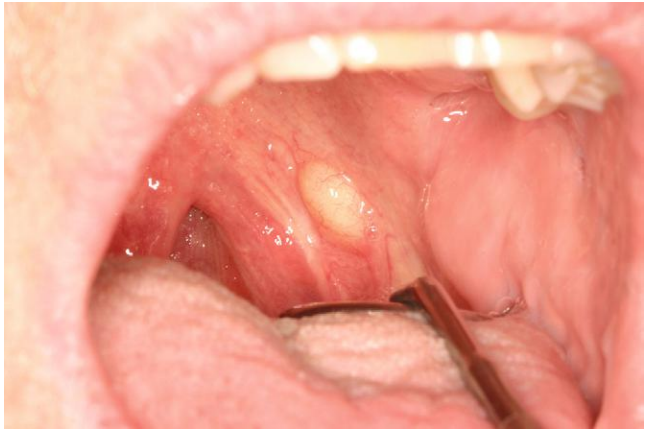#### Management and Prognosis

- Excision is curative.

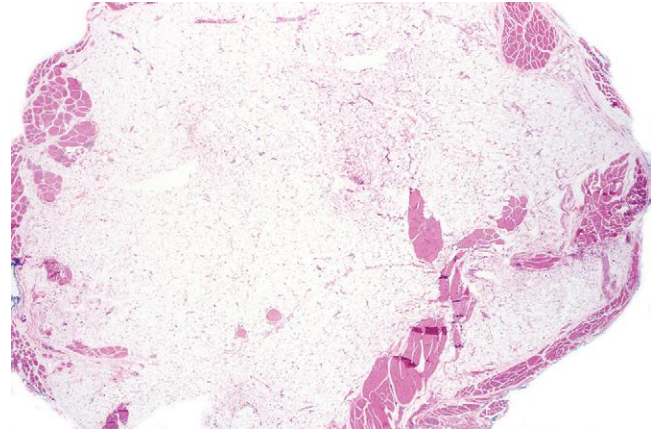
#### REFERENCES

- Billings SD, Henley JD, Summerlin DJ, et al. Spindle cell lipoma of the oral cavity. *Am J Dermatopathol.* 2006;28:28-31.
- Dahlen A, Debiec-Rychter M, Pedoutour F, et al. Clustering of deletions on chromosome 13 in benign and low-malignant lipomatous tumors. *Int J Cancer.* 2003;103:616-623.
- Epivatianos A, Markopoulos AK, Papanayotou P. Benign tumors of adipose tissue of the oral cavity: a clinicopathologic study of 13 cases. *J Oral Maxillofac Surg.* 2000;58:1113-1117; discussion 1118.
- Fanburg-Smith JC, Furlong MA, Childers EL. Liposarcoma of the oral and salivary gland region: a clinicopathologic study of 18 cases with emphasis on specific sites, morphologic subtypes, and clinical outcome. *Mod Pathol.* 2002;15:1020-1031.
- Fregnani ER, Pires FR, Falzoni R, et al. Lipomas of the oral cavity: clinical findings, histological classification and proliferative activity of 46 cases. *Int J Oral Maxillofac Surg.* 2003;32:49-53.
- Furlong MA, Fanburg-Smith JC, Childers EL. Lipoma of the oral and maxillofacial region: site and subclassification of 125 cases. *Oral Surg Oral Med Oral Pathol Oral Radiol Endod.* 2004;98:441-450.
- Juliasse LE, Nonaka CF, Pinto LP, et al. Lipomas of the oral cavity: clinical and histopathologic study of 41 cases in a Brazilian population. *Eur Arch Otorhinolaryngol.* 2010;267:459-465.
- Laco J, Mentzel T, Hornychova H, et al. Atypical lipomatous tumors of the tongue: report of six cases. *Virchows Arch.* 2009;455:383-388.
- Manor E, Sion-Vardy N, Joshua BZ, Bodner L. Oral lipoma: analysis of 58 new cases and review of the literature. *Ann Diagn Pathol.* 2011;15:257-261.
- Nascimento AF, McMenamin ME, Fletcher CD. Liposarcomas/atypical lipomatous tumors of the oral cavity: a clinicopathologic study of 23 cases. *Ann Diagn Pathol.* 2002;6:83-93.
- Rubin BP, Dal Cin P. The genetics of lipomatous tumors. *Semin Diagn Pathol.* 2001;18:286-293.
- Sirvent N, Coindre JM, Maire G, et al. Detection of MDM2-CDK4 amplification by fluorescence in situ hybridization in 200 paraffin-embedded tumor samples: utility in diagnosing adipocytic lesions and comparison with immunohistochemistry and real-time PCR. *Am J Surg Pathol.* 2007;31:1476-1489.

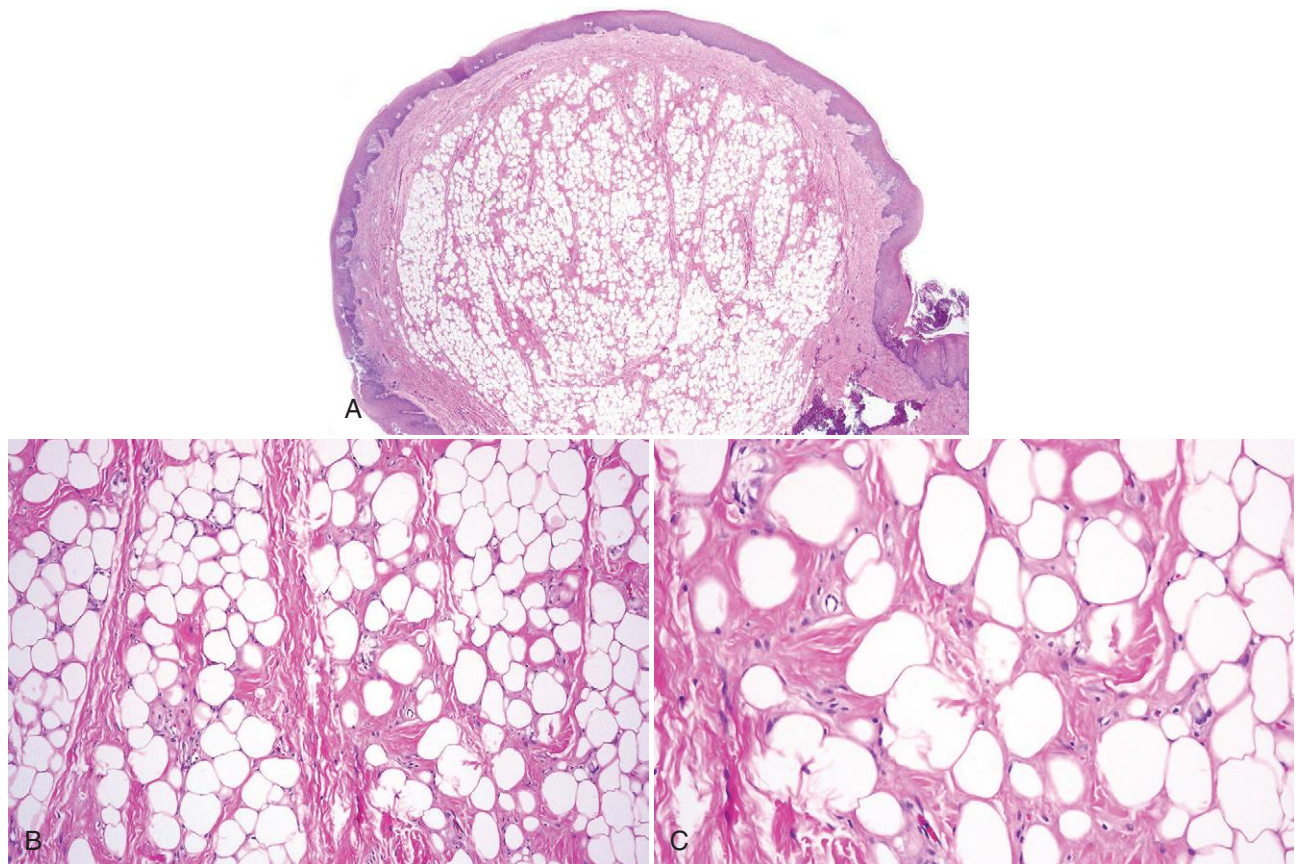




**FIGURE 5-46.** Lipoma of left soft palate.

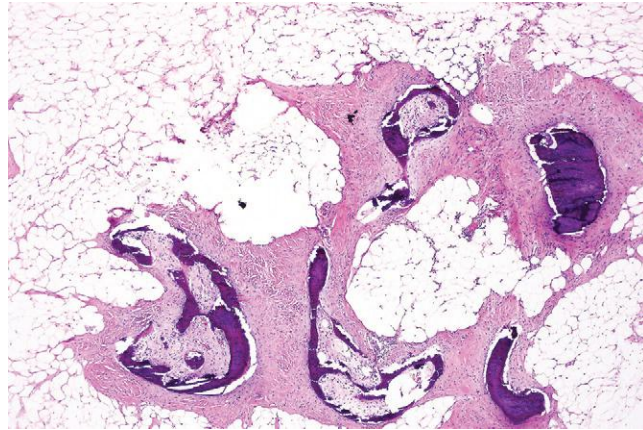


**FIGURE 5-47.** Herniation of buccal fat pad showing mature lipocytes with interspersed muscle fibers.

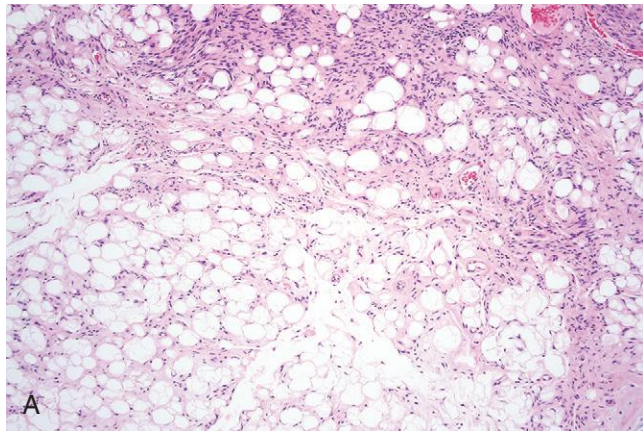


**FIGURE 5-48.** Lipoma. **A**, Nodule of lipocytes with bands of collagen. **B**, Lipocytes with intervening bands of mature collagen. **C**, Mature lipocytes with uniform lipid vacuoles.

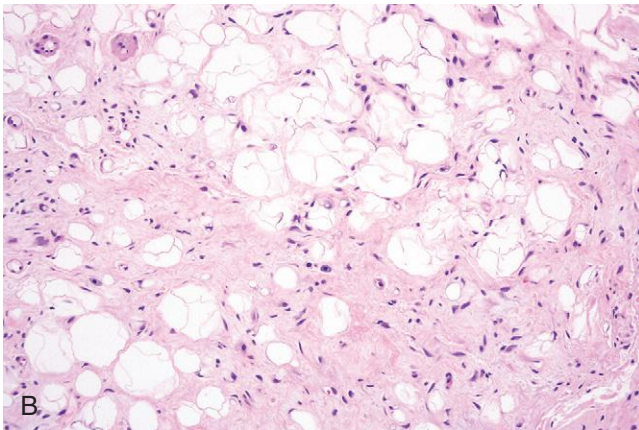




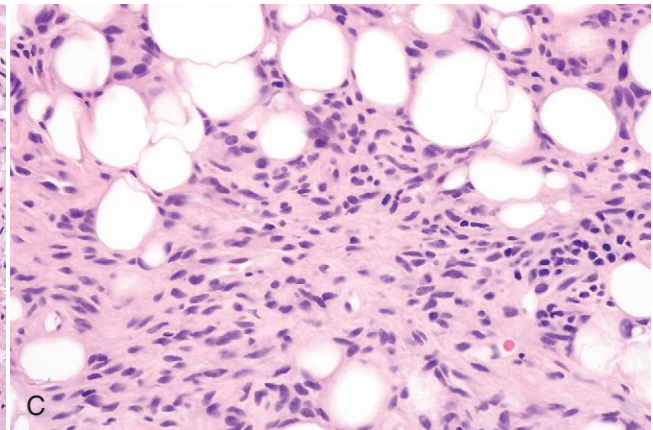
**FIGURE 5-49.** Lipoma with osseous prosoplasia.



A



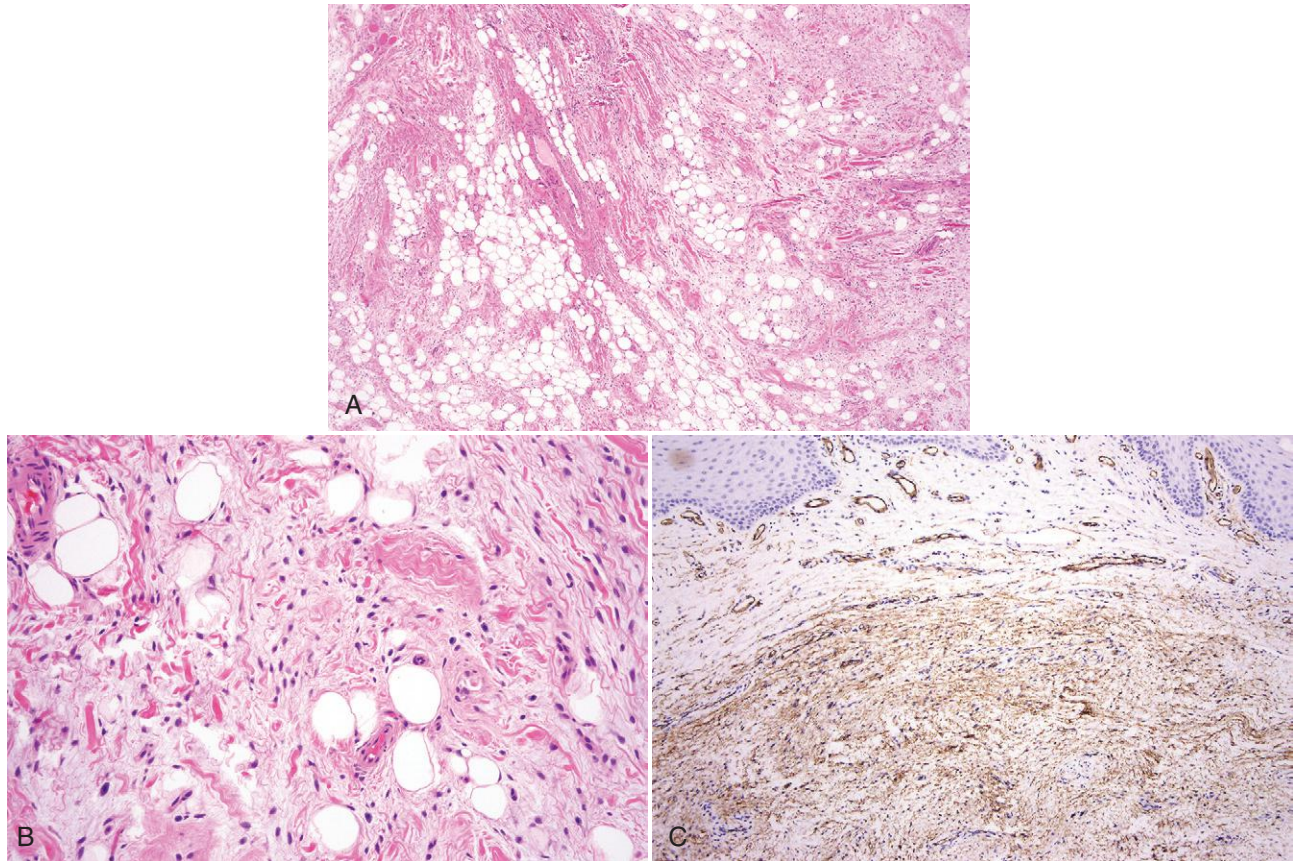
B



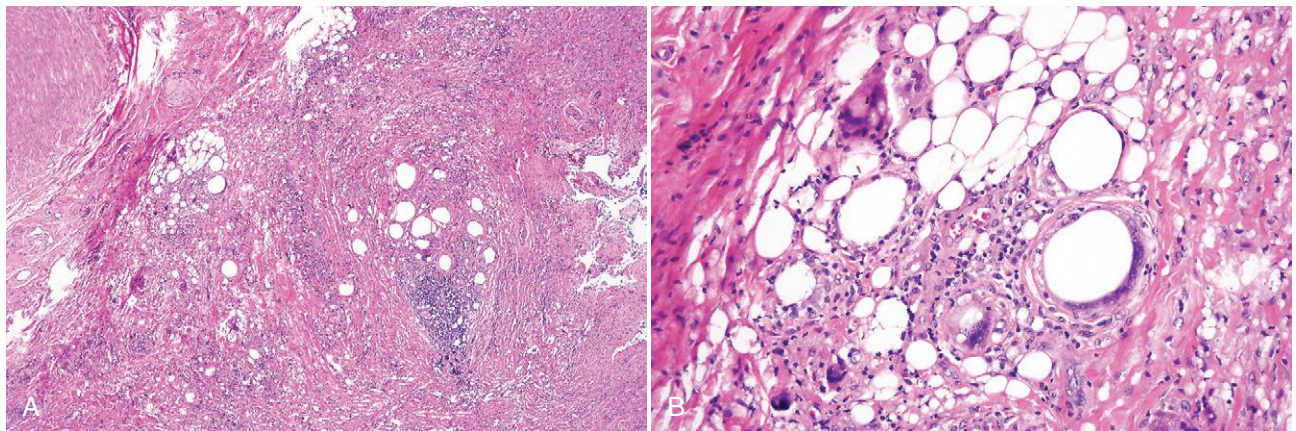
C

**FIGURE 5-50.** Spindle cell lipoma. **A,** Mature lipocytes and spindle cell proliferation. **B,** Mature lipocytes, spindle cells, and mast cells. **C,** Cellular area of spindle cells without atypia.



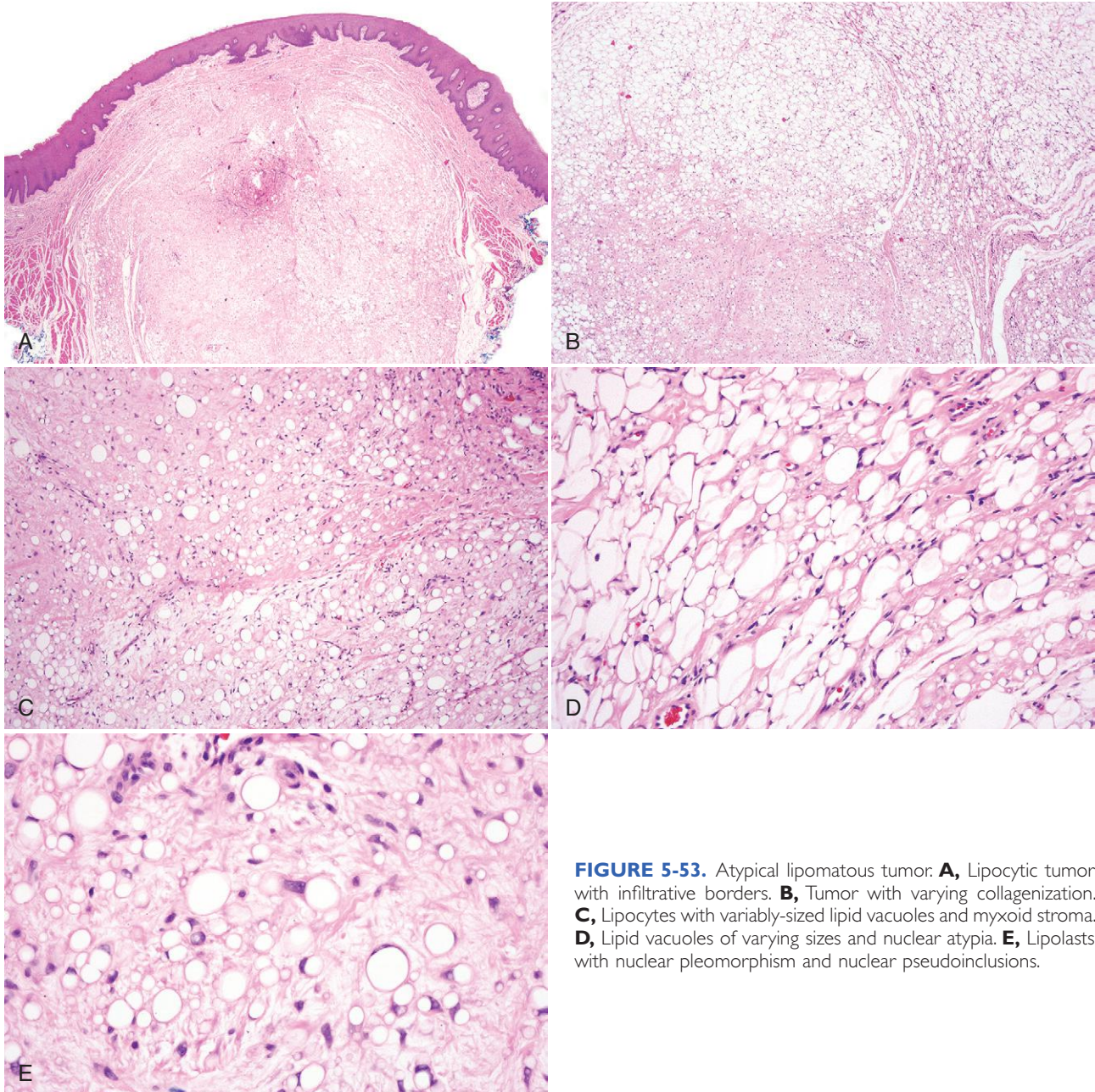


**FIGURE 5-51.** Spindle cell lipoma. **A**, Mixture of mature lipocytes, spindle cells, and dense, ropy collagen. **B**, Mature lipocytes, spindle cells, ropy collagen, and mast cells. **C**, Cells are CD34 positive.



**FIGURE 5-52.** Lipid degeneration and inflammation. **A**, Lipid vacuoles of varying sizes with fibrosis and chronic inflammation. **B**, Multinucleated giant cells with lipid vacuoles; cells with variably sized lipid vacuoles may be misinterpreted as being malignant.





**FIGURE 5-53.** Atypical lipomatous tumor: **A**, Lipocytic tumor with infiltrative borders. **B**, Tumor with varying collagenization. **C**, Lipocytes with variably-sized lipid vacuoles and myxoid stroma. **D**, Lipid vacuoles of varying sizes and nuclear atypia. **E**, Lipolasts with nuclear pleomorphism and nuclear pseudoinclusions.

## Other Uncommon Tumors

### MYOFIBROMA

Solitary myofibroma is more common than myofibromatosis (multifocal disease).

#### Clinical Findings

- *Myofibromas* are most frequent in first to third decades, often involving the tongue and buccal mucosa; one third are intraosseous (Fig. 5-54).
- *Myofibromatosis* is most frequent in the first and second year of life with 75% of cases being congenital.

- Both present as rubbery masses with or without ulceration.

#### Etiopathogenesis and Histopathologic Features

Neoplastic proliferation of spindle cells with myofibroblastic and fibroblastic differentiation; histology of both is similar.

- Nonencapsulated, often infiltrative proliferation of short fascicles of spindle cells with abundant pale pink cytoplasm, fusiform nuclei, sometimes grooved, with small nucleoli; perinuclear vacuoles often seen; dilated irregular blood vessels in a “hemangiopericytoma-like” pattern (Fig. 5-55, A-C); may see zoning with alternating layers of pale spindle cells and more cellular darker areas containing cells



with less cytoplasm; stroma is slightly chondroid/mucinous (see Fig. 5-55, D); may be slightly nodular; degenerative changes or necrosis and myxoid change in up to 60% of cases

- Positive staining for vimentin, smooth muscle actin, muscle-specific actin; negative for S-100 protein, h-caldesmon, and CD34 (see Fig. 5-55, E)

#### Differential Diagnosis

- Fibromatosis (extraabdominal desmoid tumor) is more uniform in appearance, with long sweeping fascicles, is more densely collagenized, and almost always is beta-catenin positive.
- Leiomyoma may be difficult to distinguish from myofibroma; vascularity is not as prominent, although vascular leiomyomas generally have a central vessel; low-grade leiomyosarcoma shows more atypia.
- Nodular fasciitis is infiltrative and typically has “tissue culture” appearance with feathery myofibroblasts and often inflammatory cells and multinucleated giant cells; normal mitoses are often present; spindle cells are positive for smooth muscle actin (Fig. 5-56); some reports suggest that these are true neoplasms, and some cases show abnormalities in chromosomes 3 and 15 and t(2;15).
- Tumors of neural origin are positive for S-100 protein, and cells are smaller with curvilinear nuclei.

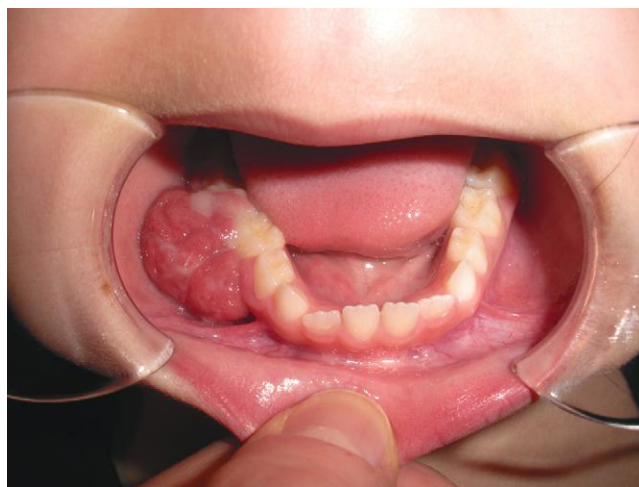- Solitary fibrous tumor has hypercellular and hypocellular areas and is S-100 protein positive; the sclerotic form is densely collagenized.

#### Management and Prognosis

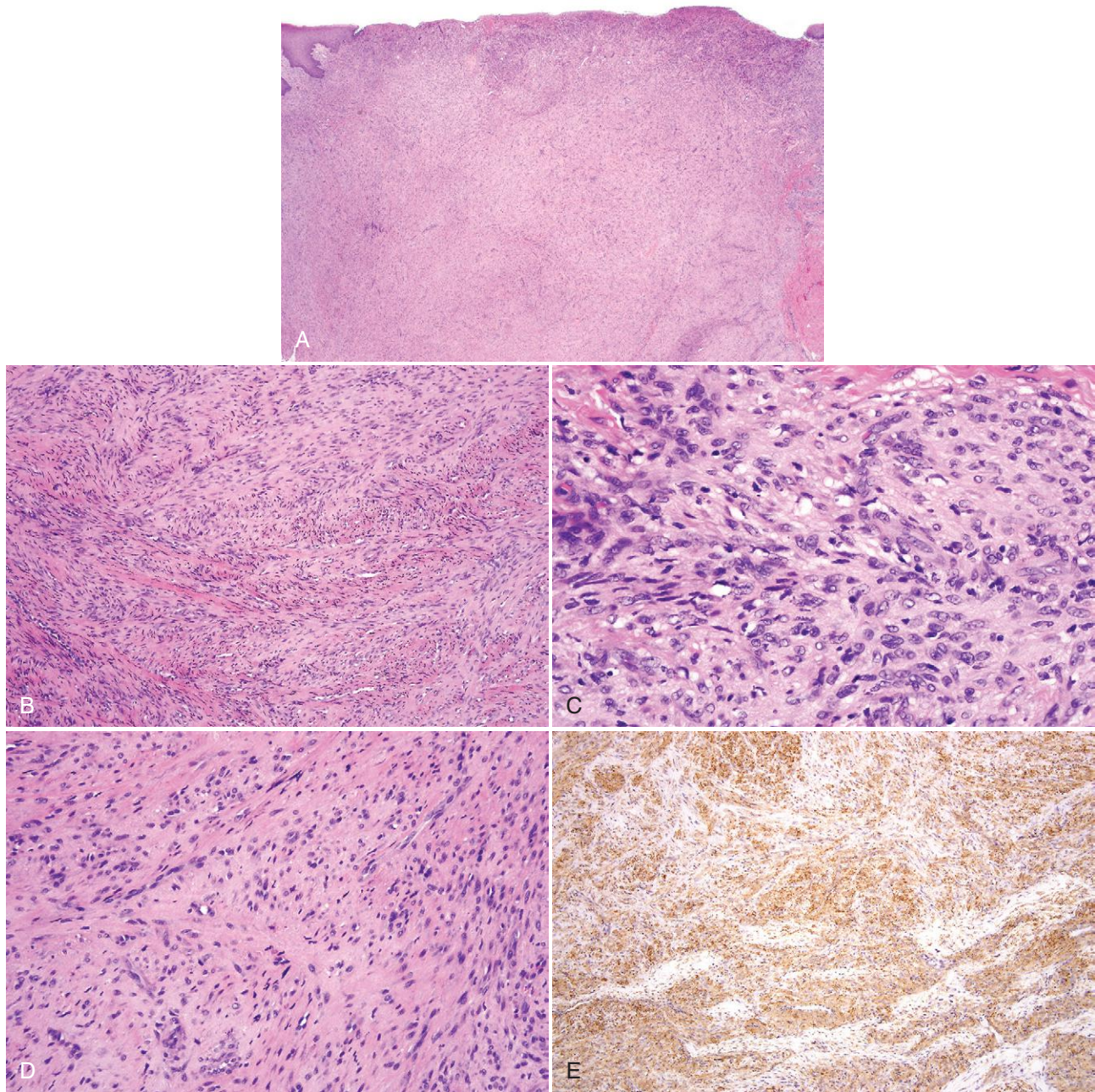
- Wide surgical excision is treatment of choice; approximately 15% to 30% of myofibromas recur and reports of clinical tumor regression are unusual; one third of myofibromatosis may show regression.

#### REFERENCES

- Beck JC, Devaney KO, Weatherly RA, et al. Pediatric myofibromatosis of the head and neck. *Arch Otolaryngol Head Neck Surg.* 1999;125:39-44.
- Dayan D, Nasrallah V, Vered M. Clinico-pathologic correlations of myofibroblastic tumors of the oral cavity: I. Nodular fasciitis. *J Oral Pathol Med.* 2005;34:426-435.
- Foss RD, Ellis GL. Myofibromas and myofibromatosis of the oral region: a clinicopathologic analysis of 79 cases. *Oral Surg Oral Med Oral Pathol Oral Radiol Endod.* 2000;89:57-65.
- Jones AC, Freedman PD, Kerpel SM. Oral myofibromas: a report of 13 cases and review of the literature. *J Oral Maxillofac Surg.* 1994;52:870-875.
- Montgomery E, Speight PM, Fisher C. Myofibromas presenting in the oral cavity: a series of 9 cases. *Oral Surg Oral Med Oral Pathol Oral Radiol Endod.* 2000;89:343-348.
- Vered M, Allon I, Buchner A, Dayan D. Clinico-pathologic correlations of myofibroblastic tumors of the oral cavity. II. Myofibroma and myofibromatosis of the oral soft tissues. *J Oral Pathol Med.* 2007;36:304-314.
- Weinreb I, Shaw AJ, Perez-Ordóñez B, et al. Nodular fasciitis of the head and neck region: a clinicopathologic description in a series of 30 cases. *J Cutan Pathol.* 2009;36:1168-1173.

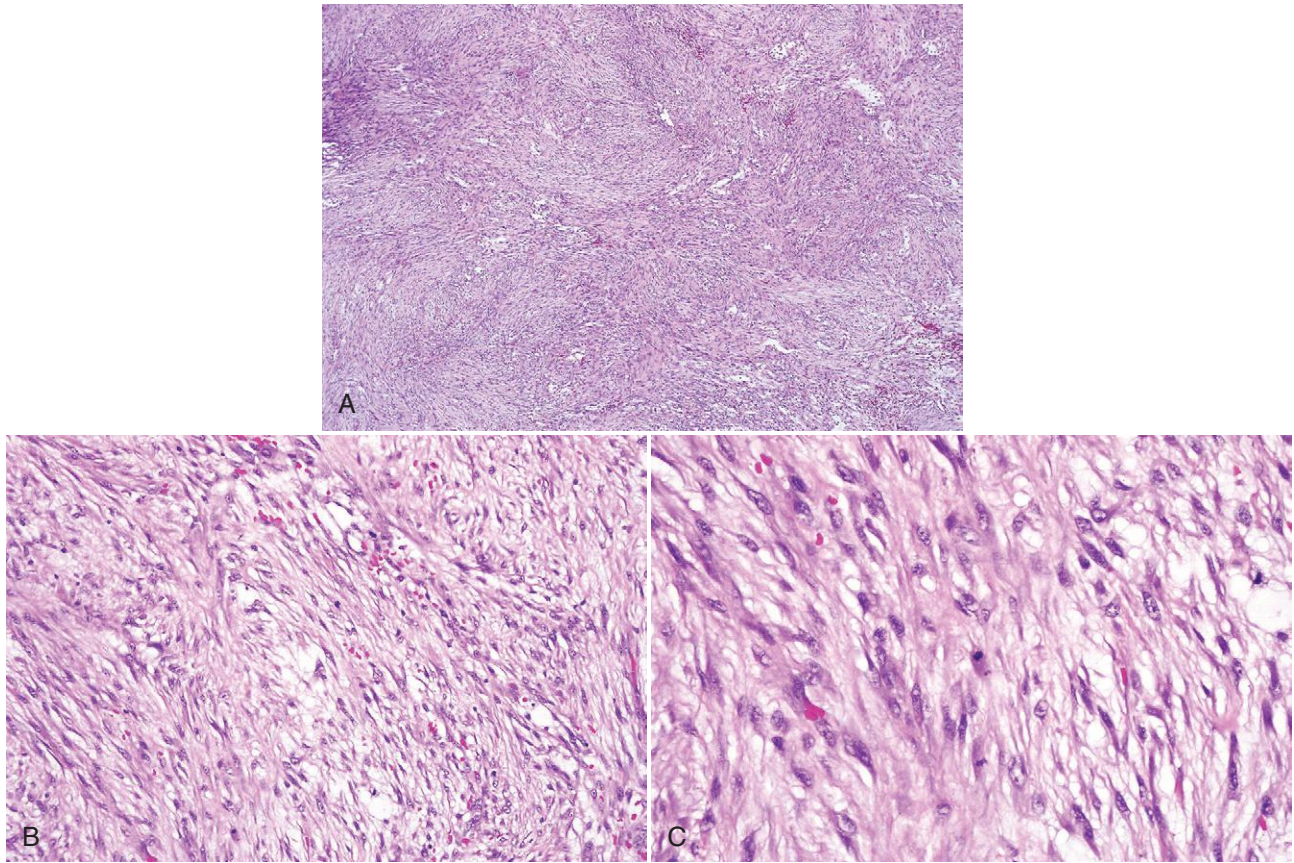


**FIGURE 5-54.** Myofibroma of the right mandibular sulcus. (Courtesy of Dr. Bonnie Padwa, Harvard School of Dental Medicine, Boston, Mass.)



**FIGURE 5-55.** Myofibroma. **A**, Spindle cell proliferation with overlying ulceration. **B**, Tumor forms short fascicles. **C**, Hypercellular areas; spindle cells have benign nuclei. **D**, Less cellular areas with stroma appearing chondroid. **E**, Cells are positive for smooth muscle actin.





**FIGURE 5-56.** Nodular fasciitis. **A**, Cellular proliferation of spindled myofibroblasts with chronic inflammation and fresh hemorrhage. **B**, Fasciculated arrangement of myofibroblasts with a “feathery” appearance and many mitotic figures. **C**, Cells show slight variation in shape and size (reactive atypia), and normal mitoses are frequent.

## Tumors of Uncertain Histogenesis

### ECTOMESENCHYMAL CHONDROMYXOID TUMOR OF THE TONGUE

#### Clinical Findings

- Firm nodule on the dorsum tongue in adults, usually in the fourth decade

#### Etiopathogenesis and Histopathologic Features

It is uncertain what tissue these tumors attempt to recapitulate, although some believe that it may represent an unusual myoepithelioma.

- Circumscribed but not encapsulated lobular proliferation of epithelioid, stellate, and spindle cells in

a chondromyxoid stroma with tissue clefts (Figs. 5-57 and 5-58, *A, B*); pattern may be pseudocystic, reticular, or solid (see Fig. 5-58, *C-E*); cells have moderate eosinophilic cytoplasm and ovoid-to-round nuclei with dispersed chromatin and inconspicuous nucleoli, although nuclear pseudoinclusions, binucleation, and slight atypia may be seen (see Figs. 5-57, *C*, and 5-58, *F*); ductlike structures are not seen; muscle entrapment is a common finding (see Fig. 5-57, *D*).

- Consistent cytoplasmic positivity for glial fibrillary acidic protein (GFAP), S-100 protein, and vimentin; cytokeratin (AE1/3), CD57, and smooth muscle actin positive in 40% to 75% of cases; generally weak or negative for desmin and epithelial membrane antigen (EMA); negative for myoepithelial markers such as calponin, p63, and smooth muscle myosin heavy chain.



### Differential Diagnosis

- Myoepithelioma, soft tissue or otherwise, usually shows positivity for calponin, p63, and smooth muscle myosin heavy chain.
- Pleomorphic adenoma contains ductlike structures and is positive for myoepithelial markers.

### Management and Prognosis

- Excision is usually curative; recurrence is possible if margins are involved.

### REFERENCES

Allen CM. The ectomesenchymal chondromyxoid tumor: a review. *Oral Dis.* 2008;14:390-395.

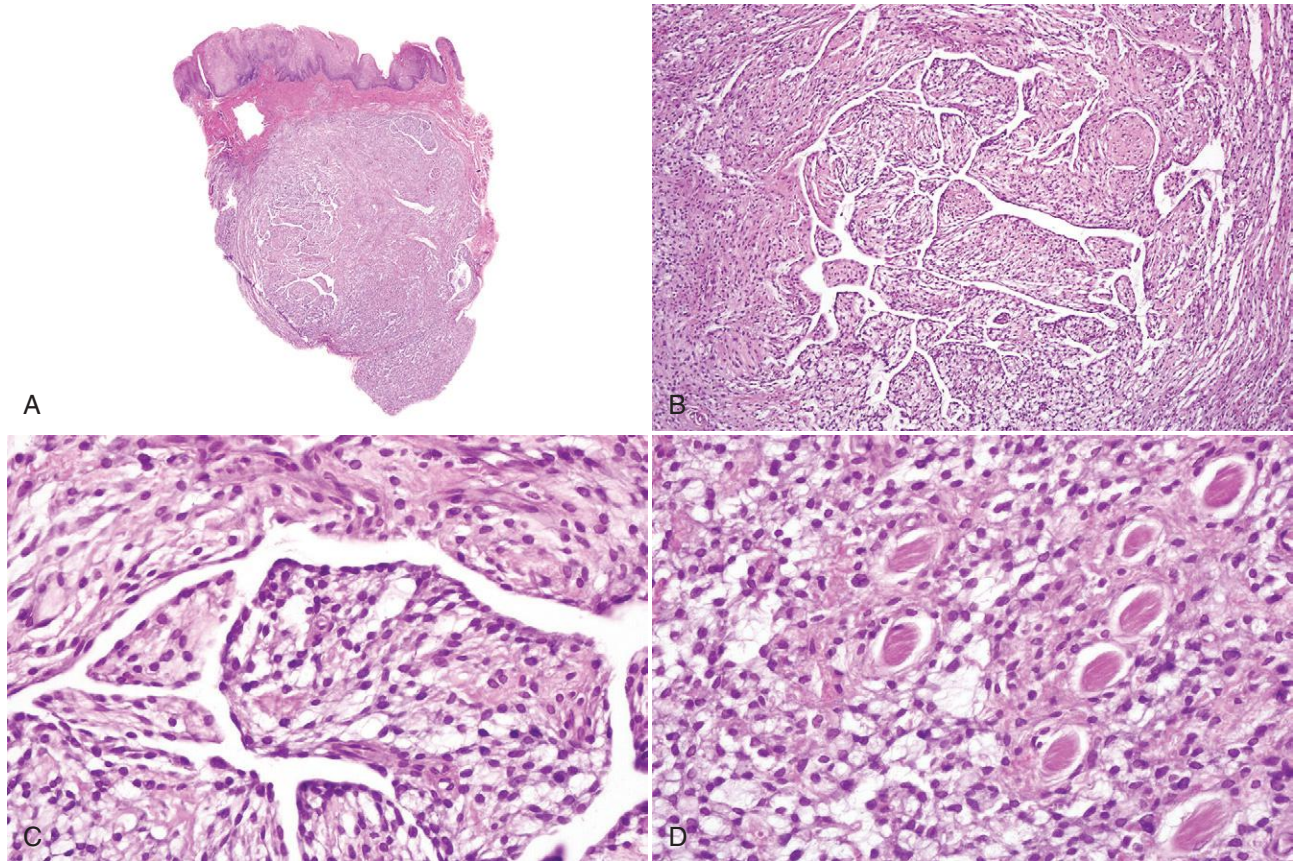
Angiero F. Ectomesenchymal chondromyxoid tumour of the tongue. A review of histological and immunohistochemical features. *Anti-cancer Res.* 2010;30:4685-4689.

Hornick JL, Fletcher CD. Cutaneous myoepithelioma: a clinicopathologic and immunohistochemical study of 14 cases. *Hum Pathol.* 2004;35:14-24.

Seo SH, Shin DH, Kang HJ, et al. Reticulated myxoid tumor of the tongue: 2 cases supporting an expanded clinical and immunophenotypic spectrum of ectomesenchymal chondromyxoid tumor of the tongue. *Am J Dermatopathol.* 2010;32:660-664.

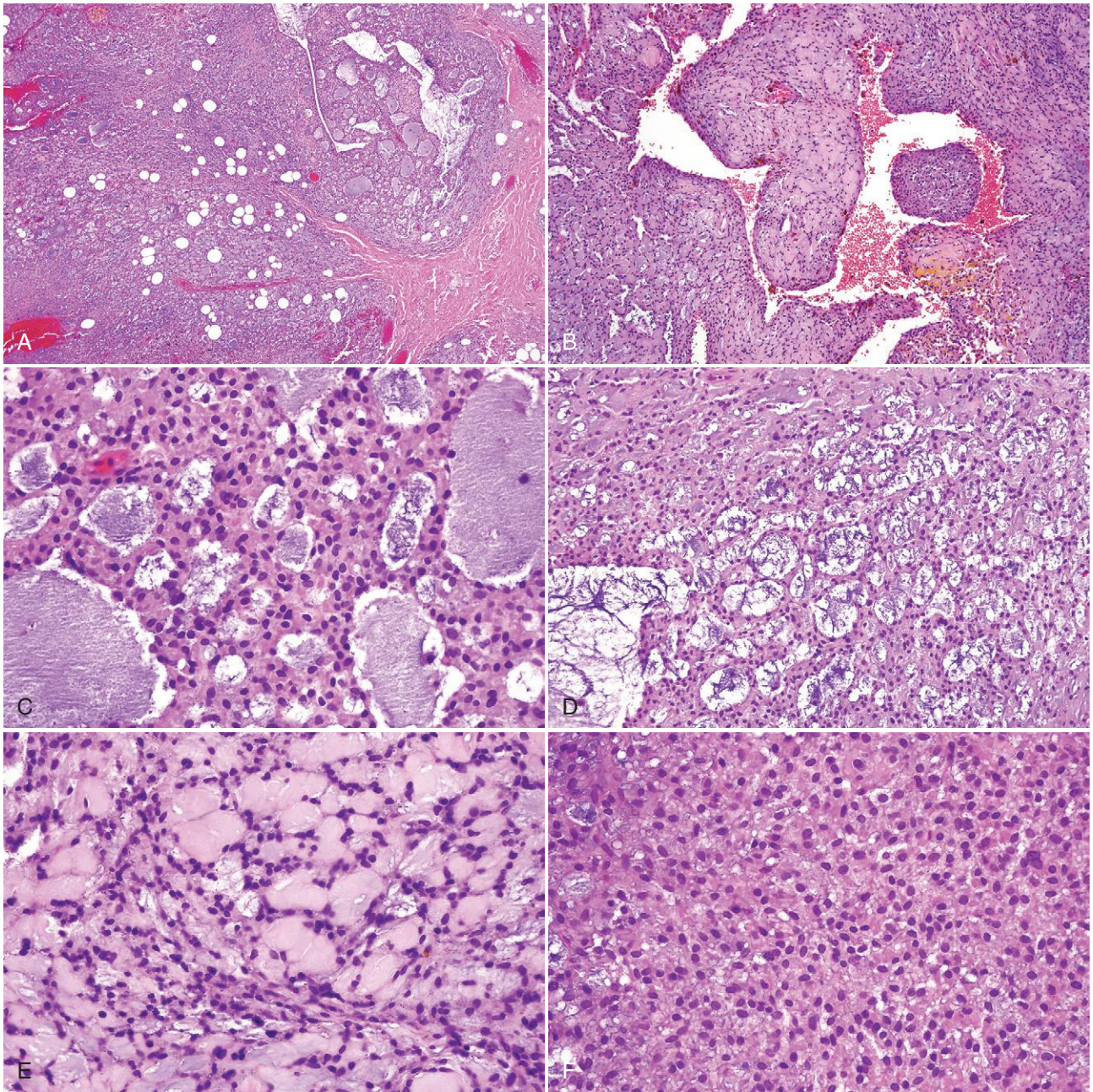
Smith BC, Ellis GL, Meis-Kindblom JM, Williams SB. Ectomesenchymal chondromyxoid tumor of the anterior tongue. Nineteen cases of a new clinicopathologic entity. *Am J Surg Pathol.* 1995;19:519-530.

Woo VL, Angiero F, Fantasia JE. Myoepithelioma of the tongue. *Oral Surg Oral Med Oral Pathol Oral Radiol Endod.* 2005;99:581-589.



**FIGURE 5-57.** Ectomesenchymal chondromyxoid tumor of the tongue. **A**, Nodule in the deep mucosa. **B**, Proliferation of spindle and epithelioid cells within myxochondroid stroma with tissue clefts. **C**, Spindle and epithelioid cells with bland nuclei. **D**, Tumor cells surround muscle fibers.





**FIGURE 5-58.** Ectomesenchymal chondromyxoid tumor of the tongue. **A**, Lobules of tumor with pseudocystic pattern. **B**, Chondromyxoid stroma with tissue clefting. **C**, Microcystic pattern showing epithelioid cells with abundant eosinophilic cytoplasm and bland nuclei. **D**, Epithelioid cells with slight nuclear atypia in a reticular pattern with myxoid stroma. **E**, Epithelioid cells in hyaline/chondroid stroma. **F**, Solid area of tumor with epithelioid cells that exhibit benign cytology.



## SOLITARY FIBROUS TUMOR

### Clinical Findings

- Adults in the sixth decade; most common sites buccal mucosa, maxillary or mandibular sulcus, lip, and tongue (Fig. 5-59)

### Etiopathogenesis and Histopathologic Features

Solitary fibrous tumor for the most part replaces the old term *hemangiopericytoma*; differentiation is toward a spindle cell that is CD34 positive.

- Circumscribed, sometimes encapsulated mass of spindle and ovoid cells with two patterns: classic pattern—small and large stag-horn vessels with proliferation of spindle cells in either hyalinized or myxoid stroma, characteristically with hypercellular and hypocellular areas (Fig. 5-60); sclerotic pattern—dense, sclerotic, and hyalinized collagen with only subtle and focal classic features; cells have indistinct cell borders and benign nuclei with small, inconspicuous nuclei (Fig. 5-61, A-D); CD34 and sometimes Bcl-2 positive (see Fig. 5-61, E); periductal hyalinization seen in salivary gland involvement (Fig. 5-62, A, B)
- Multinucleated tumor giant cells, mature lipocytes, and lymphocytes are present (see Fig. 5-62, C); presence of lipoblasts should prompt careful search for evidence of malignancy.
- Dedifferentiation leads to anaplasia and loss of CD34 positivity

### Differential Diagnosis

- Nerve sheath tumors have curvilinear nuclei and are S-100 positive although some ancient schwannomas may show similar dense and delicate collagenization.

nnomas may show similar dense and delicate collagenization.

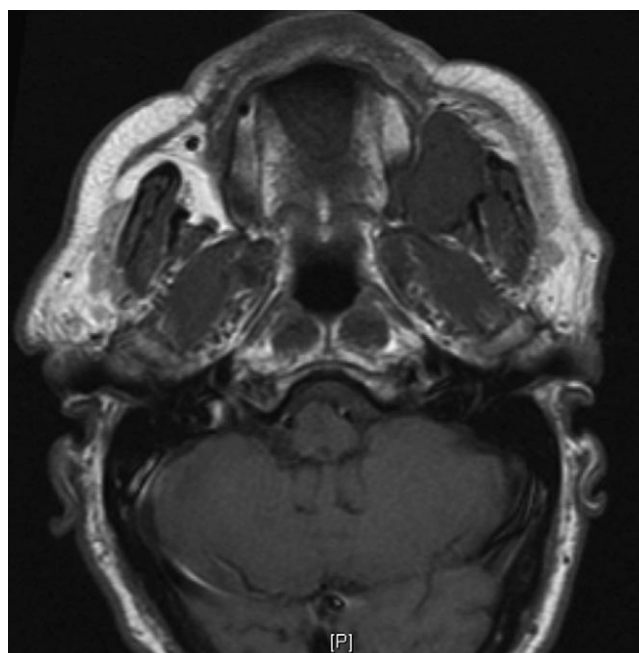
- Vascular neoplasms show a proliferation of spindle or epithelioid endothelial cells that form vessels with cytoplasmic positivity for CD31; intracellular lumina are not present in solitary fibrous tumor.
- Sclerotic fibroma and desmoid tumor are uniformly sclerotic and hyalinized with little areas of hypercellularity.
- Myopericytoma has CD34-positive endothelial cells, whereas the perivascular spindle cell proliferation is positive for smooth muscle actin.

### Management and Prognosis

- Excision is curative and recurrence is rare.

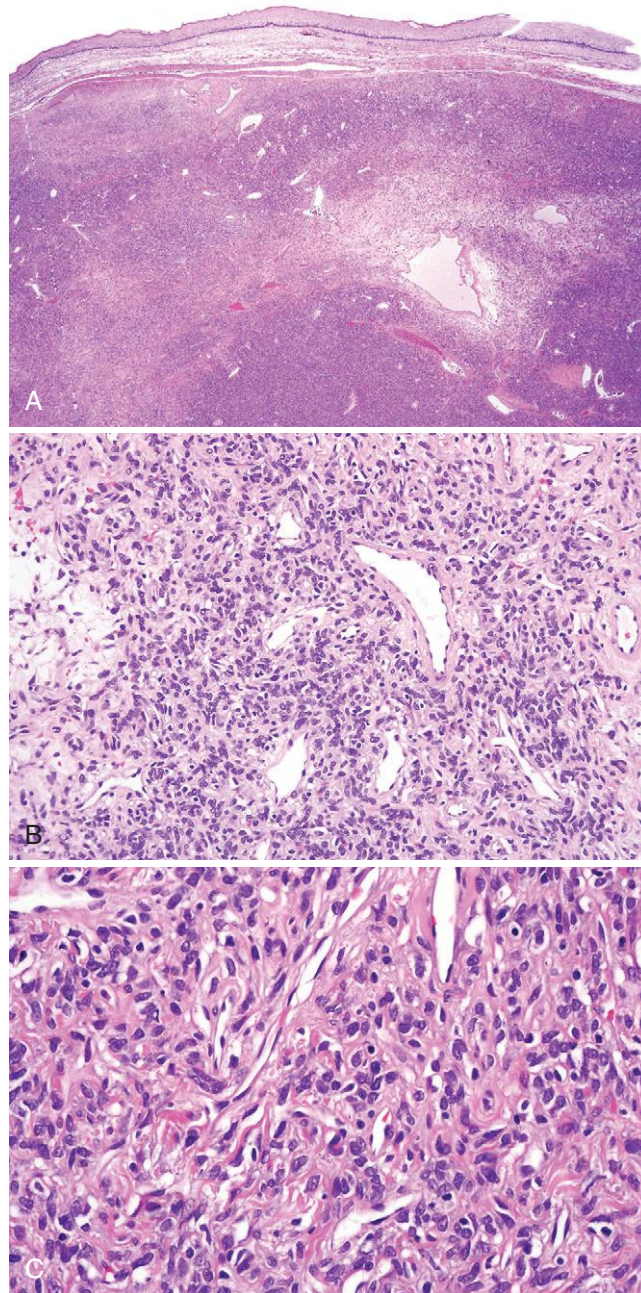
### REFERENCES

- Alawi F, Stratton D, Freedman PD. Solitary fibrous tumor of the oral soft tissues: a clinicopathologic and immunohistochemical study of 16 cases. *Am J Surg Pathol.* 2001;25:900-910.
- Chan JK. Solitary fibrous tumour—everywhere, and a diagnosis in vogue. *Histopathology.* 1997;31:568-576.
- Ganly I, Patel SG, Stambuk HE, et al. Solitary fibrous tumors of the head and neck: a clinicopathologic and radiologic review. *Arch Otolaryngol Head Neck Surg.* 2006;132:517-525.
- Ide F, Mishima K, Yamada H, et al. Perivascular myoid tumors of the oral region: a clinicopathologic re-evaluation of 35 cases. *J Oral Pathol Med.* 2008;37:43-49.
- Lee JC, Fletcher CD. Malignant fat-forming solitary fibrous tumor (so-called “lipomatous hemangiopericytoma”: clinicopathologic analysis of 14 cases. *Am J Surg Pathol.* 2011;35:1177-1185.
- Mosquera JM, Fletcher CD. Expanding the spectrum of malignant progression in solitary fibrous tumors: a study of 8 cases with a discrete anaplastic component—is this dedifferentiated SFT? *Am J Surg Pathol.* 2009;33:1314-1321.
- O'Regan EM, Vanguri V, Allen CM, et al. Solitary fibrous tumor of the oral cavity: clinicopathologic and immunohistochemical study of 21 cases. *Head Neck Pathol.* 2009;3:106-115.



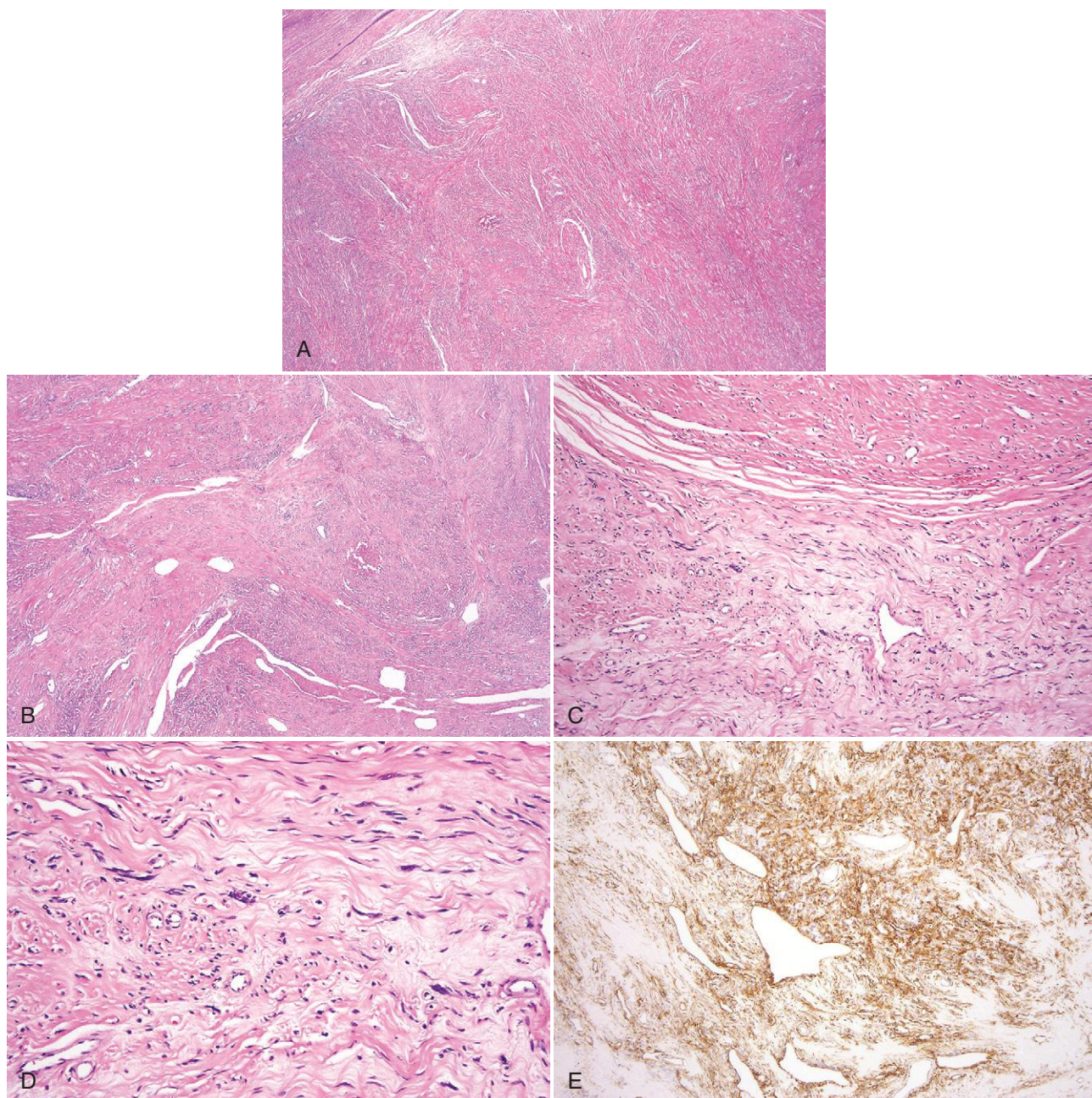
**FIGURE 5-59.** Solitary fibrous tumor: Magnetic resonance imaging showing mass of the left infratemporal fossa.





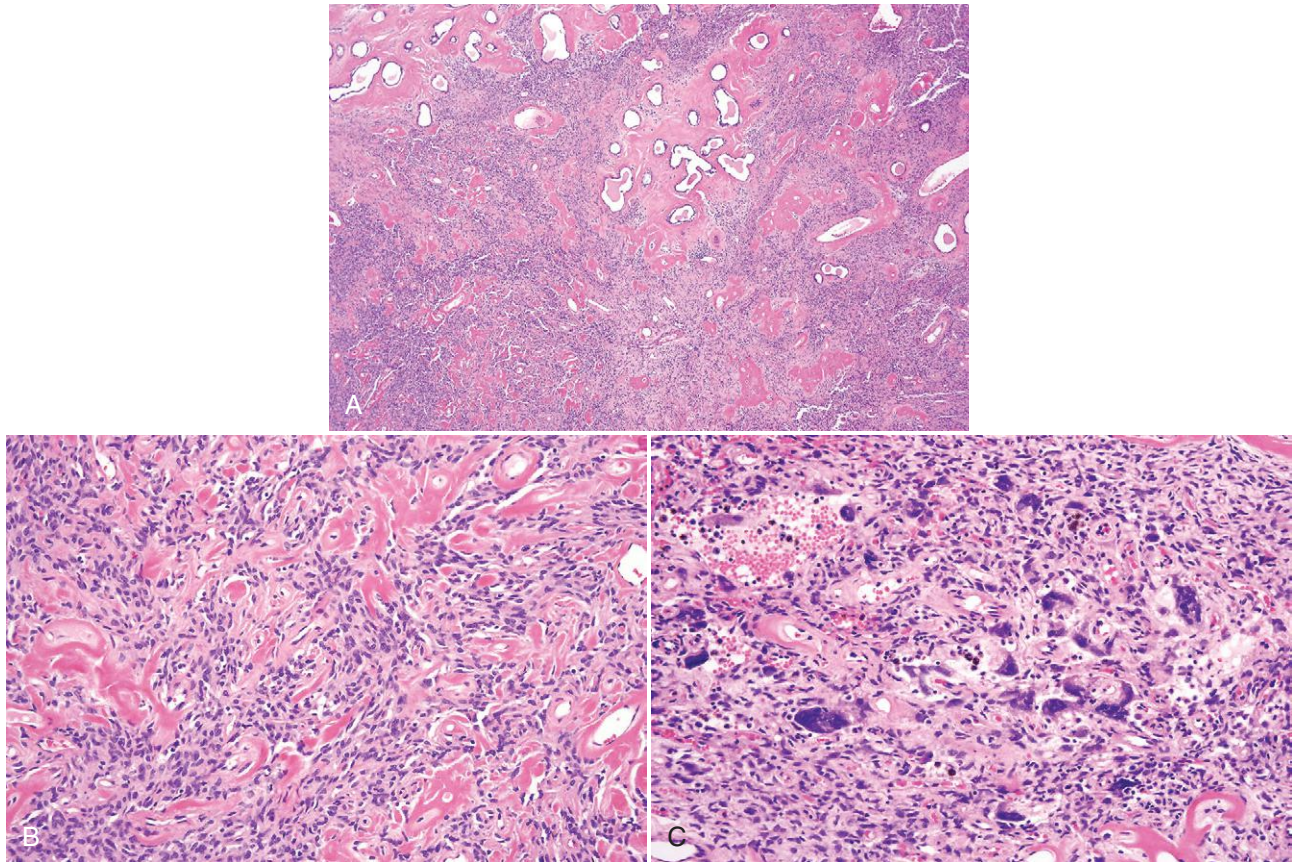
**FIGURE 5-60.** Solitary fibrous tumor, classic type. **A**, Spindle cell proliferation with hypercellular and hypocellular areas and stag-horn vessels. **B**, Dilated vessels surrounded by plump, spindle cells. **C**, Spindle cells with plump round-to-ovoid benign nuclei.





**FIGURE 5-61.** Solitary fibrous tumor; sclerotic type. **A**, Mass of densely collagenized fibrous tissue. **B**, Focal areas of increased cellularity and vascularity. **C**, Densely collagenized and hyalinized fibrous tissue (top) juxtaposed against myxoid and vascular areas. **D**, Some spindle cells have pleomorphic nuclei. **E**, Cytoplasmic positivity for CD34 in hypercellular areas.





**FIGURE 5-62.** Solitary fibrous tumor. **A**, Spindle cell proliferation with extensive hyalinization especially around salivary ducts. **B**, Spindle cell proliferation with benign nuclei. **C**, Multinucleated tumor cells are not infrequent.

## ORAL FOCAL MUCINOSIS

### Clinical Findings

- Soft, gelatinous nodule of gingiva in adults (fifth decade) (Fig. 5-63)

### Etiopathogenesis and Histopathologic Features

Oral focal mucinosis may be a response to inflammation.

- Nonencapsulated pool(s) of mucinous or myxoid alcianophilic ground substance with scattered S-100–negative spindle and stellate cells and short bands of collagen; reticulin fibers may not be evident (Figs. 5-64 and 5-65).
- Fibrous hyperplasias of the gingiva often show myxoid change; it may be that accumulation of such ground substance results in focal mucinosis.

### Differential Diagnosis

- Soft tissue angiomyxoma, a rare mesenchymal neoplasm in the mouth, is better demarcated and homogeneous with delicate collagen fibers and many dilated vessels; reticulin fibers are present and may be difficult to distinguish from focal mucinosis (Fig. 5-66).

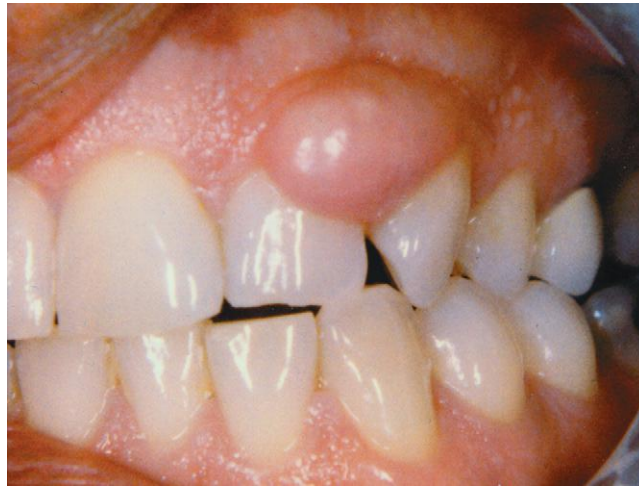- Mucoceles have pools of mucin surrounded by granulation tissue containing muciphages.
- Myxoid neurofibroma and neurothekeoma (usually multilobular) stain for neural markers.
- Superficial angiomyxoma is a rare myxoid tumor that contains numerous blood vessels with occasional CD34-positive spindle cells, and may behave aggressively.

### Management and Prognosis

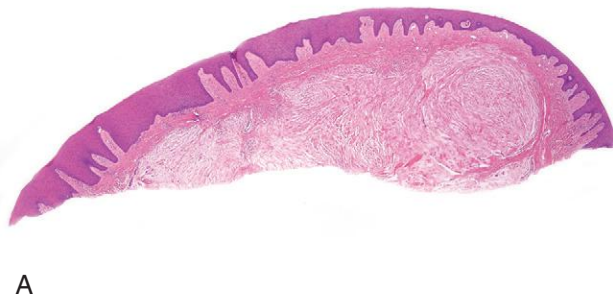- Excision is curative.

### REFERENCES

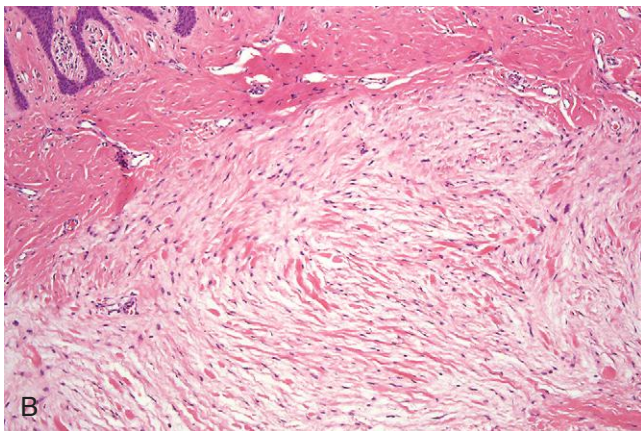
- Aldred MJ, Talacko AA, Ruljancich K, et al. Oral focal mucinosis: report of 15 cases and review of the literature. *Pathology*. 2003;35:393-396.
- Buchner A, Merrell PW, Leider AS, Hansen LS. Oral focal mucinosis. *Int J Oral Maxillofac Surg*. 1990;19:337-340.
- Calonje E, Guerin D, McCormick D, Fletcher CD. Superficial angiomyxoma: clinicopathologic analysis of a series of distinctive but poorly recognized cutaneous tumors with tendency for recurrence. *Am J Surg Pathol*. 1999;23:910-917.
- Epivatianos A, Iordanidis S, Zaraboukas T. Myxoma of the oral soft tissues: report of a case and literature review. *J Oral Maxillofac Surg*. 2007;65:317-320.
- Meer S, Beavon I. Intraoral superficial angiomyxoma. *Oral Surg Oral Med Oral Pathol Oral Radiol Endod*. 2008;106:e20-23.



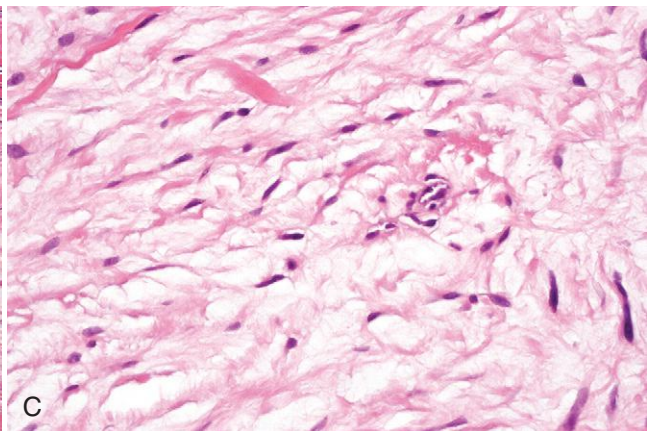
**FIGURE 5-63.** Oral focal mucinosis: soft, gelatinous nodule of gingiva.



A



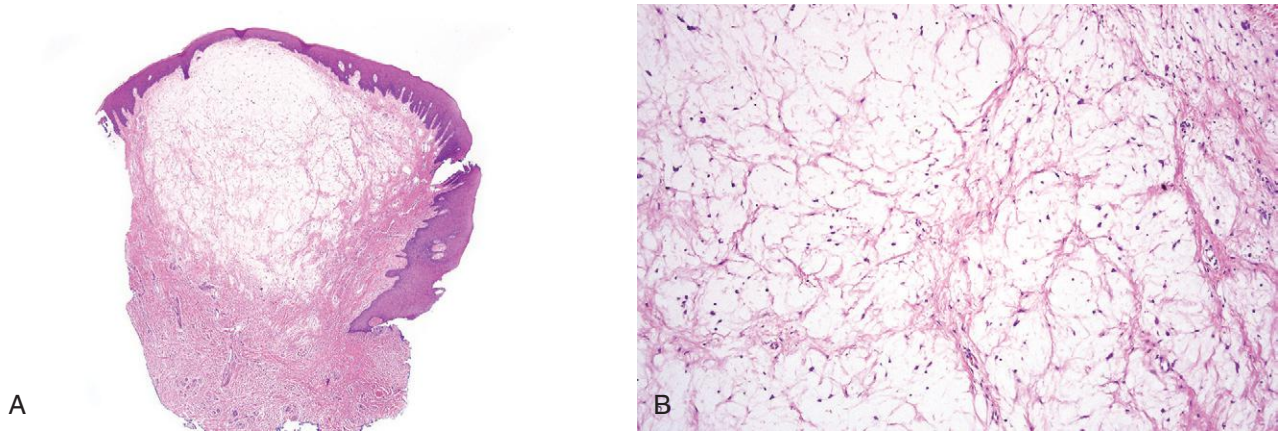
B



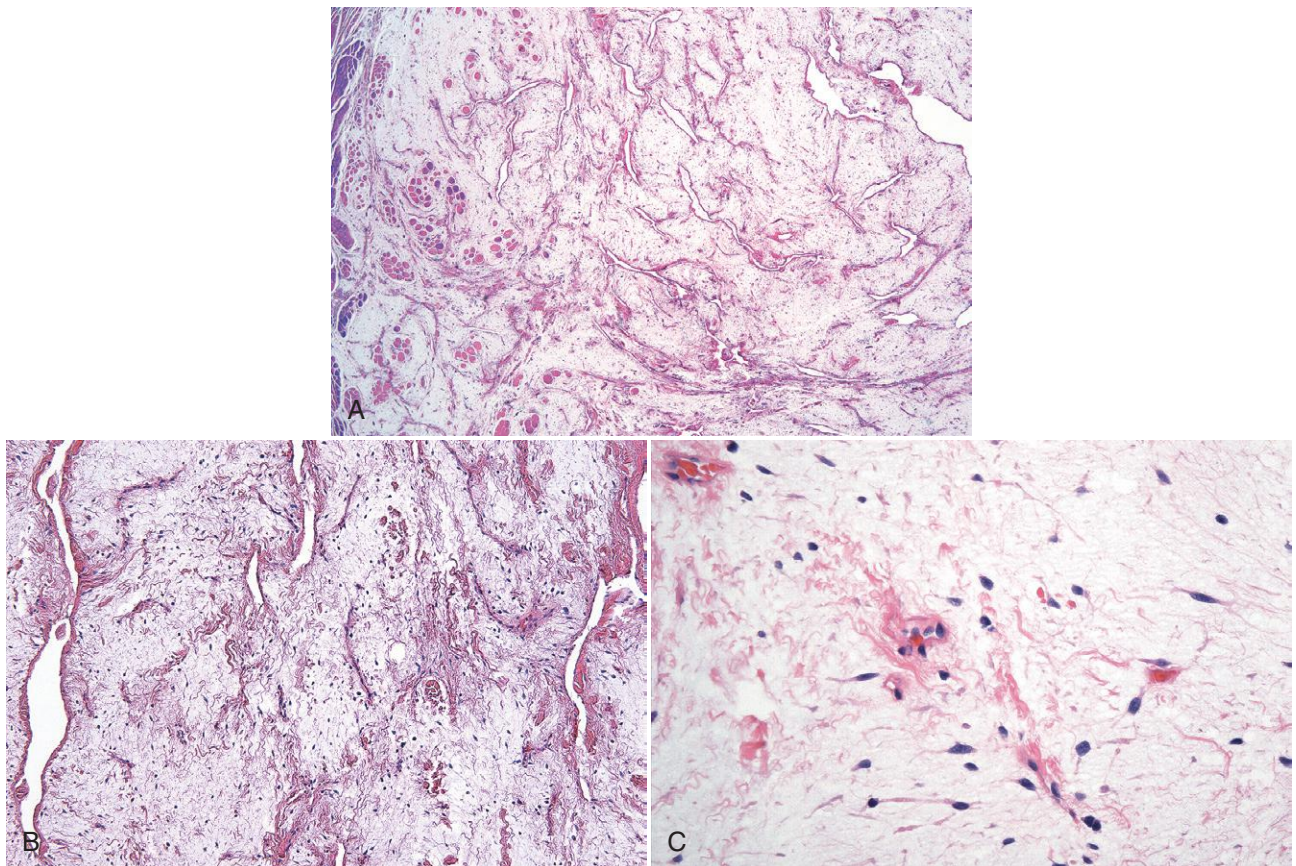
C

**FIGURE 5-64.** A, Oral focal mucinosis of the gingiva. B, Well-circumscribed pool of mucinous material and short bundles of collagen. C, Spindled fibroblasts within myxoid/mucinous stroma.





**FIGURE 5-65.** **A**, Soft tissue myxoma of the buccal mucosa. **B**, Mucinous material separated by thin collagen bands and stellate and spindled cells.



**FIGURE 5-66.** **A**, Soft tissue angiomyxoma of the oral mucosa. **B**, Mucinous material separated by delicate collagen fibers and dilated vessels. **C**, Spindled and stellate fibroblasts in mucinous stroma.

# 6

# VASCULAR, NEURAL, AND MUSCLE TUMORS

## CHAPTER CONTENTS

VASCULAR LESIONS	106
Pyogenic Granuloma	106
Varix (Venous Lake) and Venous Malformation (Venous Anomaly)	109
Caliber-Persistent Labial Artery	114
Kaposi Sarcoma	115
Lymphatic Malformation (Lymphangioma Circumscriptum)	117
NEURAL TUMORS	119
Traumatic Neuroma	119
Neurofibroma	121
Schwannoma	123
Solitary Circumscribed Neuroma (Palisaded Encapsulated Neuroma)	125
Granular Cell Tumor	127
Subgemmal Neurogenous Plaque (Subepithelial Nerve Plexus)	129
MUSCLE TUMORS	131
Leiomyoma and Angioleiomyoma (Vascular Leiomyoma)	131
Adult Rhabdomyoma	134
Embryonal Rhabdomyosarcoma	135

## Vascular Lesions

### PYOGENIC GRANULOMA

#### Clinical Findings

- Purple-to-red nodule or papule, sessile or pedunculated; common on the gingiva (75% of cases [see Chapter 5]), upper lip, and buccal mucosa; there may be a history of bleeding (Fig. 6-1, A and B).
- Patients on cyclosporine after stem cell transplantation develop pyogenic granuloma–like lesions on the buccal mucosa or tongue rather than the gingiva (see Fig. 6-1, C).

#### Etiopathogenesis and Histopathologic Features

Pyogenic granuloma represents a reactive proliferation of endothelial cells and blood vessels.

- Proliferation of endothelial cells and capillaries (often dilated)—sometimes in a lobular pattern, often with overlying ulceration—and acute and chronic inflammation are seen; mitoses are not uncommon (Figs. 6-2 and 6-3).
- Some lesions may show significant reactive atypia with hyperchromatic and pleomorphic nuclei (Fig. 6-4).

- Fibrous ingress signals organization, and lesions may convert to fibromas—especially gingival lesions (Fig. 6-5).

#### Differential Diagnosis

- Edematous polypoid masses seen in patients after stem cell transplantation on cyclosporine are better diagnosed as reactive fibrovascular polyps.

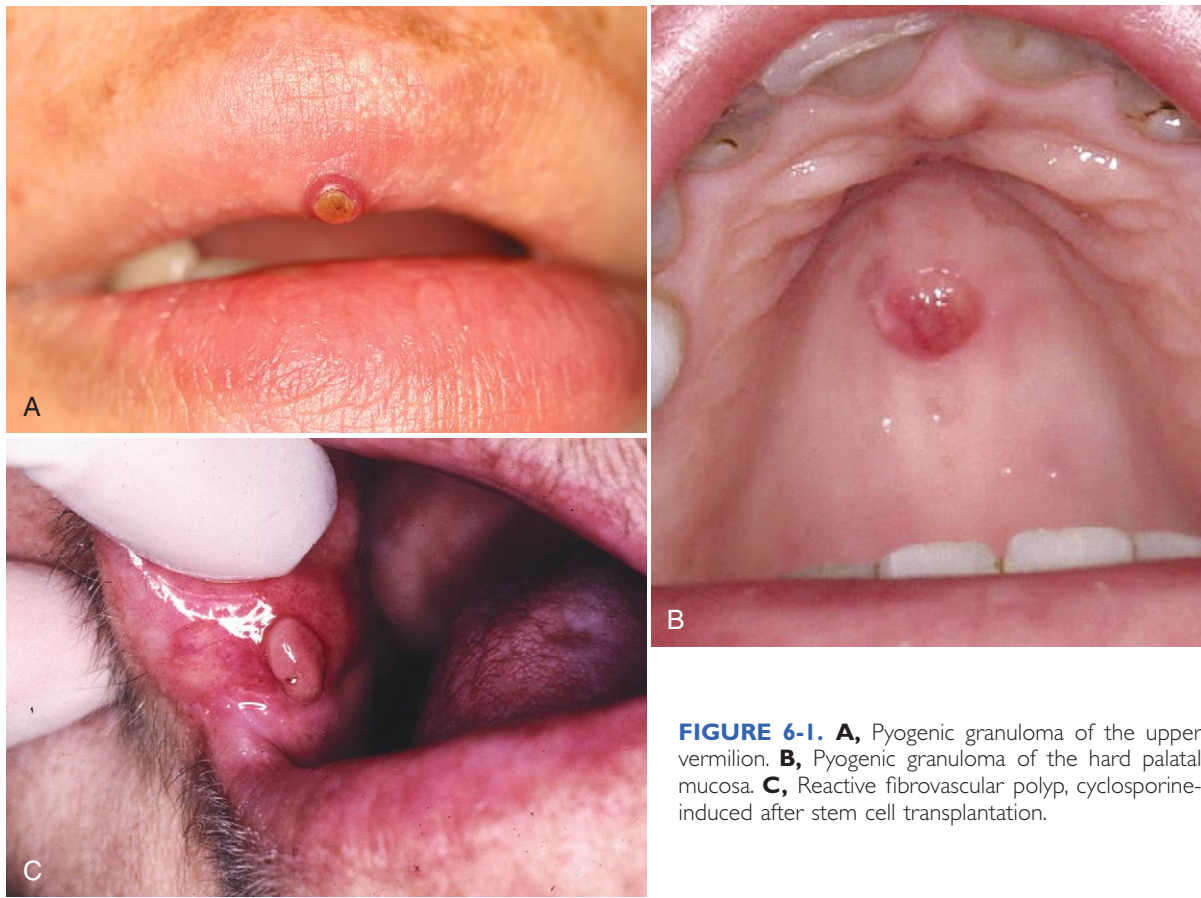
#### Management and Prognosis

- Excision is treatment of choice with recurrence in less than 5% of cases.

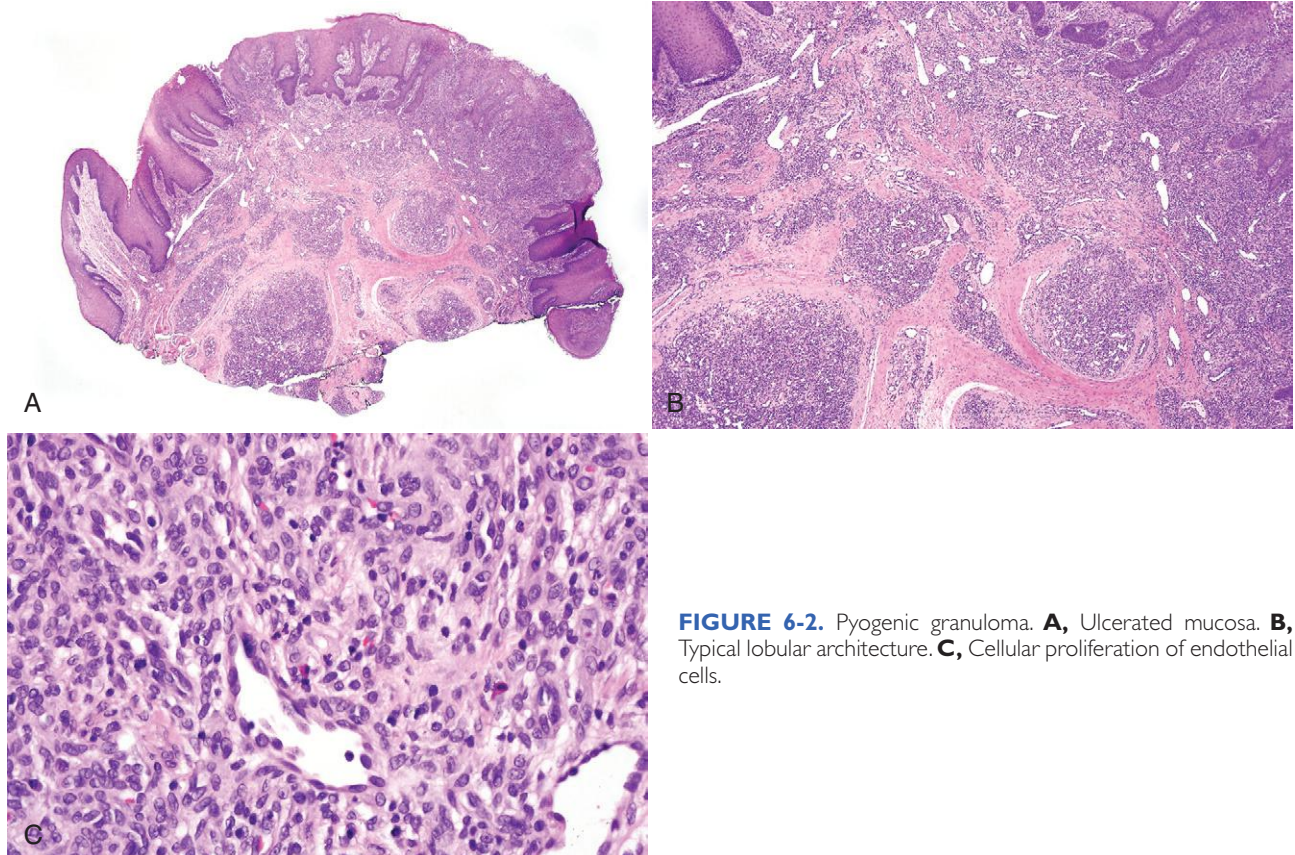
#### REFERENCES

- Fishman SJ, Mulliken JB. Hemangiomas and vascular malformations of infancy and childhood. *Pediatr Clin North Am.* 1993;40:1177-2200.
- Johann AC, Salla JT, Gomez RS, et al. GLUT-1 in oral benign vascular lesions. *Oral Dis.* 2007;13:51-55.
- North PE, Waner M, Mizeracki A, Mihm MC Jr. GLUT1: a newly discovered immunohistochemical marker for juvenile hemangiomas. *Hum Pathol.* 2000;31:11-22.
- Renshaw AA, Rosai J. Benign atypical vascular lesions of the lip. A study of 12 cases. *Am J Surg Pathol.* 1993;17:557-565.
- Woo SB, Allen CM, Orden A, et al. Nongingival soft tissue growths after allogeneic marrow transplantation. *Bone Marrow Transplant.* 1996;17:1127-1132.



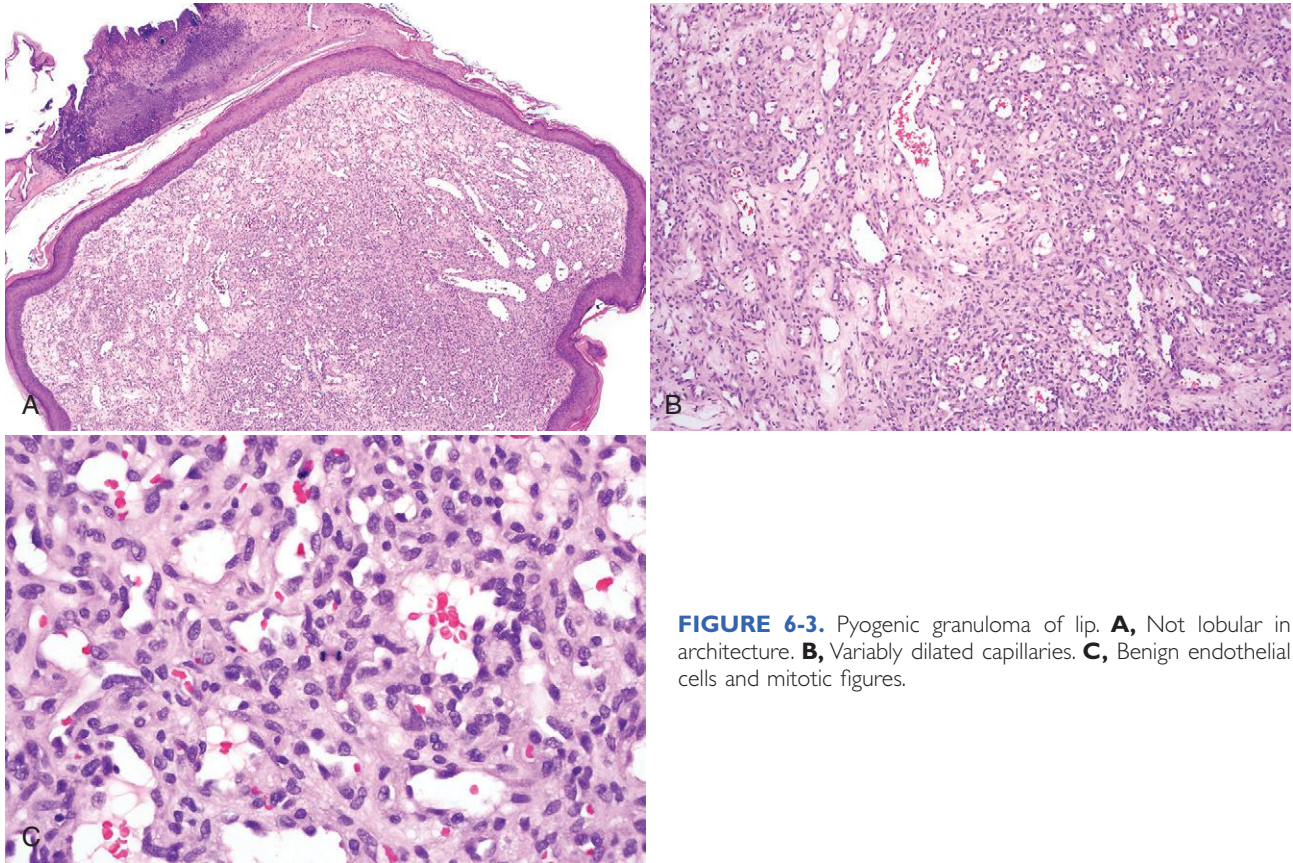


**FIGURE 6-1.** **A**, Pyogenic granuloma of the upper vermillion. **B**, Pyogenic granuloma of the hard palatal mucosa. **C**, Reactive fibrovascular polyp, cyclosporine-induced after stem cell transplantation.

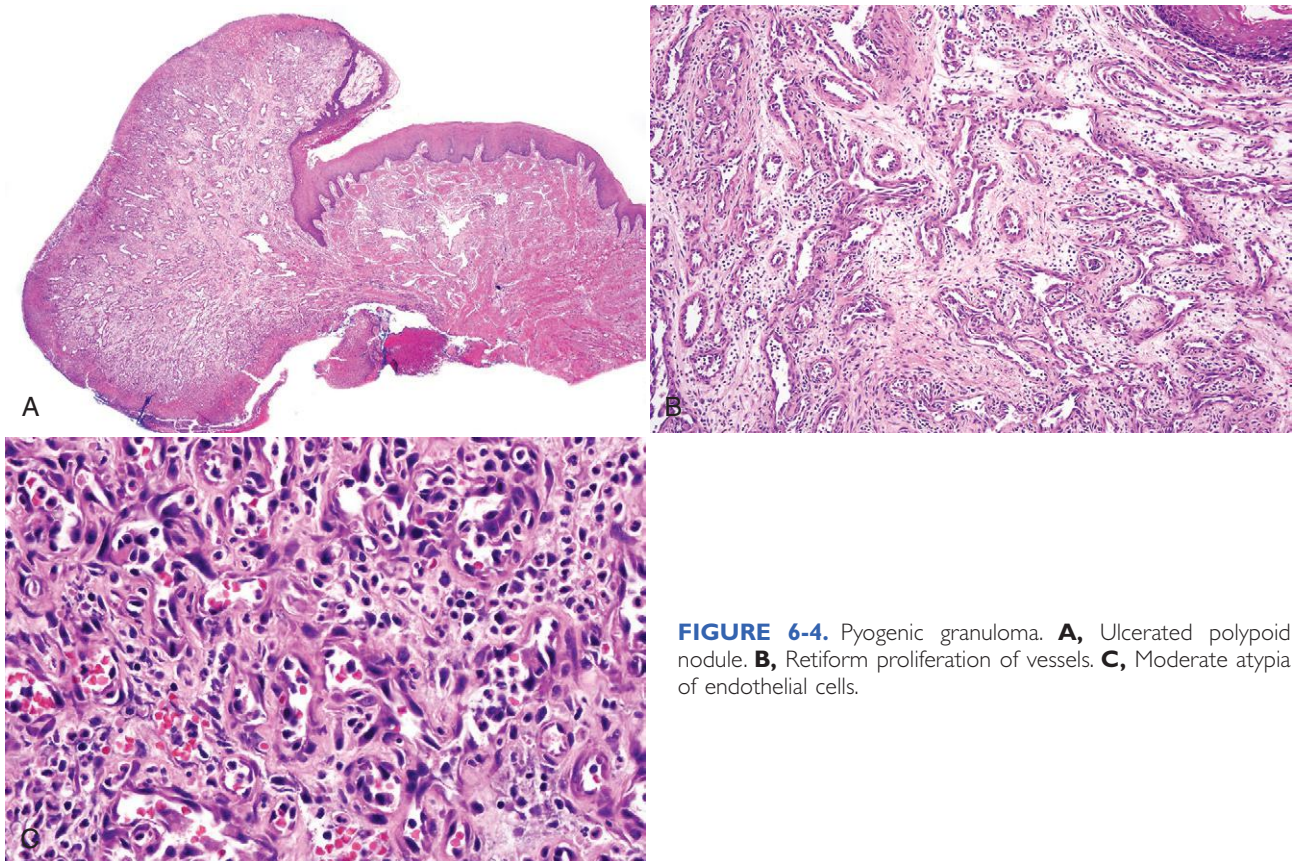


**FIGURE 6-2.** Pyogenic granuloma. **A**, Ulcerated mucosa. **B**, Typical lobular architecture. **C**, Cellular proliferation of endothelial cells.



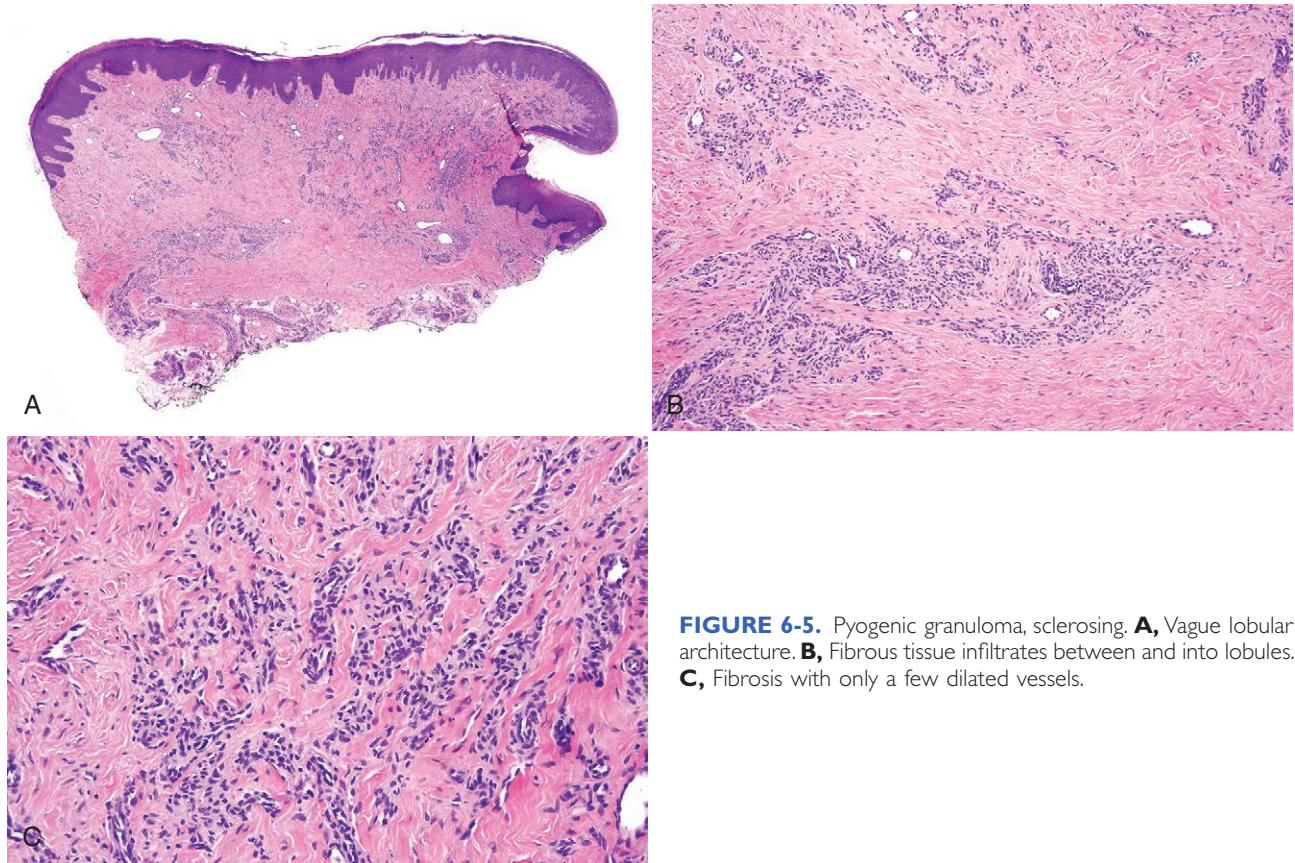


**FIGURE 6-3.** Pyogenic granuloma of lip. **A**, Not lobular in architecture. **B**, Variably dilated capillaries. **C**, Benign endothelial cells and mitotic figures.



**FIGURE 6-4.** Pyogenic granuloma. **A**, Ulcerated polypoid nodule. **B**, Retiform proliferation of vessels. **C**, Moderate atypia of endothelial cells.





**FIGURE 6-5.** Pyogenic granuloma, sclerosing. **A**, Vague lobular architecture. **B**, Fibrous tissue infiltrates between and into lobules. **C**, Fibrosis with only a few dilated vessels.

## VARIX (VENOUS LAKE) AND VENOUS MALFORMATION (VENOUS ANOMALY)

### Clinical Findings

- Usually bluish blebs are less than 1 cm and found on the lips, tongue, or buccal mucosa, which may bleed; seen in middle-aged and older adults (Fig. 6-6, A-C).
- Bilateral inguinal varices of the ventral tongue are common in older adults (see Fig. 6-6, D).
- Venous malformations are larger, often several centimeters in size, and usually are located on the tongue or lips (see Fig. 6-6, E).

### Etiopathogenesis and Histopathologic Features

Loss of elasticity of the muscle around venules (likely superficial postcapillary venules) leads to dilatation of the lumen.

- *Varix*: dilated, tortuous, thin-walled vessels with a thin muscular coat; valve leaflets may be present (Figs. 6-7 and 6-8); thrombi in various stages of organization often noted with high cellularity or hyalinization; Masson tumor (intravascular papillary endothelial hyperplasia) sometimes seen (Figs. 6-9 to 6-11)
- *Venous malformation*: proliferation of venules of varying sizes, sometimes intramuscular in location without proliferation of endothelial cells (Figs. 6-12 and 6-13)

### Differential Diagnosis

- Arteriovenous malformations show the presence of both arterioles and arteries and veins and venules; these lesions have high flow, and biopsy may lead to a severe bleeding episode.
- Hereditary hemorrhagic telangiectasia shows the presence of numerous small capillaries and venules in the lamina propria.

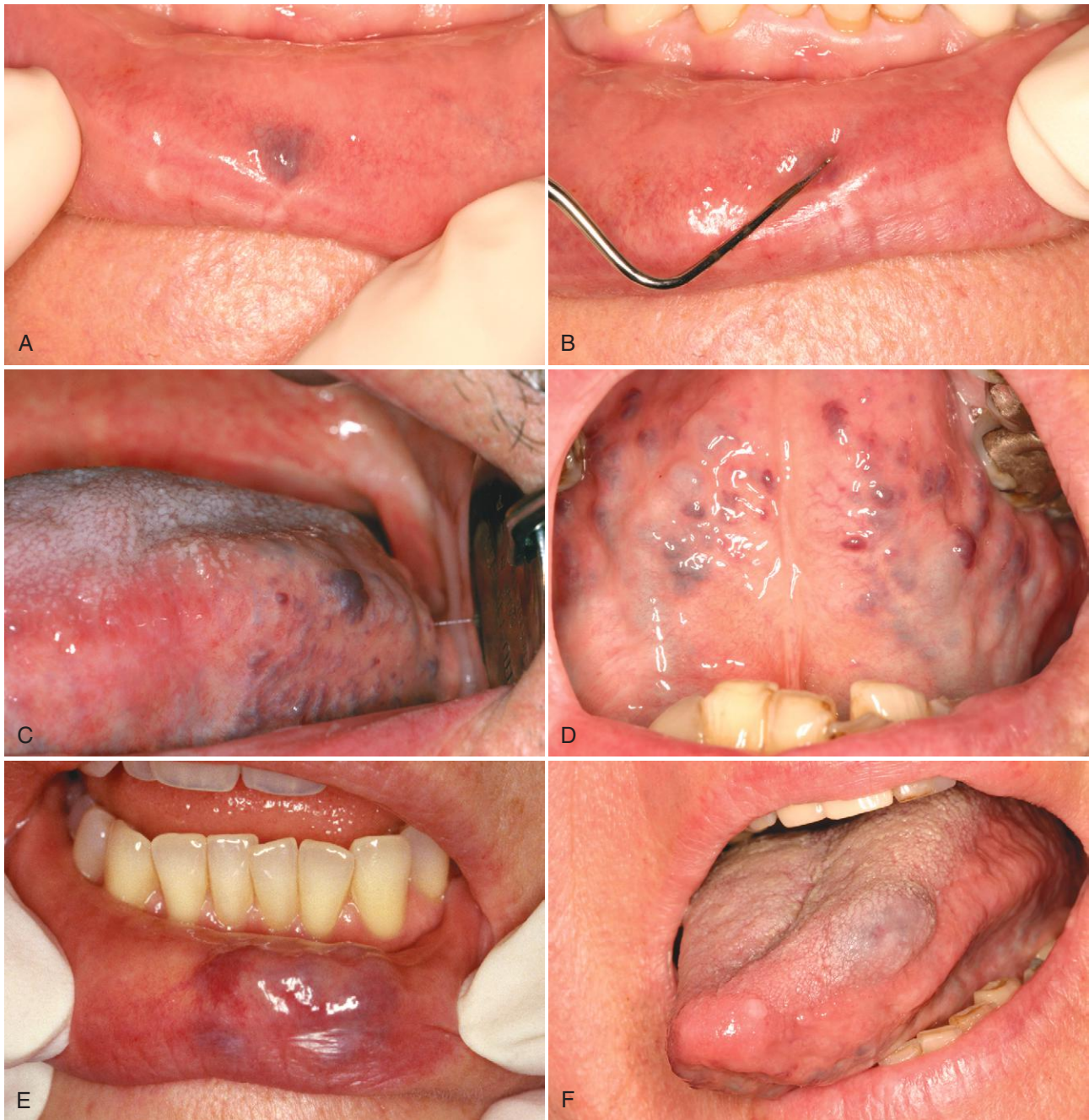### Management and Prognosis

- Excision, laser ablation, and sclerotherapy with ethanolamine oleate are useful treatments.

### REFERENCES

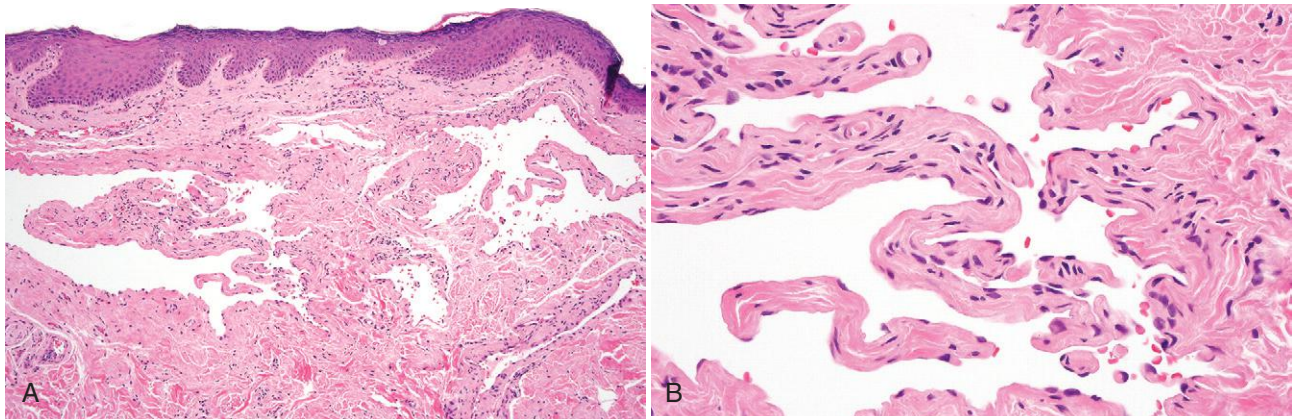
- Buckmiller LM, Richter GT, Suen JY. Diagnosis and management of hemangiomas and vascular malformations of the head and neck. *Oral Dis.* 2010;16:405-418.
- Hedstrom L, Bergh H. Sublingual varices in relation to smoking and cardiovascular diseases. *Br J Oral Maxillofac Surg.* 2010;48:136-138.
- Hong SK, Lee HJ, Seo JK, et al. Reactive vascular lesions treated using ethanolamine oleate sclerotherapy. *Dermatol Surg.* 2010;36:1148-1152.
- Mulliken JB, Glowacki J. Hemangiomas and vascular malformations in infants and children: a classification based on endothelial characteristics. *Plast Reconstr Surg.* 1982;69:412-422.
- Neville BW, Damm DD, Allen CM, Bouquot J. *Oral and Maxillofacial Pathology*. 5th ed. Philadelphia: Saunders; 2009.
- Soares AB, Altemani A, Furuse C, et al. Intravascular papillary endothelial hyperplasia: report of 2 cases and immunohistochemical study. *Oral Surg Oral Med Oral Pathol Oral Radiol Endod.* 2008;106:708-711.



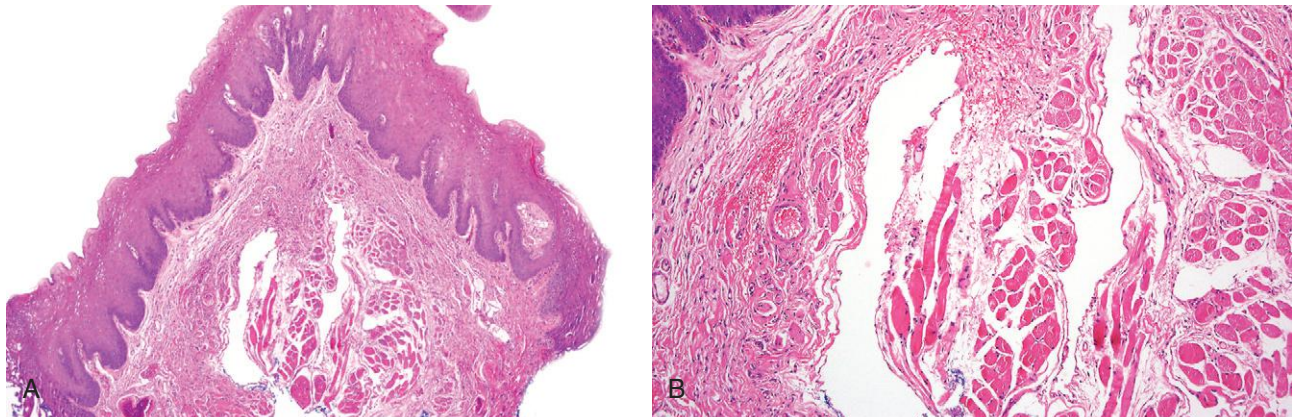


**FIGURE 6-6.** **A**, Varix of the lower labial mucosa. **B**, Same case as in **A**; Varix blanches with pressure. **C**, Varix of the left lateral tongue. **D**, Lingual varices of the ventral tongue. **E**, Venous malformation of lower labial mucosa. **F**, Venous malformation of left tongue.

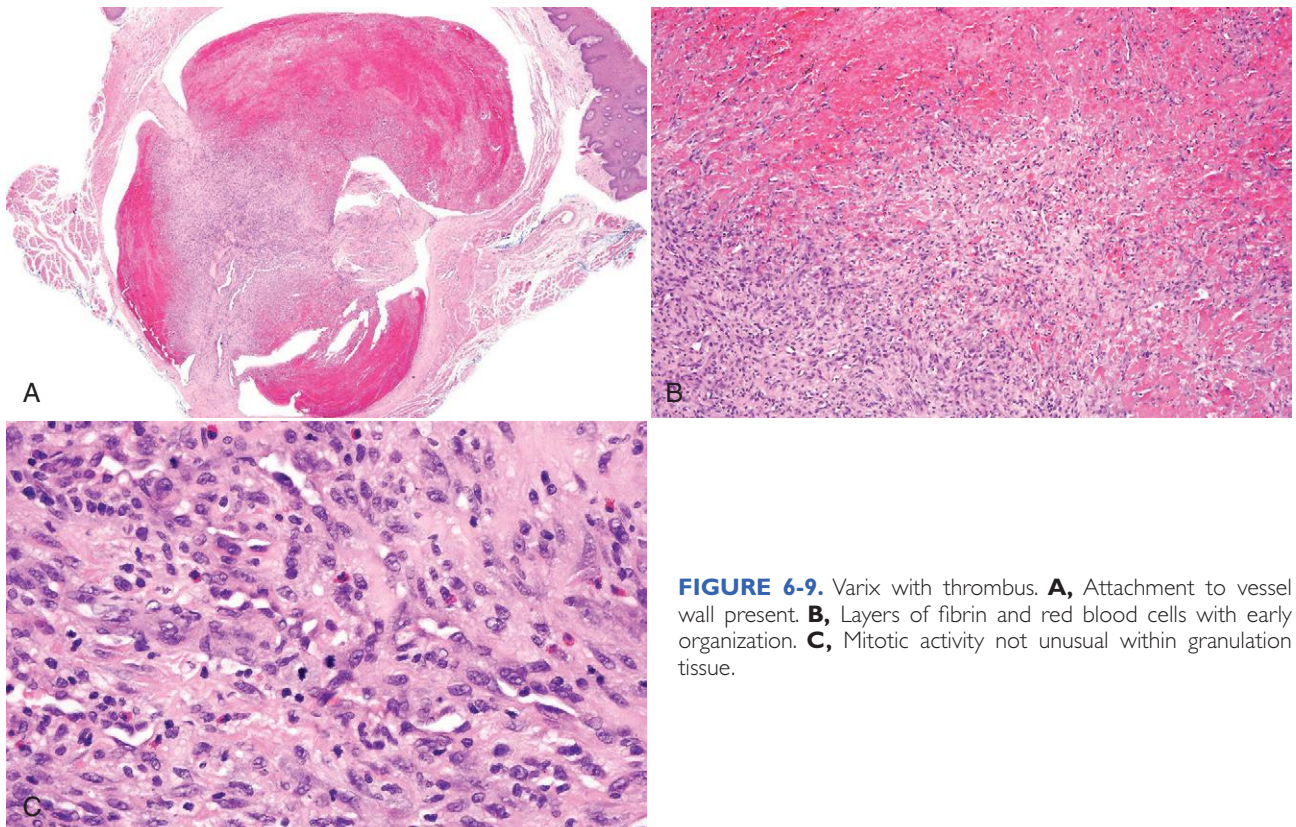




**FIGURE 6-7.** Varix. **A**, Dilated vascular space; venule seen in lower right. **B**, Single layer of endothelium and valve leafletlike structures.

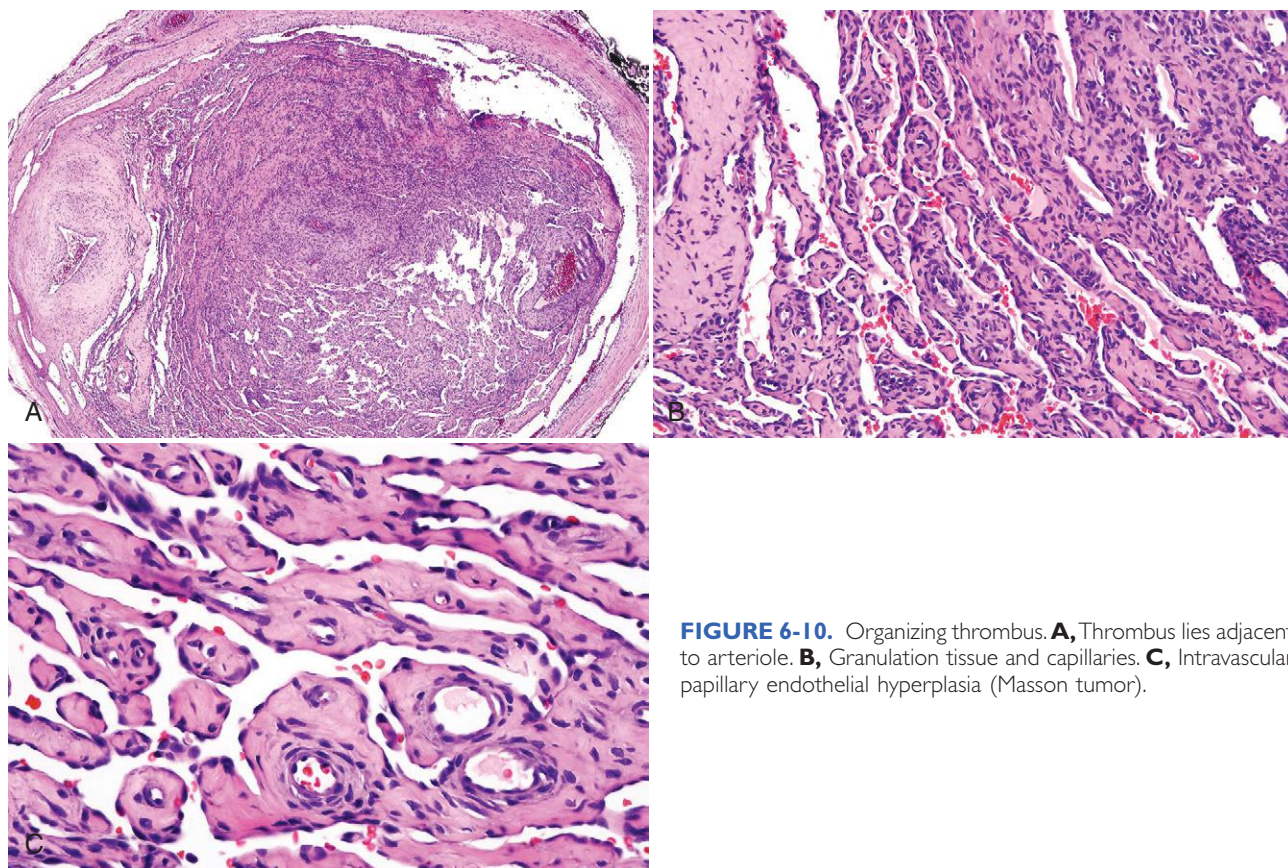


**FIGURE 6-8.** Varix. **A**, Congested and dilated venules within the muscle. **B**, Dilated endothelium-lined space between skeletal muscle fibers.

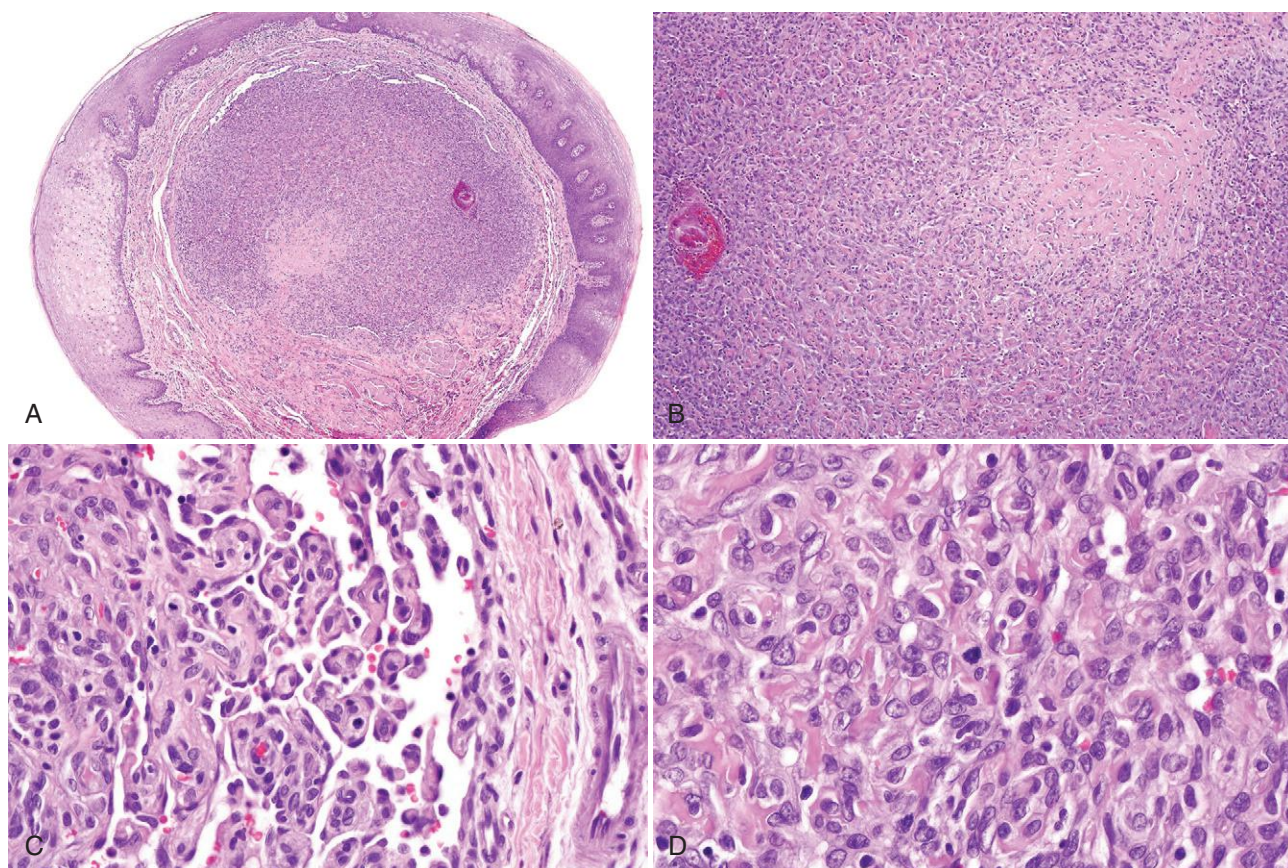


**FIGURE 6-9.** Varix with thrombus. **A**, Attachment to vessel wall present. **B**, Layers of fibrin and red blood cells with early organization. **C**, Mitotic activity not unusual within granulation tissue.



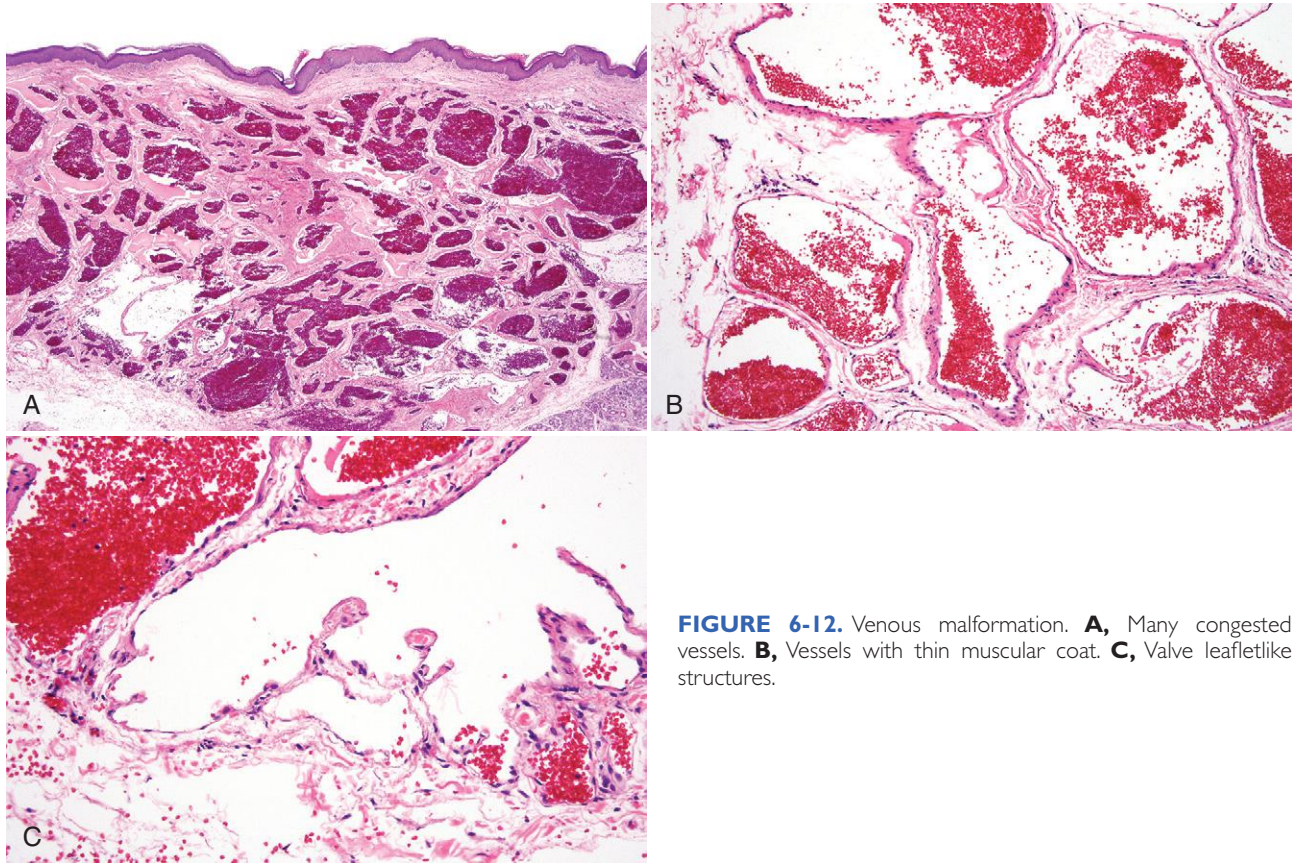


**FIGURE 6-10.** Organizing thrombus. **A**, Thrombus lies adjacent to arteriole. **B**, Granulation tissue and capillaries. **C**, Intravascular papillary endothelial hyperplasia (Masson tumor).

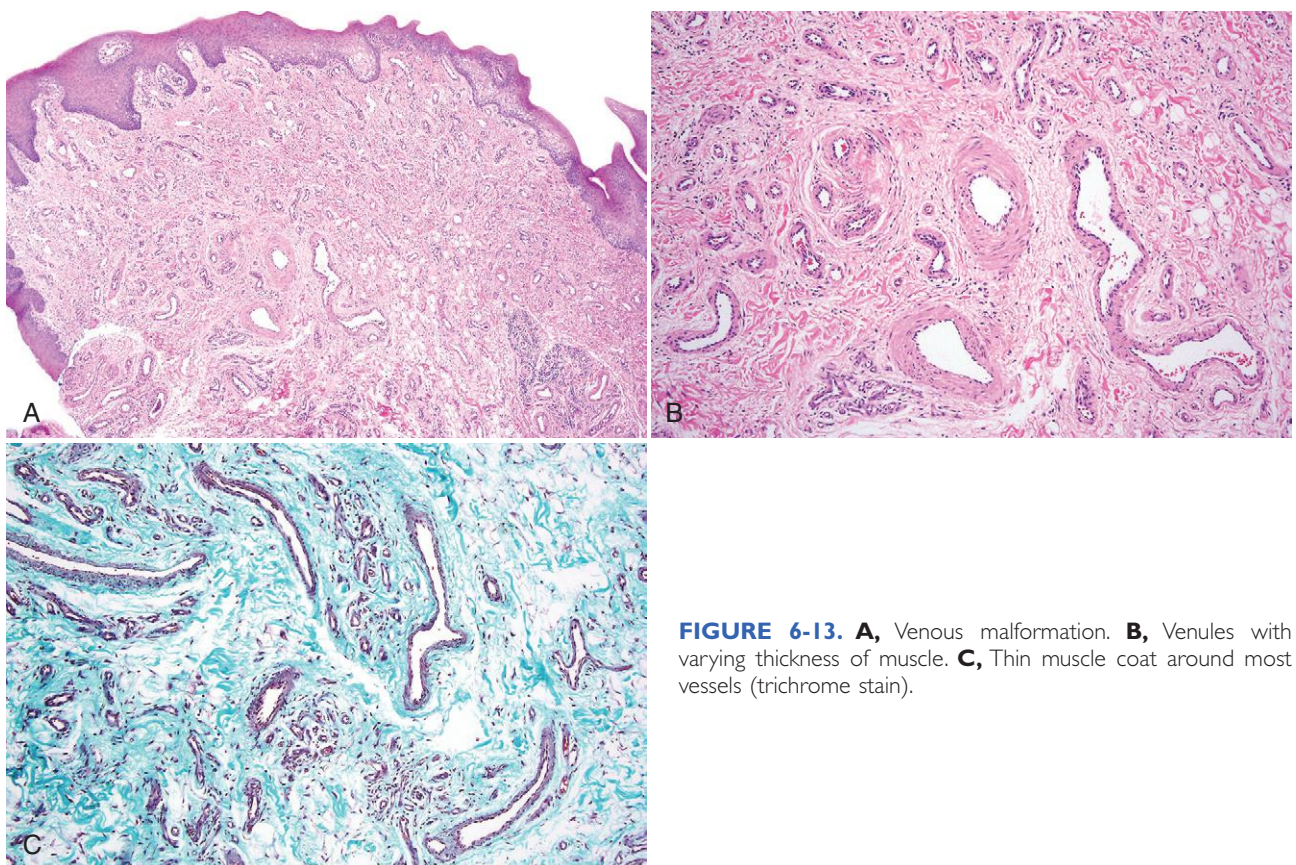


**FIGURE 6-11.** Organizing thrombus. **A**, Markedly cellular lesion. **B**, Remnant thrombus (*left*) and area of hyalinization (*right*). **C**, Focus of Masson tumor. **D**, Marked hypercellularity with mitotic figure.





**FIGURE 6-12.** Venous malformation. **A**, Many congested vessels. **B**, Vessels with thin muscular coat. **C**, Valve leafletlike structures.



**FIGURE 6-13.** **A**, Venous malformation. **B**, Venules with varying thickness of muscle. **C**, Thin muscle coat around most vessels (trichrome stain).



## CALIBER-PERSISTENT LABIAL ARTERY

### Clinical Findings

- Bluish, sometimes nodular, often vermiform, pulsatile lesion of the lower lip in adults; often mistaken for mucocele

### Etiopathogenesis and Histopathologic Features

Lesions are caused by branches of the labial artery that fail to reduce their caliber, even in the superficial tissues.

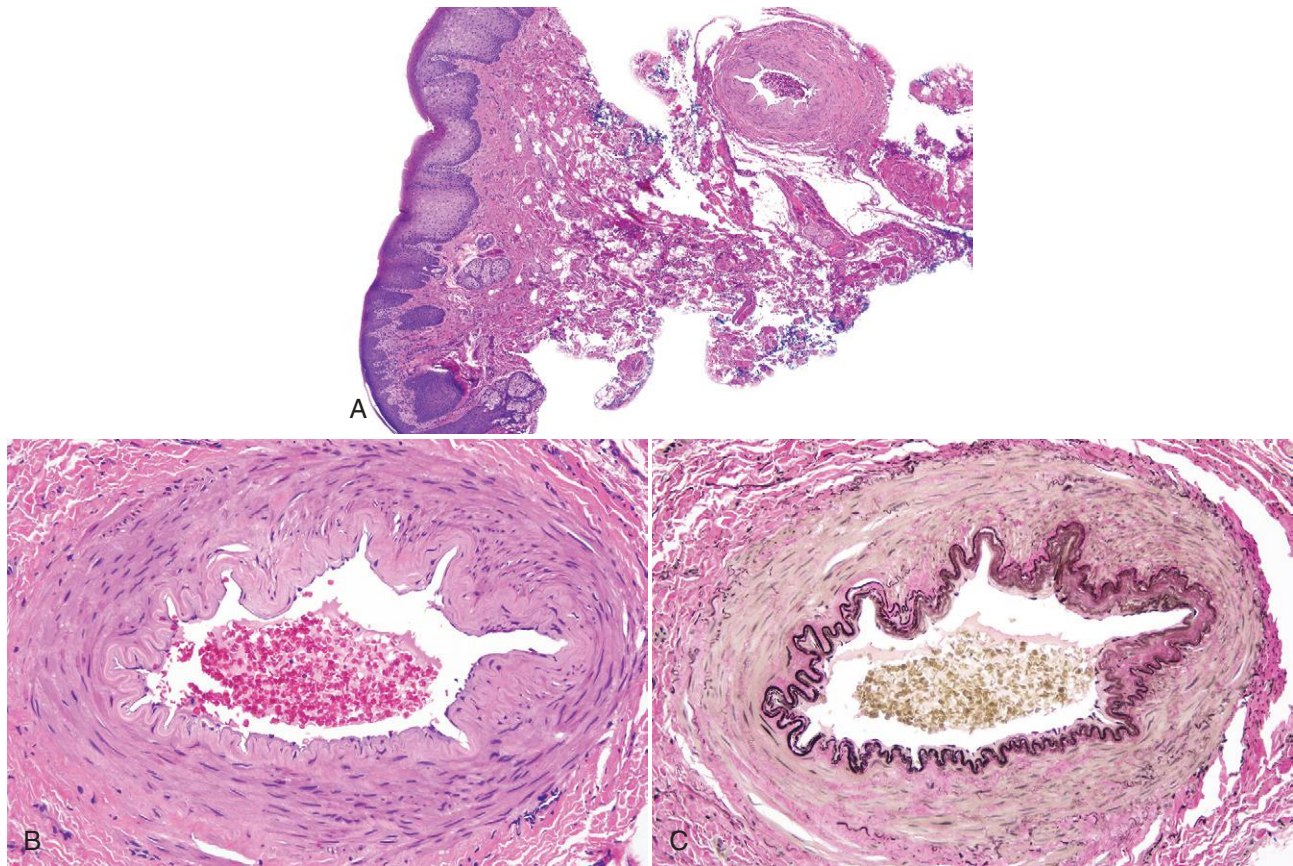
- Normal artery with elastic lamina lies within the lamina propria with an artery diameter-to-depth ratio of less than 1.6 (Fig. 6-14).

### Management and Prognosis

- Trauma leads to pulsatile bleeding, and biopsy is diagnostic.

### REFERENCES

- Jaspers MT. Oral caliber-persistent artery. Unusual presentations of unusual lesions. *Oral Surg Oral Med Oral Pathol.* 1992;74:631-633.
- Lovas JG, Rodu B, Hammond HL, et al. Caliber-persistent labial artery. A common vascular anomaly. *Oral Surg Oral Med Oral Pathol Oral Radiol Endod.* 1998;86:308-312.
- Piccione MJ, Manganaro AM, Almony JS. Caliber-persistent labial artery: diagnosis and treatment—case report. *J Oral Maxillofac Surg.* 2010;68:1987-1989.



**FIGURE 6-14.** Caliber-persistent labial artery. **A**, Vessels in deep lamina propria. **B**, Artery with elastic lamina. **C**, Elastin stain outlining elastic lamina.



## KAPOSI SARCOMA

Kaposi sarcoma is currently classified as a neoplasm of intermediate (nonmetastasizing) potential because of ambiguity regarding its biologic nature.

### Clinical Findings

- There are four clinical presentations: (1) classic type involves the skin of lower legs in older men; (2) African endemic type is disseminated and involves viscera; (3) iatrogenic type is associated with immunosuppression (especially renal and lung transplantation); and (4) epidemic type is found in patients with HIV/AIDS and involves multiple sites, especially the skin and the mouth (this coexists with the endemic form in Africa).
- Dusky red or purple macule (early lesion), plaque, or mass (late lesion) is usually on the maxillary gingiva, palate, or tongue (Fig. 6-15); oral involvement is seen in only 2% to 5% of nonepidemic cases and in 60% to 70% of patients with HIV/AIDS.
- Worsening of Kaposi sarcoma is one of the features of patients on highly active antiretroviral therapy who develop immune reconstitution inflammatory syndrome.

### Etiopathogenesis and Histopathologic Features

This tumor is associated with activity of Kaposi sarcoma-associated herpesvirus (human herpesvirus-8); transmission may be through saliva rather than through blood or semen. Activation of viral lytic and latency genes leads to tumorigenesis, with initial tumor cells being polyclonal and more advanced tumors being monoclonal and immortalized.

- Cellular proliferation of spindle cells in small whorls or fascicles with abundant extravascular erythrocytes, hemosiderin and globular eosinophilic deposits, and some intracytoplasmic granules; mitotic activity may be noted (Figs. 6-16 and 6-17).
- Studies for endothelial markers such as CD31, CD34, FLI-1, and Kaposi sarcoma-associated herpesvirus (especially LANA-1) are positive; studies for D2-40 may also be positive.

### Differential Diagnosis

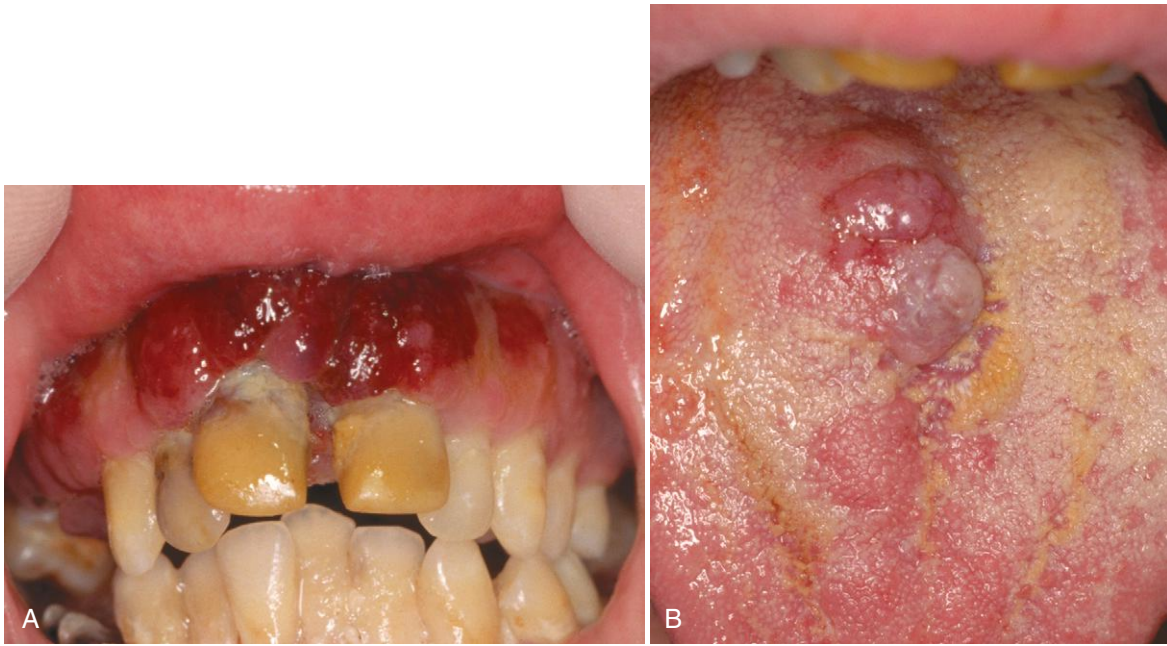
- Spindle cell angiosarcoma and solitary fibrous tumor are negative for Kaposi sarcoma-associated herpesvirus.
- Monophasic synovial sarcoma is not a vascular tumor and is CD31 negative with ductlike structures that are cytokeratin positive.

### Management and Prognosis

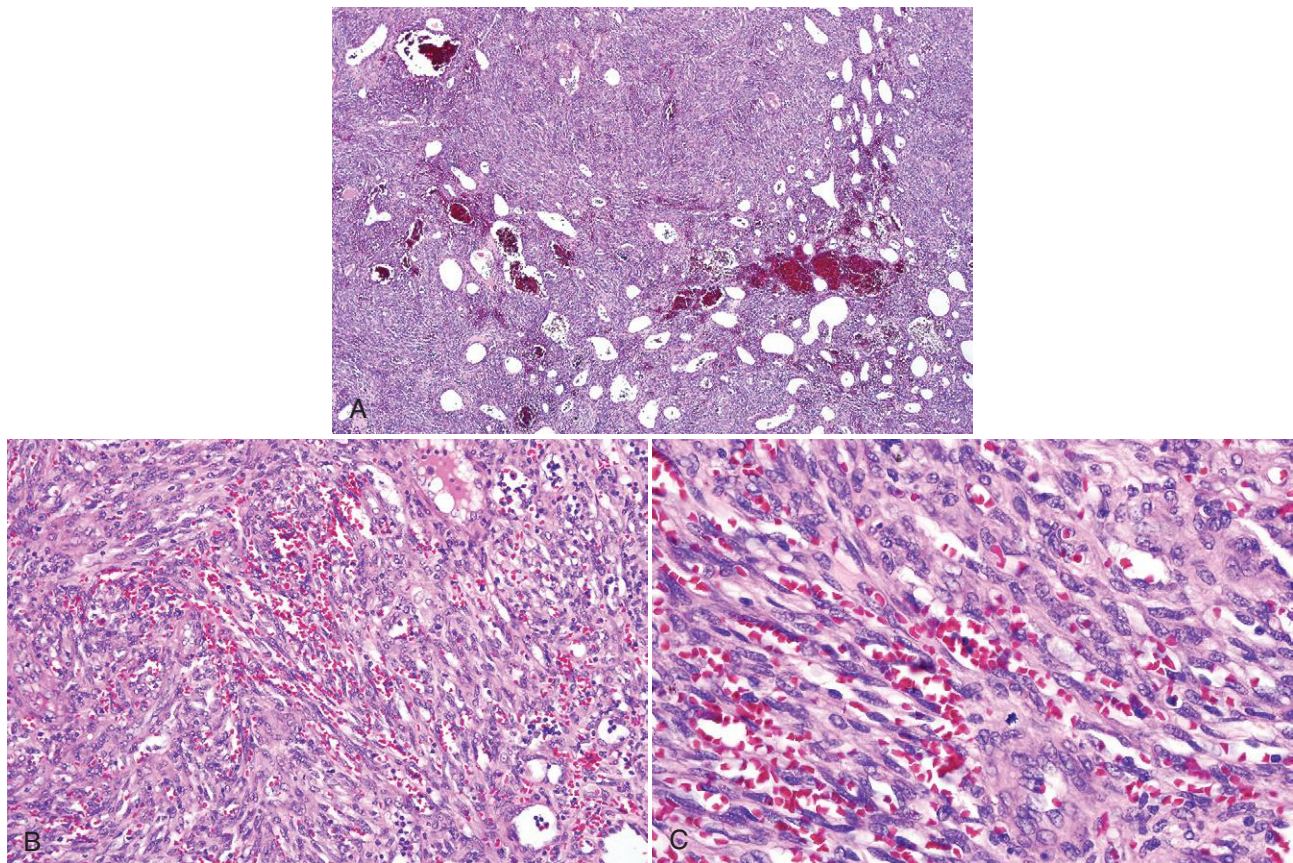
- Patients newly diagnosed with HIV/AIDS require highly active antiretroviral therapy. Oral lesions are successfully treated with excision, laser ablation, intralesional vinblastine therapy, and radiation.
- Systemic therapy includes pegylated liposomal doxorubicin or daunorubicin.
- Reduction in immunosuppressive therapy in post-transplantation patients often leads to regression of tumors.

### REFERENCES

- Bagni R, Whitby D. Kaposi's sarcoma-associated herpesvirus transmission and primary infection. *Curr Opin HIV AIDS*. 2009;4:22-26.
- Fletcher CD. The evolving classification of soft tissue tumours: an update based on the new WHO classification. *Histopathology*. 2006;48:3-12.
- Folpe AL, Chand EM, Goldblum JR, Weiss SW. Expression of FLI-1, a nuclear transcription factor, distinguishes vascular neoplasms from potential mimics. *Am J Surg Pathol*. 2001;25:1061-1066.
- Lamovec J, Knuutila S. Kaposi's sarcoma. In: Fletcher C, Unni K, Mertens F, eds. *World Health Organization Classification of Tumours: Pathology and Genetics of Tumours of Soft Tissue and Bone*. Lyon: IARC Press; 2002:170-172.
- Leidner RS, Aboulafia DM. Recrudescence Kaposi's sarcoma after initiation of HAART: a manifestation of immune reconstitution syndrome. *AIDS Patient Care STDS*. 2005;19:635-644.
- Patrikidou A, Vahtsevanos K, Charalambidou M, et al. Non-AIDS Kaposi's sarcoma in the head and neck area. *Head Neck*. 2009;31:260-268.
- Pantanowitz L, Otis CN, Dezube BJ. Immunohistochemistry in Kaposi's sarcoma. *Clin Exp Dermatol*. 2010;35:68-72.
- Pauk J, Huang ML, Brodie SJ, et al. Mucosal shedding of human herpesvirus 8 in men. *N Engl J Med*. 2000;343:1369-1377.
- Ramirez-Amador V, Anaya-Saavedra G, Martinez-Mata G. Kaposi's sarcoma of the head and neck: a review. *Oral Oncol*. 2010;46:135-145.

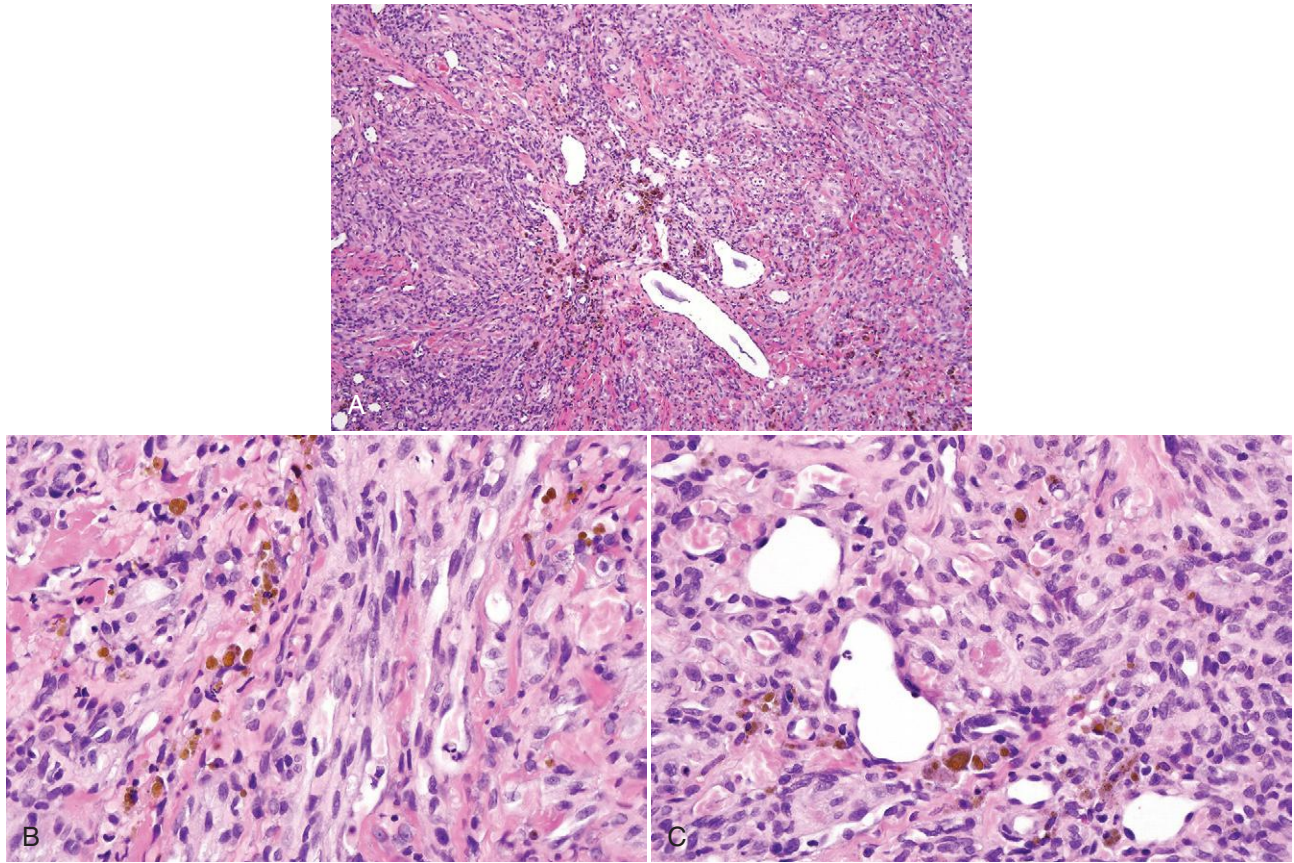


**FIGURE 6-15.** **A**, Kaposi sarcoma on the maxillary gingiva. **B**, Kaposi sarcoma on the tongue dorsum.



**FIGURE 6-16.** Kaposi sarcoma. **A**, Cellular proliferation of spindle cells, ectatic vessels, and abundant fresh hemorrhage. **B**, Spindle cells in short fascicles. **C**, Spindle cells show mild nuclear pleomorphism and mitotic activity, and erythrocytes are present between spindle cells.





**FIGURE 6-17.** Kaposi sarcoma. **A**, Proliferation of spindle cells with dilated vessels and hemosiderin. **B**, Spindle cells with mild nuclear atypia. **C**, Plump spindle cells with lumen formation and eosinophilic globules.

## LYMPHATIC MALFORMATION (LYMPHANGIOMA CIRCUMSCRIPTUM)

Unlike cystic hygromas, lymphatic malformations of the oral cavity are usually superficially located and smaller.

### Clinical Findings

- Clusters of translucent vesicular structures, usually on the tongue (50% of cases) in young adults (Fig. 6-18); typically described as “frog spawn”

### Etiopathogenesis and Histopathologic Features

This developmental malformation of lymphatic structures exhibits the absence of vascular endothelial growth factor C, which regulates lymphatic development. It is consistent with a process of lymphatic dilatation rather than neoplasia.

- Vascular spaces lined by a single layer of endothelial cells (D2-40 positive) with valvelike structures, filled with pale, wispy, or denser eosinophilic material; typically abut the epithelium and may insinuate into the muscle (Figs. 6-19 and 6-20)

### Differential Diagnosis

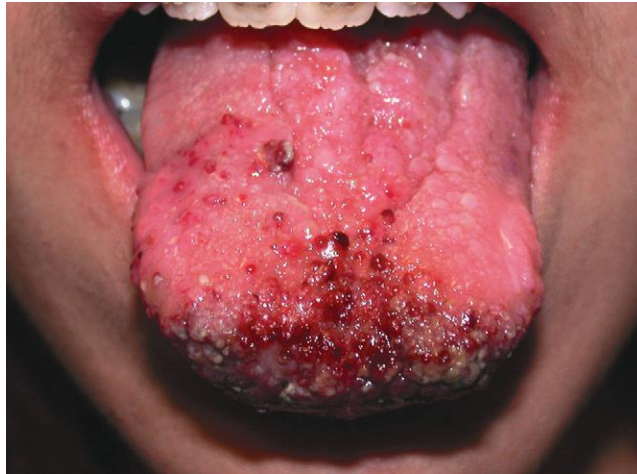- Venous malformations show a thin muscular coat and usually do not abut the epithelium.

### Management and Prognosis

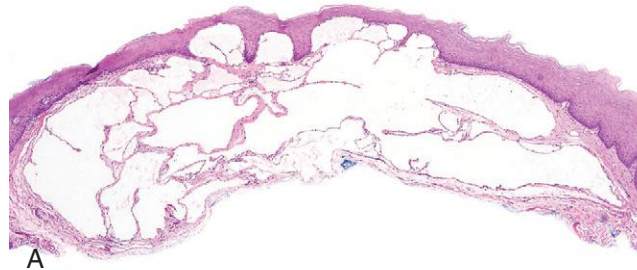
- Excision is curative for small lesions, and debulking or embolization is treatment for large lesions.

### REFERENCES

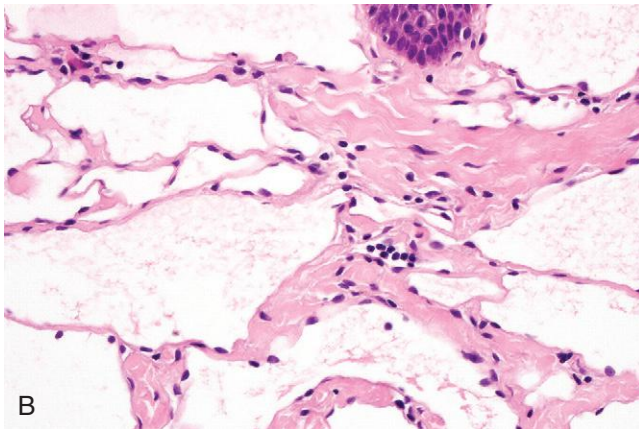
- Brennan TD, Miller AS, Chen SY. Lymphangiomas of the oral cavity: a clinicopathologic, immunohistochemical, and electron-microscopic study. *J Oral Maxillofac Surg.* 1997;55:932-935.
- Itakura E, Yamamoto H, Oda Y, et al. VEGF-C and VEGFR-3 in a series of lymphangiomas: is superficial lymphangioma a true lymphangioma? *Virchows Arch* 2009;454:317-325.
- Kalpidis CD, Lysitsa SN, Kolokotronis AE, et al. Solitary superficial microcystic lymphatic malformation (lymphangioma circumscriptum) of the gingiva. *J Periodontol.* 2006;77:1797-1801.
- Neville BW, Damm DD, Allen CM, Bouquot J. *Oral and Maxillofacial Pathology.* 5th ed. Philadelphia: Saunders; 2009.



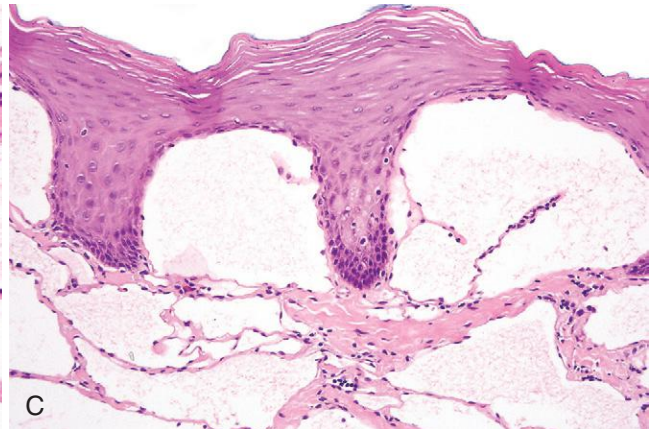
**FIGURE 6-18.** Lymphatic malformation of the tongue manifesting as clusters of hemorrhagic and ulcerated vesicles. (Courtesy of Dr. Bonnie Padwa, Harvard School of Dental Medicine, Boston, Mass.)



A



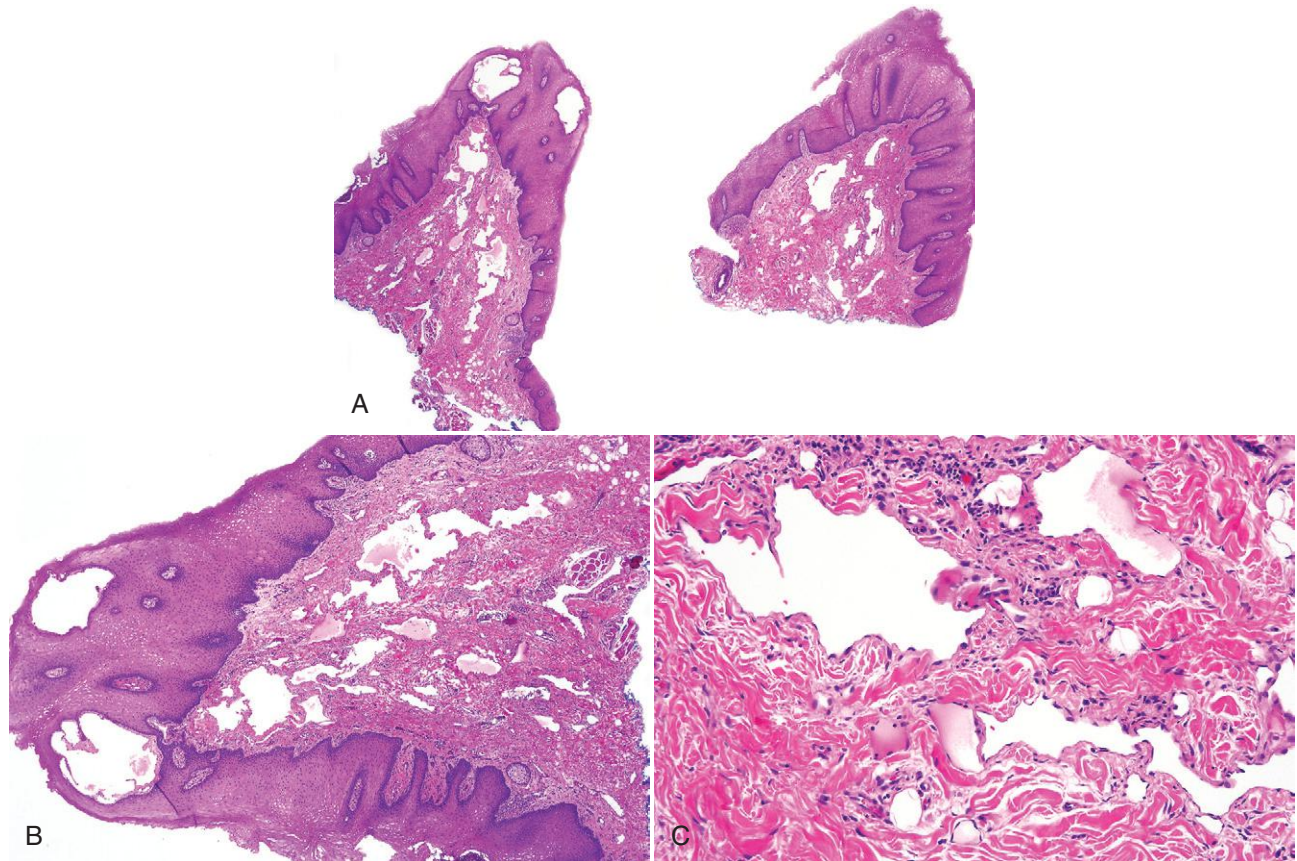
B



C

**FIGURE 6-19.** Lymphatic malformation. **A**, Large vascular spaces about the epithelium. **B**, Vascular spaces lined by single layer of endothelial cells and filled with pale, wispy lymph. **C**, Vascular spaces about the epithelium.





**FIGURE 6-20.** Lymphatic malformation. **A**, Lesion extends far into the deep lamina propria. **B**, Vascular channels still abut the epithelium. **C**, Scattered lymphatic channels in deep lamina propria.

## Neural Tumors

Neural tumors are the most common benign spindle cell lesions in the oral cavity.

### Clinical Findings

- Solitary nodule is on the tongue, lips (especially upper labial mucosa), and palate (Fig. 6-21).
- Traumatic neuromas are often painful and seen at sites of previous surgery or frequent trauma (e.g., lip, tongue, and mental nerve area in the edentulous mandible, the last from denture trauma).
- Multiple nodules on the lips and tongue strongly suggest mucosal neuromas of multiple endocrine neoplasia (MEN) type 2B; these are associated with thyroid medullary carcinoma and pheochromocytoma (see later).
- Neurofibroma, either solitary or multiple, may be associated with neurofibromatosis type 1.

## TRAUMATIC NEUROMA

### Etiopathogenesis and Histopathologic Features

Traumatic partial or total severance of nerve fibers leads to a tangle of nerves and scarring.

- Numerous nerve fibers of varying sizes with some showing mucinous change; fibrosis and scarring occurs between fibers (Figs. 6-22 and 6-23, A and B).
- Spindle cells are S-100 protein positive and neurofilament protein highlights axons (see Fig. 6-23, C)

### Differential Diagnosis

- Mucosal neuromas of MEN show hyperplasia of nerve fibers with thickened perineurium but an absence of fibrosis and scarring.

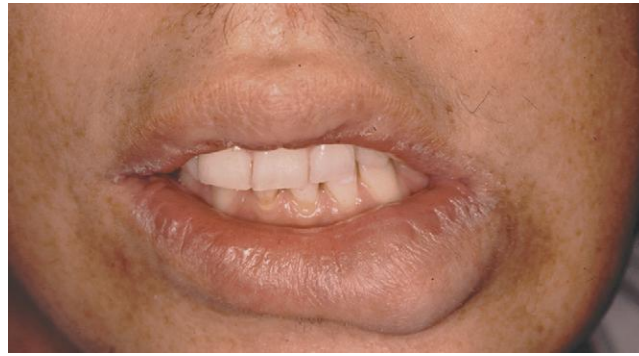### Management and Prognosis

- Excision is curative.

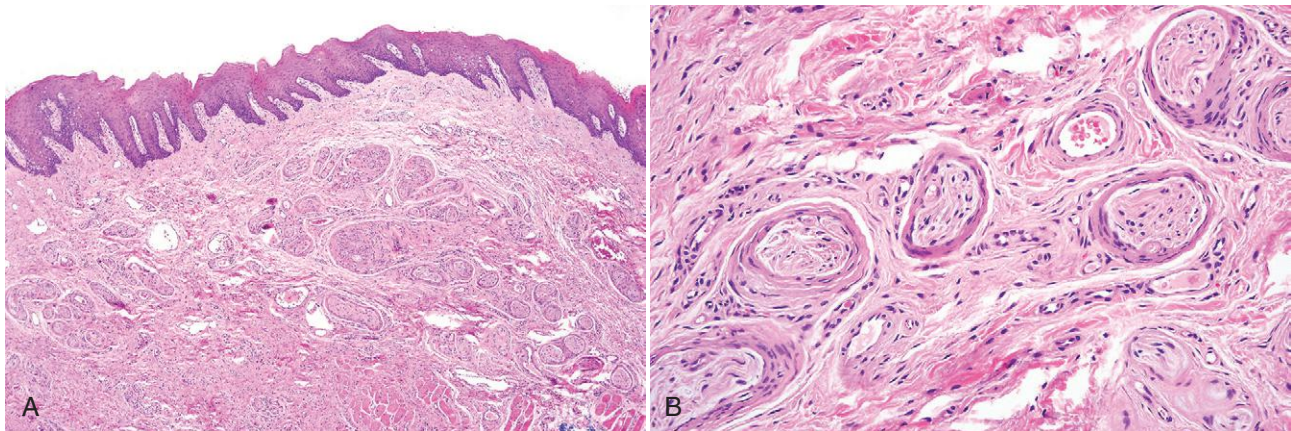
### REFERENCES

- Chrysomali E, Papanicolaou SI, Dekker NP, Regezi JA. Benign neural tumors of the oral cavity: a comparative immunohistochemical study. *Oral Surg Oral Med Oral Pathol Oral Radiol Endod.* 1997;84:381-390.
- Edwards M, Reid JS. Multiple endocrine neoplasia syndrome type IIb: a case report. *Int J Paediatr Dent.* 1998;8:55-60.
- Jordan RC, Regezi JA. Oral spindle cell neoplasms: a review of 307 cases. *Oral Surg Oral Med Oral Pathol Oral Radiol Endod.* 2003;95:717-724.
- Salla JT, Johann AC, Garcia BG, et al. Retrospective analysis of oral peripheral nerve sheath tumors in Brazilians. *Braz Oral Res.* 2009;23:43-48.

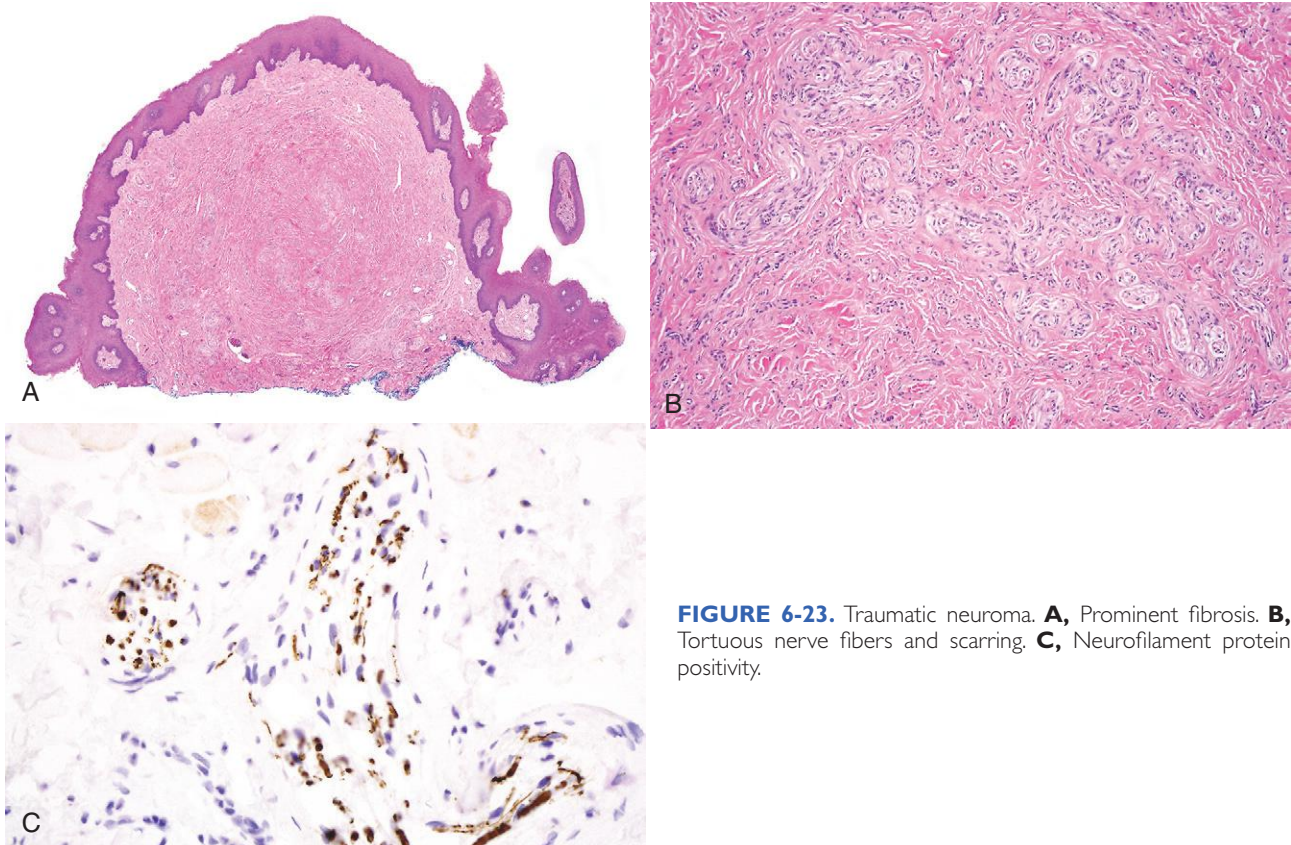




**FIGURE 6-21.** Solitary neurofibroma of lower lip.



**FIGURE 6-22.** Traumatic neuroma. **A**, Nerve fibers of varying sizes with fibrosis. **B**, Nerve fibers with thickened endoneurium.



**FIGURE 6-23.** Traumatic neuroma. **A**, Prominent fibrosis. **B**, Tortuous nerve fibers and scarring. **C**, Neurofilament protein positivity.



## NEUROFIBROMA

### Etiopathogenesis and Histopathologic Features

Neurofibromas are usually solitary and sporadic; some (especially plexiform type) are seen in patients with neurofibromatosis type A (from inactivating NF-1 gene mutation on chromosome 17q). It is associated with other signs of neurofibromatosis such as café au lait macules, Lisch nodules, and multiple skin neurofibromas.

- Nonencapsulated, discrete or diffuse proliferation of perineurial cells, fibroblasts, and Schwann cells in a delicately collagenized stroma with variably myxoid or mucinous background; cells with curvilinear, comma-shaped, or ovoid nuclei with inconspicuous nucleoli and indistinct cytoplasmic borders; scattered S-100–positive Schwann cells and occasional neurites identified; mast cells often present (Figs. 6-24 and 6-25)

### Differential Diagnosis

- Neurothekeoma has lobulated appearance, and cells are epithelioid.
- Soft tissue myxoma is S-100 negative.
- Solitary circumscribed neuroma has many neurites, slight nuclear palisading, and tissue clefts.
- Mucosal neuroma consists of nodules of tortuous and enlarged nerve fibers usually on the lips and tongue (Fig. 6-26). It is associated with MEN type 2B together

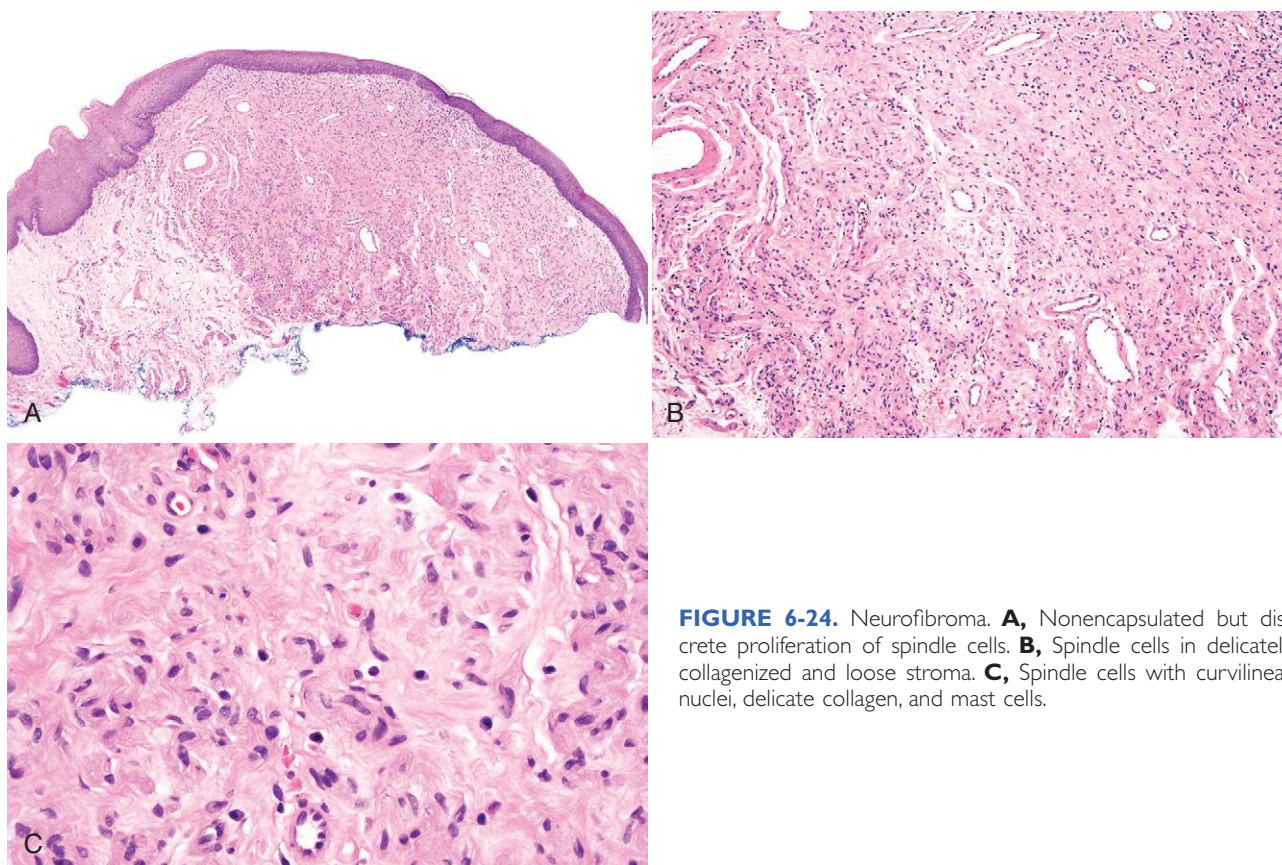
with medullary thyroid carcinoma, pheochromocytomas (often bilateral), eyelid neuromas causing lid eversion, intestinal ganglioneuromatosis, and marfanoid phenotype; autosomal dominant condition is caused by a mutation in the RET gene on chromosome 10.

### Management and Prognosis

- Excision is curative.
- Plexiform neurofibroma in patients with neurofibromatosis may undergo malignant transformation, and p53, p16, and p27 may be involved in tumor progression.

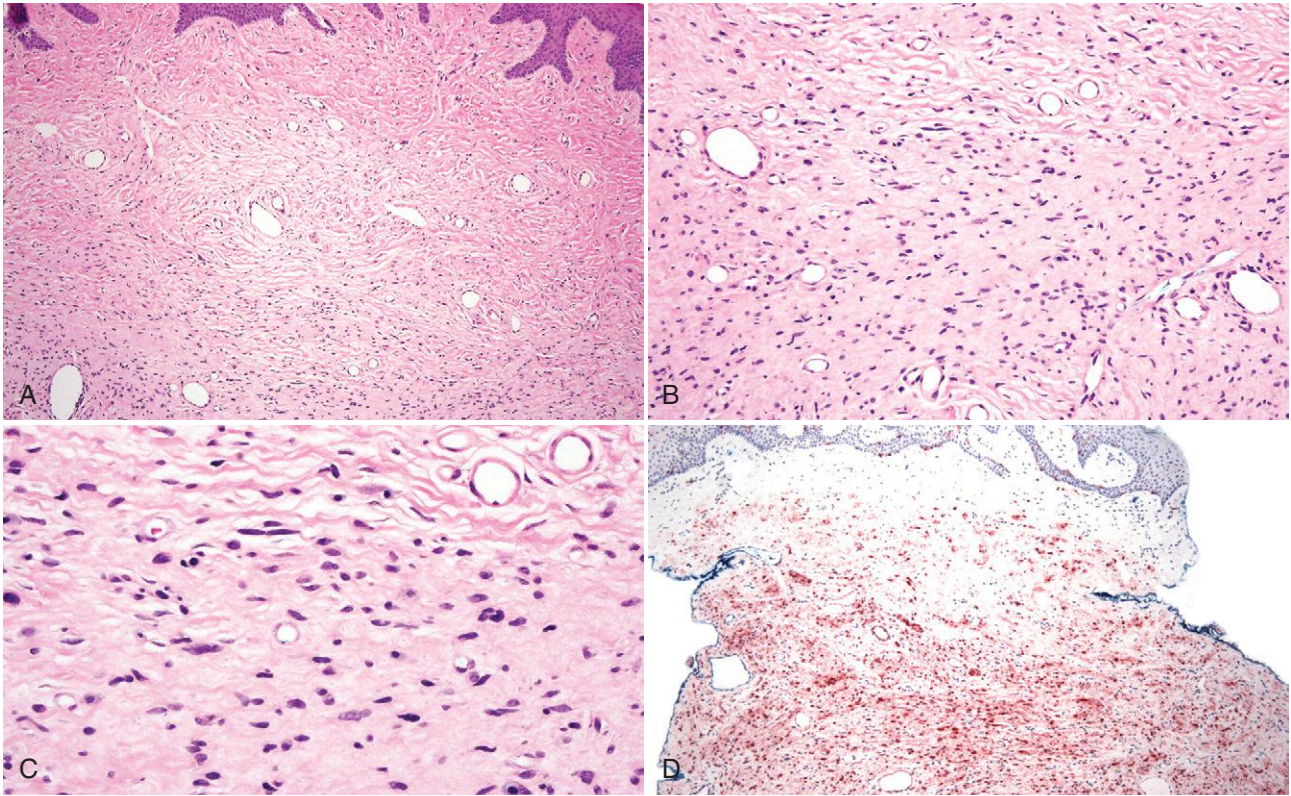
### REFERENCES

- Chrysomali E, Papanicolaou SI, Dekker NP, Regezi JA. Benign neural tumors of the oral cavity: a comparative immunohistochemical study. *Oral Surg Oral Med Oral Pathol Oral Radiol Endod.* 1997;84:381-390.
- Fletcher C, ed. *Diagnostic Histopathology of Tumors.* 3rd ed. Philadelphia: Saunders; 2007.
- Salla JT, Johann AC, Garcia BG, et al. Retrospective analysis of oral peripheral nerve sheath tumors in Brazilians. *Braz Oral Res.* 2009;23:43-48.
- Vered M, Fridman E, Carpenter WM, Buchner A. Classic neurothekeoma (nerve sheath myxoma) and cellular neurothekeoma of the oral mucosa: immunohistochemical profiles. *J Oral Pathol Med.* 2011;40:174-180.
- Zhou H, Coffin CM, Perkins SL, et al. Malignant peripheral nerve sheath tumor: a comparison of grade, immunophenotype, and cell cycle/growth activation marker expression in sporadic and neurofibromatosis 1-related lesions. *Am J Surg Pathol.* 2003;27:1337-1345.

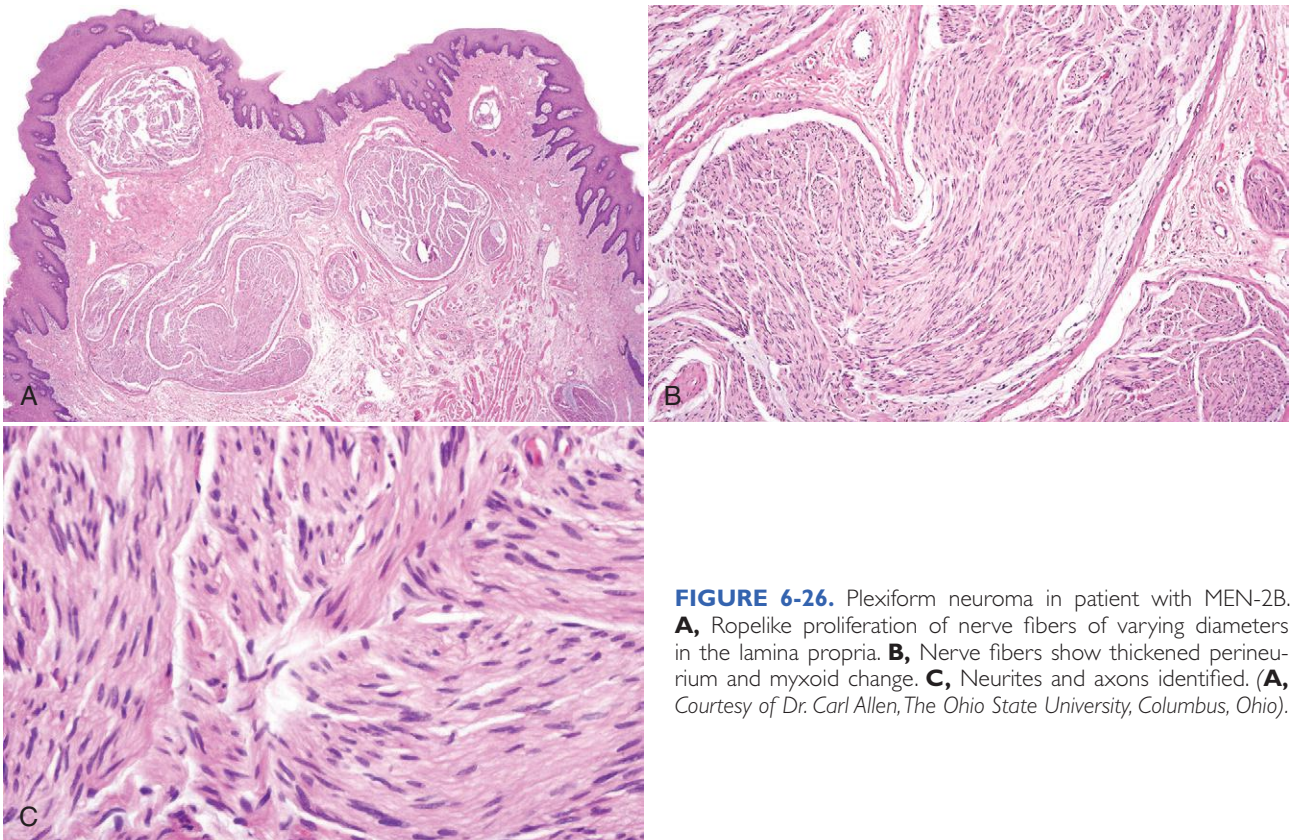


**FIGURE 6-24.** Neurofibroma. **A**, Nonencapsulated but discrete proliferation of spindle cells. **B**, Spindle cells in delicately collagenized and loose stroma. **C**, Spindle cells with curvilinear nuclei, delicate collagen, and mast cells.





**FIGURE 6-25.** Neurofibroma. **A**, Diffuse unencapsulated proliferation of spindle cells in the superficial lamina propria. **B**, Spindle cells and delicate collagen. **C**, Spindle cells with curvilinear nuclei, mast cells, and delicate collagen. **D**, Some of the cells are S-100 positive.



**FIGURE 6-26.** Plexiform neuroma in patient with MEN-2B. **A**, Ropelike proliferation of nerve fibers of varying diameters in the lamina propria. **B**, Nerve fibers show thickened perineurium and myxoid change. **C**, Neurites and axons identified. (A, Courtesy of Dr. Carl Allen, The Ohio State University, Columbus, Ohio).



## SCHWANNOMA

### Etiopathogenesis and Histopathologic Features

Schwannoma represents a neoplastic proliferation of Schwann cells and axons, developing eccentrically from the surface of nerves; it is sometimes seen in neurofibromatosis type 2.

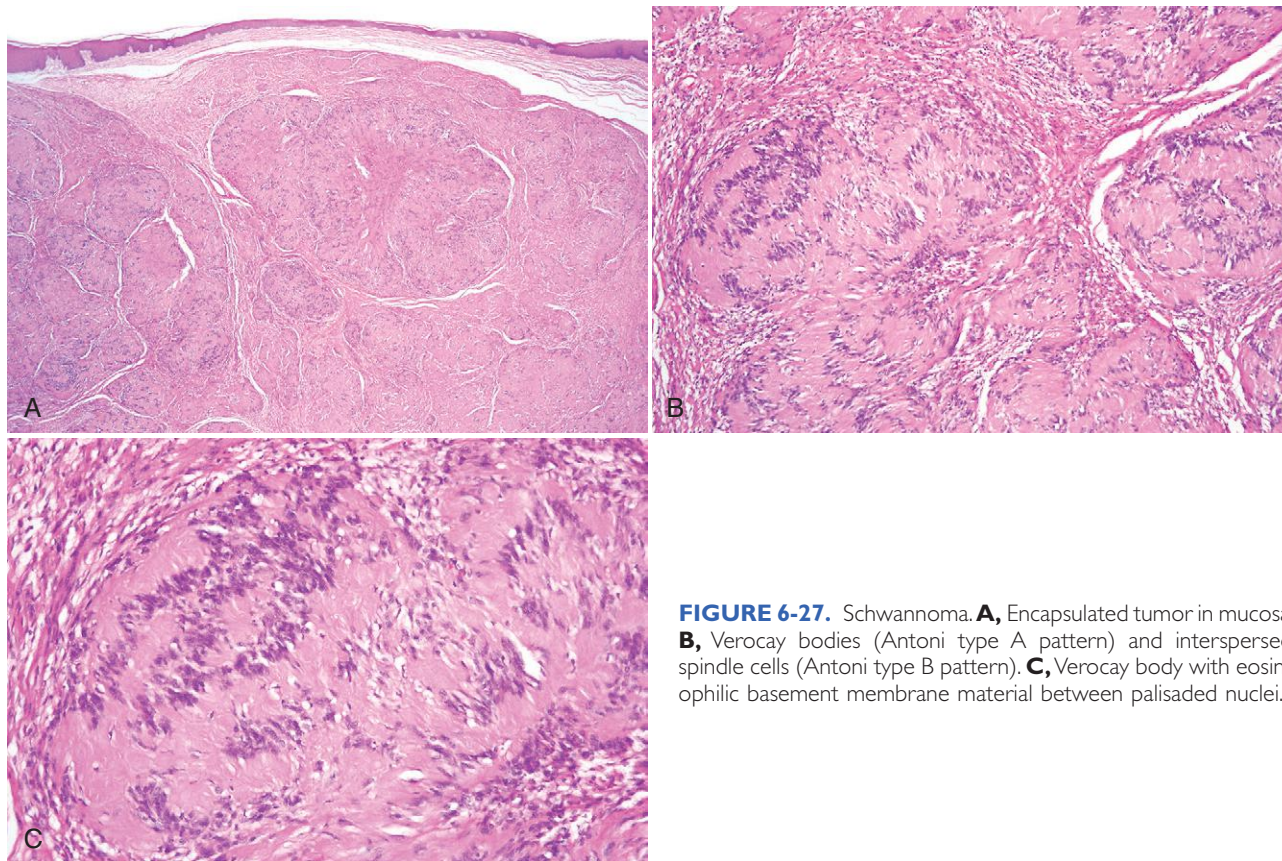
- Encapsulated proliferation of spindled Schwann cells in delicately collagenized stroma with two patterns: *Antoni type A pattern* exhibits Verocay bodies composed of palisaded nuclei and intervening eosinophilic accumulation of basement membrane–like material (Figs. 6-27 and 6-28, A and B); *Antoni type B pattern* has a more nondescript appearance with myxoid background (see Fig. 6-28, C); tumors are consistently S-100 positive and sometimes neurofilament protein (NFP) positive; capsule of perineurium is epithelial membrane antigen (EMA) positive.
- Ancient schwannomas show degenerative changes such as hemorrhage, hyalinization, cystic degeneration of stroma, atypical spindle cells with large nuclei, and variable inflammation (Fig. 6-29).

### Differential Diagnosis

- Neurofibromas are usually not encapsulated and do not contain Verocay bodies.
- Solitary circumscribed neuroma show some palisading of nuclei but contain many neurites and tissue clefts.
- Solitary fibrous tumor contains staghorn vessels, and cells are CD34 positive.
- Some leiomyomas demonstrate Verocay body–like formations but are S-100 negative.

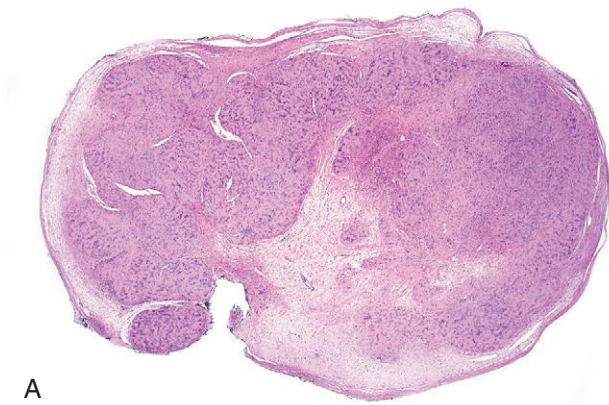
### REFERENCES

- Fletcher C, ed. *Diagnostic Histopathology of Tumors*. 3rd ed. Philadelphia: Saunders; 2007.
- Liegl B, Bennett MW, Fletcher CD. Microcystic/reticular schwannoma: a distinct variant with predilection for visceral locations. *Am J Surg Pathol*. 2008;32:1080-1087.
- Nascimento AF, Fletcher CD. The controversial nosology of benign nerve sheath tumors: neurofilament protein staining demonstrates intratumoral axons in many sporadic schwannomas. *Am J Surg Pathol*. 2007;31:1363-1370.

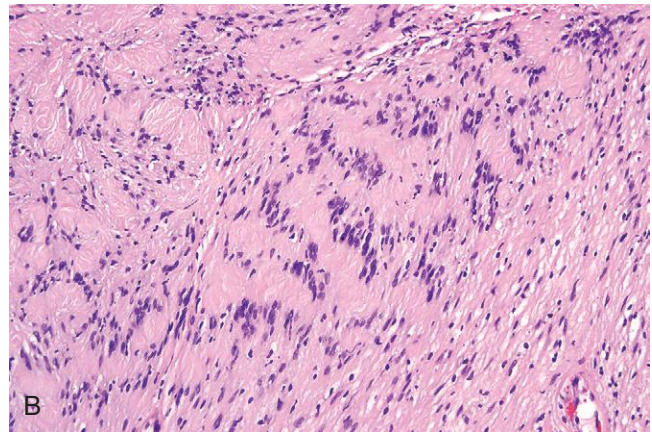


**FIGURE 6-27.** Schwannoma. **A**, Encapsulated tumor in mucosa. **B**, Verocay bodies (Antoni type A pattern) and interspersed spindle cells (Antoni type B pattern). **C**, Verocay body with eosinophilic basement membrane material between palisaded nuclei.

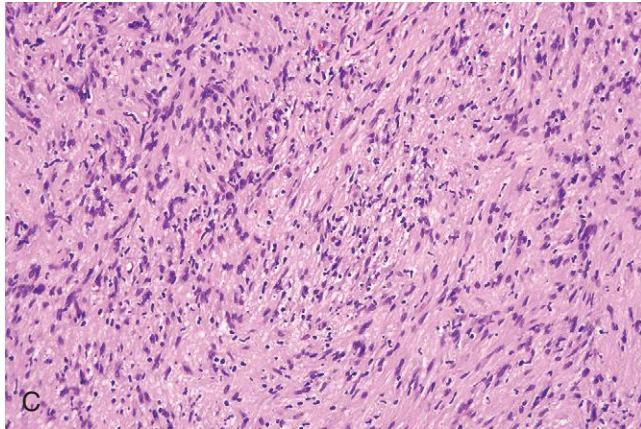




A

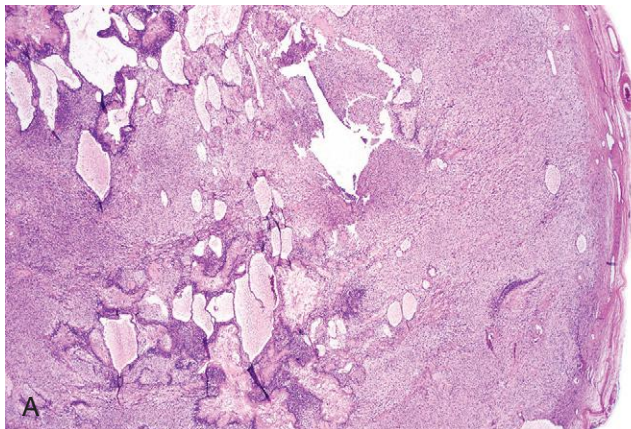


B

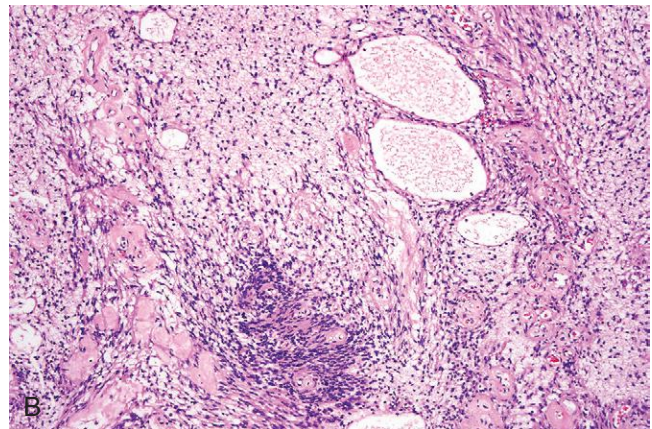


C

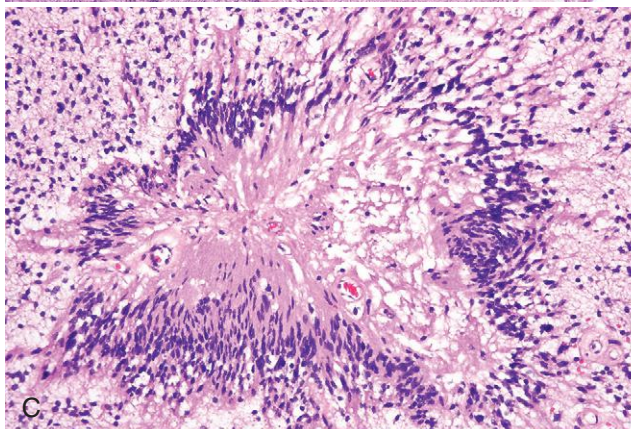
**FIGURE 6-28.** Schwannoma. **A**, Encapsulated tumor; **B**, Verocay bodies and adjacent Antoni type B tissue; **C**, Spindled cells in delicately collagenized and myxoid stroma typical for Antoni type B pattern; subtle nuclear palisading.



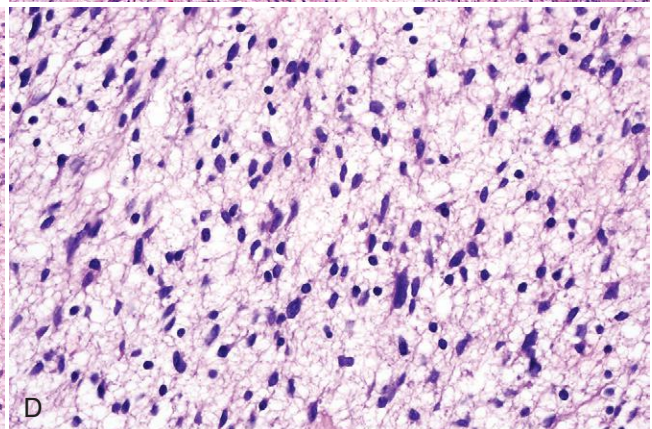
A



B



C



D

**FIGURE 6-29.** Ancient schwannoma. **A**, Encapsulated tumor with marked cystic degeneration of stroma; **B**, Spindle cell proliferation with pseudocysts and perivascular hyalinization, mostly Antoni type B tissue; **C**, Palisading of nuclei forming unusual Verocay body; **D**, Spindle cells with mild nuclear atypia.



## SOLITARY CIRCUMSCRIBED NEUROMA (PALISADED ENCAPSULATED NEUROMA)

### Etiopathogenesis and Histopathologic Features

Solitary circumscribed neuroma is likely a neoplastic proliferation of Schwann cells and neurites, possibly within a nerve.

- Approximately 75% of lesions occur on the palate or gingiva; the labial mucosa is the second most common site, and lesions occur in adults in their fifth decade.
- Circumscribed and sometimes partially encapsulated, unilobular, multilobular, or plexiform proliferation of Schwann cells, neurites, and fibroblasts occur in a delicately collagenized stroma; palisading of nuclei is characteristic; nuclei are ovoid or fusiform with dispersed chromatin and inconspicuous nucleoli; tissue clefts are a reliable feature (Figs. 6-30, A-C, 6-31 and 6-32); some lesions are predominantly myxoid.
- Spindle cells are S-100 positive; neurites are neurofilament protein positive (see Fig. 6-30, D), usually

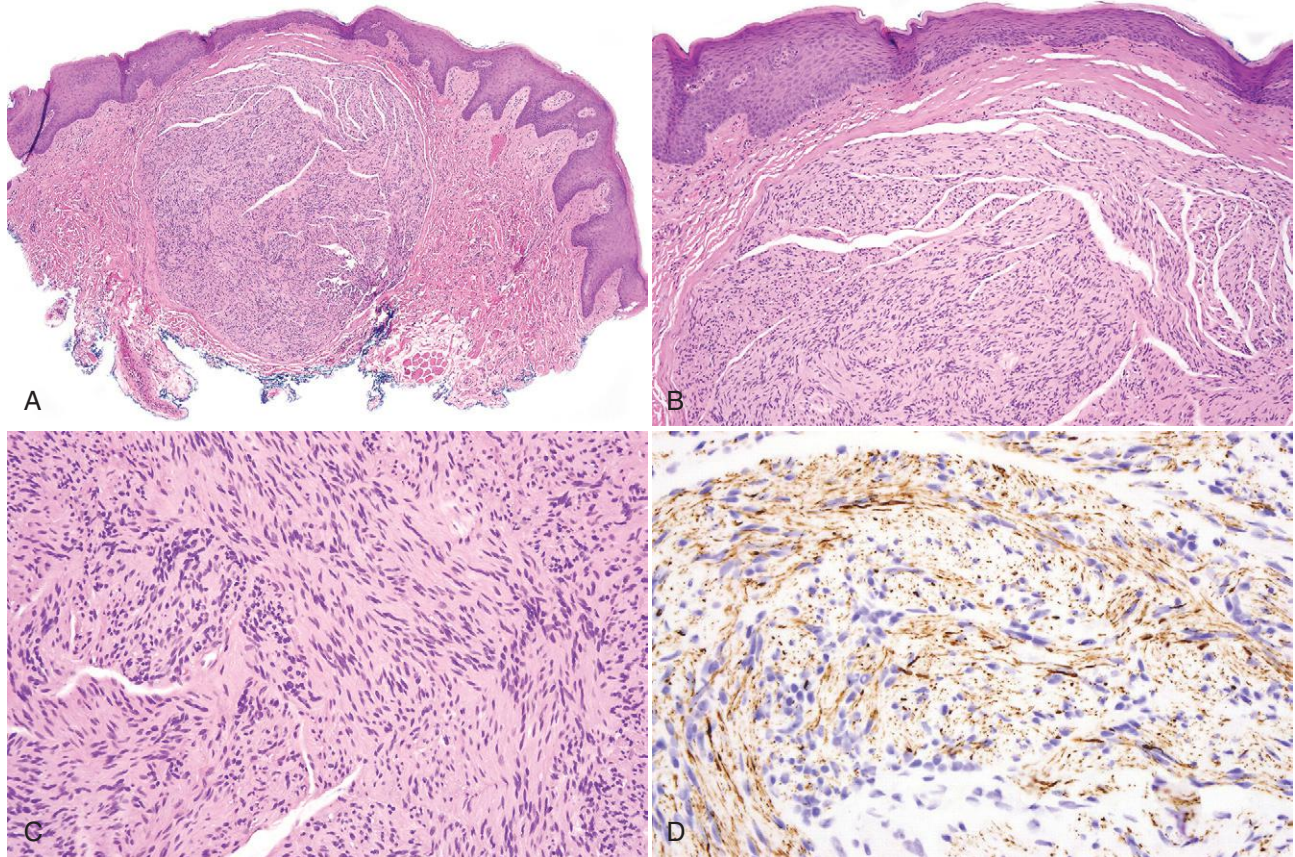
glial fibrillary acidic protein (GFAP) negative, and EMA, glucose transporter type 1 (GLUT-1), and claudin-1 positive cells around the lobules; epithelioid and vascular variants have been reported.

### Management and Prognosis

- Excision is treatment of choice; recurrence is rare.

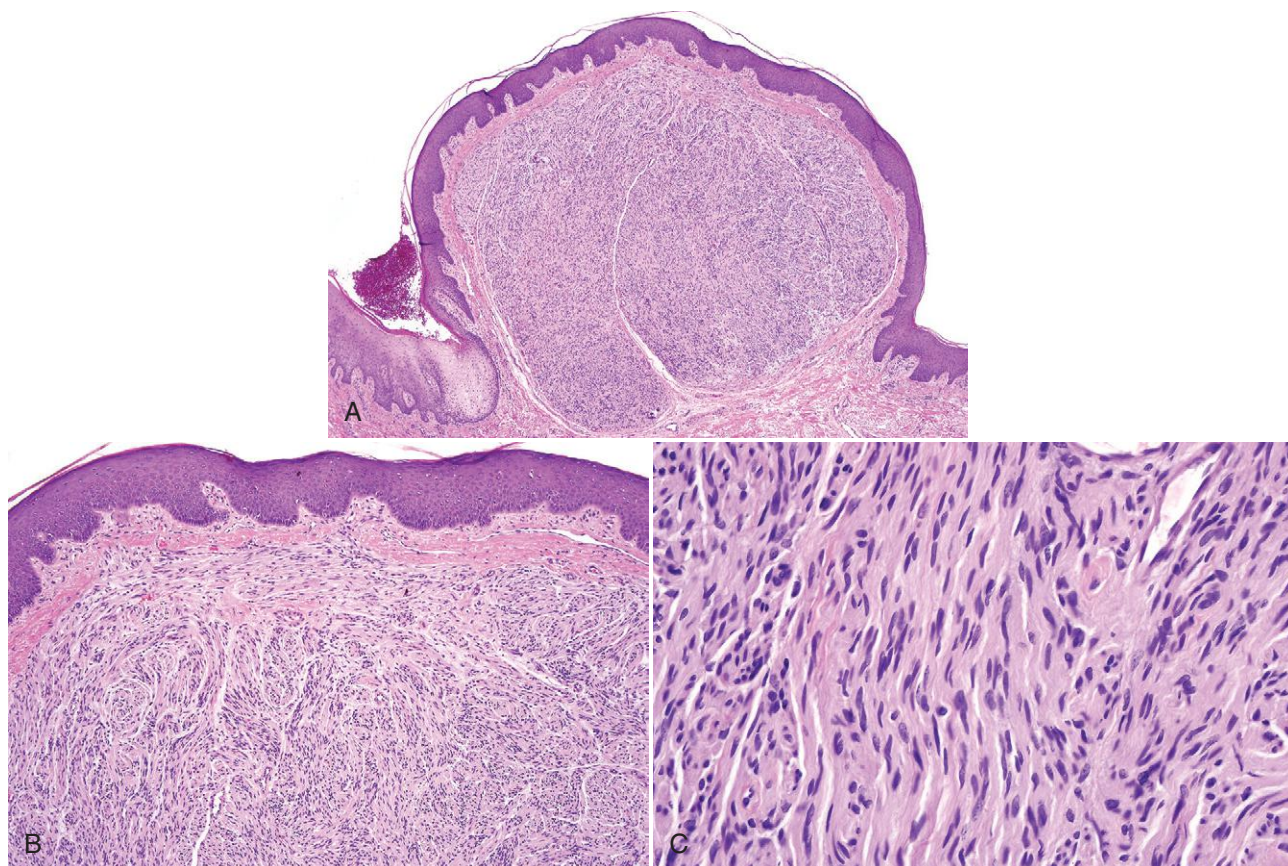
### REFERENCES

- Argenyi ZB, Penick GD. Vascular variant of palisaded encapsulated neuroma. *J Cutan Pathol.* 1993;20:92-93.
- Argenyi ZB, Cooper PH, Santa Cruz D. Plexiform and other unusual variants of palisaded encapsulated neuroma. *J Cutan Pathol.* 1993;20:34-39.
- Chauvin PJ, Wysocki GP, Daley TD, Pringle GA. Palisaded encapsulated neuroma of oral mucosa. *Oral Surg Oral Med Oral Pathol Oral Radiol Endod.* 1992;73:71-74.
- Koutlas IG, Scheithauer BW. Palisaded encapsulated ("solitary circumscribed") neuroma of the oral cavity: a review of 55 cases. *Head Neck Pathol.* 2010;4:15-26.
- Magnusson B. Palisaded encapsulated neuroma (solitary, circumscribed neuroma) of the oral mucosa. *Oral Surg Oral Med Oral Pathol Oral Radiol Endod.* 1996;83:302-304.
- Tsang WY, Chan JK. Epithelioid variant of solitary circumscribed neuroma of the skin. *Histopathology.* 1992;20:439-441.

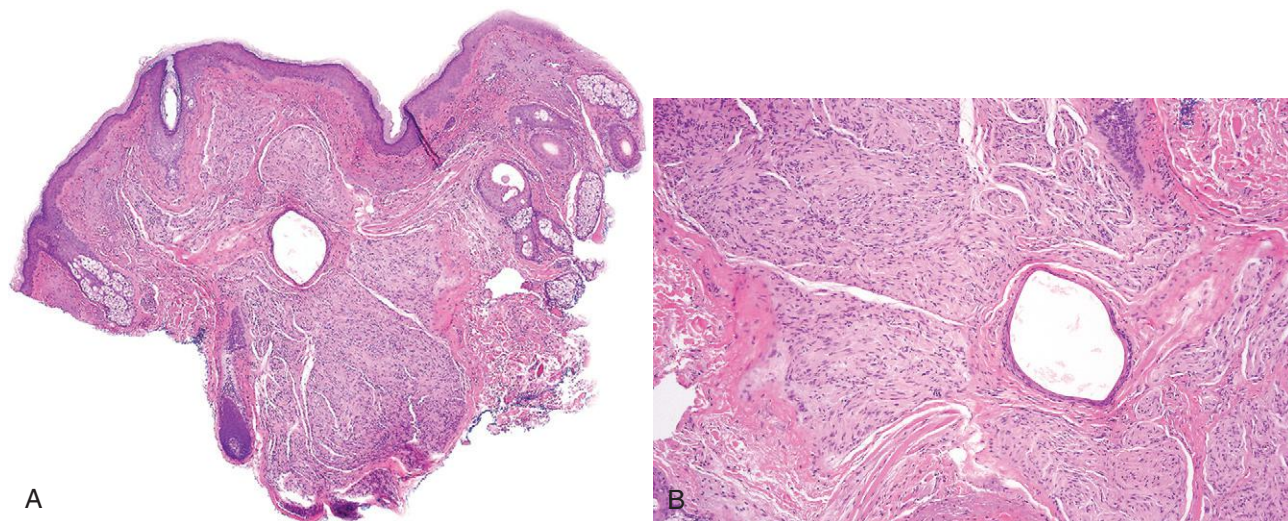


**FIGURE 6-30.** Solitary circumscribed neuroma. **A**, Circumscribed proliferation of spindle cells. **B**, Thin capsule, many clefts, and a suggestion of nuclear palisading. **C**, Spindle cells and neurites in fasciculated pattern. **D**, Neurofilament protein reveals the presence of numerous axons cut in various planes.





**FIGURE 6-31.** Solitary circumscribed neuroma. **A**, Circumscribed proliferation of spindle cells. **B**, Nonencapsulated tumor of spindle cells and neurites with nuclear palisading. **C**, Spindle cells with elongated, fusiform nuclei, and neurites.



**FIGURE 6-32.** Solitary circumscribed neuroma. **A**, Multilobular plexiform pattern. **B**, Plexiform proliferation of spindle cells and neurites with slight nuclear palisading.



## GRANULAR CELL TUMOR

### Clinical Findings

- Seen in adults; firm mass; may be slightly yellowish beneath intact epithelium; occurs more commonly on the tongue and lips; other sites include buccal mucosa and floor of the mouth (Fig. 6-33).

### Etiopathogenesis and Histopathologic Features

Granular cell tumor is believed to be of neural origin and stains for neural markers; cytoplasm is granular because of lysosomes.

- Nonencapsulated proliferation of cells with granular cytoplasm that sometimes contain eosinophilic globules; cells may be in sheets or nodules; cells often insinuate between skeletal muscle fibers; nuclei have dispersed chromatin and inconspicuous nucleoli without atypia or mitotic activity; overlying epithelium may exhibit pseudoepitheliomatous hyperplasia or be atrophic (Figs. 6-34 and 6-35, A-C).
- Cytoplasmic staining for S-100 protein, CD68, and PGP 9.5 (see Fig. 6-35, D and E).
- Plexiform granular cell tumor is a variant; it forms fascicles and nodules that encase nerves, vessels, and skin adnexa.

### Differential Diagnosis

- Congenital granular cell tumor occurs on the gingiva of neonates; tumor has arborizing small vessels, and it is S-100 negative.
- Primitive polypoid nonneural granular cell tumor often has a collarette of epithelial cells at the base, is S-100 negative, is NK1-C3 and CD68 positive, and may show nuclear atypia and mitotic activity.

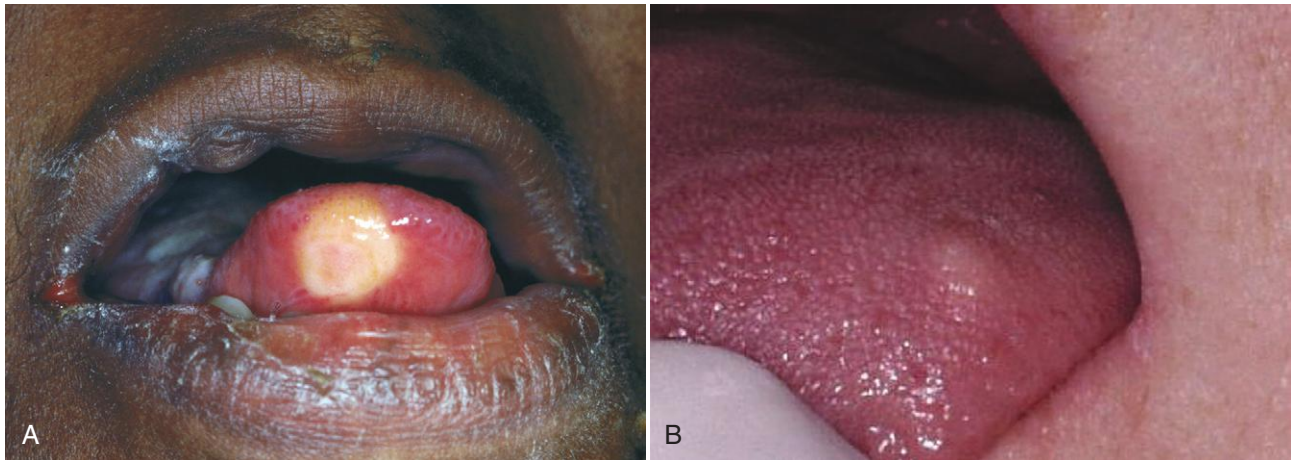
- Granular cells may be seen focally in other tumors such as benign histiocytoma and leiomyoma and may indicate degenerative change.
- Pseudoepitheliomatous hyperplasia does not show significant atypia of squamous cell carcinoma.

### Management and Prognosis

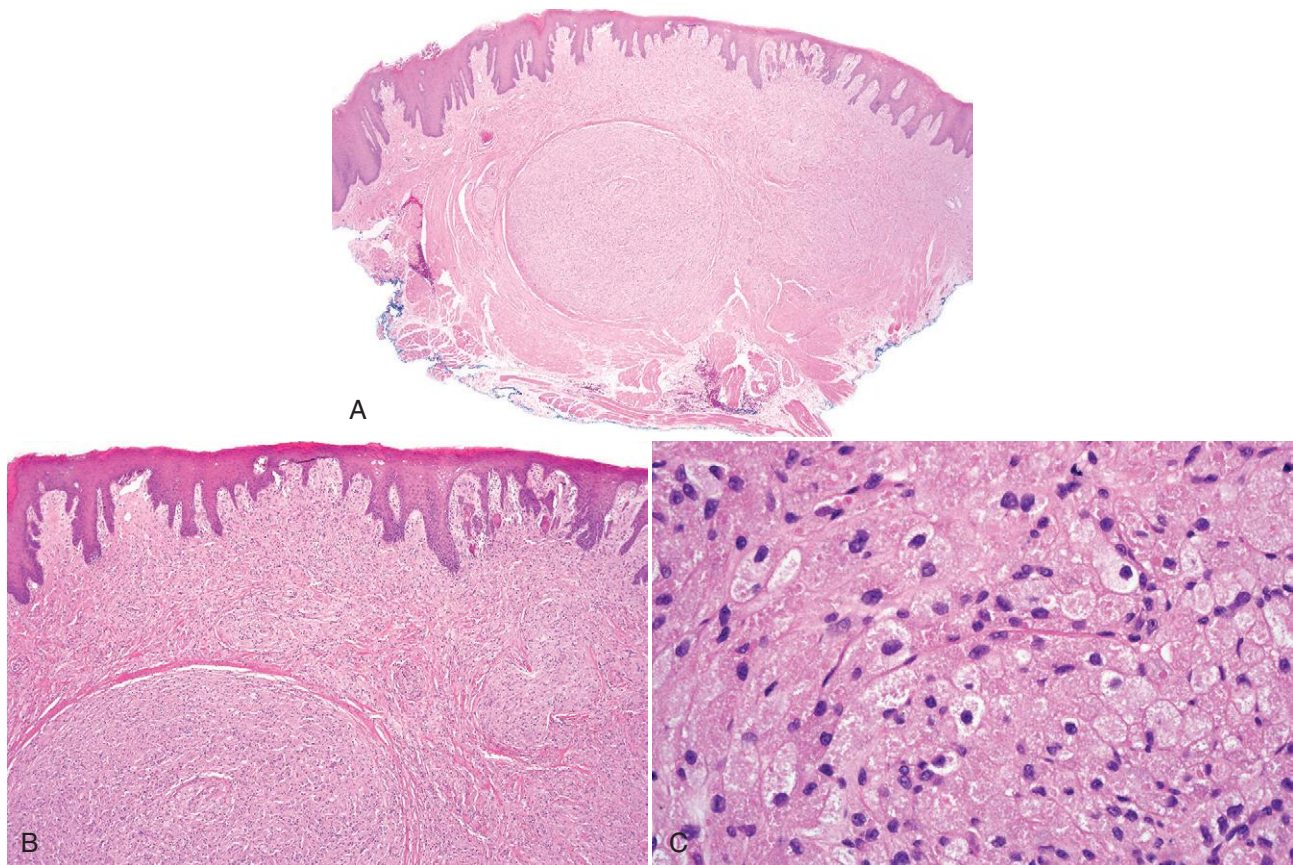
- Excision is curative; malignant forms are rare.

### REFERENCES

- Aldabagh B, Azmi F, Vadmal M, et al. Plexiform pattern in cutaneous granular cell tumors. *J Cutan Pathol.* 2009;36:1174-1176.
- Basile JR, Woo SB. Polypoid S-100-negative granular cell tumor of the oral cavity: a case report and review of literature. *Oral Surg Oral Med Oral Pathol Oral Radiol Endod.* 2003;96:70-76.
- Brannon RB, Anand PM. Oral granular cell tumors: an analysis of 10 new pediatric and adolescent cases and a review of the literature. *J Clin Pediatr Dent.* 2004;29:69-74.
- Chaudhry AP, Jacobs MS, SunderRaj M, et al. A clinico-pathologic study of 50 adult oral granular cell tumors. *J Oral Med.* 1984; 39:97-103.
- Fanburg-Smith JC, Meis-Kindblom JM, Fante R, Kindblom LG. Malignant granular cell tumor of soft tissue: diagnostic criteria and clinicopathologic correlation. *Am J Surg Pathol.* 1998;22: 779-794.
- Klima M, Peters J. Malignant granular cell tumor. *Arch Pathol Lab Med.* 1987;111:1070-1073.
- Lazar AJ, Fletcher CD. Primitive nonneural granular cell tumors of skin: clinicopathologic analysis of 13 cases. *Am J Surg Pathol.* 2005;29:927-934.
- Lee J, Bhawan J, Wax F, Farber J. Plexiform granular cell tumor. A report of two cases. *Am J Dermatopathol.* 1994;16:537-541.
- Mahalingam M, LoPiccolo D, Byers HR. Expression of PGP 9.5 in granular cell nerve sheath tumors: an immunohistochemical study of six cases. *J Cutan Pathol.* 2001;28:282-286.
- Nasser H, Danforth Jr RD, Sunbuli M, Dimitrijevic O. Malignant granular cell tumor: case report with a novel karyotype and review of the literature. *Ann Diagn Pathol.* 2010;14:273-278.
- Ordonez NG, Mackay B. Granular cell tumor: a review of the pathology and histogenesis. *Ultrastruct Pathol.* 1999;23:207-222.

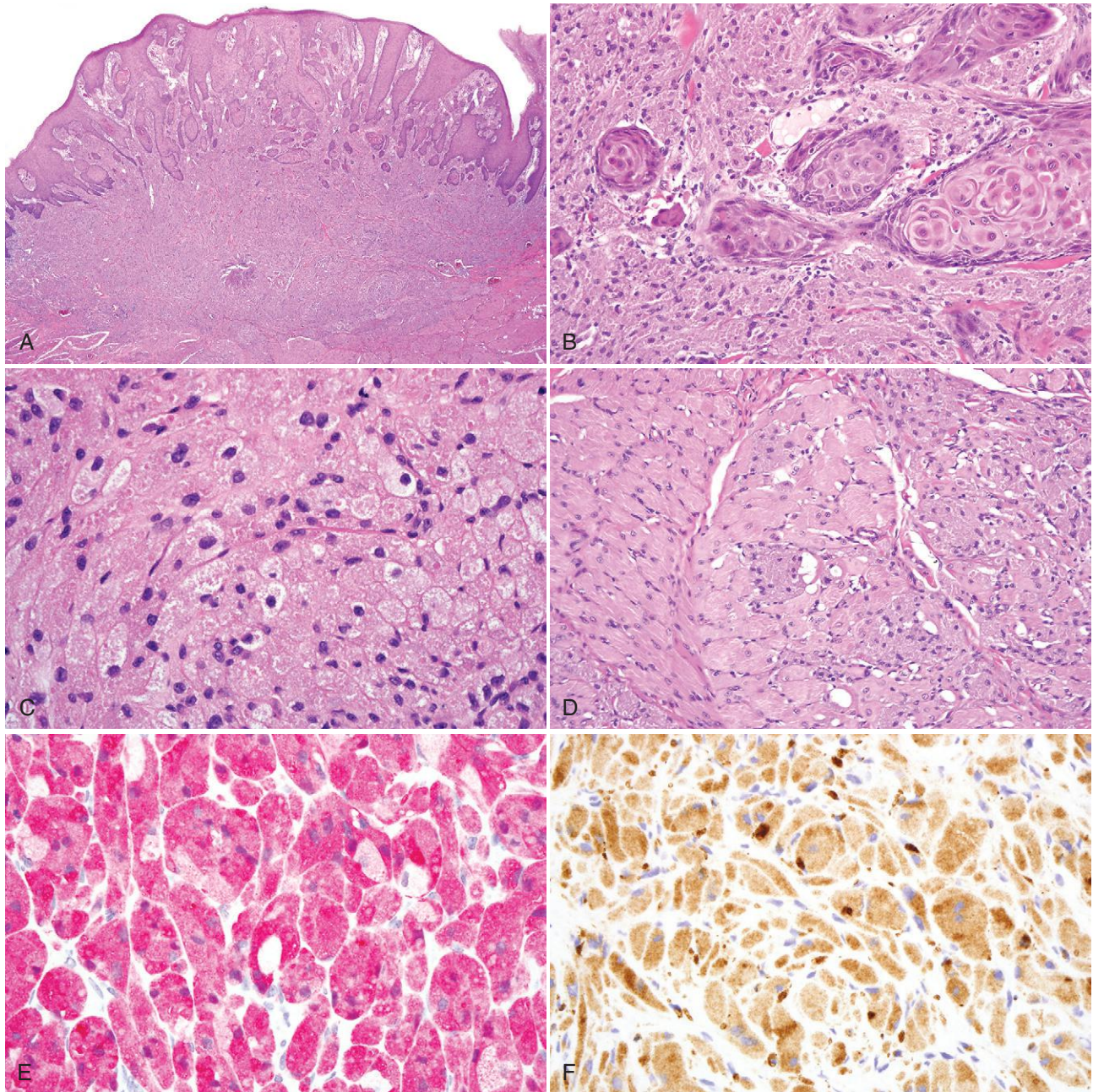


**FIGURE 6-33.** **A,** Granular cell tumor on the ventral tongue. **B,** Granular cell tumor on the tongue dorsum.



**FIGURE 6-34.** Granular cell tumor. **A,** Nodular growth pattern. **B,** Granular cells abut epithelium that exhibits slight pseudoepitheliomatous hyperplasia. **C,** Cells have granular cytoplasm and benign nuclei.





**FIGURE 6-35.** Granular cell tumor. **A**, Marked pseudoepitheliomatous hyperplasia. **B**, Epithelial islands have benign cytologic features. **C**, Granular cells with cytoplasmic eosinophilic globules. **D**, Granular cells nestled between myocytes. **E**, Cytoplasmic positivity for S-100 protein. **F**, Cytoplasmic positivity for CD68.

## SUBGEMMAL NEUROGENOUS PLAQUE (SUBEPITHELIAL NERVE PLEXUS)

### Clinical Findings

- Mucosa-colored papule or plaque is found on the posterior lateral tongue; sometimes it is associated with burning and usually occurs in adults in the sixth decade.

### Etiopathogenesis and Histopathologic Features

Subgemmal neurogenous plaque is thought by some to represent a reactive proliferation of Schwann cells, axons, perineurial cells, and endoneurial fibroblasts, possibly from trophic stimulation arising from gustatory nerve fibers.

- Delicate nerve plexus is composed of spindle cells with curvilinear nuclei; ganglion cells sometimes are seen in the deeper areas; overlying epithelium



contain taste buds typical for this site (Fig. 6-36, A-C); cytoplasm is positive for S-100 protein, neurofilament protein, and PGP9.5 (see Fig. 6-36, D and E).

### Differential Diagnosis

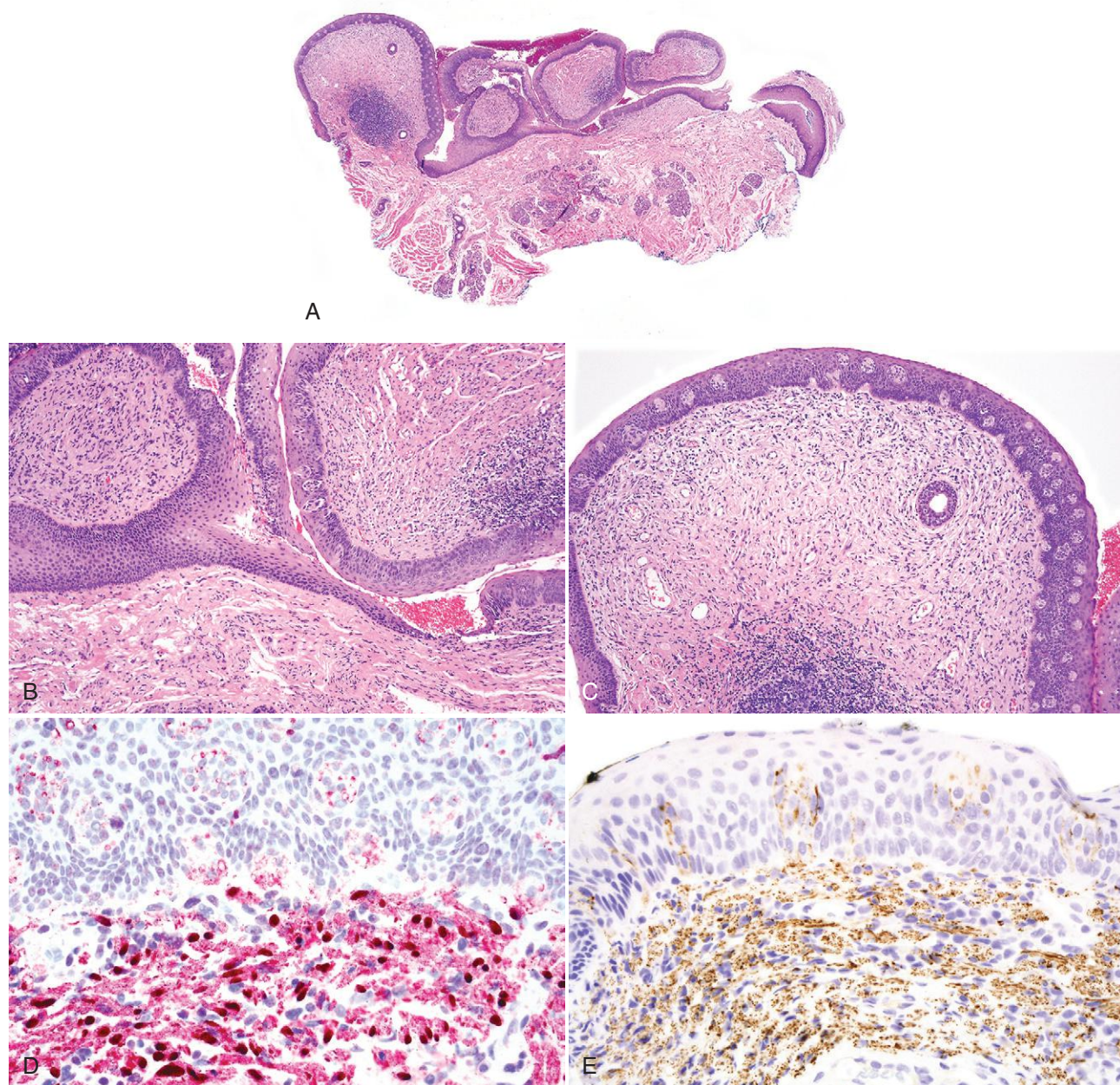
- Diffuse neurofibroma and traumatic neuroma may look similar, but this combination of nerve sheath cells and axons without scarring to differentiate them.
- It is not clear whether some subgemmal plaques represent normal neural plexi beneath the foliate papillae of the lateral tongue, because similar structures are noted beneath most taste buds.

### Management and Prognosis

- Excision is curative.

### REFERENCES

- Gueiros LA, Leon JE, Leao JC, et al. Subgemmal neurogenous plaque: clinical and microscopic evaluation of 7 cases. *Oral Surg Oral Med Oral Pathol Oral Radiol Endod.* 2009;108:920-924.
- McDaniel RK. Subepithelial nerve plexus (with ganglion cells) associated with taste buds. *Oral Surg Oral Med Oral Pathol Oral Radiol Endod.* 1999;87:605-609.
- Triantafyllou A, Coulter P. Structural organization of subgemmal neurogenous plaques in foliate papillae of tongue. *Hum Pathol.* 2004; 35:991-999.



**FIGURE 6-36.** Subgemmal neurogenous plaque. **A**, Multinodular plaque with serous glands in the tongue. **B**, Subepithelial mass of spindle cells and neurites. **C**, Delicate spindle cells and numerous taste buds in epithelium. **D**, Spindle cells and taste buds positive for S-100 protein. **E**, Spindle cells and taste buds positive for neurofilament protein.



## Muscle Tumors

### LEIOMYOMA AND ANGIOLEIOMYOMA (VASCULAR LEIOMYOMA)

#### Clinical Findings

Painless nodule usually is present in the upper lip (50% of cases) of adults; the palate is the second most common site (25% of cases) (Fig. 6-37).

#### Etiopathogenesis and Histopathologic Features

This benign neoplasm shows differentiation toward smooth muscle.

- Unencapsulated, discrete proliferation of smooth muscle cells appear in sweeping fascicles; in angioleiomyoma or vascular leiomyoma, fascicles may show a whorled configuration around a central endothelium-lined space; smooth muscle cells have pale, eosinophilic, vacuolated cytoplasm, and elongated, sometimes cigar-shaped, nuclei (Figs. 6-38, A and B, 6-39, and 6-40, A-C).
- Cytoplasm is positive for smooth muscle actin, muscle-specific actin, and desmin (see Figs. 6-38, C and 6-40, D); there is no evidence of cytologic atypia.
- Granular cell and epithelioid variants have been reported.

#### Differential Diagnosis

- Myofibroma has a chondroid-appearing stroma, may have zoning phenomenon, and occurs in younger patients.
- Nodular fasciitis shows a proliferation of spindle cells with “tissue culture” appearance, abundant myxoid

or mucinous stroma, often multinucleated giant cells, and a mixed inflammatory infiltrate; borders are not sharply demarcated, and there is cytoplasmic positivity for smooth muscle actin and muscle-specific actin.

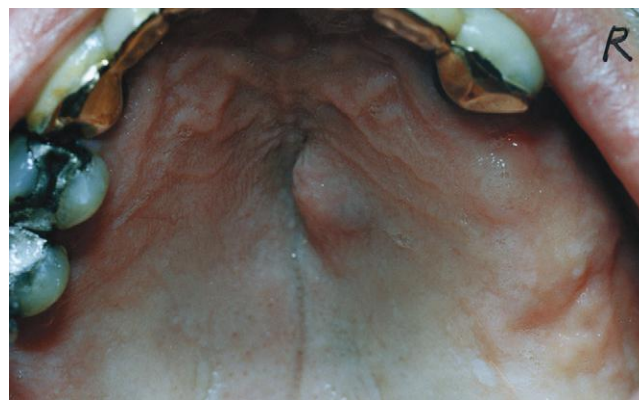- Leiomyosarcoma and fibrosarcoma exhibit cytologic atypia, and high-grade lesions show pleomorphism and mitotic activity.
- Sarcomatoid carcinoma exhibits significant cytologic atypia and positivity for pancytokeratin (see Chapter 11).

#### Management and Prognosis

- Excision is curative.

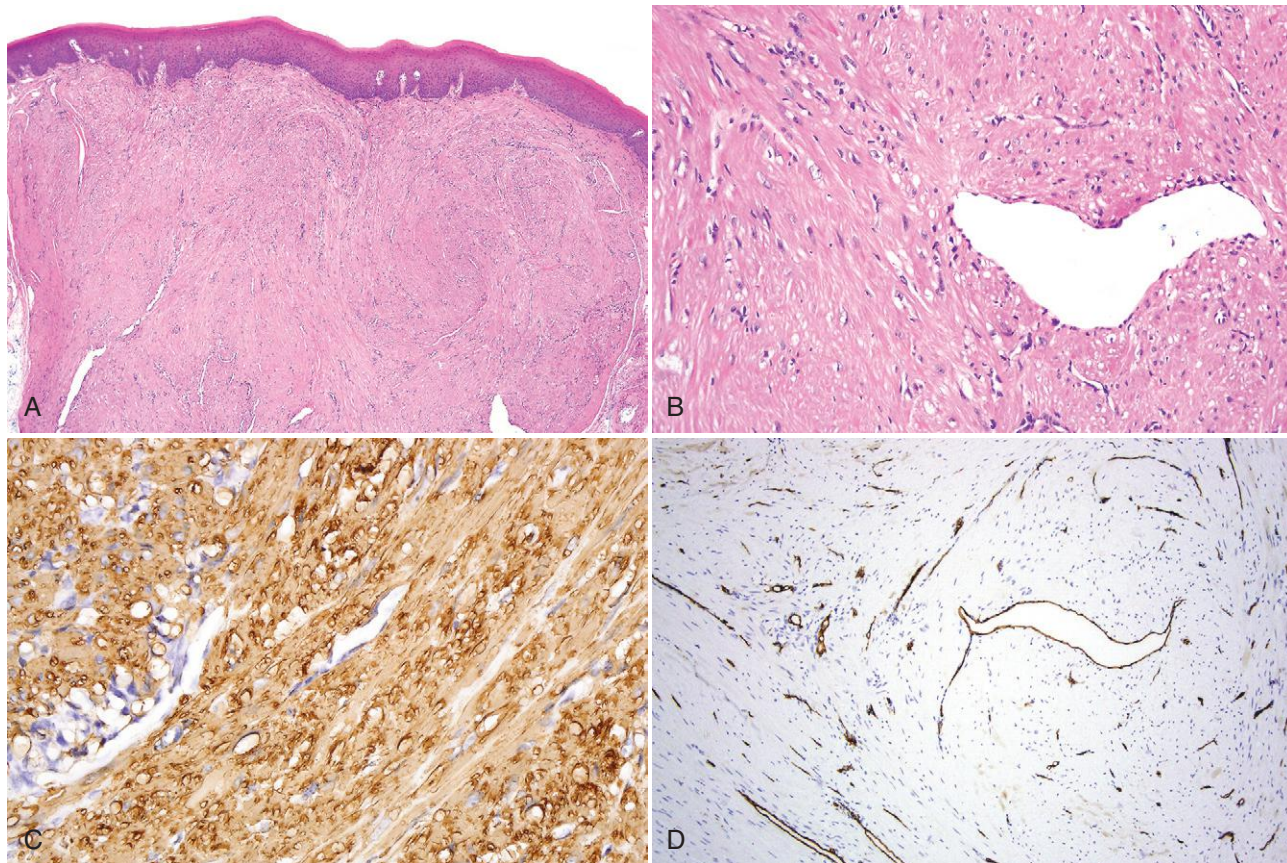
#### REFERENCES

- Baden E, Doyle JL, Lederman DA. Leiomyoma of the oral cavity: a light microscopic and immunohistochemical study with review of the literature from 1884 to 1992. *Eur J Cancer B Oral Oncol.* 1994;30B:1-7.
- Bhattacharyya I, Summerlin DJ, Cohen DM, et al. Granular cell leiomyoma of the oral cavity. *Oral Surg Oral Med Oral Pathol Oral Radiol Endod.* 2006;102:353-359.
- Brooks JK, Nikitakis NG, Goodman NJ, Levy BA. Clinicopathologic characterization of oral angioleiomyomas. *Oral Surg Oral Med Oral Pathol Oral Radiol Endod.* 2002;94:221-227.
- Dayan D, Nasrallah V, Vered M. Clinico-pathologic correlations of myofibroblastic tumors of the oral cavity: 1. Nodular fasciitis. *J Oral Pathol Med.* 2005;34:426-435.
- Gaitan Cepeda LA, Quezada Rivera D, Tenorio Rocha F, et al. Vascular leiomyoma of the oral cavity. Clinical, histopathological and immunohistochemical characteristics. Presentation of five cases and review of the literature. *Med Oral Patol Oral Cir Bucal.* 2008;13:E483-E488.
- Koutlas IG, Manivel JC. Epithelioid leiomyoma of the oral mucosa. *Oral Surg Oral Med Oral Pathol Oral Radiol Endod.* 1996;82:670-673.

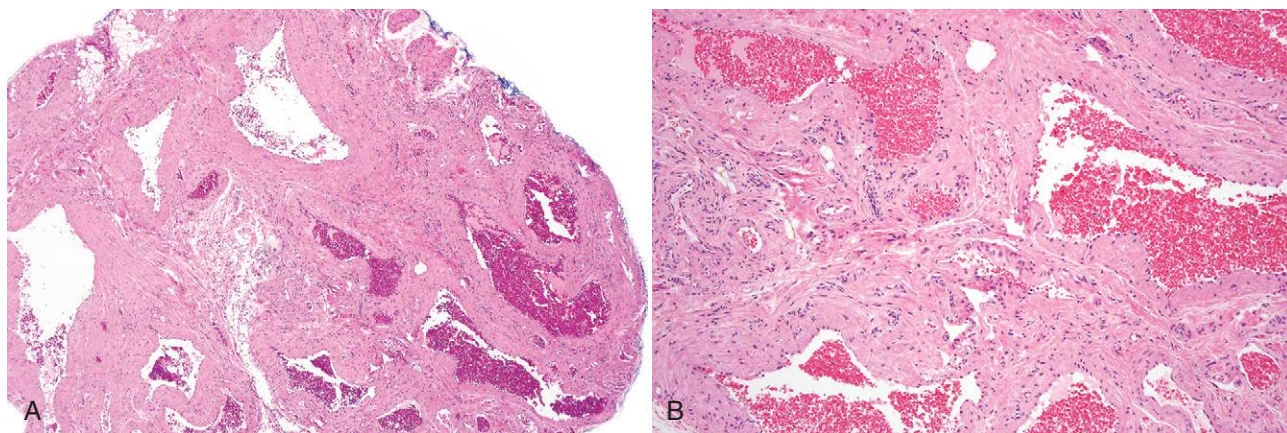


**FIGURE 6-37.** Angioleiomyoma of the hard palatal mucosa. (Courtesy of Dr. Sherwin Kershman, private practice, Houston, Tex.)



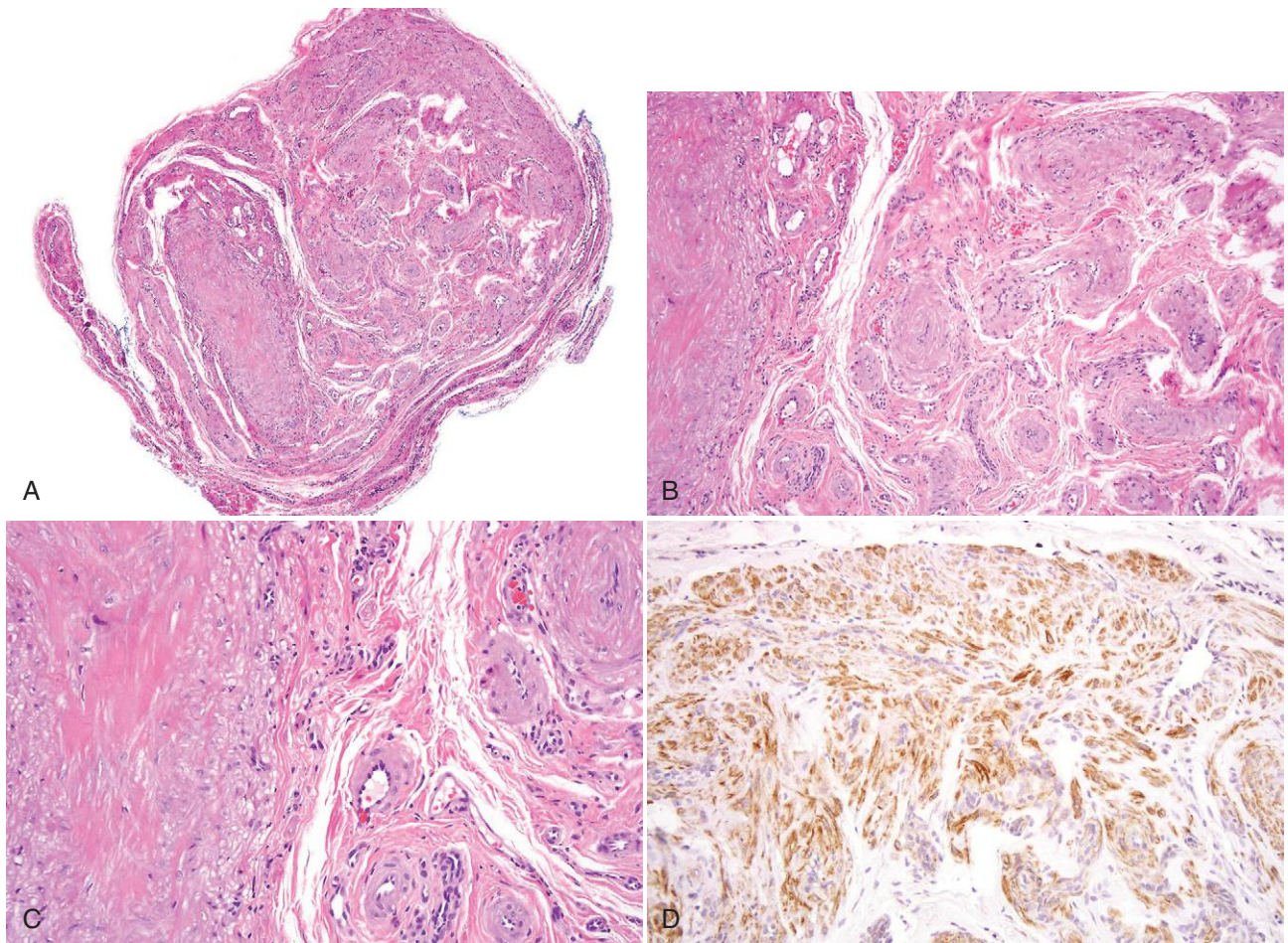


**FIGURE 6-38.** Leiomyoma. **A**, Nonencapsulated spindle cell proliferation. **B**, Pale spindle cells with vacuolated cytoplasm and scattered vascular channels. **C**, Spindle cells are smooth muscle actin positive. **D**, CD31 reveals many vessels.



**FIGURE 6-39.** Vascular leiomyoma. **A**, Many dilated vascular channels. **B**, Proliferation of smooth muscle around vessels.





**FIGURE 6-40.** Vascular leiomyoma. **A**, Thinly encapsulated spindle cell tumor. **B**, Whorls of spindle cells around small vascular spaces. **C**, Cells with pale eosinophilic and vacuolated cytoplasm. **D**, Spindle cells are smooth muscle actin positive.



## ADULT RHABDOMYOMA

Unlike the more common cardiac rhabdomyoma, extracardiac rhabdomyomas are not associated with tuberous sclerosis or other phakomatosis. More than 90% of adult extracardiac rhabdomyomas occur in the head and neck, especially in the larynx and pharynx. Adult (more common) and fetal types (in children) are recognized.

### Clinical Findings

- Adults in sixth to seventh decade with 3 to 1 male predilection.
- Mucosal, nontender mass in the tongue or larynx or pharynx causing obstructive symptoms; 3% to 5% are multifocal.

### Etiopathogenesis and Histopathologic Features

This benign neoplasm shows differentiation toward skeletal muscle fibers.

- Encapsulated proliferation of large, polyhedral cells with brightly eosinophilic cytoplasm that are often vacuolated, but not to the extent of cardiac rhabdomyomas (Fig. 6-41, A-C); small nuclei with indistinct nucleoli; muscle striations and rodlike inclusions can be seen with phosphotungstic acid and trichrome stains (see Fig. 6-41, D); cells contain glycogen that is

positive with periodic acid–Schiff stain and diastase labile; there is scant stroma.

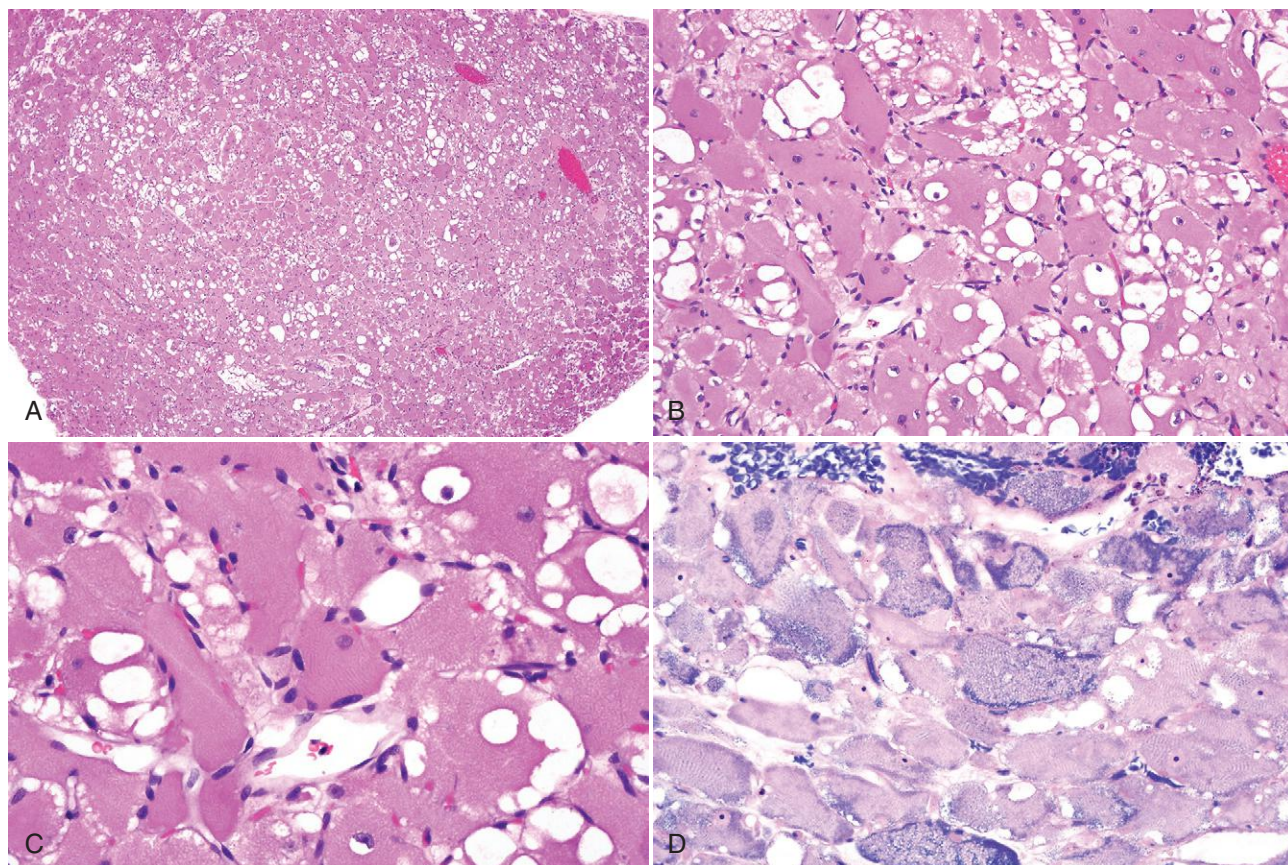
- Cells are positive for muscle-specific actin, desmin, and myoglobin.
- Fetal type features spindle cells with myotubules and rhabdomyoblast-like cells in a myxoid stroma.

### Management and Prognosis

- Excision is treatment of choice; recurrence rate is up to 40% mainly because of incomplete excision.

### REFERENCES

- Curatolo P, Bombardieri R, Jozwiak S. Tuberous sclerosis. *Lancet*. 2008;372:657-668.
- Delides A, Petrides N, Banis K. Multifocal adult rhabdomyoma of the head and neck: a case report and literature review. *Eur Arch Otorhinolaryngol*. 2005;262:504-506.
- Fletcher C, Unni K, Mertens F, eds. *World Health Organization Pathology and Genetics: Tumours of Soft Tissue and Bone*. Lyon, France: IARC Press; 2002.
- Kapadia SB, Meis JM, Frisman DM, et al. Adult rhabdomyoma of the head and neck: a clinicopathologic and immunophenotypic study. *Hum Pathol*. 1993;24:608-617.
- Papasprou G, Werner JA, Roessler M, et al. Adult rhabdomyoma in the parapharyngeal space: report of 2 cases and review of the literature. *Am J Otolaryngol*. 2010;32:240-246.
- Parara E, Christopoulos P, Tosios K, et al. A swelling of the floor of the mouth. *Oral Surg Oral Med Oral Pathol Oral Radiol Endod*. 2010;109:12-16.



**FIGURE 6-41.** Rhabdomyoma. **A**, Sheets of polyhedral cells with vacuolations. **B**, Polyhedral cells with abundant vacuolated, eosinophilic cytoplasm, and small nuclei. **C**, Cells have small nuclei with inconspicuous nucleoli, and cytoplasm contains cross striations. **D**, Phosphotungstic acid stain showing striations.



## EMBRYONAL RHABDOMYOSARCOMA

Rhabdomyosarcoma is the most common soft tissue sarcoma in children (accounting for 3% of childhood malignancies); the embryonal rhabdomyosarcoma is the most common type. Alveolar rhabdomyosarcoma tends to occur on the extremities, and it usually shows translocation t(2;13)(q35;14) leading to PAX3-FOXO1 fusion; sclerosing and spindle cell are other subtypes.

### Clinical Findings

- Usually occurs in the first decade, often younger than age 5; approximately 50% occur in the head and neck with the genitourinary tract being next most common site
- Rapidly growing mass in the cheek, buccal mucosa, or tongue

### Etiopathogenesis and Histopathologic Features

Embryonal rhabdomyosarcoma is a malignant neoplasm that recapitulates embryonic striated muscle and includes botryoid, spindle cell, and anaplastic subtypes; deletions on short arm of chromosome 11 are often seen.

- *Embryonal type*: stellate-shaped, small ovoid, and spindle cells with cellular compact areas and less cellular myxoid areas; differentiation leads to cells with eccentric nuclei and more abundant eosinophilic cytoplasm and characteristic “strap” cells (Fig. 6-42)
- *Botryoid type*: multinodular growth pattern with similar cells but with a hypercellular area (cambium layer) just beneath the epithelium
- *Anaplastic type*: anaplastic cells with atypical, hyperchromatic, and pleomorphic nuclei often with bizarre mitotic figures
- *Spindle cell type*: spindle cells with rhabdomyoblastic or smooth muscle features in a storiform or fasciculated pattern; controversial as to whether this belongs within this category

- Less differentiated cells vimentin positive; more differentiated cells desmin, muscle-specific actin, myoglobin, and Myo-D1 (nuclear staining) positive

### Differential Diagnosis

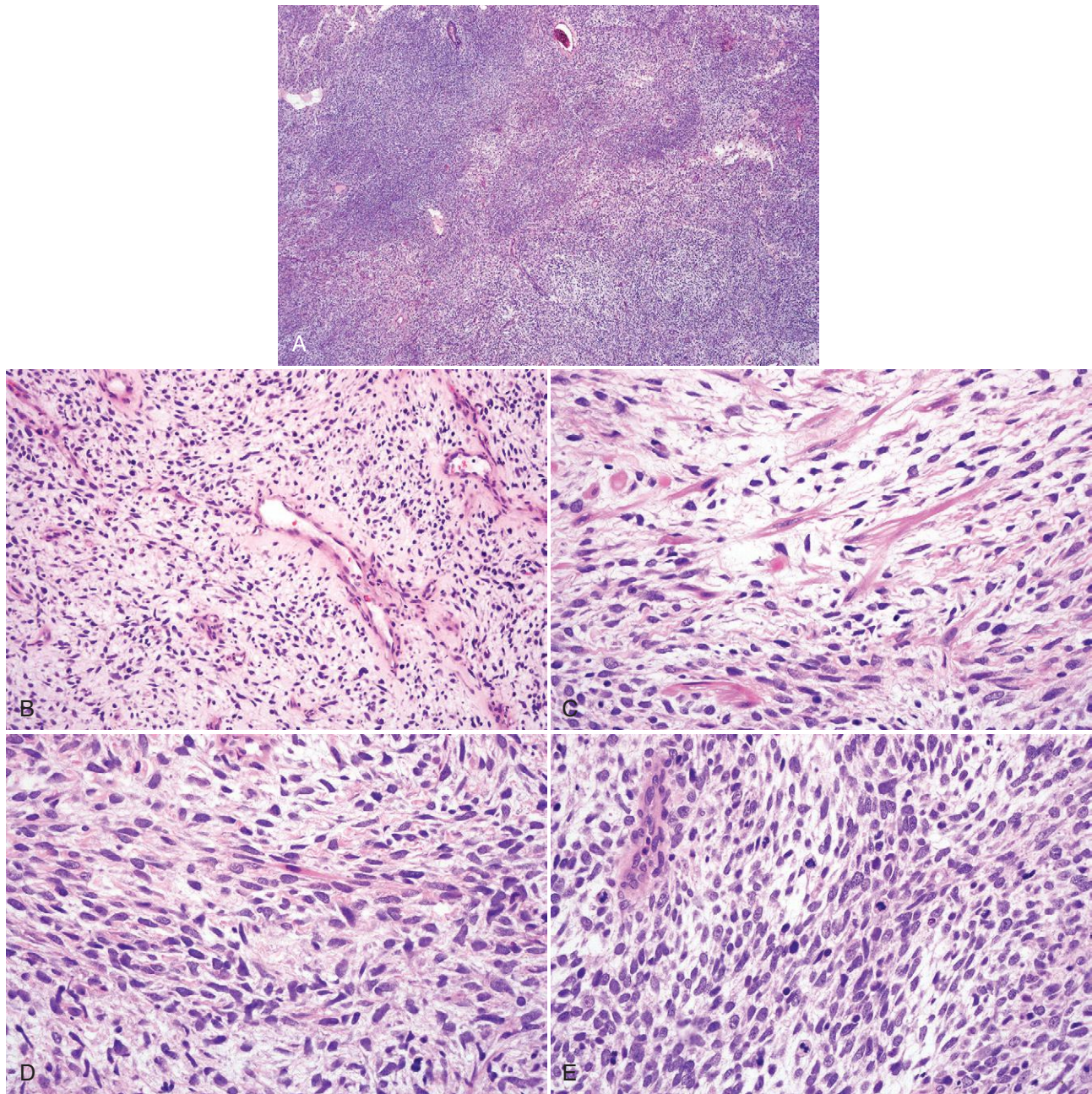
- Fetal rhabdomyomas do not show nuclear atypia.
- Lymphoma, neuroblastoma, primitive neuroectodermal tumor, and other small blue cell tumors must be ruled out with immunohistochemical studies.

### Management and Prognosis

- Surgical excision is treatment of choice with adjuvant radiotherapy as needed; new protocols that include chemotherapy have improved 5-year survival to 70%.
- Prognosis is dependent on stage, histologic type (embryonal tumors have better prognosis than alveolar or anaplastic types), age (patients younger than 10 years old fare better), and site (orbital and head and neck nonparameningeal tumors have better outcome).

### REFERENCES

- Fletcher C, Unni K, Mertens F, eds. *World Health Organization Pathology and Genetics: Tumours of Soft Tissue and Bone*. Lyon, France: IARC Press; 2002.
- Hostein I, Andraud-Fregeville M, Guillou L, et al. Rhabdomyosarcoma: value of myogenin expression analysis and molecular testing in diagnosing the alveolar subtype: an analysis of 109 paraffin-embedded specimens. *Cancer*. 2004;101:2817-2824.
- Newton WA Jr, Soule EH, Hamoudi AB, et al. Histopathology of childhood sarcomas, Intergroup Rhabdomyosarcoma Studies I and II: clinicopathologic correlation. *J Clin Oncol*. 1988;6:67-75.
- Raney RB, Anderson JR, Barr FG, et al. Rhabdomyosarcoma and undifferentiated sarcoma in the first two decades of life: a selective review of intergroup rhabdomyosarcoma study group experience and rationale for Intergroup Rhabdomyosarcoma Study V. *J Pediatr Hematol Oncol*. 2001;23:215-220.
- Raney RB, Maurer HM, Anderson JR, et al. The Intergroup Rhabdomyosarcoma Study Group (IRSG): major lessons from the IRS-I through IRS-IV studies as background for the current IRS-V treatment protocols. *Sarcoma*. 2001;5:9-15.



**FIGURE 6-42.** Embryonal rhabdomyosarcoma. **A**, Cellular tumor with myxoid areas. **B**, Ovoid and spindled tumor cells with dark nuclei in myxoid stroma. **C**, More differentiated tumor cells are polygonal or elongated with eosinophilic cytoplasm. **D**, Moderate nuclear pleomorphism and "strap" cell. **E**, More cellular area with mitotic figures.



# 7

# ULCERATIVE AND INFLAMMATORY CONDITIONS

## CHAPTER CONTENTS

ULCERATIVE CONDITIONS 137

Recurrent Aphthous Ulcers and Traumatic Ulcers 137

Traumatic Ulcerative Granuloma (Traumatic Ulcerative Granuloma With Stromal Eosinophils, Eosinophilic Ulcer of Tongue) 140

NONSPECIFIC INFLAMMATORY CONDITIONS 143

Nonspecific Irritant Contact Stomatitis 143

Frictional Blisters 145

Chronic Gingivitis 145

Foreign Body Gingivitis 148

## Ulcerative Conditions

### RECURRENT APHTHOUS ULCERS AND TRAUMATIC ULCERS

Most cases of recurrent aphthae are idiopathic; however, aphthous-like lesions are seen in Behçet disease, Crohn disease (often linear in the sulcus), hematinic deficiencies, some hypersensitivity reactions (to food, sodium lauryl sulfate found in toothpaste), cyclic neutropenia, and HIV infection. Complex aphthosis is often used to describe lesions associated with syndromes affecting the skin. Ulcers in children may be part of periodic fever, aphthosis, pharyngitis, and adenopathy (PFAPA) syndrome. Trauma and stress bring on episodes in susceptible individuals. Minor aphthous ulcers do not tend to be biopsied because of the typical history and presentation, whereas major ulcers are biopsied to rule out vesiculobullous disease. Chemotherapy-induced ulcerations are much larger, resolve predictably over 1 to 2 weeks, and are not aphthous ulcers.

#### Traumatic Ulcers

Traumatic ulcers are caused by trauma—usually on buccal mucosa, tongue, and lower lip (also on sites of morsicatio mucosae oris)—and are indistinguishable histologically from recurrent aphthous ulcers. They also occur secondarily on lesions that protrude (e.g., fibromas and gingival nodules).

#### Clinical Findings

- Recurrent aphthous ulcers begin in the second and third decades of life and diminish in severity with age; ulcers are episodic or continuous and only on the nonkeratinized mucosa, although tongue dorsum may be involved in hematinic deficiency; a yellow

fibrin membrane with surrounding erythema is present (Fig. 7-1, A-C).

- Minor ulcers are the most common, are smaller than 1 cm in size, and last 1 to 2 weeks; major ulcers are the least common, are larger than 1 cm in size, last for weeks or months, and often are associated with scarring—this form is often seen in HIV/AIDS. Herpetiform ulcers are uncommon and number more than 10 minor ulcers at each episode; severe aphthous ulcers present as continuous ulcerations.
- Traumatic ulcers can occur whenever there is history of trauma, particularly if the area is protuberant (see Fig. 7-1, D and E).

#### Etiopathogenesis and Histopathologic Features

Most cases of recurrent aphthae have a strong family history of recurrent aphthae, and some HLA-A haplotypes have been identified. TNF- $\alpha$  plays an important role in etiopathogenesis.

- Fibrin membrane with enmeshed neutrophils and underlying granulation tissue with acute and chronic inflammatory cells confined to the lamina propria; adjacent epithelium exhibits spongiotic pustules and reactive atypia (such as multinucleated epithelial cells and basal cell hyperplasia) (Fig. 7-2); traumatic ulcers often show adjacent hyperparakeratosis and surface bacterial colonies.
- Early or healing lesions show subepithelial fibrin deposition, spongiotic pustules, reactive epithelial atypia with multinucleated epithelial cells, and often intraepithelial hemorrhage (Fig. 7-3).
- Spread of inflammation to underlying muscle may lead to presence of eosinophils and histiocyte-like mononuclear cells (Fig. 7-4) (see [Traumatic Ulcerative Granulomas](#) later in this chapter.)

### Differential Diagnosis

- Evaluate for herpes simplex virus in the adjacent epithelium, and cytomegalovirus and fungi in the lamina propria in immunocompromised patients.
- Neutropenic ulcers have scarce neutrophils (Fig. 7-5).
- Medication-induced oral ulcers are not strictly aphthae and are particularly dramatic in patients on mammalian target of rapamycin (mTOR) inhibitors.
- Coagulation of the epithelium suggests concomitant contact with a caustic agent.

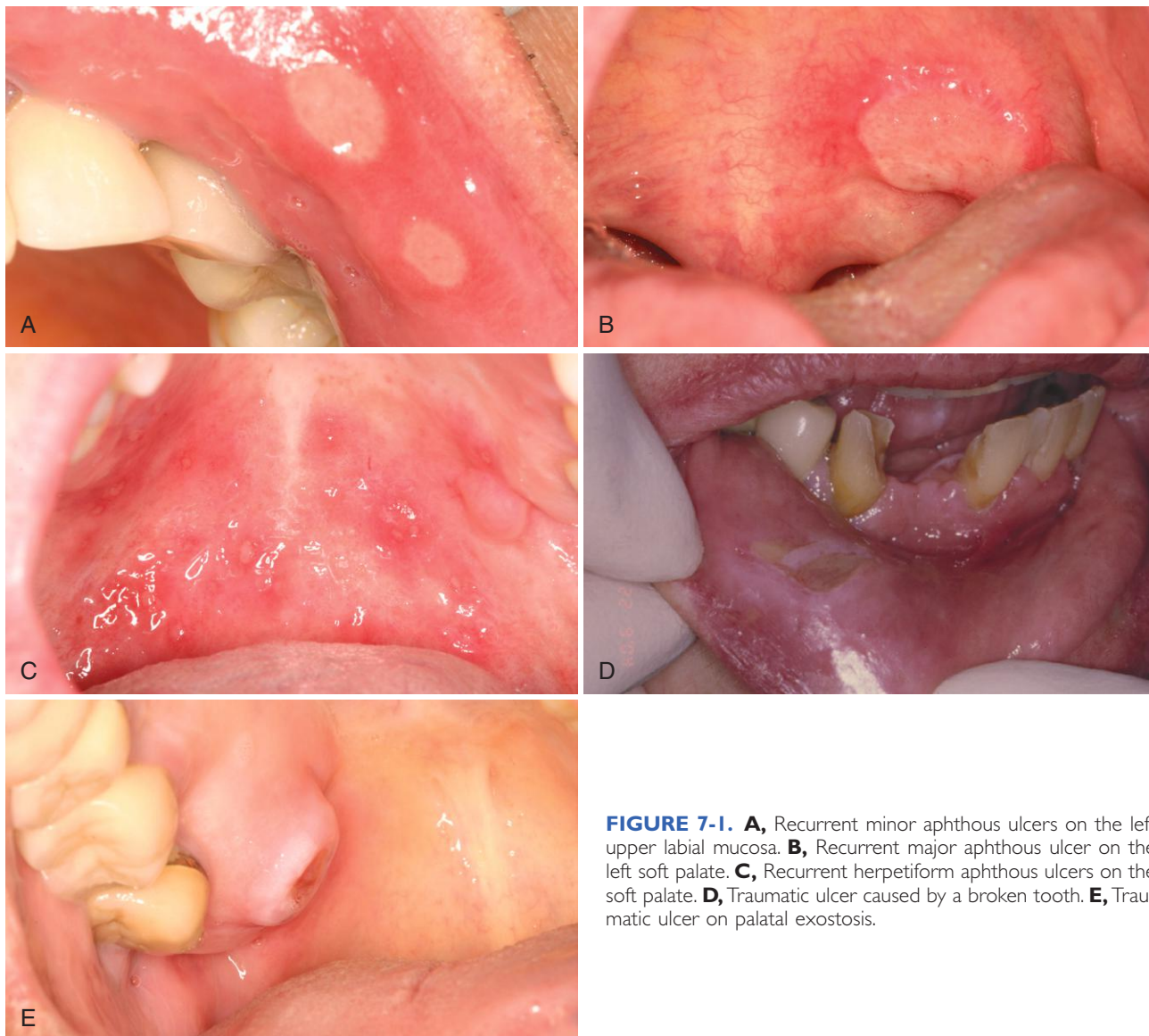### Management and Prognosis

- Topical or systemic steroid therapy or other immunosuppressive agents (see Appendix A) and topical analgesia are indicated.
- For systemic conditions presenting with aphthous-like ulcers, careful history-taking and work-up are important.

- Adenotonsillectomy may be effective in some patients with PFAPA syndrome.

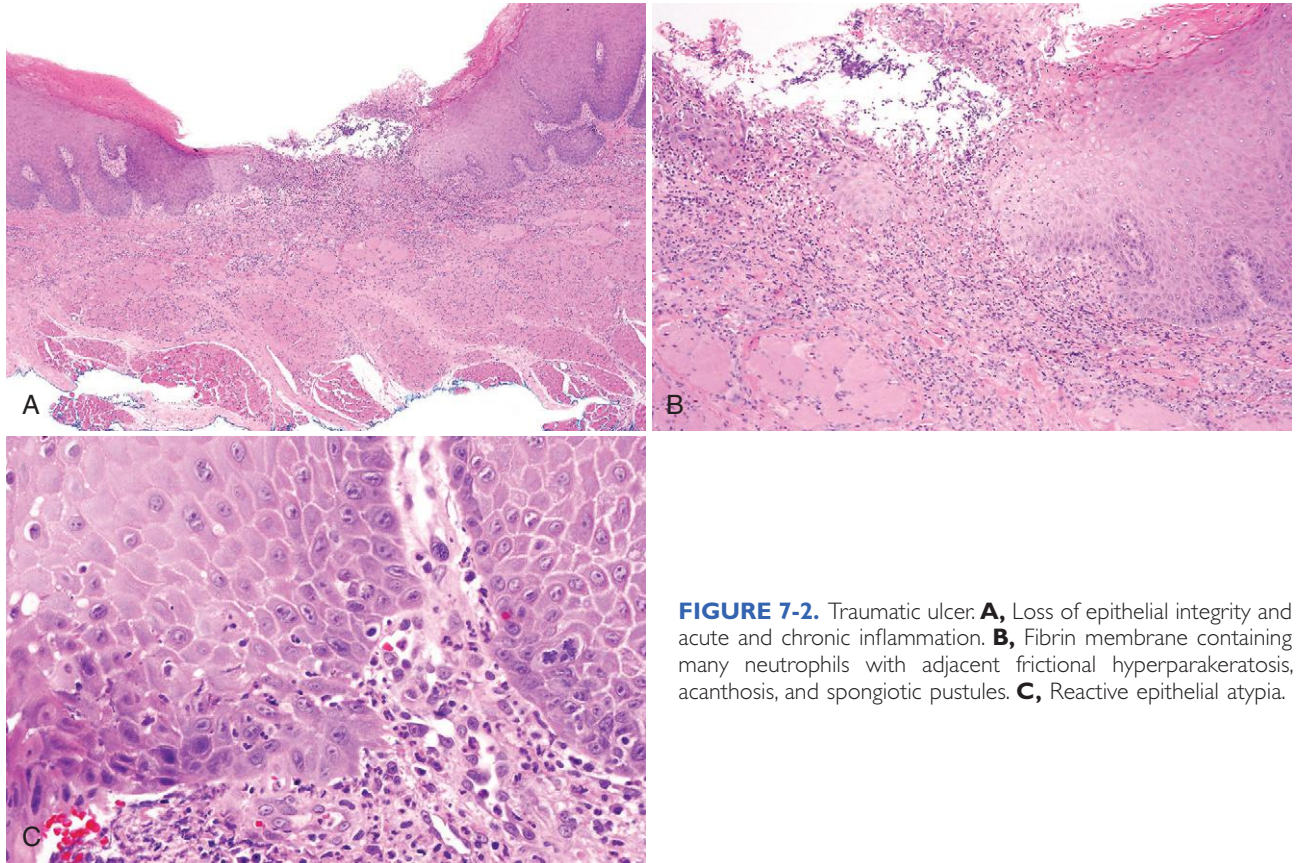
### REFERENCES

- Albanidou-Farmaki E, Deligiannidis A, Markopoulos AK, et al. HLA haplotypes in recurrent aphthous stomatitis: a mode of inheritance? *Int J Immunogenet.* 2008;35:427-432.
- Burton MJ, Pollard AJ, Ramsden JD. Tonsillectomy for periodic fever, aphthous stomatitis, pharyngitis and cervical adenitis syndrome (PFAPA). *Cochrane Database Syst Rev.* 2010;CD008669.
- Feder HM, Salazar JC. A clinical review of 105 patients with PFAPA (a periodic fever syndrome). *Acta Paediatr.* 2010;99:178-184.
- Gattorno M, Caorsi R, Meini A, et al. Differentiating PFAPA syndrome from monogenic periodic fevers. *Pediatrics.* 2009;124:e721-728.
- Jurge S, Kuffer R, Scully C, Porter SR. Mucosal disease series. Number VI. Recurrent aphthous stomatitis. *Oral Disease.* 2006;12:1-21.
- Mendes D, Correia M, Barbedo M, et al. Behçet's disease—a contemporary review. *J Autoimmun.* 2009;32:178-188.
- Schena FP, Pascoe MD, Alberu J, et al. Conversion from calcineurin inhibitors to sirolimus maintenance therapy in renal allograft recipients: 24-month efficacy and safety results from the CONVERT trial. *Transplantation.* 2009;87:233-242.

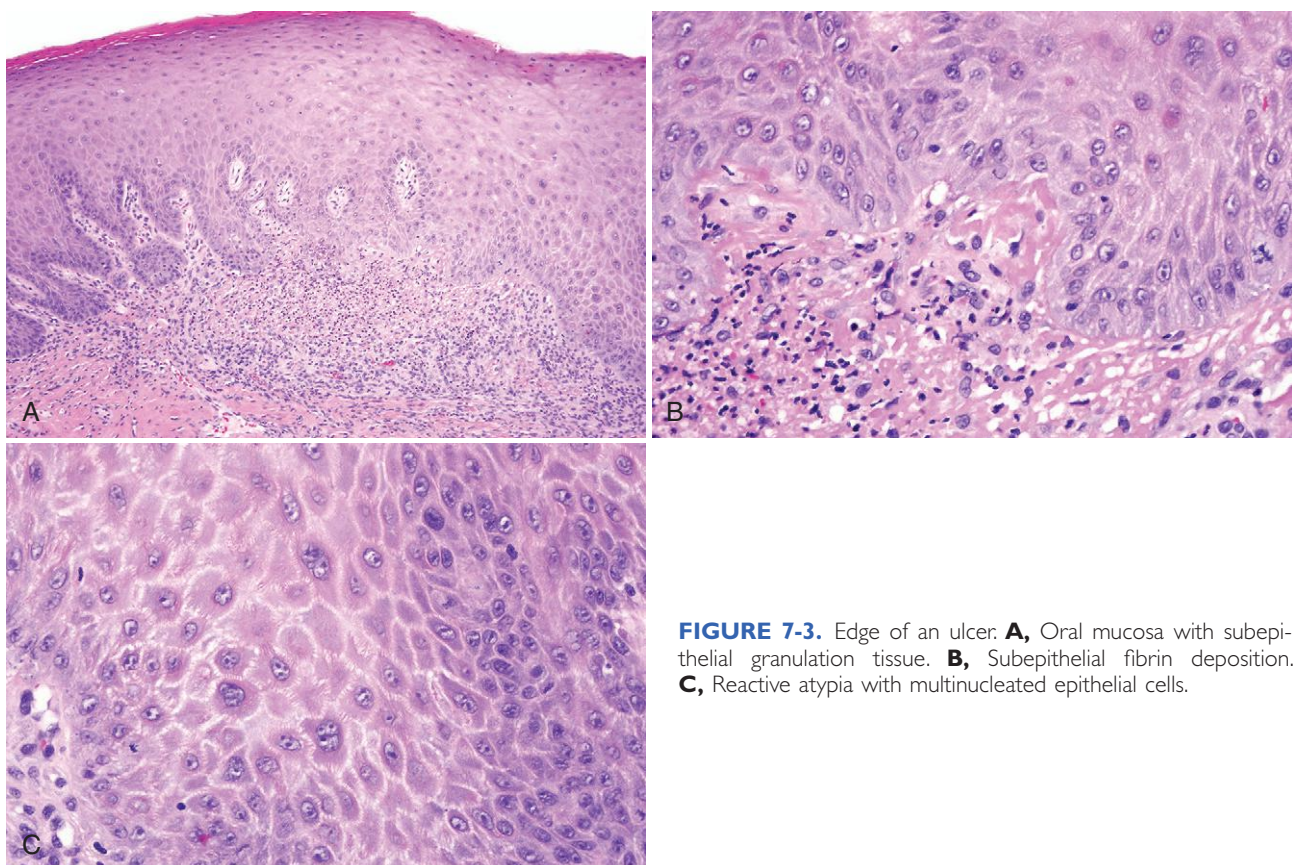


**FIGURE 7-1.** **A**, Recurrent minor aphthous ulcers on the left upper labial mucosa. **B**, Recurrent major aphthous ulcer on the left soft palate. **C**, Recurrent herpetiform aphthous ulcers on the soft palate. **D**, Traumatic ulcer caused by a broken tooth. **E**, Traumatic ulcer on palatal exostosis.



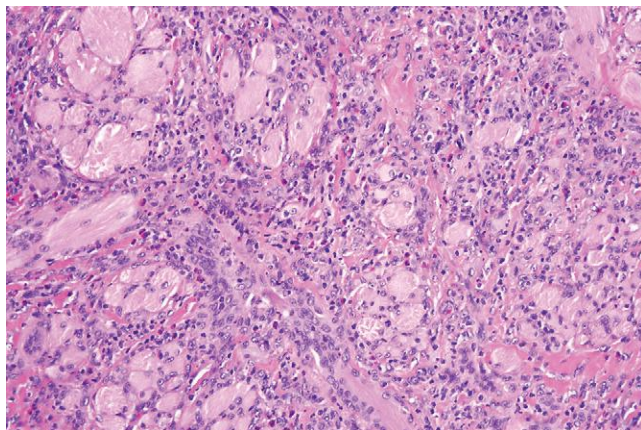


**FIGURE 7-2.** Traumatic ulcer. **A**, Loss of epithelial integrity and acute and chronic inflammation. **B**, Fibrin membrane containing many neutrophils with adjacent frictional hyperparakeratosis, acanthosis, and spongiotic pustules. **C**, Reactive epithelial atypia.

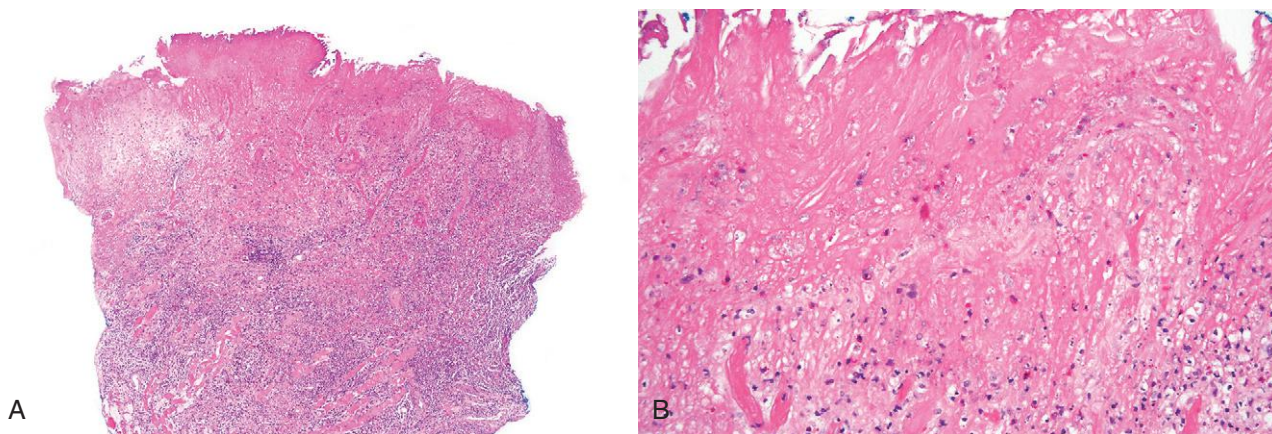


**FIGURE 7-3.** Edge of an ulcer. **A**, Oral mucosa with subepithelial granulation tissue. **B**, Subepithelial fibrin deposition. **C**, Reactive atypia with multinucleated epithelial cells.





**FIGURE 7-4.** Penetrating inflammation leads to muscle degeneration with many eosinophils and histiocyte-like cells.



**FIGURE 7-5.** **A**, Neutropenic ulcer. **B**, Paucity of neutrophils within fibrin meshwork.

## TRAUMATIC ULCERATIVE GRANULOMA WITH STROMAL EOSINOPHILS, EOSINOPHILIC ULCER OF TONGUE

### Clinical Findings

- Adult form is sharp, punched-out ulcer often with a white, keratotic rim, commonly on the lateral tongue, present for weeks, with or without pain, and raising suspicion for malignancy; any site with underlying muscle may be involved (Fig. 7-6, A); synchronous bilateral lesions or metachronous lesions may occur (see Fig. 7-6, B).
- Riga-Fede disease is an ulcer on tongue or lower lip in first year of life when newly erupted incisors traumatize mucosa (see Fig. 7-6, C).

### Etiopathogenesis and Histopathologic Features

Ulcerative granuloma is secondary to deeply penetrating inflammation involving the underlying skeletal muscle and is most often associated with trauma, but it

may also be seen in chronically traumatized ulcerative conditions, such as aphthous ulcers or other chronic inflammatory conditions; it bears resemblance to proliferative myositis.

- Ulcer with acute and chronic inflammation that penetrates into the muscle with separation and degeneration of muscle fibers (sometimes with “checkerboard” pattern), proliferation of histiocyte-like mononuclear cells, and many eosinophils (Figs. 7-7 and 7-8).
- Mononuclear cells are CD68 and Factor XIIIa positive (see Fig. 7-8, D).
- Exuberant granulation tissue may form a polypoid mass (pyogenic granuloma-like).

### Differential Diagnosis

- Diffuse large B-cell lymphomas show sheets of histiocyte-like cells that are CD20+; it is unclear if previously reported cases of atypical histiocytic granuloma may represent such lymphomas.
- Sheets of CD30+ cells raise the possibility of lymphoma, although this must be evaluated with clinical



findings; even monoclonality may not indicate neoplasia.

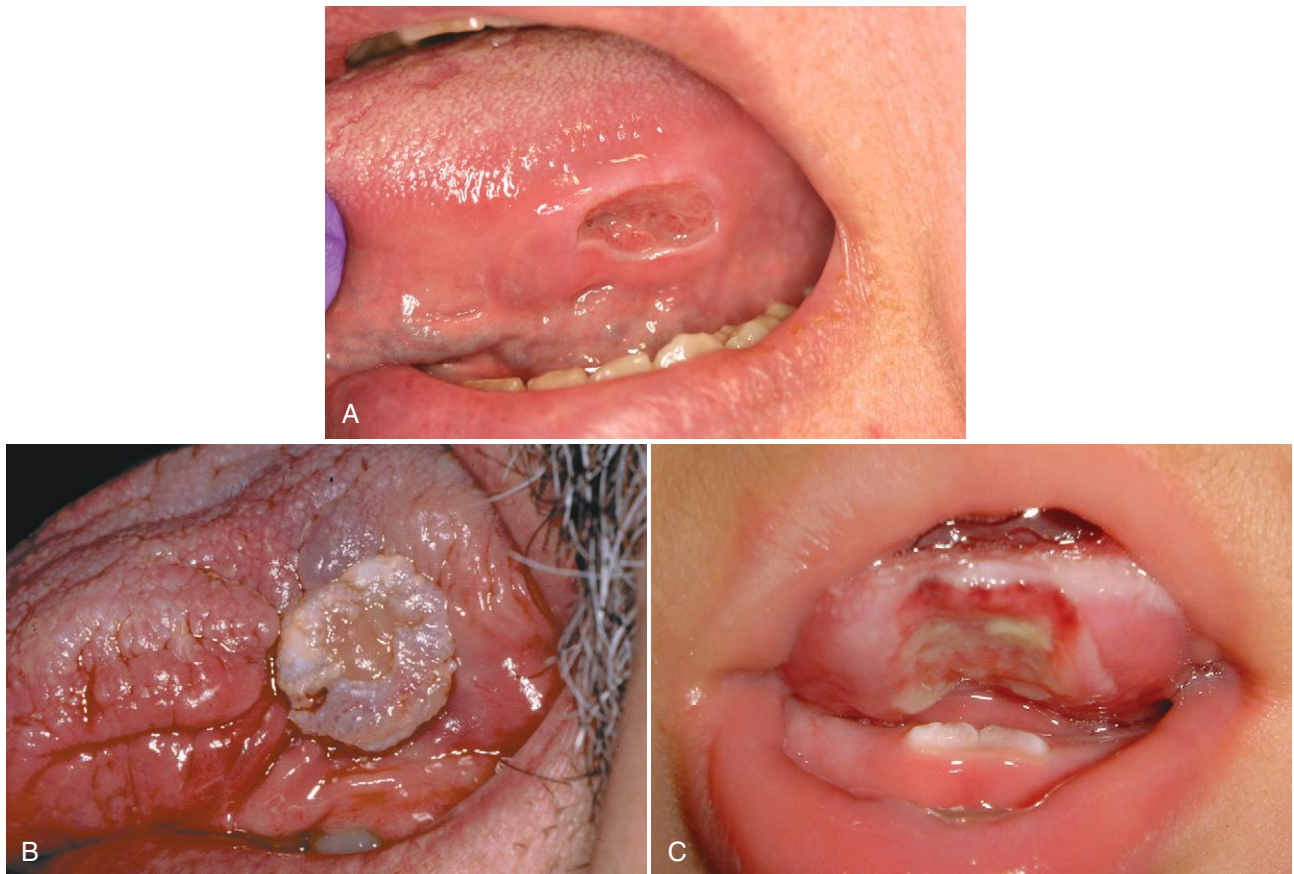- Epstein-Barr virus–associated mucocutaneous ulcers contain many CD30+ and EBV-encoded RNA (EBER) positive B cells, T cells, atypical Hodgkin-like cells, and Reed-Sternberg–like cells, with some cases showing B and T cell clonality; some cases regress, whereas others relapse and remit.

#### Management and Prognosis

- Lesions may heal after biopsy; otherwise, topical steroids, excision, or intralesional steroid injections are indicated (see Appendix A).
- Recurrence is common, especially if patient has flabby or enlarged tongue (e.g., older patients who wear lower full dentures or who have lost teeth in the posterior mandible).

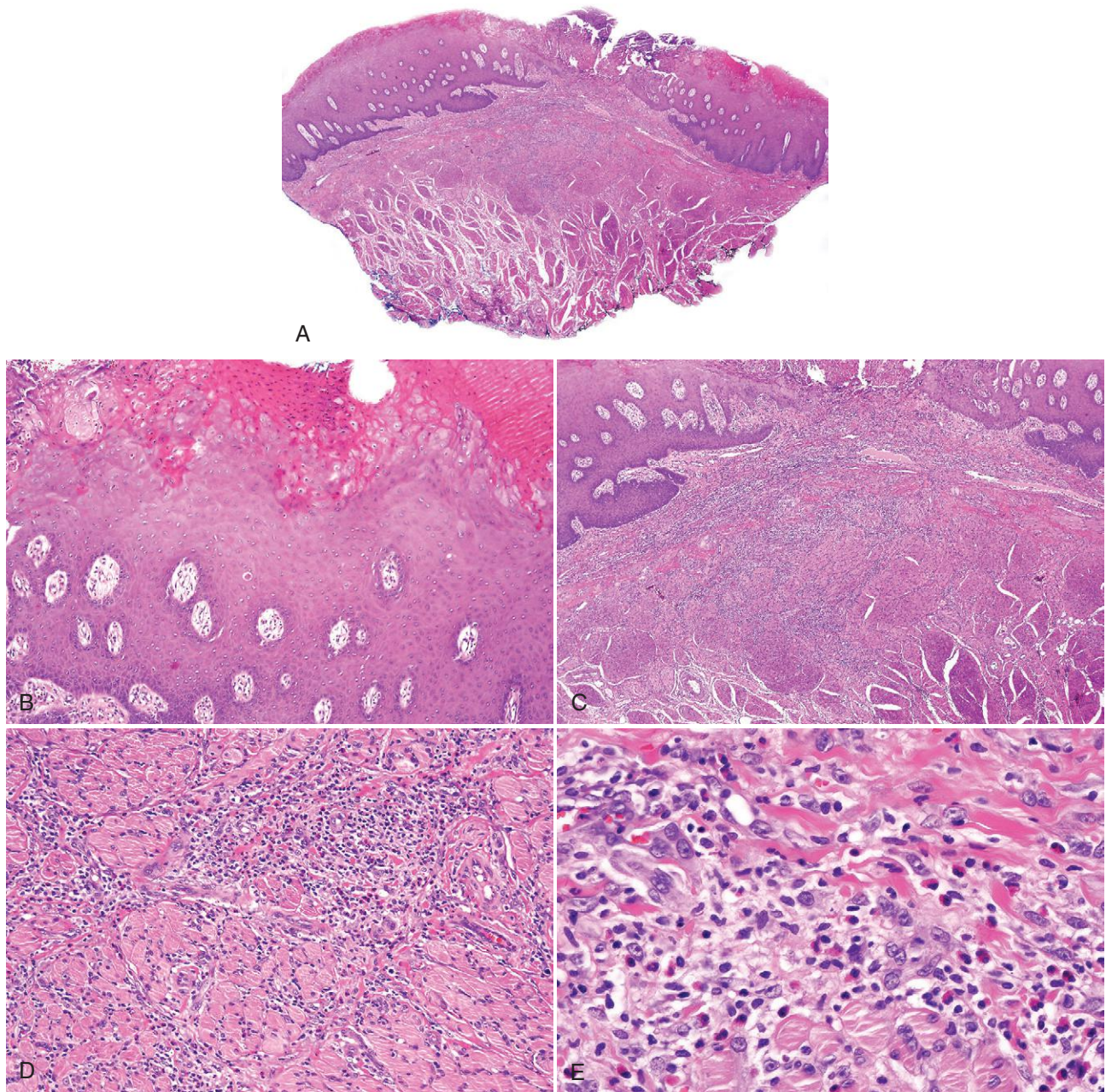
#### REFERENCES

- Alobeid B, Pan LX, Milligan L, et al. Eosinophil-rich CD30+ lymphoproliferative disorder of the oral mucosa. A form of “traumatic eosinophilic granuloma.” *Am J Clin Pathol.* 2004;121:43-50.
- del Rio E, Sanchez YE, Requena L, et al. Oral pseudolymphoma: a report of two cases. *J Cutan Pathol.* 1997;24:51-55.
- Dojcinov SD, Venkataraman G, Raffeld M, et al. EBV positive mucocutaneous ulcer—a study of 26 cases associated with various sources of immunosuppression. *Am J Surg Pathol.* 2010;34:405-417.
- El-Mofty SK, Wick MR, Miller AS. Eosinophilic ulcer of the oral mucosa. *Oral Surg Oral Med Oral Pathol.* 1993;75:716-722.
- Elzay RP. Traumatic ulcerative granuloma with stromal eosinophilia (Riga-Fede’s disease and traumatic eosinophilic granuloma). *Oral Surgery.* 1983;55:497-506.
- Eversole LR, Leider AS, Jacobsen PL, Kidd PM. Atypical histiocytic granuloma. *Cancer.* 1985;55:1722-1729.
- Salisbury CL, Budnick SD, Li S. T-cell receptor gene rearrangement and CD30 immunoreactivity in traumatic ulcerative granuloma with stromal eosinophilia of the oral cavity. *Am J Clin Pathol.* 2009;132:722-727.



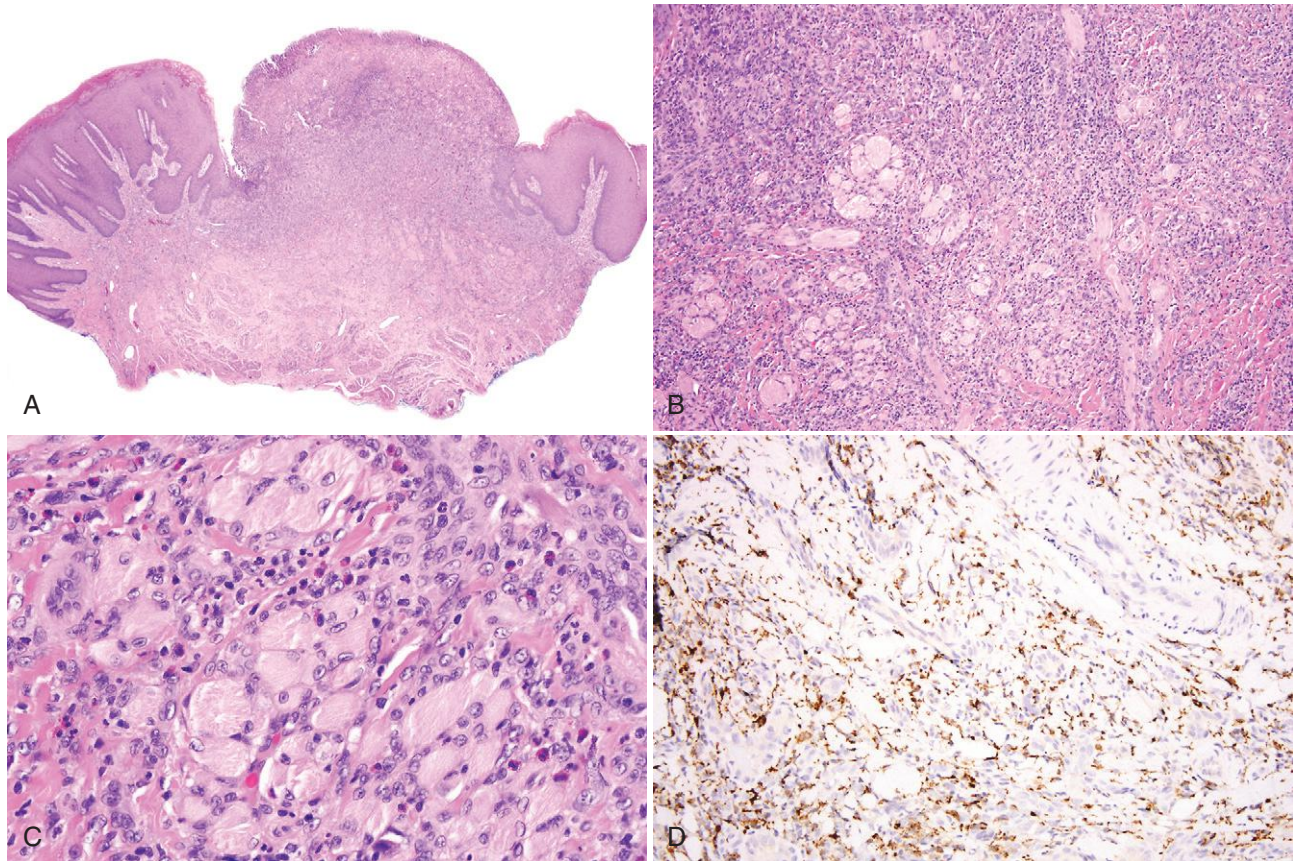
**FIGURE 7-6.** **A**, Traumatic ulcerative granuloma. **B**, Traumatic ulcerative granuloma, polypoid type. **C**, Traumatic ulcerative granuloma in young child resulting from trauma from teeth. (Courtesy of Dr. Ons Al-Khadra, Jeddah, Kingdom of Saudi Arabia.)





**FIGURE 7-7.** Traumatic ulcerative granuloma. **A**, Oral mucosa with ulceration and penetrating chronic inflammation. **B**, Overlying frictional keratosis. **C**, Muscle infiltrated by inflammatory cells. **D**, Myocyte degeneration and inflammation. **E**, Many eosinophils and histiocyte-like cells.





**FIGURE 7-8.** Traumatic ulcerative granuloma. **A**, Oral mucosa with overlying frictional keratosis, ulceration, and penetrating inflammation. **B**, Inflammation leading to fragmentation of skeletal muscle fibers. **C**, Muscle fibers surrounded by histiocyte-like mononuclear cells and eosinophils. **D**, Histiocyte-like cells around muscle fibers are CD68+.

## Nonspecific Inflammatory Conditions

### NONSPECIFIC IRRITANT CONTACT STOMATITIS

#### Clinical Findings

- White, necrotic plaque with or without ulceration with an erythematous background and a history of exposure to contactant

#### Etiopathogenesis and Histopathologic Features

Irritation by contactant is stronger than that seen with alcoholic mouth rinses and leads to inflammatory changes. Stronger irritants (e.g., aspirin) lead to necrosis and ulceration.

- Epithelial hyperplasia with marked spongiosis and leukocytic (especially neutrophilic) exocytosis; ulceration may be present (Figs. 7-9 to 7-11); some lesions show coagulation of the superficial keratinocytes with reactive keratinocytic atypia, and karyorrhexis (see Fig. 7-11) (see also Smokeless Tobacco Lesion in Chapter 10).

#### Differential Diagnosis

- Presence of a large number of eosinophils in the epithelium suggests hypersensitivity reaction.
- Contact stomatitis caused by restorations or cinnamic aldehyde-containing products result in lichenoid reactions.

#### Management and Prognosis

- Abstain from using contactant.
- Topical steroid therapy resolves lesions (see Appendix A).

#### REFERENCES

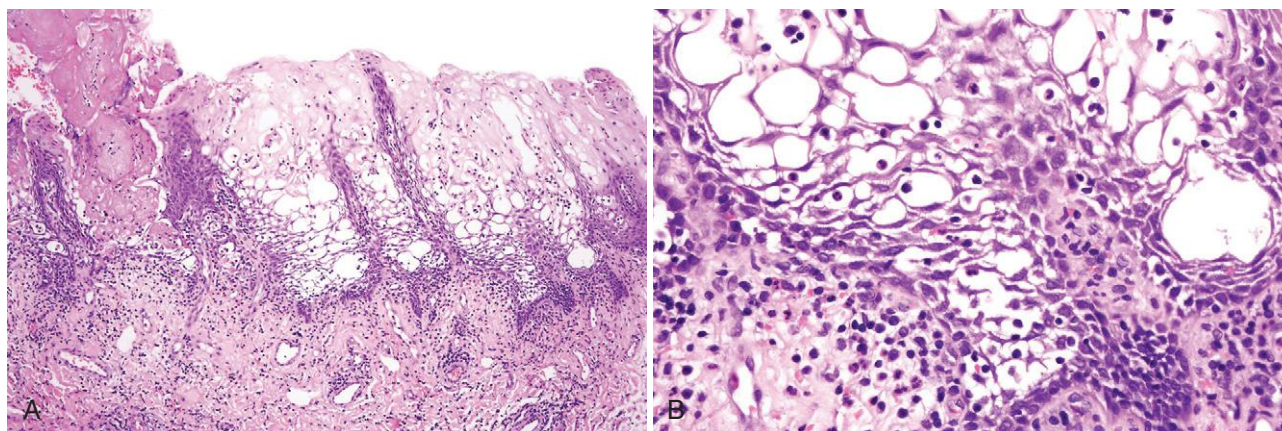
Bagga S, Thomas BS, Bhat M. Garlic burn as self-inflicted mucosal injury—a case report and review of the literature. *Quintessence Int.* 2008;39:491-494.

Gilvetti C, Porter SR, Fedele S. Traumatic chemical oral ulceration: a case report and review of the literature. *Br Dent J.* 2010;208:297-300.

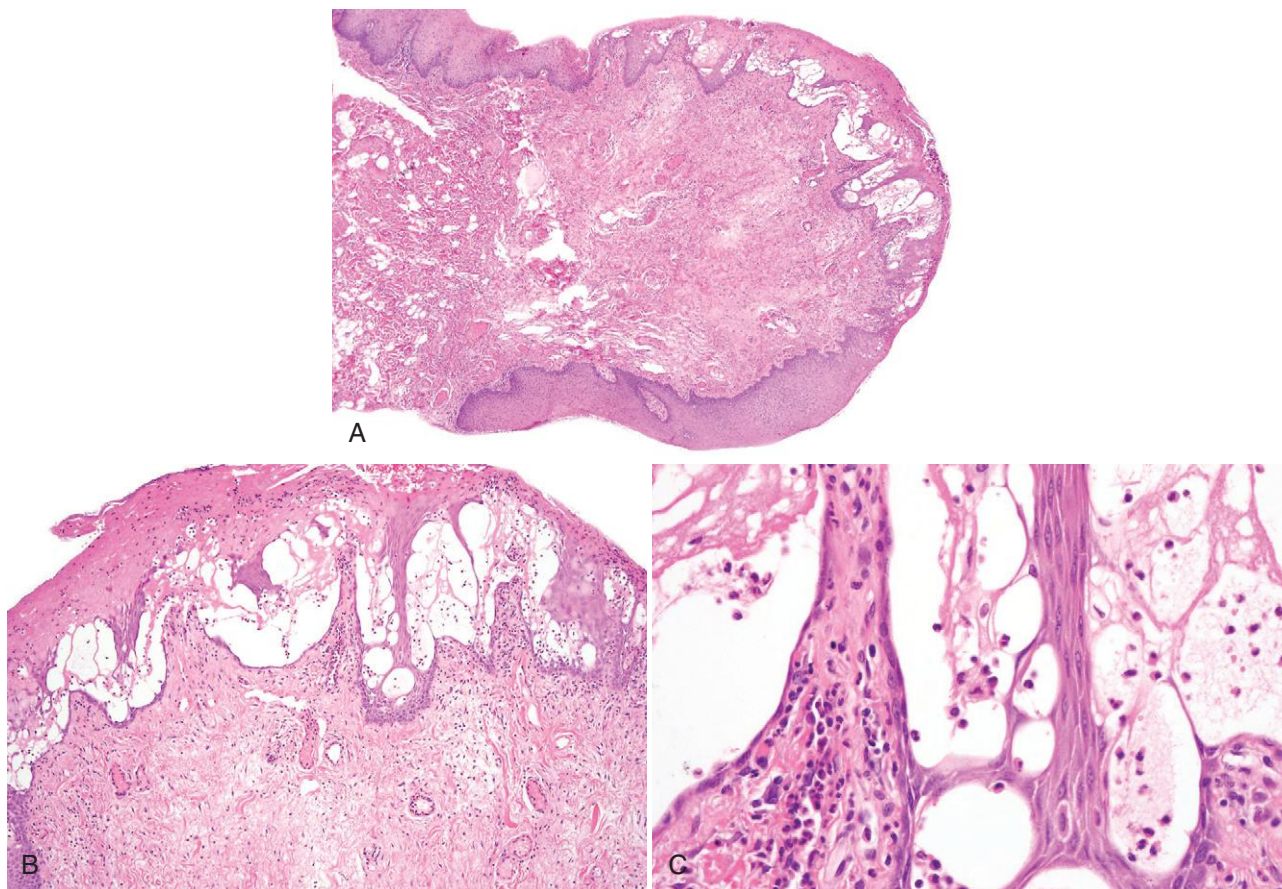
LeSueur BW, Yiannias JA. Contact stomatitis. *Dermatol Clin.* 2003;21:105-114.

Sapir S, Bimstein E. Cholinergic gel induced oral lesion: report of case. *J Clin Pediatr Dent.* 2000;24:103-106.



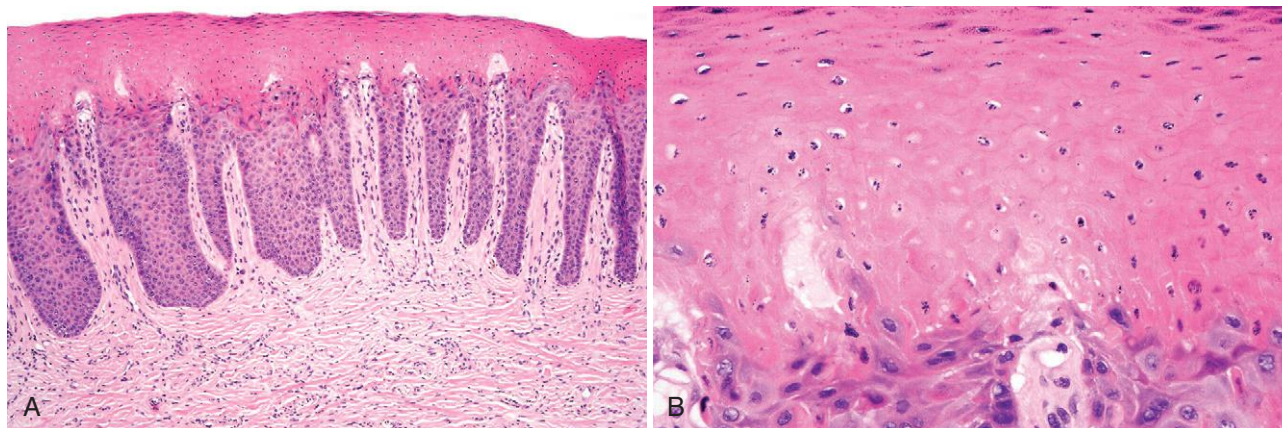


**FIGURE 7-9.** Irritant contact stomatitis. **A**, Oral mucosa exhibiting ulceration, spongiosis, and epithelial hyperplasia. **B**, Marked spongiosis and leukocyte exocytosis with mild reactive atypia.



**FIGURE 7-10.** Fibroma with irritant contact stomatitis. **A**, Fibroma with ulceration and marked spongiosis. **B**, Ulceration and intraepithelial blistering. **C**, Marked spongiosis and leukocyte exocytosis.





**FIGURE 7-11.** Irritant contact stomatitis. **A**, Hyperparakeratosis and coagulation of superficial keratinocytes. **B**, Coagulated superficial keratinocytes with reactive epithelial atypia and karyorrhexis.

## FRictional BLISTERS

### Clinical Findings

- Blisters occur at sites of trauma, particularly on the nonkeratinized mandibular or maxillary sulci traumatized by denture flanges.

### Etiopathogenesis and Histopathologic Features

Traumatic shear forces separate the epithelium from the connective tissue.

- Benign epithelial hyperplasia with intraepithelial or subepithelial blistering and accumulation of serum or fibrin; variable inflammation and vascular ectasia (Figs. 7-12 and 7-13)
- Bright eosinophilic pools of plasma (“plasma pooling”), further evidence of surface injury (Fig. 7-14)

### Differential Diagnosis

- Lymphatic malformations or lymphangioma circumscriptum consists of endothelium-lined spaces that abut the epithelium.
- Mucous membrane pemphigoid does not usually exhibit marked epithelial hyperplasia and accumulation of fluid or fibrin.
- Superficial mucocèles exhibit subepithelial collections of mucin and muciphages.

### Management and Prognosis

- Lesions resolve if source of trauma is removed.

## CHRONIC GINGIVITIS

### Clinical Findings

- Common at all ages but in particular during adolescence and pregnancy because of hormonal influences; red, tender gingiva that readily bleeds on brushing or eating (Fig. 7-15).

### Etiopathogenesis and Histopathologic Features

Gingivitis and periodontitis result from production of inflammatory cytokines in response to plaque bacterial lipopolysaccharides.

- Loss of normal keratinization may be seen; epithelial hyperplasia with spongiosis and leukocyte exocytosis, as well as plasma cell infiltrate (sometimes intense) in the lamina propria (Fig. 7-16); plaque bacteria often are identified and commonly contain actinomycetes but without clinging neutrophils, and they do not qualify for a diagnosis of actinomycosis (see Actinomycosis in Chapter 4; Fig. 7-17).

### Differential Diagnosis

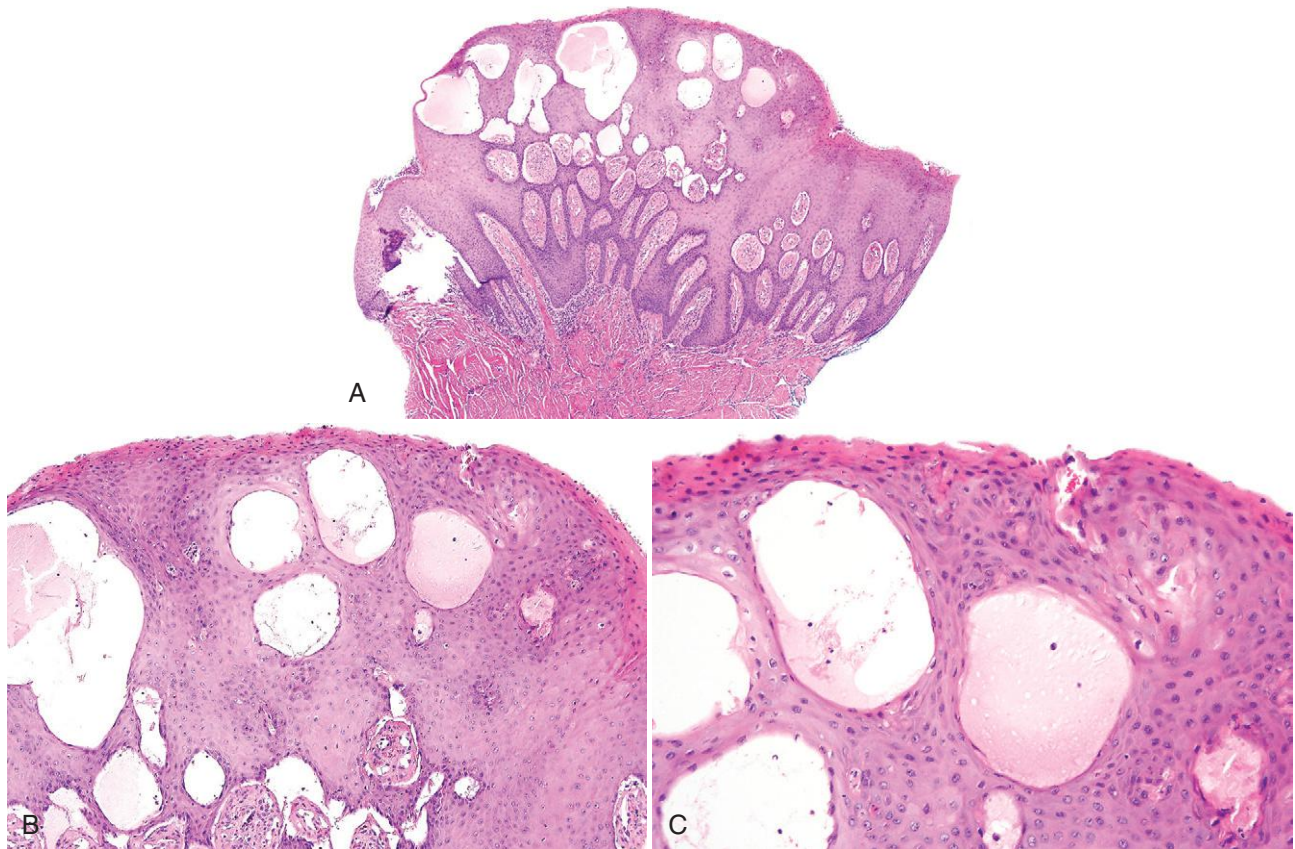
- Plasma cell gingivitis shows intense polyclonal plasma cell infiltrate present in sheets.

### Management and Prognosis

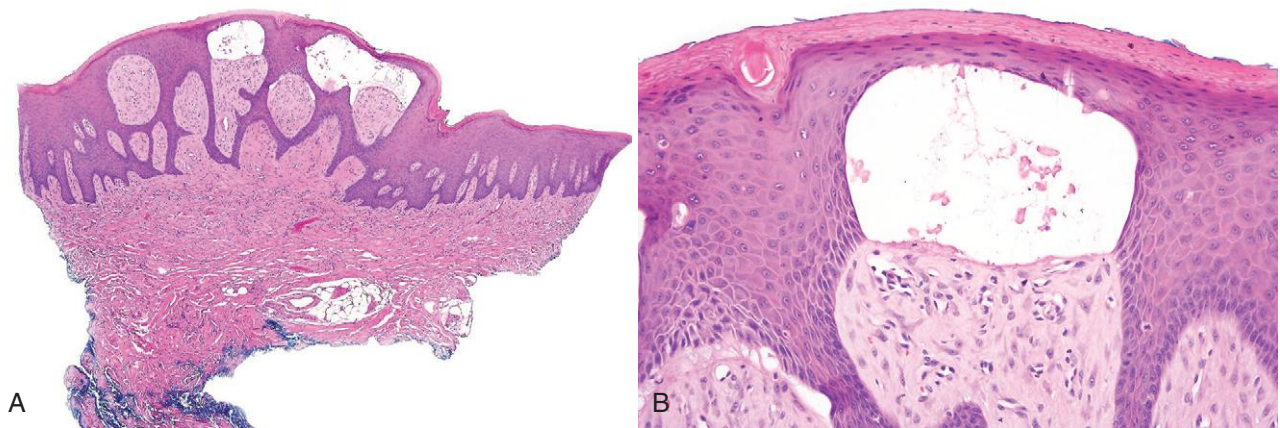
- Perform dental scaling, root planing, and prophylaxis to remove plaque; maintain good oral hygiene.

### REFERENCES

- Neville BW, Damm DD, Allen CM, Bouquot J. *Oral and Maxillofacial Pathology*. 5th ed. Philadelphia: Saunders; 2009.
- Wang PL, Ohura K. *Porphyromonas gingivalis* lipopolysaccharide signaling in gingival fibroblasts—CD14 and Toll-like receptors. *Crit Rev Oral Biol Med*. 2002;13:132-142.

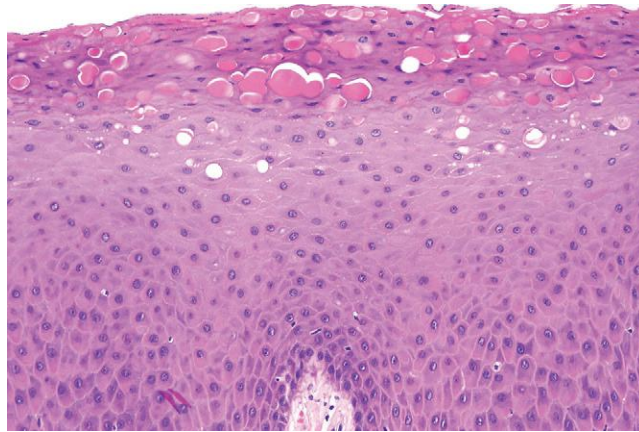


**FIGURE 7-12.** Frictional blister caused by denture. **A**, Epithelial hyperplasia with blisters. **B**, Epithelial hyperplasia with subepithelial and intraepithelial blisters. **C**, Intraepithelial blisters filled with fluid.

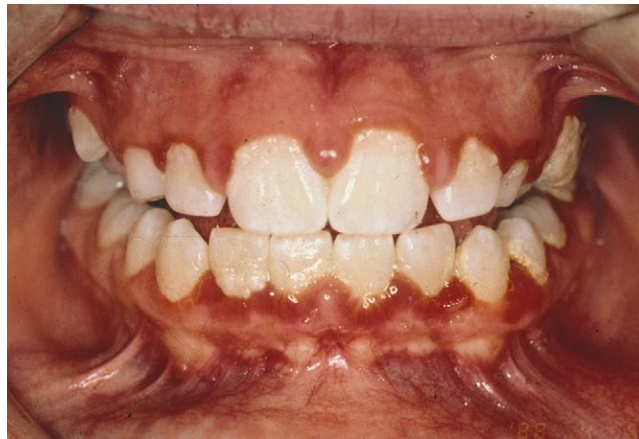

**FIGURE 7-13.** **A**, Frictional blister in giant cell fibroma. **B**, Subepithelial blister and stellate and multinucleated cells.

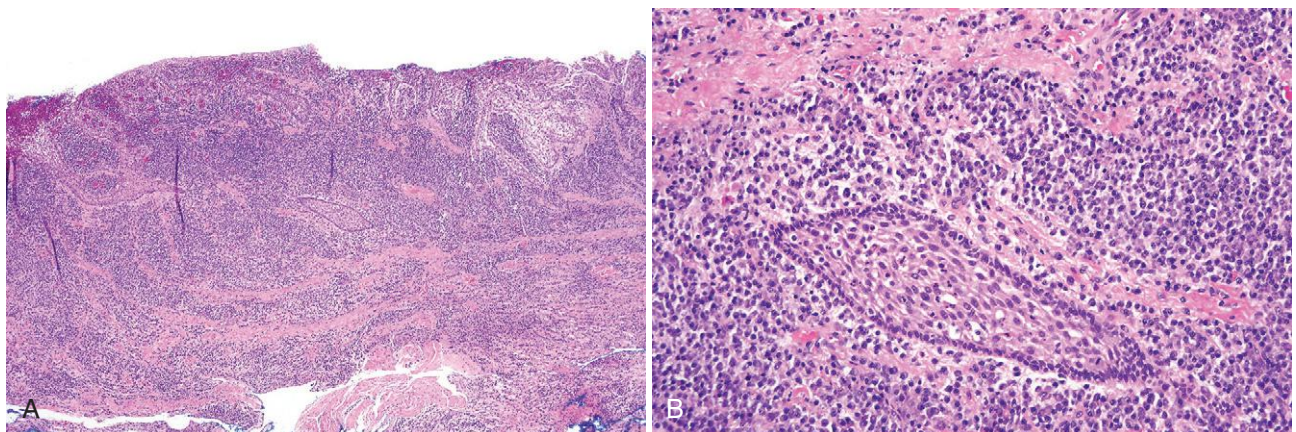




**FIGURE 7-14.** Plasma pooling between superficial keratinocytes.

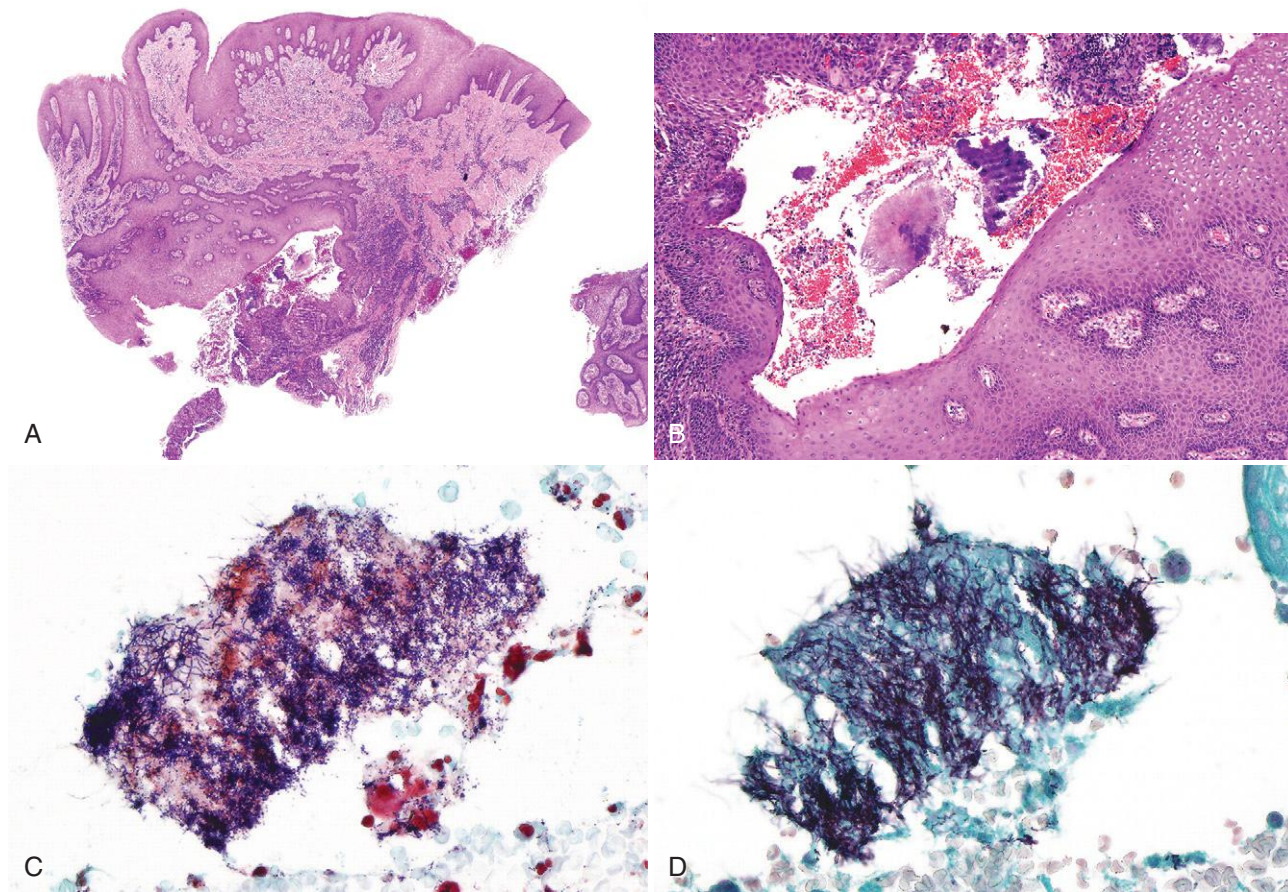


**FIGURE 7-15.** Chronic gingivitis with erythematous and edematous marginal gingiva.



**FIGURE 7-16.** Chronic gingivitis. **A**, Epithelium shows marked spongiosis and neutrophilic exocytosis. **B**, Many plasma cells are present.





**FIGURE 7-17.** Chronic hyperplastic gingivitis. **A**, Benign epithelial and fibrous hyperplasia with chronic inflammation. **B**, Dental plaque bacterial without rim of neutrophils. **C**, Dental plaque containing gram-positive filaments and cocci (Brown and Brenn stain). **D**, Dental plaque containing argyrophilic filaments (methenamine silver stain).

## FOREIGN BODY GINGIVITIS

### Clinical Findings

- Erythematous or pigmented gingival tissues (if related to amalgam) that may be tender

### Etiopathogenesis

Foreign body gingivitis is a reaction to components of dental polishing pastes and amalgam restorations. Energy-dispersive x-ray analysis confirms the presence of silica, aluminium, zinc, calcium, titanium, and barium from dental abrasives from professional polishing pastes, toothpastes, and amalgam.

- Nonspecific acute and chronic inflammation that may be intense; lichenoid or nonnecrotizing granulomatous inflammation in 20% to 48% of cases; fine granules of refractile foreign material (5 microns or less) or amalgam identified (Fig. 7-18); overlying epithelium atrophic or hyperplastic

### Differential Diagnosis

- Granulomas in orofacial granulomatosis lack foreign material.

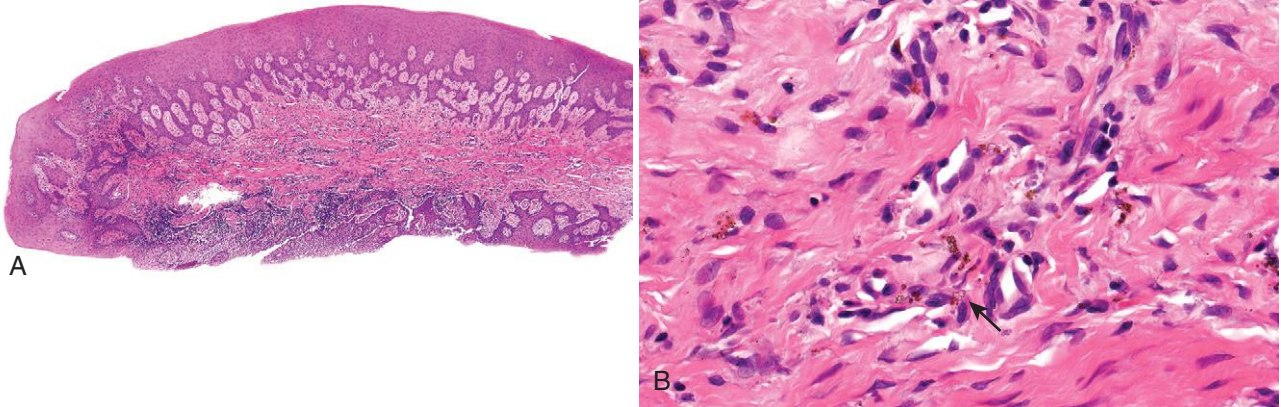
### Management and Prognosis

- Steroids reduce inflammation and symptoms, but the foreign material is not readily degradable.
- Surgery may be necessary.

### REFERENCES

- Daley TD, Wysocki GP. Foreign body gingivitis: an iatrogenic disease? *Oral Surg Oral Med Oral Pathol.* 1990;69:708-712.
- Gordon SC, Daley TD. Foreign body gingivitis: clinical and microscopic features of 61 cases. *Oral Surg Oral Med Oral Pathol Oral Radiol Endod.* 1997;83:562-570.
- Koppang HS, Roushan A, Srafilzadeh A, et al. Foreign body gingival lesions: distribution, morphology, identification by x-ray energy dispersive analysis and possible origin of foreign material. *J Oral Pathol Med.* 2007;36:161-172.





**FIGURE 7-18.** Foreign body gingivitis. **A**, Oral mucosa with mild chronic inflammation. **B**, Granules of foreign material, some of which are slightly crystalline in nature (*arrow*).

## 8

# IMMUNE-MEDIATED, AUTOIMMUNE, AND GRANULOMATOUS CONDITIONS

## CHAPTER CONTENTS

### GRANULOMATOUS INFLAMMATION 150

Foreign Body Granulomas 150

Orofacial Granulomatosis and Crohn Disease 154

### PYOSTOMATITIS VEGETANS 157

### IMMUNE-MEDIATED CONDITIONS 158

Benign Migratory Glossitis (Migratory Stomatitis; Geographic Tongue, Erythema Areata Migrans) 158

Nonspecific Hypersensitivity Reactions 160

Erythema Multiforme 161

Plasma Cell Orificial Mucositis (Plasma Cell Stomatitis, Mucous Membrane Plasmacytosis) 163

Lichen Planus/Lichenoid Mucositis 165

### AUTOIMMUNE CONDITIONS 173

Mucous Membrane Pemphigoid 173

Pemphigus Vulgaris 177

Paraneoplastic Pemphigus 180

Lupus Erythematosus 181

Wegener Granulomatosis 183

## Granulomatous Inflammation

True granulomas are collections of epithelioid histiocytes with variable inflammation and giant cells. Necrotizing granulomas are often seen in infectious processes and diseases of collagen degradation and necrobiosis. [Table 8-1](#) lists the common granulomatous processes affecting the oral cavity; those caused by infections are discussed in [Chapter 4](#).

### FOREIGN BODY GRANULOMAS

#### Clinical Findings

- Nondescript nodule with a history of trauma; common on lip; related to injection of dermal fillers

#### Etiopathogenesis and Histopathologic Features

Extrinsic foreign material introduced accidentally (e.g., glass or amalgam filling material) or intentionally (e.g., dermal fillers) excites a histiocytic response. Though generally resorbed, dermal fillers may migrate to sites, distant from the original injection. Foreign body granulomas also form as a reaction to endogenous substances, such as cholesterol from cell membranes,

keratin (ruptured epidermal inclusion cysts), and hair (ruptured hair follicle).

- Proliferation of epithelioid histiocytes and foreign body giant cells, nonnecrotizing; refractile or nonrefractile foreign material may be identified ([Fig. 8-1](#)).
- Poly-L-lactic acid fillers are refractile fusiform or geometric structures ([Fig. 8-2](#)).
- Lipid and silicone granulomas have cytoplasmic vacuoles of varying sizes ([Figs. 8-3 and 8-4](#)).
- Calcium hydroxylapatite consists of gray-brown microspheres, 25 to 40 microns in diameter, that are nonrefractile; they stimulate endogenous collagen production and are resorbed within a few months, but they may cause a granulomatous response ([Fig. 8-5](#)).
- Foreign body granulomas are common in odontogenic cysts (see [Chapter 14](#)), around amalgam tattoos (see [Chapter 9](#)), and in keratinizing squamous cell carcinomas (see [Chapter 11](#)).

#### Differential Diagnosis

- Hyaluronic acid fillers appear as amorphous basophilic pools of ground substance that stains for alcian



**TABLE 8-1** Types of Granulomatous Inflammation

Granulomatous Inflammation	Distinguishing Features
<b>Reactive</b>	
Foreign body granuloma	Refractile or nonrefractile foreign material present; sometimes foreign material not identified
Intrinsic (e.g., ruptured hair follicle, cholesterol, keratin)	History of trauma or introduction of foreign material
Extrinsic	Dermal filler, amalgam
<b>Infectious</b>	
Bacterial infection (e.g., <i>Bartonella henselae</i> )	Warthin-Starry stain
Mycobacterial infection (often necrotizing)	Acid-fast bacillus or Fite stain
Spirochetal infection (e.g., tertiary syphilis gumma)	Warthin-Starry, Dieterle, or modified Steiner stain
Deep fungal infections	Methenamine silver or PAS stain; may see pseudoepitheliomatous hyperplasia
<b>Others</b>	
Sarcoidosis	Hilar lymphadenopathy, elevated ACE levels
Crohn disease	Gastrointestinal symptoms, positive endoscopic findings
Orofacial granulomatosis	Idopathic or related to Crohn disease
Wegener granulomatosis	Upper respiratory or renal findings, c-ANCA positive
Lichenoid granulomatous inflammation	Coexisting lichenoid stomatitis
Palisaded granulomas (e.g., rheumatoid nodule)	History of rheumatoid arthritis or necrobiotic disease

ACE, Angiotensin converting enzyme; c-ANCA, cytoplasmic antineutrophil cytoplasmic antibodies; PAS, periodic acid-Schiff.

blue and colloidal iron; they do not incite a reaction (Fig. 8-6).

- Palisaded granulomas of necrobiosis lipoidica, granuloma annulare, and rheumatoid arthritis are rarely encountered intraorally.
- Lipid granulomas may resemble atypical lipomatous tumors.

### Management and Prognosis

- Excision is curative.

### REFERENCES

Ficarra G, Mosqueda-Taylor A, Carlos R. Silicone granuloma of the facial tissues: a report of seven cases. *Oral Surg Oral Med Oral Pathol Oral Radiol Endod.* 2002;94:65-73.

Jham BC, Nikitakis NG, Scheper MA, et al. Granulomatous foreign-body reaction involving oral and perioral tissues after injection of biomaterials: a series of 7 cases and review of the literature. *J Oral Maxillofac Surg.* 2009;67:280-285.

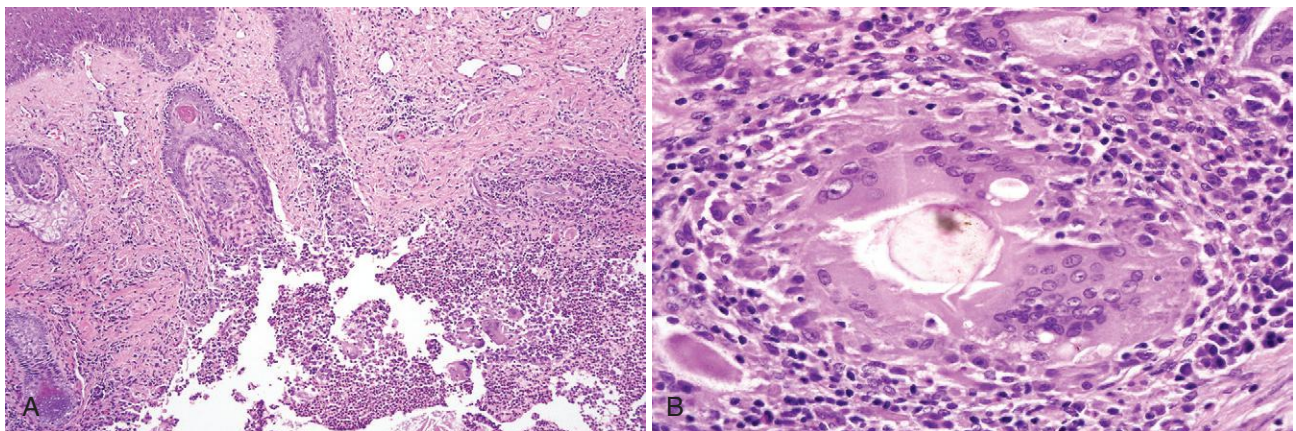
Lombardi T, Samson J, Plantier F, et al. Oral granulomas after injection of cosmetic fillers. Histopathologic and clinical study of 11 cases. *J Oral Path Med.* 2004;33:115-120.

Narins RS, Coleman 3rd WP, Glogau RG. Recommendations and treatment options for nodules and other filler complications. *Dermatol Surg.* 2009;35(suppl 2):1667-1671.

Requena L, Requena C, Christensen L, et al. Adverse reactions to injectable soft tissue fillers. *J AM Acad Dermatol.* 2011;64:1-34.

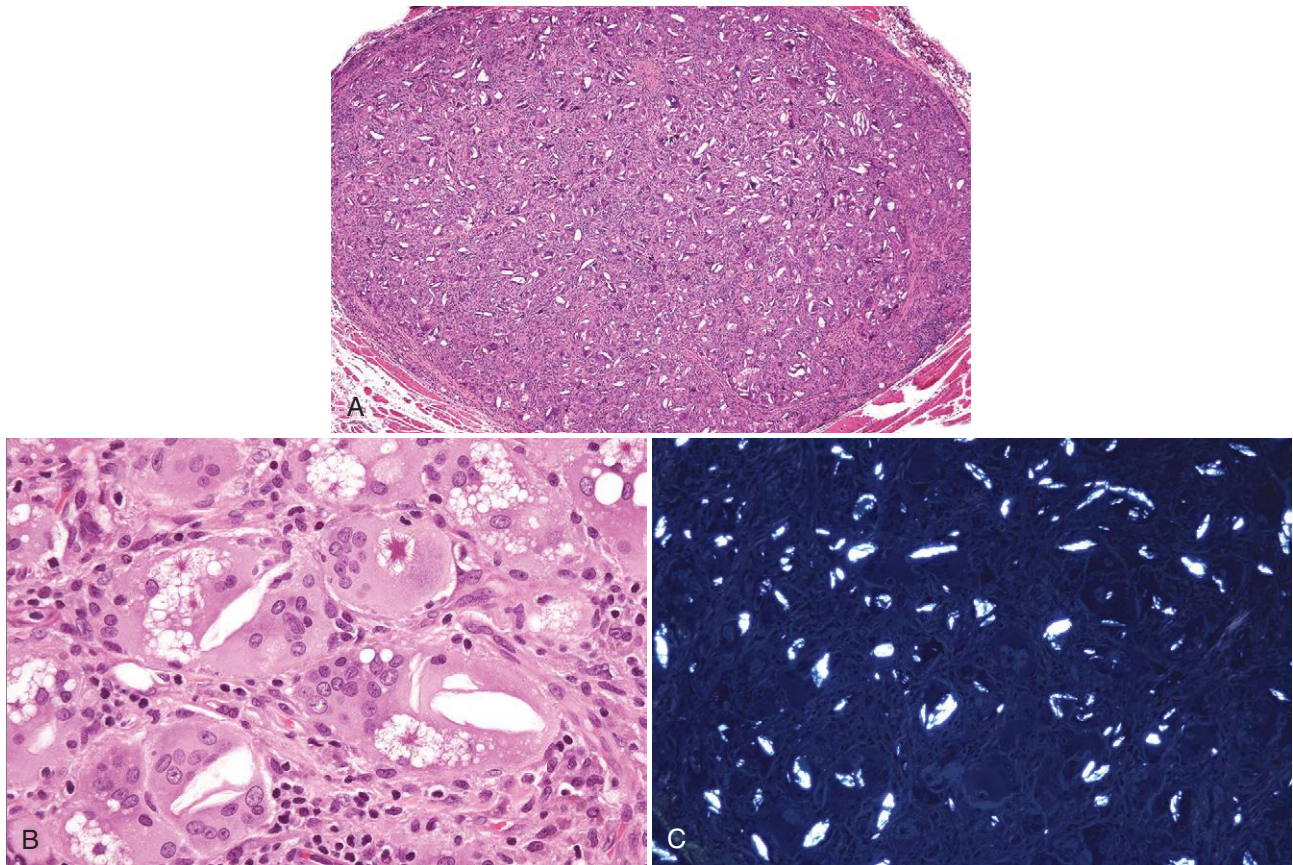
Sage RJ, Chaffins ML, Kouba DJ. Granulomatous foreign body reaction to hyaluronic acid: report of a case after melolabial fold augmentation and review of management. *Dermatol Surg.* 2009;35(suppl 2):1698-1700.

Skov BG. Rheumatoid nodule in the oral mucosa. *J Oral Path Med.* 1987;16:403-405.

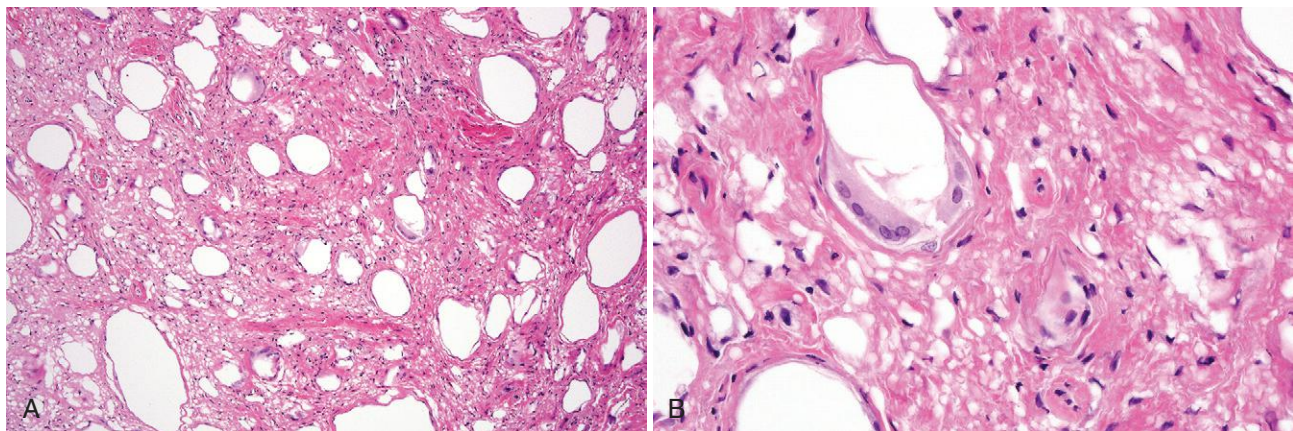


**FIGURE 8-1.** Ruptured hair follicle. **A**, Granulomatous inflammation with abscess. **B**, Fragment of hair within foreign body giant cell.



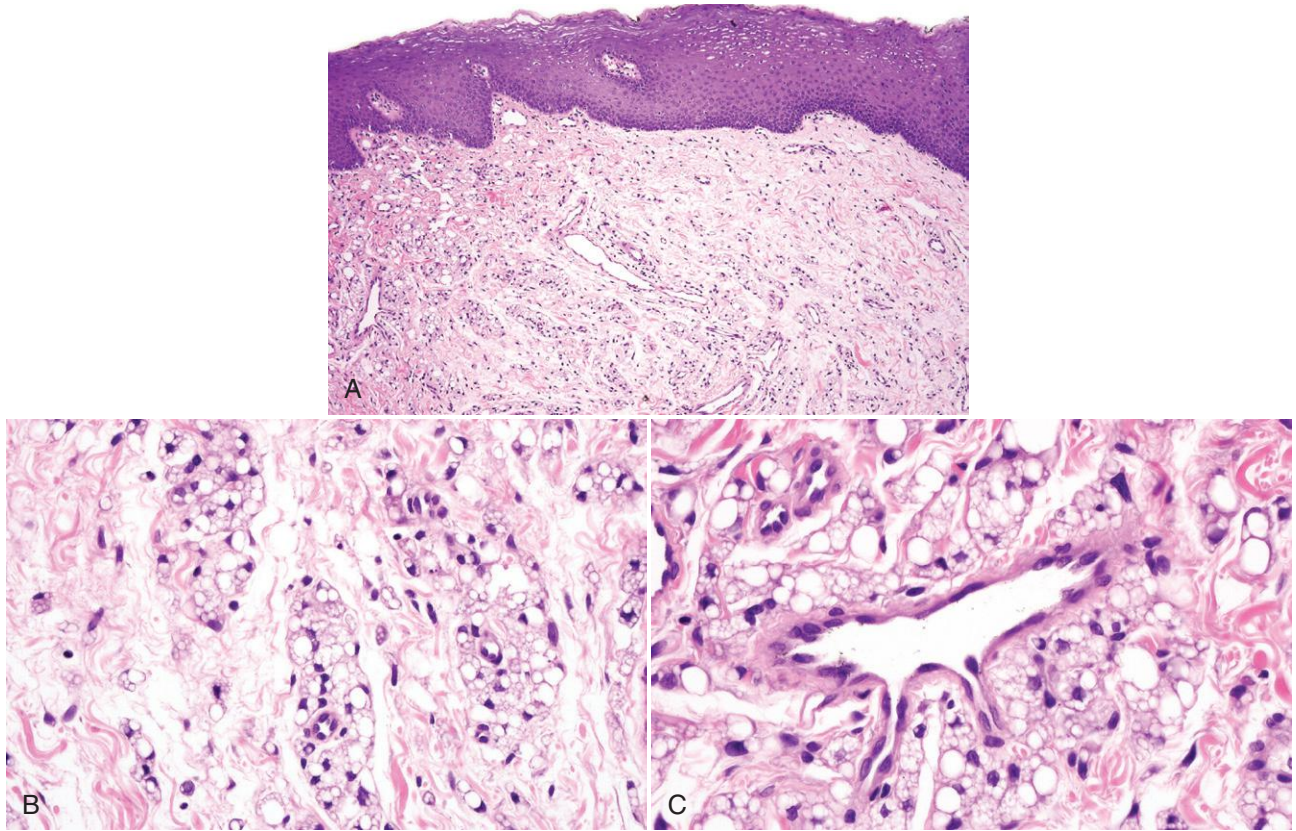


**FIGURE 8-2.** Poly-L-lactic acid granuloma. **A**, Nodule consists of multinucleated giant cells and fusiform clefts. **B**, Multinucleated giant cells with bubbly cytoplasm, fusiform clefts, and asteroid bodies. **C**, Refractile foreign material.

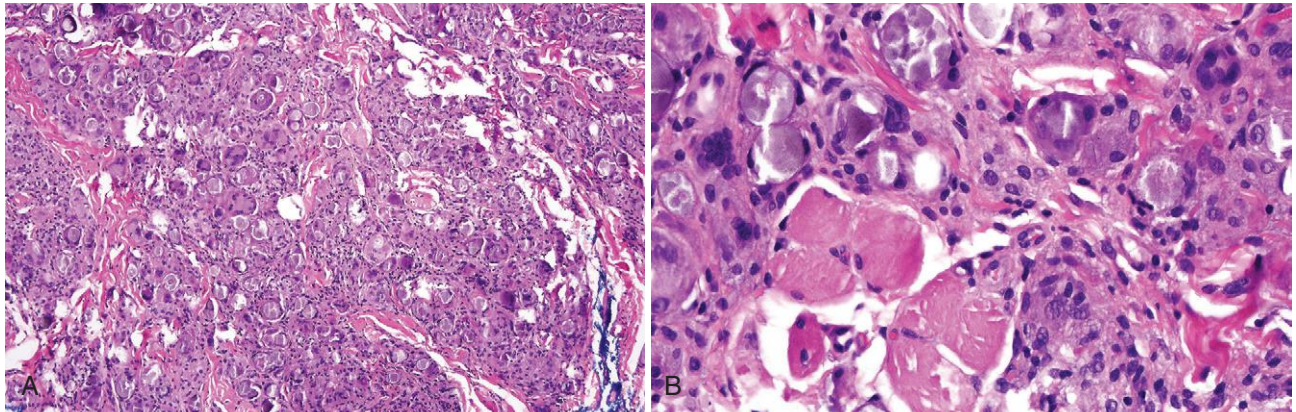


**FIGURE 8-3.** Lipid granuloma. **A**, Lipid material and fibrosis. **B**, Lipid vacuoles of varying sizes and foreign body giant cell.



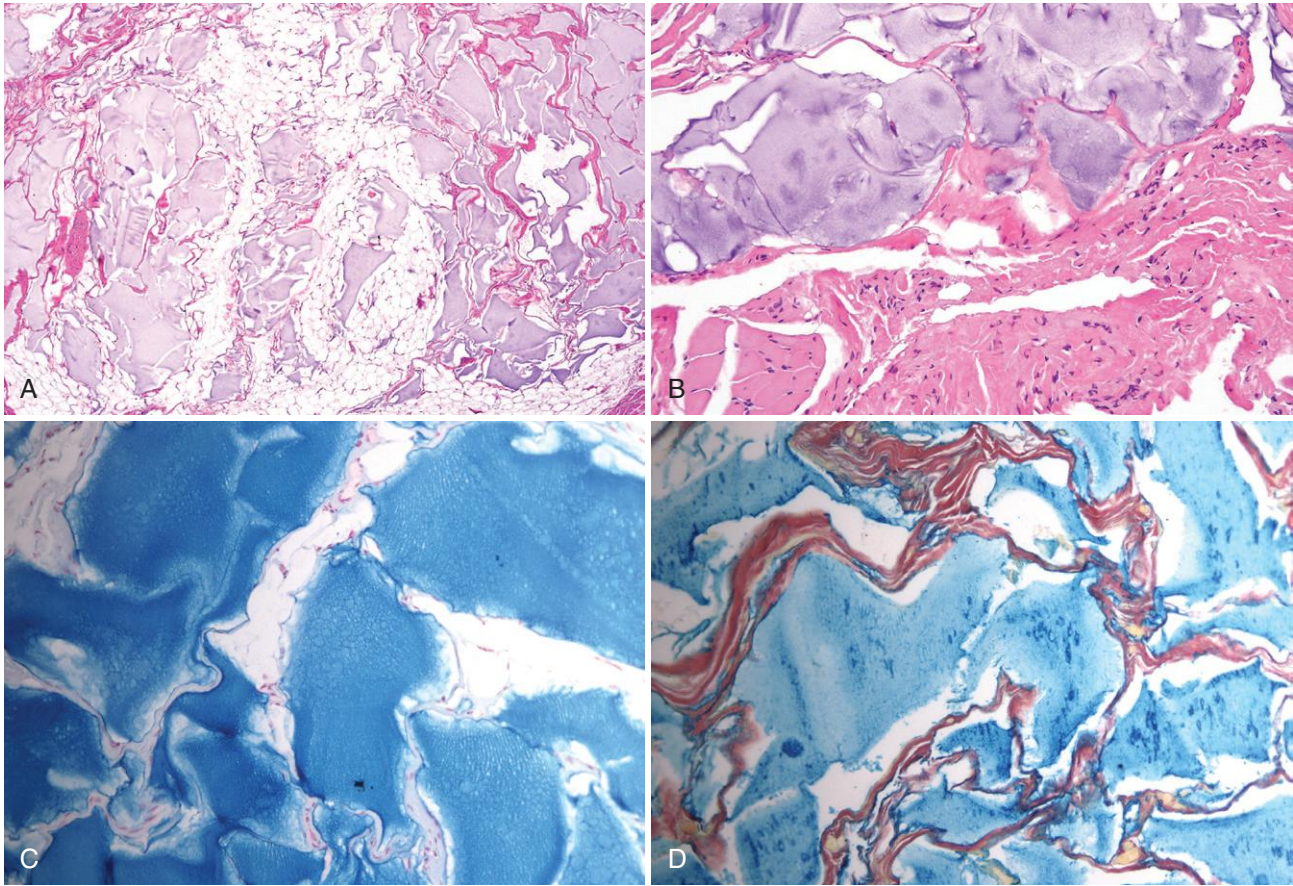


**FIGURE 8-4.** Silicone granuloma. **A**, Many vacuolated cells in the lamina propria. **B**, Macrophages containing vacuoles of varying sizes. **C**, Macrophages with bubbly vesicular cytoplasm and slight reactive nuclear atypia.



**FIGURE 8-5.** Calcium hydroxylapatite filler. **A**, Uniformly sized round particulate material in the lamina propria with many multinucleated foreign body giant cells. **B**, Nonrefractile gray-brown round particles surrounded by histiocytes.





**FIGURE 8-6.** Hyaluronic acid filler. **A**, Pools of inert amorphous basophilic material within fat. **B**, Mild fibrosis but no foreign body reaction or inflammation. **C**, Positive alcian blue stain. **D**, Positive colloidal iron stain.

## OROFACIAL GRANULOMATOSIS AND CROHN DISEASE

Orofacial granulomatosis may be idiopathic or the first sign of Crohn disease.

### Clinical Features

- Generally affects young adults; lips show diffuse or localized rubbery swelling that does not remit (unlike angioedema); tissues feel tight and sore (Fig. 8-7, A and B).
- May also show concomitant swelling of the gingiva; long-standing cases show cobblestoning and fissuring of mucosa from edema.
- Melkersson-Rosenthal syndrome, in addition to the lip swelling, exhibits fissured tongue and facial palsy; because fissured tongue is very common and facial palsy in this syndrome is very rare, it is unclear if this is a true syndrome.
- Crohn disease—in addition to the aforementioned features, there may also be papular folds of tissue in the maxillary and mandibular sulci, aphthous-like ulcers, gastrointestinal symptoms, and thickened and erythematous appearance of perivermilion skin (see

Fig. 8-7, C); oral findings precede the diagnosis of intestinal disease in 50% of cases; some patients may also present with pyostomatitis vegetans (see later).

### Etiopathogenesis and Histopathologic Features

Orofacial granulomatosis may be seen in patients who are sensitive to foodstuffs such as eggs and chocolate, flavorings including cinnamaldehyde, and preservatives such as benzoates and metabisulfites. Crohn disease is thought to be an inflammatory response possibly to intestinal microbes in genetically susceptible hosts (e.g., polymorphisms in the NOD2/CARD15 genes).

- Nonnecrotizing granulomas are noted and may be subtle in early disease (especially in idiopathic orofacial granulomatosis) (Fig. 8-8) or more florid in later disease; granulomas of Crohn disease may occur in salivary glands and may contain eosinophils (Figs. 8-9 and 8-10); multiple levels should be performed, if necessary, through the entire block to locate granulomas; edema and chronic inflammation alone are not sufficient for the diagnosis.

### Differential Diagnosis

- Other granulomatous processes must be ruled out with histochemical stains.



- Granulomas of sarcoidosis are nonnecrotizing and well demarcated or “naked” (Fig. 8-11); patients are often blacks, have hilar lymphadenopathy, and elevated levels of angiotensin-converting enzyme; labial salivary gland biopsies show granulomas in 33% of cases.

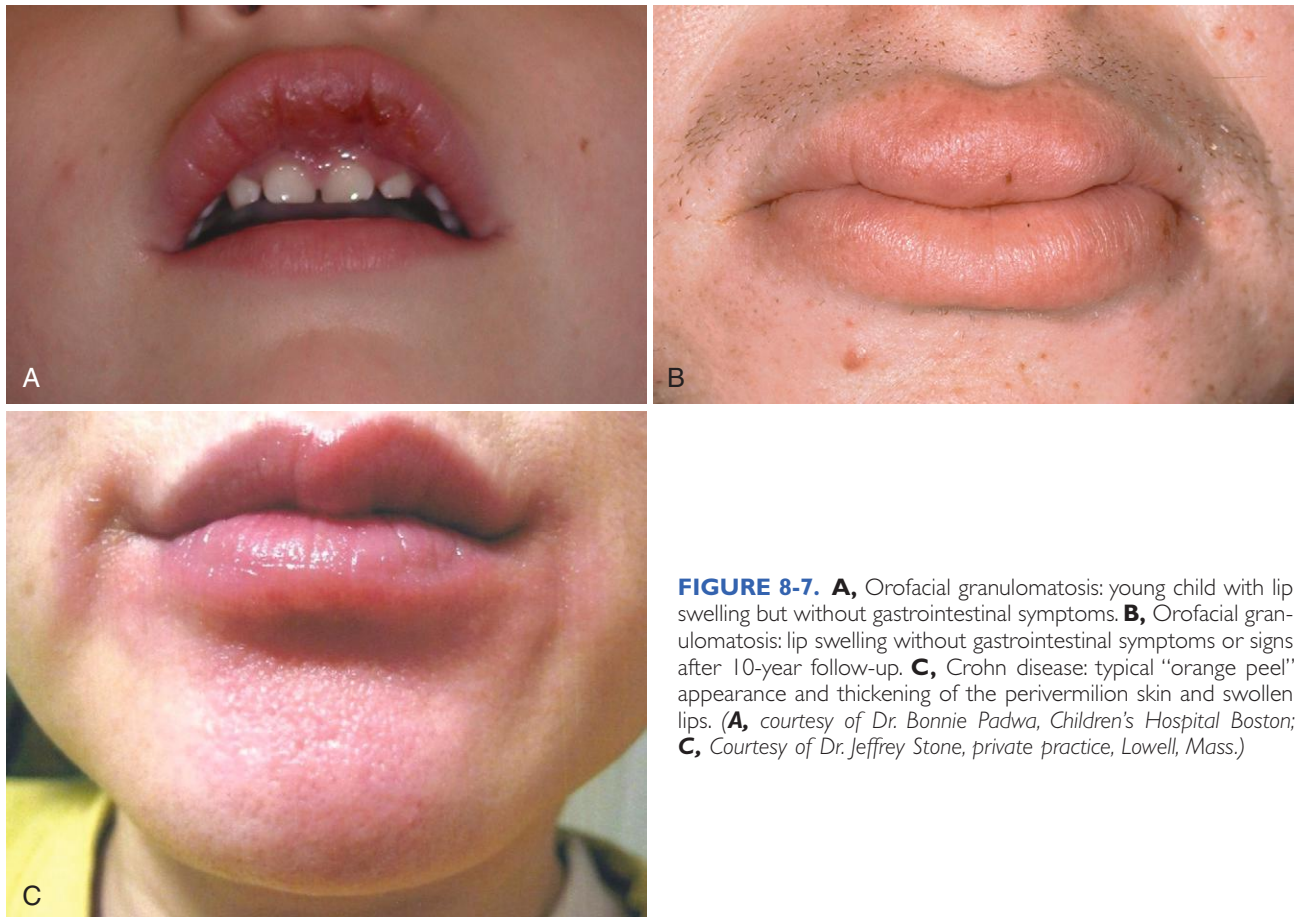### Management and Prognosis

- Patch test for the idiopathic type to determine if hypersensitivity to the environment exists; intralesional steroid injections can be done every week for several weeks, but relapse is common; topical, intralesional, and systemic therapy controls disease in 70% of patients; minocycline or thalidomide helps some patients.
- Gastrointestinal work-up is indicated if there are intestinal symptoms.

### REFERENCES

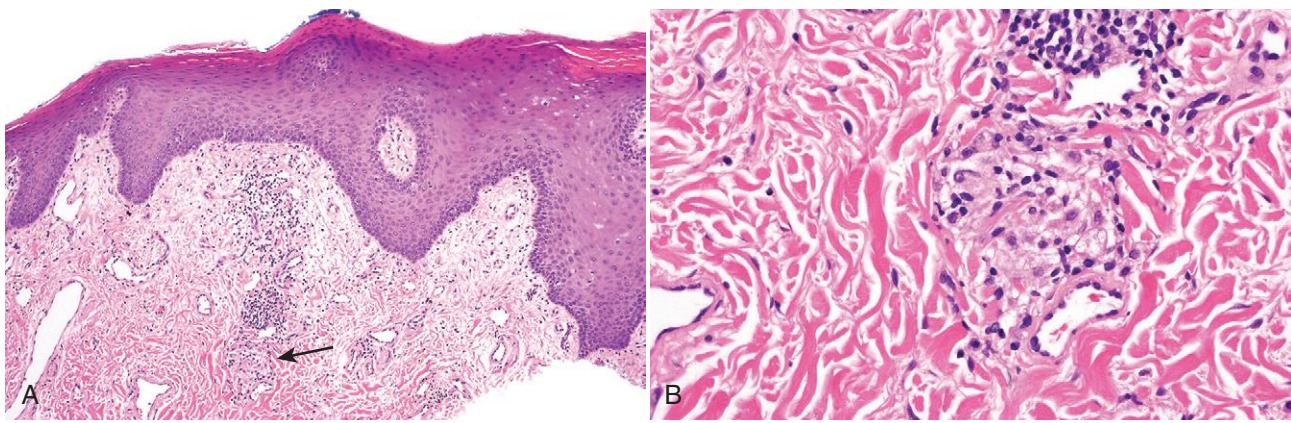
- Abraham C, Cho JH. Inflammatory bowel disease. *N Engl J Med*. 2009;361:2068-2078.
- Al Johani KA, Moles DR, Hodgson TA, et al. Orofacial granulomatosis: clinical features and long-term outcome of therapy. *J Am Acad Dermatol*. 2010;62:611-620.

- Dupuy A, Cosnes J, Revuz J, et al. Oral Crohn disease: clinical characteristics and long-term follow-up of 9 cases. *Arch Dermatol*. 1999;135:439-442.
- Grave B, McCullough M, Wiesenfeld D. Orofacial granulomatosis—a 20-year review. *Oral Dis*. 2009;15:46-51.
- Harty S, Fleming P, Rowland M, et al. A prospective study of the oral manifestations of Crohn’s disease. *Clin Gastroenterol Hepatol*. 2005;3:886-891.
- Hegarty A, Hodgson T, Porter S. Thalidomide for the treatment of recalcitrant oral Crohn’s disease and orofacial granulomatosis. *Oral Surg Oral Med Oral Pathol Oral Radiol Endod*. 2003;95:576-585.
- Lourenco SV, Hussein TP, Bologna SB, et al. Oral manifestations of inflammatory bowel disease: a review based on the observation of six cases. *J Eur Acad Dermatol Venerol*. 2010;24:204-207.
- Plauth M, Jenss H, Meyle J. Oral manifestations of Crohn’s disease. *J Clin Gastroenterol*. 1991;13:29-37.
- Saalman R, Mattsson U, Jontell M. Orofacial granulomatosis in childhood—a clinical entity that may indicate Crohn’s disease as well as food allergy. *Acta Paediatr*. 2009;98:1162-1167.
- Tabak L, Agirbas E, Yilmazbayhan D, et al. The value of labial biopsy in the differentiation of sarcoidosis from tuberculosis. *Sarcoidosis Vasc Diffuse Lung Dis*. 2001;18:191-195.
- Tilakaratne WM, Freysdottir J, Fortune F. Orofacial granulomatosis: review on aetiology and pathogenesis. *J Oral Pathol Med*. 2008;37:191-195.

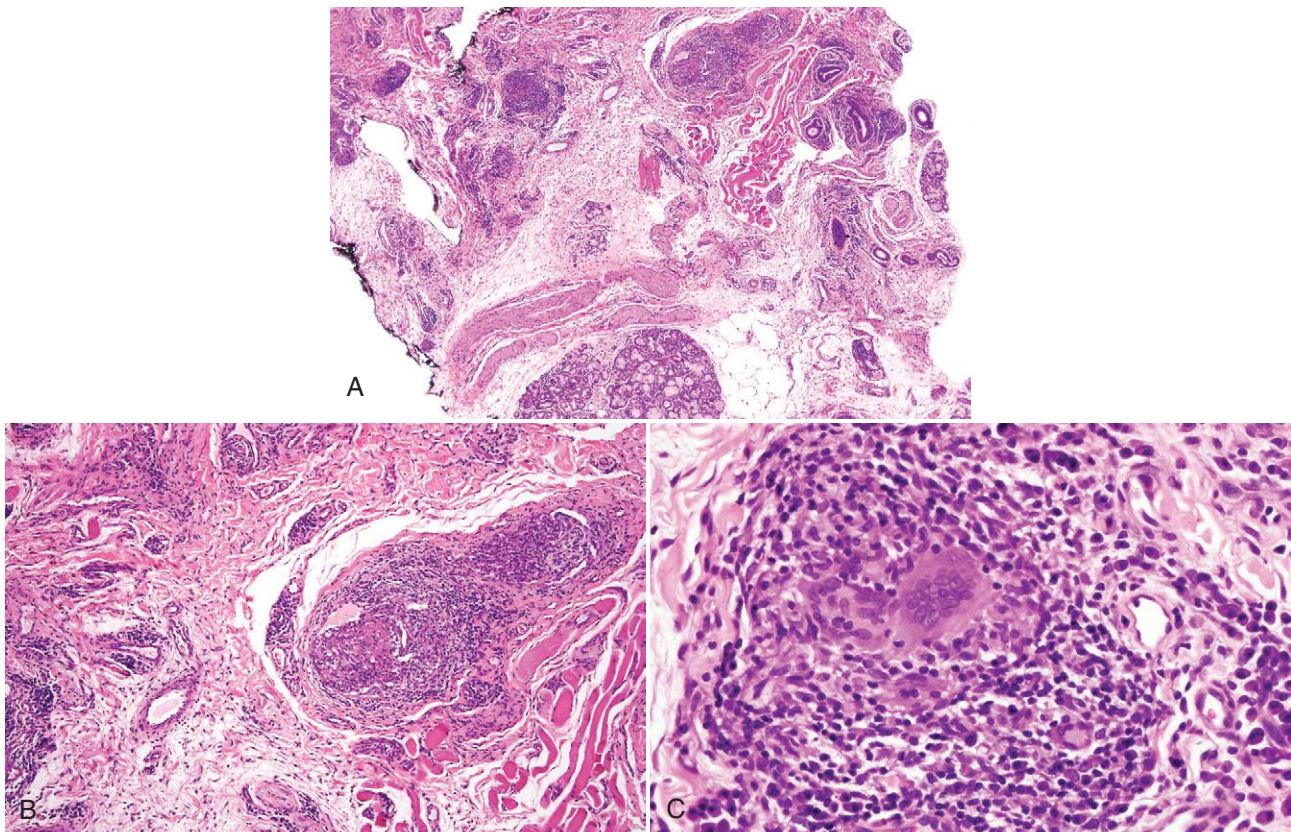


**FIGURE 8-7.** **A**, Orofacial granulomatosis: young child with lip swelling but without gastrointestinal symptoms. **B**, Orofacial granulomatosis: lip swelling without gastrointestinal symptoms or signs after 10-year follow-up. **C**, Crohn disease: typical “orange peel” appearance and thickening of the perivermilion skin and swollen lips. (**A**, courtesy of Dr. Bonnie Padwa, Children’s Hospital Boston; **C**, Courtesy of Dr. Jeffrey Stone, private practice, Lowell, Mass.)

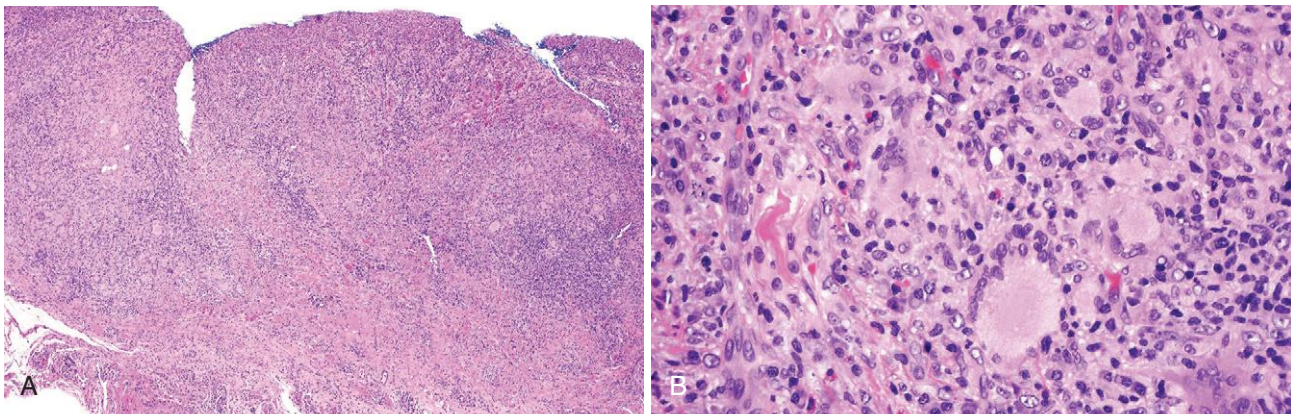




**FIGURE 8-8.** Idiopathic orofacial granulomatosis. **A**, Lamina propria is edematous and contains a subtle granuloma (*arrow*) and dilated vessels. **B**, Subtle nonnecrotizing granuloma.

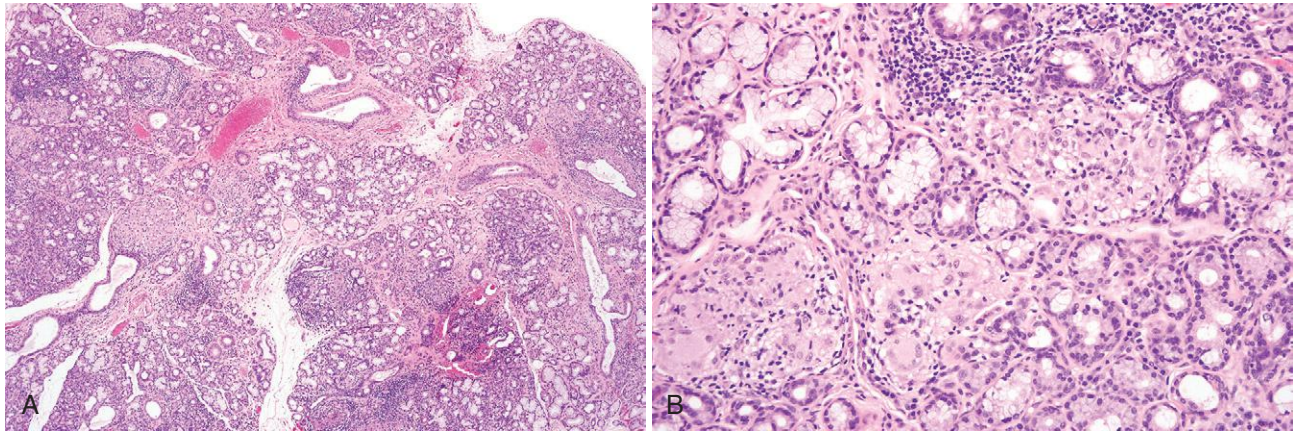


**FIGURE 8-9.** Crohn disease. **A**, Many nonnecrotizing granulomas within salivary glands of the lip. **B**, Nonnecrotizing granulomas with chronic inflammation. **C**, Multinucleated giant cells.



**FIGURE 8-10.** Crohn disease. **A**, Pronounced granulomatous inflammation in the lamina propria with overlying ulceration. **B**, Eosinophils within granulomas.





**FIGURE 8-11.** Sarcoidosis. **A**, Minor salivary gland containing granulomas. **B**, Nonnecrotizing “naked” granulomas with multinucleated giant cells.

## Pyostomatitis Vegetans

### Clinical Findings

- Shallow ulcers and erosions, miliary abscesses and pustules on erythematous mucosa (Fig. 8-12); vegetations may be a feature; sometimes folding and fissuring of the buccal mucosa occurs.
- Most common associations are ulcerative colitis (approximately 70%), Crohn disease (10% to 15%) and liver disease; peripheral blood eosinophilia is present in 90% of cases; some cases are idiopathic.

### Etiopathogenesis and Histologic Features

Pyostomatitis vegetans is the oral counterpart of pyoderma vegetans.

- Epithelial hyperplasia, spongiosis, and suprabasilar clefting with acantholysis are present; neutrophilic and eosinophilic abscesses are noted within the clefts and in the connective tissue papillae (Fig. 8-13).
- Direct immunofluorescence studies for immunoglobulin G (IgG) and C3 are negative.

### Differential Diagnosis

- Pemphigus vulgaris exhibits intercellular deposition of IgG on direct immunofluorescence studies.

### Management and Prognosis

- Oral lesions respond well to topical steroids or tacrolimus (see Appendix A).

### REFERENCES

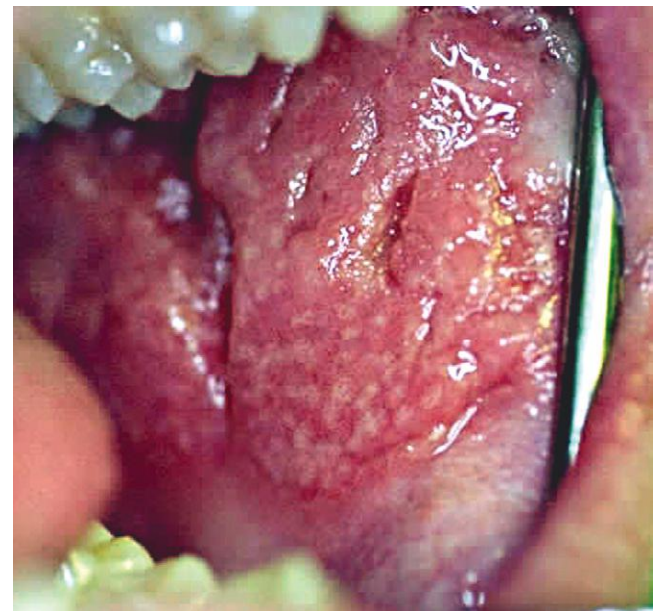- DeRossi SS, Salazar G, Sarin J, Alawi F. Chronic lesions of the gingiva and mucosa. *J Am Dent Assoc.* 2007;138:1589-1592.
- Femiano F, Lanza A, Buonaiuto C, et al. Pyostomatitis vegetans: a review of the literature. *Med Oral Patol Oral Cir Bucal.* 2009;14:E114-117.

Gonzalez-Moles MA, Gil-Montoya JA, Ruiz-Avila I, et al. Pyostomatitis vegetans: dramatic clinical response to clobetasol propionate treatment in aqueous solution. *J Eur Acad Dermatol Venerol.* 2008;22:252-253.

Hegarty AM, Barrett AW, Scully C. Pyostomatitis vegetans. *Clin Exp Dermatol.* 2004;29:1-7.

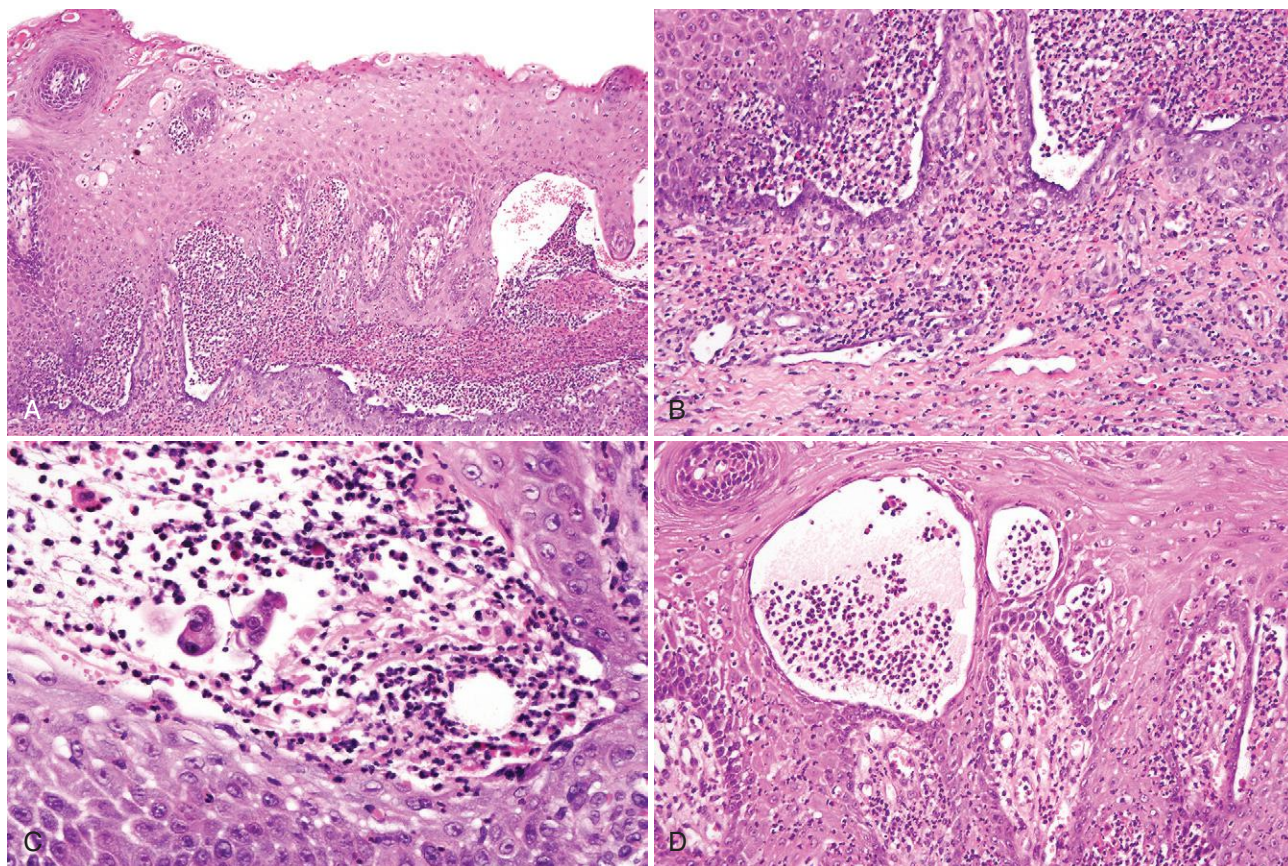
Ko HC, Jung DS, Jwa SW, et al. Two cases of pyodermitis-pyostomatitis vegetans. *J Dermatol.* 2009;36:293-297.

Markiewicz M, Suresh L, Margarone 3rd J, et al. Pyostomatitis vegetans: a clinical marker of silent ulcerative colitis. *J Oral Maxillofac Surg.* 2007;65:346-348.



**FIGURE 8-12.** Pyostomatitis vegetans manifesting as coalescent ulcers in a linear “snail track” configuration. (From Markiewicz M, Suresh L, Margarone J, et al: Pyostomatitis vegetans: a clinical marker of silent ulcerative colitis. *J Oral Maxillofacial Surg.* 2007; 65:346-348.)





**FIGURE 8-13.** Pyostomatitis vegetans. **A**, Epithelial hyperplasia with suprabasilar clefting. **B**, Suprabasilar clefting with eosinophils within cleft and in lamina propria. **C**, Acantholytic cells and eosinophils within cleft. **D**, Intraepithelial abscesses.

## Immune-Mediated Conditions

### BENIGN MIGRATORY GLOSSITIS (MIGRATORY STOMATITIS; GEOGRAPHIC TONGUE, ERYTHEMA AREATA MIGRANS)

#### Clinical Findings

- Occurs in 1% to 2% of population, usually in adults
- Well-demarcated, patchy erythematous depapillation of tongue dorsum; raised, linear or circinate, often with discontinuous white peripheral rim; associated with fissured tongue in 25% of cases (Fig. 8-14, A and B); rare on sites other than the tongue (see Fig. 8-14, C)

#### Etiopathogenesis and Histopathologic Features

There is a strong association with atopy (history of hay fever, eczema, asthma, or food intolerance), and psoriasis (especially pustular forms); some associated with human leukocyte antigen (HLA)-Cw6 (also seen in psoriasis).

- Loss of filiform papillae; psoriasiform epithelial hyperplasia with spongiosis and spongiotic pustules (involving one third to two thirds of the thickness of the epithelium); variable lymphocytic infiltrate (Figs. 8-15 to 8-17)

- Stains for candidal hyphae negative

#### Differential Diagnosis

- Candidiasis also shows psoriasiform epithelial hyperplasia and spongiotic pustules that are confined to the superficial two to three layers of keratinocytes; candidal hyphae are identified with periodic acid-Schiff stain.
- Spongiotic pustules at the edge of ulcers or in erosions involve the ulcer edge and the superficial keratinocytes.
- Condition is indistinguishable from psoriasis.

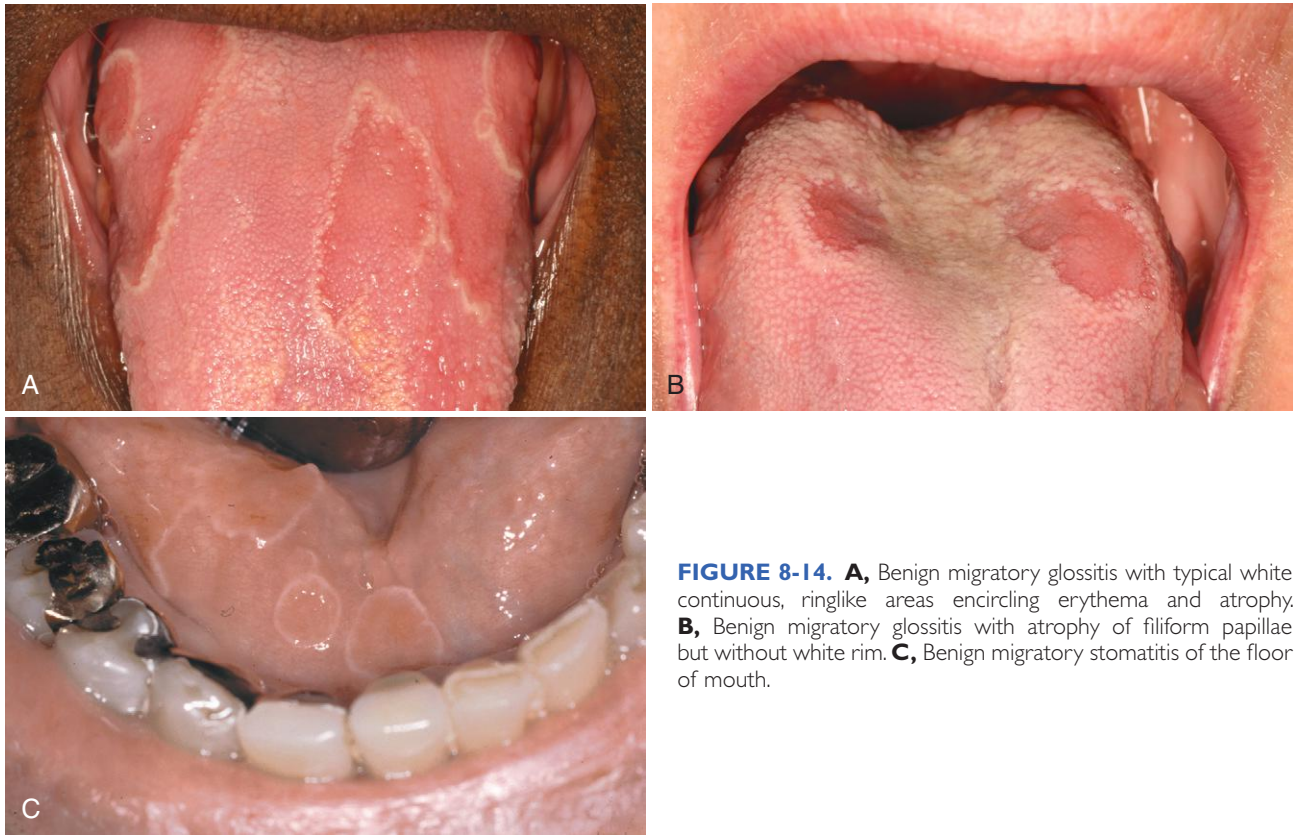
#### Management and Prognosis

- Chronic resolving-relapsing condition
- Pain control with viscous lidocaine and diphenhydramine swish and spit preparation; topical steroids as necessary (see Appendix A)

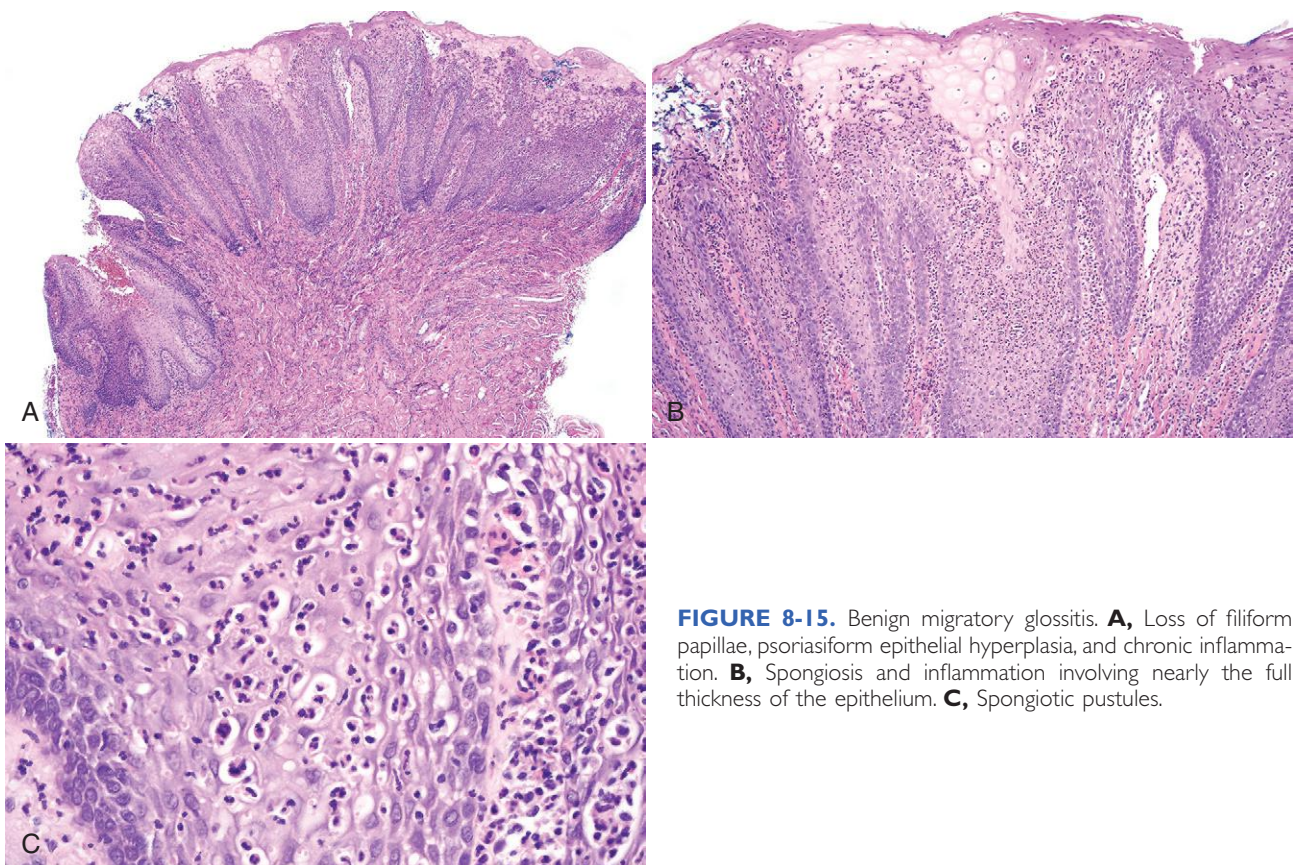
#### REFERENCES

- Gonzaga HF. Both psoriasis and benign migratory glossitis are associated with HLA-Cw6. *Br J Dermatol.* 1996;135:368-370.
- Goregen M, Melikoglu M, Miloglu O, Erdem T. Predisposition of allergy in patients with benign migratory glossitis. *Oral Surg Oral Med Oral Pathol Oral Radiol Endod.* 2010;110:470-474.
- Jainkittivong A, Langlais RP. Geographic tongue: clinical characteristics of 188 cases. *J Contemp Dent Pract.* 2005;6:123-135.
- Zargari O. The prevalence and significance of fissured tongue and geographical tongue in psoriatic patients. *Clin Exp Dermatol.* 2006;31:192-195.



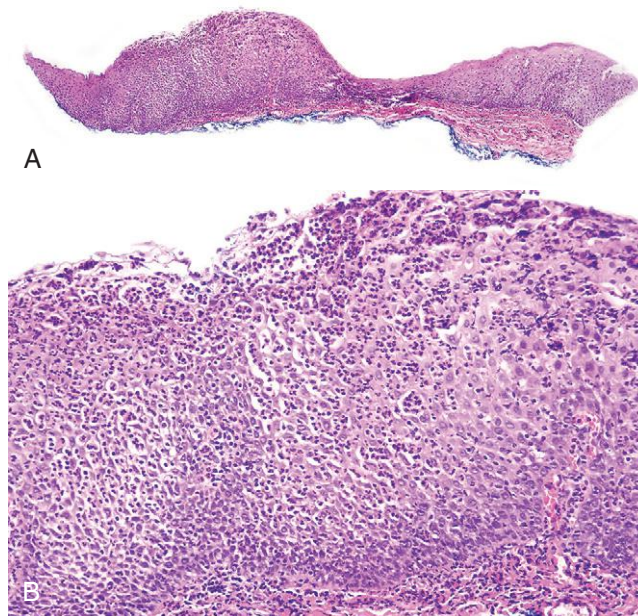


**FIGURE 8-14.** **A**, Benign migratory glossitis with typical white continuous, ringlike areas encircling erythema and atrophy. **B**, Benign migratory glossitis with atrophy of filiform papillae but without white rim. **C**, Benign migratory stomatitis of the floor of mouth.

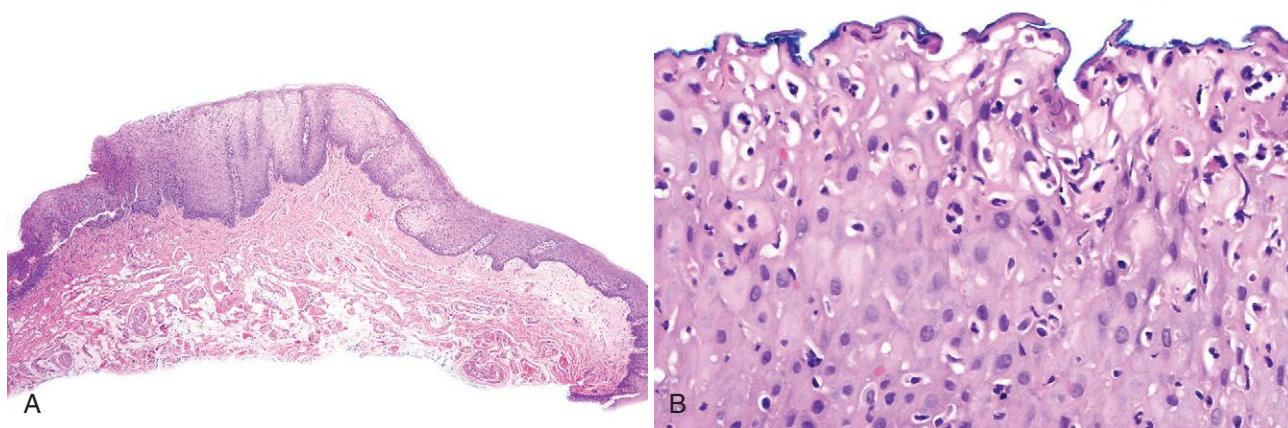


**FIGURE 8-15.** Benign migratory glossitis. **A**, Loss of filiform papillae, psoriasiform epithelial hyperplasia, and chronic inflammation. **B**, Spongiosis and inflammation involving nearly the full thickness of the epithelium. **C**, Spongiotic pustules.





**FIGURE 8-16.** Benign migratory glossitis. **A**, Atrophy of filiform papillae. **B**, Spongiotic pustules involving nearly full epithelial thickness.



**FIGURE 8-17.** Benign migratory glossitis, likely evolving or resolving. **A**, Mild acanthosis and local inflammation. **B**, Subtle spongiotic pustules.

## NONSPECIFIC HYPERSENSITIVITY REACTIONS

### Clinical Findings

- Painful erythematous lesions of the oral mucosa with symptoms coinciding with exposure

### Etiopathogenesis and Histopathologic Features

Contact hypersensitivity reactions are probably within the spectrum of irritant contact stomatitis (see [Chapter 7](#)).

- Spongiotic mucositis with benign epithelial hyperplasia, variable chronic inflammation, and eosinophils in the lamina propria and epithelium ([Fig. 8-18](#))

### Differential Diagnosis

- Eosinophils and spongiosis seen in nonspecific inflammatory lesions

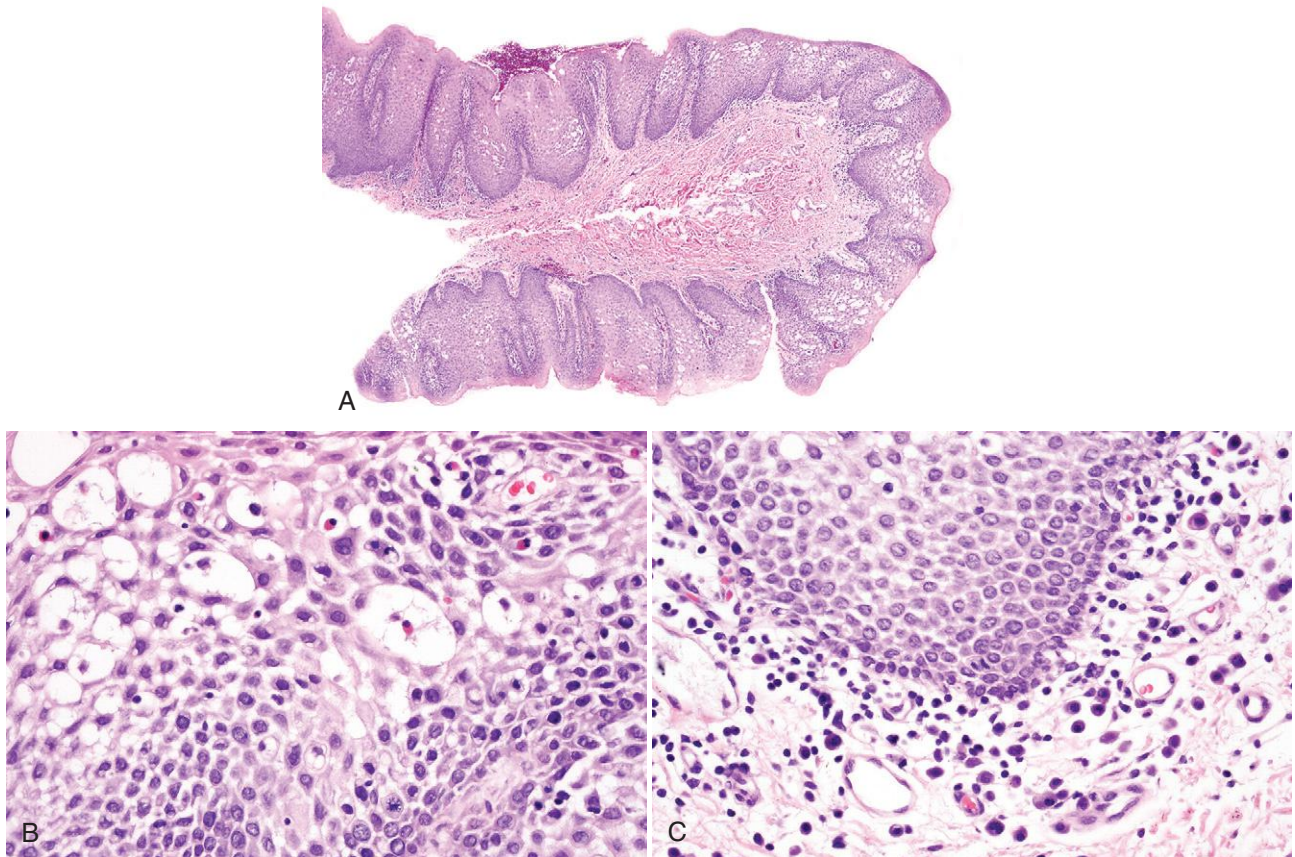
### Management and Prognosis

- Avoidance of inciting agent; topical steroids to resolve lesions (see [Appendix A](#))

### REFERENCES

- Ayango L, Rogers 3rd RS. Oral manifestations of erythema multiforme. *Dermatol Clin.* 2003;21:195-205.
- Chrysomali E, Lozada-Nur F, Dekker NP, et al. Apoptosis in oral erythema multiforme. *Oral Surg Oral Med Oral Pathol Oral Radiol Endod.* 1997;83:272-280.
- Farthing P, Bagan JV, Scully C. Mucosal disease series. Number IV. Erythema multiforme. *Oral Dis.* 2005;11:261-267.
- Lozada-Nur F, Gorsky M, Silverman S Jr. Oral erythema multiforme: clinical observations and treatment of 95 patients. *Oral Surg Oral Med Oral Pathol.* 1989;67:36-40.
- Sanchis JM, Bagan JV, Gavalda C, et al. Erythema multiforme: diagnosis, clinical manifestations and treatment in a retrospective study of 22 patients. *J Oral Pathol Med.* 2010;39:747-752.





**FIGURE 8-18.** Hypersensitivity reaction. **A**, Benign epithelial hyperplasia and spongiosis. **B**, Eosinophils within spongiotic epithelium. **C**, Mild lymphoplasmacytic infiltrate in lamina propria.

## ERYTHEMA MULTIFORME

Erythema multiforme is an acute, self-limited, inflammatory mucocutaneous disease that manifests on the skin; it often involves the oral, ocular, and genital mucosa.

### Clinical Findings

- Affects adults between 20 to 40 years of age; 20% are children; history of viral infection, specifically herpes simplex virus infection, several weeks earlier
- Pruritic, itchy red papules on face, neck, and extremities that progress centripetally toward the trunk over days with postinflammatory hyperpigmentation; ring-like “target” or “iris” lesions typical, especially on the palms
- Oral lesions in 25% to 70% of patients; diffuse painful erythema or ulcerations affecting the mucosa; chronic oral erythema multiforme reported without involvement of skin (Fig. 8-19)
- Minor type: less than 10% skin involvement with little-to-no mucous membranes affected; major type:

more extensive skin involvement with mucous membranes affected

- Stevens-Johnson syndrome, a more severe form of toxic epidermal necrolysis, is more often a drug-induced hypersensitivity reaction or hypersensitivity to *Mycoplasma pneumoniae* and is no longer considered synonymous with severe erythema multiforme.

### Etiopathogenesis and Histopathologic Features

Erythema multiforme is often a hypersensitivity reaction to herpes simplex virus (in at least 50% of cases); other cases result from reactions to nonsteroidal anti-inflammatory drugs, anticonvulsants, or benzoic acid.

- Hydropic degeneration of basal cells, leukocyte exocytosis, keratinocyte apoptosis and necrosis, and sometimes subepithelial bulla formation occur, although these features vary depending on the stage of the lesion; hallmark in skin biopsies is lymphocyte satellitosis around necrotic keratinocytes; variable lymphohistiocytic infiltrate appears in lamina propria and around vessels; usually no eosinophils are present unless the condition is drug associated (Fig. 8-20).

### Differential Diagnosis

- Lichen planus and contact hypersensitivity reactions may appear similar and are differentiated by history and clinical findings; contact stomatitis usually shows eosinophils.

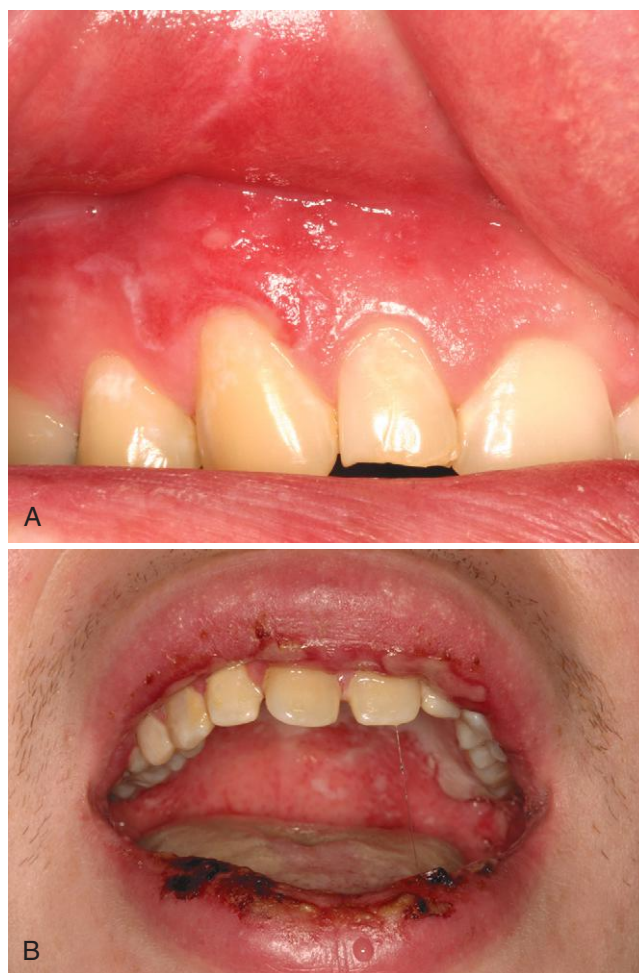### Management and Prognosis

- Mild disease is managed with supportive care and systemic or topical analgesics for pain because it is self-limiting and resolves within a few weeks; more severe cases are usually managed with systemic and topical corticosteroids (see [Appendix A](#)).
- Treatment with acyclovir at the first sign of disease in recurrent erythema multiforme controls disease in approximately 50% of the patients.

### REFERENCES

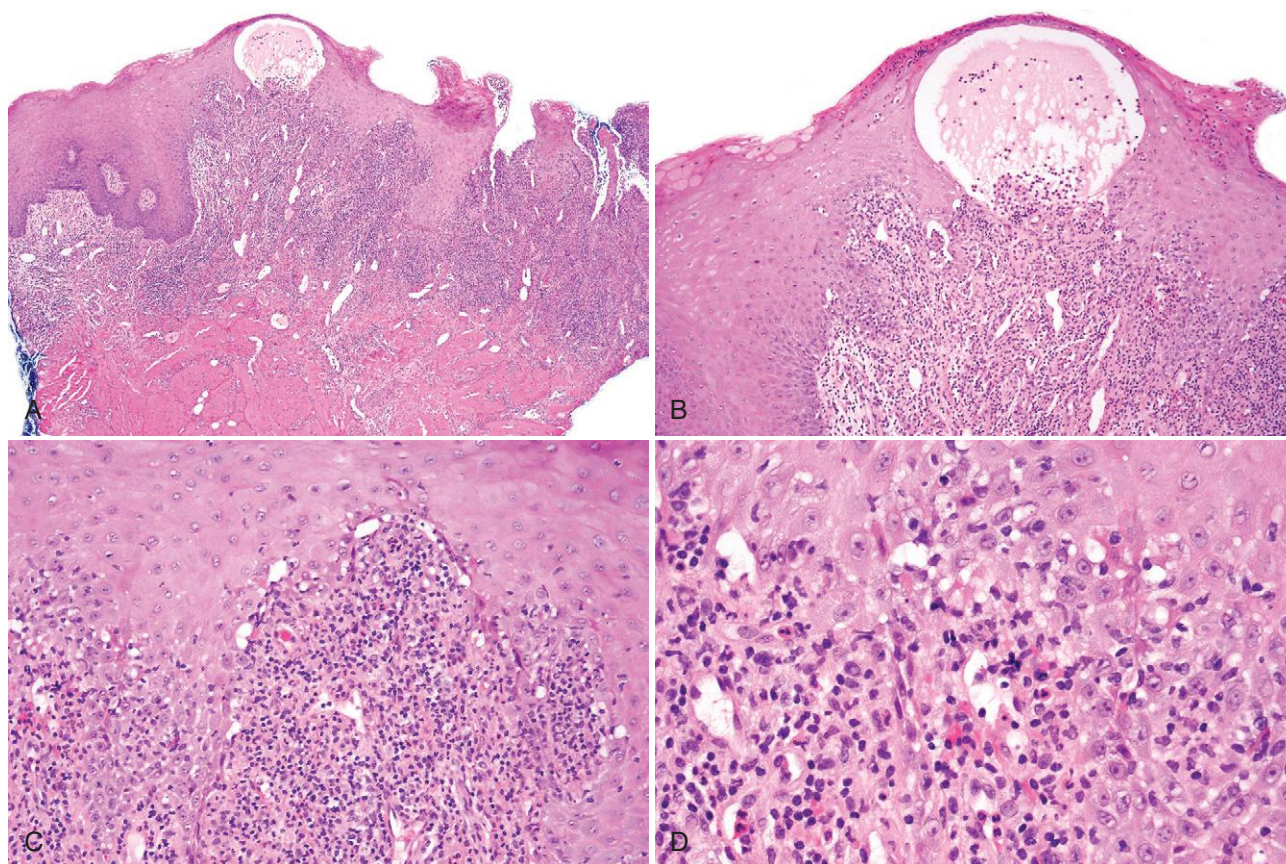
- Ayangco L, Rogers RS 3rd. Oral manifestations of erythema multiforme. *Dermatol Clin*. 2003;21:195-205.
- Buchner A, Lozada F, Silverman S Jr. Histopathologic spectrum of oral erythema multiforme. *Oral Surg Oral Med Oral Pathol*. 1980;49:221-228.

- Chrysomali E, Lozada-Nur F, Dekker NP, et al. Apoptosis in oral erythema multiforme. *Oral Surg Oral Med Oral Pathol Oral Radiol Endod*. 1997;83:272-280.
- Farthing P, Bagan JV, Scully C. Mucosal disease series. Number IV. Erythema multiforme. *Oral Dis*. 2005;11:261-267.
- Leaute-Labreze C, Lamireau T, Chawki D, et al. Diagnosis, classification, and management of erythema multiforme and Stevens-Johnson syndrome. *Arch Dis Child*. 2000;83:347-352.
- Lewis MA, Lamey PJ, Forsyth A, Gall J. Recurrent erythema multiforme: a possible role of foodstuffs. *Br Dent J*. 1989;166:371-373.
- Roujeau JC. Stevens-Johnson syndrome and toxic epidermal necrolysis are severity variants of the same disease which differs from erythema multiforme. *J Dermatol*. 1997;24:726-729.
- Sanchis JM, Bagan JV, Gavalda C, et al. Erythema multiforme: diagnosis, clinical manifestations and treatment in a retrospective study of 22 patients. *J Oral Pathol Med*. 2010;39:747-752.
- Sun Y, Chan RK, Tan SH, Ng PP. Detection and genotyping of human herpes simplex viruses in cutaneous lesions of erythema multiforme by nested PCR. *J Med Virol*. 2003;71:423-428.
- Williams PM, Conklin RJ. Erythema multiforme: a review and contrast from Stevens-Johnson syndrome/toxic epidermal necrolysis. *Dent Clin North Am*. 2005;49:67-76.



**FIGURE 8-19.** Recurrent oral erythema multiforme. **A**, Recurrent lesions secondary to reactivated herpes simplex virus: erythema and ulcers on the gingiva and labial mucosa. **B**, Ulcers of upper labial and palatal mucosa and hemorrhagic crusts on lips. (Courtesy of Dr. Nathaniel Treister, Harvard School of Dental Medicine, Boston, Mass.)





**FIGURE 8-20.** Recurrent oral erythema multiforme (from patient in Fig. 8-19). **A**, Subepithelial blister and acute and chronic inflammation. **B**, Subepithelial blister, with adjacent epithelium exhibiting eosinophilic necrotic keratinocytes. **C**, Hydropic degeneration of basal cells, necrotic keratinocytes, and acute and chronic inflammation. **D**, Hydropic degeneration of basal cells, necrotic keratinocytes, lymphocyte exocytosis, and acute and chronic inflammation.

## PLASMA CELL ORIFICIAL MUCOSITIS (PLASMA CELL STOMATITIS, MUCOUS MEMBRANE PLASMACYTOSIS)

### Clinical Findings

- Brightly erythematous, sometimes nodular gingival hyperplasia occurs (Fig. 8-21); other mucosal sites and mucosa of the upper airway may be involved; localized plaques and cobblestoning may be present, and fissuring of the corners of the mouth and swollen lips are often noted.

### Etiopathogenesis and Histopathologic Features

Hypersensitivity reaction to contactant such as chewing gum, toothpaste, or other contactant.

- Loss of normal keratinization, epithelial hyperplasia with spongiosis, and leukocyte exocytosis; intense plasma cell infiltrate (polyclonal) within the lamina propria (Figs. 8-22 and 8-23); Russell bodies and lymphocytes may be seen.

### Differential Diagnosis

- Banal gingivitis and periodontitis are usually associated with multifocal plasma cell infiltrates that are less dense; clinical findings are important in differentiating these lesions.
- Plasmacytomas show monoclonal plasma cell proliferation with light chain restriction.

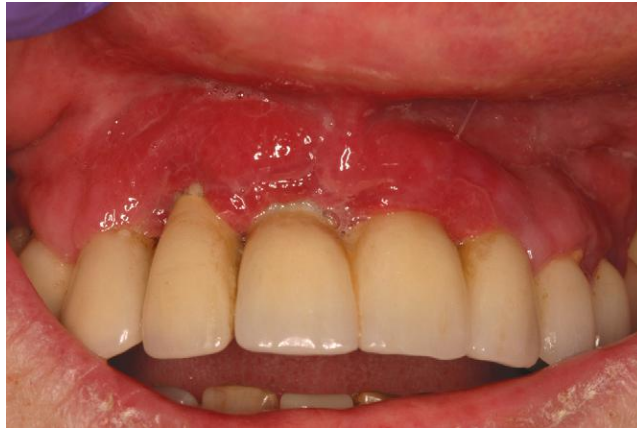### Management and Prognosis

- Identify and discontinue contactant; topical steroid therapy may be helpful (see Appendix A).

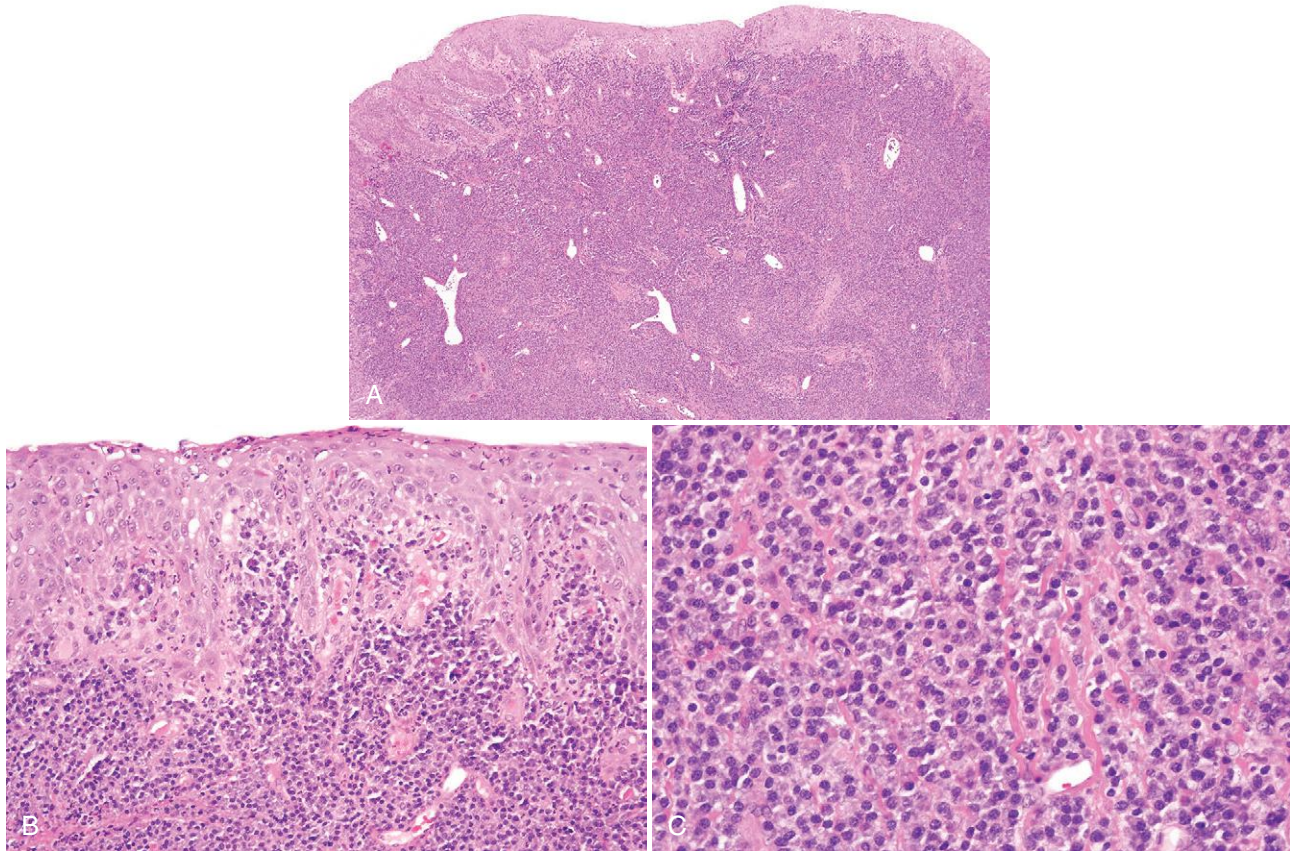
### REFERENCES

- Anil S. Plasma cell gingivitis among herbal toothpaste users: a report of three cases. *J Contemp Dent Pract.* 2007;8:60-66.
- Solomon LW, Wein RO, Rosenwald I, Laver N. Plasma cell mucositis of the oral cavity: report of a case and review of the literature. *Oral Surg Oral Med Oral Pathol Oral Radiol Endod.* 2008;106:853-860.
- Timms MS, Sloan P. Association of supraglottic and gingival idiopathic plasmacytosis. *Oral Surg Oral Med Oral Pathol.* 1991;71:451-453.
- White JW, Olsen KD, Banks PM. Plasma cell orificial mucositis. Report of a case and review of the literature. *Arch Dermatol.* 1986;122:1321-1324.



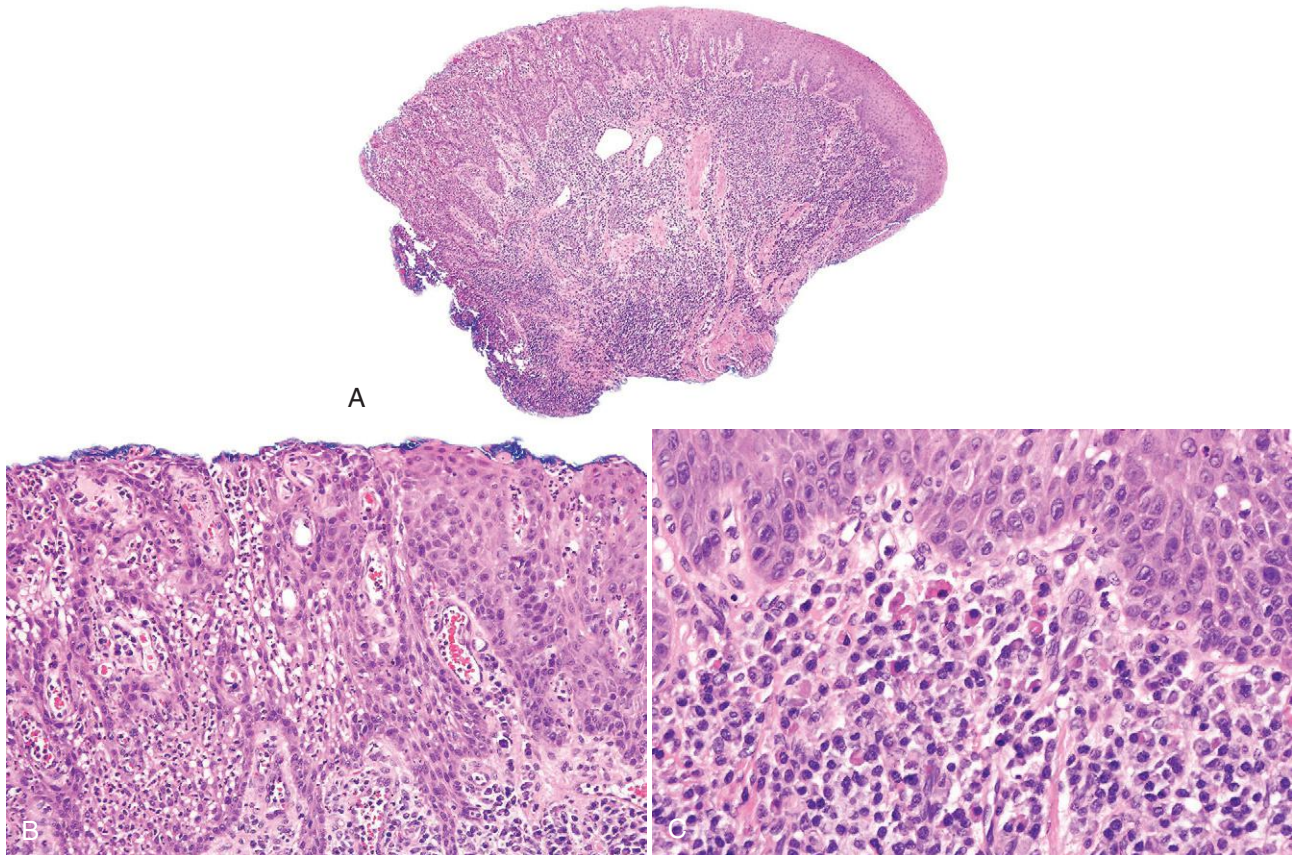


**FIGURE 8-21.** Plasma cell gingivitis manifesting as a nodular swelling and erythema in the maxillary facial gingiva.



**FIGURE 8-22.** Plasma cell gingivitis. **A,** Intense plasma cell infiltrate in the expanded lamina propria, abutting the epithelium (from patient in Fig. 8-21). **B,** Loss of normal surface keratin, spongiosis, and neutrophilic exocytosis. **C,** Intense benign plasma cell infiltrate.





**FIGURE 8-23.** Plasma cell gingivitis. **A**, Moderate plasma cell infiltrate. **B**, Marked spongiosis and neutrophilic exocytosis. **C**, Plasma cells and Russell bodies abutting the epithelium.

## LICHEN PLANUS/LICHENOID MUCOSITIS

Although considered an autoimmune condition by some, the target antigen has yet to be identified.

### Clinical Findings

- This condition occurs in 1% to 2% of adults, usually women in middle age; lesions are generally bilateral and symmetric.
- Three presentations are noted, often in combination: *reticular/keratotic* (classic)—white striations or papules, not usually painful, appear on the buccal mucosa, ventral and dorsal tongue, labial mucosa, and gingiva (Fig. 8-24, *A*); *erythematous/erosive*—red areas of the mucosa, particularly on the gingiva, that look raw and are painful (desquamative gingivitis) (see Fig. 8-24, *B* and *C*); *ulcerative*—yellow fibrin membrane (see Fig. 8-24, *D*); postinflammatory hyperpigmentation is noted in dark-skinned individuals (see Fig. 8-24, *E*); lesions on the tongue result in atrophy of filiform papillae and may not be well reticulated (see Fig. 8-24, *F*).
- Skin involvement is present in 10% to 15% of patients (see Fig. 8-24, *G*); vulvovaginal-gingival and peno-gingival lichen planus are usually associated with the desquamative form of the condition and with

buccal mucosa fibrosis occurring in a minority of patients.

- Chronic graft-versus-host disease after allogenic stem cell transplantation has a similar appearance, but presence of plaques should raise suspicion for proliferative leukoplakia (see Fig. 8-24, *H*)
- Granulomatous lichenoid mucositis tends to affect the upper labial mucosa as macular erythema (see Fig. 8-24, *I*)
- Demarcated white plaques that develop within lichen planus should always be biopsied; often, leukoplakias or erythroleukoplakias are mistakenly diagnosed as plaque-type lichen planus leading to the perception of high incidence of malignant transformation reported in the literature; solitary white plaques should not be considered plaque-type lichen planus but rather leukoplakia.

### Etiopathogenesis and Histopathologic Features

Lichen planus and lichenoid reactions are a final common pathway of tissue reaction characterized clinically by reticulated keratosis and variable erythema and histologically by T cell destruction of the basal cells; tumor necrosis factor- $\alpha$  plays an important role. It is not possible to distinguish by histopathology among idiopathic lichen planus, lichenoid hypersensitivity reactions related to medications (such as hydrochlorothiazide

and other antihypertensive agents, carbamazepine, allopurinol, sulfasalazine, and some monoclonal antibodies), contact lichenoid reactions to dental amalgams, or lichen planus associated with hepatitis C. The degree to which histopathologic features manifest depends on the stage of the lesion and whether the lesion has been treated. Cutaneous disease is associated with a higher incidence of HLA-DRB1\*0101, and vulvovaginal-gingival syndrome may be associated with HLA-DQB1\*0201. HLA-DR6 is seen in higher incidence in Italians with hepatitis C–associated lichen planus.

- Two most important criteria: degeneration and loss (squamatization) of the basal cell layer and a lymphocytic band of variable thickness at interface with blurring of interface; lesions may be parakeratotic or orthokeratotic, and epithelium may be hyperplastic or atrophic (Figs. 8-25 and 8-26).
- Spongiosis, leukocyte exocytosis, colloid (Civatte or cytoid) body formation, sawtooth rete ridges, postinflammatory hypermelanosis, thickened basement membrane zone, increased numbers of Langerhans cells, and subepithelial clefting are variable findings; clefting is a reliable artifact and is caused by lack of basal cell adhesion to the lamina propria rather than necessarily representing a clinical blister (Figs. 8-27 to 8-29).
- Plasma cells often are noted in the vicinity of an ulcer or in gingival lesions; eosinophils may be seen and hypersensitivity reaction should be considered if present in large numbers, especially within the epithelium.
- Granulomatous lichenoid lesions (on the labial mucosa) exhibit many histiocytes in the lamina propria (Figs. 8-30 and 8-31).
- The terms *lichenoid stomatitis* and *mucositis* are often used if not all of the features are seen or if they are subtle; such lesions may be waxing or waning or result from therapy (Fig. 8-32).
- Direct immunofluorescence shows shaggy fibrinogen in stalactite pattern at basement membrane zone, and IgM staining of colloid bodies and basement membrane zone (Fig. 8-33); granular (not linear) C3 deposition may be seen.
- Lichenoid hypersensitivity reactions are indistinguishable histologically from idiopathic lichen planus.
- A particular contact hypersensitivity reaction is cinnamic aldehyde–associated lichenoid mucositis characterized by a dense lymphohistiocytic infiltrate at the interface and perivascular and paravascular lymphoid aggregates (these should not be interpreted as vasculitis) (Fig. 8-34).

### Differential Diagnosis

- Epithelial dysplasia (and carcinoma) often exhibits a lymphocytic band at the interface associated with hyperplasia (not loss) of the basal cell layer (see Chapter 11); use of term *lichenoid dysplasia* is misleading and should be avoided.

- Chronic graft-versus-host disease has muted features of lichen planus and the lymphocytic band is usually sparse because of immunosuppression (Fig. 8-35).
- Lupus erythematosus shows hydropic degeneration of basal cells, alternating epithelial atrophy and hyperplasia, a lymphocytic band at the interface, and linear IgG at the interface on direct immunofluorescence.
- Mucous membrane pemphigoid exhibits preservation of the basal cells (see later).
- Chronic ulcerative stomatitis (a condition that histologically resembles erosive lichen planus) exhibits antibodies directed against  $\delta$ Np63 $\alpha$ , an isoform of p63 in the nucleus of epithelial cells; direct immunofluorescence studies using monkey esophagus shows speckled nuclear staining; indirect immunofluorescence using guinea pig esophagus demonstrates nuclear reactivity particularly well.
- Rare cases of lichen planus pemphigoides have been reported, possibly resulting from epitope spread.

### Management and Prognosis

- Management of symptomatic lesions is with episodic topical antiinflammatory therapy (see Appendix A); tumor necrosis factor inhibitors may resolve lesions (but may also precipitate them).
- Changing antihypertensive medications may not be helpful, because most classes of such medications may result in these lesions.
- Malignant transformation of lichen planus is controversial (likely 0.1% to 0.2%); some cases of histologic dysplasia with a lymphocytic band at the interface (a frequent occurrence) is misdiagnosed as lichen planus with reactive atypia, and these lesions progress to carcinoma; conversely, cases of lichen planus with reactive atypia (a frequent occurrence) are diagnosed as lichenoid dysplasia.
- Replacing amalgam restorations in patients with demonstrated hypersensitivity to amalgams resolves lesions.

### REFERENCES

- Al-Hashimi I, Schifter M, Lockhart PB, et al. Oral lichen planus and oral lichenoid lesions: diagnostic and therapeutic considerations. *Oral Surg Oral Med Oral Pathol Oral Radiol Endod.* 2007;103(suppl): S25 e1-12.
- Asarch A, Gottlieb AB, Lee J, et al. Lichen planus–like eruptions: an emerging side effect of tumor necrosis factor-alpha antagonists. *J Am Acad Dermatol.* 2009;61:104-111.
- Beutner EH, Chorzelski TD, Parodi A, et al. Ten cases of chronic ulcerative stomatitis with stratified epithelium-specific antinuclear antibody. *J Am Acad Dermatol.* 1991;24:781-782.
- Carrozzo M, Brancatello F, Dametto E, et al. Hepatitis C virus–associated oral lichen planus: is the geographical heterogeneity related to HLA-DR6? *J Oral Pathol Med.* 2005;34:204-208.
- Kimkong I, Hirankarn N, Nakkuntod J, Kitkumthorn N. Tumour necrosis factor-alpha gene polymorphisms and susceptibility to oral lichen planus. *Oral Dis.* 2011;17:206-209.
- Kulthanan K, Jiamton S, Varothai S, et al. Direct immunofluorescence study in patients with lichen planus. *Int J Dermatol.* 2007;46: 1237-1241.
- Lodi G, Scully C, Carrozzo M, et al. Current controversies in oral lichen planus: report of an international consensus meeting. Part 1. Viral infections and etiopathogenesis. *Oral Surg Oral Med Oral Pathol Oral Radiol Endod.* 2005;100:40-51.



Mignogna MD, Fortuna G, Leuci S, et al. Lichen planus pemphigoides, a possible example of epitope spreading. *Oral Surg Oral Med Oral Pathol Oral Radiol Endod.* 2010;109:837-843.

Sciubba JJ. Autoimmune oral mucosal diseases: clinical, etiologic, diagnostic, and treatment considerations. *Dent Clin North Am.* 2011;55:89-103.

Scully C, Carrozzo M. Oral mucosal disease: lichen planus. *Br J Oral Maxillofac Surg.* 2008;46:15-21.

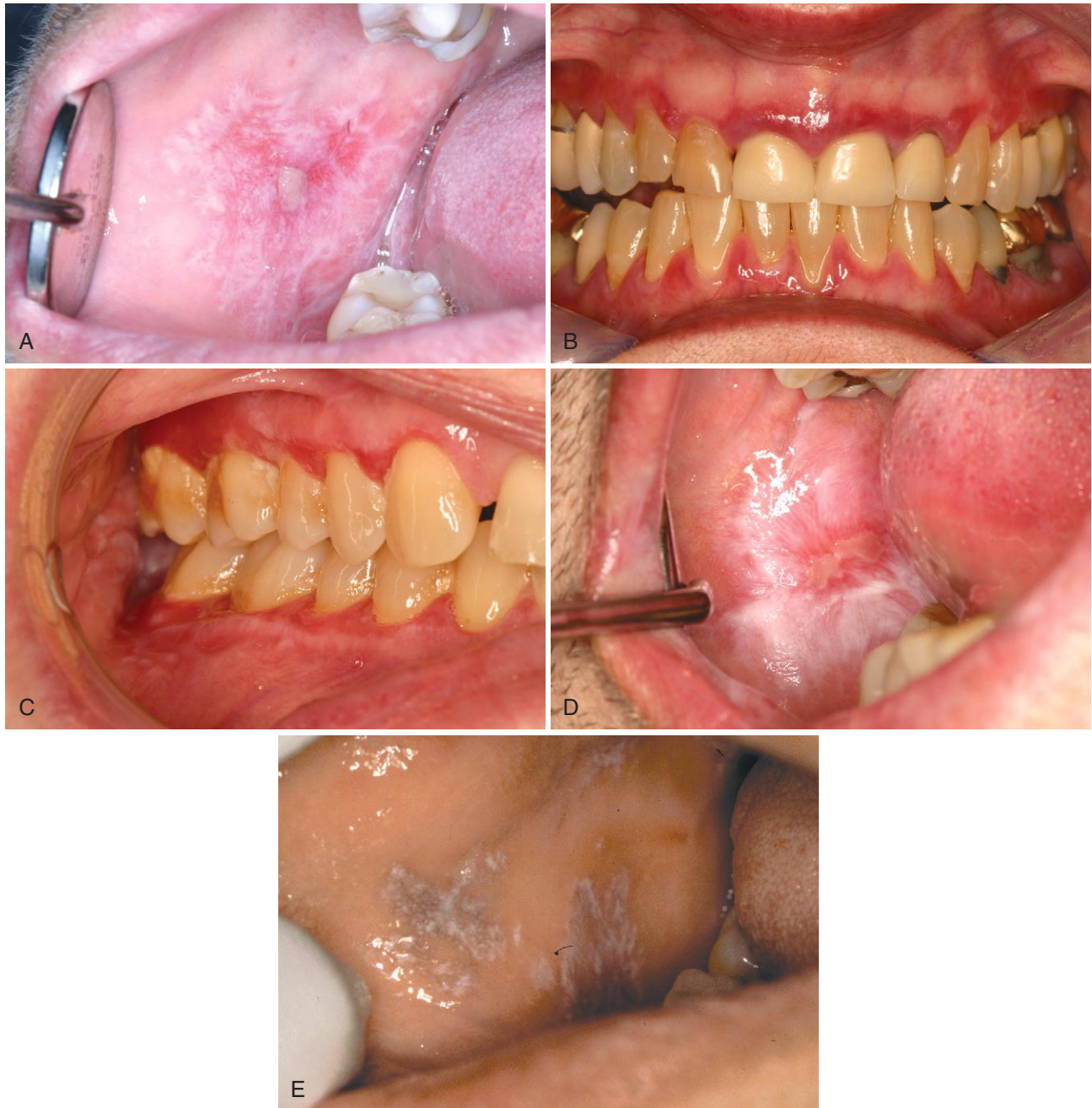Setterfield JF, Neill S, Shirlaw PJ, et al. The vulvovaginal gingival syndrome: a severe subgroup of lichen planus with characteristic clinical features and a novel association with the class II HLA DQB1\*0201 allele. *J Am Acad Dermatol.* 2006;55:98-113.

Solomon LW. Chronic ulcerative stomatitis. *Oral Dis.* 2008;14:383-389.

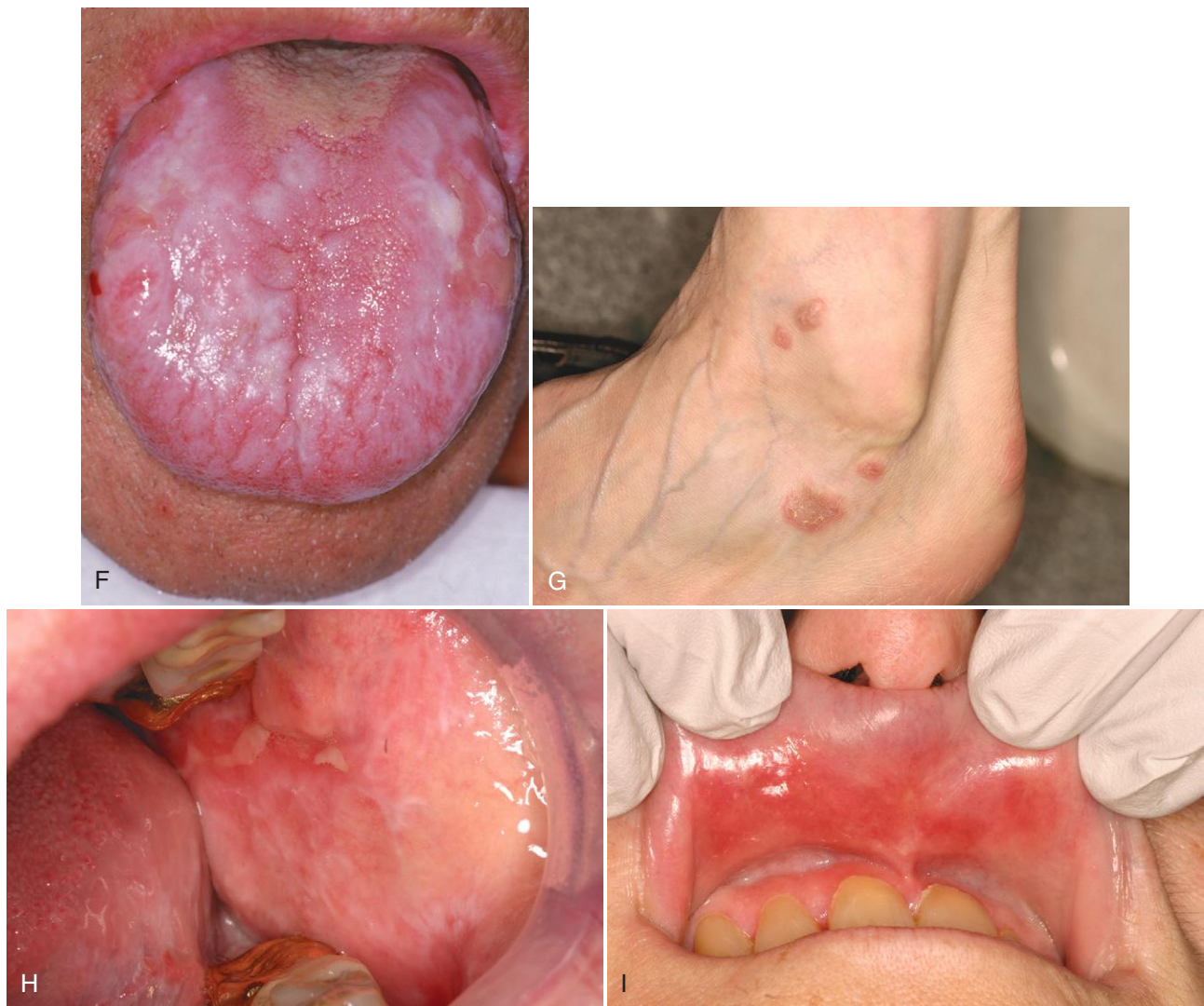Thornhill MH. Oral lichenoid lesions and amalgam fillings. *Evid Based Dent.* 2006;7:74-75.

Thornhill MH, Sankar V, Xu XJ, et al. The role of histopathological characteristics in distinguishing amalgam-associated oral lichenoid reactions and oral lichen planus. *J Oral Pathol Med.* 2006;35:233-240.

van der Meij EH, Mast H, van der Waal I. The possible premalignant character of oral lichen planus and oral lichenoid lesions: a prospective five-year follow-up study of 192 patients. *Oral Oncol.* 2007;43:742-748.

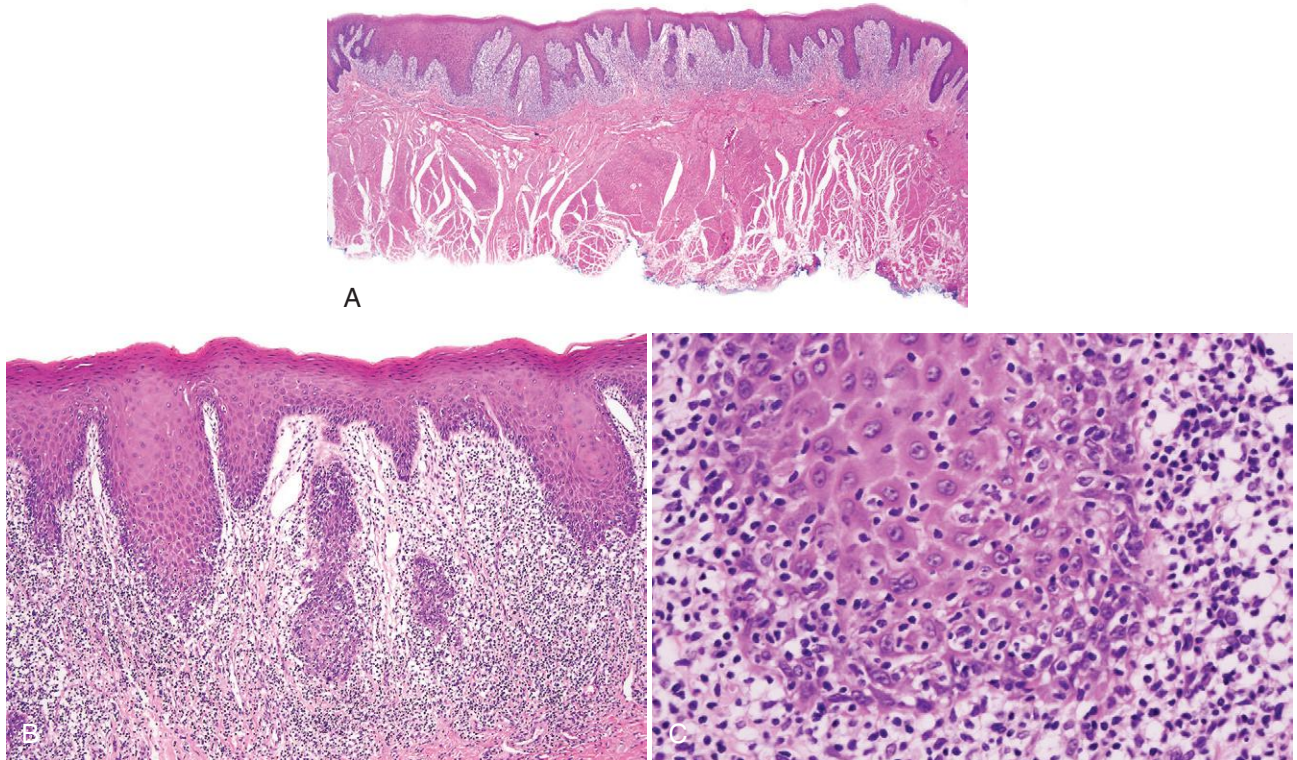


**FIGURE 8-24.** Lichen planus. **A**, Reticulated, erythematous, and ulcerated (yellow fibrin membrane). **B**, Erythematous lichen planus presenting as diffuse desquamative gingivitis with faint reticulations. **C**, Erythematous lichen planus with diffuse erythema with faint reticulations, affecting all four quadrants in this patient. **D**, Reticulated, erythematous, and ulcerated (yellow fibrin membrane). **E**, Reticulated lesion with associated postinflammatory hyperpigmentation. *Continued*

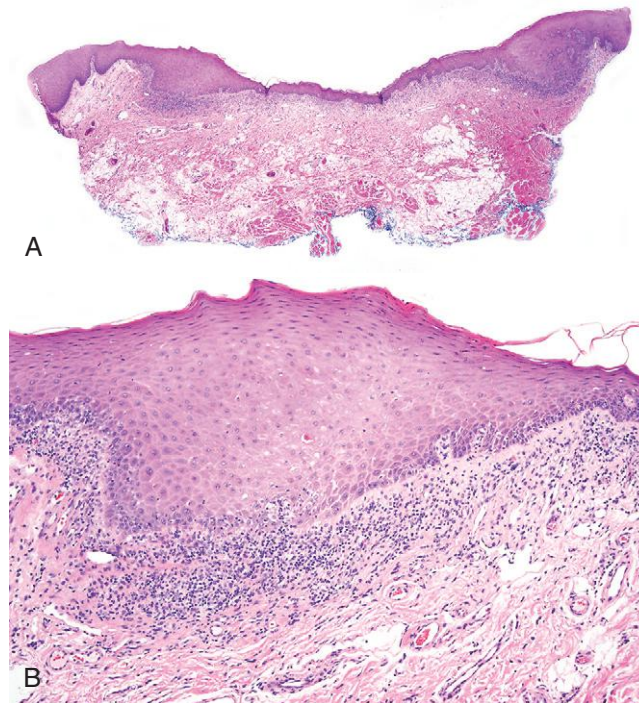


**FIGURE 8-24, cont'd.** **F**, Lichen planus on the tongue: symmetric white cast, atrophy of filiform papillae, and ulceration on lateral aspects; lips are also involved. **G**, Lichen planus of the skin of the foot. **H**, Chronic graft-versus-host disease: reticulated, erythematous, and ulcerated. **I**, Granulomatous lichenoid stomatitis: erythema of the upper labial mucosa.



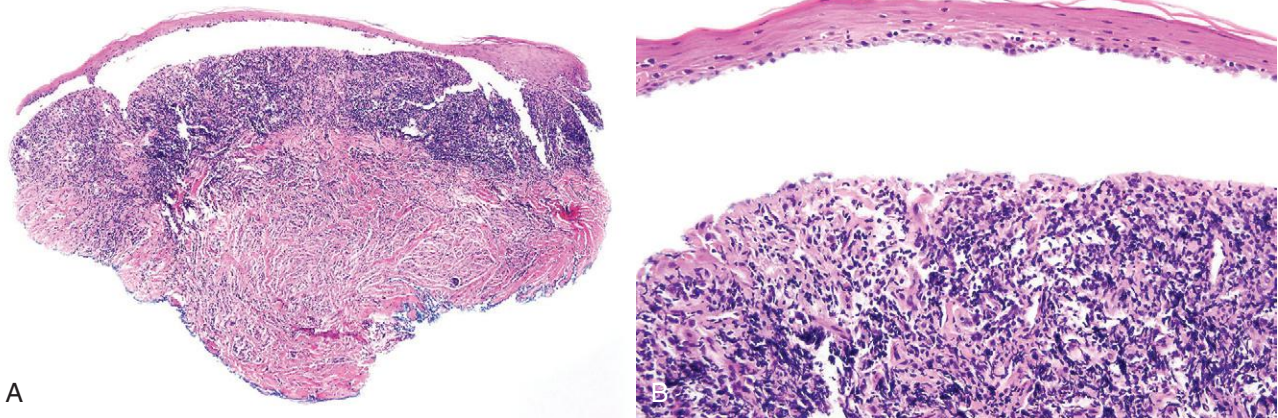


**FIGURE 8-25.** Lichen planus. **A**, Hyperparakeratosis, epithelial hyperplasia, sawtooth rete ridges, and lymphocytic band. **B**, Hyperparakeratosis, spongiosis, leukocyte exocytosis, and lymphocytic band at the interface. **C**, Squamated (degenerated) basal cells without colloid bodies.

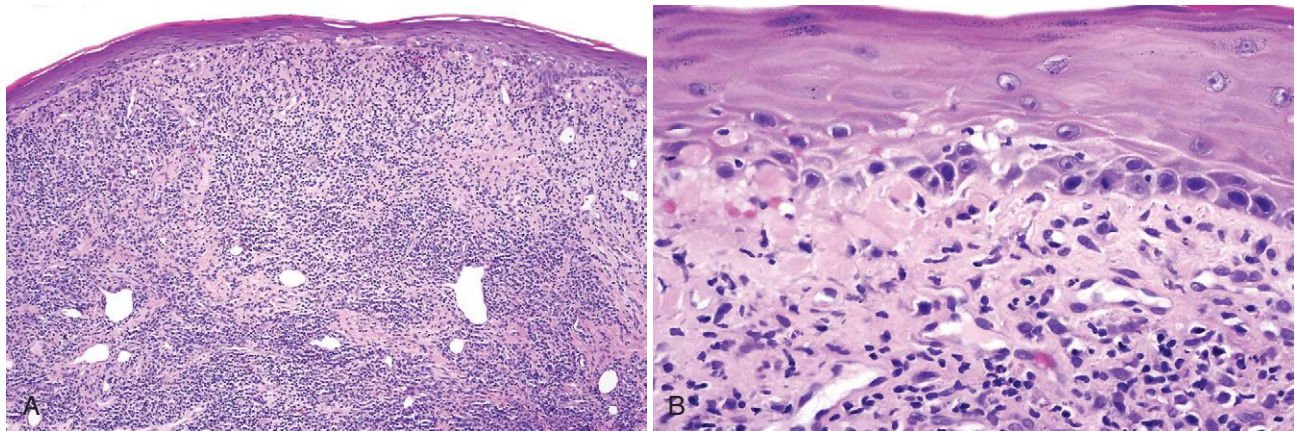


**FIGURE 8-26.** Lichen planus. **A**, Epithelium exhibits both hyperplasia and atrophy with lymphocytic band. **B**, Squamatization of basal cells, thickened basement membrane zone, and mild-to-moderate lymphocytic band.

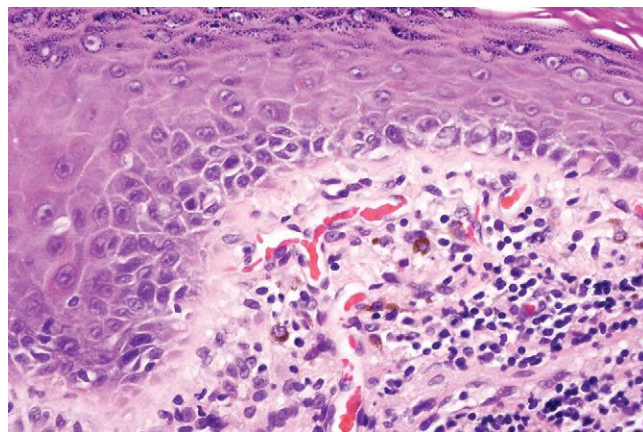




**FIGURE 8-27.** Lichen planus. **A**, Hyperorthokeratosis, epithelial atrophy, subepithelial cleft, and lymphocytic band. **B**, Squamatization of basal cells leading to subepithelial cleft.

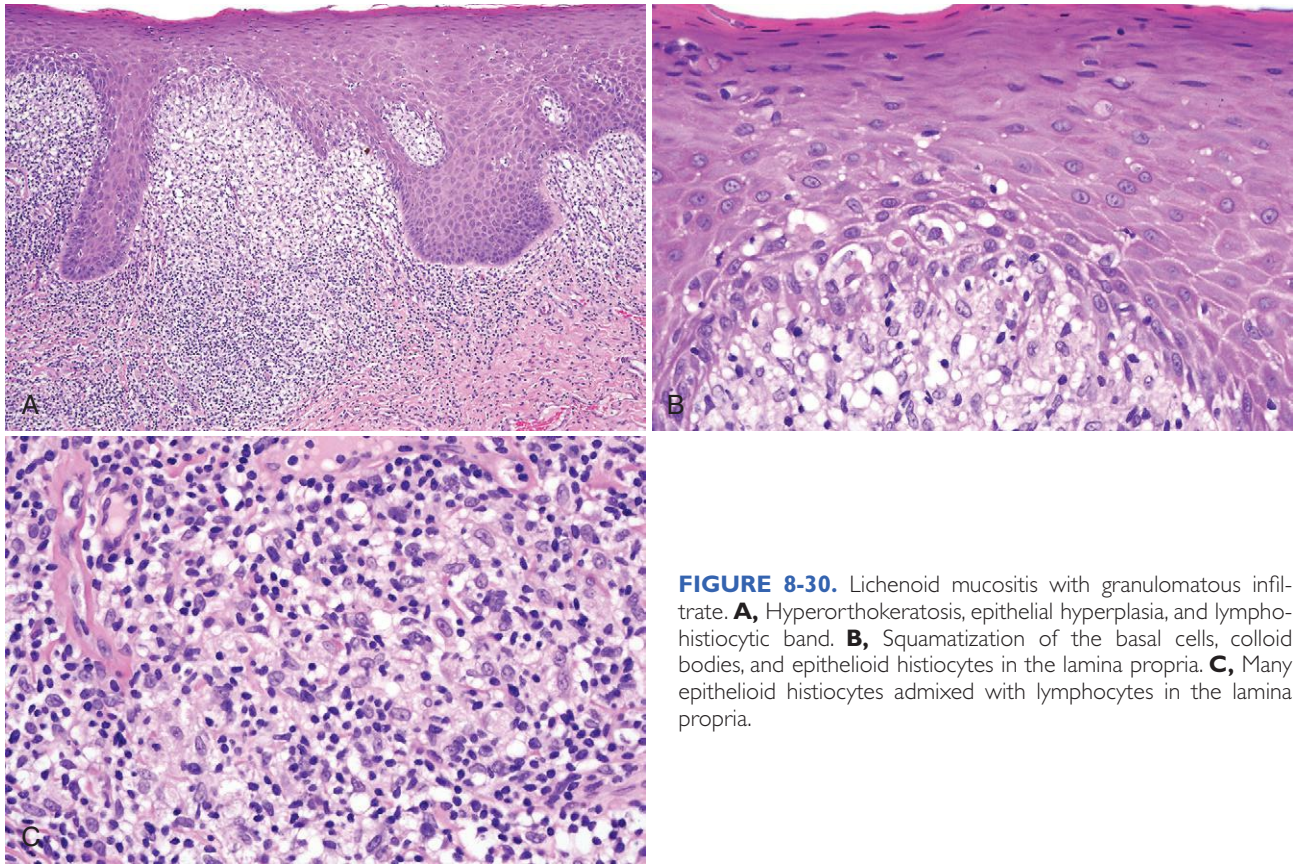


**FIGURE 8-28.** Gingival lichen planus. **A**, Hyperorthokeratosis, epithelial atrophy, and intense lymphoplasmacytic infiltrate. **B**, Epithelial atrophy and many colloid bodies.

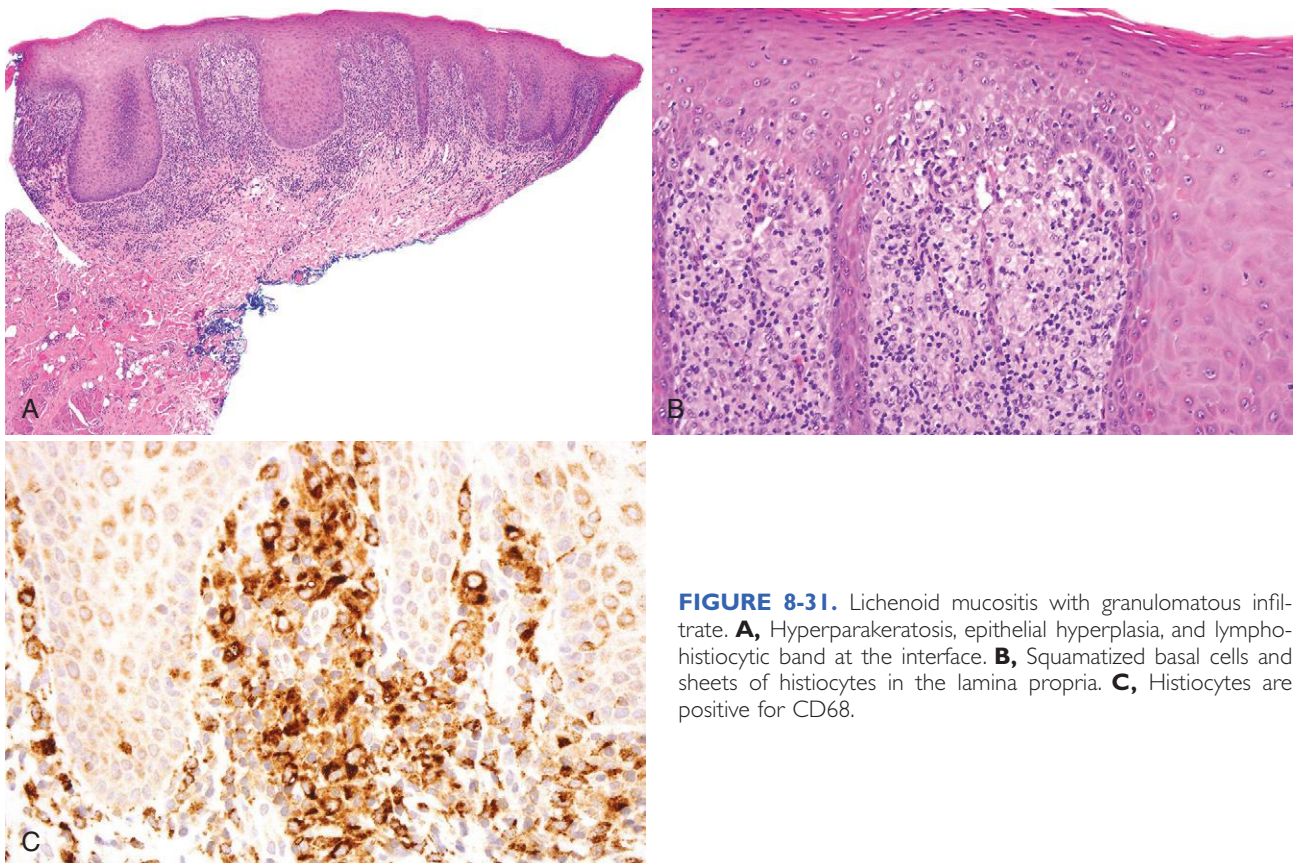


**FIGURE 8-29.** Lichen planus with incontinent melanin and melanophages (postinflammatory hypermelanosis).



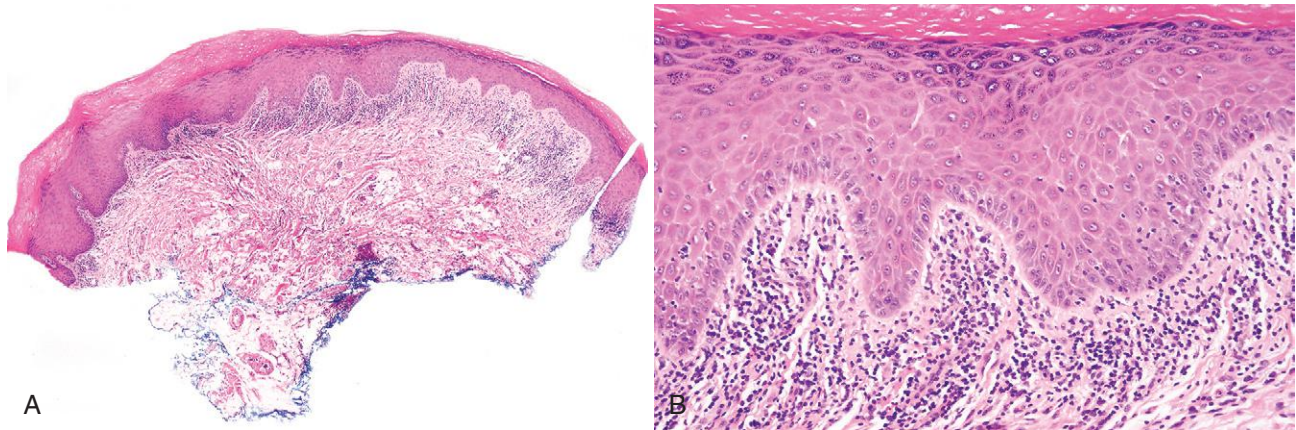


**FIGURE 8-30.** Lichenoid mucositis with granulomatous infiltrate. **A**, Hyperorthokeratosis, epithelial hyperplasia, and lymphohistiocytic band. **B**, Squamatization of the basal cells, colloid bodies, and epithelioid histiocytes in the lamina propria. **C**, Many epithelioid histiocytes admixed with lymphocytes in the lamina propria.

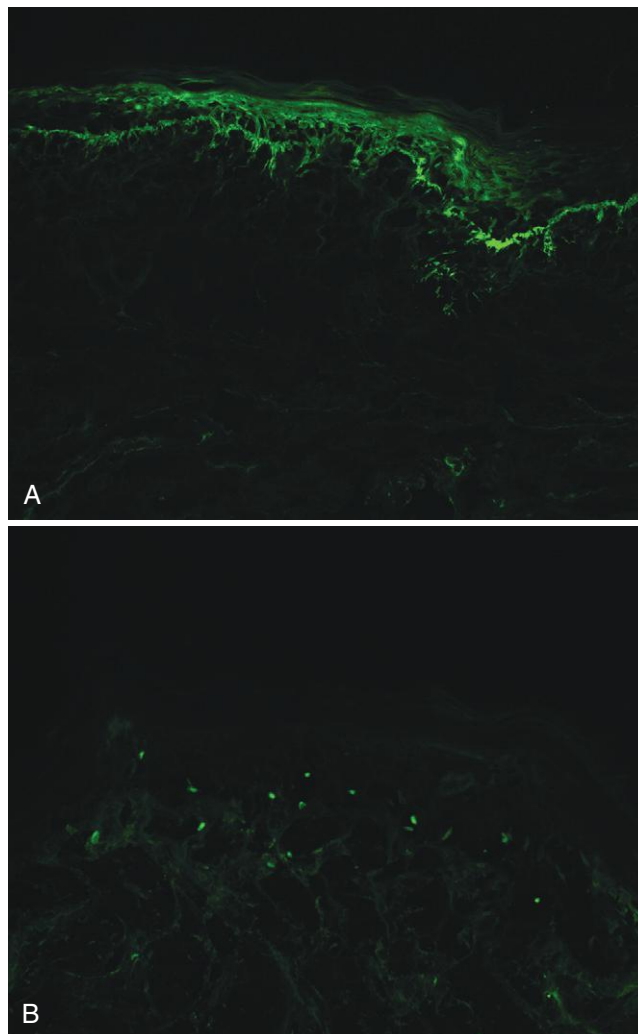


**FIGURE 8-31.** Lichenoid mucositis with granulomatous infiltrate. **A**, Hyperparakeratosis, epithelial hyperplasia, and lymphohistiocytic band at the interface. **B**, Squamatized basal cells and sheets of histiocytes in the lamina propria. **C**, Histiocytes are positive for CD68.



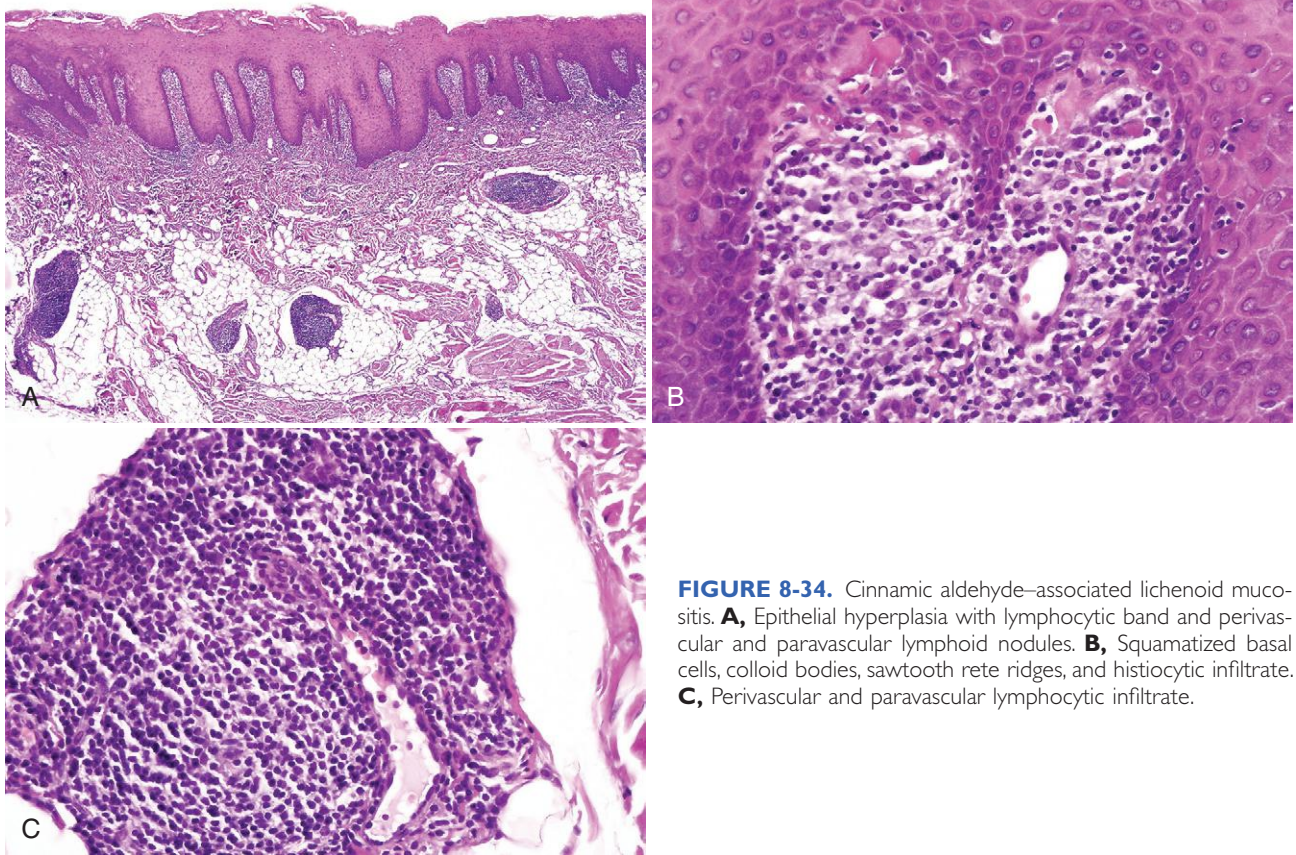


**FIGURE 8-32.** Lichenoid mucositis. **A**, Hyperorthokeratosis of variable thickness, sawtooth rete ridges, and mild-to-moderate lymphocytic infiltrate; likely a waxing or waning lichen planus. **B**, Mild spongiosis, leukocyte exocytosis, and lymphocytic band.

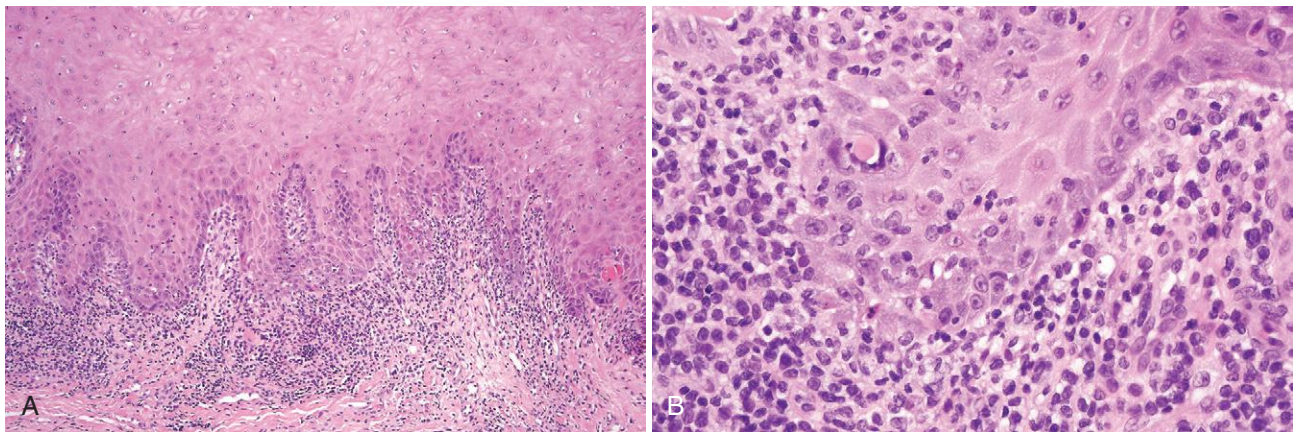


**FIGURE 8-33.** Lichen planus: direct immunofluorescence study. **A**, Shaggy deposits of fibrinogen at the basement membrane zone. **B**, IgM staining of colloid bodies.





**FIGURE 8-34.** Cinnamic aldehyde–associated lichenoid mucositis. **A**, Epithelial hyperplasia with lymphocytic band and perivascular and paravascular lymphoid nodules. **B**, Squamated basal cells, colloid bodies, sawtooth rete ridges, and histiocytic infiltrate. **C**, Perivascular and paravascular lymphocytic infiltrate.



**FIGURE 8-35.** Chronic graft-versus-host disease. **A**, Oral mucosa with bandlike lymphocytic infiltrate at interface. **B**, Typical degeneration/squamization of basal cells with colloid body and lymphocytic infiltrate.

## Autoimmune Conditions

The two autoimmune diseases that often present in the oral mucosa are mucous membrane pemphigoid (by far the more common) and pemphigus vulgaris, and a common clinical presentation is desquamative gingivitis (generalized red, denuded gingiva), similar to lichen planus. Other autoimmune diseases such as lupus erythematosus, linear IgA disease, and epidermolysis

bullosa acquisita rarely manifest in the mouth in the absence of skin lesions.

## MUCOUS MEMBRANE PEMPHIGOID

Mucous membrane pemphigoid is a heterogeneous group of subepithelial blistering disorders with autoantibodies directed against a number of antigens, depending on the presentation.



### Clinical Findings

- Pemphigoid usually occurs in middle-aged females.
- Painful, bleeding gums are reported, especially when brushing teeth; desquamative gingivitis is the most common presentation with bright red, denuded, painful, and tender gingiva (usually on the buccal or facial aspect) (Fig. 8-36, A); ulcers are uncommon on other sites without gingival involvement; remnants of necrotic blister roof appears as pseudomembrane.
- Approximately 70% to 80% of all cases of desquamative gingivitis represent either mucous membrane pemphigoid or lichen planus; the rest are other autoimmune blistering diseases or oral hypersensitivity reactions (see Fig. 8-36, B).

### Etiopathogenesis and Histopathologic Features

Primary mucosal disease generally involves BP180 (BPAg2), less often BP230 (BPAg1), laminin-332 (formerly laminin-5 or epiligrin), and  $\beta 4$  subunit of  $\alpha 6\beta 4$  integrin; oral and ocular pemphigoid are associated with increased frequency of HLA-DQB1\*0301.

- Subepithelial clefting is noted with preservation of basal cells that protrude into the cleft; epithelium may be hyperplastic or atrophic and generally lacks spongiosis; biopsies often show only detached fragments of epithelium with intact basal cells (Figs. 8-37, 8-38 and 8-39); lamina propria shows variable lymphocytic infiltrate; eosinophils are uncommon.
- Direct immunofluorescence studies show linear IgG, C3, and/or IgA at the basement membrane zone (Fig. 8-40).
- Circulating antibodies manifest in less than half the cases; immunoreactants localize to the roof of the lesion in salt split skin technique.

### Differential Diagnosis

- Lichen planus shows subepithelial clefting, as well as degeneration or squamatization of basal cells, colloid bodies, and sawtooth rete ridges.
- Presence of linear IgA on direct immunofluorescence should **not** be interpreted as primary linear IgA bullous disorder, unless there are typical skin lesions of linear IgA bullous dermatosis, bullous dermatosis of childhood, or dermatitis herpetiformis associated with celiac disease.
- Paraneoplastic pemphigoid has been reported in cases of lymphoma and renal cell carcinoma, but these may represent paraneoplastic autoimmune multiorgan syndrome (see later).
- Lichen planus pemphigoides, and the simultaneous development of autoantibodies against pemphigus vulgaris, occur because of epitope spread.

- Angina bullosa hemorrhagica manifests with intact basal cells, hemorrhage within subepithelial bulla and granulation tissue, and exhibits a typical clinical history of waxing and waning hemorrhagic bullae with a history of chronic steroid inhaler use.

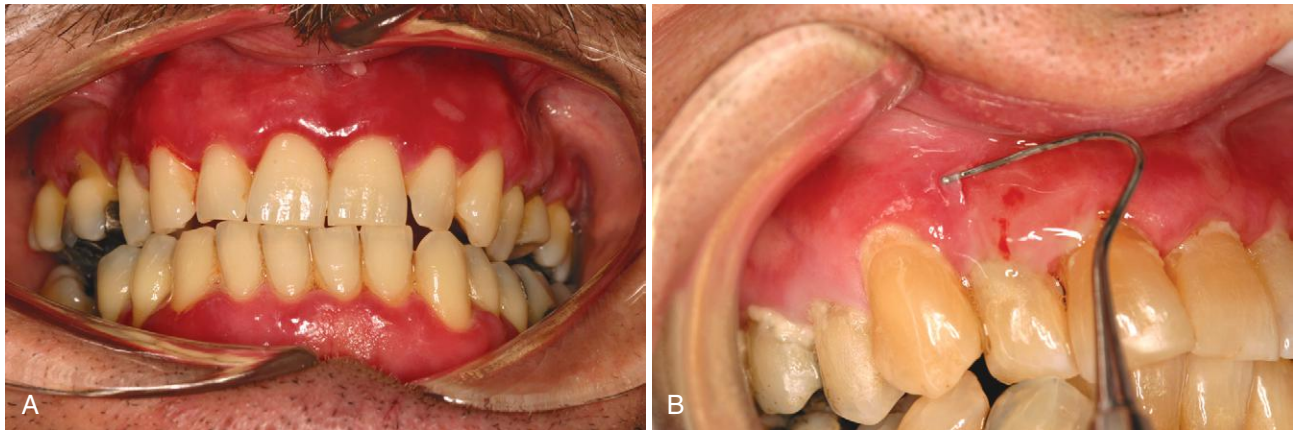
### Management and Prognosis

- Topical steroids are the mainstay of treatment with or without up-front systemic steroid therapy to rapidly bring disease under control (see Appendix A); a stent used to hold the steroid under occlusion is particularly helpful (Fig. 8-41); topical or systemic analgesia is used for pain control; patient should see an ophthalmologist and dermatologist to evaluate for conjunctival and skin lesions.
- Dapsone is particularly effective for mucous membrane pemphigoid; alternative therapies include niacinamide and vitamin B or etanercept.

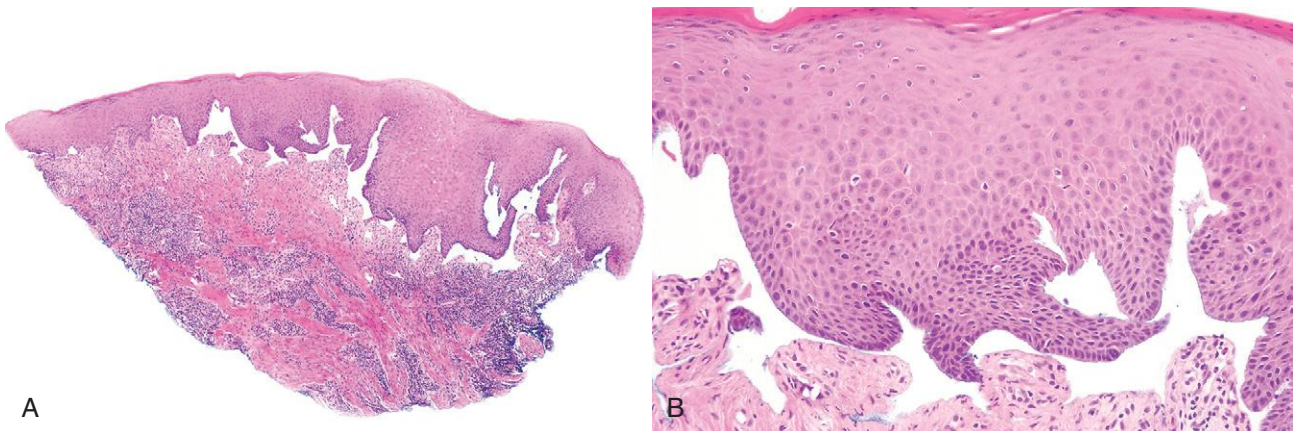
### REFERENCES

- Carrozzo M, Fasano ME, Broccoletti R, et al. HLA-DQB1 alleles in Italian patients with mucous membrane pemphigoid predominantly affecting the oral cavity. *Br J Dermatol.* 2001;145:805-808.
- Chan LS, Ahmed AR, Anhalt GJ, et al. The first international consensus on mucous membrane pemphigoid: definition, diagnostic criteria, pathogenic factors, medical treatment, and prognostic indicators. *Arch Dermatol.* 2002;138:370-379.
- Egan CA, Zone JJ. Linear IgA bullous dermatosis. *Int J Dermatol.* 1999;38:818-827.
- Giuliani M, Favia GF, Lajolo C, Miani CM. Angina bullosa hemorrhagica: presentation of eight new cases and a review of the literature. *Oral Dis.* 2002;8:54-58.
- Horvath B, Niedermeier A, Podstawa E, et al. IgA autoantibodies in the pemphigoids and linear IgA bullous dermatosis. *Exp Dermatol.* 2010;19:648-653.
- Kharfi M, Khaled A, Karaa A, et al. Linear IgA bullous dermatosis: the more frequent bullous dermatosis of children. *Dermatol Online J.* 2010;16:2.
- Leao JC, Ingafou M, Khan A, et al. Desquamative gingivitis: retrospective analysis of disease associations of a large cohort. *Oral Dis.* 2008;14:556-560.
- Lo Russo L, Fierro G, Guiglia R, et al. Epidemiology of desquamative gingivitis: evaluation of 125 patients and review of the literature. *Int J Dermatol.* 2009;48:1049-1052.
- Saravanan K, Baer ST, Meredith A, et al. Benign mucous membrane pemphigoid of the upper aero-digestive tract: rare paraneoplastic syndrome presentation in renal cell carcinoma. *J Laryngol Otol.* 2006;120:237-239.
- Schmidt E, Zillikens D. Modern diagnosis of autoimmune blistering skin diseases. *Autoimmun Rev.* 2010;10:84-89.
- Scully C, Lo Muzio L. Oral mucosal diseases: mucous membrane pemphigoid. *Br J Oral Maxillofac Surg.* 2008;46:358-366.
- Sobjanek M, Sokolowska-Wojdylo M, Sztaba-Kania M, et al. Clinical and immunopathological heterogeneity of 22 cases of linear IgA bullous dermatosis. *J Eur Acad Dermatol Venerol.* 2008;22:1131.
- Yih WY, Maier T, Kratochvil FJ, Zieper MB. Analysis of desquamative gingivitis using direct immunofluorescence in conjunction with histology. *J Periodontol.* 1998;69:678-685.
- Zakka LR, Keskin DB, Reche P, Ahmed AR. Relationship between target antigens and major histocompatibility complex (MHC) class II genes in producing two pathogenic antibodies simultaneously. *Clin Exp Immunol.* 2010;162:224-236.

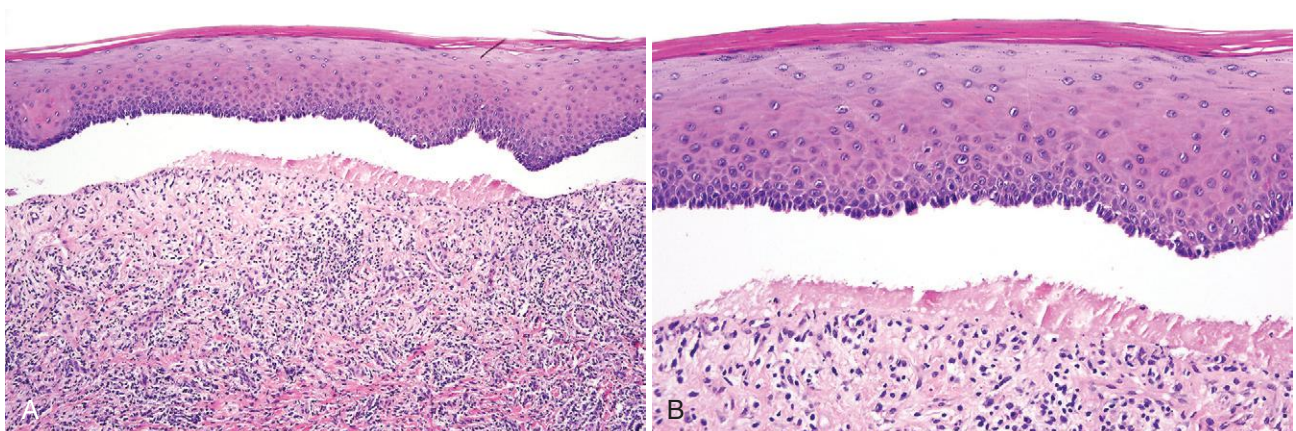




**FIGURE 8-36.** **A**, Mucous membrane pemphigoid: typical desquamative gingivitis with erythematous and eroded marginal gingiva with an ulcer. **B**, Linear IgA disease: desquamative and ulcerative gingivitis with delicate blister roof; abundant plaque on teeth because it is painful to brush teeth.

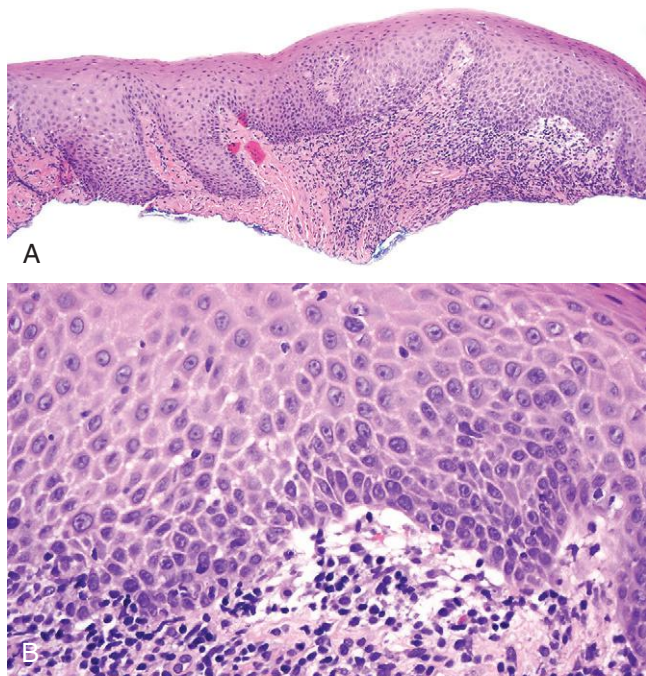


**FIGURE 8-37.** Mucous membrane pemphigoid. **A**, Epithelial hyperplasia with subepithelial cleft and mild lymphocytic infiltrate. **B**, Preservation of basal cells and little inflammation in epithelium.

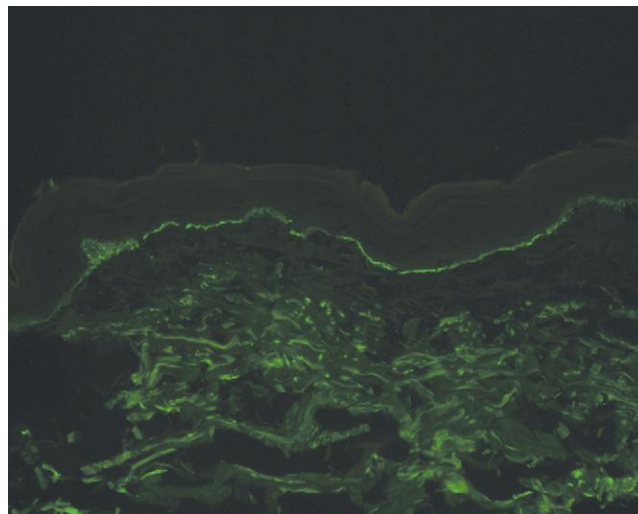


**FIGURE 8-38.** Mucous membrane pemphigoid. **A**, Epithelial atrophy and subbasal clefting with minimal inflammation. **B**, Epithelium without inflammation and intact basal cells protrude into a cleft that contains fibrin.

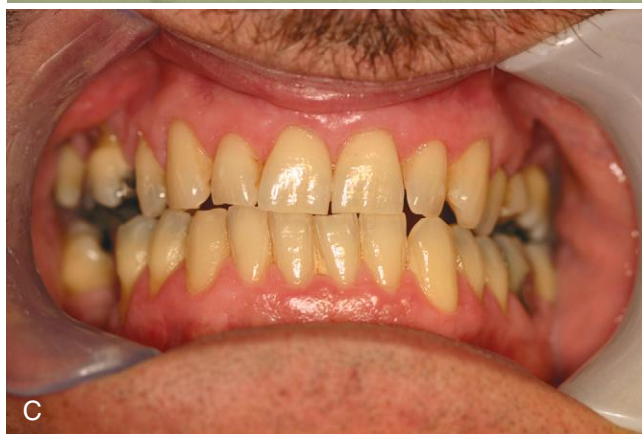
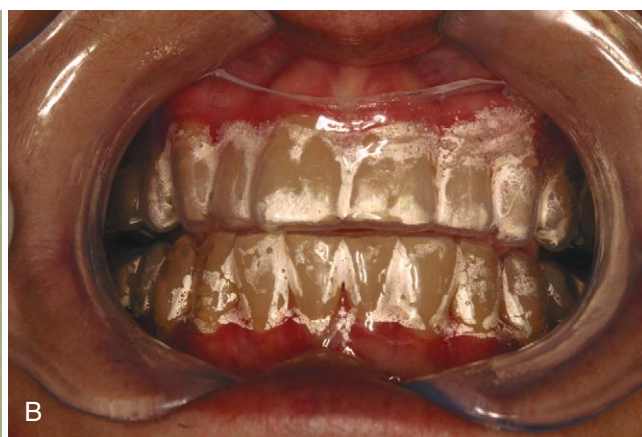
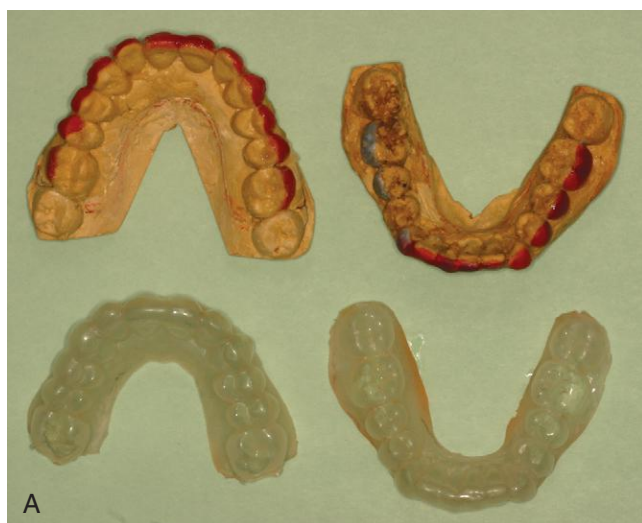

**FIGURE 8-39.** Mucous membrane pemphigoid. **A**, Subtle subepithelial cleft and chronic inflammation. **B**, Subtle subepithelial cleft; this case was strongly positive for linear IgG on direct immunofluorescence studies.



**FIGURE 8-40.** Mucous membrane pemphigoid: Direct immunofluorescence shows linear IgG deposition at the basement membrane zone.



**FIGURE 8-41.** Treatment using a stent. **A**, A custom plastic stent is fabricated from molds of the teeth and gingiva. **B**, Patient from Fig. 8-36, **A** is wearing the stent. **C**, Resolution of lesions after 4 weeks of topical steroid therapy.



## PEMPHIGUS VULGARIS

### Clinical Findings

- Condition occurs in middle-aged and older patients, often of Ashkenazi-Jewish descent; genetic susceptibility associated with HLA-DRB1 (\*0402)-DQB1 (\*0503) in whites in the United States; Asians may show association with HLA-DRB1 (\*0403 and \*0406); other putative associations may be a result of linkage disequilibrium.
- Painful ulcers and shallow erosions occur, characteristically on the hard and soft palate; a necrotic blister roof appears as a pseudomembrane; desquamative gingivitis is often present (Fig. 8-42, A-D).
- Oral findings often precede skin findings (flaccid bullae and erosions) or may be the only manifestation (see Fig. 8-42, E).
- Pemphigus may be induced by medications such as penicillamine and angiotensin-converting enzyme inhibitors.

### Etiopathogenesis and Histopathologic Features

Antibodies are directed against desmoglein-3 in oral pemphigus vulgaris, and also against desmoglein-1 if there is mucocutaneous disease. Pemphigus foliaceus (including fogo selvagem, the endemic form), and pemphigus erythematosus (features of pemphigus foliaceus and lupus erythematosus) do not usually present in the mouth. The quantity of antibody and antigen to which it is directed dictates clinical presentation.

- Suprabasilar cleft with rounded acantholytic cells appear; there is variable chronic inflammation in the lamina propria (Figs. 8-43 and 8-44).
- Direct immunofluorescence shows intercellular deposition of IgG (Fig. 8-45); intercellular staining for IgA may also be seen and up to two thirds of patients show circulating IgA antibodies against desmoglein-3; epitope spread may account for the production of antibodies against multiple antigens.
- Indirect immunofluorescence findings are seen in cases with more severe disease; antibody levels correlate with disease activity and are useful data for monitoring response to therapy.

### Differential Diagnosis

- Pyostomatitis vegetans shows acantholysis and eosinophilic abscesses that are negative on immunofluorescence; patients have inflammatory bowel disease.
- Darier disease and warty dyskeratoma show dyskeratosis and, with benign familial pemphigus (Hailey-Hailey disease), are negative on direct immunofluorescence.

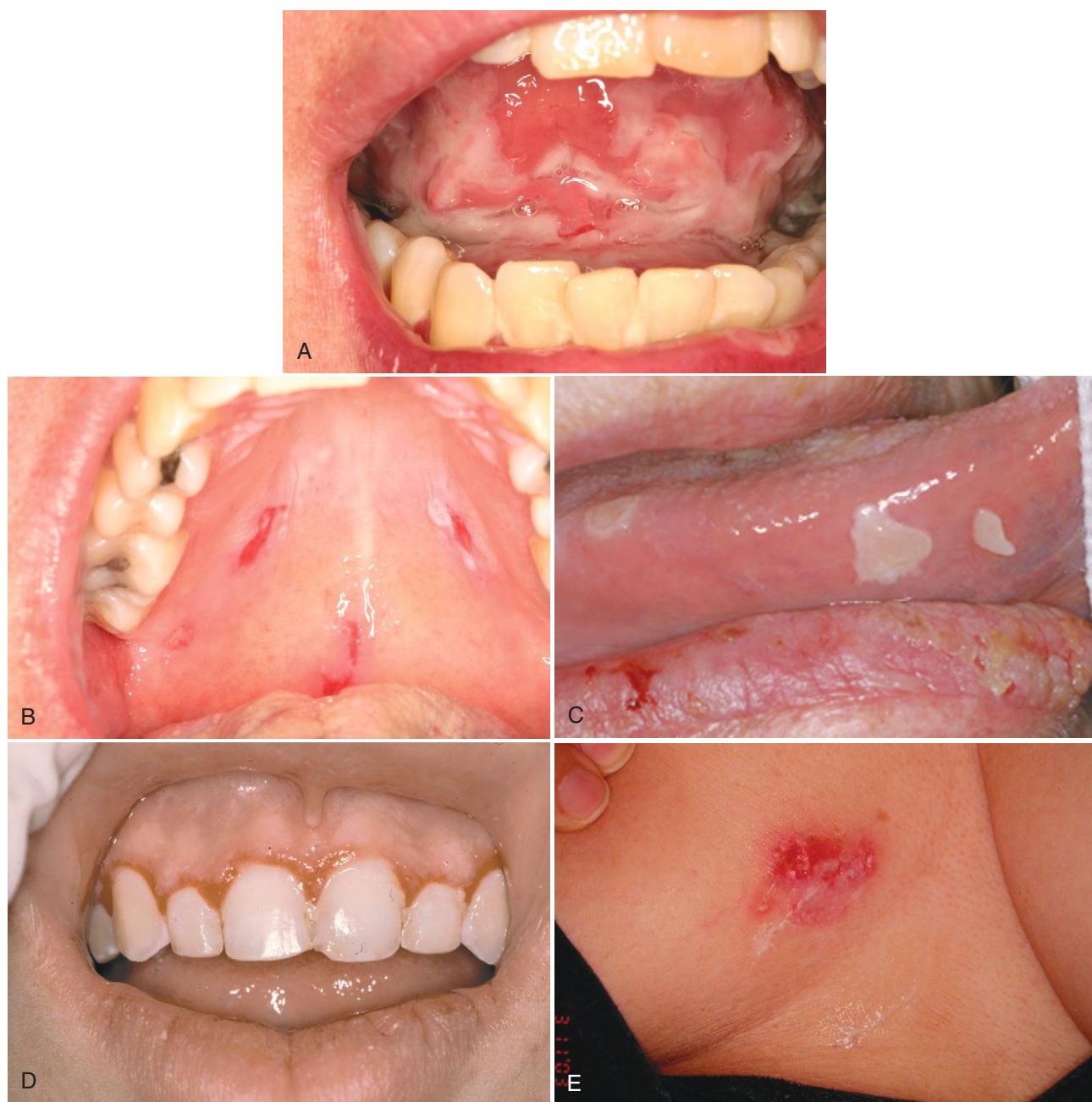- Focal acantholytic dyskeratosis is seen as an incidental finding, especially on the lip lesions.
- Pseudoacantholysis is seen as suboptimal fixation artifact; cells are not rounded but rather are angulated (Fig. 8-46).
- IgA pemphigus rarely affects the oral mucosa and exhibits deposition of IgA intercellularly, with circulating IgA directed against desmocollins and desmogleins.

### Management and Prognosis

- Circulating levels of IgG are helpful for monitoring response to therapy; however, patients with oral findings usually do not have significant levels of serum IgG.
- Oral disease may be successfully treated with topical steroids combined with initial systemic therapy to bring disease under control (see Appendix A); pain is controlled with topical or systemic analgesics.
- Mycophenolate as monotherapy, or multiagent therapy is combined with prednisone, rituximab, and intravenous immunoglobulin therapy.

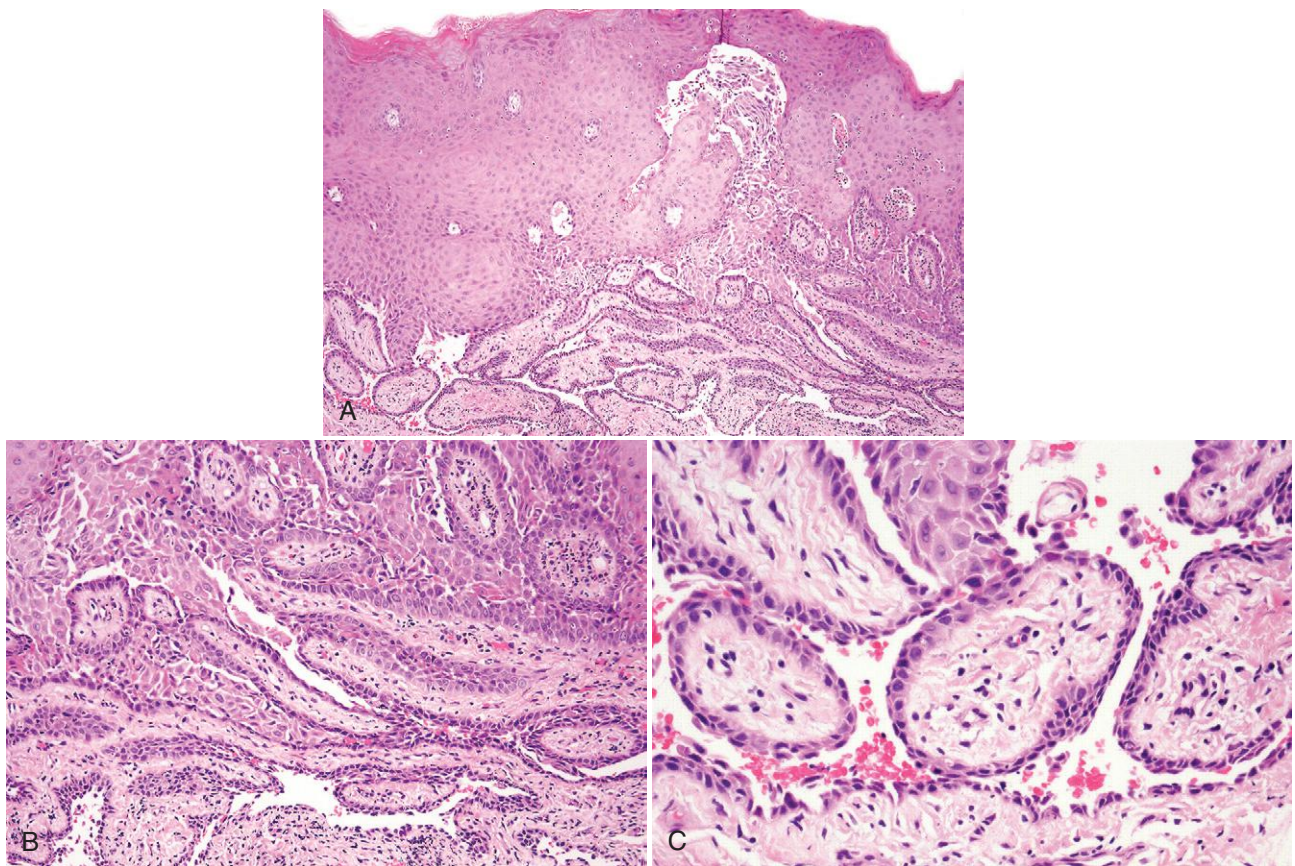
### REFERENCES

- Guedes AC, Rotta O, Leite HV, Leite VH. Ultrastructural aspects of mucosae in endemic pemphigus foliaceus. *Arch Dermatol.* 2002; 138:949-954.
- Erdag G, Qureshi HS, Greer KE, Patterson JW. Immunoglobulin A pemphigus involving the perianal skin and oral mucosa: an unusual presentation. *Cutis* 2007;80:218-220.
- Lee E, Lendas KA, Chow S, et al. Disease relevant HLA class II alleles isolated by genotypic, haplotypic, and sequence analysis in North American Caucasians with pemphigus vulgaris. *Hum Immunol.* 2006;67:125-139.
- McKee P, Calonje E, Granter S, eds. *Pathology of the Skin.* 3rd ed. Philadelphia: Saunders; 2005.
- Mentink LF, de Jong MC, Kloosterhuis GJ, et al. Coexistence of IgA antibodies to desmogleins 1 and 3 in pemphigus vulgaris, pemphigus foliaceus, and paraneoplastic pemphigus. *Br J Dermatol.* 2007;156:635-641.
- Mignogna MD, Fortuna G, Leuci S, Ruoppo E. Oropharyngeal pemphigus vulgaris and clinical remission: a long-term, longitudinal study. *Am J Clin Dermatol.* 2010;11:137-145.
- Robinson ND, Hashimoto T, Amagai M, Chan LS. The new pemphigus variants. *J Am Acad Dermatol.* 1999;40:649-671.
- Schmidt E, Zillikens D. Modern diagnosis of autoimmune blistering skin diseases. *Autoimmun Rev.* 2010;10:84-89.
- Sciubba JJ. Autoimmune oral mucosal diseases: clinical, etiologic, diagnostic, and treatment considerations. *Dent Clin North Am.* 2011;55:89-103.
- Scully C, Mignogna M. Oral mucosal disease: pemphigus. *Br J Oral Maxillofac Surg.* 2008;46:272-277.
- Strowd LC, Taylor SL, Jorizzo JL, Namazi MR. Therapeutic ladder for pemphigus vulgaris: emphasis on achieving complete remission. *J Am Acad Dermatol.* 2011;64:490-494.

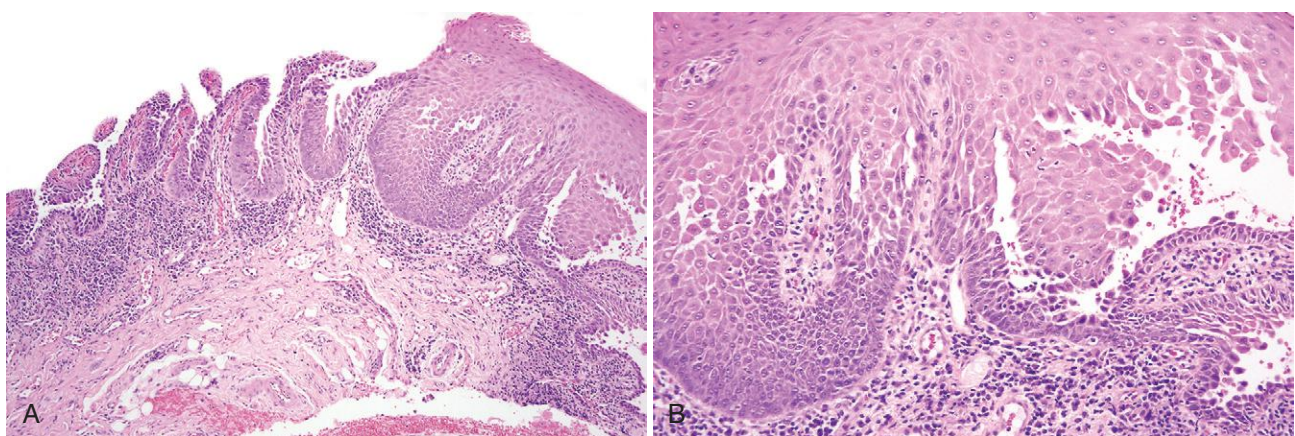


**FIGURE 8-42.** Pemphigus vulgaris. **A**, Extensive ulcers of the floor of mouth and ventral tongue. **B**, Same patient as in **A** with typical shallow erosions of the palate. **C**, Demarcated fibrin plaques or necrotic blister roof. **D**, Linear band of erosion on gingiva (desquamative gingivitis). **E**, Erosions on the skin and a small fresh bulla.



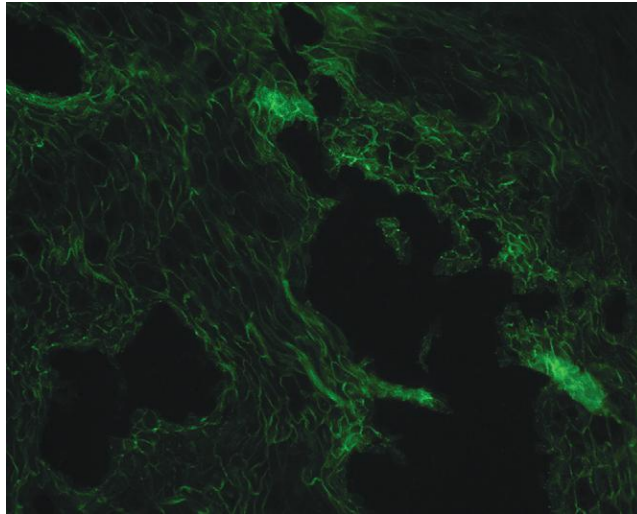


**FIGURE 8-43.** Pemphigus vulgaris. **A**, Oral mucosa exhibiting suprabasilar clefting. **B**, Suprabasilar clefting and cells showing acantholysis. **C**, Rounded acantholytic cells within the cleft; connective papillae rimmed by one to two layers of basal and suprabasal keratinocytes.

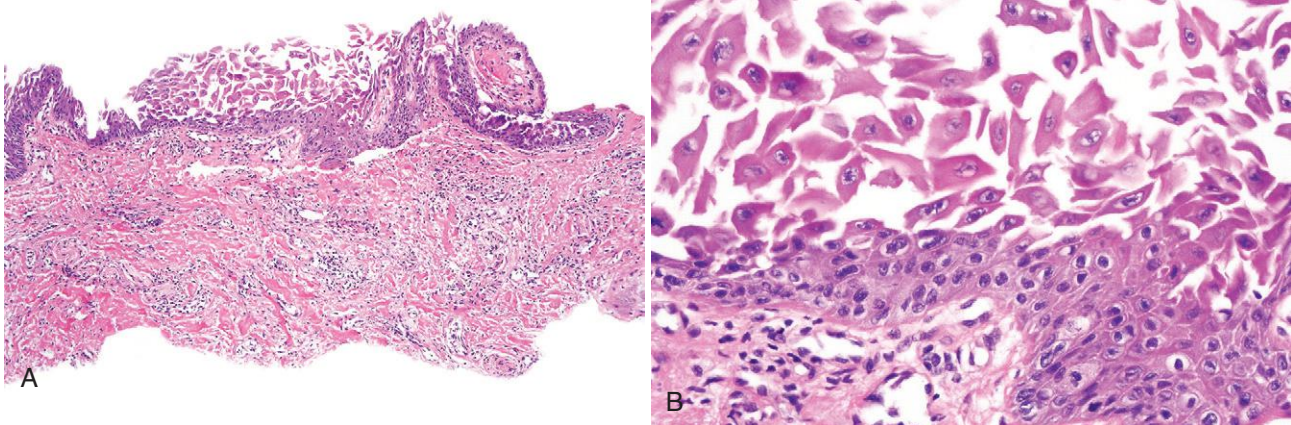


**FIGURE 8-44.** Pemphigus vulgaris. **A**, Oral mucosa with acantholysis; part of the blister has deroofed leaving villous-like projections of connective tissue covered by a few layers of epithelium (left). **B**, Suprabasilar acantholysis and plasma cell infiltrate in lamina propria.





**FIGURE 8-45.** Pemphigus vulgaris: direct immunofluorescence shows intercellular deposition of IgG.



**FIGURE 8-46.** Suboptimal fixation artifact. **A**, Mucosal lesion exhibiting pseudoacantholysis with suprabasilar clefting and villous-like connective tissue papillae. **B**, Pseudoacantholytic cells are uniformly polyhedral and dyscohesive with degenerated nuclei exhibiting clumped chromatin.

## PARANEOPLASTIC PEMPHIGUS

Paraneoplastic pemphigus is an uncommon disorder and a paraneoplastic syndrome. Some have proposed that the term *paraneoplastic autoimmune multiorgan syndrome* may be more appropriate, because lesions may resemble to a larger or smaller extent pemphigus, pemphigoid, lichen planus, or erythema multiforme with multiorgan involvement. Paraneoplastic pemphigus is associated with HLA-DRB1\*03 in whites and Cw\*14 in Chinese patients.

### Clinical Findings

- Extensive painful ulcers and erosions of the oral cavity with hemorrhagic crusts on the lips appear similar to Stevens-Johnson syndrome (Fig. 8-47).
- Skin lesions are poikilodermic, lichenoid, or blistering, and biopsies are usually taken from the skin owing to ease of access.

- Non-Hodgkin lymphoma (40%), chronic lymphocytic leukemia (30%), Castleman disease (10%), thymoma (6%), sarcoma (6%), Waldenström macroglobulinemia (6%), and other malignancies are associated with this disorder; it is not usually associated with carcinoma.

### Etiopathogenesis and Histopathologic Features

One hypothesis for this disease is that dysregulated cytokine production by tumor cells drives the development of autoimmunity with antibodies produced by the host. Damage is mediated by autoantibodies and T cell-mediated cytotoxicity. Autoantibodies are directed against desmoglein-1 and -3, envoplakin, periplakin, and desmoplakin for the most part. Other antigens include BP 230 (BP Ag1), plectin, and plakoglobin.

- Suprabasilar clefting occurs with acantholysis, and interface stomatitis with lichenoid lymphocytic band and subepithelial clefting are evident.



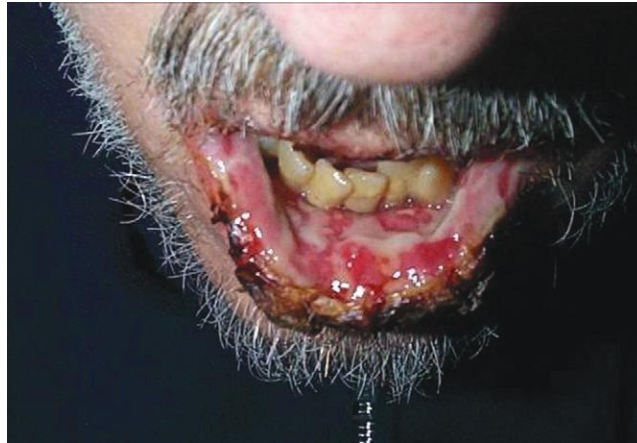- Direct immunofluorescence shows intercellular, linear, and granular subepithelial deposits of IgG and C3 and sometimes IgM; positive indirect immunofluorescence studies using rat bladder epithelium are diagnostic.
- Western blotting and immunoprecipitation identify the specific antibodies.

### Management and Prognosis

- A search for and identification of underlying malignancy is of utmost importance, although treatment of the malignancy may not always halt progression of mucocutaneous disorder.
- Systemic therapy consists of high-dose prednisone, cyclophosphamide, rituximab, cyclosporine, and intravenous immunoglobulin, although oral disease may be refractory; involvement of the lung leads to significant morbidity, and respiratory failure is often a terminal event.

### REFERENCES

- Allen CM, Camisa C. Paraneoplastic pemphigus: a review of the literature. *Oral Dis.* 2000;6:208-214.
- Anhalt GJ. Paraneoplastic pemphigus. *J Invest Dermatol Symp Proc.* 2004;9:29-33.
- Kaplan I, Hodak E, Ackerman L, et al. Neoplasms associated with paraneoplastic pemphigus: a review with emphasis on non-hematologic malignancy and oral mucosal manifestations. *Oral Oncol.* 2004;40:553-562.
- McKee P, Calonje E, Granter S, eds. *Pathology of the Skin.* 3rd ed. Philadelphia: Saunders; 2005.
- Nguyen VT, Ndoye A, Bassler KD, et al. Classification, clinical manifestations, and immunopathological mechanisms of the epithelial variant of paraneoplastic autoimmune multiorgan syndrome: a reappraisal of paraneoplastic pemphigus. *Arch Dermatol.* 2001;137:193-206.
- Schmidt E, Zillikens D. Modern diagnosis of autoimmune blistering skin diseases. *Autoimmun Rev.* 2010;10:84-89.
- Yan Z, Hua H, Gao Y. Paraneoplastic pemphigus characterized by polymorphic oral mucosal manifestations—report of two cases. *Quintessence Int.* 2010;41:689-694.
- Zimmermann J, Bahmer F, Rose C, et al. Clinical and immunopathological spectrum of paraneoplastic pemphigus. *J Dtsch Dermatol Ges.* 2010;8:598-606.



**FIGURE 8-47.** Paraneoplastic pemphigus: extensive ulcerations and crusting of the lips. (Courtesy of Dr. Arturo Saavedra, Harvard Medical School, Boston, Mass.)

## LUPUS ERYTHEMATOSUS

Discoid and systemic lupus erythematosus are commonly associated with oral lesions.

### Clinical Findings

- Disease affects predominantly females; oral lesions rarely occur in the absence of skin lesions, which vary depending on the subtype—the three most common being systemic, subacute, and discoid; photodistributed “butterfly rash” on the malar region is typical for systemic lupus erythematosus; scaly and atrophic plaques with follicular plugging and postinflammatory hyperpigmentation is common in discoid lupus erythematosus (Fig. 8-48, A and B).
- Oral disease presents as aphthous-like ulcers or reticulated and erythematous (lichenoid) lesions on the buccal mucosa or as erythematous macules and

keratotic plaques on the palatal or labial mucosa; up to 20% and 45% of patients with discoid and systemic lupus erythematosus, respectively, have oral lesions (see Fig. 8-48, C and D).

- Keratoconjunctivitis sicca may develop if there is concomitant secondary Sjögren syndrome.

### Etiopathogenesis and Histopathologic Features

Lupus erythematosus is an autoimmune disease that may show multiorgan involvement. Antibodies are directed against double-stranded DNA (dsDNA).

- Both epithelial hyperplasia and atrophy with vacuolar degeneration of basal cells, bandlike lymphocytic infiltrate at the interface, and deep perivascular and paravascular lymphocytic infiltrates occur; thickening of epithelial and vascular basement membranes appears.

- Direct immunofluorescence studies show a positive lupus band test or linear/granular deposition of IgG, IgM, or IgA at the basement membrane; a positive lupus band test for clinically normal skin is strongly predictive of systemic lupus erythematosus.
- Antinuclear antibody, anti-dsDNA, antiribonucleoproteins and anti-Ro antibodies are usually present.

#### Differential Diagnosis

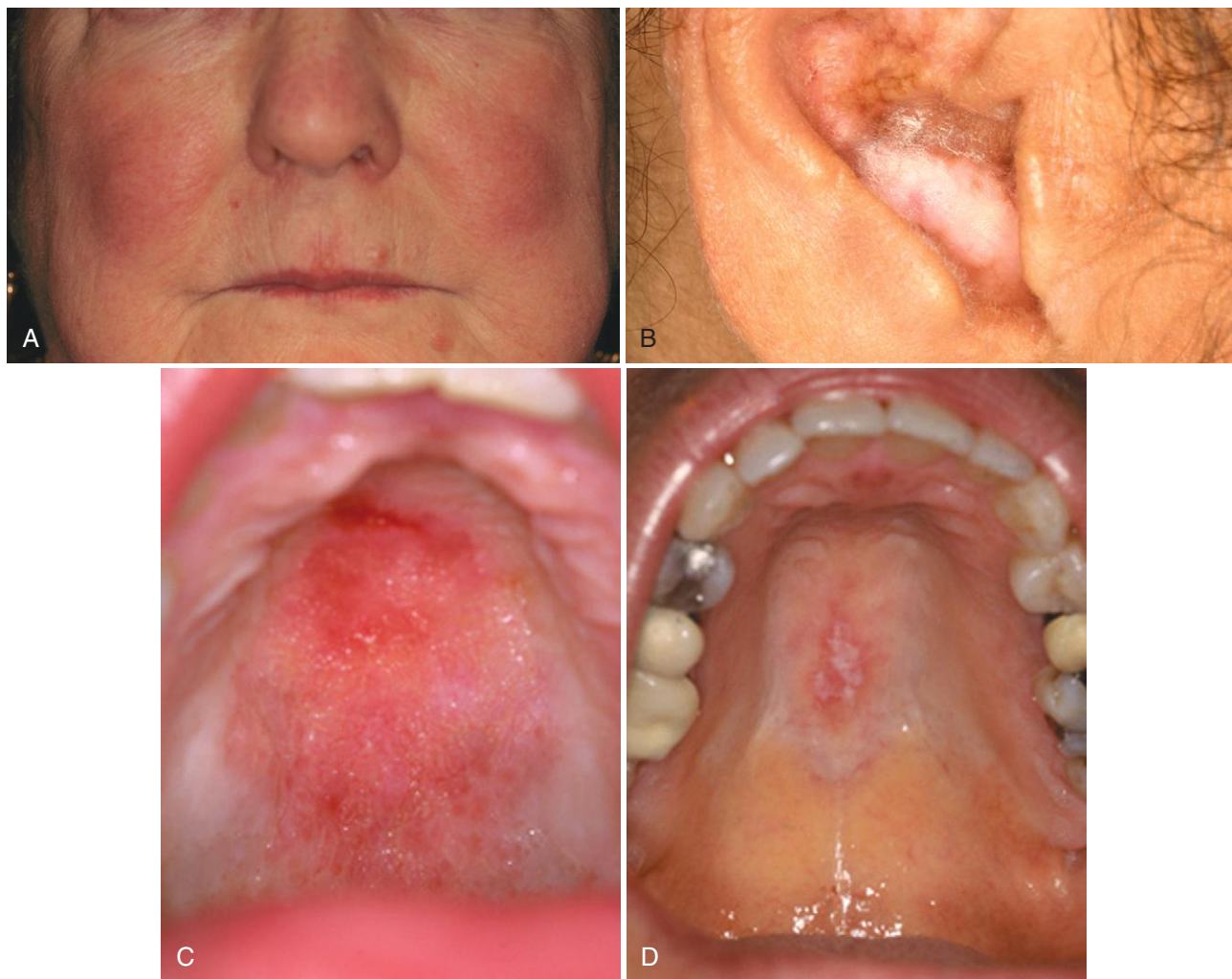- Cinnamic aldehyde contact stomatitis exhibits a lymphocytic band at the interface and deep perivascular and paravascular infiltrates, but not usually hydropic degeneration of basal cells, and it has negative lupus band test.
- Lichen planus does not show positive immunofluorescence for linear IgG.

#### Management and Prognosis

- Topical and/or systemic therapy for mucosal lesions depending on the severity (see [Appendix A](#)).

#### REFERENCES

- Karjalainen TK, Tomich CE. A histopathologic study of oral mucosal lupus erythematosus. *Oral Surg Oral Med Oral Pathol.* 1989;67:547-554.
- Lopez-Labady J, Villarreal-Dorrego M, Gonzalez N, et al. Oral manifestations of systemic and cutaneous lupus erythematosus in a Venezuelan population. *J Oral Pathol Med.* 2007;36:524-527.
- Lourenco SV, Nacagami Sotto M, Constantino Vilela MA, et al. Lupus erythematosus: clinical and histopathological study of oral manifestations and immunohistochemical profile of epithelial maturation. *J Cutan Pathol.* 2006;33:657-662.
- Lourenco SV, de Carvalho FR, Boggio P, et al. Lupus erythematosus: clinical and histopathological study of oral manifestations and immunohistochemical profile of the inflammatory infiltrate. *J Cutan Pathol.* 2007;34:558-564.
- Marques ER, Lourenco SV, Lima DM, Nico MM. Oral lesions in lupus erythematosus—cytokines profiles of inflammatory infiltrate. *J Cutan Pathol.* 2010;37:439-445.
- Nico MM, Vilela MA, Rivitti EA, Lourenco SV. Oral lesions in lupus erythematosus: correlation with cutaneous lesions. *Eur J Dermatol.* 2008;18:376-381.



**FIGURE 8-48.** **A**, Systemic lupus erythematosus: typical malar (“butterfly”) rash. **B**, Discoid lupus erythematosus: skin atrophy and hyperpigmentation of ear. **C**, Oral lupus erythematosus: poorly demarcated erythema of the mucosa of hard palate, symmetric in distribution. **D**, White plaque with surrounding erythema of the hard palate, symmetric in distribution.



## WEGENER GRANULOMATOSIS

Wegener granulomatosis falls under the larger category of antineutrophil cytoplasmic autoantibody (ANCA)-associated vasculitides that also include microscopic polyangiitis, Churg-Strauss syndrome, and renal-limited vasculitis. Wegener granulomatosis is associated with HLA-DPB1.

### Clinical Findings

- Affects adults; oral findings are the first presentation in approximately 6% to 13% of patients; limited form of the disease affects only the upper airways and oral cavity.
- Painful, necrotic ulcers of the oral mucosa, in particular the hard palate, manifest as “midline destructive disease” (Fig. 8-49, A); gingiva is hyperplastic with a friable, pebbly, and erythematous appearance and pinpoint hemorrhage characteristic for vasculitides (“strawberry gingivitis”) (see Fig. 8-49, B).
- Nasal carriage of *Staphylococcus aureus* is associated with increased risk for relapse.

### Etiopathogenesis and Histopathologic Findings

Wegener granulomatosis is a small- and medium-vessel necrotizing vasculitis that in its full expression affects the upper respiratory tract and oral mucosa, lungs, and kidneys (necrotizing glomerulonephritis).

- Edema of lamina propria with mixed acute and chronic inflammatory infiltrate with variable geographic necrosis; necrotizing granulomas are noted although vasculitis may be difficult to identify (Fig. 8-50)

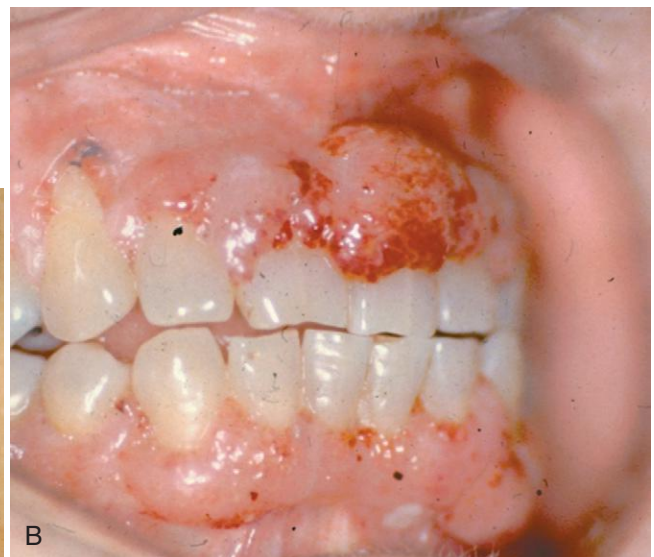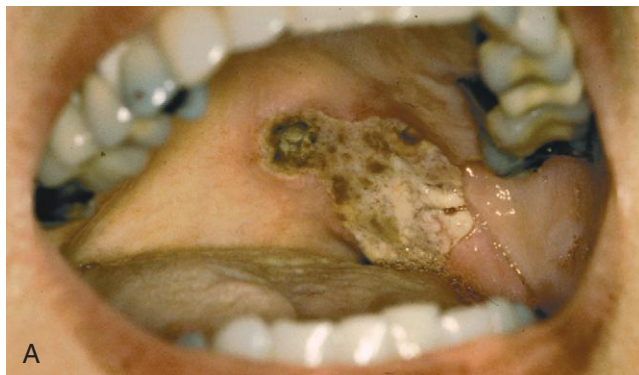- Indirect immunofluorescence testing reveals the presence of ANCA in a cytoplasmic (cANCA) or perinuclear (pANCA) pattern with enzyme-linked immunosorbent assay (ELISA) positivity for antibodies against proteinase-3 and myeloperoxidase, respectively.

### Management and Prognosis

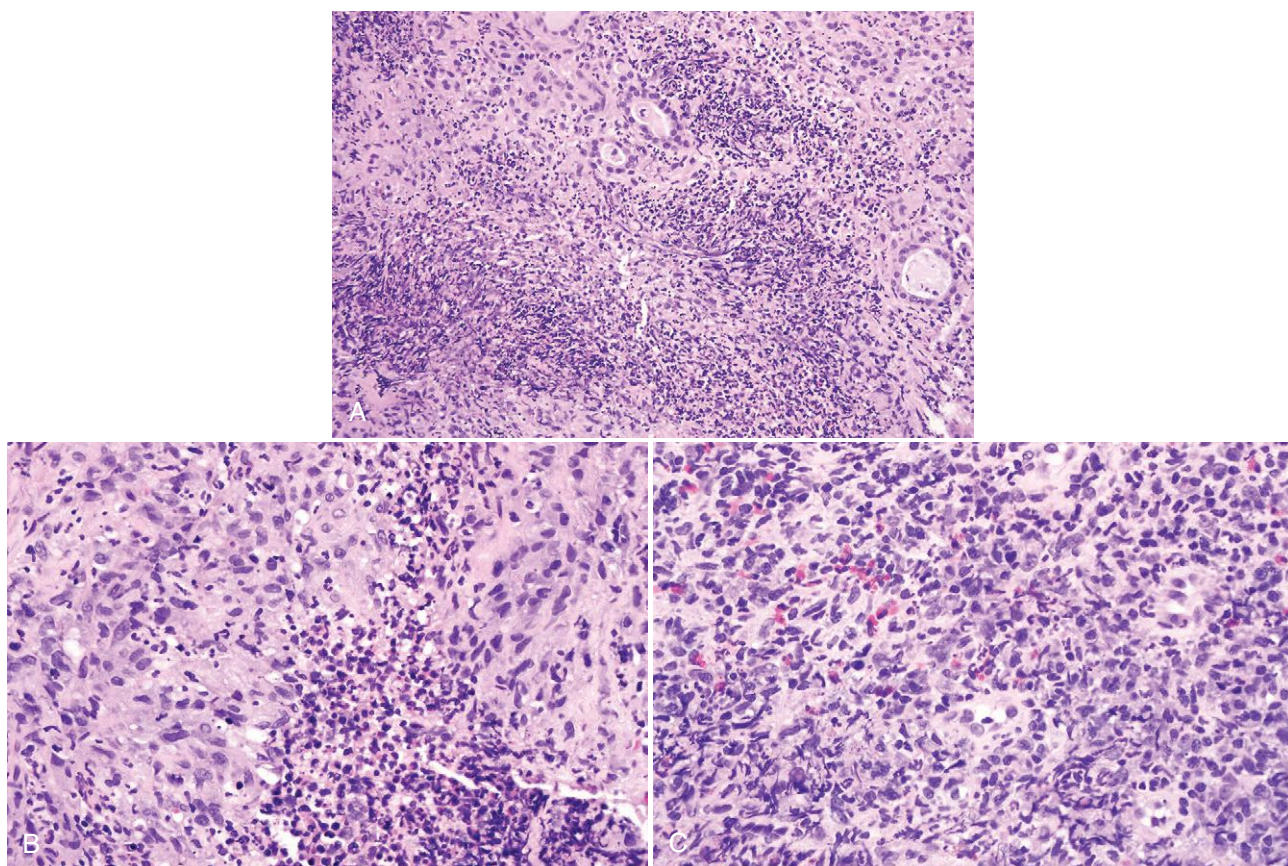
- High-dose prednisone and cyclophosphamide for several months is a mainstay of therapy; methotrexate, azathioprine, and mycophenolate mofetil mitigates toxicity of prolonged cyclophosphamide use; rituximab is useful for refractory cases.
- Surgical reconstruction may be necessary if there has been extensive tissue destruction.

### REFERENCES

- Chen M, Kallenberg CG. ANCA-associated vasculitides—advances in pathogenesis and treatment. *Nat Rev Rheumatol*. 2010;6:653-664.
- Chen M, Kallenberg CG. The environment, geoeidemiology and ANCA-associated vasculitides. *Autoimmun Rev*. 2010;9:A293-A298.
- Hattar K, Bickenbach A, Csernok E, et al. Wegener's granulomatosis: antiproteinase 3 antibodies induce monocyte cytokine and prostanoind release—role of autocrine cell activation. *J Leukoc Biol*. 2002;71:996-1004.
- Ponniah I, Shaheen A, Shankar KA, Kumaran MG. Wegener's granulomatosis: the current understanding. *Oral Surg Oral Med Oral Pathol Oral Radiol Endod*. 2005;100:265-270.
- Rodrigo JP, Suarez C, Rinaldo A, et al. Idiopathic midline destructive disease: fact or fiction. *Oral Oncol*. 2005;41:340-348.
- Stewart C, Cohen D, Bhattacharyya I, et al. Oral manifestations of Wegener's granulomatosis: a report of three cases and a literature review. *J Am Dent Assoc*. 2007;138:338-348; quiz 96, 98.
- Stone JH, Merkel PA, Spiera R, et al. Rituximab versus cyclophosphamide for ANCA-associated vasculitis. *N Engl J Med*. 2010;363:221-232.



**FIGURE 8-49.** Wegener granulomatosis. **A**, Necrotic ulcer on palate. **B**, Hyperplastic gingiva with hemorrhage (“strawberry gingivitis”). Courtesy of Dr. Richard K. Wesley, St. John Providence Medical Center, Grosse Pointe, Mich.)



**FIGURE 8-50.** Wegener granulomatosis. **A**, Mixed inflammatory infiltrate with "geographic" necrosis. **B**, Granulomatous inflammation adjacent to necrosis. **C**, Acute and chronic inflammation with many eosinophils and nuclear debris.



# 9

## PIGMENTED LESIONS

### CHAPTER CONTENTS

EXOGENOUS PIGMENTATION 185

Amalgam Tattoo 185

Graphite Tattoo 188

Medication-Induced Pigmentation 189

MELANOCYTIC PIGMENTATION 191

Oral Melanotic Macule 191

Postinflammatory Hypermelanosis 193

Melanoacanthosis (Melanoacanthoma) 196

Oral Melanocytic Nevus 198

Dysplastic Melanocytic Nevus and Mucosal Melanoma 203

NEUROECTODERMAL PIGMENTATION 207

Melanotic Neuroectodermal Tumor of Infancy 207

## Exogenous Pigmentation

### AMALGAM TATTOO

#### Clinical Features

- Amalgam tattoo is localized (usually < 1 cm) or, less commonly, diffuse; it is a slate-gray macule of oral mucosa and is nontender and evenly pigmented.
- Tattoo often appears on gingiva adjacent to amalgam restorations or crowns, but it may be on any surface and, in particular, after apicoectomy (root apex surgery) with amalgam retrofill (Fig. 9-1, A-C).

#### Etiopathogenesis and Histopathologic Features

Silver within amalgam (combination of silver, mercury, tin, and other metals) stains argyrophilic reticulin fibers of connective tissue. It either leaches out of contacting amalgams or root canal fillings, or is traumatically implanted.

- Scar is often present (especially if lesion is not adjacent to an amalgam) with variable lymphocytic infiltrate (Fig. 9-2, A).
- Fine golden-brown particles are deposited in a “beaded” pattern along connective tissue fibers and basement membrane of epithelium and blood vessels.
- Reticulin fibers, endomysium, and endoneurium may be stained golden-brown with no particulate

deposits; larger particles often are found within foreign body granulomas (see Fig. 9-2, B-E; Figs. 9-3 and 9-4).

- Refractile crystalline foreign material may be seen occasionally in traumatically implanted lesions; this likely represents fragments of dental cement placed with amalgams.

#### Differential Diagnosis

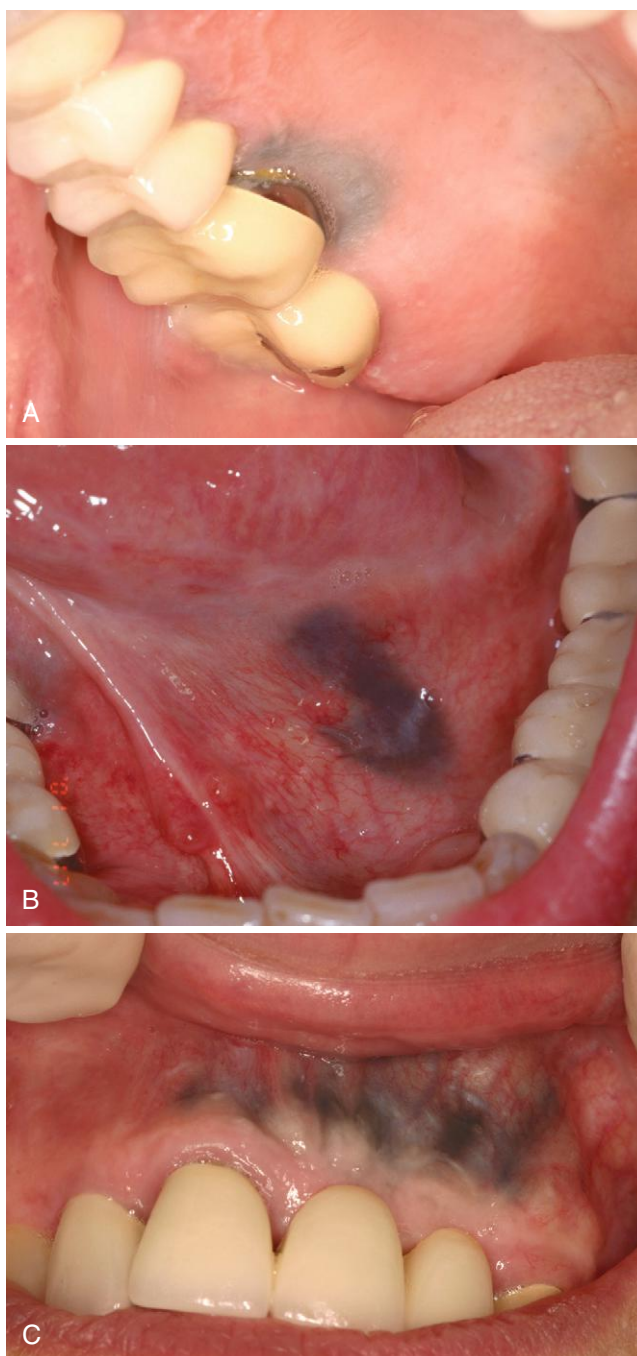- Medication-induced pigmentation exhibits fine particles that align in linear fashion between collagen fibers, but they do not stain the fibers; usually they are Fontana-Masson and/or iron positive (see later).

#### Management and Prognosis

- Surgical or laser removal is curative and is performed for cosmetic reasons.

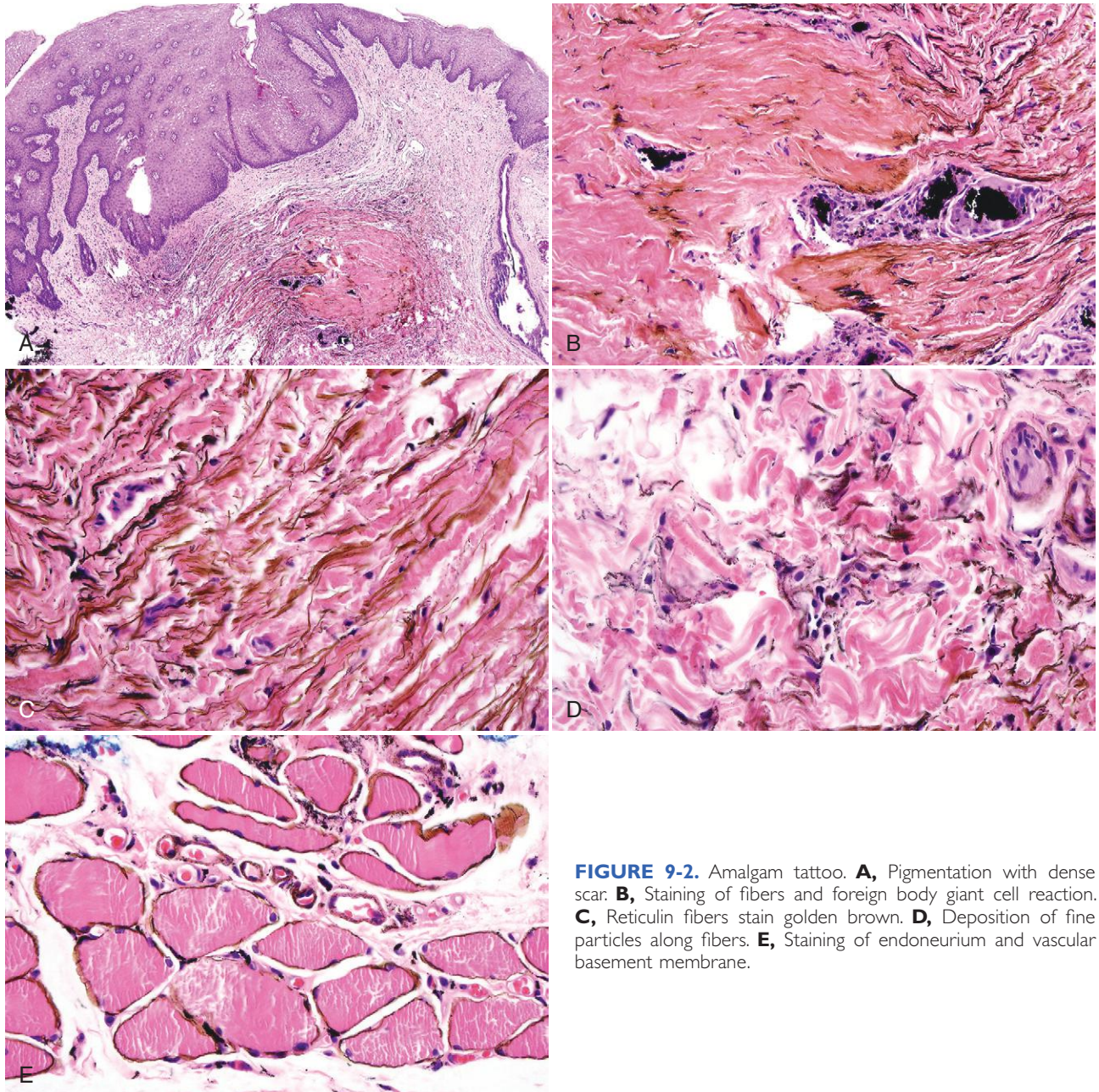
#### REFERENCES

- Buchner A. Amalgam tattoo (amalgam pigmentation) of the oral mucosa: clinical manifestations, diagnosis and treatment. *Refuat Hapeh Vehashinayim*. 2004;21:25-28, 92.
- Buchner A, Hansen LS. Amalgam pigmentation (amalgam tattoo) of the oral mucosa. A clinicopathologic study of 268 cases. *Oral Surg Oral Med Oral Pathol*. 1980;49:139-147.
- Kanzaki T, Eto H, Miyazawa S. Electron microscopic x-ray microanalysis of metals deposited in oral mucosa. *J Dermatol*. 1992;19:487-492.
- Lau JC, Jackson-Boeters L, Daley TD, et al. Metallothionein in human gingival amalgam tattoos. *Arch Oral Biol*. 2001;46:1015-1020.

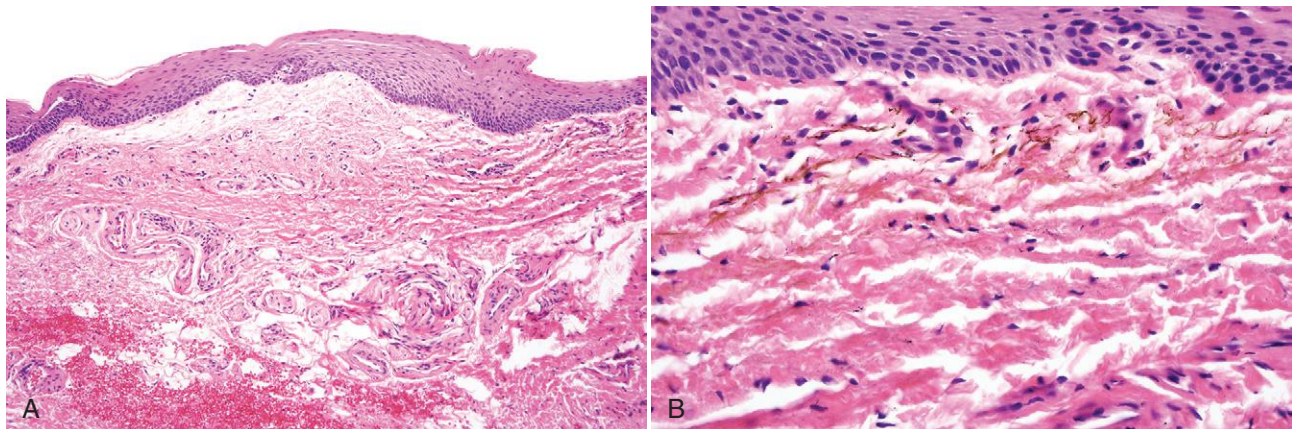


**FIGURE 9-1.** **A**, Amalgam tattoo adjacent to a crown. **B**, Amalgam tattoo on the floor of mouth. **C**, Amalgam tattoo related to apicoectomy (apical surgery) scar.



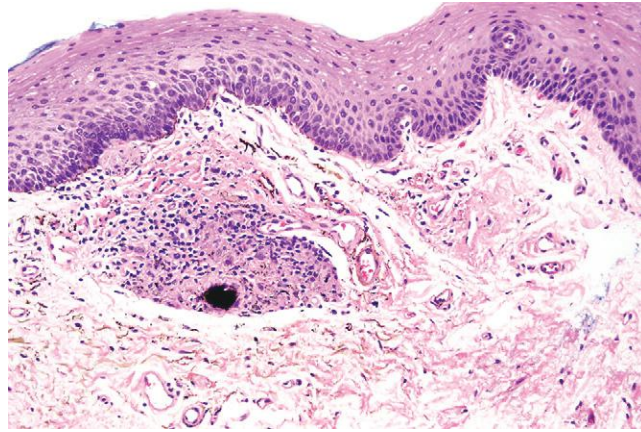


**FIGURE 9-2.** Amalgam tattoo. **A**, Pigmentation with dense scar. **B**, Staining of fibers and foreign body giant cell reaction. **C**, Reticulin fibers stain golden brown. **D**, Deposition of fine particles along fibers. **E**, Staining of endoneurium and vascular basement membrane.



**FIGURE 9-3.** Subtle amalgam tattoo. **A**, Focal scarring noted (*right*). **B**, Staining of reticulin fibers.





**FIGURE 9-4.** Amalgam tattoo: foreign body granuloma and staining of basement membrane of epithelium.

## GRAPHITE TATTOO

### Clinical Findings

- Localized gray-to-black, nontender macule on any mucosal site but often on palate (e.g., child who falls when running with a pencil held between the teeth, puncturing the palate)

### Etiopathogenesis and Histopathologic Features

This is caused by traumatic implantation of pencil graphite.

- Coarse black granules of nonrefractile, slightly geometric, foreign material, some of which lie within multinucleated giant cells of foreign body granulomas; no distinguishing features so history important in diagnosis (Fig. 9-5)

### Differential Diagnosis

- Unlike amalgam, it is slightly birefringent, maintains birefringence after treatment with 10% ammonium sulfide, and does not stain connective tissue fibers.

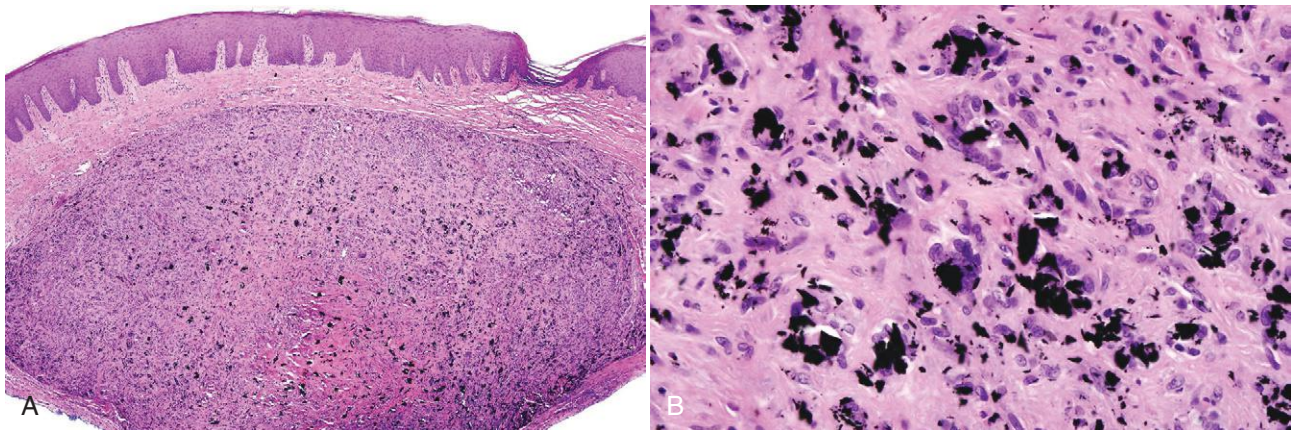
- Other traumatically-implanted foreign bodies should be considered, and the diagnosis should be elicited by a careful history taking (Fig. 9-6).

### Management and Prognosis

- Excision or no treatment

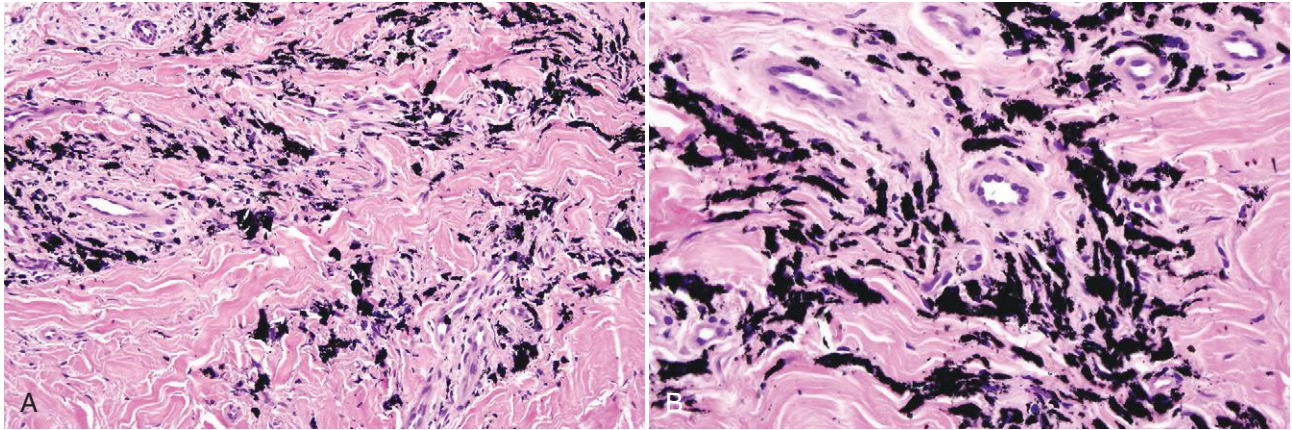
### REFERENCES

- Daley TD, Gibson D. Practical applications of energy dispersive x-ray microanalysis in diagnostic oral pathology. *Oral Surg Oral Med Oral Pathol.* 1990;69:339-344.
- Peters E, Gardner DG. A method of distinguishing between amalgam and graphite in tissue. *Oral Surg Oral Med Oral Pathol.* 1986;62:73-76.
- Phillips GE, John V. Use of a subepithelial connective tissue graft to treat an area pigmented with graphite. *J Periodontol.* 2005;76:1572-1575.



**FIGURE 9-5.** Graphite tattoo. **A**, Granulomatous reaction and fibrosis. **B**, Irregular, geometric, large and small, black particles with histiocytic reaction.





**FIGURE 9-6.** Graphite tattoo. **A**, Black particulate foreign material with fibrosis. **B**, Large and small black particles without staining of collagen.

## MEDICATION-INDUCED PIGMENTATION

### Clinical Findings

- Diffuse, painless, symmetric, bluish-gray macular pigmentation of the hard palate; patient may have concomitant skin lesions (Fig. 9-7).
- Patient on minocycline, antimalarial medications (such as mepacrine or quinacrine), birth control pills, clofazimine, and imatinib are susceptible.
- Tetracycline and its analogues are taken up by teeth and bone, which appear brown, and this is visible through the oral mucosa.

### Etiopathogenesis and Histopathologic Features

Condition is caused by break-down products of the medication that chelate with iron or melanin.

- Particles are brown, spherical, uniform, only a few microns in diameter, and they tend to align in linear fashion between collagen fibers, although this may represent pigment within dendritic processes of macrophages; particles are often present within macrophages (Fig. 9-8, A-D).
- Staining is positive with Prussian blue for iron and Fontana-Masson for melanin, although degree of staining is variable (see Fig. 9-8, E); usually elicits no fibrosis or inflammation.
- Teeth are stained by tetracycline fluoresce under polarized light.

### Differential Diagnosis

- Amalgam is not spherical, and it stains the collagen fibers.

- Hemosiderin particles are larger, coarser, and more variable in size and stain with Prussian blue stain (Fig 9-9).
- Melanin is not as uniform, and it is often present concomitantly within basal cells.
- Rare instances of pigmentation caused by leaching of metals from a denture have been reported.

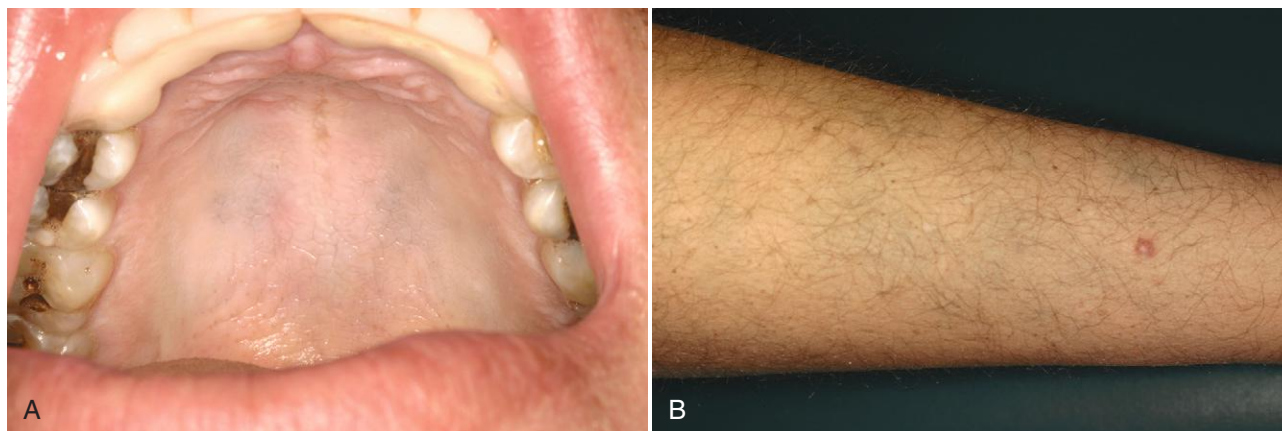
### Management and Prognosis

- No treatment is necessary unless there is cosmetic concern, in which case laser ablation may be helpful.

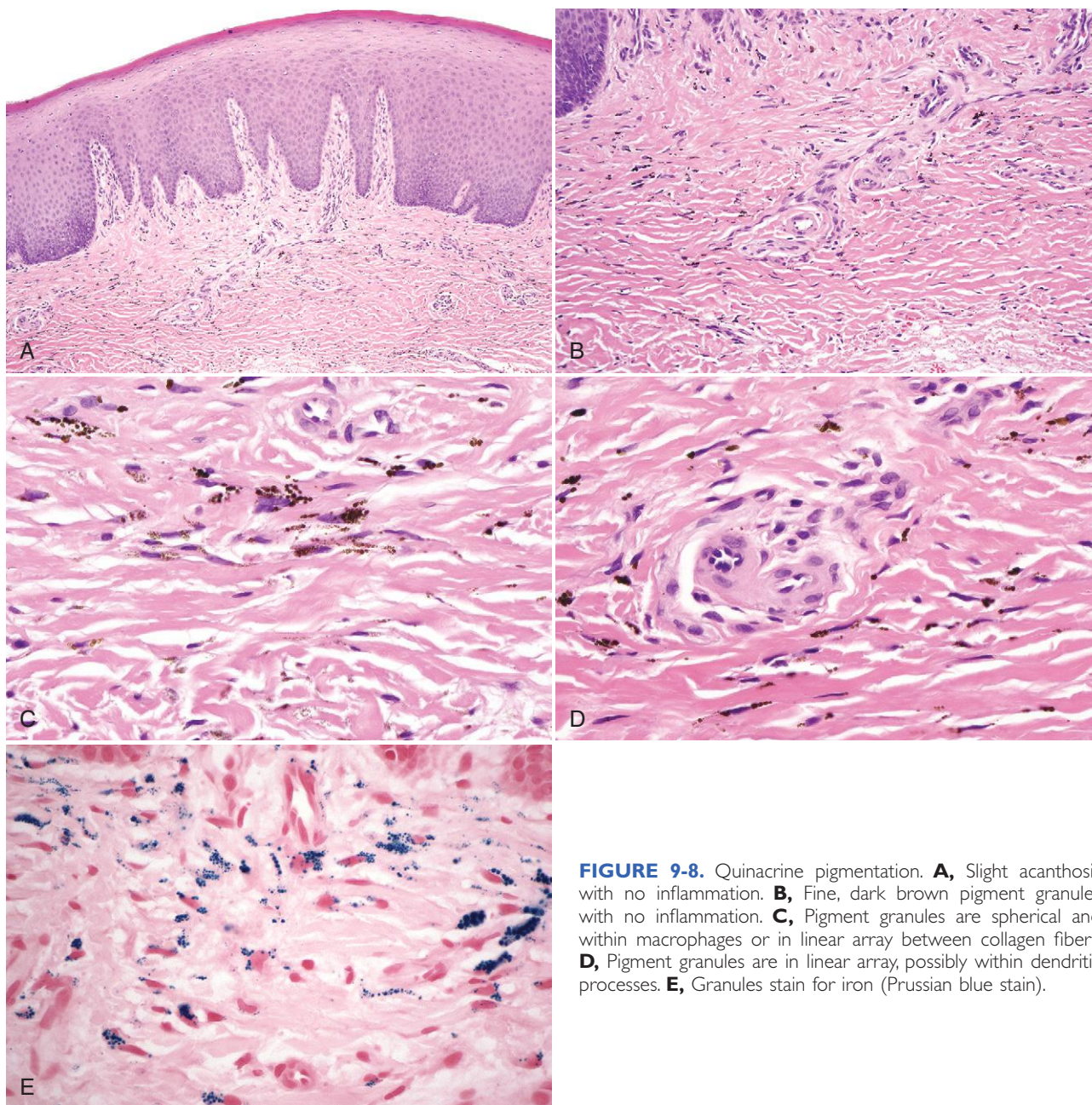
### REFERENCES

- Cale AE, Freedman PD, Lumerman H. Pigmentation of the jawbones and teeth secondary to minocycline hydrochloride therapy. *J Periodontol.* 1988;59:112-114.
- Kleinegger CL, Hammond HL, Finkelstein MW. Oral mucosal hyperpigmentation secondary to antimalarial drug therapy. *Oral Surg Oral Med Oral Pathol Oral Radiol Endod.* 2000;90:189-194.
- Lerman MA, Karimbux N, Guze KA, Woo SB. Pigmentation of the hard palate. *Oral Surg Oral Med Oral Pathol Oral Radiol Endod.* 2009;107:8-12.
- Mattsson U, Halbritter S, Morner Serikoff E, et al. Oral pigmentation in the hard palate associated with imatinib mesylate therapy: a report of three cases. *Oral Surg Oral Med Oral Pathol Oral Radiol Endod.* 2011;111:e12-16.
- Sloan P, Kujan O. Re: Martin TJM, Sharp I. Oral mucosal pigmentation secondary to treatment with mepacrine, with sparing of the denture bearing area. *Br J Oral Maxillofac Surg.* 2004;42:351-353. *Br J Oral Maxillofac Surg.* 2005;43:268.
- Treister NS, Magalnick D, Woo SB. Oral mucosal pigmentation secondary to minocycline therapy: report of two cases and a review of the literature. *Oral Surg Oral Med Oral Pathol Oral Radiol Endod.* 2004;97:718-725.



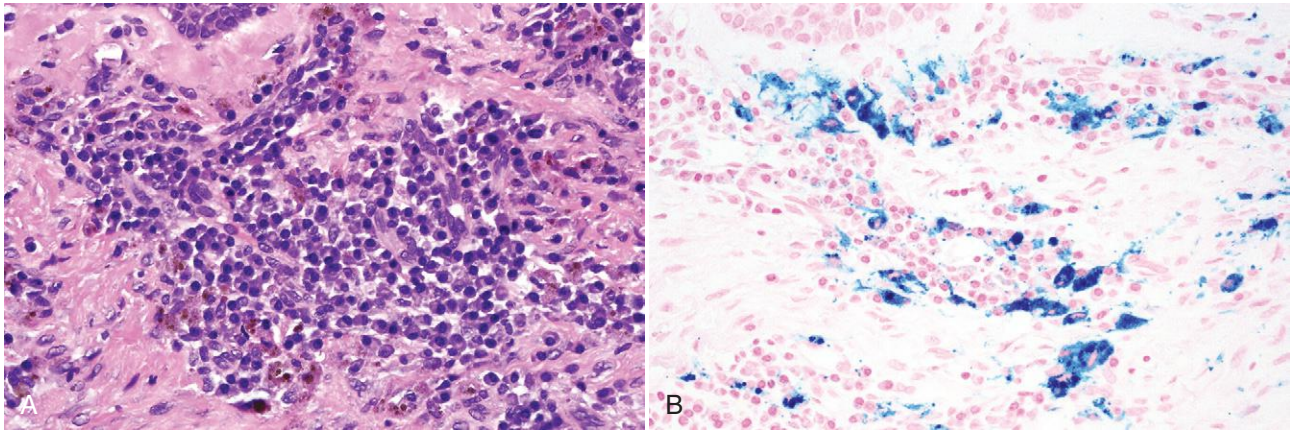


**FIGURE 9-7.** **A**, Minocycline pigmentation of the palate. **B**, Same patient as in **A**, with minocycline pigmentation of skin on shin.



**FIGURE 9-8.** Quinacrine pigmentation. **A**, Slight acanthosis with no inflammation. **B**, Fine, dark brown pigment granules with no inflammation. **C**, Pigment granules are spherical and within macrophages or in linear array between collagen fibers. **D**, Pigment granules are in linear array, possibly within dendritic processes. **E**, Granules stain for iron (Prussian blue stain).





**FIGURE 9-9.** Hemosiderin deposits. **A**, Coarse, irregular brown granules associated with many plasma cells. **B**, Granules stain blue for iron (Prussian blue stain).

## Melanocytic Pigmentation

Physiologic pigmentation is very common on the gingiva and other mucosa of dark-skinned individuals and is generally bilaterally symmetric and evenly pigmented (Fig. 9-10, A).

The two most common melanocytic lesions in the oral cavity are oral melanotic macule (comprising more than 80% of melanotic lesions) and postinflammatory hypermelanosis. Some melanotic macules are likely to represent end-stage postinflammatory hyperpigmentation. The less common melanoacanthosis also represents postinflammatory pigmentation.

### ORAL MELANOTIC MACULE

#### Clinical Findings

- Macules are seen in adults, usually in the fifth decade, but rarely, they may occur congenitally on the tongue.
- Discrete, brown-to-tan-to-black, painless macules are usually evenly pigmented, less than 1 cm, usually on the lower vermilion, palate, or gingiva (see Fig. 9-10, B and C).
- The macule is most often solitary but may be multifocal, especially in the Laugier-Hunziker syndrome (with melanonychia) (see Fig. 9-10, D)
- Unlike ephelides, they do not darken with exposure to sunlight.

#### Etiopathogenesis and Histopathologic Features

Some melanotic macules may represent postinflammatory hypermelanosis, but others are idiopathic.

- Increased melanin occurs within basal cells in the absence of or with minimal melanocytic hyperplasia; with incontinent melanin and melanophages in lamina propria; melanin is most prominent in the lower half of the epithelium and at tips of rete ridges (Figs. 9-11 and 9-12).
- Variable vascular ectasia and absent-to-mild lymphocytic infiltrate may be evident.

- Overlying epithelium usually shows mild acanthosis.

#### Differential Diagnosis

- Postinflammatory hypermelanosis appears similar with obvious inflammation present; melanotic macule may represent end stage of postinflammatory changes.
- Melanoacanthosis shows acanthosis with dendritic melanocytes present throughout the thickness of the epithelium.
- Rule out Addison disease if onset of multiple melanotic macules is sudden.
- Melanotic macules are present in lentiginos syndromes, such as neurofibromatosis, Peutz-Jeghers syndrome, McCune-Albright syndrome, Carney syndrome complex, and Bannayan-Ruvalcaba-Riley syndrome.

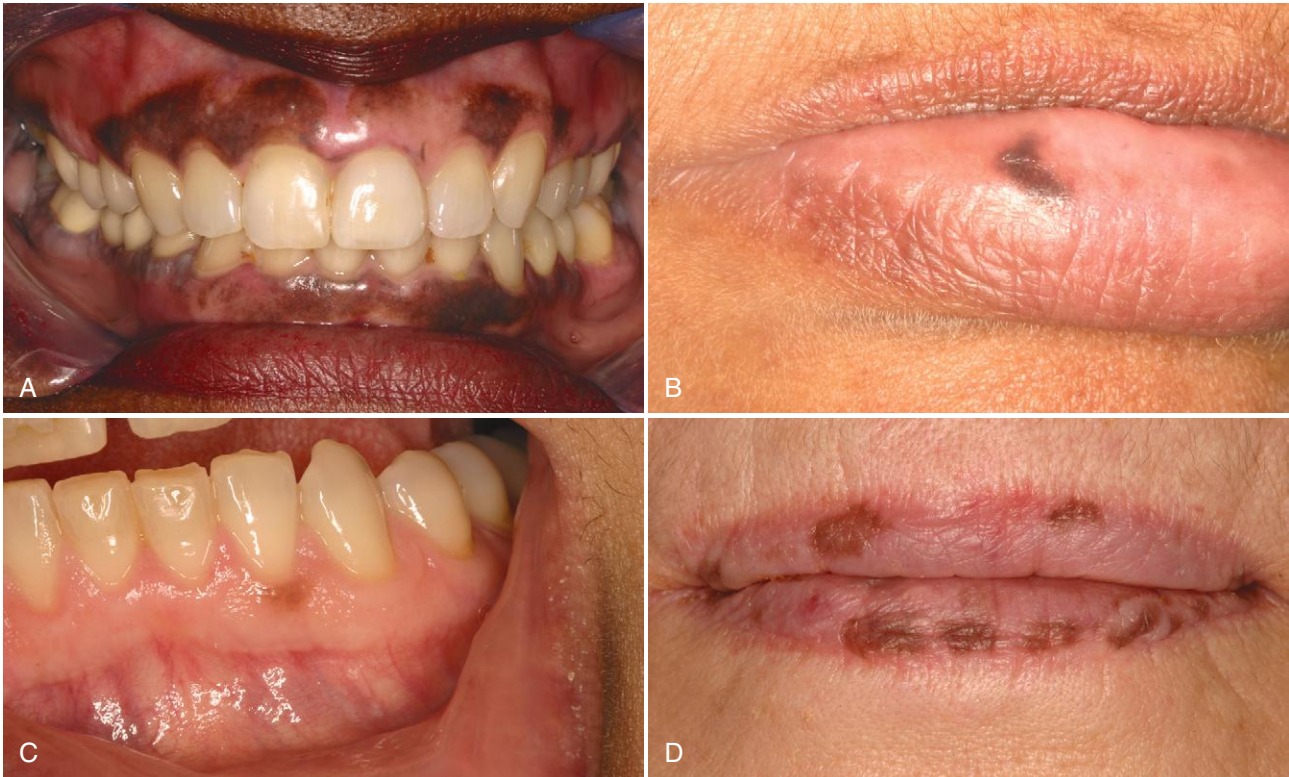#### Management and Prognosis

- No treatment is necessary; laser ablation may be helpful if there are cosmetic concerns.
- Most cases are not followed up, and it is unclear if the macules disappear over time.

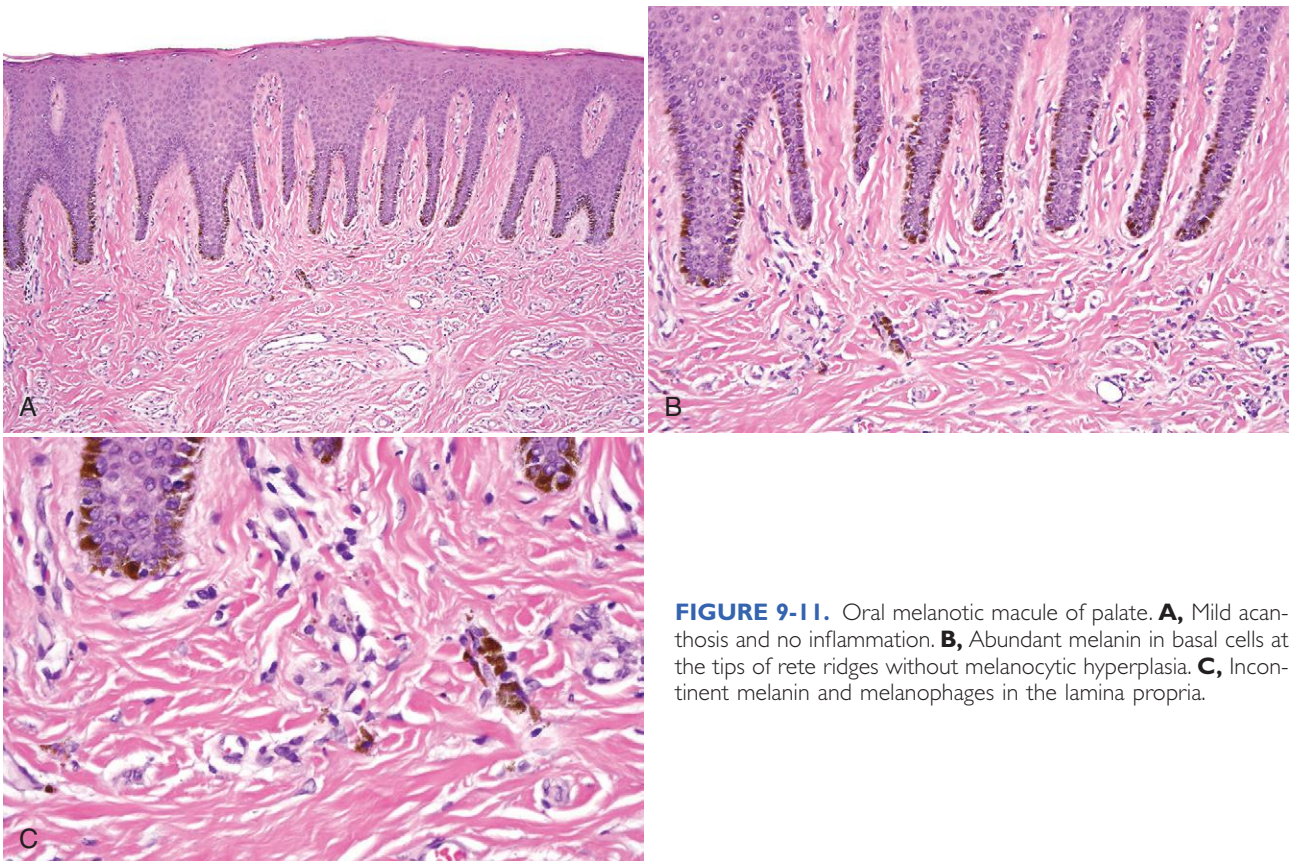
#### REFERENCES

- Buchner A, Merrell PW, Carpenter WM. Relative frequency of solitary melanocytic lesions of the oral mucosa. *J Oral Pathol Med.* 2004; 33:550-557.
- Dohil MA, Billman G, Pransky S, Eichenfield LF. The congenital lingual melanotic macule. *Arch Dermatol.* 2003;139:767-770.
- Gupta G, Williams RE, Mackie RM. The labial melanotic macule: a review of 79 cases. *Br J Dermatol.* 1997;136:772-775.
- Horvath A, Stratakis CA. Carney complex and lentiginosis. *Pigment Cell Melanoma Res.* 2009;22:580-587.
- Kaugars GE, Heise AP, Riley WT, et al. Oral melanotic macules. A review of 353 cases. *Oral Surg Oral Med Oral Pathol.* 1993;76:59-61.
- Mignogna MD, Lo Muzio L, Ruoppo E, et al. Oral manifestations of idiopathic lenticular mucocutaneous pigmentation (Laugier-Hunziker syndrome): a clinical, histopathologic and ultrastructural review of 12 cases. *Oral Dis.* 1999;5:80-86.
- Veraldi S, Cavicchini S, Benelli C, Gasparini G. Laugier-Hunziker syndrome: a clinical, histopathologic, and ultrastructural study of four cases and review of the literature. *J Am Acad Dermatol.* 1991;25:632-636.
- Yago K, Tanaka Y, Asanami S. Laugier-Hunziker-Baran syndrome. *Oral Surg Oral Med Oral Pathol Oral Radiol Endod.* 2008;106:e20-25.



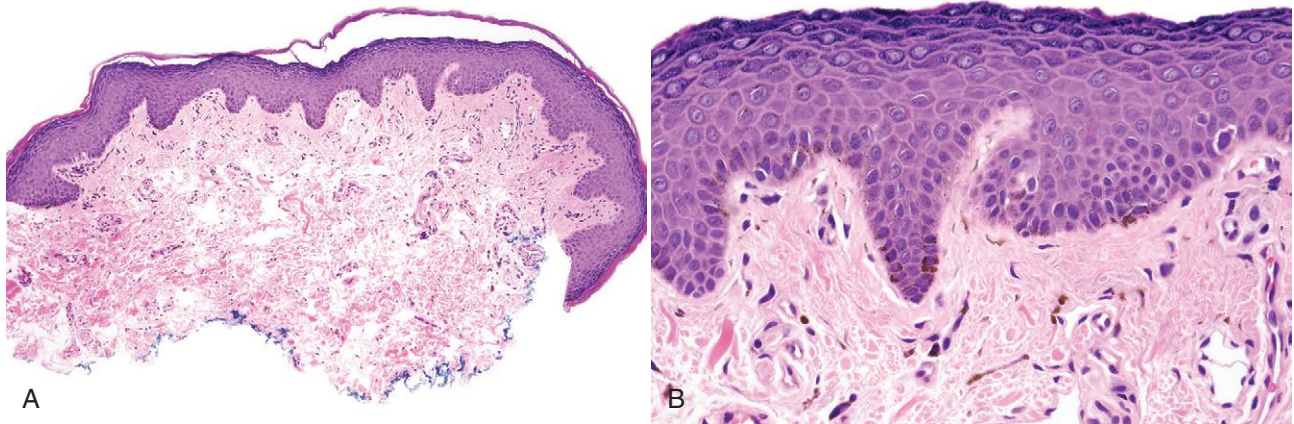


**FIGURE 9-10.** **A,** Physiologic pigmentation. **B,** Oral melanotic macule of the lower vermilion. **C,** Oral melanotic macule of the gingiva. **D,** Multiple oral melanotic macules, idiopathic.



**FIGURE 9-11.** Oral melanotic macule of palate. **A,** Mild acanthosis and no inflammation. **B,** Abundant melanin in basal cells at the tips of rete ridges without melanocytic hyperplasia. **C,** Incontinent melanin and melanophages in the lamina propria.





**FIGURE 9-12.** Oral melanotic macule of lower lip. **A**, Absence of melanocytic hyperplasia. **B**, Melanin within basal cells and midepithelium and melanophages in lamina propria.

## POSTINFLAMMATORY HYPERMELANOSIS

### Clinical Findings

- Associated with nonspecific inflammation or known inflammatory disease, especially lichen planus, history of significant antecedent inflammation (such as post-radiation mucositis and postchemotherapy mucositis), or a smoking habit (smoker's melanosis).
- Diffuse pigmentation appears on the involved mucosa in the area of the underlying inflammatory condition (Fig. 9-13); pigmentation may also be discrete if associated with localized inflammation.

### Etiopathogenesis and Histopathologic Features

Inflammatory lesions and, in particular, lichenoid lesions often result in perturbation of melanocytes in the epithelium, causing increased melanin deposition.

- Increased melanin pigment within basal cells with no or mild benign melanocytic hyperplasia; incontinent melanin, melanophages, and inflammation in the

lamina propria (Figs. 9-14 and 9-15) occurs; infrequently, there is benign melanocytic hyperplasia (Fig. 9-16); some lesions resemble early melanoacanthosis (Fig. 9-17).

- Inflammatory process is evident (e.g., lichenoid mucositis or nonspecific chronic inflammation) (Fig. 9-18).

### Differential Diagnosis

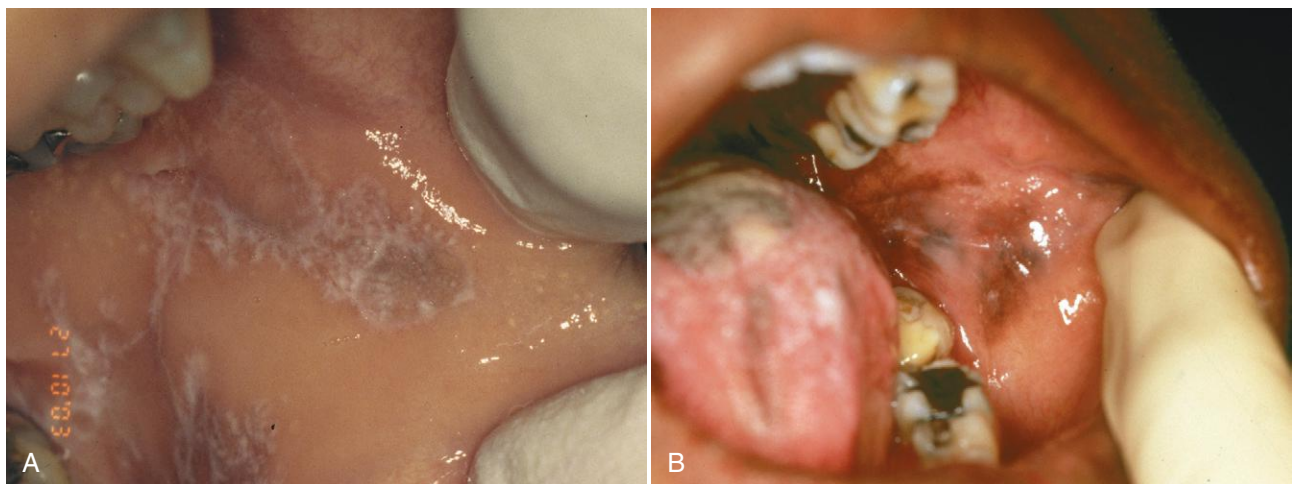
- Condition likely overlaps with melanoacanthosis if significant melanocytic hyperplasia is present (see Fig. 9-17, *B*).

### Management and Prognosis

- Even with treatment of the underlying inflammatory condition with topical steroid therapy, it takes many months for the pigmentary changes to fade.

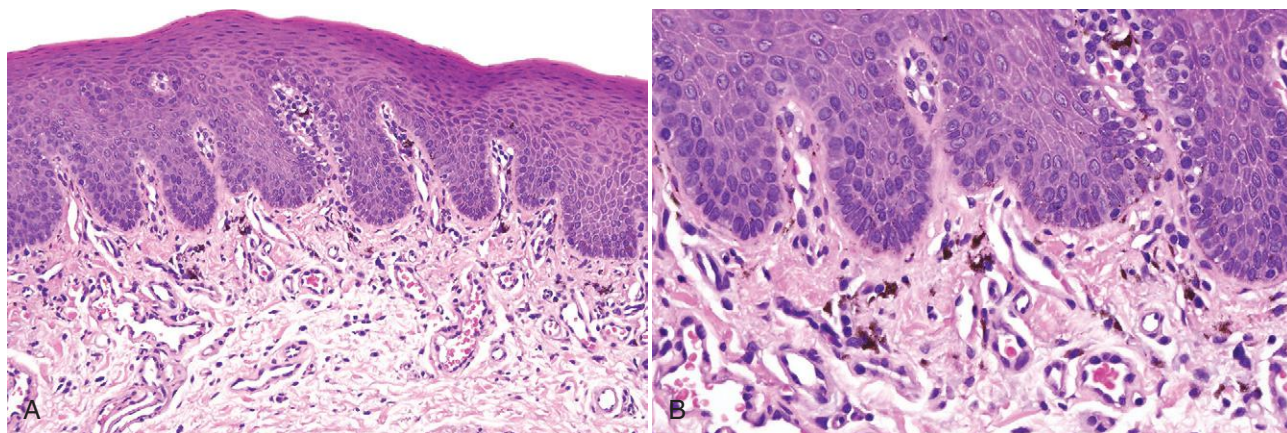
### REFERENCE

McKee P, Calonje E, Granter S, eds. *Pathology of the Skin*. 3rd ed. Philadelphia: Saunders; 2005.

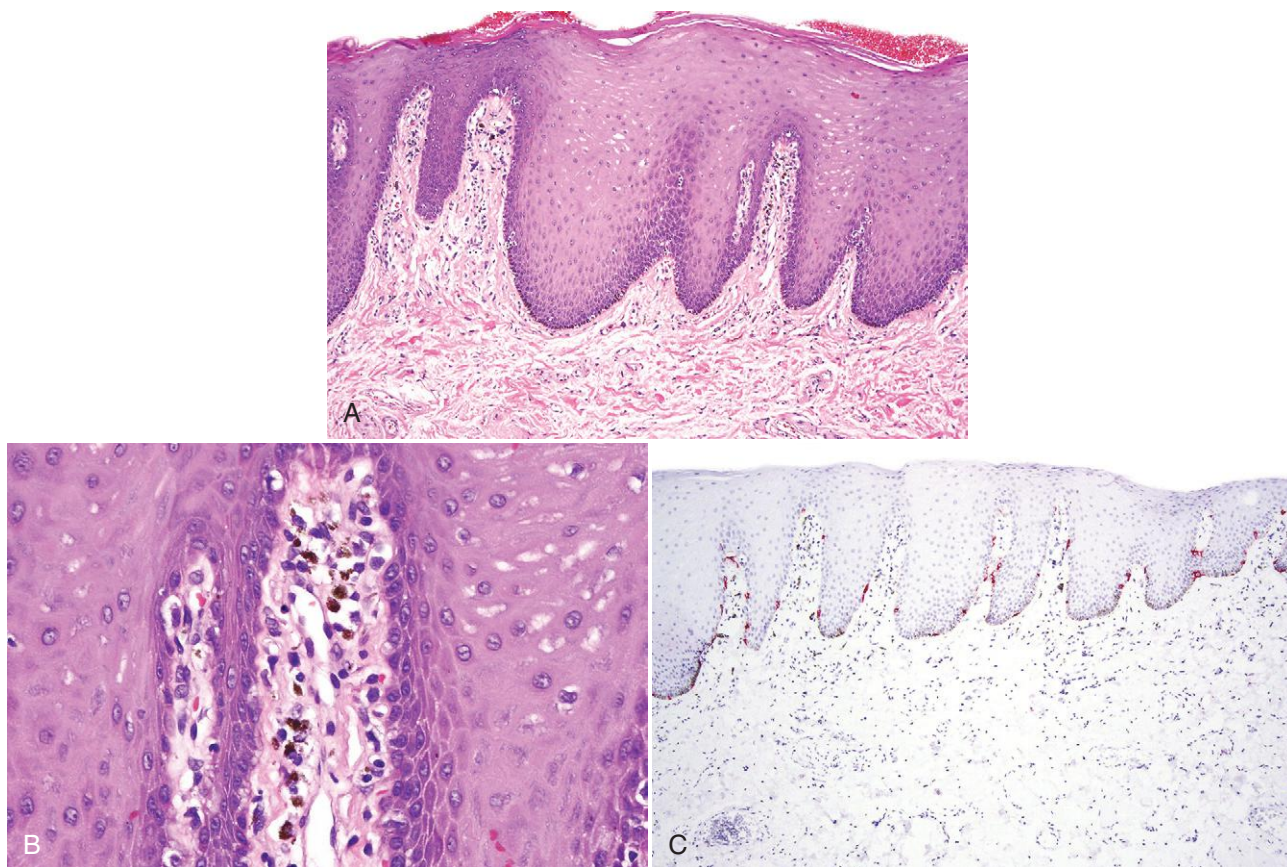


**FIGURE 9-13.** **A**, Postinflammatory hypermelanosis in lichen planus. **B**, Postradiation mucositis hypermelanosis.



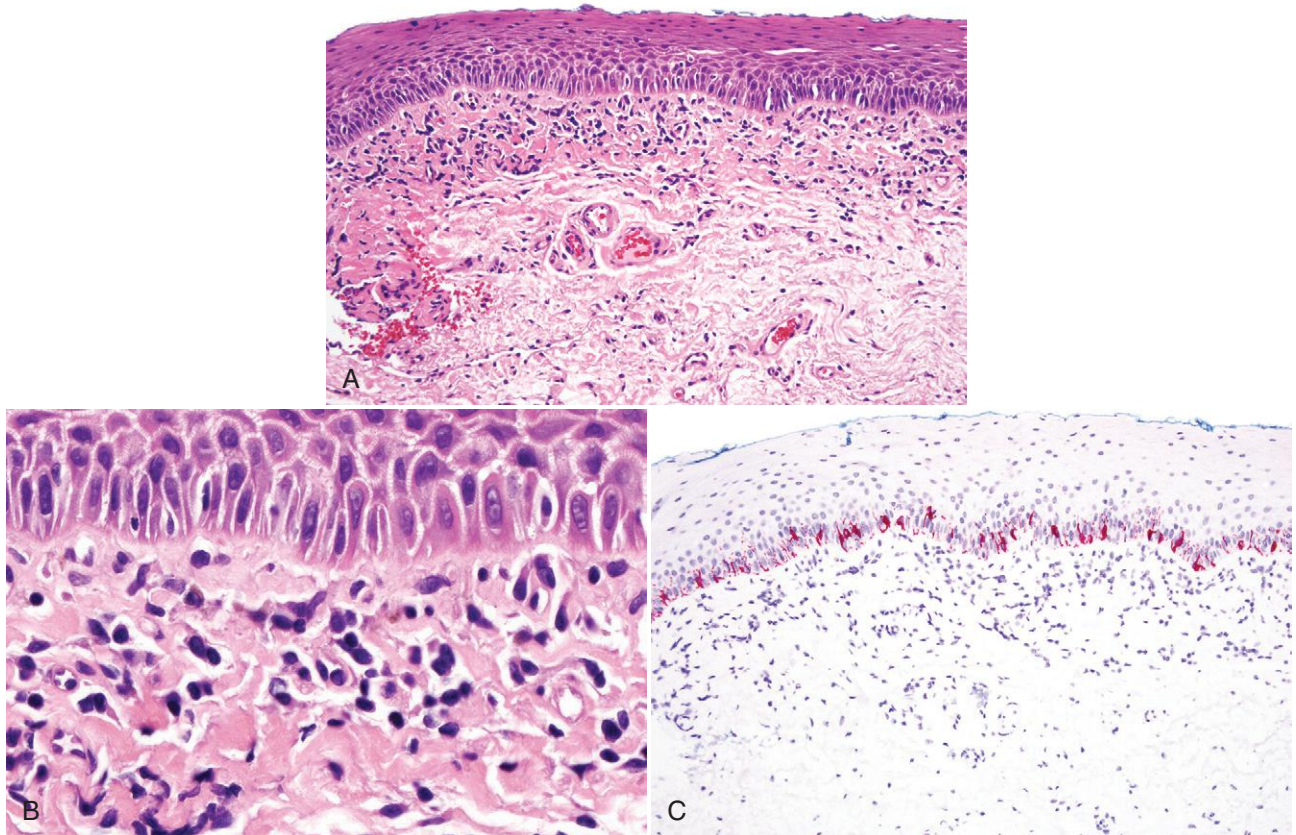


**FIGURE 9-14.** Postinflammatory hypermelanosis. **A**, Acanthosis, chronic inflammation, and vascular ectasia. **B**, Melanin in basal cells and lamina propria.

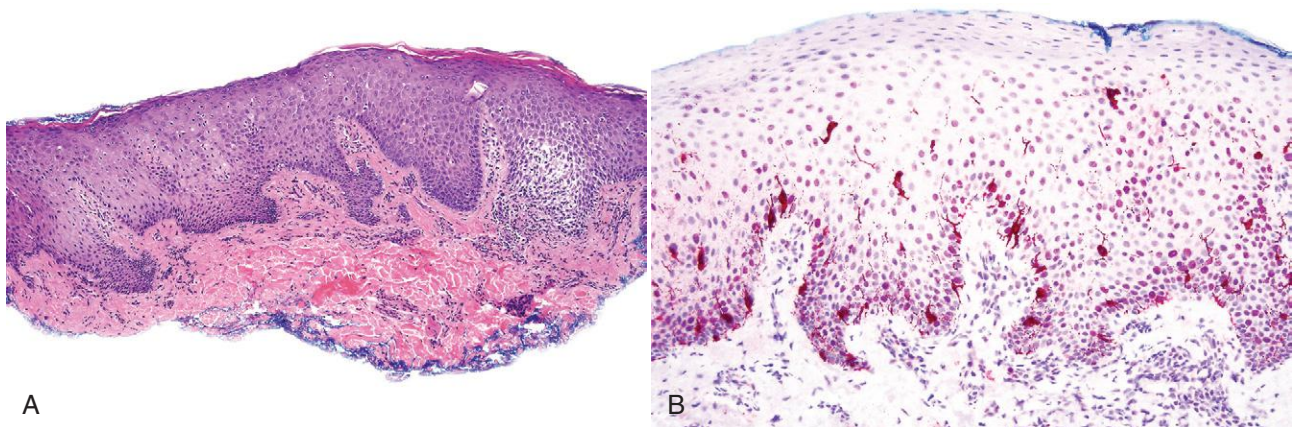


**FIGURE 9-15.** Postinflammatory hypermelanosis. **A**, Acanthosis and mild chronic inflammation. **B**, Melanin and melanophages with vascular ectasia. **C**, Minimal-to-no melanocytic hyperplasia (Melan-A).



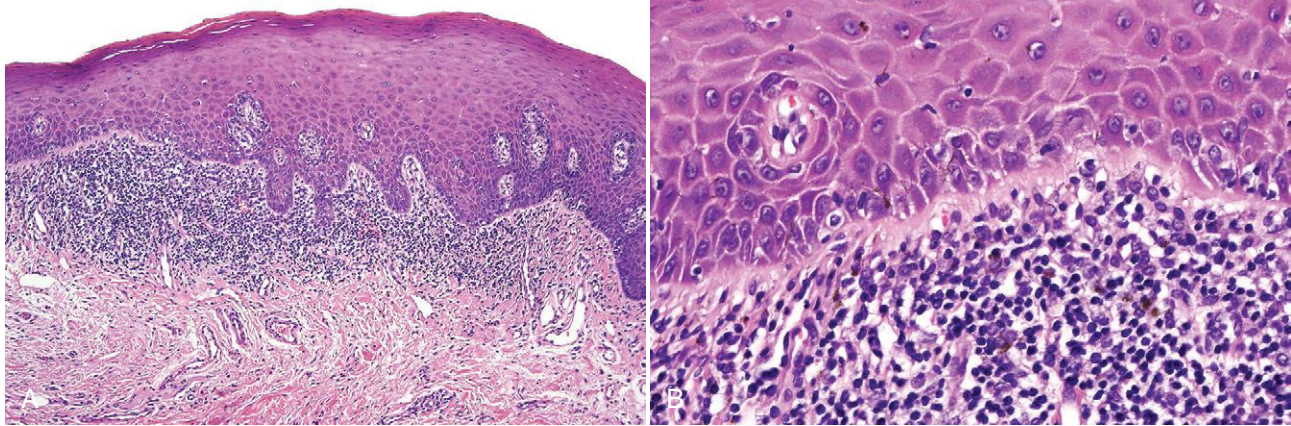


**FIGURE 9-16.** Postinflammatory hypermelanosis. **A**, Mild epithelial atrophy and chronic inflammation. **B**, Benign melanocytic hyperplasia and melanophages in the lamina propria. **C**, Fairly marked, benign lentiginous melanocytic hyperplasia (Melan-A).



**FIGURE 9-17.** Postinflammatory hypermelanosis. **A**, Acanthosis, spongiosis, and chronic inflammation. **B**, Benign melanocytic hyperplasia (Melan-A); this may represent early melanoacanthosis.





**FIGURE 9-18.** Lichenoid stomatitis. **A**, Squamatization of basal cells and lymphocytic band at the interface. **B**, Melanin pigment within dendritic processes in epithelium and melanophages in lamina propria.

## MELANOACANTHOSIS (MELANOACANTHOMA)

The term *melanoacanthosis* is preferable to *melanoacanthoma* because this macular lesion is not a tumorlike proliferation and is clinically distinct from cutaneous melanoacanthomas that occur in older white patients as plaques or nodules.

### Clinical Findings

- Melanoacanthosis occurs fairly rapidly (days to a few weeks); painless, tan-brown macules may be solitary (80%) or multifocal and are usually greater than 1 cm; they usually occur in young adult black females (Fig. 9-19); most common location is buccal mucosa (50%), followed by the palatal mucosa and lips.

### Etiopathogenesis and Histopathologic Features

This condition is likely a form of postinflammatory hypermelanosis (see earlier).

- Proliferation of benign dendritic melanocytes located throughout the full thickness of the acanthotic epithelium; minimal surface keratinization and spongiosis; increased melanin within basal cells; melanin, melanophages, and variable chronic inflammation in the lamina propria (Figs. 9-20, 9-21, A and B and 9-22)
- Melanocytes positive for S-100, Melan-A, and HMB-45 (see Fig. 9-21, C)

### Differential Diagnosis

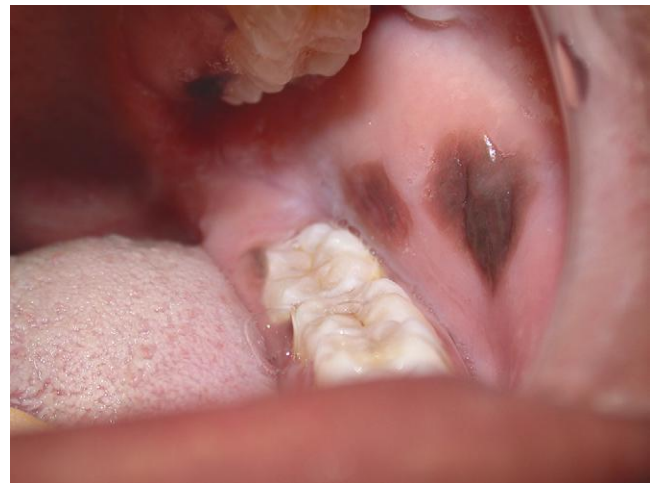- Lack of melanocytic atypia rules out an atypical melanocytic proliferation or melanoma in situ despite transmigration of melanocytes.

### Management and Prognosis

- No treatment is necessary; lesions will likely fade over time.

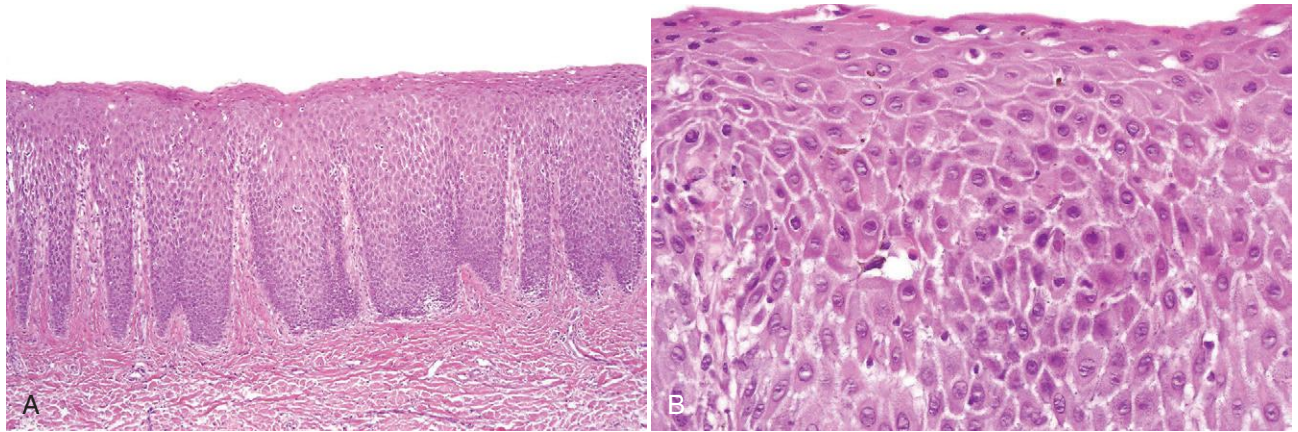
### REFERENCES

- Carlos-Bregni R, Contreras E, Netto AC, et al. Oral melanoacanthoma and oral melanotic macule: a report of 8 cases, review of the literature, and immunohistochemical analysis. *Med Oral Patol Oral Cir Bucal.* 2007;12:E374-379.
- Fatahzadeh M, Sirois DA. Multiple intraoral melanoacanthomas: a case report with unusual findings. *Oral Surg Oral Med Oral Pathol Oral Radiol Endod.* 2002;94:54-56.
- Fornatora ML, Reich RF, Haber S, et al. Oral melanoacanthoma: a report of 10 cases, review of the literature, and immunohistochemical analysis for HMB-45 reactivity. *Am J Dermatopathol.* 2003;25:12-15.
- Goode RK, Crawford BE, Callihan MD, Neville BW. Oral melanoacanthoma. Review of the literature and report of ten cases. *Oral Surg Oral Med Oral Pathol.* 1983;56:622-628.
- Tomich CE, Zunt SL. Melanoacanthosis (melanoacanthoma) of the oral mucosa. *J Dermatolog Surg Oncol.* 1990;16:231-236.
- Yarom N, Hirshberg A, Buchner A. Solitary and multifocal oral melanoacanthoma. *Int J Dermatol.* 2007;46:1232-1236.

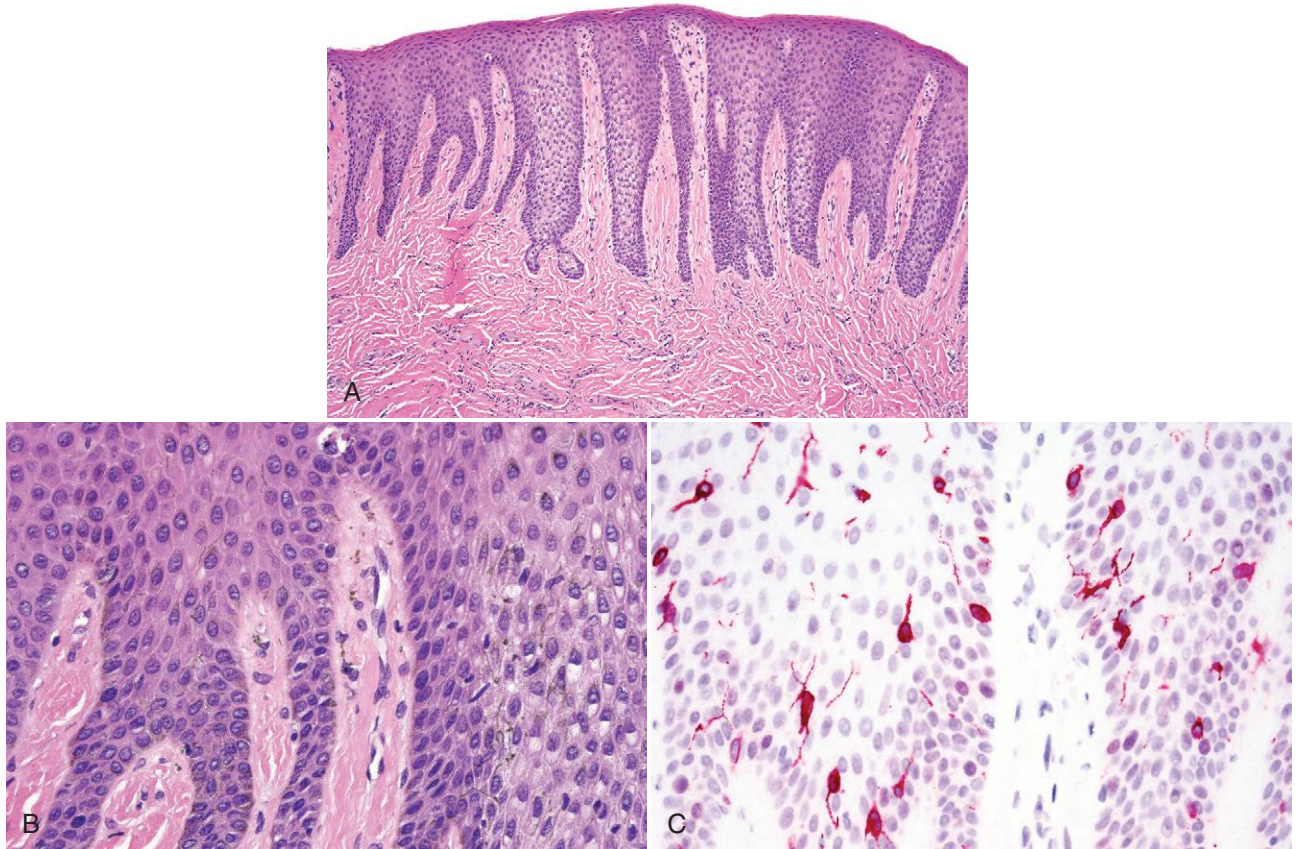


**FIGURE 9-19.** Melanoacanthosis of left buccal mucosa. (Courtesy of Dr. Bonnie Padwa, Harvard School of Dental Medicine, Boston, Mass.)



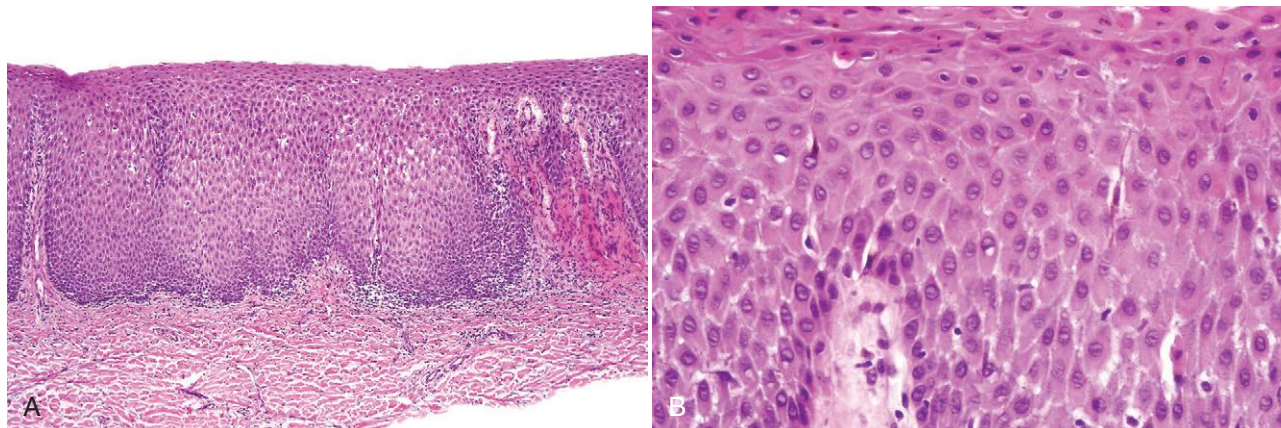


**FIGURE 9-20.** Melanoacanthosis. **A**, Acanthosis, spongiosis, and mild chronic inflammation. **B**, Dendritic melanocytes in superficial epidermis.



**FIGURE 9-21.** Melanoacanthosis. **A**, Parakeratosis and acanthosis with no inflammation. **B**, Many pigmented dendritic processes in the epidermis and melanin in the lamina propria. **C**, Dendritic melanocytes high in the epidermis (Melan-A).





**FIGURE 9-22.** Melanoacanthosis. **A**, Acanthosis, spongiosis, and mild chronic inflammation. **B**, Dendritic melanocytes high in the epithelium.

## ORAL MELANOCYTIC NEVUS

### Clinical Findings

- Most are noted in the third to fourth decade of life.
- Frequency is as follows: intramucosal nevi (64% to 80%), blue nevi (8% to 17%), and compound (6% to 17%); junctional and combined nevi are rare.
- Intramucosal, compound, and combined nevi tend to be plaques or nodules, and blue and junctional nevi are macules or plaques (Fig. 9-23); plaque-type blue nevus is a distinct subtype of blue nevus.
- Common sites are palatal mucosa (34% to 44%), mucobuccal fold (24%), buccal mucosa (11% to 22%), lip vermilion (18%), and gingiva (12% to 23%).

### Etiopathogenesis and Histopathologic Findings

Oral melanocytic nevi are hamartomas that derive from nevomelanocytes cells that originate from the neural crest.

- Intramucosal nevus: nests and theques of epithelioid cells (type A) just beneath the epithelium with variable pigment content, often heavily pigmented near surface; lymphocyte-like (type B) or neuroid spindle cells (type C) deeper in the lamina propria; slight junctional activity acceptable for intramucosal nevus; may see significant nuclear-shaped pleomorphism, but chromatin dispersed without mitotic activity (Figs. 9-24 to 9-26)
- Junctional nevus: many nests of benign nevus cells in the basal layer
- Compound nevus: combination of intramucosal and junctional nevus (Fig. 9-27)
- Blue nevus: spindled nevus cells with benign nuclei without junctional nests; usually heavily pigmented; epithelioid variant seen; nonpigmented spindle cells HMB-45 positive, and like skin lesions may be S-100 negative (Figs. 9-28 and 9-29)

- Combined nevus: presence of both intramucosal and blue nevus usually without superficial nesting (Figs. 9-30 and 9-31)
- Rare cases of balloon cell nevus reported
- Cells positive for S-100 protein, Melan-A, and HMB-45

### Differential Diagnosis

- Amalgam tattoo differs from blue nevus because of deposition of pigment granules along connective tissue fibers and is negative for melanocytic markers.
- Medication-induced pigmentation exhibits regular spherical granules that stain for iron and is negative for melanocytic markers.
- Dysplastic nevus and malignant melanoma show cytologic atypia; oral melanoma almost always has an intraepithelial dysplastic melanocytic component; metastatic melanoma to the oral mucosa will not show an in situ component.

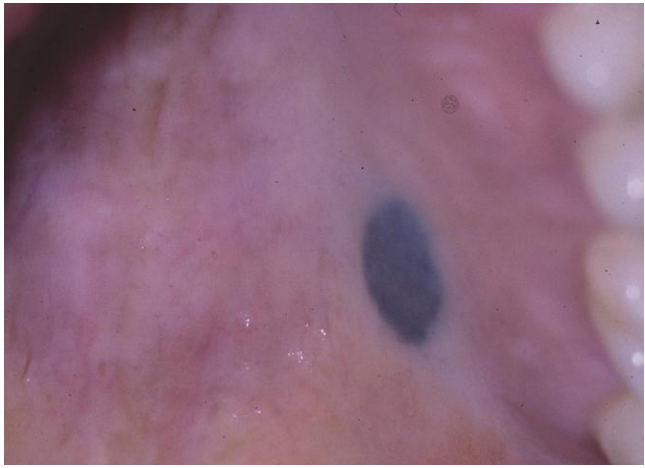### Management and Prognosis

- Excision is curative and lesions do not recur. Remnant lesions after incisional biopsy do not require excision.

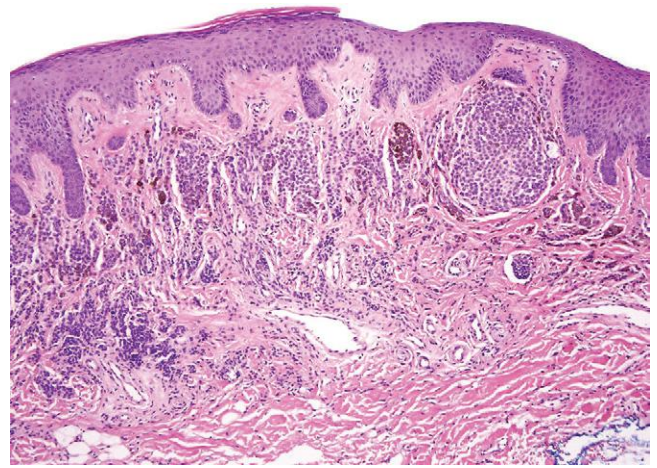
### REFERENCES

- Buchner A, Merrell PW, Carpenter WM. Relative frequency of solitary melanocytic lesions of the oral mucosa. *J Oral Pathol Med.* 2004;33:550-557.
- Damm DD, White DK, Lyu PE, Puno P. Balloon cell nevus of the oral mucosa. *Oral Surg Oral Med Oral Pathol Oral Radiol Endod.* 2008;105:755-757.
- Ficarra G, Hansen LS, Engebretsen S, Levin LS. Combined nevi of the oral mucosa. *Oral Surg Oral Med Oral Pathol.* 1987;63:196-201.
- Fistarol SK, Itin PH. Plaque-type blue nevus of the oral cavity. *Dermatology.* 2005;211:224-233.
- McKee P, Calonje E, Granter S, eds. *Pathology of the Skin.* 3rd ed. Philadelphia: Saunders; 2005.
- Meleti M, Mooi WJ, Casparie MK, van der Waal I. Melanocytic nevi of the oral mucosa—no evidence of increased risk for oral malignant melanoma: an analysis of 119 cases. *Oral Oncol.* 2007;43:976-981.
- Sun J, Morton TH Jr, Gown AM. Antibody HMB-45 identifies the cells of blue nevi. An immunohistochemical study on paraffin sections. *Am J Surg Pathol.* 1990;14:748-751.

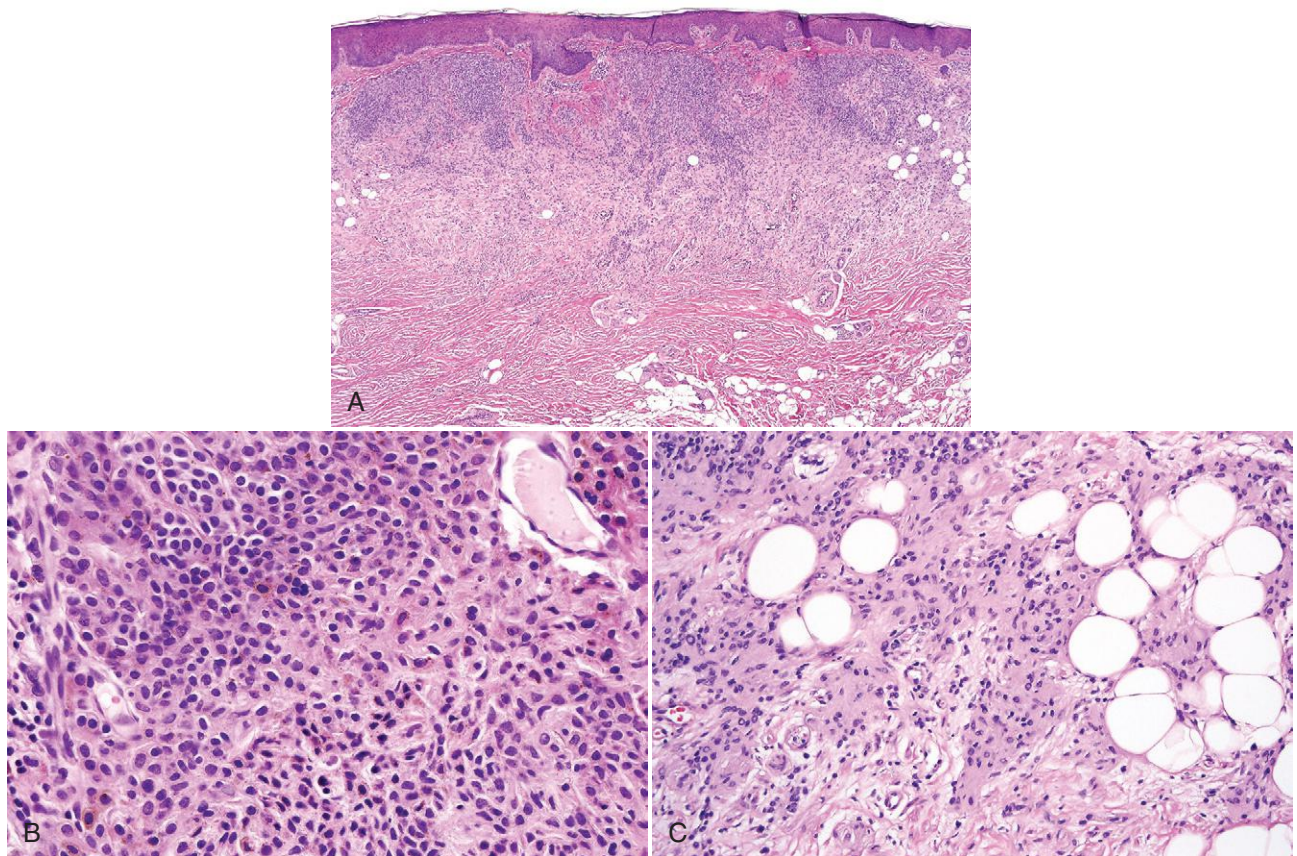




**FIGURE 9-23.** Blue nevus of the palate. (Courtesy of Dr. Sadru Kabani, private practice, Cambridge, Mass.)

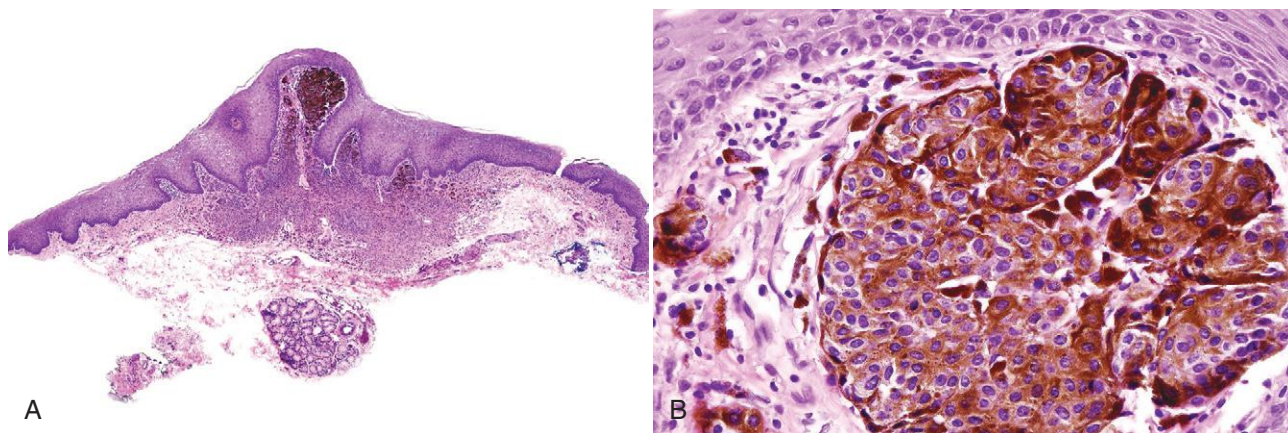


**FIGURE 9-24.** Intramucosal nevus with nests of epithelioid pigmented cells (type A) near the surface and lymphocyte-like cells (type B) and spindle cells (type C) deeper in tissues.

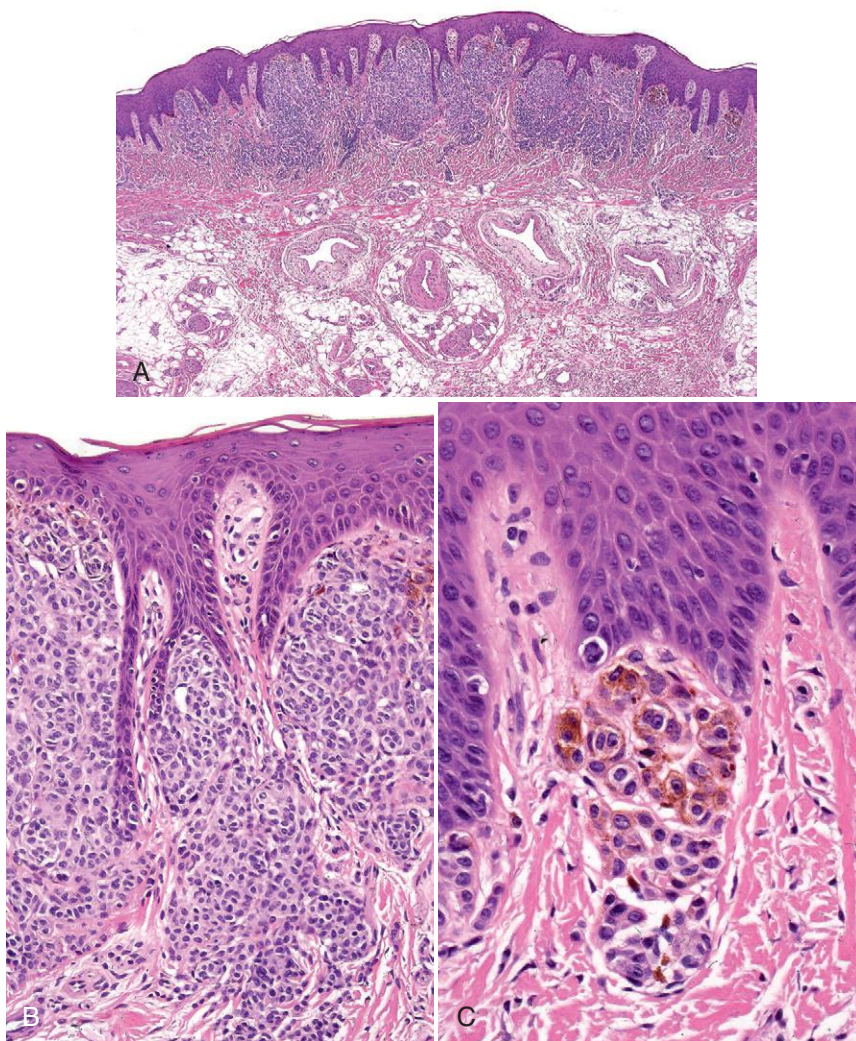


**FIGURE 9-25.** Intramucosal nevus. **A**, Grenz zone and superficial epithelioid and deeper spindle cells. **B**, Nests of pigmented epithelioid nevus cells transitioning to individual nevus cells. **C**, Spindled neuroid (type C) or lymphoid-appearing cells (type B) (top) with mature lipocytes.



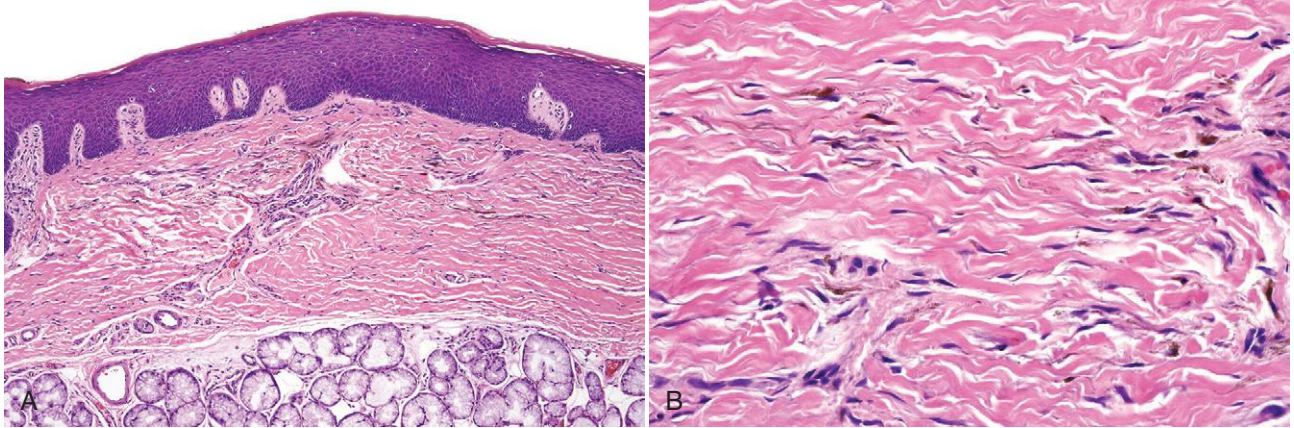


**FIGURE 9-26.** Intramucosal nevus. **A**, Buccal mucosa exhibiting epithelial hyperplasia. **B**, Heavily pigmented nevus cells and a few melanophages.

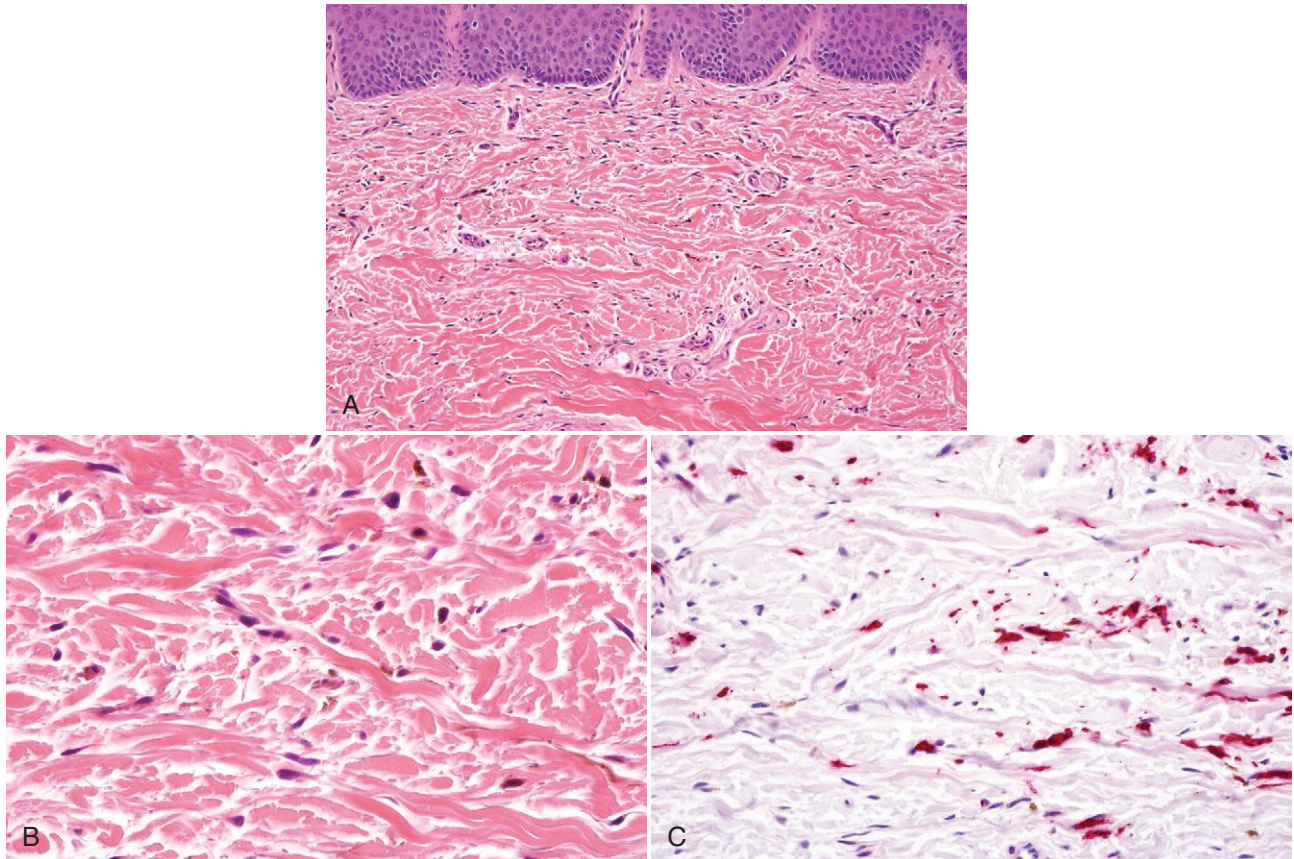


**FIGURE 9-27.** Compound nevus. **A**, Symmetric lesion with nevus cells abutting epithelium. **B**, Epithelioid nevus cells appear to hang from tips of rete ridges. **C**, Junctional nesting of pigmented nevus cells. (A, From Woo S. *Oral mucosa pigmented lesions*. In: McKee PH, Colonje E: *Diagnostic Atlas of Melanocytic Pathology*. Philadelphia: Saunders; 2009.)



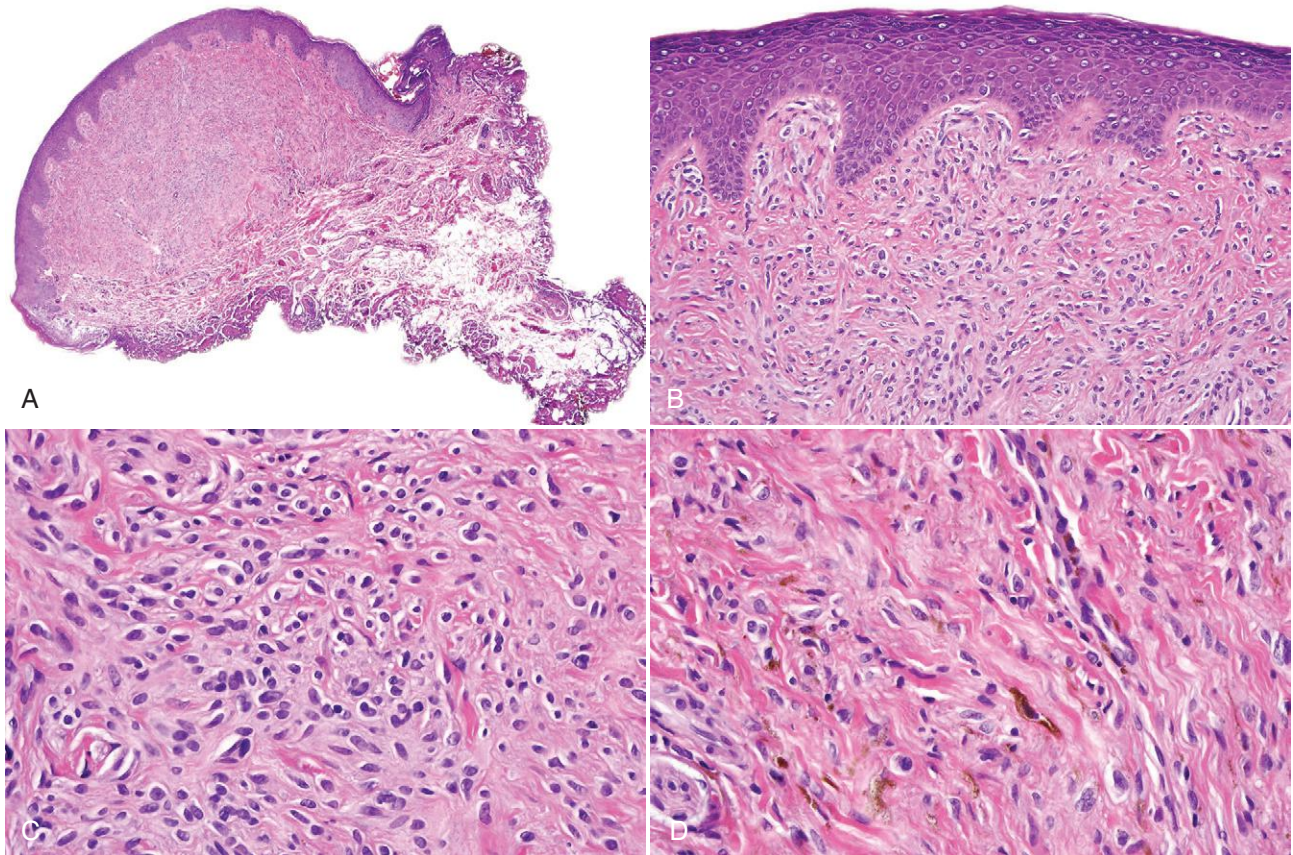


**FIGURE 9-28.** Blue nevus of palate. **A**, Subtly pigmented lesion in lamina propria. **B**, Spindled pigmented dendritic melanocytes.

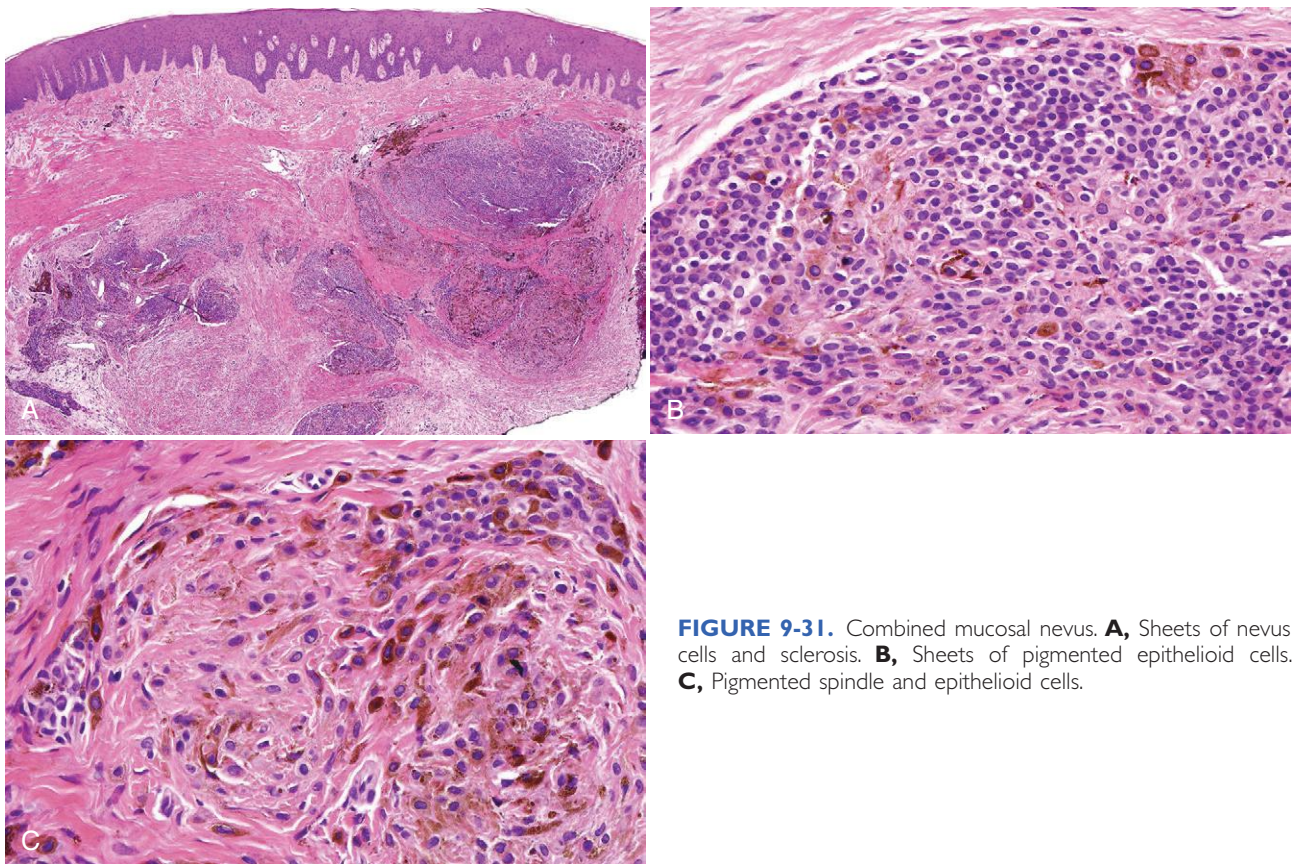


**FIGURE 9-29.** Blue nevus. **A**, Proliferation of spindle cells in lamina propria. **B**, Subtly pigmented spindled melanocytes. **C**, Positivity with Melan-A.





**FIGURE 9-30.** Combined mucosal nevus. **A**, Polypoid mass. **B**, Superficial cells are spindled and epithelioid and do not show nesting. **C**, Slightly nested epithelioid cells. **D**, Pigmented dendritic cells.



**FIGURE 9-31.** Combined mucosal nevus. **A**, Sheets of nevus cells and sclerosis. **B**, Sheets of pigmented epithelioid cells. **C**, Pigmented spindle and epithelioid cells.



## DYSPLASTIC MELANOCYTIC NEVUS AND MUCOSAL MELANOMA

### Clinical Findings

Head and neck melanoma constitutes 1% to 8% of all melanomas; it is much more common in the sinonasal tract than in the oral cavity, and it is more common in blacks and Japanese. It tends to occur in older patients compared with skin melanomas.

- Occurs in fifth to seventh decade of life with male predilection; usually on the palatal mucosa, gingiva, or lip.
- Melanoma arises within a dysplastic melanocytic lesion similar to acral lentiginous melanoma (Fig. 9-32).
- Melanomas are usually greater than 1 cm and are irregularly pigmented with irregular borders; nodularity and areas of hemorrhage should arouse suspicion.

### Etiopathogenesis and Histopathologic Features

Because the oral cavity is not exposed to the sun, oral melanomas are of unclear etiopathogenesis, and they behave in a similar fashion to acral lentiginous melanoma.

- Dysplastic melanocytic nevus or in situ melanoma: proliferation of atypical melanocytes within the epithelium either in lentiginous or pagetoid fashion; retraction artifact seen in melanocytes and nests (Fig. 9-33, A)
- Melanoma: atypical spindled or epithelioid melanocytes within lamina propria; large nuclei, prominent nucleoli, and pseudoinclusions in epithelioid cells (Figs. 9-34, A-C, 9-35, A-C; see Fig. 9-33, B and C); up to 40% amelanotic; transepithelial migration of atypical melanocytes characteristic (see Figs. 9-34, D, 9-35, D); cells S-100 protein positive, HMB-45 positive, Melan-A positive, and cytokeratin negative (see Fig. 9-34, E)
- Level I: in situ lesion or microinvasion only; level II: invasion into the lamina propria only; level III: invasion into the deep structures (such as muscle, bone, or cartilage); Clark's levels and Breslow thickness not useful for prognostication
- Sarcomatoid features, pseudopapillary architecture and undifferentiated cells, thickness greater than 5 mm, and vascular invasion associated with poor survival

### Differential Diagnosis

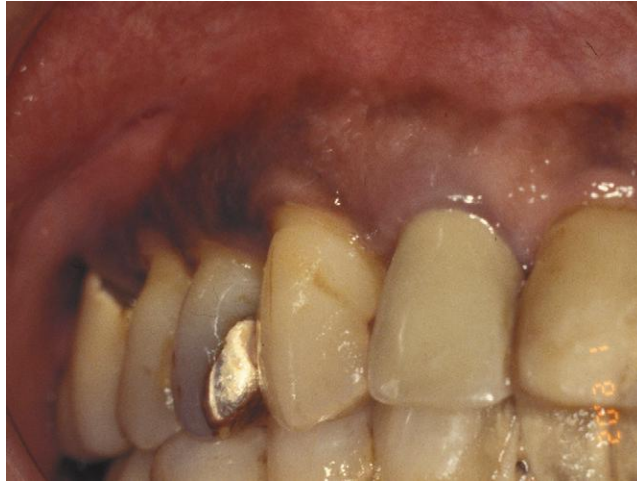- Poorly differentiated spindled and epithelioid malignancies are differentiated from melanoma based on positive identification of cytoplasmic S-100 protein, HMB-45, Melan-A, and negativity with cytokeratin.

### Management and Prognosis

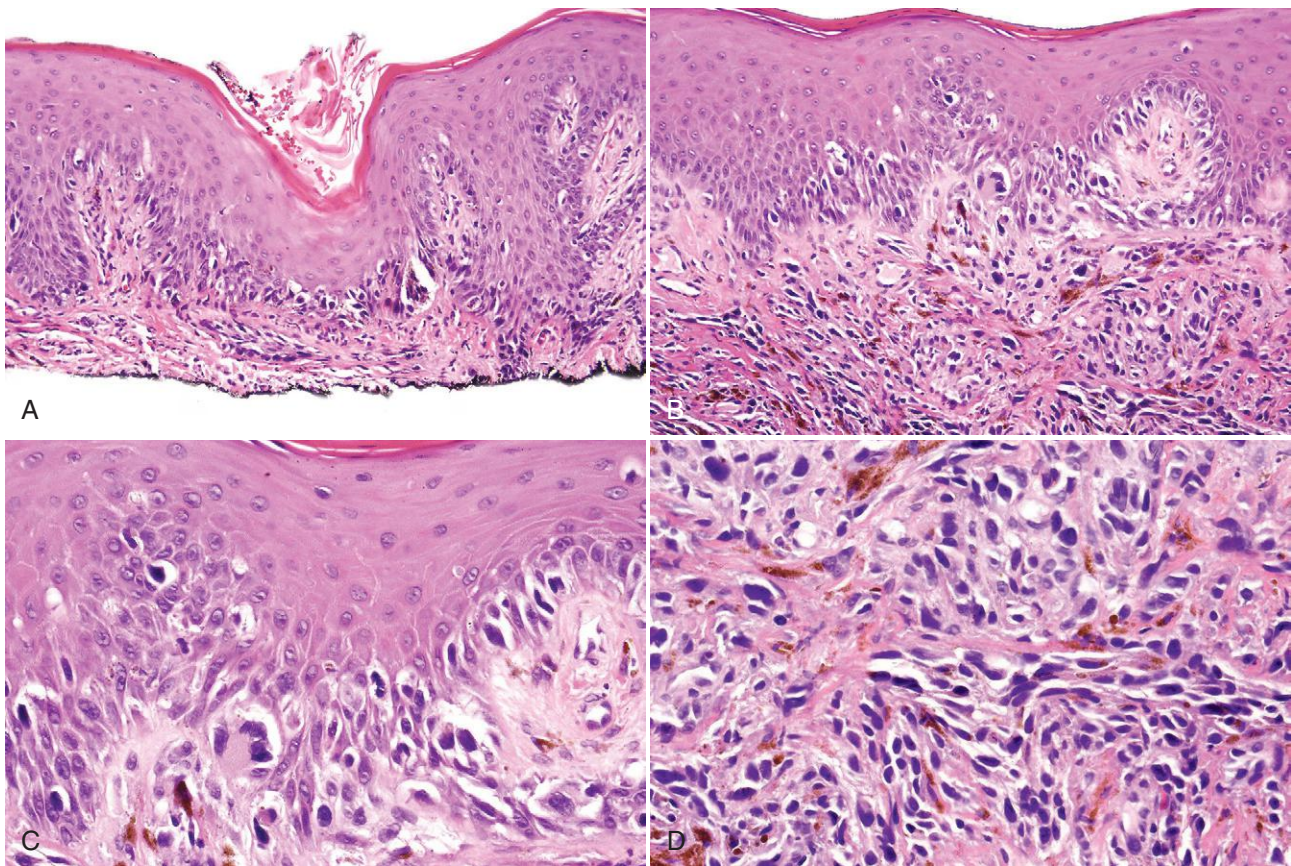
- Excision with clear margins is the treatment of choice; recurrence rate is 50%; adjuvant radiotherapy reduces local relapse and metastases, but it may not improve survival.
- Stage I disease with level I and III invasion have median survival of 138 and 117 months, respectively.
- Nodal and distant metastases occur in 24% and 44% of cases, respectively, and 5-year survival is 20% to 30%.
- Chemotherapeutic regimens, including the use of interferon, are still under investigation.

### REFERENCES

- Chang AE, Karnell LH, Menck HR. The National Cancer Data Base report on cutaneous and noncutaneous melanoma: a summary of 84,836 cases from the past decade. The American College of Surgeons Commission on Cancer and the American Cancer Society. *Cancer*. 1998;83:1664-1678.
- Lourenco SV, Sanguenza M, Sotto MN, et al. Primary oral mucosal melanoma: a series of 35 new cases from South America. *Am J Dermatopathol*. 2009;31:323-330.
- Manolidis S, Donald PJ. Malignant mucosal melanoma of the head and neck: review of the literature and report of 14 patients. *Cancer*. 1997;80:1373-1386.
- Meleti M, Leemans CR, de Bree R, et al. Head and neck mucosal melanoma: experience with 42 patients, with emphasis on the role of postoperative radiotherapy. *Head Neck*. 2008;30:1543-1551.
- Mendenhall WM, Amdur RJ, Hinerman RW, et al. Head and neck mucosal melanoma. *Am J Clin Oncol*. 2005;28:626-630.
- Prasad ML, Busam KJ, Patel SG, et al. Clinicopathologic differences in malignant melanoma arising in oral squamous and sinonasal respiratory mucosa of the upper aerodigestive tract. *Arch Pathol Lab Med*. 2003;127:997-1002.
- Prasad ML, Patel SG, Huvos AG, et al. Primary mucosal melanoma of the head and neck: a proposal for microstaging localized, stage I (lymph node-negative) tumors. *Cancer*. 2004;100:1657-1664.
- Queirolo P, Acquati M, Kirkwood JM, et al. Update: current management issues in malignant melanoma. *Melanoma Res*. 2005;15:319-324.
- Rapini RP, Golitz LE, Greer RO Jr, et al. Primary malignant melanoma of the oral cavity. A review of 177 cases. *Cancer*. 1985;55:1543-1551.

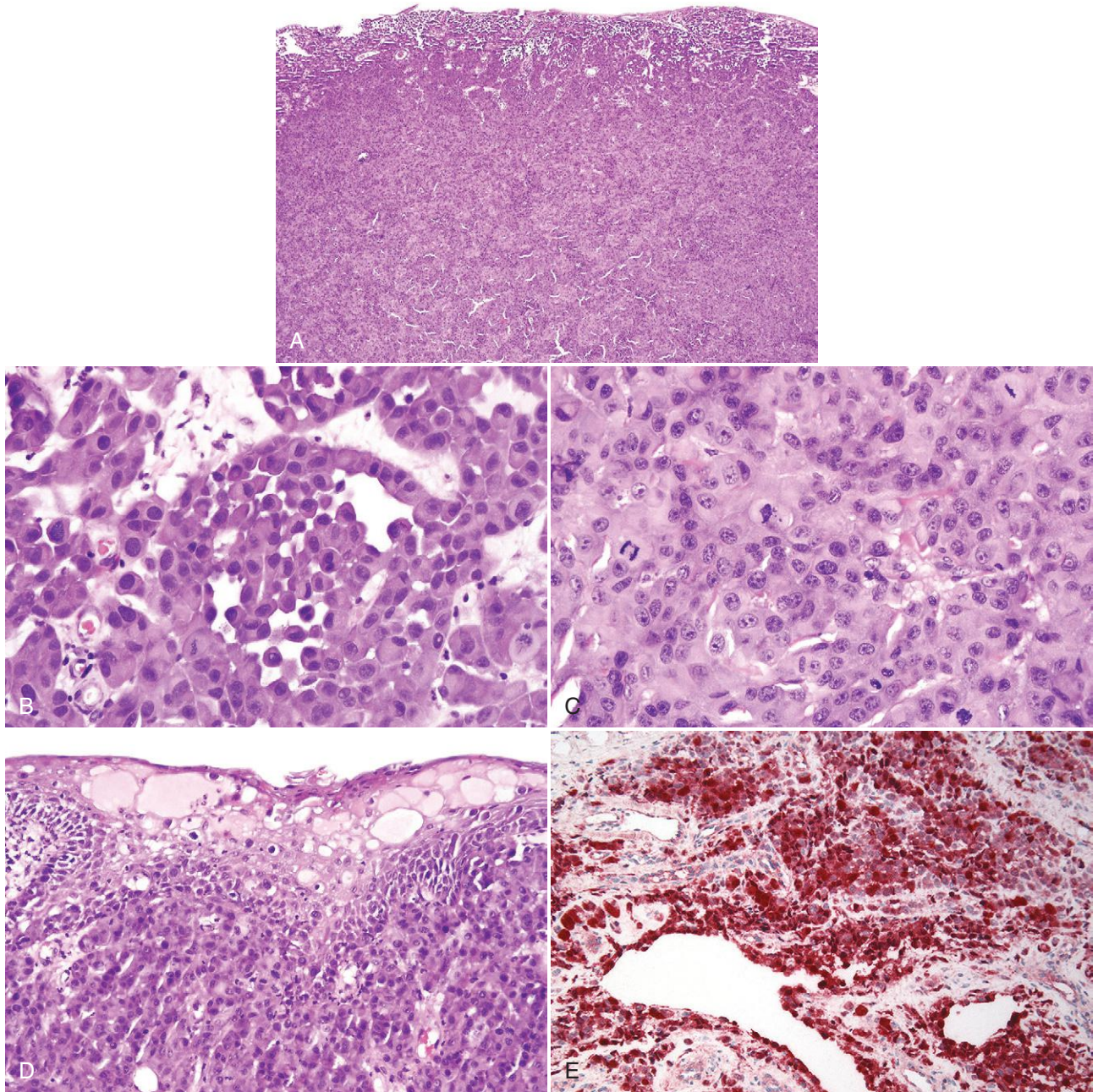


**FIGURE 9-32.** Melanocytic dysplasia of the maxillary gingiva.



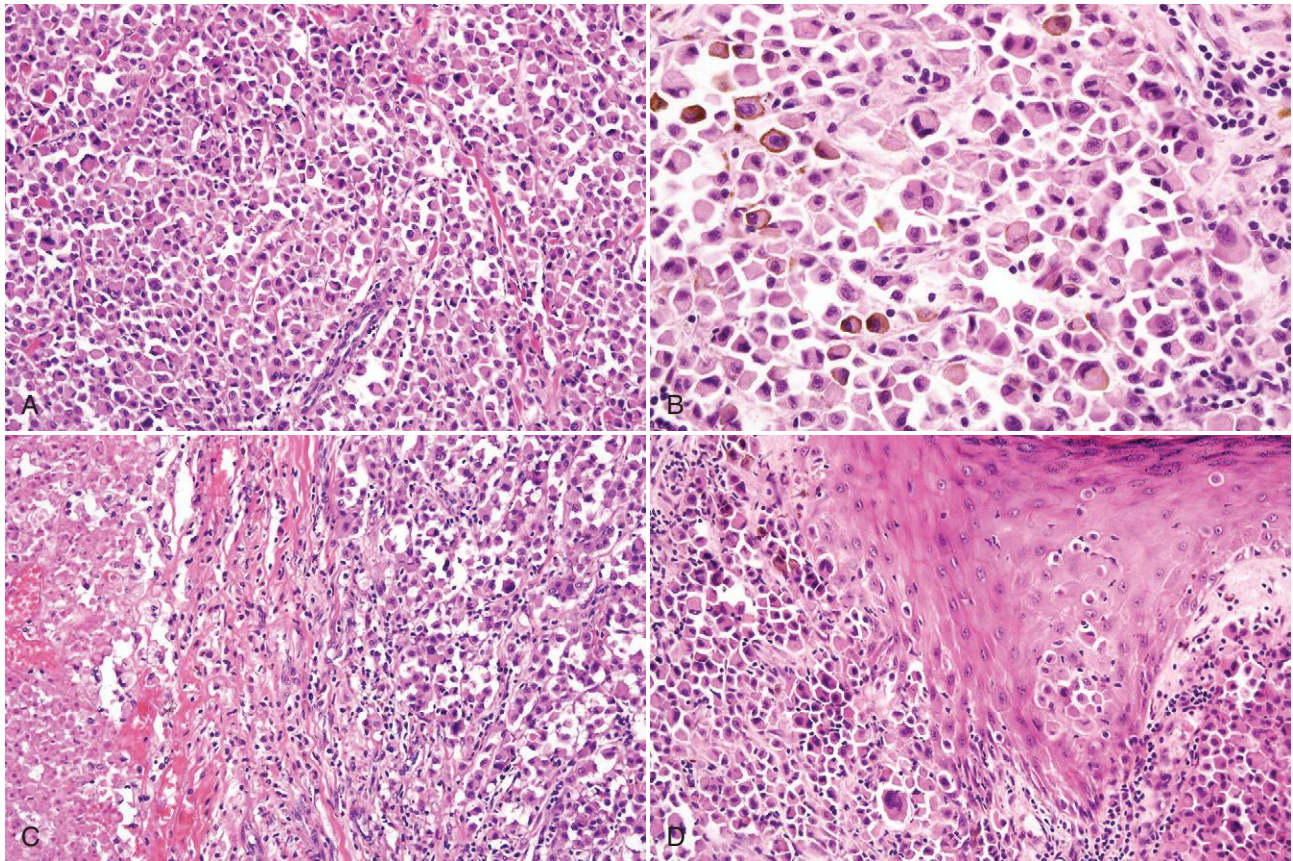
**FIGURE 9-33.** Melanoma arising from melanocytic dysplasia (from patient in Fig. 9-32). **A**, Dysplastic melanocytic nevus with atypical nested melanocytes within epithelium at some distance from the main tumor. **B**, Atypical spindled and pleomorphic pigmented melanocytes in the lamina propria. **C**, Epithelium exhibits lentiginous proliferation of atypical melanocytes. **D**, Melanoma composed of pleomorphic epithelioid and spindled melanocytes.





**FIGURE 9-34.** Amelanotic nodular melanoma. **A**, Sheets of atypical melanocytes with overlying ulcer. **B**, Large polyhedral cells with eccentric nuclei and abundant cytoplasm without obvious melanin. **C**, Many mitotic figures and cells with pseudoinclusion. **D**, Atypical melanocytes within the epithelium. **E**, Tumor cells are S-100 positive.





**FIGURE 9-35.** Nodular melanoma. **A**, Sheets of atypical polyhedral melanocytes. **B**, Large atypical epithelioid melanocytes with pleomorphic nuclei and melanin. **C**, Areas of necrosis. **D**, Atypical melanocytes within the epithelium.



## Neuroectodermal Pigmentation

### MELANOTIC NEUROECTODERMAL TUMOR OF INFANCY

#### Clinical Findings

- Most cases manifest in the first 6 months of life, and more than 90% occur in the head and neck; slight male predilection (1.5:1) and is the most common site (60%) (Fig. 9-36); extraoral cases are more common in children older than 1 year.
- Tumor grows rapidly and consists of a brownish-red, mass of the alveolar mucosa with a radiolucency within the bone.
- Vanillylmandelic acid is increased in urine.
- Lymph node or distant metastases occur in 3% to 7% of cases.

#### Etiopathogenesis and Histopathologic Features

Melanotic neuroectodermal tumor of infancy is likely to derive from tissues of neural crest origin.

- Biphasic tumor: larger, polygonal epithelioid cells with large nuclei and dispersed chromatin appear as islands or in an alveolar pattern; these cells contain melanin and are positive for HMB-45, PGP9.5, pancytokeratin, and occasionally S-100 protein; smaller ovoid, poorly differentiated neuroblast-like cells with hyperchromatic nuclei and scant cytoplasm stain for synaptophysin, chromogranin, and CD56; both populations are positive for neuron-specific enolase (Figs. 9-37 and 9-38).

- Increased Ki67 fraction (usually in neuroblast-like cells) and presence of CD99 may correlate with poorer prognosis.
- Metastatic lesions usually contain neuroblast-like cells.

#### Differential Diagnosis

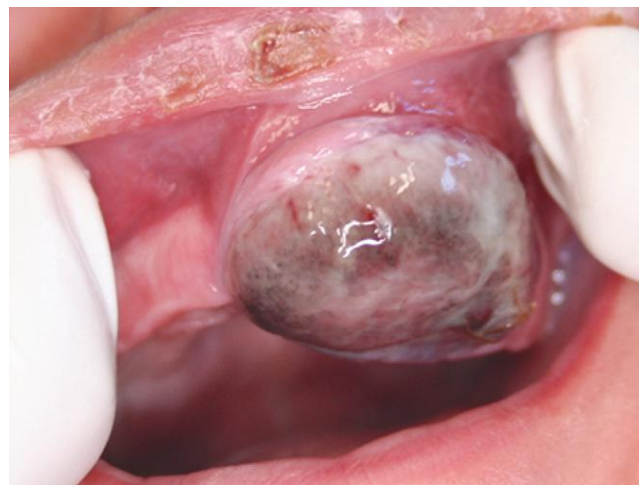- Biphasic nature of the tumor and positivity for melanocyte markers rules out other small blue cell tumors of childhood, such as neuroblastoma, rhabdomyosarcoma (myogenin positive and MyoD positive), and Ewing sarcoma/peripheral neuroectodermal tumor (CD99 positive).

#### Management and Prognosis

- Surgery is treatment of choice; some cases require radiotherapy and/or chemotherapy.
- Recurrence rate is 20%, with more than half of these in the maxilla and occurring within weeks of surgery.

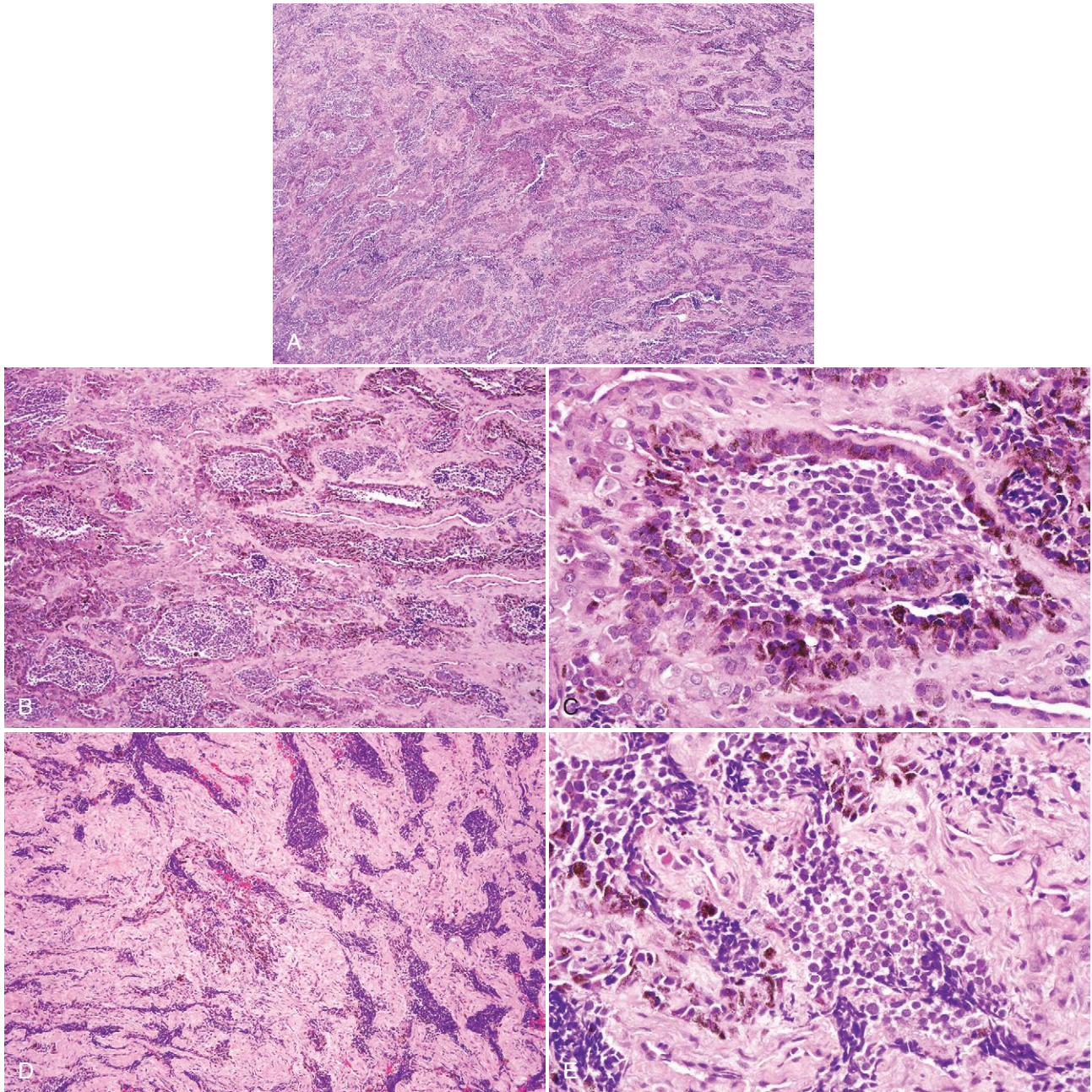
#### REFERENCES

- Barrett AW, Morgan M, Ramsay AD, et al. A clinicopathologic and immunohistochemical analysis of melanotic neuroectodermal tumor of infancy. *Oral Surg Oral Med Oral Pathol Oral Radiol Endod.* 2002;93:688-698.
- Chaudhary A, Wakhlu A, Mittal N, et al. Melanotic neuroectodermal tumor of infancy: 2 decades of clinical experience with 18 patients. *J Oral Maxillofac Surg.* 2009;67:47-51.
- Kruse-Losler B, Gaertner C, Burger H, et al. Melanotic neuroectodermal tumor of infancy: systematic review of the literature and presentation of a case. *Oral Surg Oral Med Oral Pathol Oral Radiol Endod.* 2006;102:204-216.



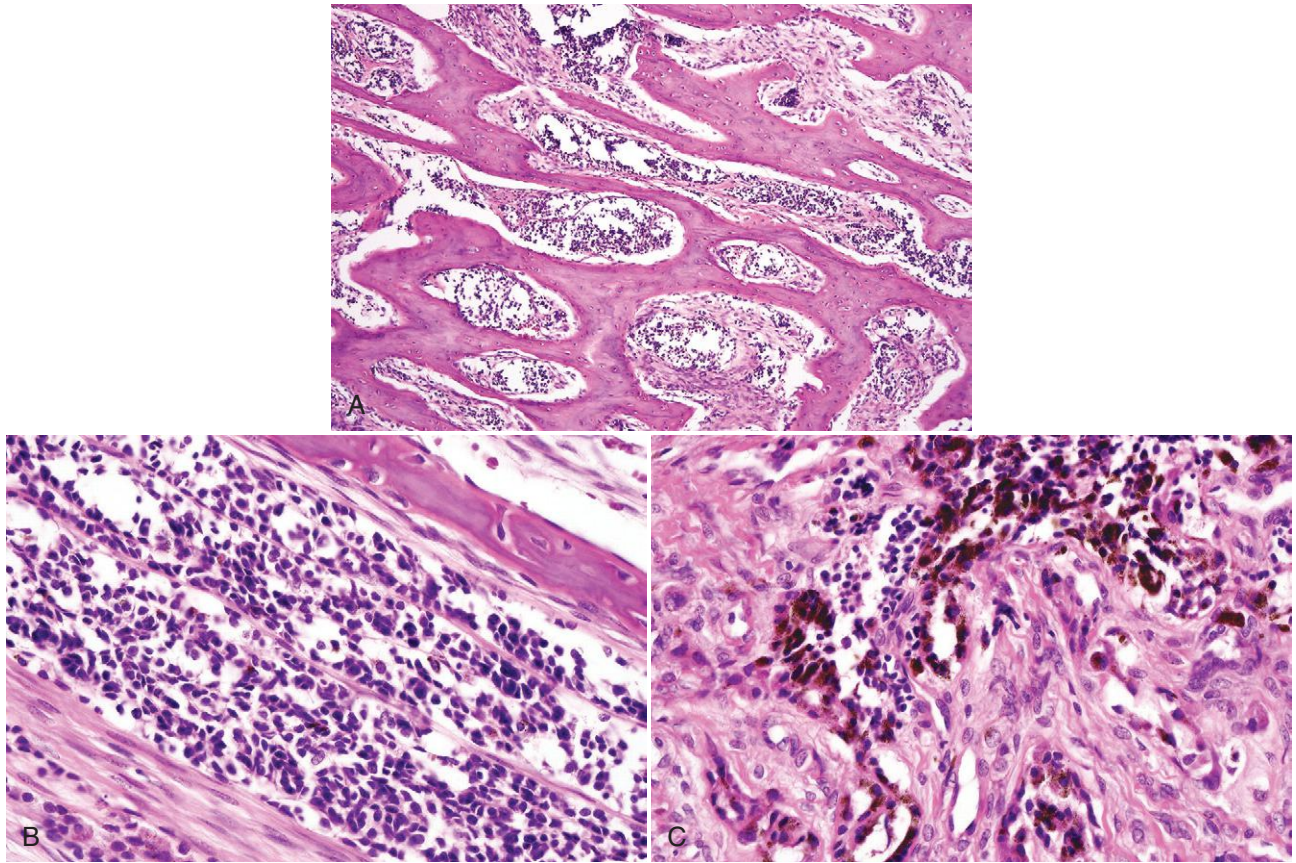
**FIGURE 9-36.** Melanotic neuroectodermal tumor of infancy: pigmented mass of the left maxillary alveolar ridge. (From Gonçalves CF, Costa NL, Oliveira-Neto HH, et al. Melanotic neuroectodermal tumor of infancy: report of 2 cases. *J Oral Maxillofac Surg.* 2010; 68:2344.)





**FIGURE 9-37.** Melanotic neuroectodermal tumor of infancy. **A**, Sheets of tumor cells with biphasic pattern. **B**, Islands of tumor cells, some of which are pigmented, within fibrous stroma. **C**, Larger epithelioid tumor cells with pale cytoplasm and large, pale nuclei contain melanin; smaller cells with dark nuclei do not. **D**, Areas with primarily hyperchromatic neuroblast-like cells. **E**, Small cells with hyperchromatic nuclei juxtaposed against larger cells, some of which contain melanin.





**FIGURE 9-38.** Melanotic neuroectodermal tumor of infancy. **A**, Small blue cell tumor extensively infiltrates bone. **B**, One population consists of neuroblast-like cells with occasional cells containing melanin. **C**, Biphasic population of darkly staining neuroblast-like cells and epithelioid cells containing melanin. (**A**, Courtesy of Dr. Harry Kozakewich, Harvard Medical School, Boston, Mass.)

# 10

## REACTIVE KERATOTIC LESIONS (NONLEUKOPLAKIAS)

### CHAPTER CONTENTS

WHITE LESIONS 210

REACTIVE LESIONS 210

Leukoedema 210

Contact Desquamation 213

FRictionAL/FACTITIAL KERATOSES 214

Morsicatio Mucosae Oris (Morsicatio Buccarum, Pathominia Mucosae Oris) 214

Benign Alveolar Ridge (Frictional) Keratosis (Oral Lichen Simplex Chronicus) 218

Nonspecific Benign Reactive Keratoses 221

TOBACCO-RELATED LESIONS 223

Smokeless Tobacco Lesion 223

Nicotinic Stomatitis (Stomatitis Nicotina) 226

SUBMUCOUS FIBROSIS 227

### White Lesions

White lesions are some of the more commonly biopsied lesions and one of the most challenging for general pathologists and dermatopathologists. This is particularly because of confusion over nomenclature (especially over the term *leukoplakia*) and difficulty recognizing oral frictional keratoses, the two most common being morsicatio mucosae oris and benign alveolar ridge keratosis. There are also other frictional/reactive keratoses that are not as well defined histologically. [Table 10-1](#) provides a list of mucosal conditions that are usually white; these are discussed subsequently and in other chapters.

The oral mucosa appears white for several reasons:

- Presence of keratin in a normally nonkeratinized site
- Hyperparakeratosis or hyperorthokeratosis in a normally keratinized site
- Coagulation of superficial keratinocytes
- Edema of keratinocytes
- Alteration of the epithelial cells because of abnormal keratin formation or aggregation (see [Chapter 2](#))
- Dysplasia (see [Chapter 11](#))
- Nonepithelial changes such as underlying scarring and fibrosis

When a mildly irritating substance comes in contact with the mucosa or when there is mild physical surface

trauma, superficial cells become edematous and degenerate until the effects of the irritation (contacting chemical or physical irritation) are diluted, beyond which the keratinocytes appear normal. Such changes are seen in leukoedema and morsicatio mucosae oris. Smokeless tobacco lesions in particular show this effect, although over time carcinogens from tobacco may result in significantly keratotic and dysplastic lesions. Aspirin, however, is so caustic that it leads to complete destruction of the epithelial layer, resulting in ulceration and necrosis rather than a keratotic lesion, although the earliest changes may be leukoedema. Irritant contact stomatitis results in a clinical erythematous lesion with spongiosis as its main histologic feature (see [Chapter 7](#)). Correlating the histopathologic and clinical findings is key to arriving at an accurate diagnosis.

### Reactive Lesions

#### LEUKOEDEMA

##### Clinical Findings

- Present in up to 90% of the population; more readily discerned in dark-skinned individuals; history of mild surface injury such as smoking, sucking, or use of strong oral rinses or toothpaste
- Delicate lacy, gray-white lines on the buccal mucosa or tongue (nonkeratinized site) that disappear with stretching ([Fig. 10-1](#))



**TABLE 10-1** Histologic Diagnoses for Papulomacular White Lesions

<b>Developmental/Hereditary</b>
Cannon white sponge nevus
Hereditary benign intraepithelial dyskeratosis
Oral pachyonychia congenita
Darier disease
<b>Reactive/Inflammatory</b>
<b>Chemical or Heat</b>
Leukoedema
Dentifrice-associated desquamation
Smokeless tobacco lesion
Nicotinic stomatitis
<b>Frictional/Factitial</b>
Morsicatio mucosae oris
Benign alveolar ridge keratosis (oral lichen simplex chronicus)
Frictional hyperparakeratosis at the edge of traumatic ulcers
Other frictional/factitial keratosis
<b>Immune-Mediated or Autoimmune</b>
Lichenoid stomatitis, lichenoid hypersensitivity reaction, or lichen planus
Lupus erythematosus
Chronic graft-versus-host disease
<b>Infectious</b>
Candidiasis
Hairy leukoplakia
Others (e.g., geotrichosis)
<b>Premalignant and Malignant</b>
Epithelial dysplasia
Carcinoma-in-situ
Atypical endophytic squamous proliferation
Verrucous hyperplasia
Squamous cell carcinoma
Verrucous carcinoma
<b>Fibrosis (Not Involving the Epithelium)</b>
Submucous fibrosis
Mucosal fibrosis in progressive systemic sclerosis

**Etiopathogenesis and Histopathologic Features**

Leukodema usually results from mildly irritating fluid substances (cigarette or marijuana smoke or dentifrice) in episodic contact with the mucosa; putative failure of injured cell to maintain sodium pump leads to ingress of water.

- Keratinocyte edema of superficial cells appear pale and ballooned; absent nuclei may be due to plane of section or degeneration; cell membranes have compacted “jigsaw” puzzle appearance; deeper cells show perinuclear halos (but do not represent koilocytes because they lack other nuclear characteristics); usually, minimal-to-no keratin is noted, although keratin chevrons may be present (Figs. 10-2 and 10-3).
- Benign epithelial hyperplasia with minimal-to-no inflammation may be seen.

**Differential Diagnosis**

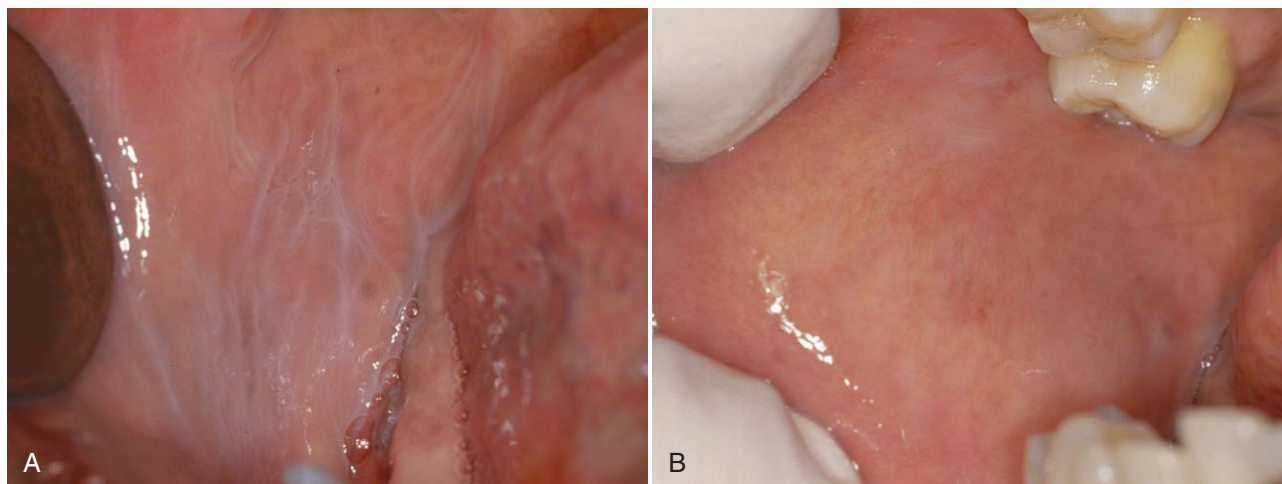
- Keratinocyte edema is seen in association with frictional/factitial keratoses.
- Hairy leukoplakia shows nuclear membrane condensations and Cowdry inclusion bodies.
- Koilocytic nuclei have irregular nuclear outlines and hyperchromasia.

**Management and Prognosis**

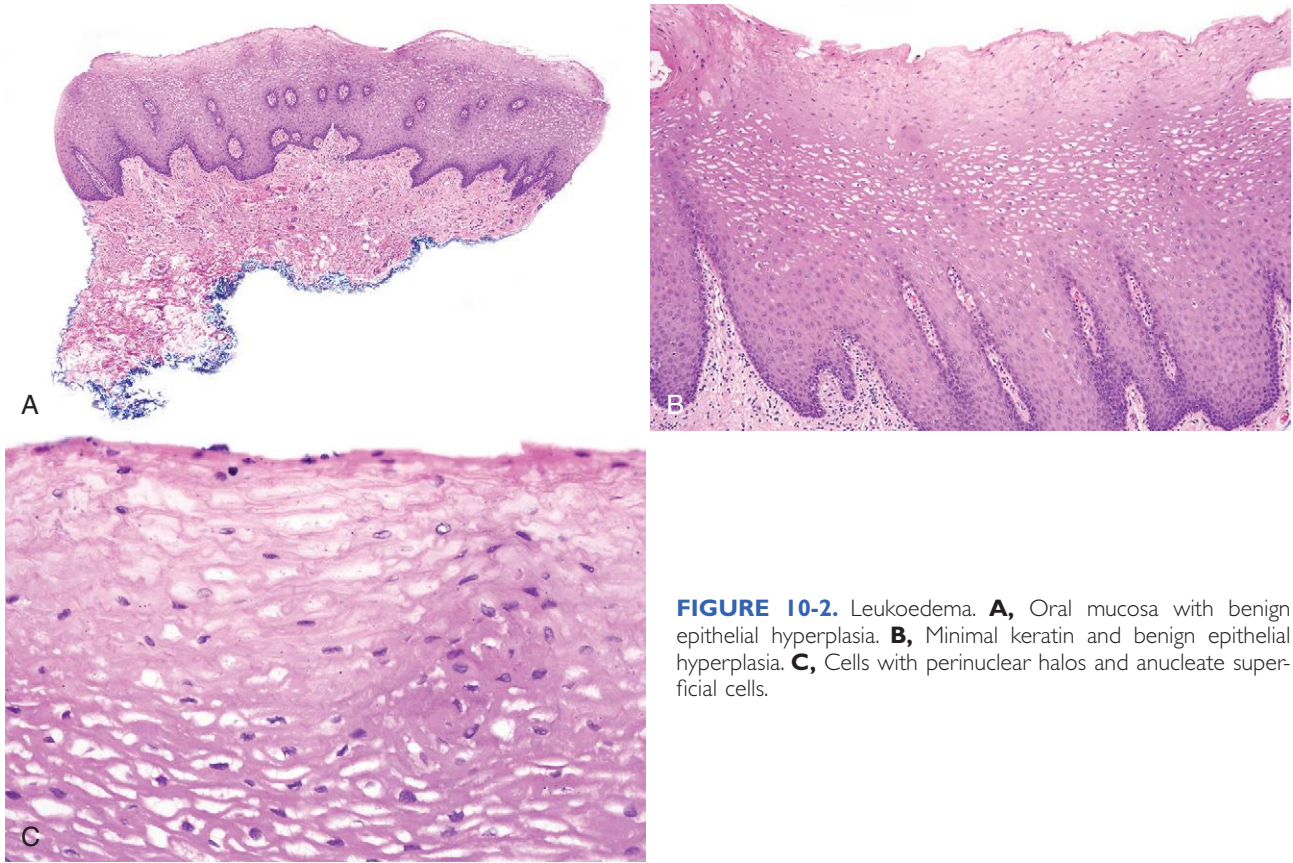
- No treatment is necessary for primary leukoedema.

**REFERENCES**

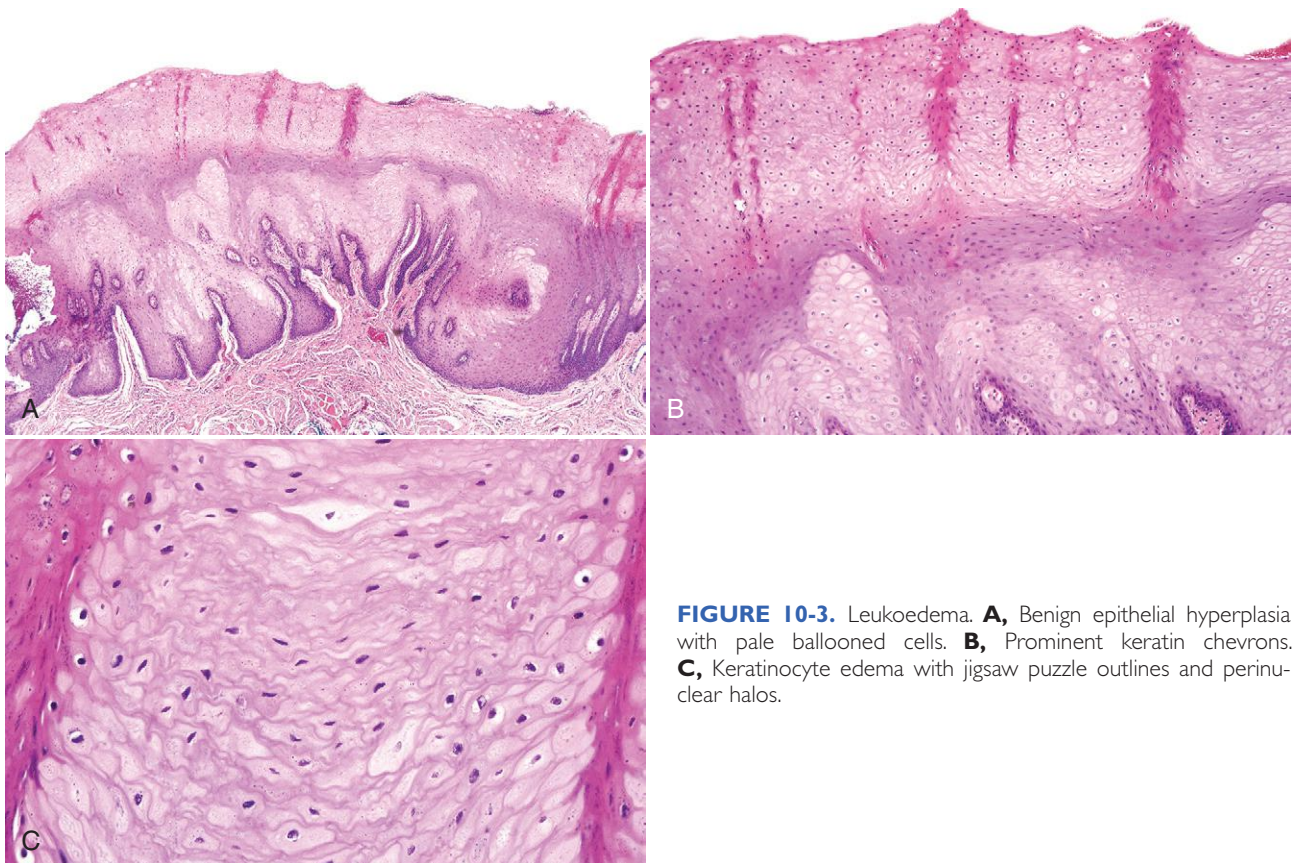
- Canaan TJ, Meehan SC. Variations of structure and appearance of the oral mucosa. *Dent Clin North Am.* 2005;49:1-14.
- Heyl T, Raubenheimer EJ. Sucking pads (sucking calluses) of the lips in neonates: a manifestation of transient leukoedema. *Pediatr Dermatol.* 1987;4:123-128.
- Versteeg PA, Slot DE, van der Velden U, van der Weijden GA. Effect of cannabis usage on the oral environment: a review. *Int J Dent Hyg.* 2008;6:315-320.



**FIGURE 10-1.** Leukoedema. **A**, Diffuse, filmy, slightly reticulated area of right buccal mucosa. **B**, Stretching the mucosa of the patient in **A** causes lesion to disappear.



**FIGURE 10-2.** Leukoedema. **A**, Oral mucosa with benign epithelial hyperplasia. **B**, Minimal keratin and benign epithelial hyperplasia. **C**, Cells with perinuclear halos and anucleate superficial cells.



**FIGURE 10-3.** Leukoedema. **A**, Benign epithelial hyperplasia with pale ballooned cells. **B**, Prominent keratin chevrons. **C**, Keratinocyte edema with jigsaw puzzle outlines and perinuclear halos.



## CONTACT DESQUAMATION

### Clinical Findings

- Painless, thready white fragments lie on the mucosa (usually nonkeratinized sites) that easily peel off, leaving normal mucosa (Fig. 10-4); surrounding leukoedema may be seen; patients may also develop contact cheilitis.

### Etiopathogenesis and Histopathologic Features

Condition results from caustic mouth washes high in alcohol content, strong toothpastes, or other contactants that are irritants but not strong enough to cause necrosis and ulceration.

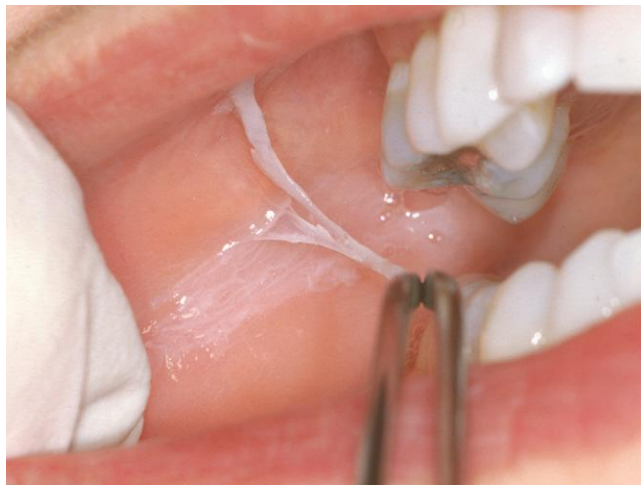- Strips of desquamated keratinocytes appear eosinophilic and coagulated (Figs. 10-5 and 10-6).

### Management

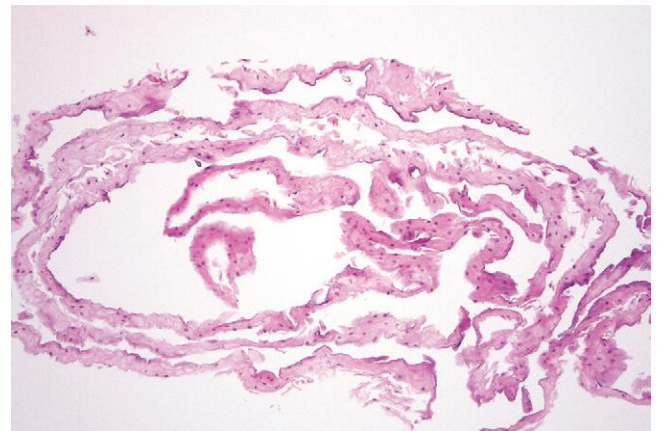
- Resolution on discontinuation of use of dentifrice

### REFERENCES

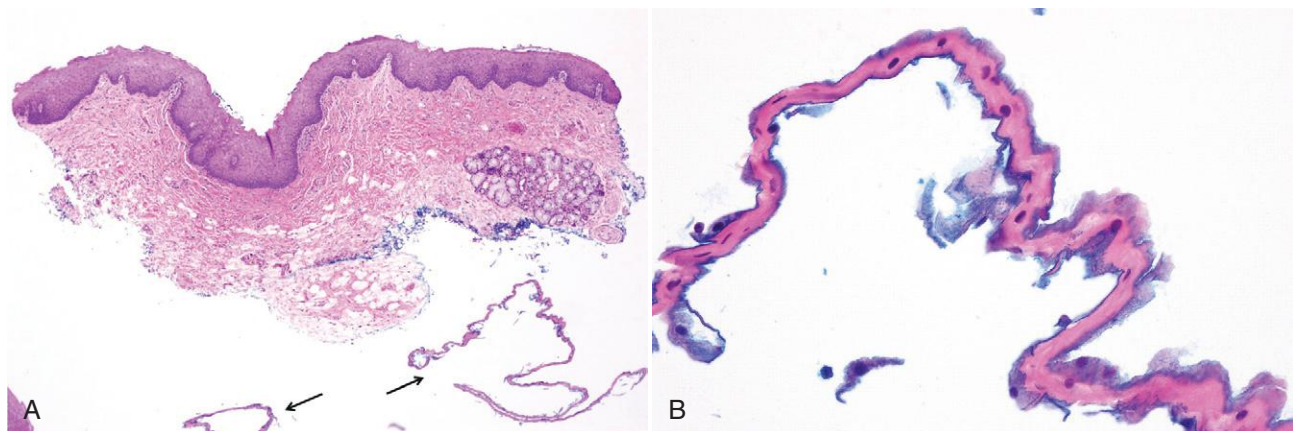
- Francalanci S, Sertoli A, Giorgini S, et al. Multicentre study of allergic contact cheilitis from toothpastes. *Contact Dermatitis*. 2000;43: 216-222.
- Kowitz G, Jacobson J, Meng Z, Lucatorto F. The effects of tartar-control toothpaste on the oral soft tissues. *Oral Surg Oral Med Oral Pathol*. 1990;70:529-536.
- Kuttan NA, Narayana N, Moghadam BK. Desquamative stomatitis associated with routine use of oral health care products. *Gen Dent*. 2001;49:596-602.



**FIGURE 10-4.** Dentifrice-induced desquamation: superficial keratinocytes are degenerated and peel off leaving normal-appearing mucosa.



**FIGURE 10-5.** Dentifrice-induced desquamation: tissue from patient shown in Figure 10-4.



**FIGURE 10-6.** Dentifrice-induced desquamation. **A**, Strips of epithelium (arrows) detached from the mucosa. **B**, Ribbons of coagulated keratinocytes.

## Frictional/Factitial Keratoses

The majority of hyperparakeratotic and hyperorthokeratotic lesions in the oral cavity are reactive, frictional keratoses. Two histologically well-defined frictional keratoses in the oral cavity are morsicatio mucosae oris (generally on the nonkeratinized mucosa) and benign alveolar ridge keratosis (lesions on the keratinized mucosa). The linea alba on the buccal mucosa is considered a variation of normal but is a severe localized leukoedema or a mild morsicatio mucosae oris (Fig. 10-7, A).

### MORSICATIO MUCOSAE ORIS (MORSICATIO BUCCARUM, PATHOMINIA MUCOSAE ORIS)

#### Clinical Findings

- Most common locations are close to the biting surfaces of the teeth, namely buccal mucosa, lateral/ventral tongue, and lower labial mucosa (rare on upper labial mucosa); more than 50% of patients are unaware of their habit (which may be nocturnal).
- Poorly demarcated papules and plaques often display a “shaggy,” sometimes papillary surface and may be associated with areas of erythema and ulceration, depending on severity of the parafunctional chewing habit (see Fig. 10-7, B-D).
- Chronic irritation of the mucosa against an oral appliance or other hard foreign object results in similar findings.

#### Etiopathogenesis and Histologic Features

Parafunctional habits such as raking of the teeth, prothesis, or other foreign object against the nonkeratinized mucosa results in these benign reactive keratotic lesions.

- Linea alba shows severe leukoedema (Fig. 10-8).
- Classic lesions show marked hyperparakeratosis with fissures and clefts often rimmed by bacteria (impetiginization); superficial keratinocytes exhibit intracellular edema (ballooned and anucleate, see Leukoedema earlier) (Figs. 10-9 and 10-10); the parakeratosis gradually diminishes toward the lateral edges (Fig. 10-11).
- Benign epithelial hyperplasia sometimes with surface papillomatosis is present; rete ridges are tapered; inflammation is usually absent unless ulcer is present; there may be “plasma pooling” (Figs. 10-12 to 10-14).

- Some lesions show only thin hyperparakeratosis and prominent keratinocyte edema (findings noted at the edges of classic lesions); rarely, *Candida* is identified unassociated with inflammation.

- Long-standing lesions may show focal hyperorthokeratosis similar to benign alveolar ridge keratosis (oral lichen simplex chronicus).

It is important that these lesions not be signed out as merely “hyperparakeratosis, acanthosis” because this relegates these lesions to the category of leukoplakia, a nonspecific diagnosis (see Chapter 11).

#### Differential Diagnosis

- Hairy tongue is characterized by hyperplastic filiform papillae, usually with many bacterial colonies (Fig. 10-15) (see Chapter 1, on normal tongue anatomy).
- Hairy leukoplakia usually shows sharp demarcation of the parakeratin from an underlying pale band of edematous keratinocytes; chromatin beading against the nuclear membrane, Cowdry inclusions, and identification of Epstein-Barr virus (EBV) in the keratinocytes are diagnostic elements.
- Verrucous hyperplasia with hyperparakeratosis usually shows prominent verrucous architecture, and the degrees of dysplasia may be minimal to severe; verrucous carcinoma has an endophytic and pronounced exophytic verrucous configuration and parakeratin clefting with bulbous, frondlike rete ridges.
- Any other papular/nodular lesion, such as a dysplasia or even a fibroma, may show overlying secondary frictional/factitial keratosis.

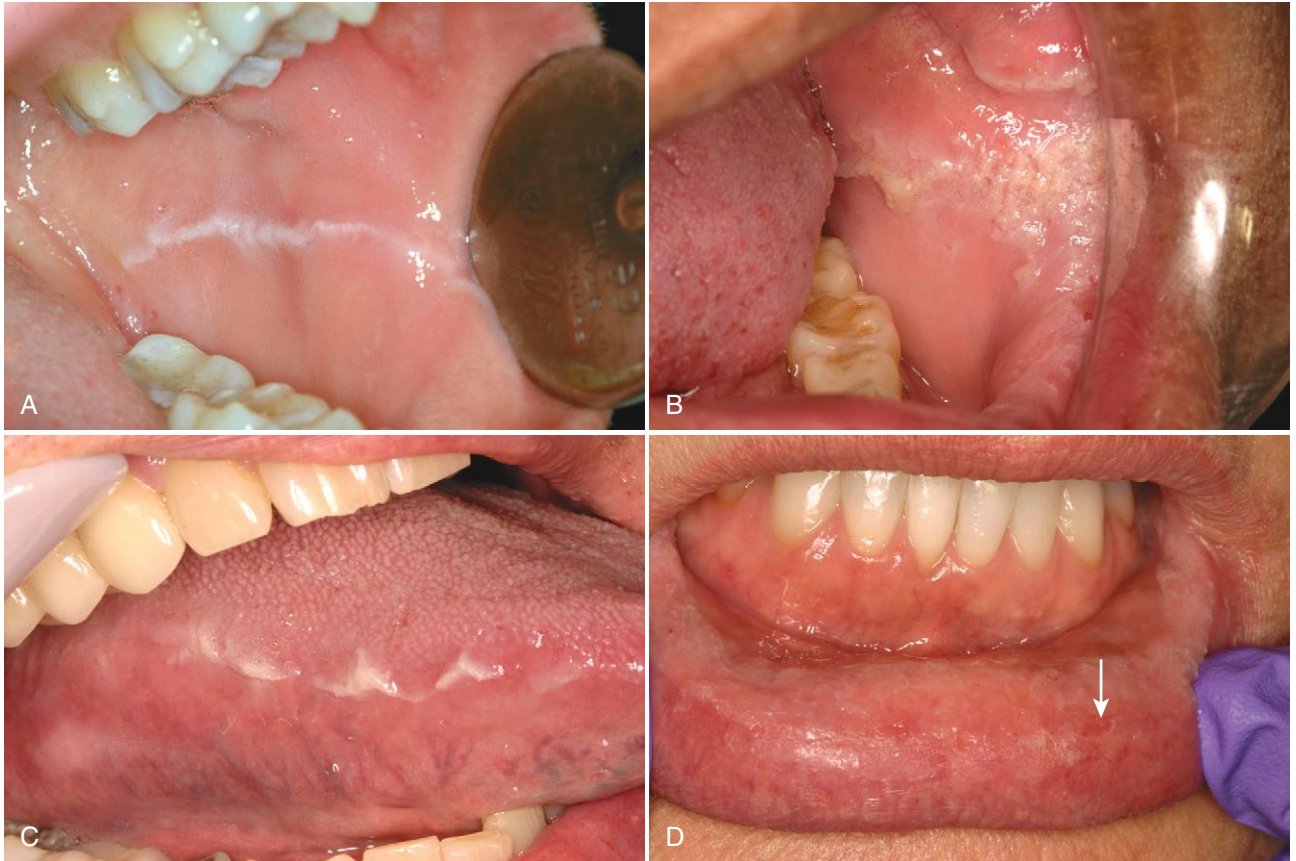#### Management and Prognosis

- Use of barrier devices to prevent patients from habitually chewing the mucosa is not helpful and often leads to raking of the mucosa against the appliance.
- Lesions have no malignant potential and do not require further management.

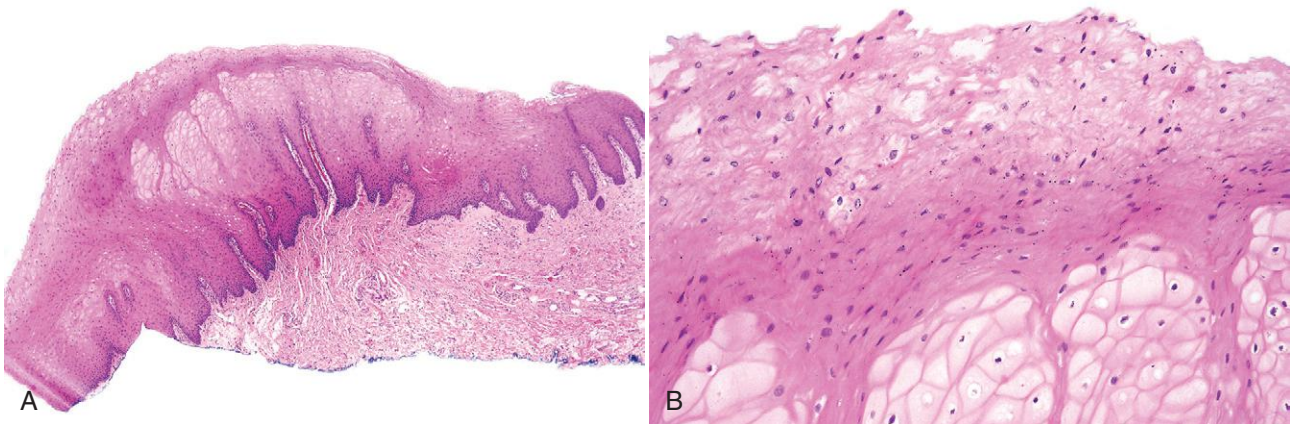
#### REFERENCES

- Glass LF, Maize JC. Morsicatio buccarum et labiorum (excessive cheek and lip biting). *Am J Dermatopathol*. 1991;13:271-274.
- Hjorting-Hansen E, Holst E. Morsicatio mucosae oris and suctio mucosae oris. *Scand J Dent Res*. 1970;78:492-499.
- Reichart PA, Philipsen HP. Betel chewer's mucosa—a review. *J Oral Pathol Med*. 1998;27:239-242.
- Woo SB, Lin D. Morsicatio mucosae oris—a chronic oral frictional keratosis, not a leukoplakia. *J Oral Maxillofac Surg*. 2009;67:140-146.



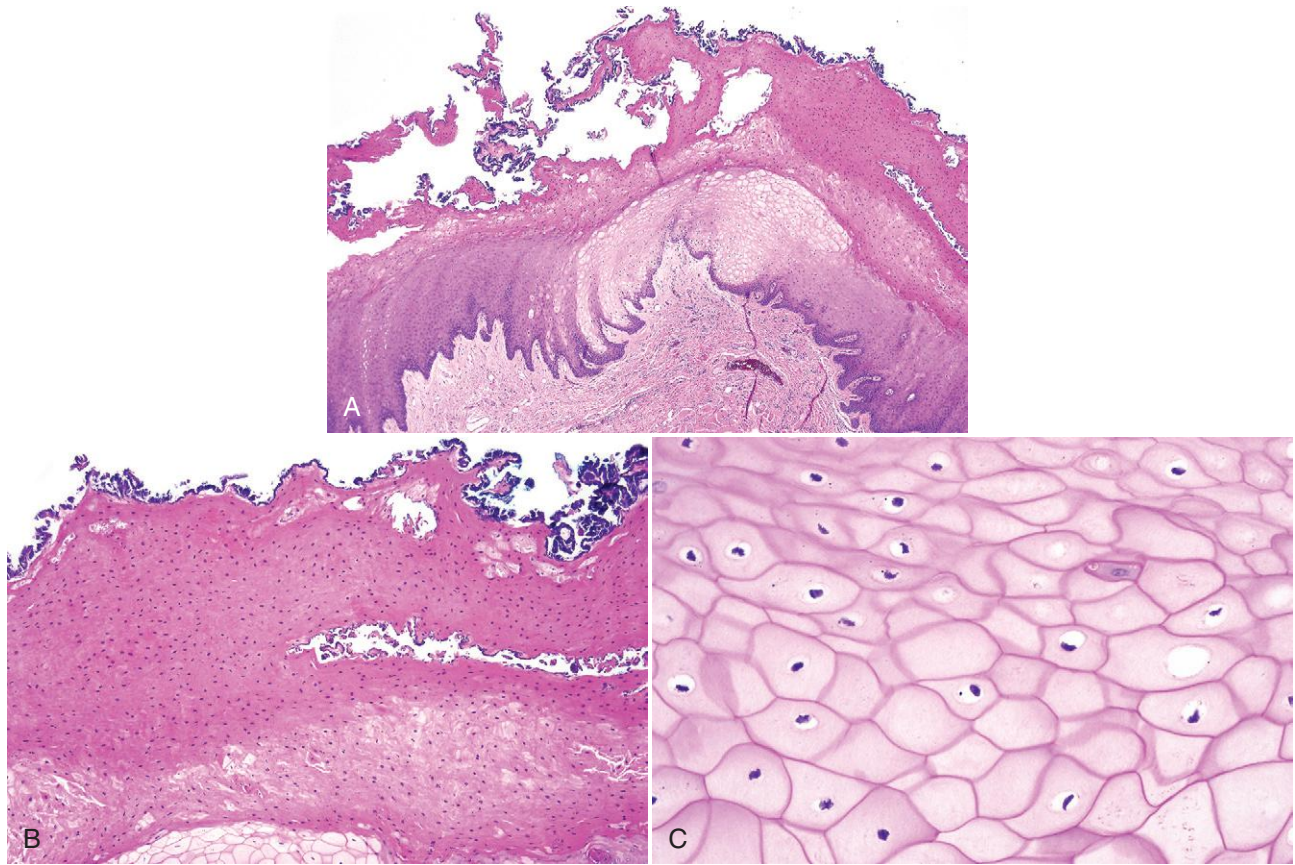


**FIGURE 10-7.** **A**, Linea alba; note slight reticulated leukoedema on either side. **B**, Morsicatio mucosae oris: poorly-demarcated yellowish white, macerated plaque that fades into normal mucosa. **C**, Morsicatio mucosae oris: white papules of right lateral tongue that fade into normal mucosa. **D**, Morsicatio mucosae oris of lower labial mucosa with irregular macerated papules and plaques and areas of erosion (arrow).

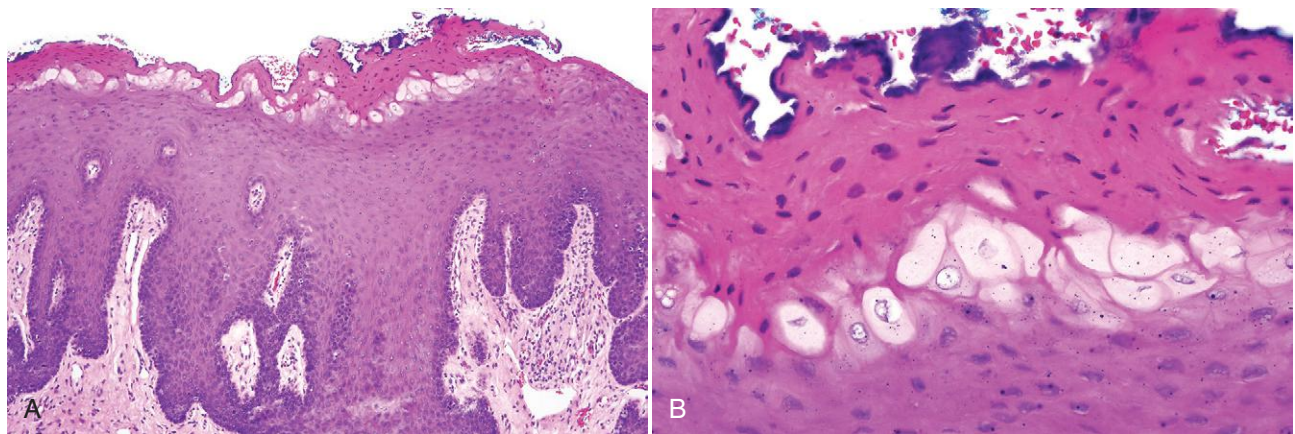


**FIGURE 10-8.** Linea alba. **A**, Benign epithelial hyperplasia and keratinocyte edema. **B**, Superficial cells with perinuclear halos are not koilocytes.



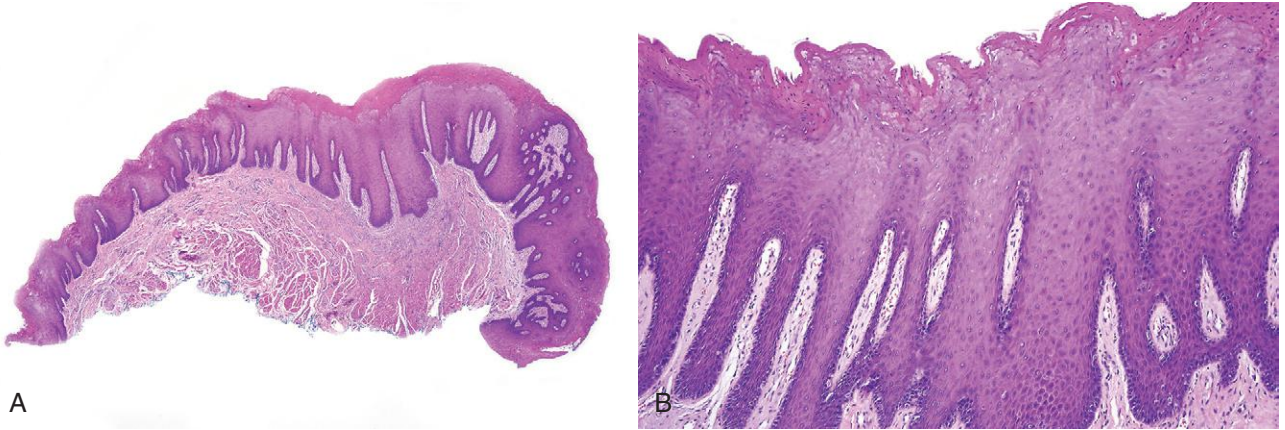


**FIGURE 10-9.** Morsicatio mucosae oris. **A**, Marked hyperparakeratosis with fissures and clefts rimmed by bacteria and keratinocyte edema. **B**, Marked parakeratosis with bacterial colonization and no inflammation. **C**, Prominent keratinocyte edema with degenerated nuclei (not koilocytes).

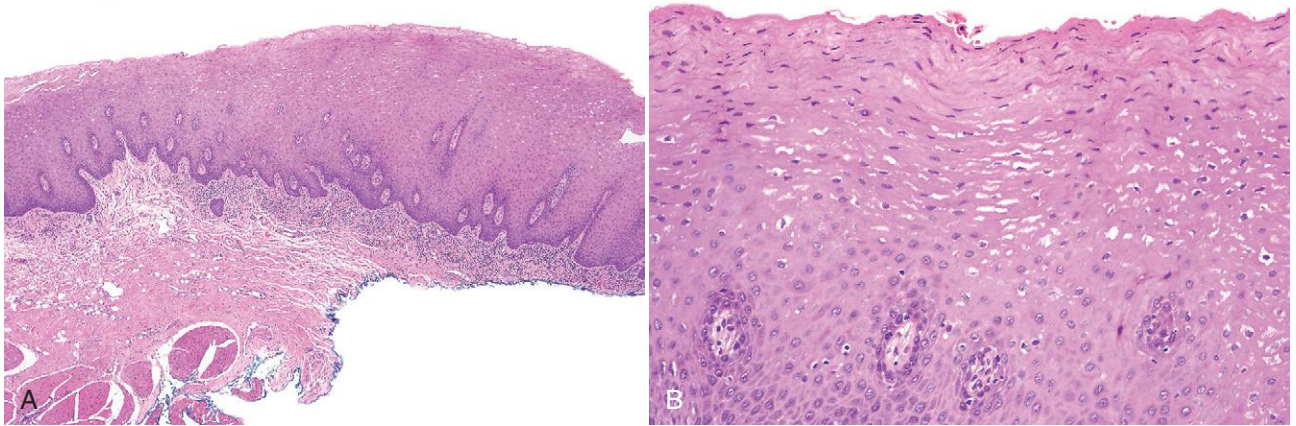


**FIGURE 10-10.** Morsicatio mucosae oris. **A**, Hyperparakeratosis and benign epithelial hyperplasia. **B**, Parakeratosis with bacterial colonies and keratinocyte edema.

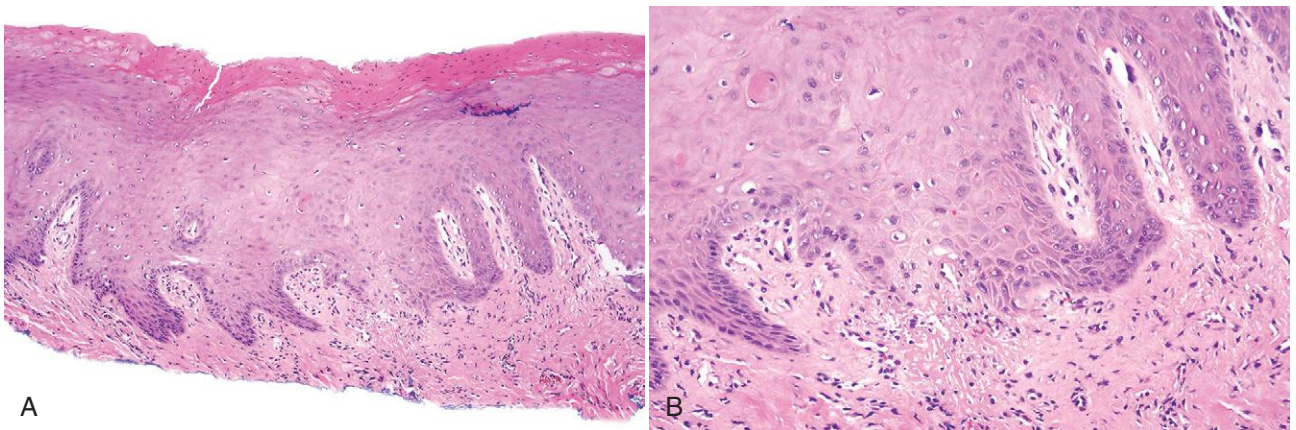




**FIGURE 10-11.** Morsicatio mucosae oris. **A**, Hyperparakeratosis that gradually decreases toward the edges and benign epithelial hyperplasia. **B**, Lateral areas showing only mild parakeratosis with slight surface papillomatosis.

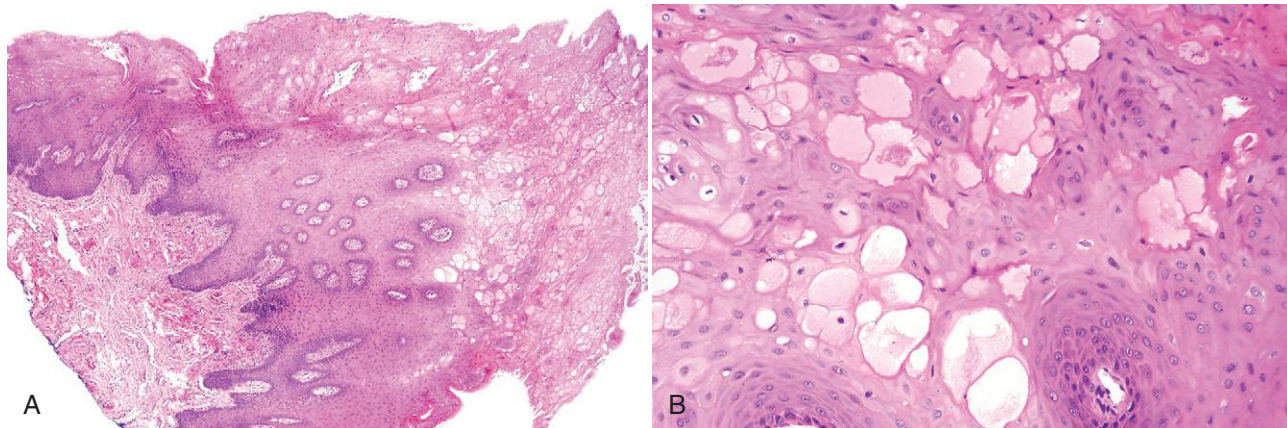


**FIGURE 10-12.** Morsicatio mucosae oris. **A**, Mild parakeratosis, benign epithelial hyperplasia, and chronic inflammation. **B**, Keratinocyte edema.

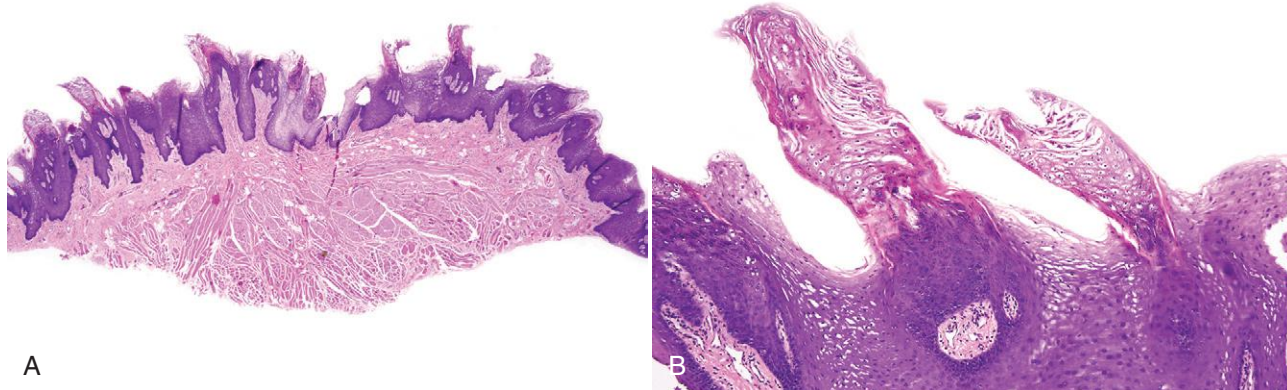


**FIGURE 10-13.** Morsicatio mucosae oris. **A**, Hyperparakeratosis and epithelial hyperplasia. **B**, Reactive atypia and healing ulcer (subepithelial fibrin deposition).





**FIGURE 10-14.** Morsicatio mucosae oris. **A**, Benign epithelial hyperplasia with plasma pooling from trauma. **B**, Plasma pooling between superficial keratinocytes.



**FIGURE 10-15.** Hairy tongue. **A**, Hyperplastic filiform papillae. **B**, Hyperplastic filiform papillae.

## BENIGN ALVEOLAR RIDGE (FRICTIONAL) KERATOSIS (ORAL LICHEN SIMPLEX CHRONICUS)

### Clinical Features

- Poorly demarcated white plaque of the keratinized mucosa of the retromolar pad, gingiva, and palate and particularly where teeth have been extracted (Fig. 10-16); often rough surface

### Etiopathogenesis and Histopathologic Features

This is likely caused by trauma of food being crushed against the gingiva or alveolar mucosa from the unopposed teeth and less often by direct impingement of the teeth on mucosa.

- Hyperorthokeratosis with wedge-shaped hypergranulosis and elongated and tapered rete ridges often confluent at the tips; surface of epithelium may have an undulating surface or be significantly papillary; thickness of keratin gradually decreases at the edge

of the lesion; inflammation is usually absent (Figs. 10-17 and 10-18).

- Occasionally, hyperparakeratosis may be seen, sometimes with bacterial colonies (Figs. 10-19 and 10-20).

### Differential Diagnosis

- Verrucous hyperplasia exhibits papillary or verrucous epithelial hyperplasia with varying degrees of epithelial dysplasia; clinical lesions are usually well demarcated.

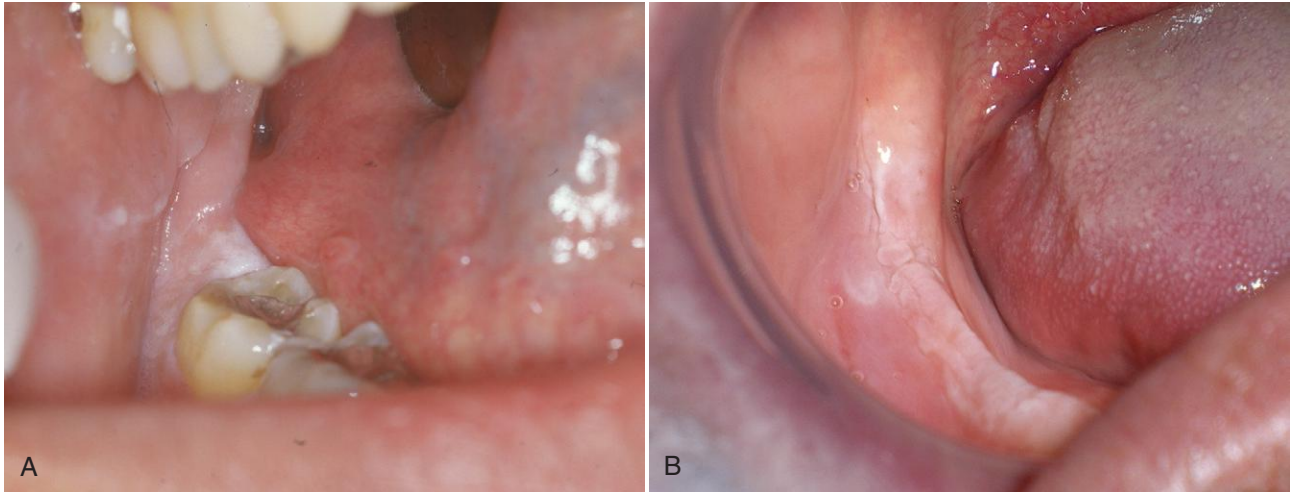
### Management and Prognosis

- No treatment is necessary, and there is no malignant potential.

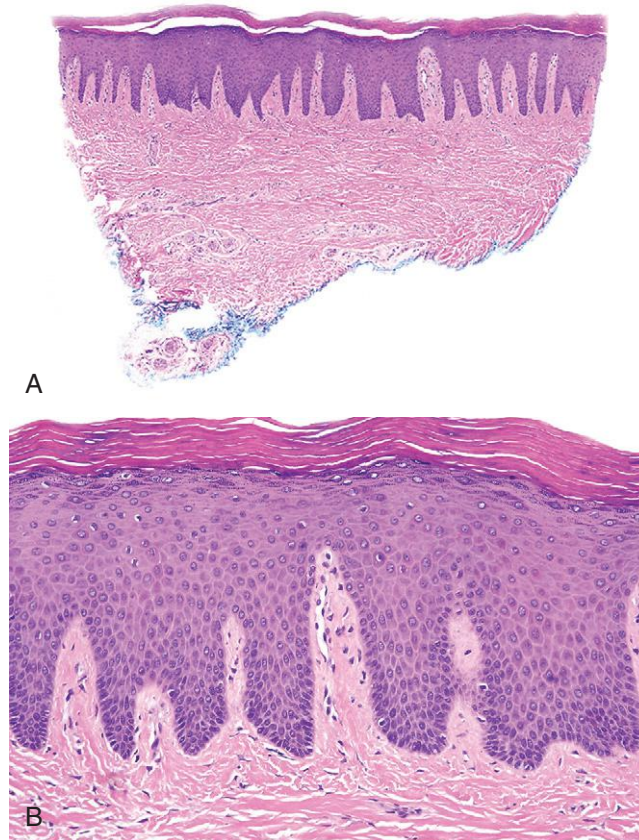
### REFERENCES

- Chi AC, Lambert PR 3rd, Pan Y, et al. Is alveolar ridge keratosis a true leukoplakia?: a clinicopathologic comparison of 2,153 lesions. *J Am Dent Assoc.* 2007;138:641-651.
- Natarajan E, Woo SB. Benign alveolar ridge keratosis (oral lichen simplex chronicus): a distinct clinicopathologic entity. *J Am Acad Dermatol.* 2008;58:151-157.

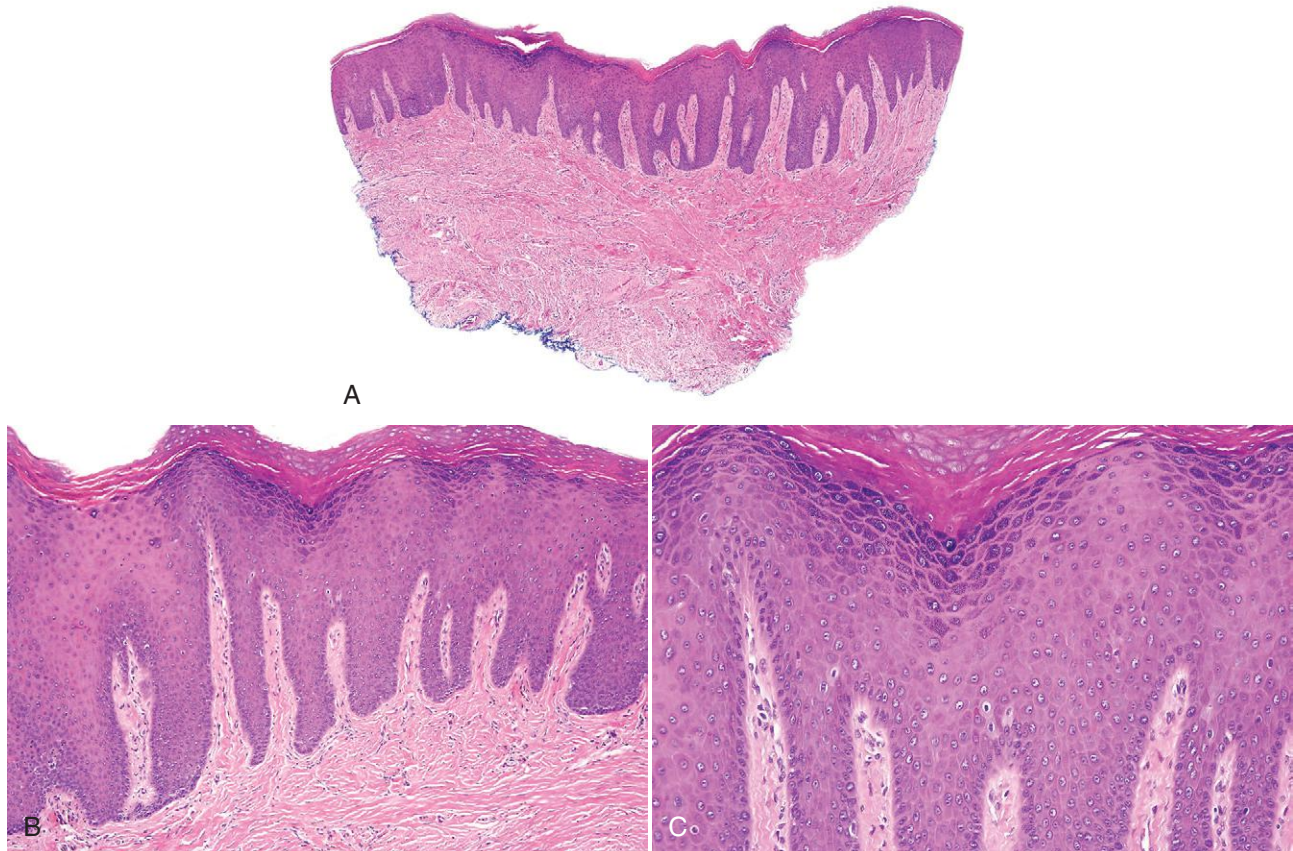




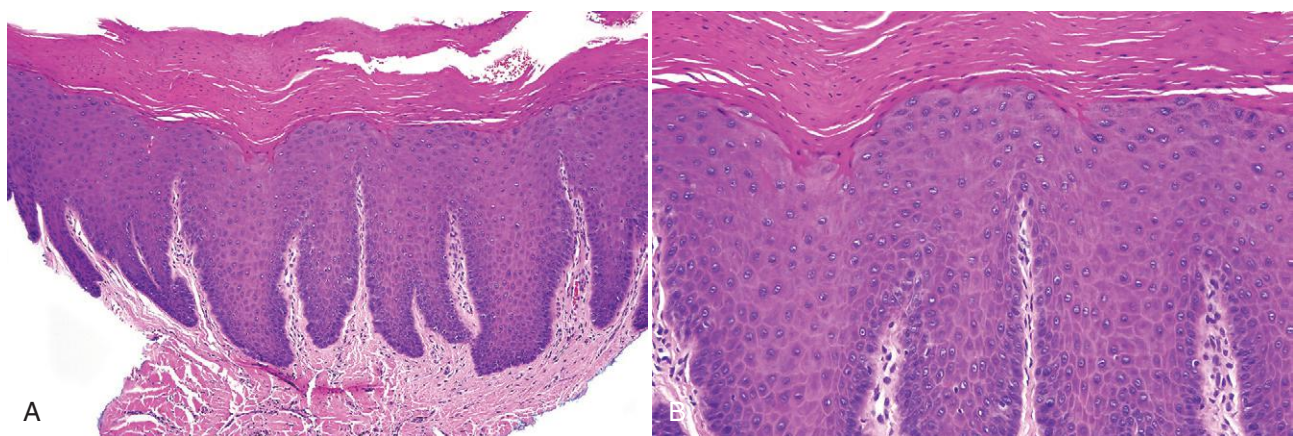
**FIGURE 10-16.** **A**, Benign alveolar ridge keratosis of the right retromolar pad: note the chronic frictional keratosis of the buccal mucosa and poor demarcation. **B**, Benign alveolar ridge keratosis of the right edentulous mandible: poorly demarcated white lesion, which was bilateral, under a denture. (Courtesy of Dr. Mary Grote, Beaver Dam, Wisc.)



**FIGURE 10-17.** Benign alveolar ridge keratosis, mild. **A**, Hyperorthokeratosis and long, tapered rete ridges. **B**, Benign epithelial hyperplasia.

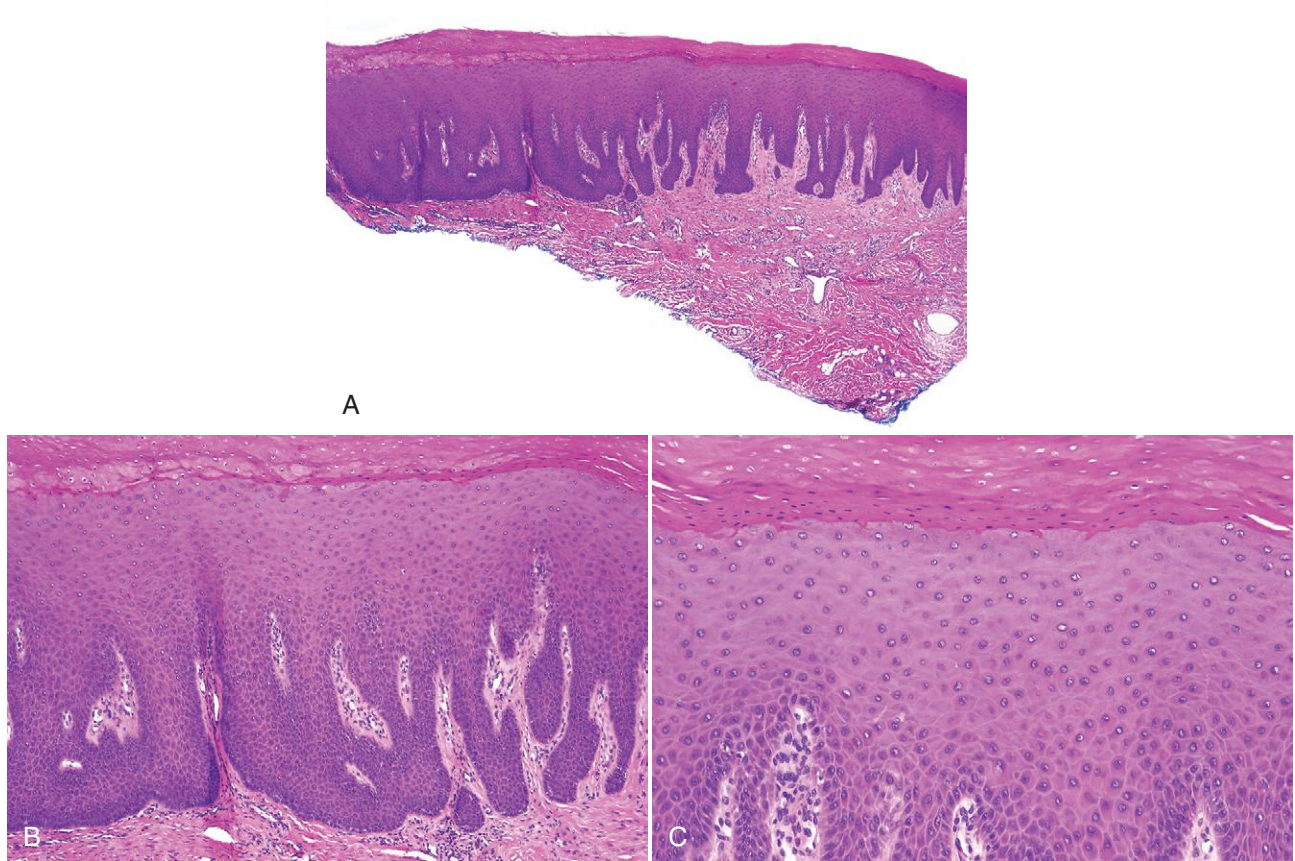


**FIGURE 10-18.** Benign alveolar ridge keratosis. **A**, Hyperorthokeratosis (less keratotic at the lateral edges), slight papillomatosis and long, tapered rete ridges. **B**, Hyperorthokeratosis, wedge-shaped hypergranulosis, and tapered rete ridges. **C**, Wedge-shaped hypergranulosis and no epithelial atypia.



**FIGURE 10-19.** Benign alveolar ridge keratosis. **A**, Hyperparakeratosis and long, tapered rete ridges with mild vascular ectasia suggestive of previous inflammation. **B**, Hyperparakeratosis and benign epithelial hyperplasia.





**FIGURE 10-20.** Benign alveolar ridge keratosis. **A**, Hyperparakeratosis and orthokeratosis, benign epithelial hyperplasia, and mild chronic inflammation. **B**, Hyperparakeratosis and orthokeratosis with elongated rete ridges confluent at the tips. **C**, Benign epithelial hyperplasia.

## NONSPECIFIC BENIGN REACTIVE KERATOSES

### Clinical Findings

- White lesion, not well demarcated; present at any site, but often at sites of trauma

### Etiopathogenesis and Histopathologic Features

These keratotic lesions do not show the typical histologic features of well-defined keratotic entities, and they may represent waxing or waning specific keratotic diseases, such as lichen planus, healing ulcers, or frictional keratoses such as morsicatio mucosae oris or benign alveolar ridge keratosis.

- Hyperparakeratosis or hyperorthokeratosis diminishes at the periphery where it meets normal mucosa; epithelial hyperplasia forms tapered rete ridges; variable chronic inflammation and vascular ectasia; some

reactive epithelial atypia is evident; subepithelial fibrin may be present (Figs. 10-21 to 10-24).

- When rendering a diagnosis, the phrase *likely reactive* should be added to *hyperkeratosis*, *acanthosis*, and *chronic inflammation* because this helps with patient management.

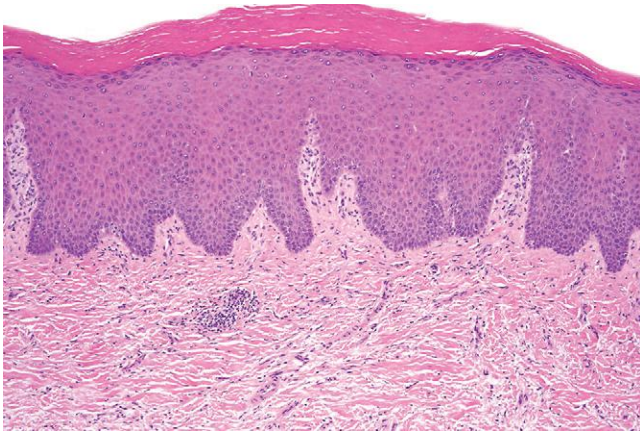
### Differential Diagnosis

- Early dysplasia must be ruled out, especially if the clinical lesion is well-demarcated and situated at a high-risk site for dysplasia and oral cancer.

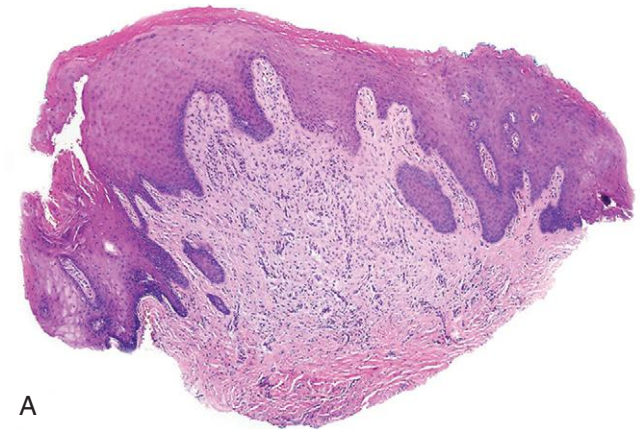
### Management and Prognosis

- Removal of possible contact irritants and follow-up with repeat biopsy.
- Excision should be considered if the lesion is well-demarcated and at a high-risk site (if this can be achieved without excessive morbidity).

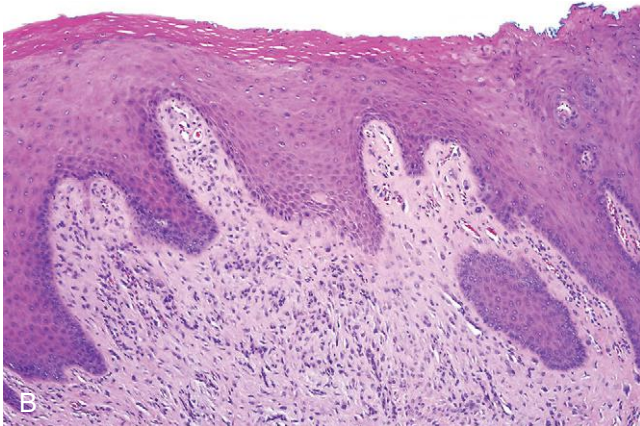




**FIGURE 10-21.** Likely frictional/reactive keratosis: hyperorthokeratosis, benign epithelial hyperplasia, and mild chronic inflammation, which is likely an early benign alveolar ridge keratosis.

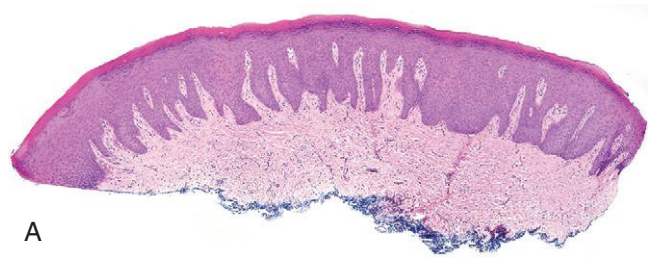

**A**

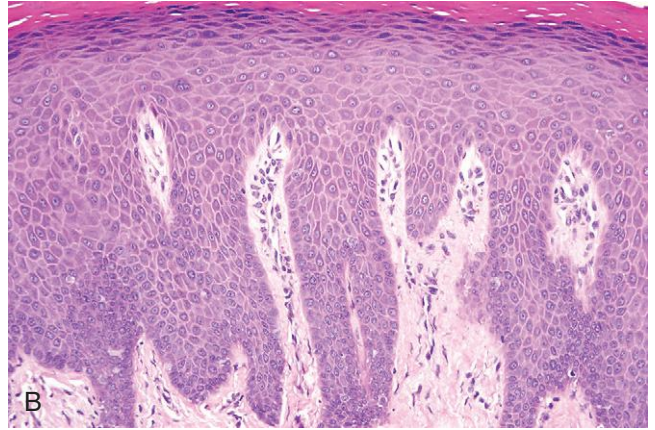


**B**

**FIGURE 10-22.** Reactive keratosis. **A**, Hyperorthokeratosis that diminishes toward the right lateral edge. **B**, Mild focal reactive atypia; this may be the edge of a healing ulcer because of focal squamatization of basal cells and presence of granulation tissue.

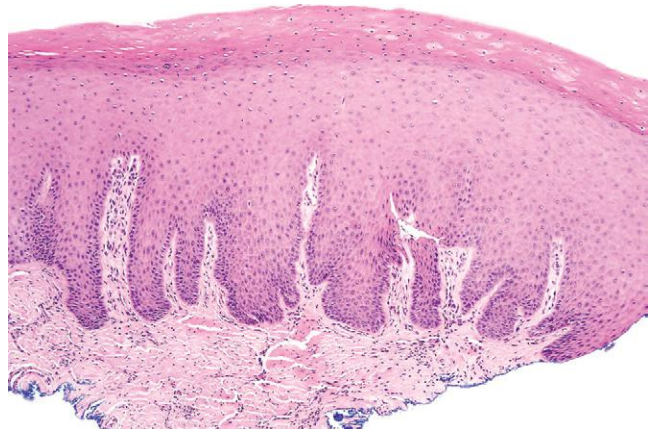

**A**



**B**

**FIGURE 10-23.** Likely frictional/reactive keratosis. **A**, Hyperorthokeratosis and benign epithelial hyperplasia forming tapered and confluent rete ridges. **B**, Benign epithelial hyperplasia.



**FIGURE 10-24.** Likely frictional/reactive keratosis: hyperparakeratosis, epithelial hyperplasia with mild reactive atypia, and mild vascular ectasia.



## Tobacco-Related Lesions

### SMOKELESS TOBACCO LESION

Smokeless tobacco (either fine snuff or coarser chewing tobacco) has different composition in different countries: in general, moist Swedish snuff (“snus”) is lower in tobacco-associated nitrosamines than American moist or dry snuff but has higher alkalinity (pH 8 to 9) and greater tendency to cause mucosal damage. Toombak from Ethiopia has the highest levels of nitrosamines; smokeless tobacco is often mixed with spices and areca nut (gutka or paan) in many Asian countries (see Submucous Fibrosis later). There is interest in using smokeless tobacco in “risk reduction” smoking cessation programs because the risk of oral cancer is much lower when compared with cigarette smoking.

#### Clinical Findings

- Early lesions are poorly demarcated, uniform gray-white, and edematous with wrinkles and parallel ridges and fissures in the area where the tobacco is placed; teeth may show staining, gingival recession, and root exposure; lesions are usually reversible on stopping the habit (Fig. 10-25).
- More advanced lesions are dense, well-demarcated, keratotic plaques; these areas must be biopsied for evaluation of dysplasia, and the lesions are unlikely to be reversible.

#### Etiopathogenesis and Histopathologic Features

Smokeless tobacco lesions are caused by contact with caustic agents within the tobacco. Long-standing lesions occur from carcinogens within the tobacco and are essentially lesions of leukoplakia (see Chapter 11).

- Early lesions: slight parakeratosis with prominent keratinocyte edema of superficial cells that stops abruptly; karyopyknosis is common; keratin “chevrons” often are seen, but this is not specific to this

condition (see Leukoedema earlier); epithelial hyperplasia is present with minimal reactive atypia and variable chronic inflammation (Figs. 10-26, A and B and 10-27).

- May see amorphous amyloid-like eosinophilic deposits in the lamina propria and within minor salivary gland parenchyma (see Fig. 10-26, C).
- More advanced keratotic lesions exhibit hyperparakeratosis or orthokeratosis with or without dysplasia (see Chapter 11; Fig. 10-28).

#### Differential Diagnosis

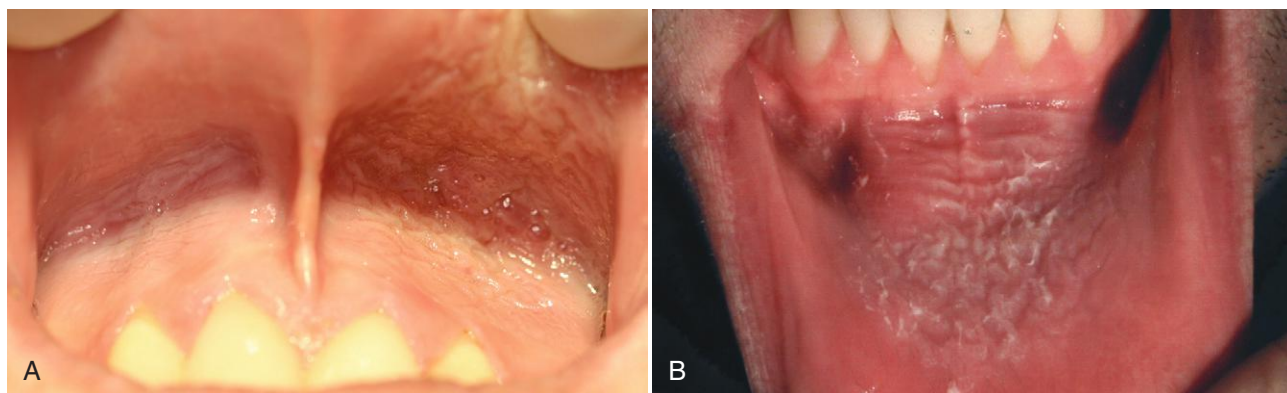
- Other contact lesions may have similar histopathologic features.

#### Management and Prognosis

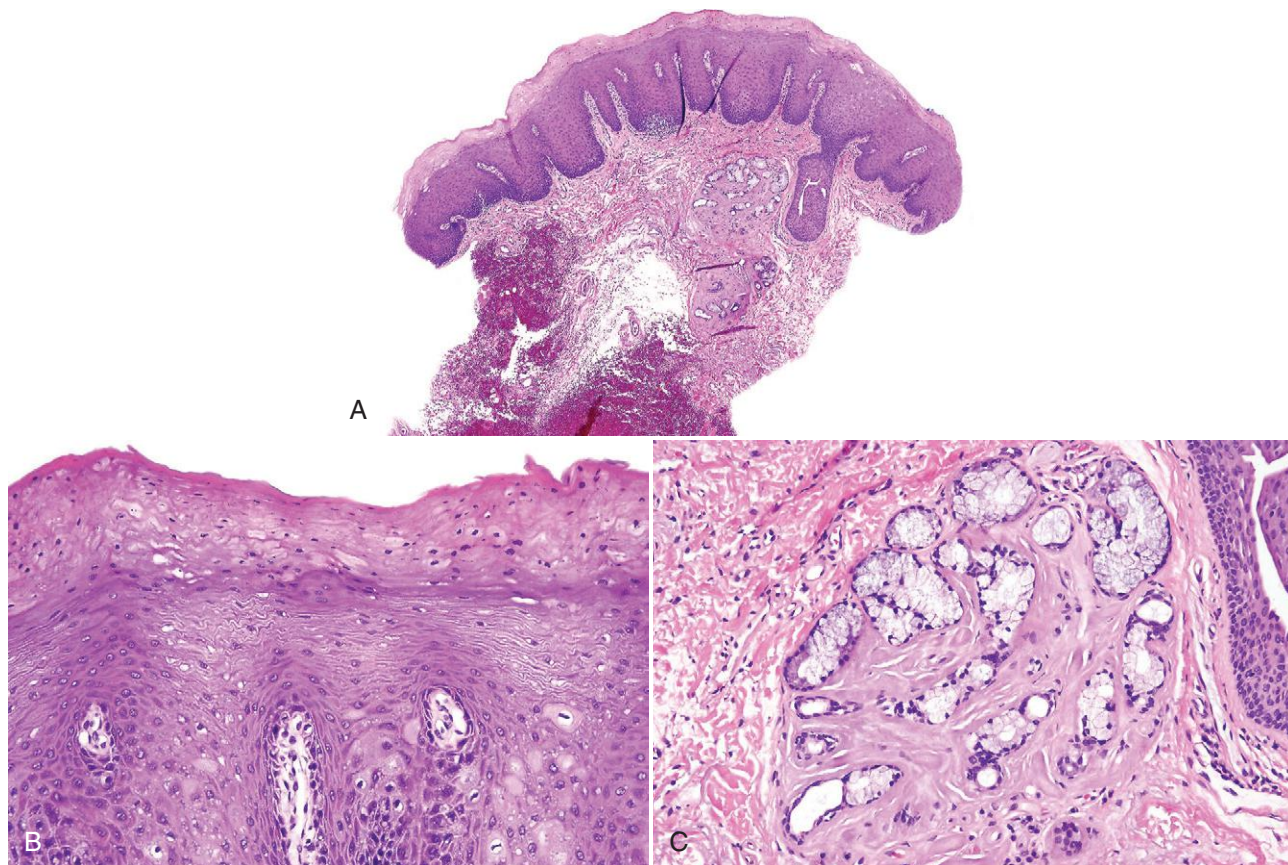
- Early lesions generally resolve if the habit is discontinued.
- Hyperkeratotic lesions should be regularly evaluated for dysplasia or excised/ablated with discontinuation of habit.

#### REFERENCES

- Andersson G, Axell T, Larsson A. Histologic changes associated with the use of loose and portion-bag packed Swedish moist snuff: a comparative study. *J Oral Pathol Med.* 1989;18:491-497.
- Daniels TE, Hansen LS, Greenspan JS, et al. Histopathology of smokeless tobacco lesions in professional baseball players. Associations with different types of tobacco. *Oral Surg Oral Med Oral Pathol.* 1992;73:720-725.
- Hirsch JM, Heyden G, Thilander H. A clinical, histomorphological and histochemical study on snuff-induced lesions of varying severity. *J Oral Pathol.* 1982;11:387-398.
- Idris AM, Warnakulasuriya KA, Ibrahim YE, et al. Characterization of an amorphous deposit in the lamina propria in oral snuff users in the Sudan as collagen. *J Oral Pathol Med.* 1998;27:157-162.
- Kallischnigg G, Weitkunat R, Lee PN. Systematic review of the relation between smokeless tobacco and non-neoplastic oral diseases in Europe and the United States. *BMC Oral Health.* 2008;8:13.
- Warnakulasuriya KA, Ralhan R. Clinical, pathological, cellular and molecular lesions caused by oral smokeless tobacco—a review. *J Oral Pathol Med.* 2007;36:63-77.

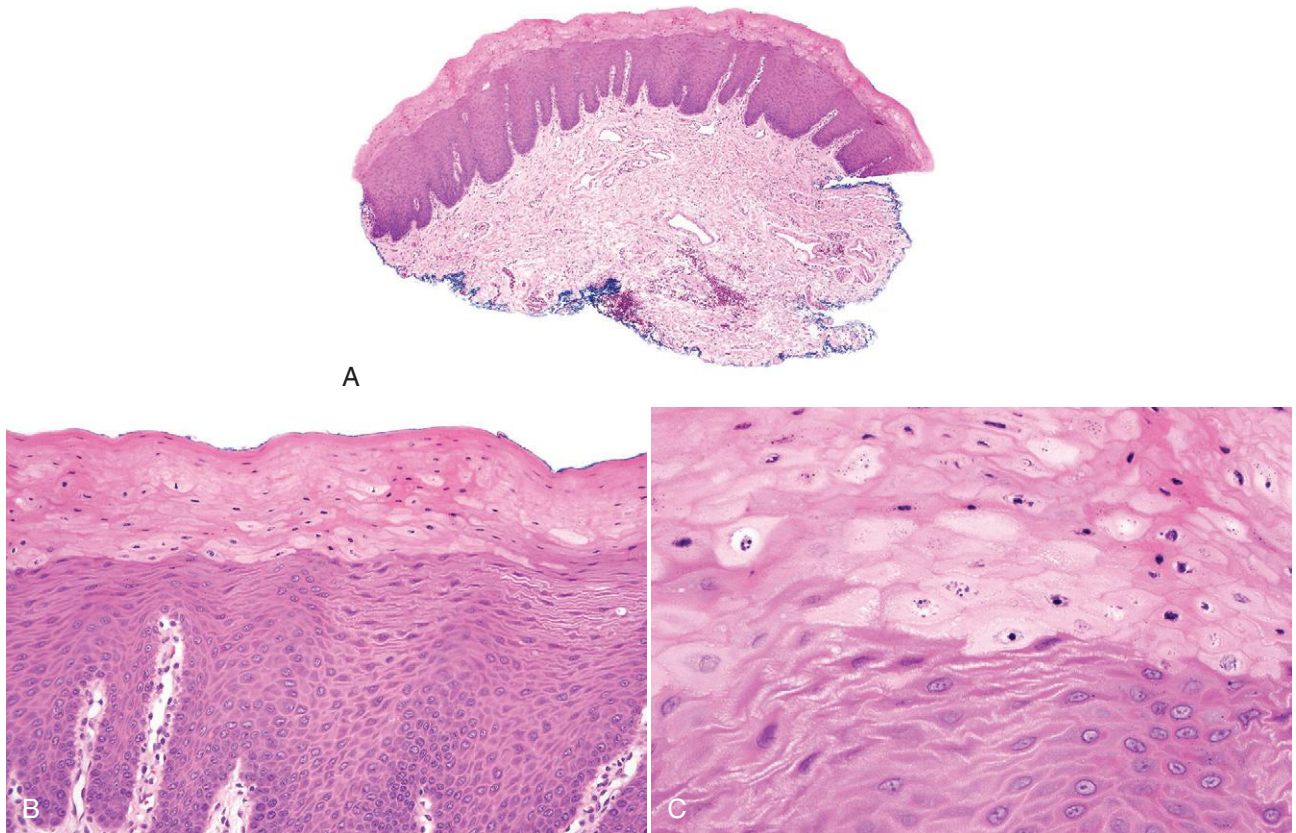


**FIGURE 10-25.** Smokeless tobacco lesion. **A**, Typical wrinkled and ridged, poorly-demarcated gray-white lesion of the vestibule where tobacco is placed. **B**, Typical wrinkled and ridged, poorly demarcated gray-white lesion of the vestibule where tobacco is placed. (Courtesy of Dr. Sherwin Kershman, Houston, Tex.)

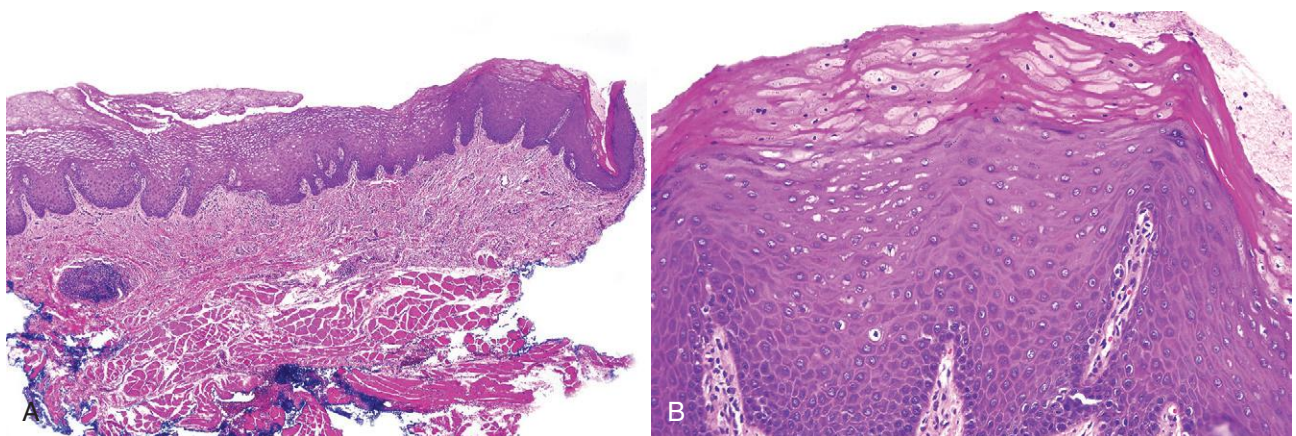


**FIGURE 10-26.** Smokeless tobacco lesion. **A**, Oral mucosa with well-demarcated area of degenerated keratinocytes and salivary gland involvement. **B**, Very thin layer of parakeratin on the surface and thick band of degenerated keratinocytes, with nuclear karyopyknosis. **C**, Salivary glands containing amyloid-like material.





**FIGURE 10-27.** Smokeless tobacco lesion. **A**, Oral mucosa with subtle keratin chevrons and demarcated area of degenerated keratinocytes. **B**, Pale band of degenerated keratinocytes and no epithelial atypia. **C**, Karyopyknosis within edematous keratinocytes.



**FIGURE 10-28.** Smokeless tobacco lesion. **A**, Keratotic later lesion: oral mucosa exhibiting early lesion on the *left* and more advanced keratotic lesion on the *right*. **B**, Moderate hyperparakeratosis-orthokeratosis with benign epithelial hyperplasia and mild chronic inflammation.

## NICOTINIC STOMATITIS (STOMATITIS NICOTINA)

### Clinical Findings

- Symmetric, usually painless involvement of the hard palate, and sometimes the soft palate; mucosa with a white cast (variable in intensity depending on severity of disease) within which are scattered red punctate papules (Fig. 10-29)

### Etiopathogenesis and Histopathologic Features

This is a form of reactive keratosis caused by heat (not nicotine) usually from pipe smoking, although it may also occur in heavy cigarette smokers, “reverse smokers” (those who smoke with the lit end of the cigarette in their mouths), and those who frequently drink very hot beverages.

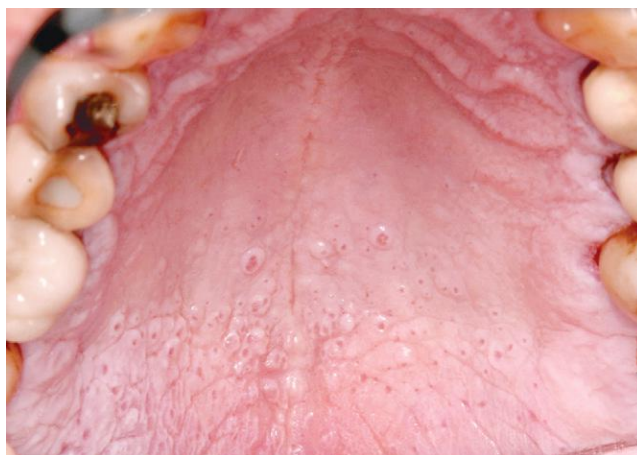- Hyperorthokeratosis or parakeratosis, benign epithelial hyperplasia, with or without reactive epithelial atypia, and variable chronic inflammation; squamous metaplasia of excretory salivary ducts and chronic sialodochitis (periductal inflammation) (Fig. 10-30).

### Management and Prognosis

- Early mucosal changes are generally reversible on stopping the habit.

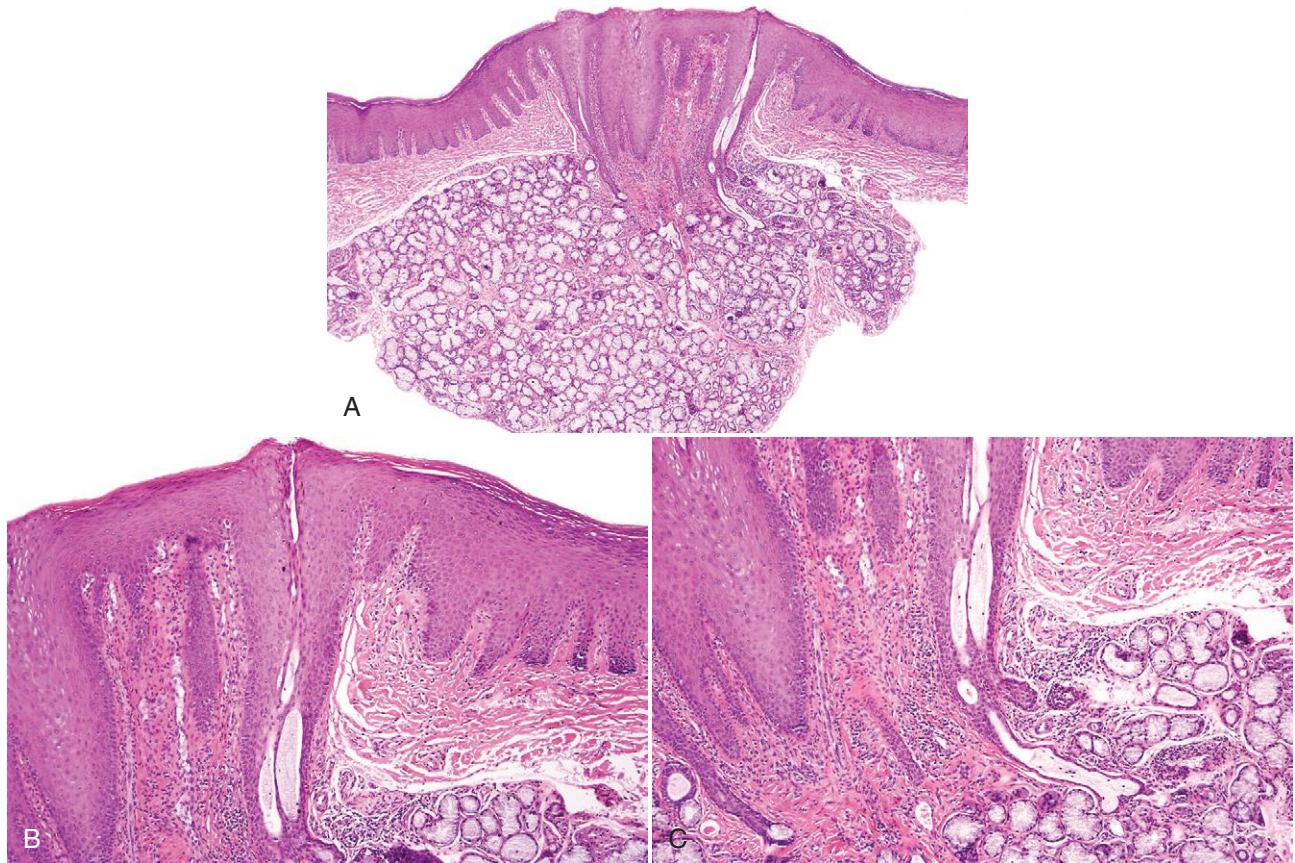
### REFERENCES

- dos Santos RB, Katz J. Nicotinic stomatitis: positive correlation with heat in maté tea drinks and smoking. *Quintessence Int.* 2009;40:537-540.
- Reddy CR, Kameswari VR, Ramulu C, Reddy PG. Histopathological study of stomatitis nicotina. *Br J Cancer.* 1971;25:403-410.
- Reddy CRRM, Raju MVS, Ramulu C, Reddy PG. Changes in the ducts of the glands of the hard palate in reverse smokers. *Cancer.* 1972;30:231-238.



**FIGURE 10-29.** Nicotinic stomatitis. (Courtesy of Dr. Linda Lee, Princess Margaret Hospital, Toronto, Canada.)





**FIGURE 10-30.** Nicotinic stomatitis. **A**, Hyperorthokeratosis and squamous metaplasia of ducts forming a raised papule. **B**, Hyperorthokeratosis, parakeratosis, and squamous metaplasia of ducts with periductal chronic inflammation. **C**, Periductal and parenchymal chronic inflammation of glands.

## Submucous Fibrosis

Submucous fibrosis is a premalignant condition seen in areca nut and betel leaf chewers, a practice common in India, parts of South East Asia, and Taiwan. It is included in this chapter because the mucosa appears white, although this is a result of underlying fibrosis rather than significant keratosis.

### Clinical Findings

- Diffuse, pale, marblelike but not keratotic areas are on the buccal mucosa, soft palate, and tongue in patients who chew areca nut; late lesions have typical “piano wire” feel to the mucosa from fibrous bands; erythema and ulcers may be present; appearance of leukoplakia or erythroplakia usually precedes development of squamous cell carcinoma (Fig. 10-31, A).
- Patients report burning and increasing trismus (see Fig. 10-31, B).

### Etiopathogenesis and Histopathologic Features

Areca nut contains alkaloids, such as arecoline, that stimulate collagen synthesis and reduce collagen degradation—possibly through the transforming growth

factor beta (TGF- $\beta$ ) pathway—and these alkaloids can be converted to carcinogenic nitrosamines. Areca nut contains abundant copper and flavonoids that act together to stabilize and enhance cross-linking of collagen. Areca nut products are part of gutka (which includes slaked lime and powdered tobacco) or paan (which includes slaked lime, spices, and sometimes tobacco wrapped in Piper betel leaf). Gutka use is associated with more rapid development of lesions.

- Hyperkeratosis, epithelial atrophy, and diffuse fibrosis of varying severity are in lamina propria; collagen becomes more dense and more hyalinized with prolonged use (Fig. 10-32).
- Dysplasia often is present in the overlying epithelium in long-standing lesions with subsequent development of invasive squamous cell carcinoma (Fig. 10-33).

### Differential Diagnosis

- Fibrosis from trauma is localized with obvious history.
- Progressive systemic sclerosis appears similar, but the presence of autoantibodies and a history of areca nut use differentiates between the two.



### Management and Prognosis

- Intralesional injections of corticosteroids, collagenase, hyaluronidase, and systemic treatment with pentoxifylline and interferon- $\gamma$  have all been useful; surgical excision of the scars with grafting helps to temporarily correct trismus.
- Close follow-up is needed because 7% to 13% of patients develop squamous cell carcinoma.

### REFERENCES

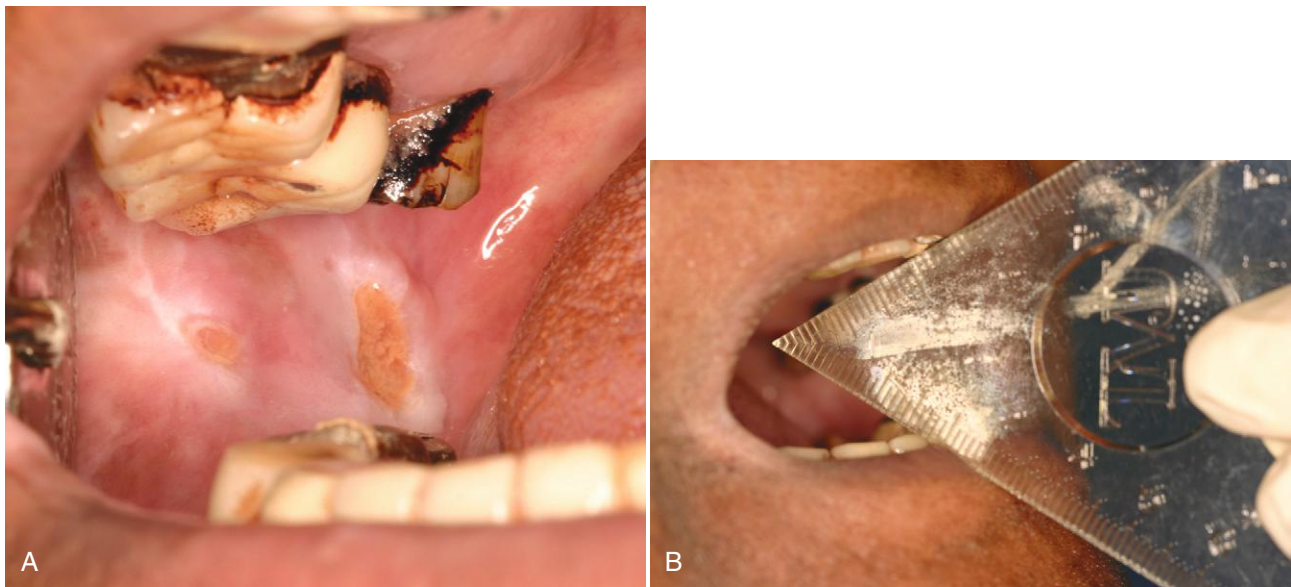
Javed F, Chotai M, Mehmood A, Almas K. Oral mucosal disorders associated with habitual gutka usage: a review. *Oral Surg Oral Med Oral Pathol Oral Radiol Endod.* 2010;109:857-864.

Jiang X, Hu J. Drug treatment of oral submucous fibrosis: a review of the literature. *J Oral Maxillofac Surg.* 2009;67:1510-1515.

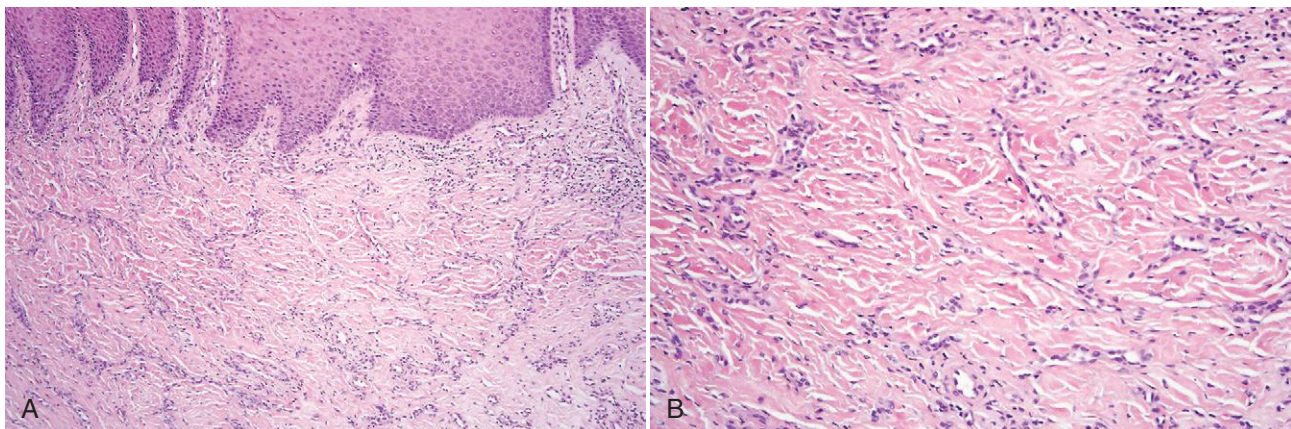
Lee CH, Ko YC, Huang HL, et al. The precancer risk of betel quid chewing, tobacco use and alcohol consumption in oral leukoplakia and oral submucous fibrosis in southern Taiwan. *Br J Cancer.* 2003;88:366-372.

Pandya S, Chaudhary AK, Singh M, Mehrotra R. Correlation of histopathological diagnosis with habits and clinical findings in oral submucous fibrosis. *Head Neck Oncol.* 2009;1:10.

Tilakaratne WM, Klinikowski MF, Saku T, et al. Oral submucous fibrosis: review on aetiology and pathogenesis. *Oral Oncol.* 2006;42:561-568.

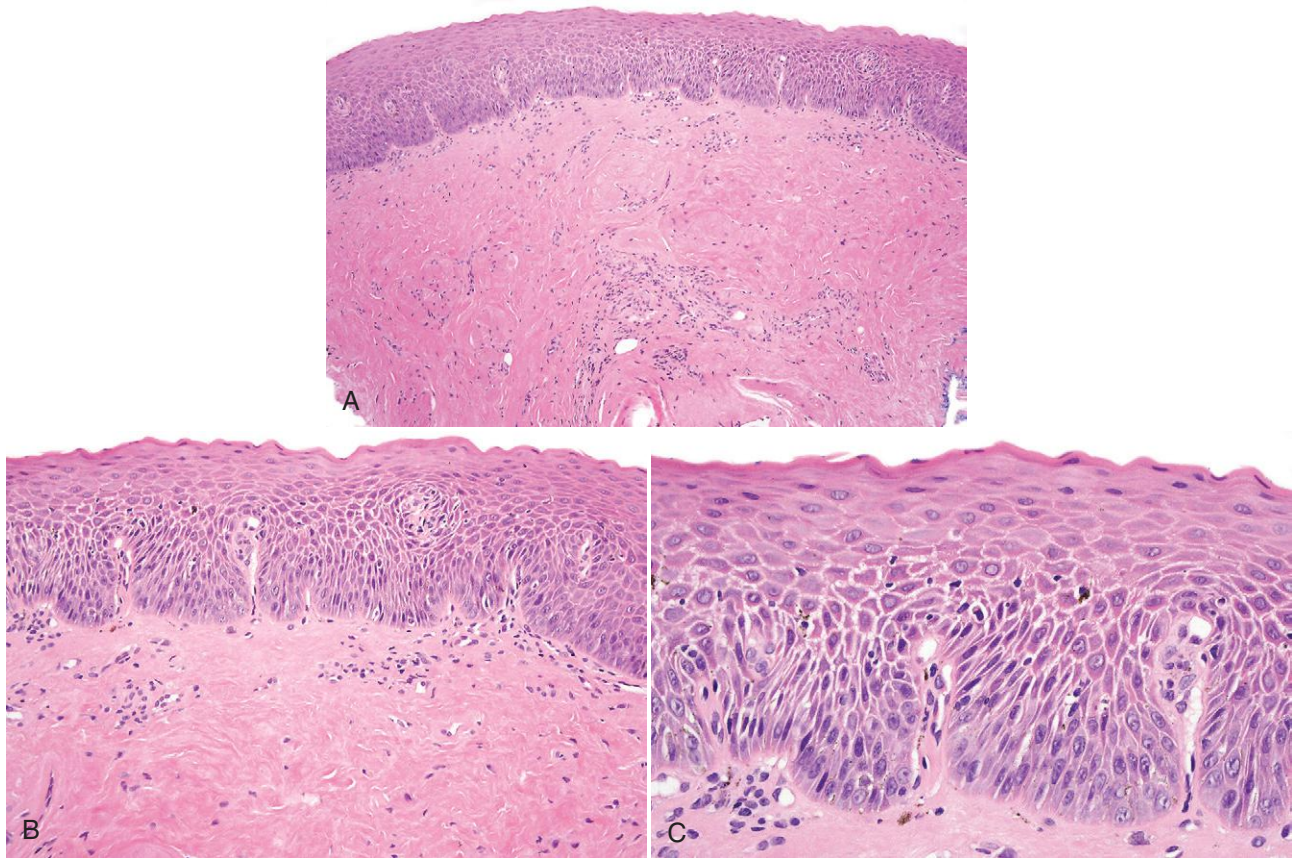


**FIGURE 10-31.** Submucous fibrosis. **A**, Poorly demarcated white and ulcerated area of the buccal mucosa with brown staining of teeth from areca nut habit. **B**, Same patient as in **A**; marked fibrosis leading to interincisal opening of only 20 mm (normal >40 mm).



**FIGURE 10-32.** Submucous fibrosis. **A**, Fibrosis of the lamina propria with mild chronic inflammation; epithelium does not exhibit significant basal cell atypia. **B**, Mild-to-moderate hyalinized collagen in the lamina propria.





**FIGURE 10-33.** Submucous fibrosis with dysplasia. **A,** Mucosa exhibits marked underlying fibrosis. **B,** Epithelium exhibits moderate dysplasia with basal cell hyperplasia and hyalinized fibrous tissue in lamina propria. **C,** Basal cell hyperplasia and mild pleomorphism involving approximately half the epithelium.

# 11

# LEUKOPLAKIA, ORAL DYSPLASIA, AND SQUAMOUS CELL CARCINOMA

## CHAPTER CONTENTS

Leukoplakia, Erythroplakia, and Dysplasia 230

Human Papillomavirus–Associated Apoptotic Dysplasia 241

Squamous Cell Carcinoma 243

## LEUKOPLAKIA, ERYTHROPLAKIA, AND DYSPLASIA

The term *oral dysplasia* is synonymous with *intraepithelial neoplasia* as used when discussing the cervix. The equivalent terms *squamous intraepithelial neoplasia* and *oral intraepithelial neoplasia* have not to date been universally accepted. The diagnostic term *epithelial atypia* is sometimes used interchangeably with *epithelial dysplasia* and this causes confusion; reactive epithelial atypia should always be reported as such. Diagnosis of dysplasia when there is reactive epithelial atypia may account for why some so-called dysplastic lesions regress over time.

Leukoplakia is not *any* white plaque but rather a white plaque that does not conform clinically or histopathologically to any specific disease and cannot be attributed to reactive, frictional, or traumatic causes. As such, it is a clinical term only and is used when other specific histopathologic and clinical entities are excluded (especially frictional keratoses [see [Chapter 10](#)]). Leukoplakia is the most common precursor lesion before invasive cancer develops.

### Development of Invasive Carcinoma

- Of all leukoplakias, 9% to 37% (the most recent figure being 47%) represent dysplasia, carcinoma in situ, or invasive carcinoma at time of biopsy.
- Over time, 16% to 36% of dysplasias develop invasive carcinoma.
- Over time, up to 16% of benign hyperkeratosis without dysplasia will develop dysplasia and/or carcinoma.
- The highest incidence of malignancy is on the ventral tongue, floor of mouth, and soft palate, which are all nonkeratinized sites.
- Over time, 60% to 100% of proliferative leukoplakias develop carcinoma.

### Clinical Features

- All forms of leukoplakia are more often seen in older individuals. Correlation of histopathologic findings with clinical appearance of lesions is of the utmost importance in the accurate diagnosis of dysplasia.

### Localized Leukoplakia

- *Localized leukoplakia* (at a single site) is more common in men and is strongly associated with smoking; leukoplakia are identified:

- *Homogeneous leukoplakia* is a uniform white plaque, at least partially well-demarcated, with or without fissuring ([Fig. 11-1, A and B](#)).
- *Nonhomogeneous leukoplakia* has verrucous/nodular and erythroplakic areas; it has a higher frequency of developing into dysplasia or carcinoma; erythroleukoplakia is more likely to be misdiagnosed clinically as lichen planus because of its red and white character; although typical reticulations are not present and it is unilateral, demarcation is usually best seen around the white/keratotic areas of the lesion ([Fig. 11-2](#); see [Fig. 11-1](#)).
- Verrucous hyperplasia of buccal mucosa may be associated with an areca nut habit.

### Proliferative Leukoplakia

- Proliferative form is multifocal or extensively affects contiguous sites and often affects gingiva.
- More common in women, it is not strongly associated with smoking; it is present and progressive over 10 to 20 years.
- Homogeneous forms are uncommon; most are nonhomogeneous and usually verrucous/nodular or erythroleukoplakic ([Fig. 11-3](#)).

### Erythroleukoplakia

- Erythroleukoplakic form is often clinically misdiagnosed as lichen planus because of multifocality and bilaterality; demarcation is usually best seen around the white/keratotic areas of the lesion, which may show fissuring.
- Erythroplakia appears as a velvety red plaque, usually painless; it is much less common than leukoplakia; more than 90% of these lesions are dysplastic or malignant at the time of diagnosis ([Fig. 11-4](#)).

### Etiopathogenesis and Histopathologic Features

Risk factors for localized leukoplakia (excluding the lip where lesions are usually related to actinic damage) are likely the same as for squamous cell carcinoma: cigarette smoking, excessive alcohol consumption, areca nut habit, history of cancer and cancer therapy, history of prolonged immunosuppression, family history of cancer, and age; risk factors for proliferative leukoplakia are less well-defined. Human papillomavirus (HPV)



**TABLE 11-1** Histopathologic Features of Dysplasia

Architectural features	<ul style="list-style-type: none"> <li>• Bulky and/or endophytic proliferation</li> <li>• Verrucous or papillary epithelial proliferation</li> <li>• Bulbous or drop-shaped rete ridges</li> <li>• Sharply demarcated keratinization, usually multifocal with “skip” areas</li> <li>• Hyperkeratosis with atrophy in the absence of inflammation, usually sharply demarcated</li> </ul>
Organizational features	<ul style="list-style-type: none"> <li>• Loss of stratification and polarity</li> <li>• Dyscohesion</li> <li>• Basal cell hyperplasia</li> <li>• Mitoses (even if normal-appearing) beyond the suprabasal keratinocytes</li> <li>• Keratin pearl formation, usually at tips of rete ridges</li> </ul>
Cytologic features (those noted on exfoliative cytology)	<ul style="list-style-type: none"> <li>• Basal cell hyperplasia</li> <li>• Increased nuclear:cytoplasmic ratio or enlarged nuclei</li> <li>• Variation in nuclear shape (pleomorphism) and size (anisonucleosis)</li> <li>• Variation in cell shape (pleomorphism) and size (anisocytosis)</li> <li>• Coarse chromatin and prominent nucleoli</li> <li>• Abnormal mitoses</li> <li>• Dyskeratosis or keratin pearl formation</li> <li>• Cells with glassy appearance of cytoplasm</li> </ul>

is associated with apoptotic dysplasias (see later). Mutations of genes on 3p, 9p, and 17 seen in squamous cell carcinomas have not been consistently found in oral dysplasia.

#### Architectural Evidence of Dysplasia

Features of dysplasia that occur in the absence of, or with minimal evidence of, cytologic dysplasia are often observed in clinical lesions of verrucous and proliferative leukoplakias (Table 11-1)

- Bulky epithelial proliferation, especially if endophytic and without leukocyte exocytosis or spongiosis (Figs. 11-5 to 11-7); many of these are thick plaques or masses clinically
- Papillary or verrucous epithelial proliferation, broad based, in an exophytic or endophytic configuration, often bulky (Figs. 11-8 to 11-10)
- Bulbous or drop-shaped rete ridges (Fig. 11-11)
- Sharp demarcation of the keratotic area from the adjacent normal epithelium and “skip” areas of normal mucosa sandwiched by hyperkeratotic or dysplastic epithelium (Figs. 11-12 and 11-13)
- Marked hyperorthokeratosis with epithelial atrophy (usually sharply demarcated) in the absence of inflammation and/or not representing a specific disease entity (such as atrophic or treated lichen planus) should be viewed with suspicion; not all dysplasias are hyperplastic lesions
- Sixteen percent of so-called benign hyperkeratoses developing into carcinoma owing to underdiagnosis of these lesions with minimal cytologic atypia.

#### Organizational Evidence of Dysplasia

Maturation disarray or dysmaturation, and loss of stratification and polarization characterized by basal cell hyperplasia (also cytologic evidence of dysplasia), discohesion, increased mitotic activity beyond immediate suprabasal cells, and keratin pearls within tips of rete ridges may be evident.

#### Cytologic Evidence of Dysplasia

Cytologic features are similar to those at other mucosal sites and are readily noted on exfoliative cytology (see Table 11-1); reactive epithelial atypia from inflammation may show the same features to a lesser degree.

- Graded mild (less than one third of the thickness of the epithelium involved by dysplasia), moderate (one third to two thirds), and severe (more than two thirds, not including carcinoma in situ) by convention (Figs. 11-14 to 11-16); carcinoma in situ shows full thickness involvement (Fig. 11-17); presence of a lymphocytic band at the interface is common and does not necessarily represent preexisting lichen planus; this is likely a T cell response to altered antigens on dysplastic keratinocytes.
- Involvement of ducts by dysplasia must be documented, because deep margins may not be clear of dysplasia if deep portions of duct are involved; this feature is associated with an increased rate of local recurrence (Figs. 11-18 and 11-19).
- Molecular markers and presence of high-risk HPV is not consistently predictive of subsequent development of invasive carcinoma.

#### Differential Diagnosis

- Reactive atypia is sometimes difficult to differentiate from true dysplasia, especially in the presence of reepithelialization and healing ulceration; if one cannot be sure, suggest using the phrases *likely reactive*, *unsure if reactive*, *unlikely reactive*, or *suspicious for dysplasia* to guide patient management.
- Lichen planus or lichenoid mucositis with reactive atypia tends to show squamatization of basal cells (instead of basal cell hyperplasia) and colloid body formation; multinucleated epithelial cells with finely dispersed chromatin and abundant cytoplasm are often seen in reactive lesions (Fig. 11-20).
- Candidiasis may show significant reactive atypia; to complicate matters, dysplastic epithelium is often colonized by *Candida*, likely because of breakdown of immune surveillance in some cases.

#### Management and Prognosis

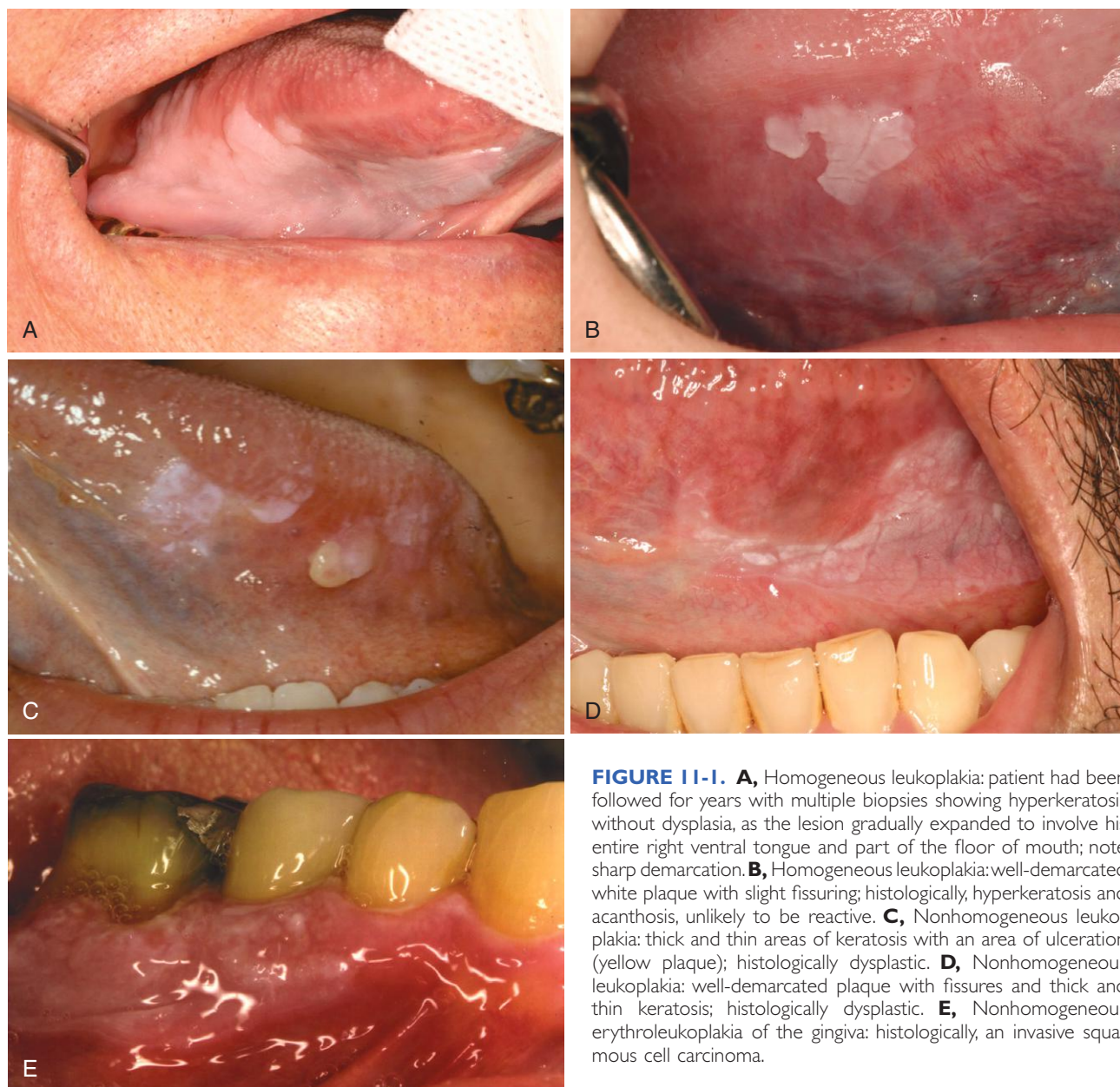
- Multiple biopsies should be performed for nonhomogeneous leukoplakia and proliferative leukoplakia.
- All dysplasias, including mild dysplasias (not reactive atypia) should be carefully followed or excised/ablated, depending on the clinical situation (e.g., high-risk site and high-risk history); recurrence occurs in 30% to 60% of cases.

- Cases that are suspicious for dysplasia because of architectural abnormalities without cytologic evidence of dysplasia, location at high-risk sites, or sharp demarcation may be candidates for narrow excision or ablation, unless morbidity is unacceptable.
- Lifetime follow-up is recommended.

#### REFERENCES

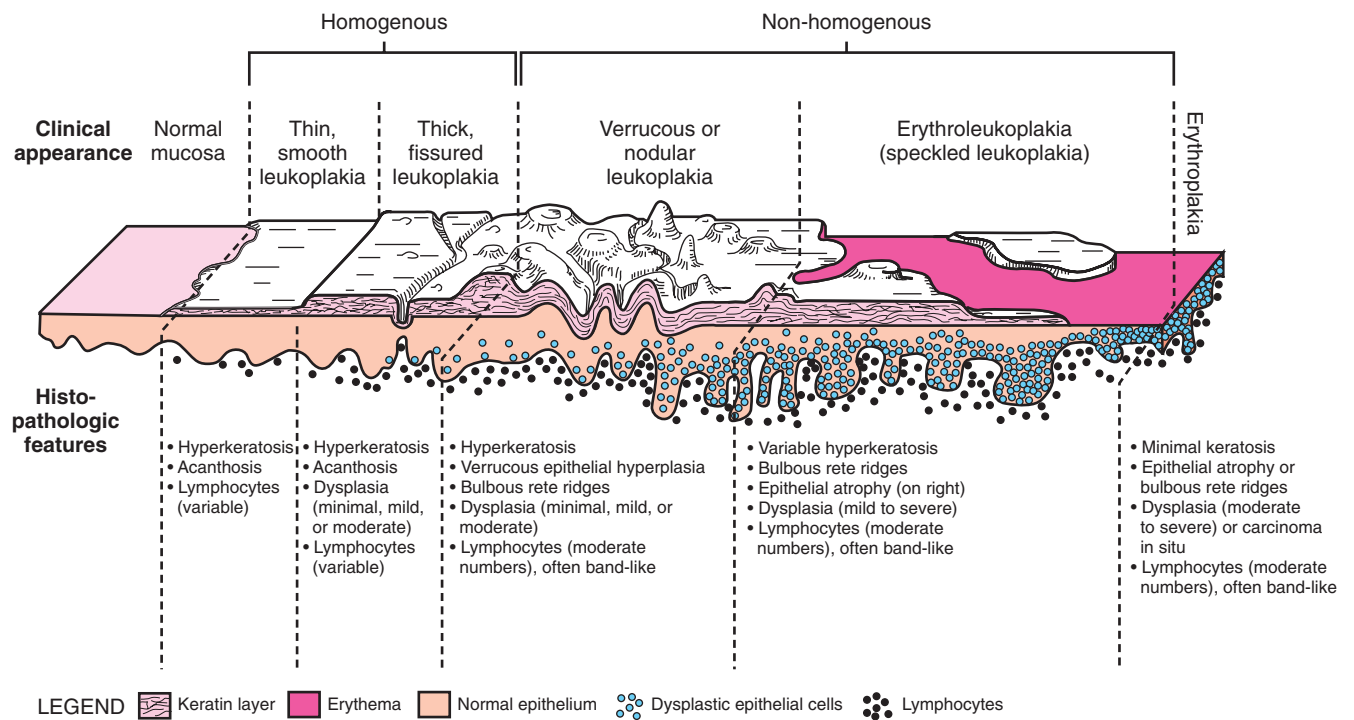
- Bagan J, Scully C, Jimenez Y, Martorell M. Proliferative verrucous leukoplakia: a concise update. *Oral Dis*. 2010;16:328-332.
- Barnes L, Eveson J, Reichart P, Sidransky D, eds. *Pathology and Genetics of Head and Neck Tumors*. Lyon, France: IARC Press; 2005.
- Brandwein-Gensler M, Smith RV. Prognostic indicators in head and neck oncology including the new 7th edition of the AJCC staging system. *Head Neck Pathol*. 2010;4:53-61.
- Daley TD, Lovas JG, Peters E, et al. Salivary gland duct involvement in oral epithelial dysplasia and squamous cell carcinoma. *Oral Surg Oral Med Oral Pathol Oral Radiol Endod*. 1996;81:186-192.
- Gale N, Michaels L, Luzar B, et al. Current review on squamous intraepithelial lesions of the larynx. *Histopathology*. 2009;54:639-656.
- Lee JJ, Hung HC, Cheng SJ, et al. Carcinoma and dysplasia in oral leukoplakias in Taiwan: prevalence and risk factors. *Oral Surg Oral Med Oral Pathol Oral Radiol Endod*. 2006;101:472-480.

- Napier SS, Speight PM. Natural history of potentially malignant oral lesions and conditions: an overview of the literature. *J Oral Pathol Med*. 2008;37:1-10.
- Pitiyage G, Tilakaratne WM, Tavassoli M, Warnakulasuriya S. Molecular markers in oral epithelial dysplasia: review. *J Oral Pathol Med*. 2009;38:737-752.
- Reichart PA, Philipsen HP. Oral erythroplakia—a review. *Oral Oncol*. 2005;41:551-561.
- Shafer WG, Waldron CA. Erythroplakia of the oral cavity. *Cancer*. 1975;36:1021-1028.
- Silverman S, Gorsky M, Lozada F. Oral leukoplakia and malignant transformation. *Cancer*. 1984;53:563-568.
- Speight PM. Update on oral epithelial dysplasia and progression to cancer. *Head Neck Pathol*. 2007;1:61-66.
- Waldron CA, Shafer WG. Leukoplakia revisited: a clinicopathologic study of 3265 oral leukoplakias. *Cancer*. 1975;36:1386-1392.
- Wang YP, Chen HM, Kuo RC, et al. Oral verrucous hyperplasia: histologic classification, prognosis, and clinical implications. *J Oral Pathol Med*. 2009;38:651-656.
- Warnakulasuriya S, Reibel J, Bouquot J, Dabelsteen E. Oral epithelial dysplasia classification systems: predictive value, utility, weaknesses and scope for improvement. *J Oral Pathol Med*. 2008;37:127-133.
- Yang SW, Lee YS, Chen TA, et al. Human papillomavirus in oral leukoplakia is no prognostic indicator of malignant transformation. *Cancer Epidemiol*. 2009;33:118-122.

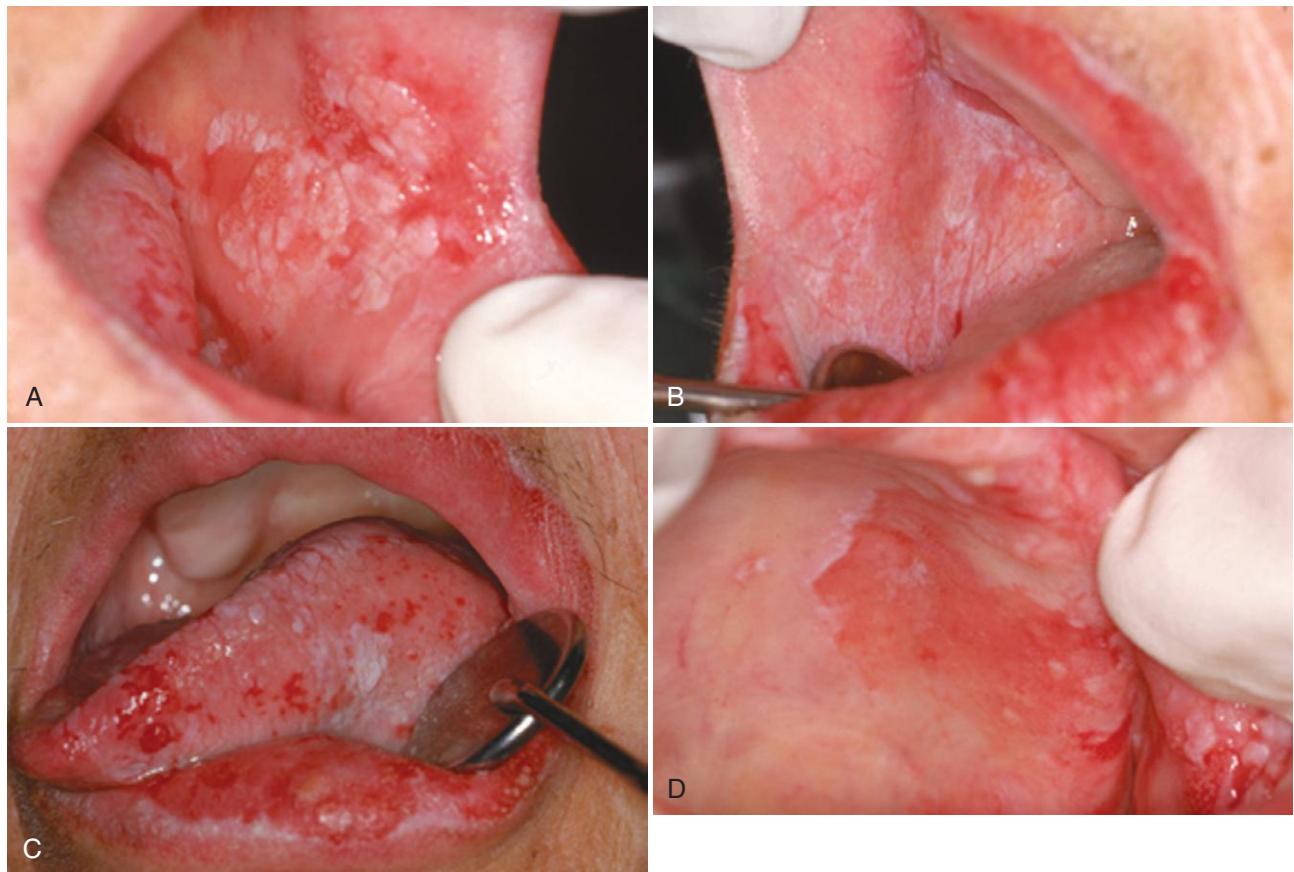


**FIGURE 11-1.** **A**, Homogeneous leukoplakia: patient had been followed for years with multiple biopsies showing hyperkeratosis without dysplasia, as the lesion gradually expanded to involve his entire right ventral tongue and part of the floor of mouth; note sharp demarcation. **B**, Homogeneous leukoplakia: well-demarcated white plaque with slight fissuring; histologically, hyperkeratosis and acanthosis, unlikely to be reactive. **C**, Nonhomogeneous leukoplakia: thick and thin areas of keratosis with an area of ulceration (yellow plaque); histologically dysplastic. **D**, Nonhomogeneous leukoplakia: well-demarcated plaque with fissures and thick and thin keratosis; histologically dysplastic. **E**, Nonhomogeneous erythroleukoplakia of the gingiva: histologically, an invasive squamous cell carcinoma.



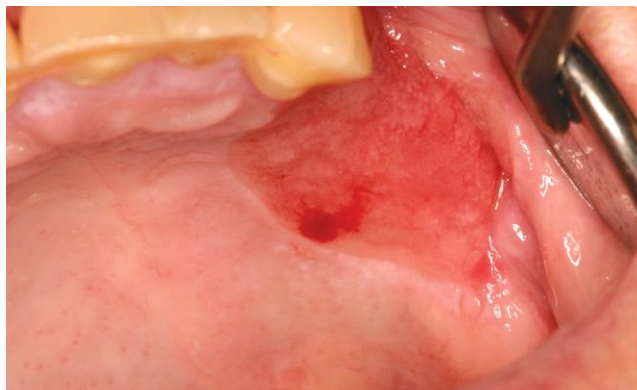

**FIGURE 11-2.** Representation of the clinical and likely corresponding histopathologic findings in leukoplakia. (Modified from Bouquot JE, Gnepp DR. Laryngeal precancer: a review of the literature, commentary, and comparison with oral leukoplakia. *Head Neck.* 1991;13:488-497.)

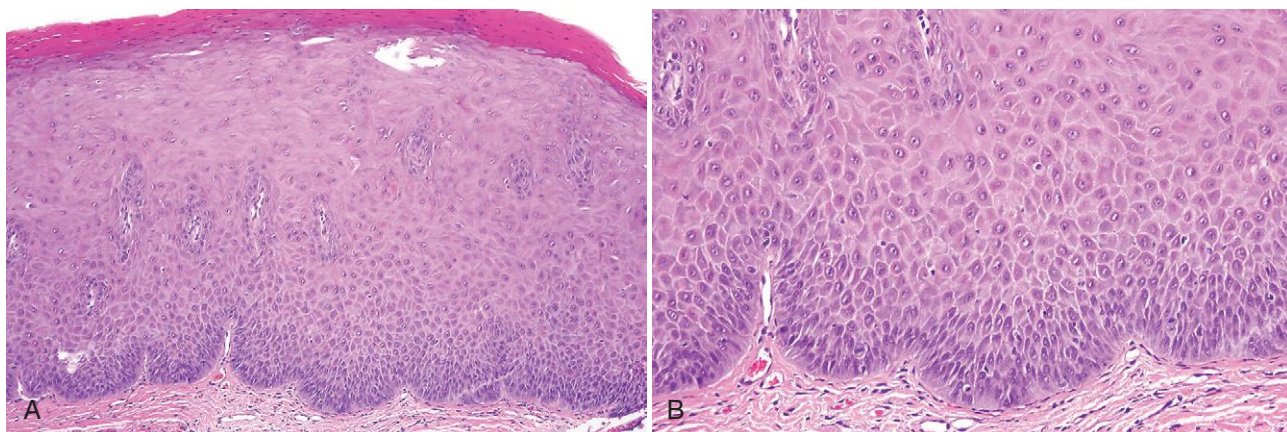


**FIGURE 11-3.** Proliferative erythroleukoplakia from one patient. **A**, Red and white plaque on the left buccal mucosa; fissured white plaques are focally demarcated. **B**, Red and white fissured plaque on the right buccal mucosa, not well-demarcated. **C**, Red and white fissured plaques on the ventral tongue and lower labial mucosa, not well-demarcated. **D**, Red and white plaques of the palate. Patient developed invasive squamous cell carcinoma.

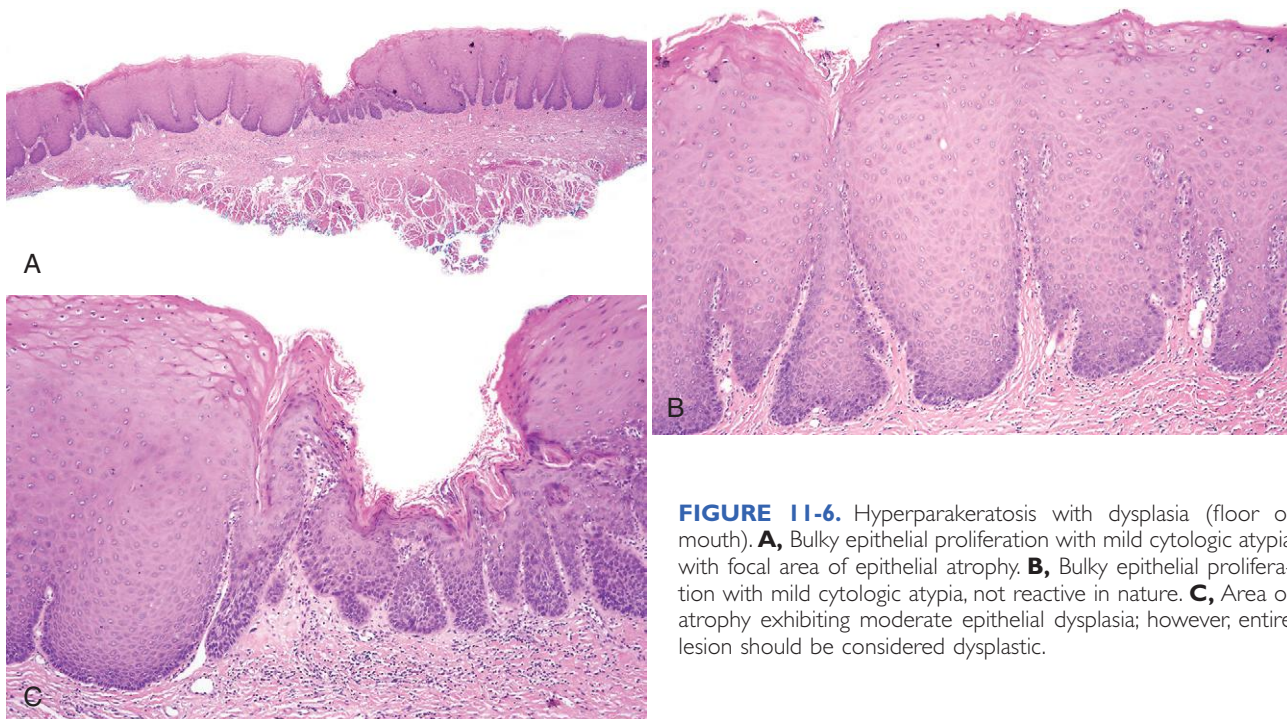




**FIGURE 11-4.** Erythroplakia of the palate; histologically, carcinoma in situ.

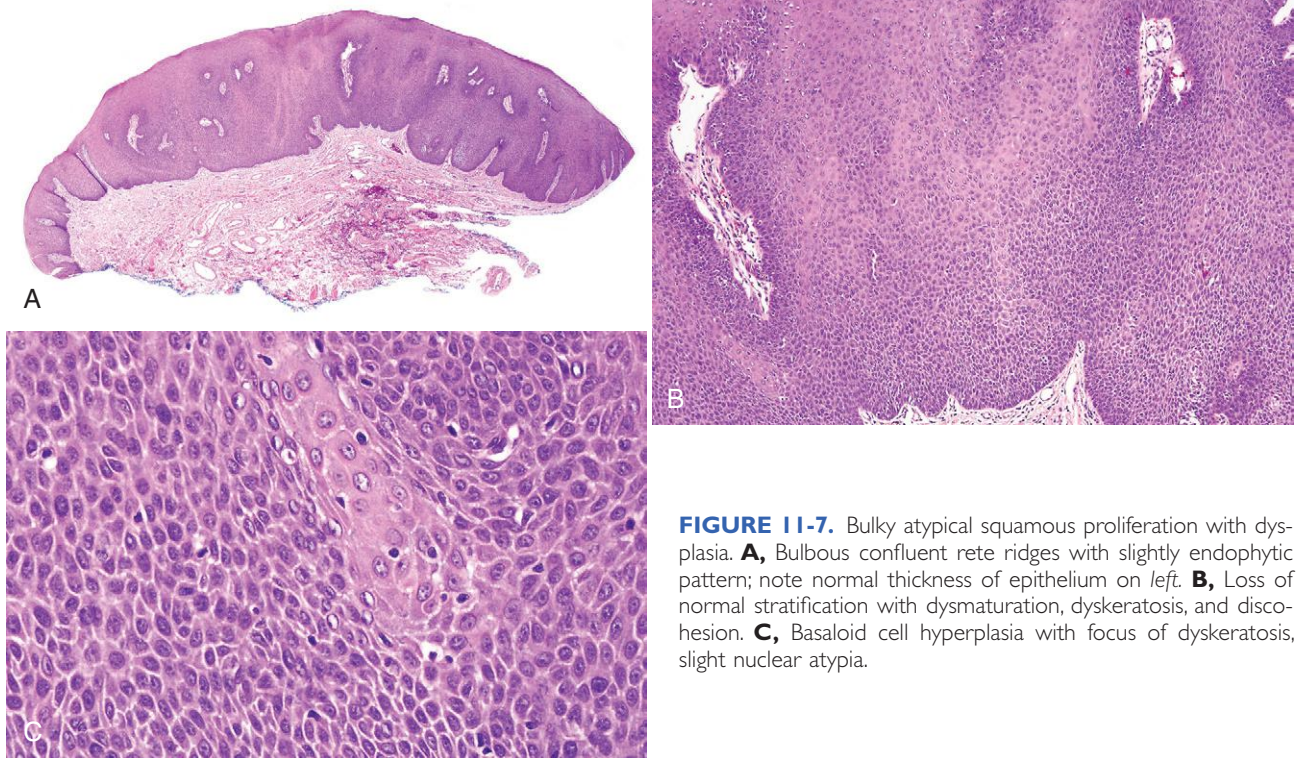


**FIGURE 11-5.** Hyperparakeratosis with dysplasia. **A**, Bulky epithelial proliferation and cells with glassy cytoplasm. **B**, Slight basal cell hyperplasia.

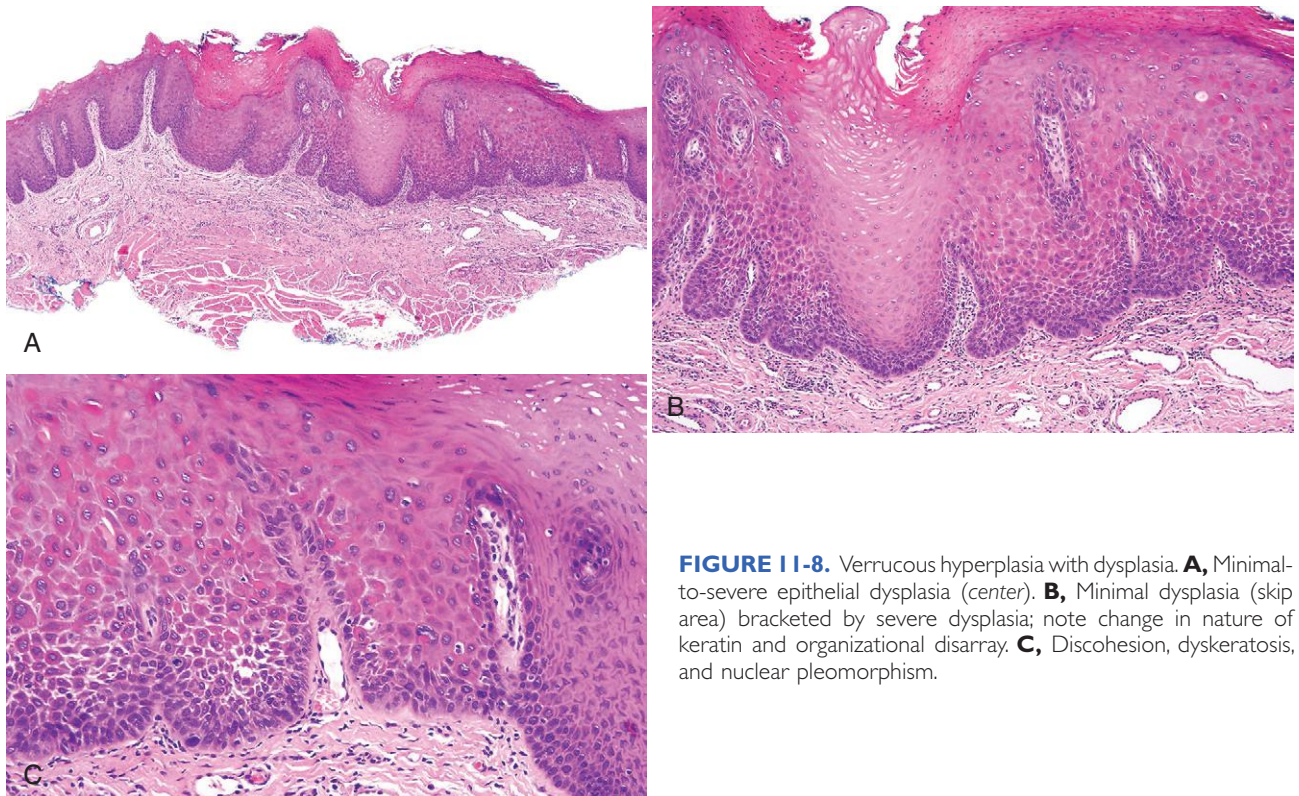


**FIGURE 11-6.** Hyperparakeratosis with dysplasia (floor of mouth). **A**, Bulky epithelial proliferation with mild cytologic atypia with focal area of epithelial atrophy. **B**, Bulky epithelial proliferation with mild cytologic atypia, not reactive in nature. **C**, Area of atrophy exhibiting moderate epithelial dysplasia; however, entire lesion should be considered dysplastic.



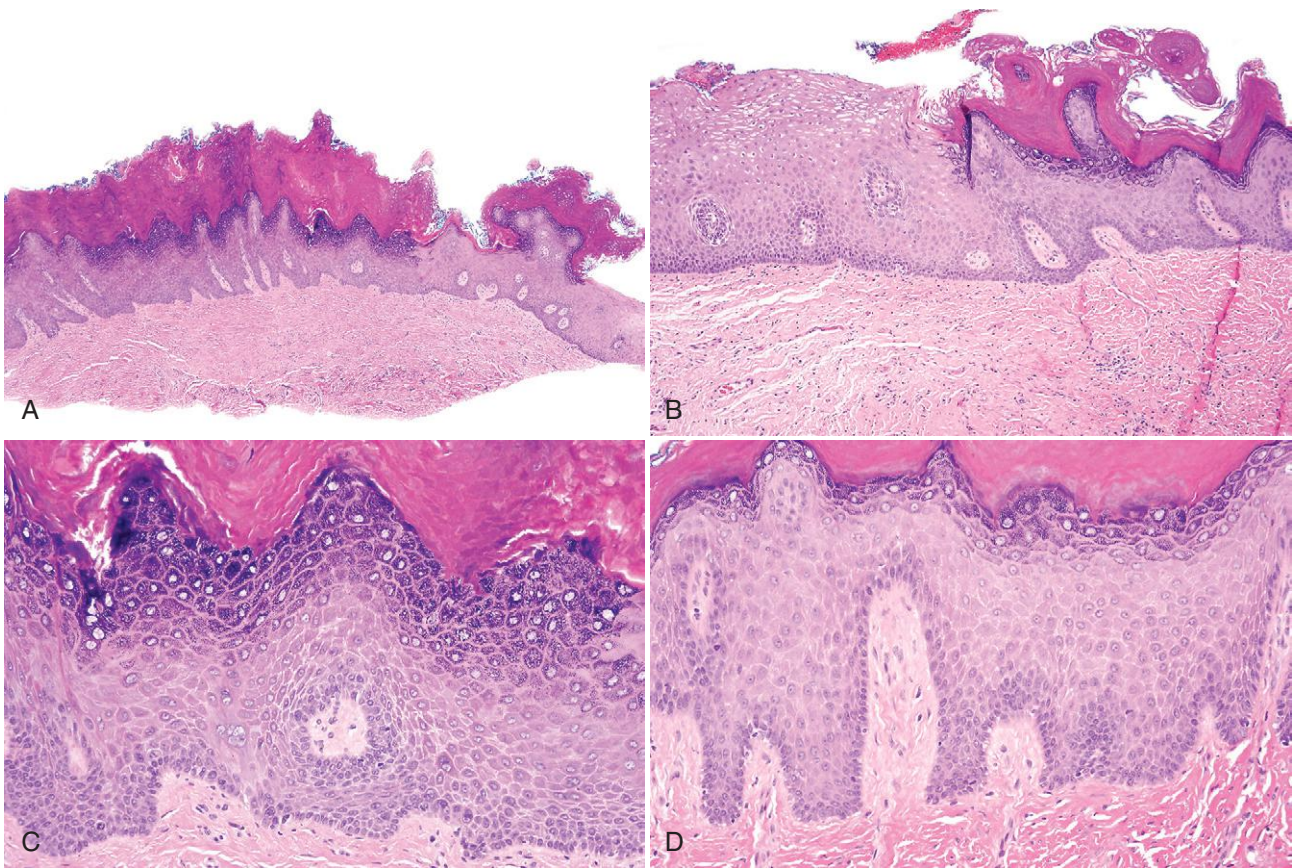


**FIGURE 11-7.** Bulky atypical squamous proliferation with dysplasia. **A**, Bulbous confluent rete ridges with slightly endophytic pattern; note normal thickness of epithelium on left. **B**, Loss of normal stratification with dysmaturation, dyskeratosis, and discohesion. **C**, Basaloid cell hyperplasia with focus of dyskeratosis, slight nuclear atypia.

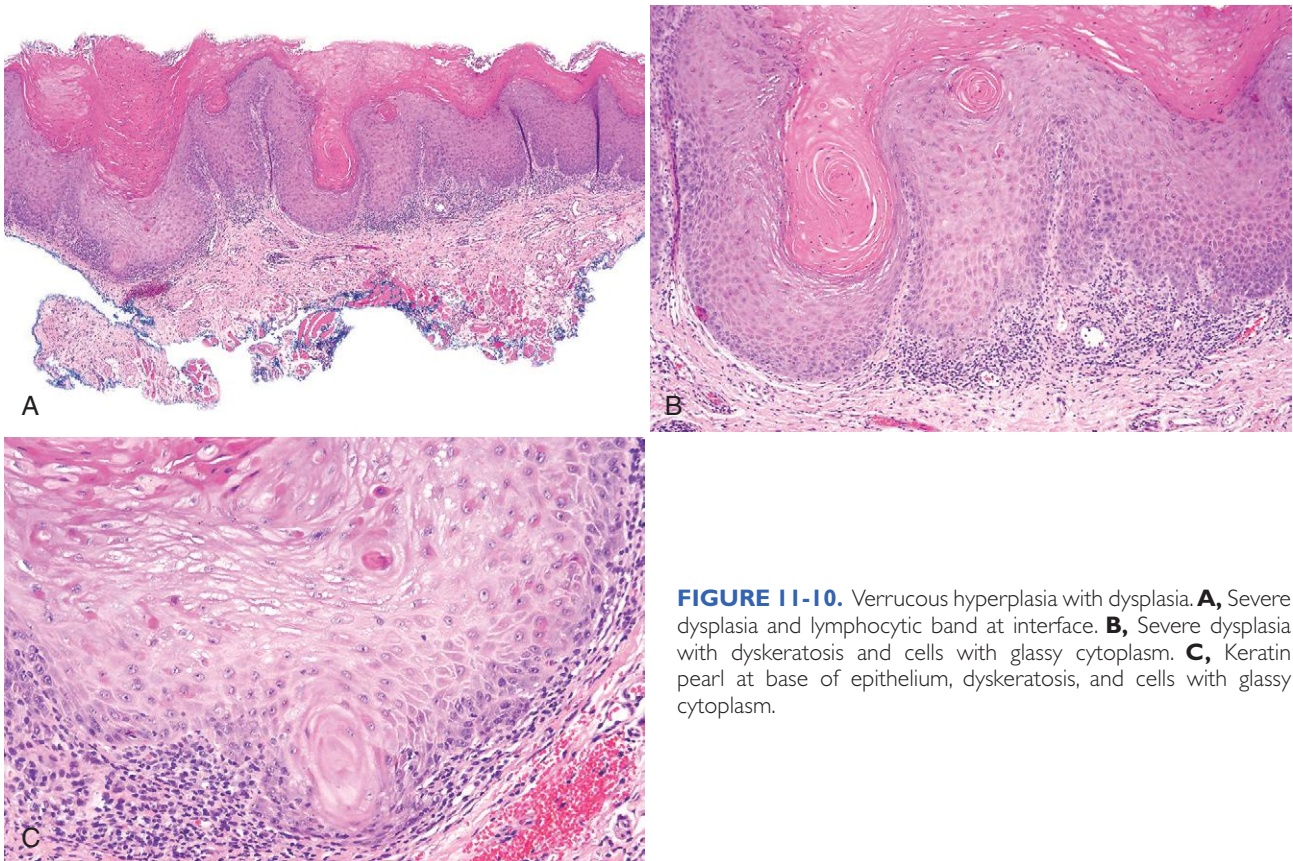


**FIGURE 11-8.** Verrucous hyperplasia with dysplasia. **A**, Minimal-to-severe epithelial dysplasia (center). **B**, Minimal dysplasia (skip area) bracketed by severe dysplasia; note change in nature of keratin and organizational disarray. **C**, Discohesion, dyskeratosis, and nuclear pleomorphism.



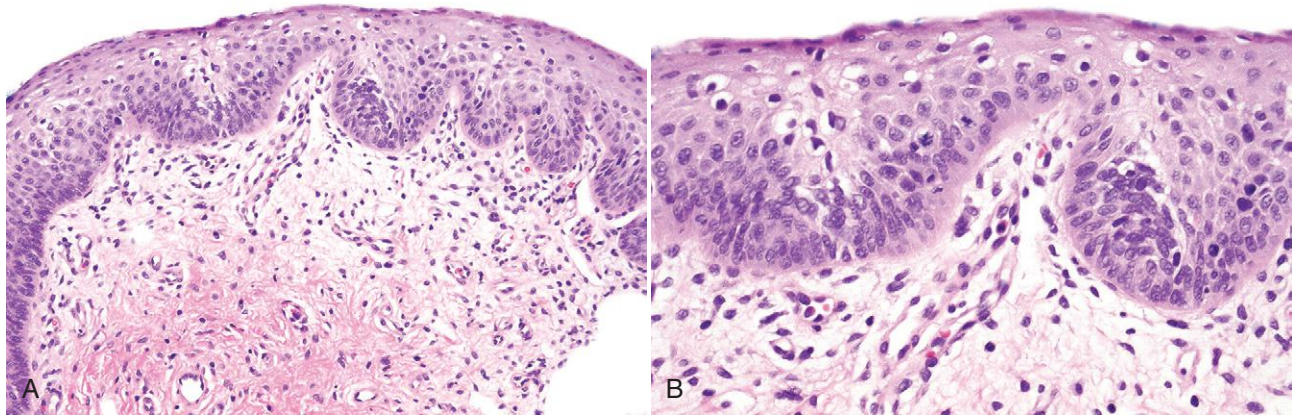


**FIGURE 11-9.** Verrucous hyperplasia with dysplasia. **A**, Hyperorthokeratosis, hypergranulosis, and verrucous epithelial proliferation showing sharp demarcation from surrounding normal epithelium; note early, thinly keratotic area sandwiched by hyperorthokeratotic areas. **B**, Abrupt keratinization corresponding to sharp demarcation clinically. **C**, Mild dysplasia involving the lower one third only. **D**, Another area shows insignificant dysplasia but with similar architecture.

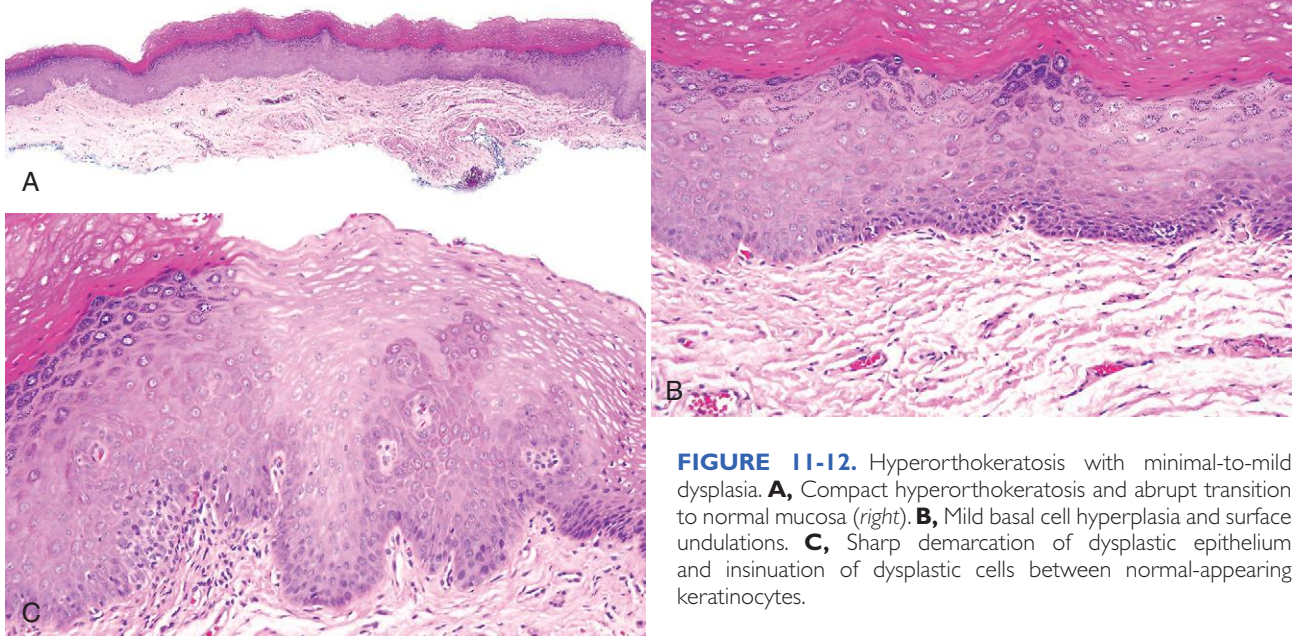


**FIGURE 11-10.** Verrucous hyperplasia with dysplasia. **A**, Severe dysplasia and lymphocytic band at interface. **B**, Severe dysplasia with dyskeratosis and cells with glassy cytoplasm. **C**, Keratin pearl at base of epithelium, dyskeratosis, and cells with glassy cytoplasm.

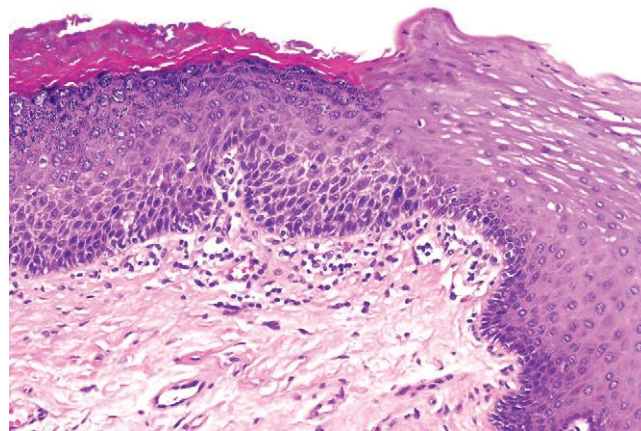




**FIGURE 11-11.** Mild dysplasia. **A**, Drop-shaped rete ridges with basal cell hyperplasia. **B**, Basal cell hyperplasia and cells with pleomorphic nuclei and mitoses.

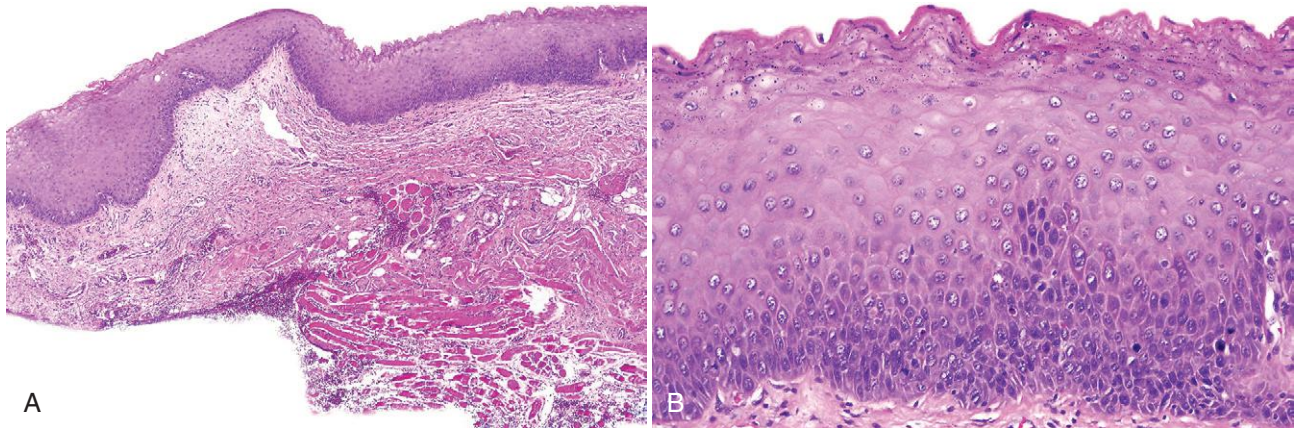


**FIGURE 11-12.** Hyperorthokeratosis with minimal-to-mild dysplasia. **A**, Compact hyperorthokeratosis and abrupt transition to normal mucosa (*right*). **B**, Mild basal cell hyperplasia and surface undulations. **C**, Sharp demarcation of dysplastic epithelium and insinuation of dysplastic cells between normal-appearing keratinocytes.

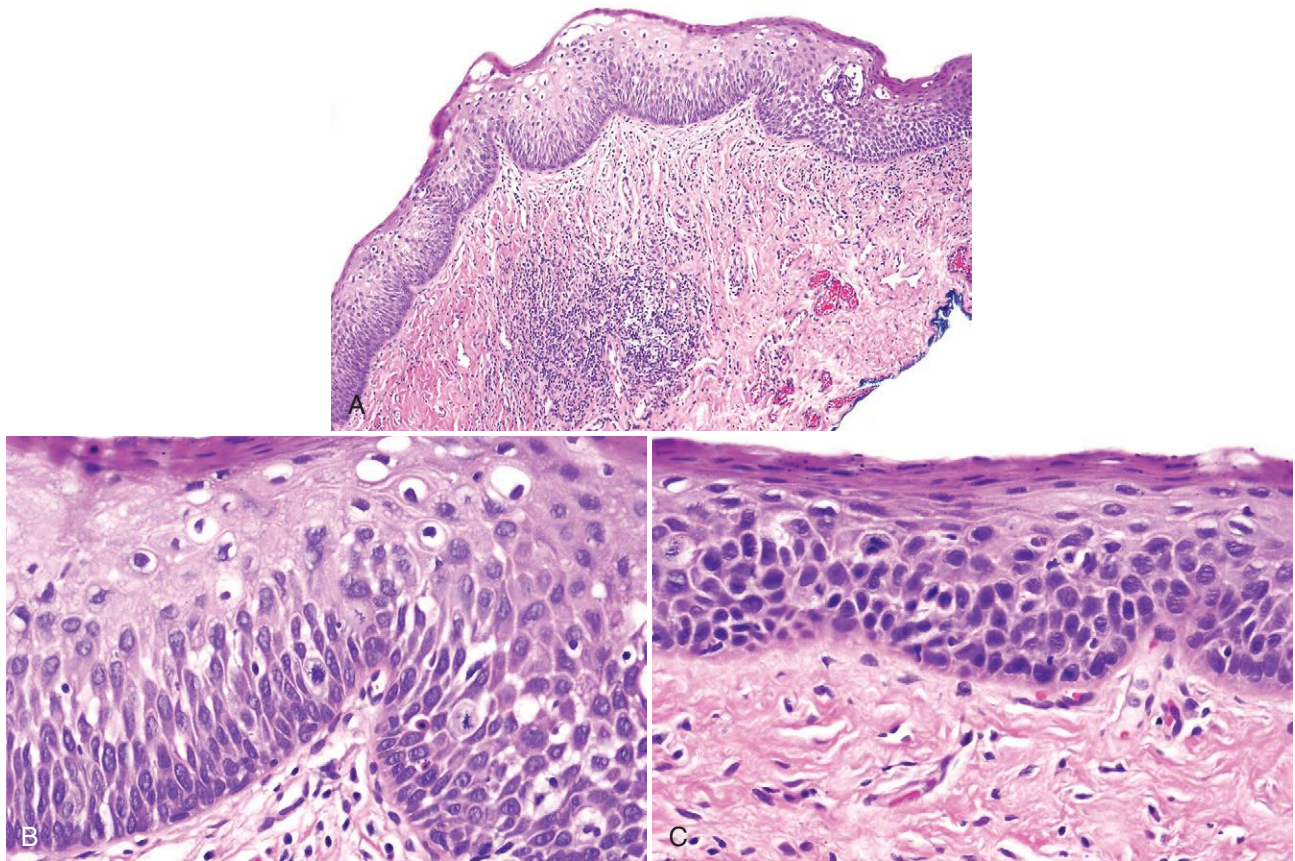


**FIGURE 11-13.** Hyperorthokeratosis with moderate epithelial dysplasia: abrupt transition between keratotic dysplasia with discohesive and pleomorphic cells and normal mucosa, corresponding to sharply demarcated clinical lesion.



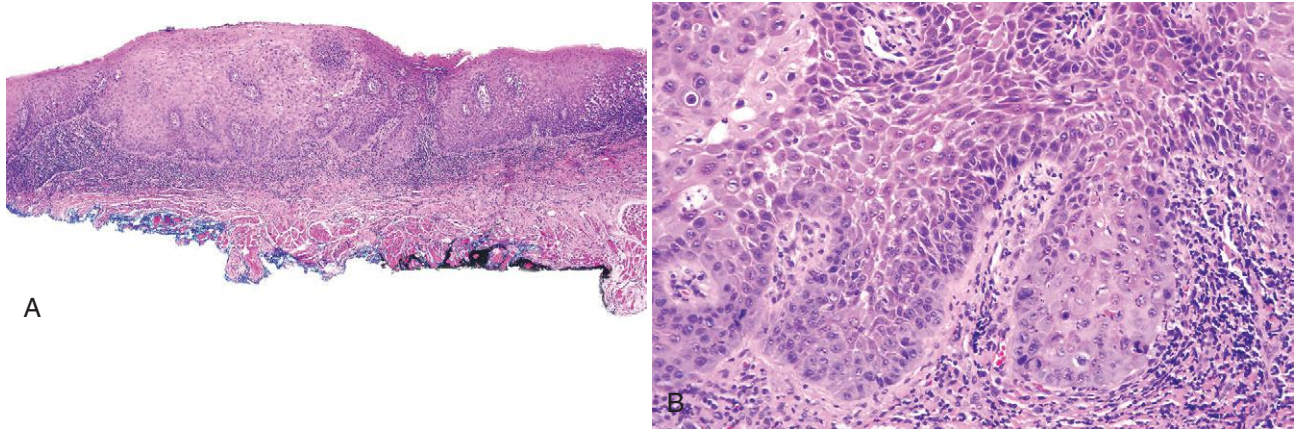


**FIGURE 11-14.** Mild epithelial dysplasia. **A**, Hyperparakeratosis and mild epithelial dysplasia. **B**, Basal cell hyperplasia in the absence of inflammation involving less than one third the thickness of epithelium.

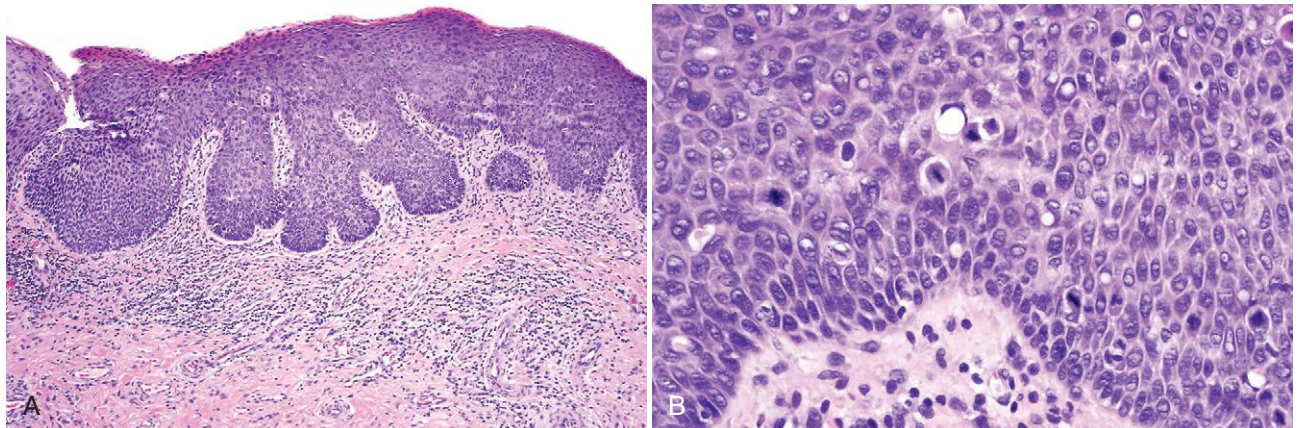


**FIGURE 11-15.** Moderate epithelial dysplasia. **A**, Bulbous rete ridge and basal cell hyperplasia and discohesion (*right*). **B**, Basal cell hyperplasia and mitoses. **C**, Area bordering on severe dysplasia with discohesion, high mitoses, cells with increased nuclear-to-cytoplasmic ratio, and hyperchromatic nuclei.



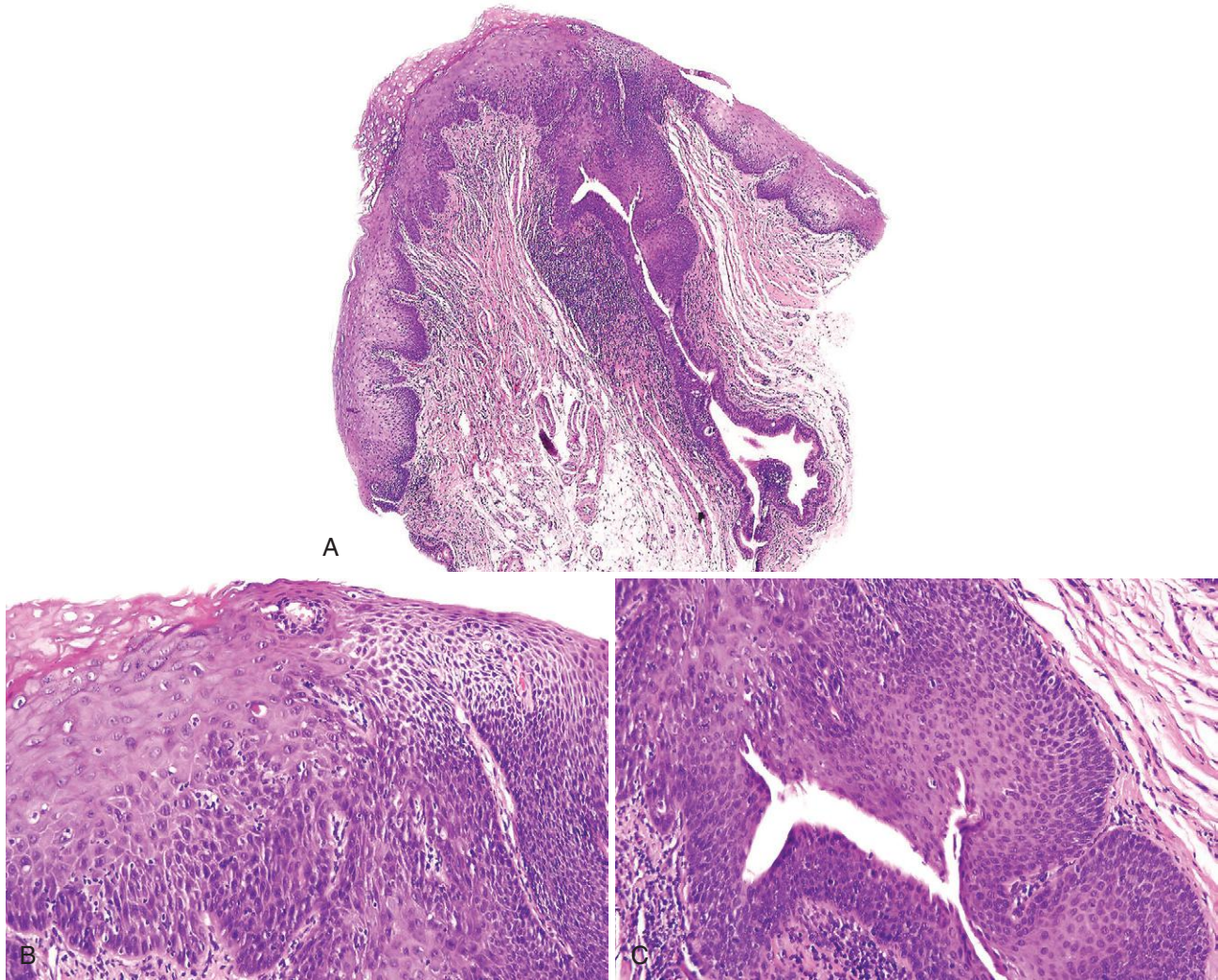


**FIGURE 11-16.** Hyperparakeratosis and severe epithelial dysplasia. **A**, Eosinophilic cells with glassy cytoplasm, bulbous rete ridges, and lymphocytic band. **B**, Discohesion, nuclear pleomorphism, hyperchromatism, and abnormal mitoses.

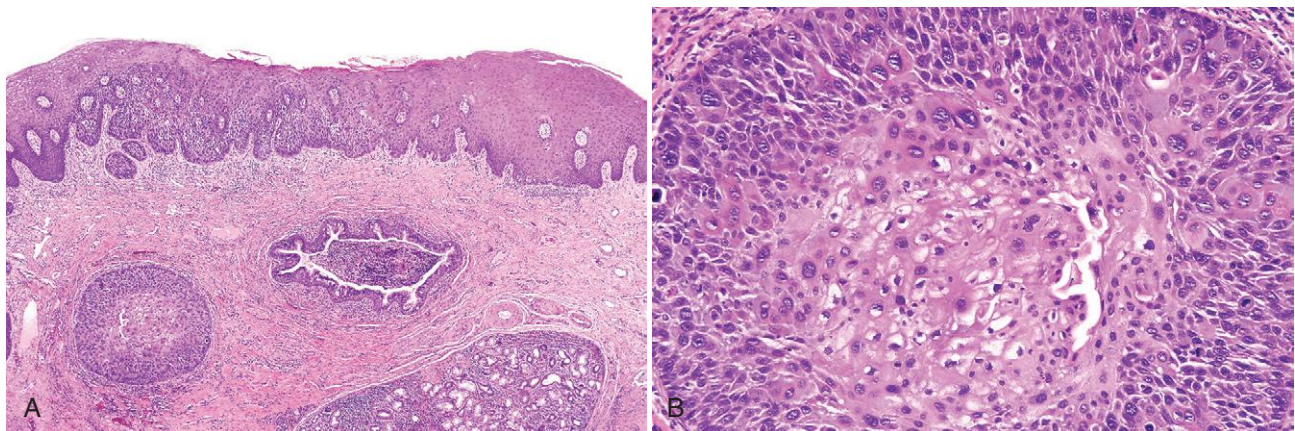


**FIGURE 11-17.** Carcinoma in situ. **A**, Budding rete ridges, dysplastic cells involving full thickness of epithelium, and lymphocytic infiltrate. **B**, Basal cell hyperplasia, cells with large nuclei, and many high mitotic figures.



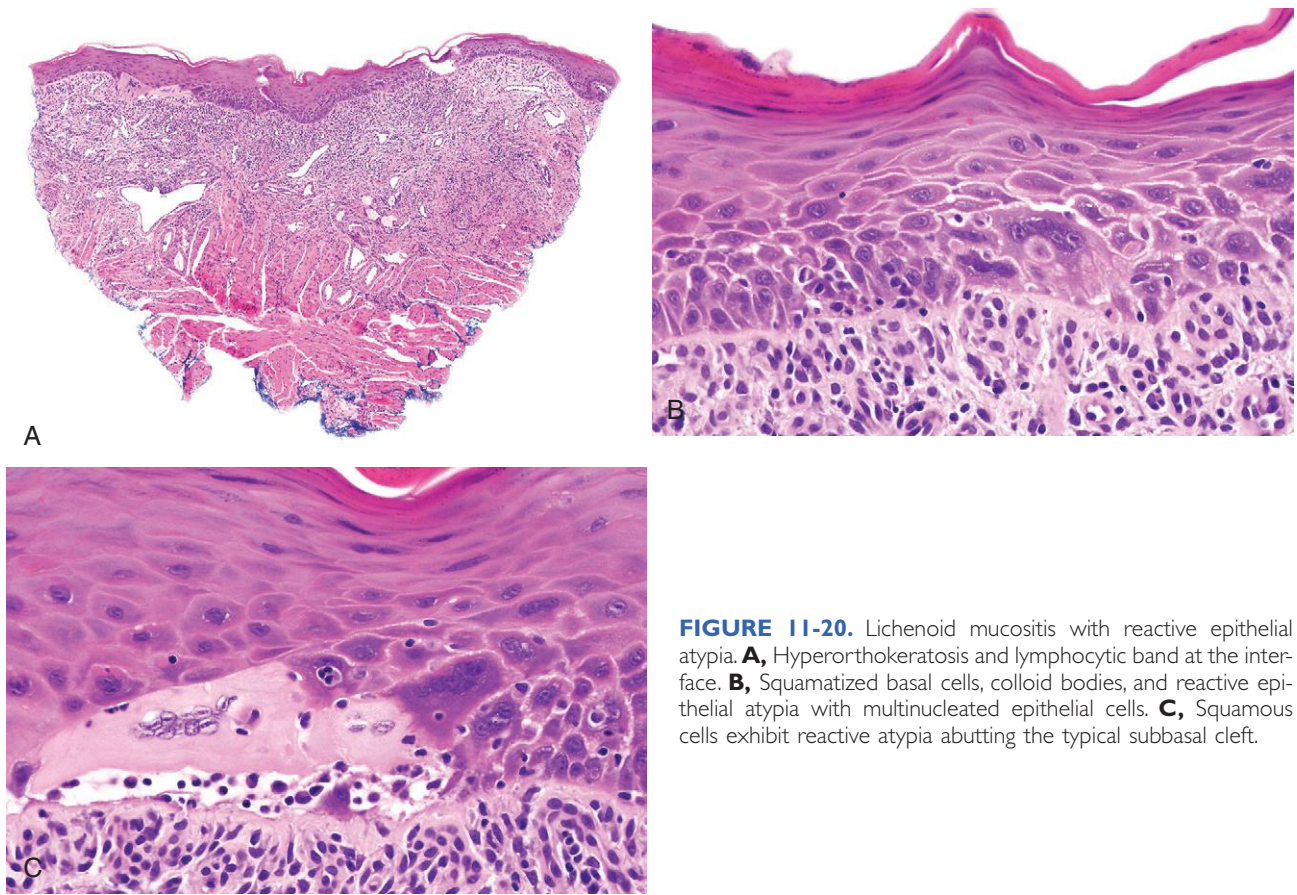


**FIGURE 11-18.** Moderate-to-severe epithelial dysplasia involving excretory duct. **A**, Sharply demarcated hyperorthokeratosis with dysplasia involving upper portion of duct. **B**, Surface exhibits discohesion, basal cell hyperplasia, and nuclear hyperchromatism. **C**, Dysplasia (basal cell hyperplasia) of duct.



**FIGURE 11-19.** Moderate-to-severe epithelial dysplasia involving excretory duct. **A**, Overlying epithelium exhibits basal cell hyperplasia; one duct is involved by dysplasia. **B**, Pleomorphic and dysplastic cells involve the full thickness of the duct.





**FIGURE 11-20.** Lichenoid mucositis with reactive epithelial atypia. **A**, Hyperorthokeratosis and lymphocytic band at the interface. **B**, Squamatized basal cells, colloid bodies, and reactive epithelial atypia with multinucleated epithelial cells. **C**, Squamous cells exhibit reactive atypia abutting the typical subbasal cleft.

## HUMAN PAPILLOMAVIRUS–ASSOCIATED APOPTOTIC DYSPLASIA

### Clinical Findings

- Indistinguishable from other leukoplakias; sharply demarcated white plaque, usually in adult men

### Etiopathogenesis and Histopathologic Features

This condition is associated with high-risk HPV subtypes, and it shares some features with Bowen disease. It has been referred to as koilocytic dysplasia.

- Usually bright parakeratosis; full-thickness involvement by cells in varying stages of apoptosis, from karyorrhexis (similar to mitosoid bodies) to degenerated cells with pyknotic nuclei; apoptotic cells are discohesive with surrounding halos; surrounding keratinocytes exhibit dysplasia, and koilocytes may be present; some cases are papillary (Figs. 11-21, A-C, 11-22 and 11-23, A-C).
- High-risk HPV subtypes are identified in up to 80% of cases (see Figs. 11-21, D, and 11-23, D).
- Continuous bandlike p16 positivity is always present (see Fig. 11-21, E).

### Differential Diagnosis

- Heck disease does not show significant atypia/dysplasia or continuous p16 positivity but will show karyorrhectic cells (mitosoid bodies).
- Conventional carcinoma in situ does not show significant numbers of such apoptotic cells and are p16 and high-risk HPV–negative cells.
- Bowenoid papulosis does not show the same degree of apoptosis.

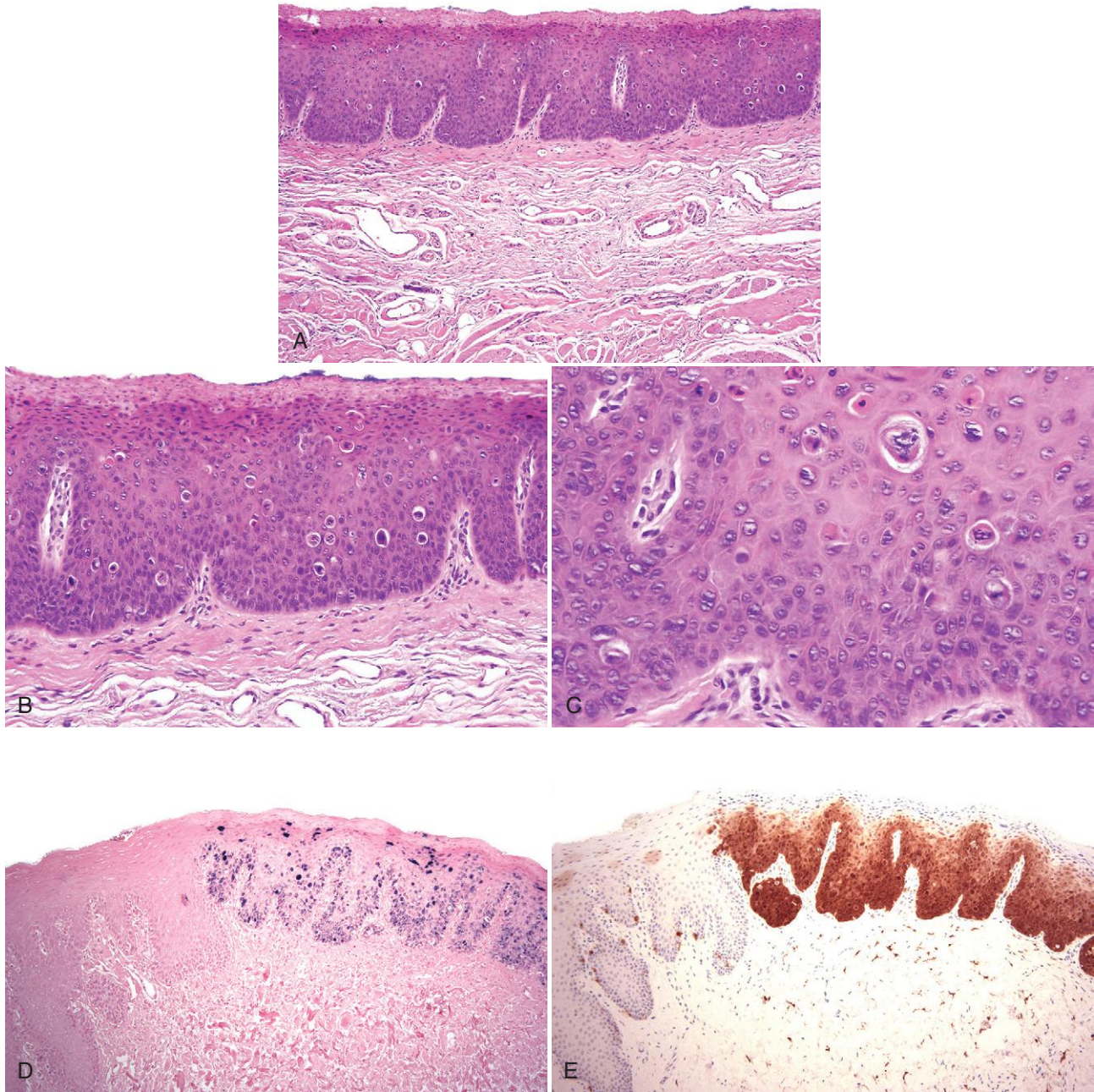
### Management and Prognosis

- Excision with clear margins is treatment of choice.

### REFERENCES

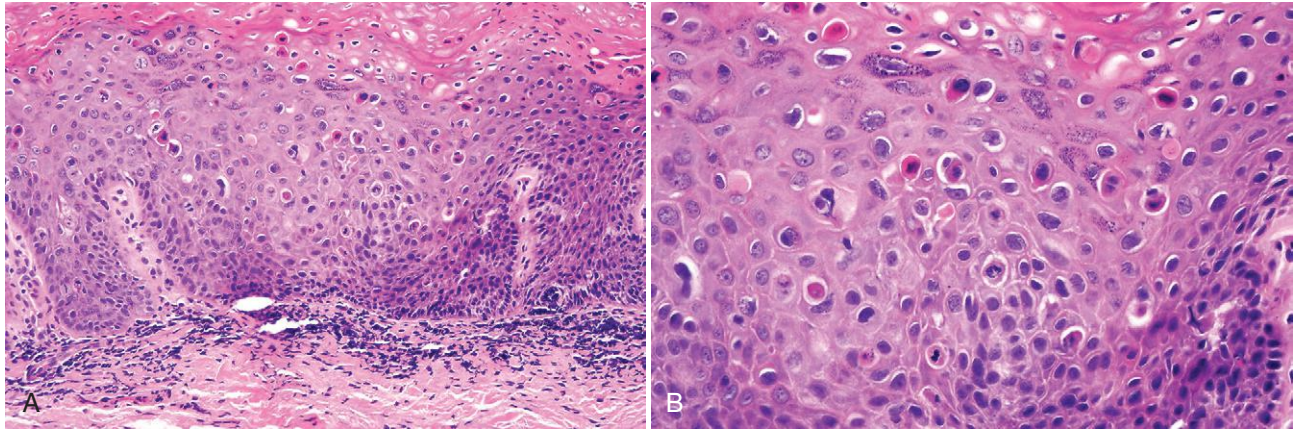
- Daley T, Birek C, Wysocki GP. Oral bowenoid lesions: differential diagnosis and pathogenetic insights. *Oral Surg Oral Med Oral Pathol Oral Radiol Endod.* 2000;90:466-473.
- Fornatora M, Jones AC, Kerpel S, Freedman P. Human papillomavirus-associated oral epithelial dysplasia (koilocytic dysplasia): an entity of unknown biologic potential. *Oral Surg Oral Med Oral Pathol Oral Radiol Endod.* 1996;82:47-56.
- Kratochvil FJ, Cioffi GA, Auclair PL, Rathbun WA. Virus-associated dysplasia (bowenoid papulosis?) of the oral cavity. *Oral Surg Oral Med Oral Pathol.* 1989;68:312-316.
- Rinaggio J, Glick M, Lambert WC. Oral bowenoid papulosis in an HIV-positive male. *Oral Surg Oral Med Oral Pathol Oral Radiol Endod.* 2006;101:328-332.



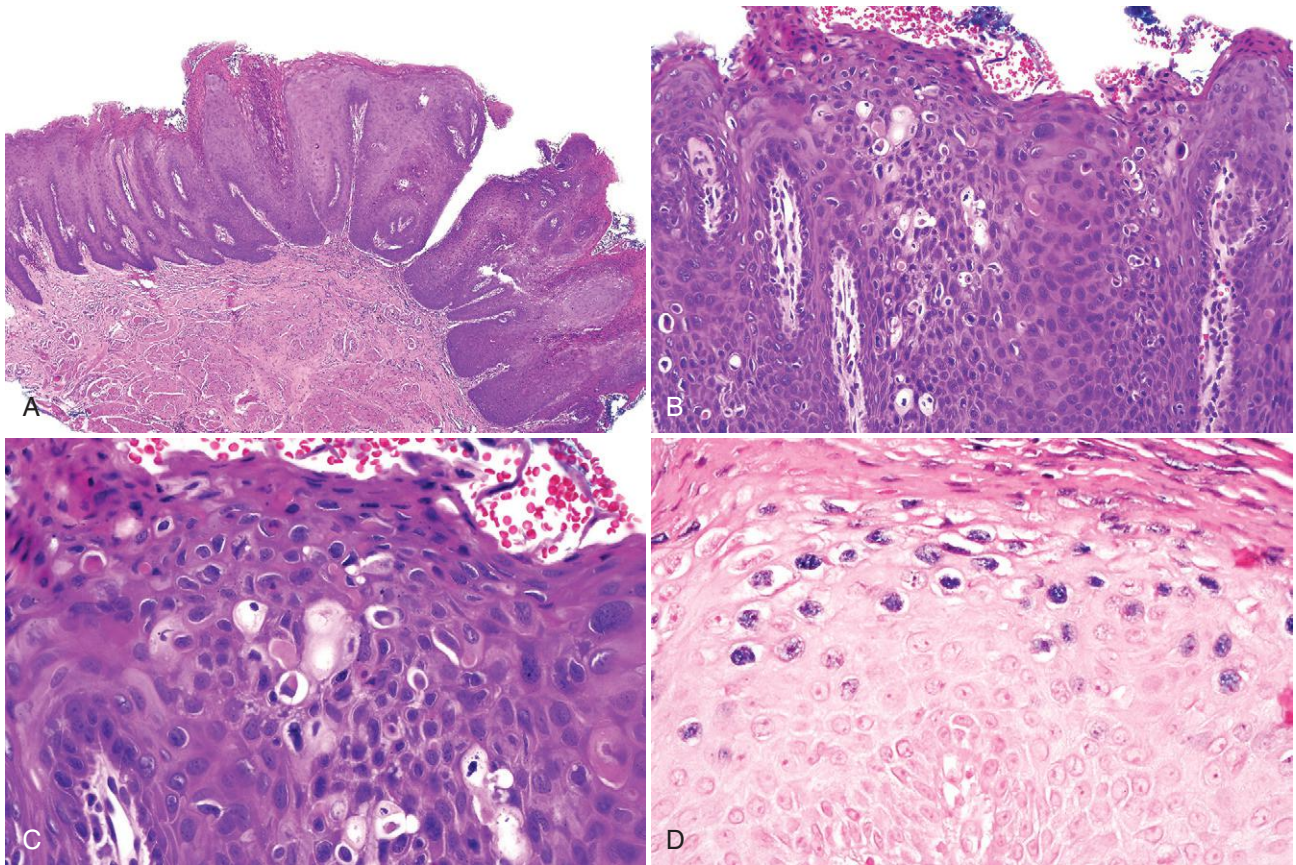


**FIGURE 11-21.** Dysplasia. **A**, Hyperparakeratosis and discohesive cells with halos involving full thickness of epithelium. **B**, Hyperparakeratosis and many cells exhibiting various stages of apoptosis. **C**, Karyorrhectic and apoptotic cells; adjacent cells show nuclear atypia. **D**, In situ hybridization is positive for high-risk human papillomavirus (HPV) subtypes; note abrupt transition to noninvolved epithelium. **E**, p16 stains most of the keratinocytes beneath the parakeratin in a pattern corresponding to the positive study for high-risk HPV in **D**; note abrupt transition to noninvolved epithelium.





**FIGURE 11-22.** HPV-associated apoptotic dysplasia. **A**, Hyperparakeratosis and full thickness involvement by dysplastic and apoptotic cells. **B**, Koilocytes and karyorrhectic and apoptotic cells are present.



**FIGURE 11-23.** **A**, Hyperparakeratosis and papillary epithelial hyperplasia. **B**, Apoptotic conventional dysplastic cells are present. **C**, Koilocytes and apoptotic and conventional dysplastic cells. **D**, In situ hybridization is positive for high-risk human papillomavirus subtypes.

## SQUAMOUS CELL CARCINOMA

Squamous cell carcinomas are the eleventh most common malignancy in the United States and the sixth most common worldwide. Risk factors are cigarette smoking, excessive alcohol consumption, areca nut habit, history of cancer and cancer therapy, history

of prolonged immunosuppression, family history of cancer, and age, similar for oral dysplasia (see earlier), but the most potent are tobacco and alcohol, which have synergistic activity. More recently, HPV infection has been shown to be associated with oropharyngeal and tonsillar carcinomas. Patients with Plummer-Vinson syndrome (iron deficiency anemia, atrophic glossitis,



and esophageal webs) are also predisposed to oral squamous cell carcinoma.

### Clinical Features

- Older adults with preexisting leukoplakia, erythroplakia, proliferative leukoplakia, or nonhealing indurated ulcer or mass; may also arise de novo (Fig. 11-24)
- Paresthesia, mobile teeth (if tumor invades the bone), and reduced mobility of soft tissues; only one third are diagnosed with localized tumors

### Etiopathogenesis and Histopathologic Features

Benzopyrenes and nitrosamines in cigarette smoke and tobacco products and arecoline in areca nut are carcinogenic agents. Alterations in activity of genes on 3p, 9p and 17 have been consistently found. E6 and E7 oncoproteins of HPV inactivate p53 and Rb tumor suppressor genes, respectively, the latter leading to overexpression of p16, the presence of which is highly correlated with HPV-associated squamous cell carcinoma of the tonsils and oropharynx.

- Several different histologic subtypes exist. Verrucous carcinoma does not tend to metastasize, and oropharyngeal tumors associated with HPV have a better prognosis compared with conventional squamous cell carcinoma. The classification used subsequently is based primarily on morphology and, unless specified, it does not necessarily have prognostic significance.

### CONVENTIONAL INFILTRATING SQUAMOUS CELL CARCINOMA

- Malignant epithelial cells proliferate and invade the surrounding stroma as single cells, islands, and cords of epithelial cells; desmoplasia, lymphocytes, and eosinophils are often seen at the tumor front and may or may not correlate with prognosis (Fig. 11-25, A and B).
- Cytologic changes (See Table 11-1): keratin formation may be abundant (well-differentiated) or the tumor may be minimally to nonkeratinizing; keratin pearl formation may be associated with foreign body reaction (Fig. 11-26; see Fig. 11-25 C).
- Overlying and adjacent epithelium exhibits varying degrees of dysplasia, but this may be minimal; candidal infection is common (Fig. 11-27).
- Tumor thickness correlates with recurrence, nodal metastases, and survival, although this is site specific (e.g., tumors  $\leq 3$  mm exhibit 8% subclinical metastasis, 0% local recurrence, and 100% 5-year survival; tumors  $\geq 9$  mm show 53% metastasis, 24% recurrence, and 66% 5-year survival).
- Tumors with bulbous rete ridges that infiltrate on a broad front (bluntly invasive) and have significantly lower recurrence and metastases.

- Lymphovascular, perineural, and bone invasion correlate with metastases, local recurrence, and reduced survival.

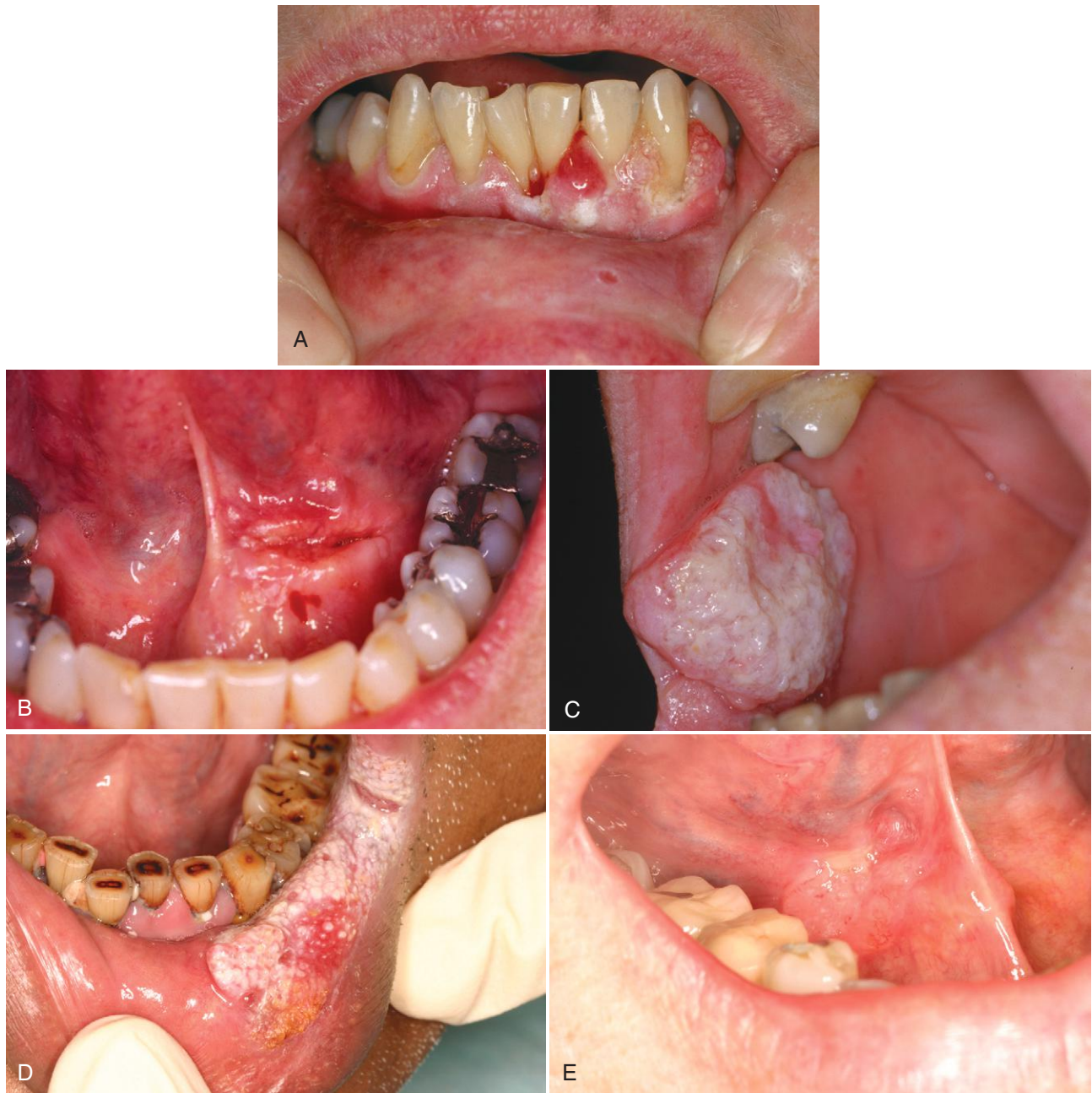### Management and Prognosis

- Intraoral films, panoramic films, and CT, MRI, and PET scans help delineate extent of tumor.
- Stage I and II tumors are treated with en bloc resection with or without lymph node dissection.
- Stage III and IV tumors are treated with surgery with neck dissection, radiation therapy with or without radiation sensitizers, and/or chemotherapy; cetuximab, a monoclonal antibody against epidermal growth factor receptor has shown promise in improving disease control.
- Sentinel node biopsies are positive in 20% to 30% of clinically benign neck nodes and upstage tumors in 30% to 50% of cases.
- Five-year survival is as follows: 83% with local disease, 55% with locoregional disease, 32% with distant metastases.
- Long-term follow-up is of utmost importance because second primary tumors occur in 7% to 33% of patients.

### REFERENCES

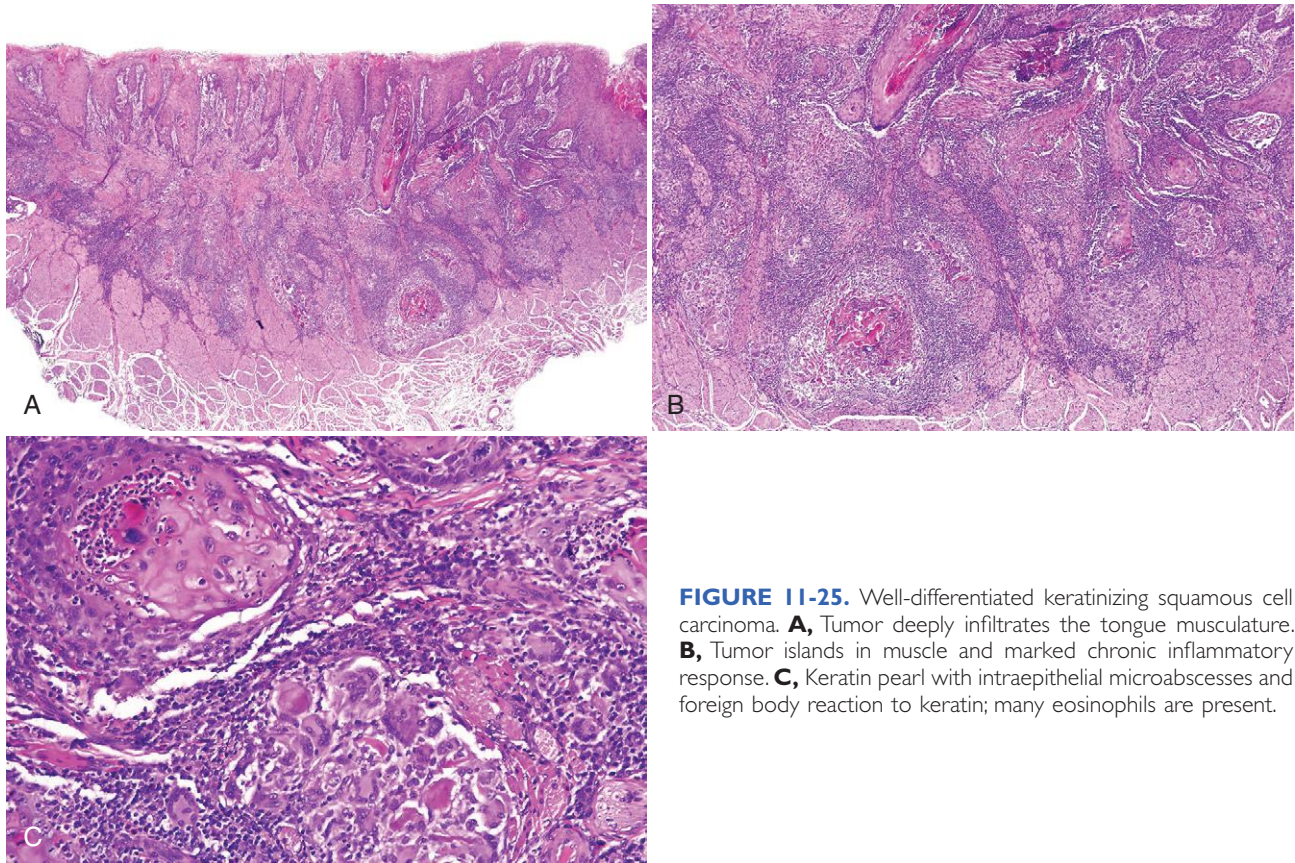
- Brinkman BM, Wong DT. Disease mechanism and biomarkers of oral squamous cell carcinoma. *Curr Opin Oncol.* 2006;18:228-233.
- Civantos FJ, Zitsch RP, Schuller DE, et al. Sentinel lymph node biopsy accurately stages the regional lymph nodes for T1-T2 oral squamous cell carcinomas: results of a prospective multi-institutional trial. *J Clin Oncol.* 2010;28:1395-1400.
- Haddad R, Annino D, Tishler RB. Multidisciplinary approach to cancer treatment: focus on head and neck cancer. *Dent Clin North Am.* 2008;52:1-17.
- Mohit-Tabatabai M, Sobel HJ, Rush BF, Mashberg A. Regulation of thickness of floor of mouth stage I and II cancers to regional metastasis. *Am J Surg.* 1986;152:351-353.
- Odell EW, Jani P, Sherriff M, et al. The prognostic value of individual histologic grading parameters in small lingual squamous cell carcinomas. The importance of the pattern of invasion. *Cancer.* 1994;74:789-794.
- Ocharoenrat P, Pillai G, Patel S, et al. Tumour thickness predicts cervical nodal metastases and survival in early oral tongue cancer. *Oral Oncol.* 2003;9:386-390.
- Patel SG, Shah JP. TNM staging of cancers of the head and neck: striving for uniformity among diversity. *CA Cancer J Clin.* 2005;55:242-258; quiz 261-262, 264.
- Pereira MC, Oliveira DT, Kowalski LP. The role of eosinophils and eosinophil cationic protein in oral cancer: a review. *Arch Oral Biol.* 2011;56:353-358.
- Po Wing Yuen A, Lam KY, Lam LK, et al. Prognostic factors of clinically stage I and II oral tongue carcinoma—a comparative study of stage, thickness, shape, growth pattern, invasive front malignancy grading, Martínez-Gimeno score, and pathologic features. *Head Neck.* 2002;24:513-520.
- Scully C, Bagan J. Oral squamous cell carcinoma: overview of current understanding of etiopathogenesis and clinical implications. *Oral Dis.* 2009;15:388-399.
- SEER. <http://seer.cancer.gov/statfacts/html/oralcav.html>
- Woolgar JA. Histopathological prognosticators in oral and oropharyngeal squamous cell carcinoma. *Oral Oncol.* 2006;42:229-239.



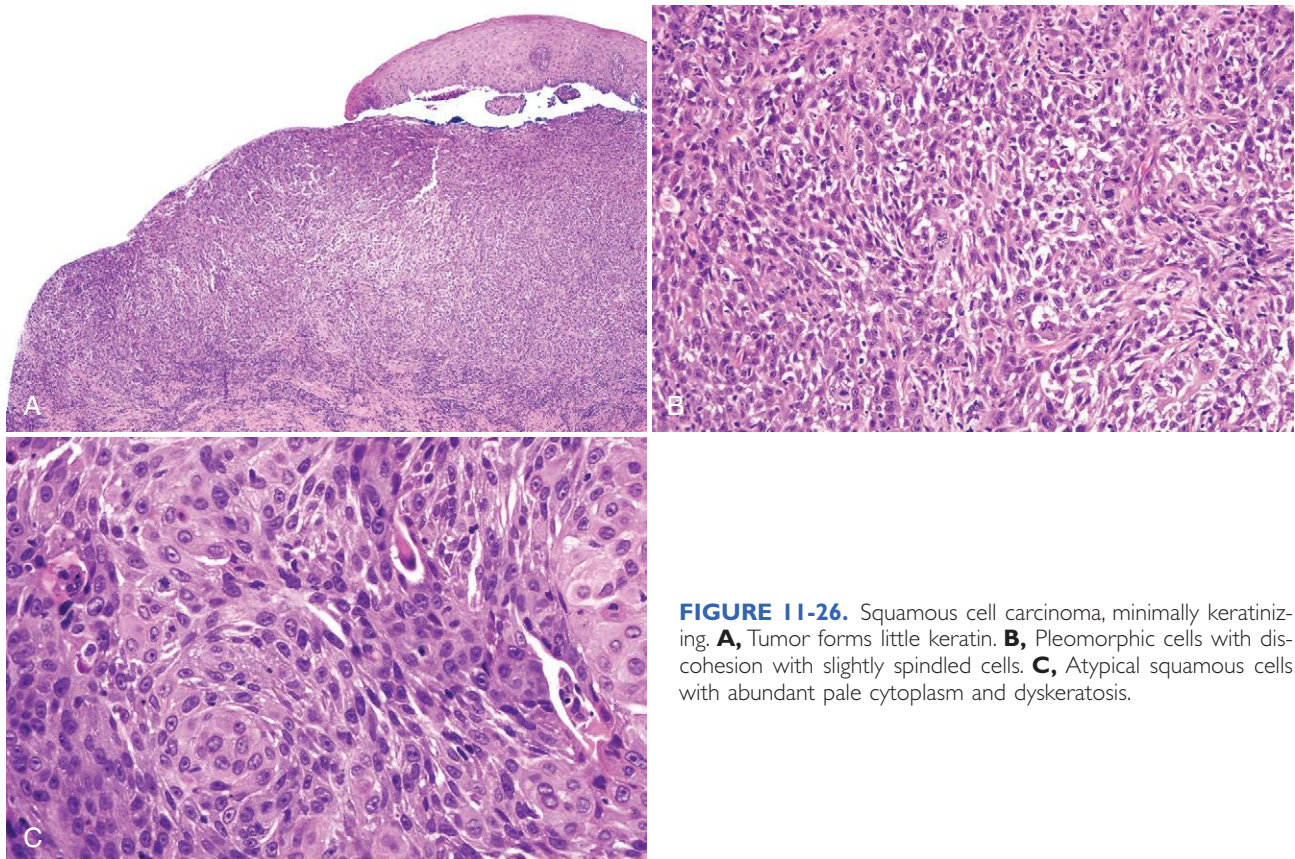


**FIGURE 11-24.** Squamous cell carcinoma. **A**, Tumor arising in erythroleukoplakia. **B**, Indurated ulcer in floor of mouth with background of faint leukoplakia (anterior). **C**, Mass in buccal mucosa. **D**, Tumor arising in erythroleukoplakia in areca nut chewer (note brown-red staining of teeth). **E**, One-cm indurated mass in floor of mouth had already metastasized to ipsilateral lymph node (stage III).



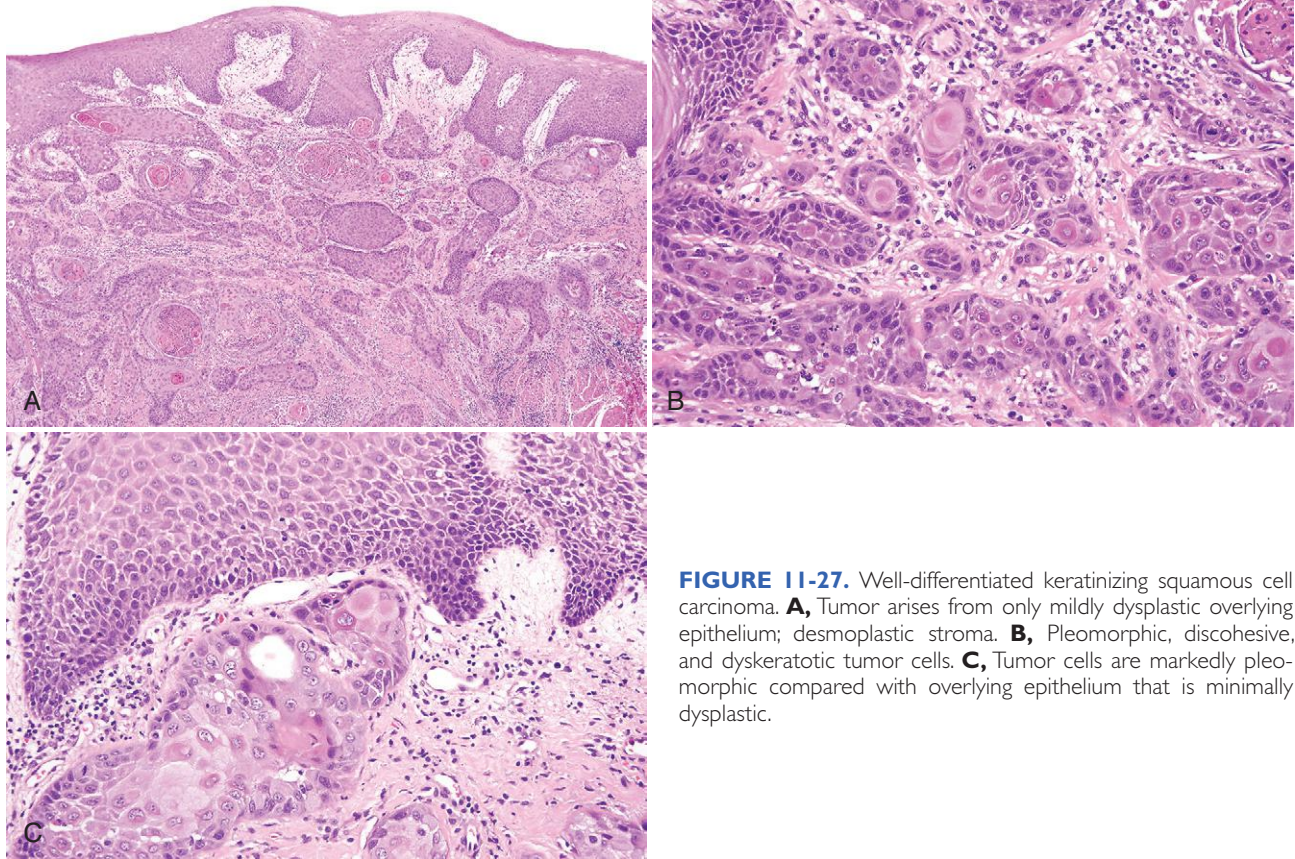


**FIGURE 11-25.** Well-differentiated keratinizing squamous cell carcinoma. **A**, Tumor deeply infiltrates the tongue musculature. **B**, Tumor islands in muscle and marked chronic inflammatory response. **C**, Keratin pearl with intraepithelial microabscesses and foreign body reaction to keratin; many eosinophils are present.



**FIGURE 11-26.** Squamous cell carcinoma, minimally keratinizing. **A**, Tumor forms little keratin. **B**, Pleomorphic cells with discohesion with slightly spindled cells. **C**, Atypical squamous cells with abundant pale cytoplasm and dyskeratosis.





**FIGURE 11-27.** Well-differentiated keratinizing squamous cell carcinoma. **A**, Tumor arises from only mildly dysplastic overlying epithelium; desmoplastic stroma. **B**, Pleomorphic, discohesive, and dyskeratotic tumor cells. **C**, Tumor cells are markedly pleomorphic compared with overlying epithelium that is minimally dysplastic.

### SARCOMATOID SQUAMOUS CELL CARCINOMA

- Lesion usually appears in the posterior oral cavity and is polypoid and ulcerated in nature (Fig. 11-28, A); tumor may be associated with history of radiation (see Fig. 11-28, B).
- Biphasic cell population; often reveals polypoid proliferation of atypical epithelioid and stellate-shaped cells, as well as spindle cells with a fasciculated or storiform pattern; spindle cells are cytokeratin (especially AE1/3), vimentin, and p63 positive, and S-100, CD10, and calponin negative; pleomorphic cells and mitoses frequently are encountered, and there is overlying epithelial dysplasia; in most cases, conventional keratinizing squamous cell carcinoma is present at the edges of the tumor (Figs. 11-29 to 11-31); rarely, osseous prosoplasia is present.
- Differential diagnoses: nodular fasciitis has feathery or tissue culture myxoid appearance, does not show significant atypia, and spindle cells are cytokeratin negative and SMA positive (Fig. 11-32); desmoplastic melanoma is S-100 positive and may be HMB-45 and Melan-A negative, and cytokeratin negative; spindle cell mesenchymal neoplasms will not have a conventional squamous cell carcinoma with cytokeratin and vimentin-positive cells; myoepithelial carcinomas are positive for S-100 protein and calponin;

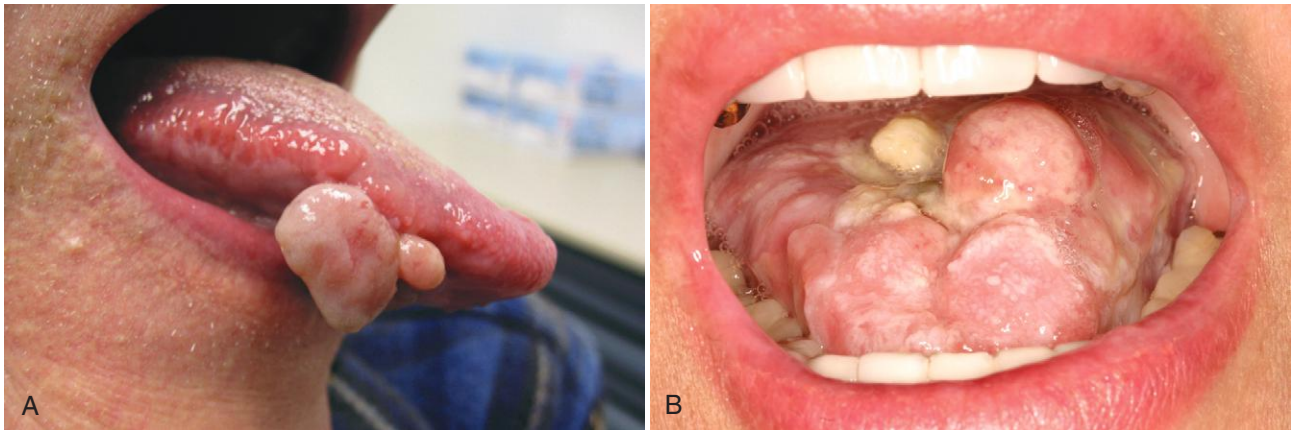
fibroblasts with radiation-induced atypia do not contain cytokeratin.

- Prognosis: 3-year survival is only 28% in some studies; others show that polypoid lesions have better prognosis compared with deeply infiltrating lesions.

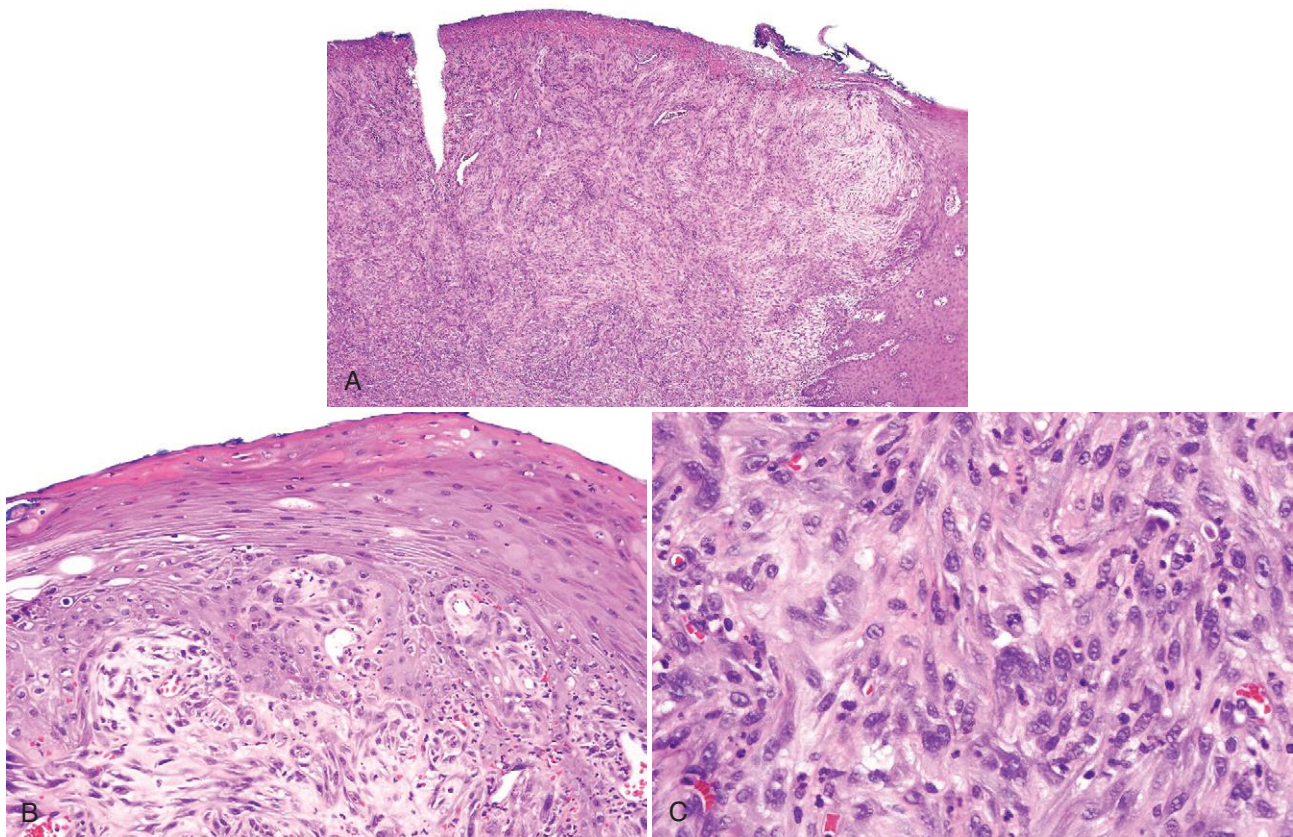
### REFERENCES

- Choi HR, Sturgis EM, Rosenthal DI, et al. Sarcomatoid carcinoma of the head and neck: molecular evidence for evolution and progression from conventional squamous cell carcinomas. *Am J Surg Pathol.* 2003;27:1216-1220.
- Ellis GL, Corio RL. Spindle cell carcinoma of the oral cavity. *Oral Surgery Oral Medicine Oral Pathol.* 1980;50:523-534.
- Ellis GL, Langloss JM, Heffner DK, Hyams VJ. Spindle-cell carcinoma of the aerodigestive tract. *Am J Surg Pathol.* 1987;11:335-342.
- Su HH, Chu ST, Hou YY, et al. Spindle cell carcinoma of the oral cavity and oropharynx: factors affecting outcome. *J Chin Med Assoc.* 2006;69:478-483.
- Thompson LD, Wieneke JA, Miettinen M, Heffner DK. Spindle cell (sarcomatoid) carcinomas of the larynx: a clinicopathologic study of 187 cases. *Am J Surg Pathol.* 2002;26:153-170.
- Viswanathan S, Rahman K, Pallavi S, et al. Sarcomatoid (spindle cell) carcinoma of the head and neck mucosal region: a clinicopathologic review of 103 cases from a tertiary referral cancer centre. *Head Neck Pathol.* 2010;4:265-275. Epub.
- Weidner N, Askin FB, Berthrong M, et al. Bizarre (pseudomalignant) granulation-tissue reactions following ionizing-radiation exposure. A microscopic, immunohistochemical, and flow-cytometric study. *Cancer.* 1987;59:1509-1514.
- Zarbo RJ, Crissman JD, Venkat H, Weiss MA. Spindle-cell carcinoma of the upper aerodigestive tract mucosa. *Am J Surg Pathol.* 1986;10:741-753.



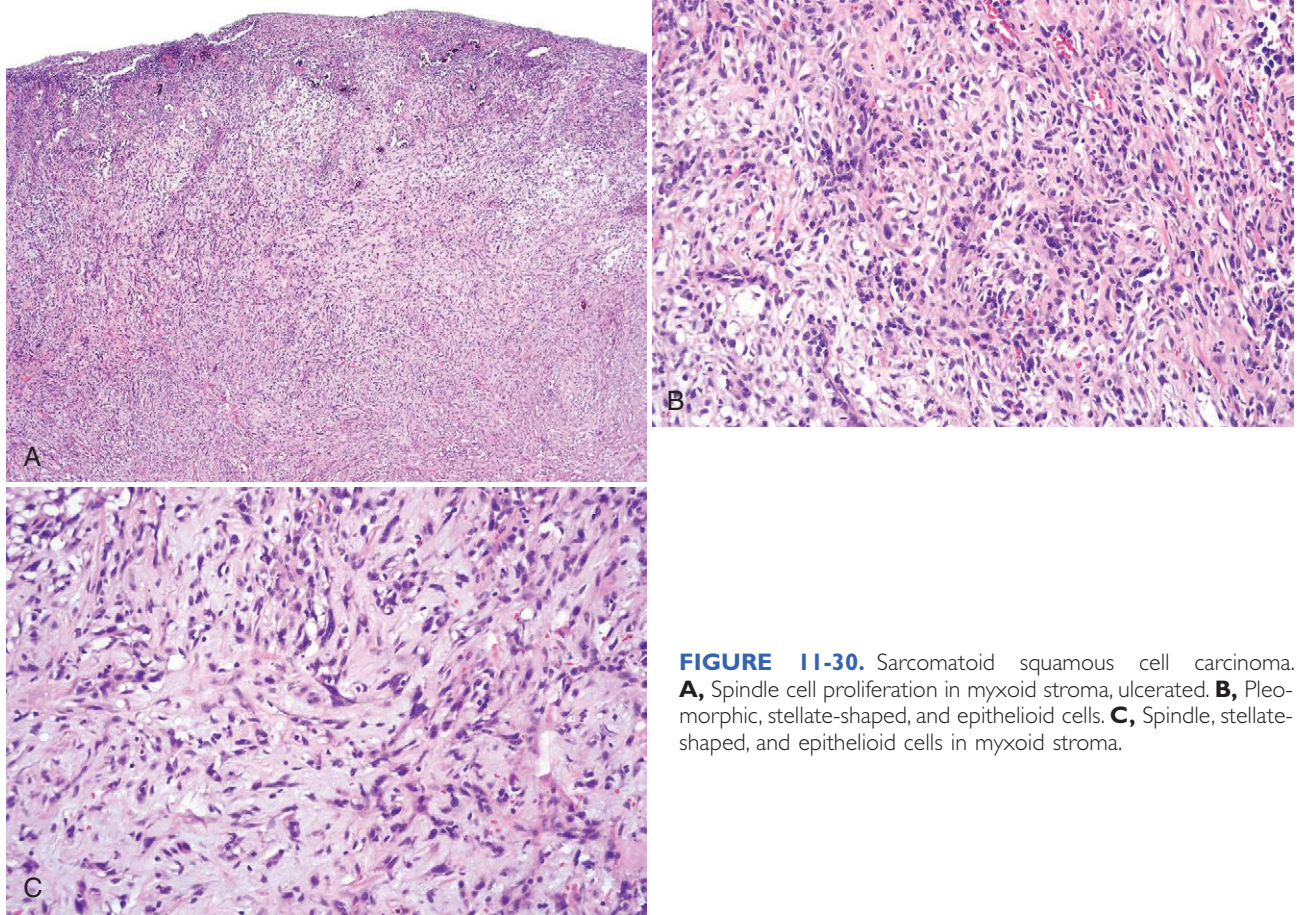


**FIGURE 11-28.** **A**, Sarcomatoid squamous cell carcinoma of right tongue manifesting as a polypoid mass. **B**, Sarcomatoid squamous cell carcinoma: tumor of the tongue dorsum in a patient previously irradiated for a squamous cell carcinoma of the left side of the tongue. (**A**, Courtesy of Division of Dermatology, Brigham and Women's Hospital, Boston, Mass.)

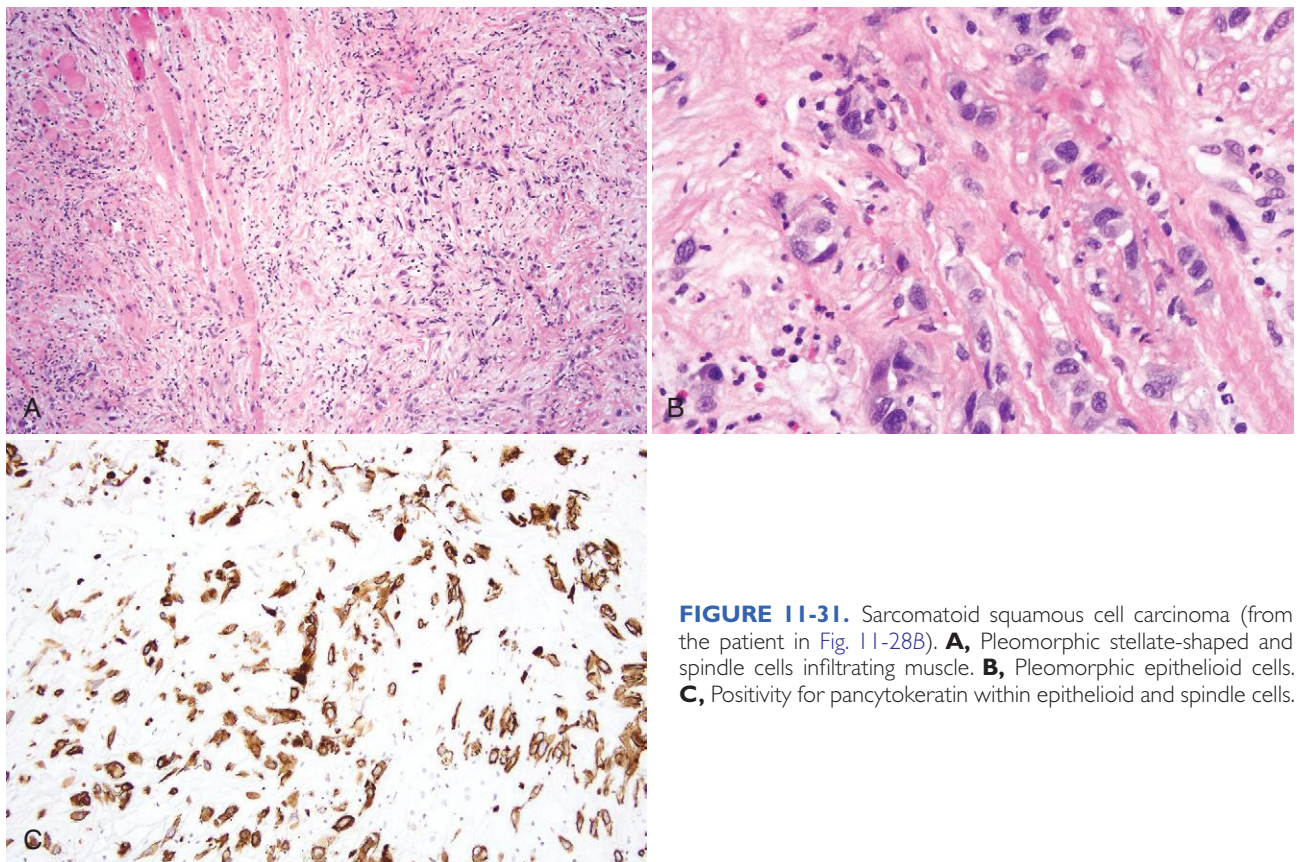


**FIGURE 11-29.** Sarcomatoid squamous cell carcinoma. **A**, Spindle cell proliferation in short fascicles with storiform pattern, ulcerated. **B**, Interface of invasive spindle cells and mildly dysplastic surface epithelium. **C**, Epithelioid and spindle cells with pleomorphic nuclei.



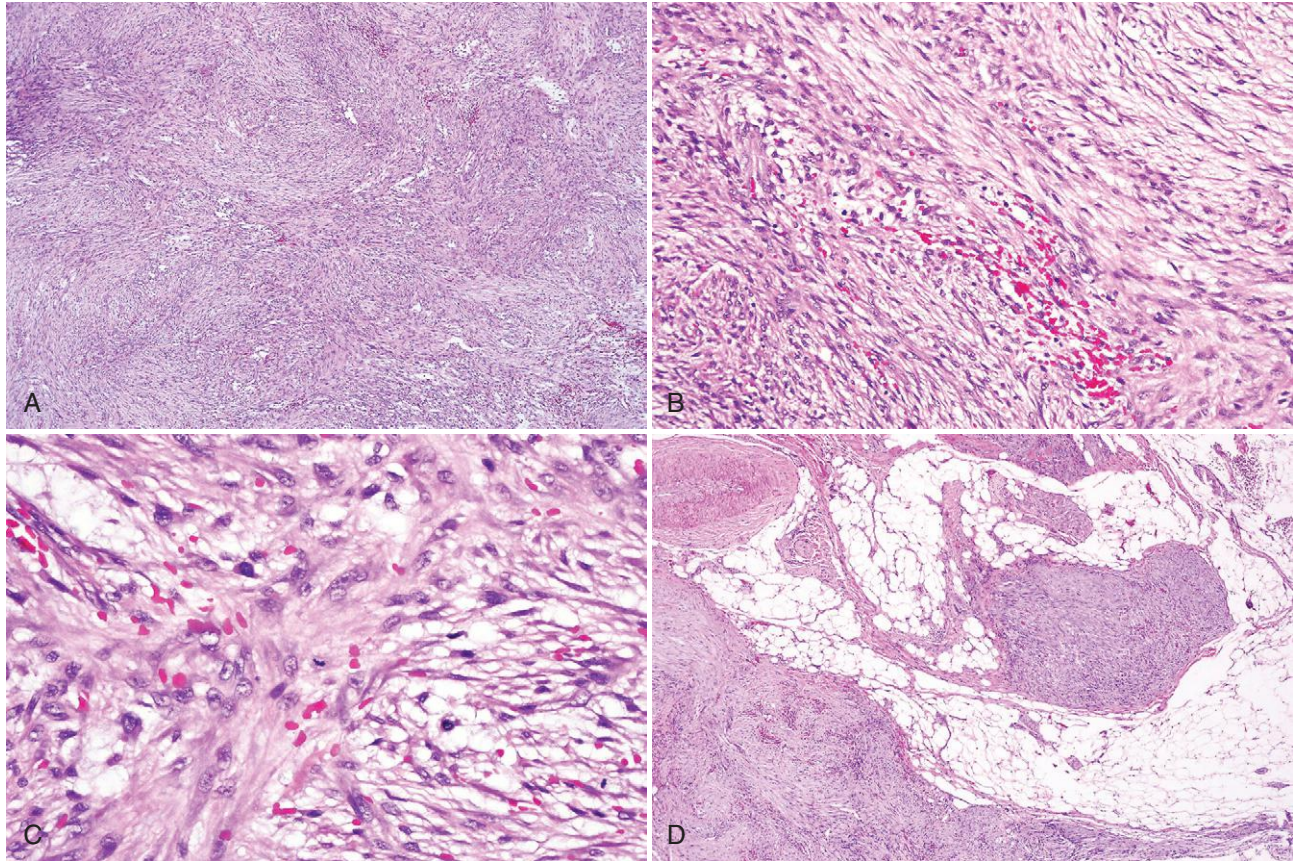


**FIGURE 11-30.** Sarcomatoid squamous cell carcinoma. **A**, Spindle cell proliferation in myxoid stroma, ulcerated. **B**, Pleomorphic, stellate-shaped, and epithelioid cells. **C**, Spindle, stellate-shaped, and epithelioid cells in myxoid stroma.



**FIGURE 11-31.** Sarcomatoid squamous cell carcinoma (from the patient in Fig. 11-28B). **A**, Pleomorphic stellate-shaped and spindle cells infiltrating muscle. **B**, Pleomorphic epithelioid cells. **C**, Positivity for pancytokeratin within epithelioid and spindle cells.





**FIGURE 11-32.** Nodular fasciitis. **A**, Proliferation of streaming fascicles of spindle cells in myxoid stroma. **B**, Spindle cells have loose, feathery cell-culture appearance with extravasated red blood cells. **C**, Spindle cells have large reactive nuclei and mitotic activity. **D**, Lesion extends into fat.

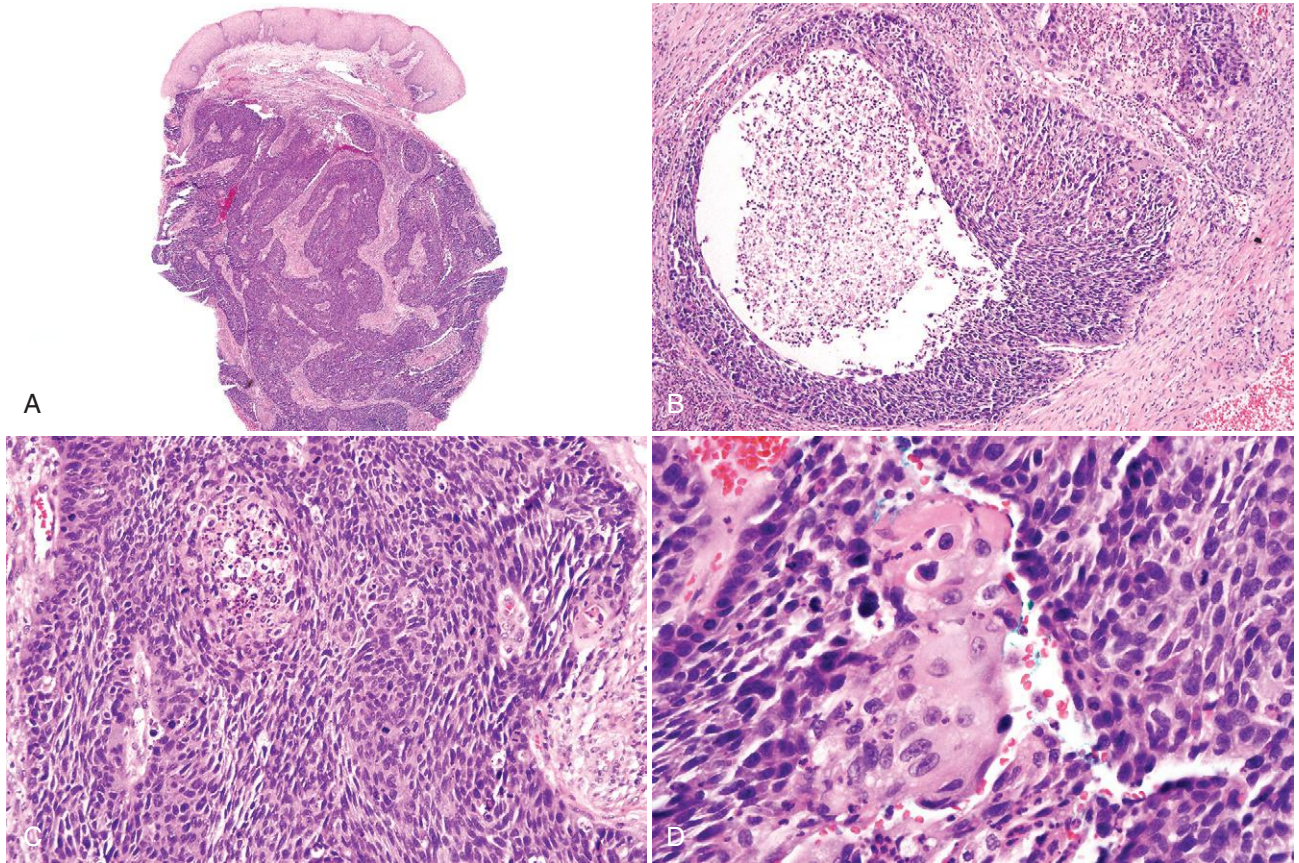
### BASALOID SQUAMOUS CELL CARCINOMA

- Usually in the posterior oral cavity; generally discovered at late stage with nodal involvement and poor survival
- Biphasic pattern; proliferation of lobules and sometimes trabeculae of basaloid cells often with comedonecrosis and areas of hyalinization; cells basaloid with hyperchromatic nuclei, scant cytoplasm, indistinct cell borders; many mitoses; should recognize conventional squamous cell carcinoma in lesion (Figs. 11-33 to 11-35); some cases may be positive for high-risk HPV.
- Differential diagnoses: neuroendocrine carcinomas are chromogranin, synaptophysin, and glial fibrillary acidic protein (GFAP) positive, and they would not contain conventional squamous cell carcinoma; HPV-associated oropharyngeal nonkeratinizing squamous cell carcinoma—a distinct subtype of head and neck carcinoma that has basaloid morphology (discussed subsequently)
- Prognosis: 3-year survival approximately 35%

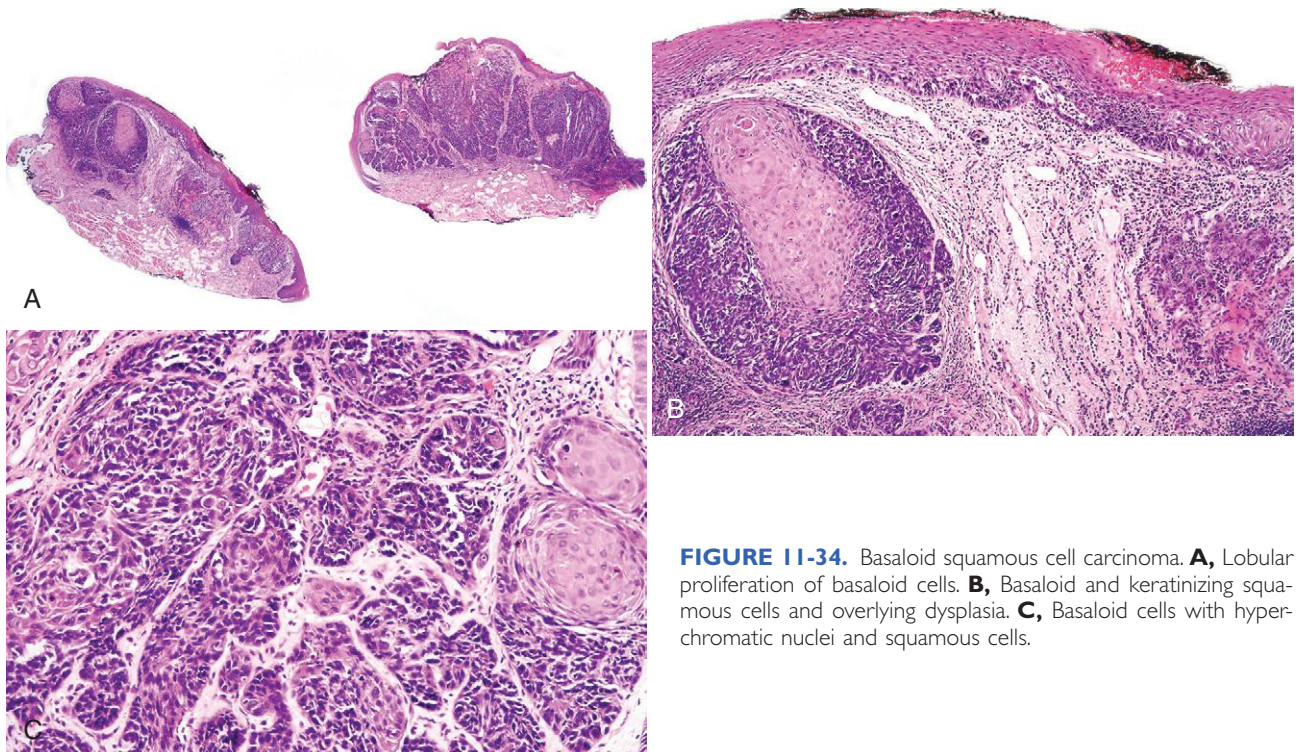
### REFERENCES

- Barnes L, MacMillan C, Ferlito A, Rinaldo A, et al. Basaloid squamous cell carcinoma of the head and neck: clinicopathological features and differential diagnosis. *Ann Otol Rhinol Laryngol.* 1996;105:75-82.
- Begum S, Westra WH. Basaloid squamous cell carcinoma of the head and neck is a mixed variant that can be further resolved by HPV status. *Am J Surg Pathol.* 2008;32:1044-1050.
- Chernock RD, Lewis JS Jr, Zhang Q, El-Mofty SK. Human papillomavirus-positive basaloid squamous cell carcinomas of the upper aerodigestive tract: a distinct clinicopathologic and molecular subtype of basaloid squamous cell carcinoma. *Hum Pathol.* 2010;41:1016-1023.
- Ereno C, Gaafar A, Garmendia M, et al. Basaloid squamous cell carcinoma of the head and neck: a clinicopathological and follow-up study of 40 cases and review of the literature. *Head Neck Pathol.* 2008;2:83-91.
- Friedrich RE, Sperber C, Jakel T, et al. Basaloid lesions of oral squamous epithelial cells and their association with HPV infection and P16 expression. *Anticancer Res.* 2010;30:1605-1612.
- Wain SL, Kier R, Vollmen RT, Bossen EH. Basaloid-squamous carcinoma of the tongue, hypopharynx, and larynx: report of 10 cases. *Hum Pathol.* 1986;17:1158-1166.



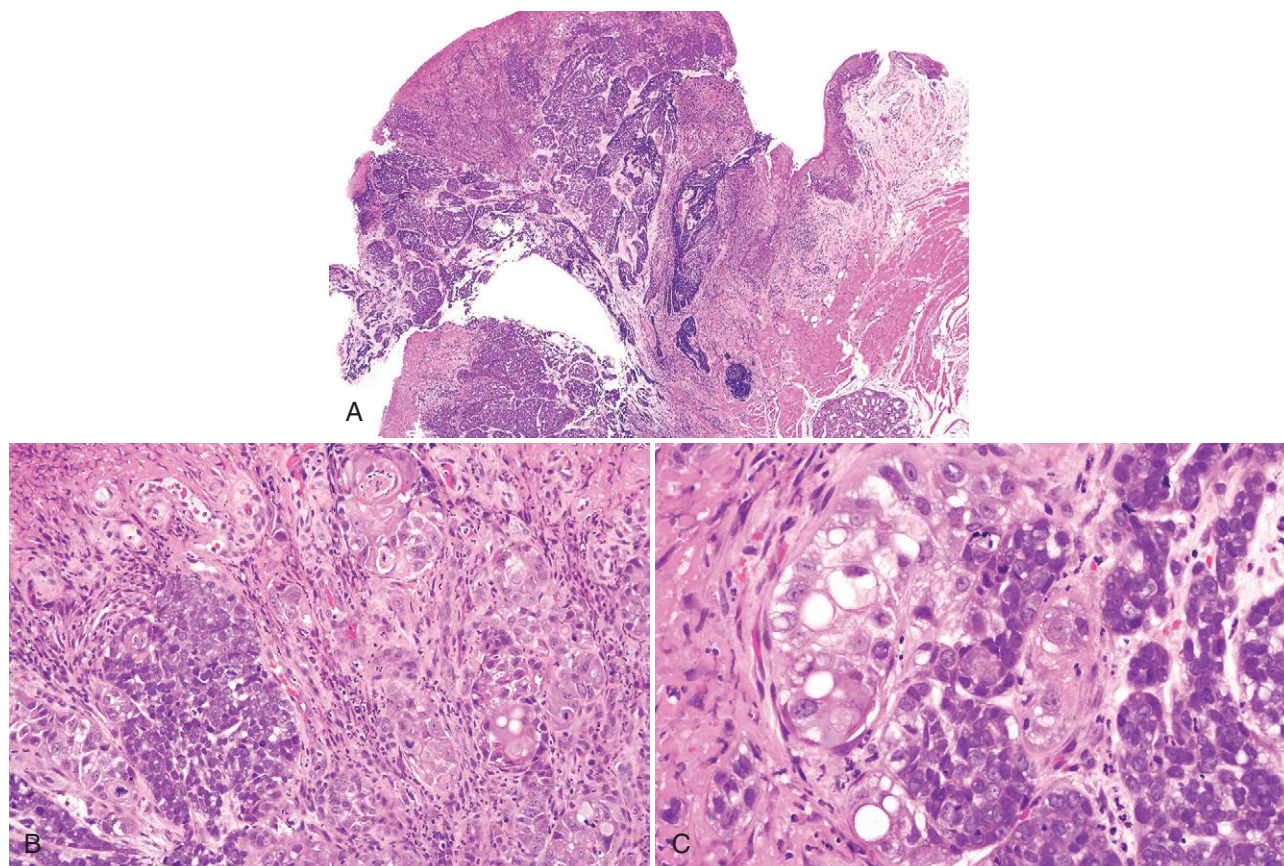


**FIGURE 11-33.** Basaloid squamous cell carcinoma. **A**, Proliferation of trabeculae and cords of basaloid cells with necrosis. **B**, Basaloid and squamous cells with comedonecrosis and keratinization (*right*). **C**, Basaloid and squamous cells with focal necrosis and many mitotic figures. **D**, Focus of keratin pearl formation.



**FIGURE 11-34.** Basaloid squamous cell carcinoma. **A**, Lobular proliferation of basaloid cells. **B**, Basaloid and keratinizing squamous cells and overlying dysplasia. **C**, Basaloid cells with hyperchromatic nuclei and squamous cells.





**FIGURE 11-35.** Basaloid squamous cell carcinoma. **A**, Lobules and large islands of basaloid cells and conventional squamous cell carcinoma. **B**, Transition between basaloid and squamous cells present (bottom). **C**, Basaloid cells with large, hyperchromatic nuclei and pleomorphic squamous cells.

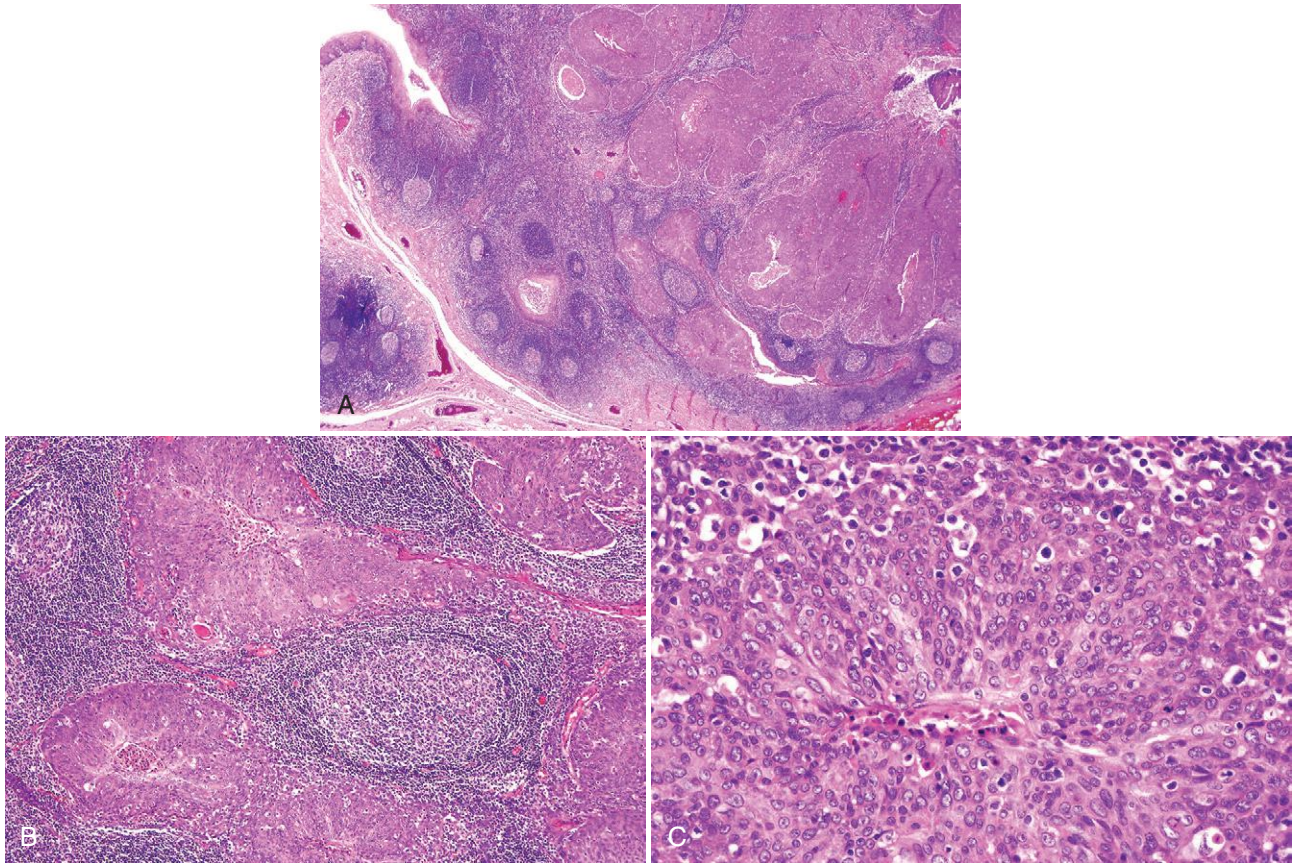
### HUMAN PAPILLOMAVIRUS–ASSOCIATED OROPHARYNGEAL AND TONSILLAR NONKERATINIZING SQUAMOUS CELL CARCINOMA

- Patients are 5 to 10 years younger, and disease is mostly in the oropharynx; not strongly associated with smoking.
- Cells are ovoid with indistinct cytoplasmic outlines, moderate amounts of pale cytoplasm, and ovoid nuclei with small nucleoli and dispersed chromatin; they are positive for HPV-16 (most common), -18, -31, -33 or -35, p16, and epidermal growth factor receptors (Figs. 11-36 to 11-38).
- Nodal metastases are usually present; conversely, carcinomas (often cystic) that are p16 positive within cervical nodes usually represent metastases from occult primary tumors in the oropharynx or tonsil.
- Differential diagnosis: basaloid squamous cell carcinoma has conventional squamous cell carcinoma; however, some HPV-associated carcinomas may be keratinizing, and some basaloid squamous cell carcinomas may be HPV and p16 positive.
- Prognosis: 3-year survival is significantly better than for conventional squamous cell carcinoma (82% vs. 57%); prognosis may also be improved if tumor is p16 positive regardless of HPV status.

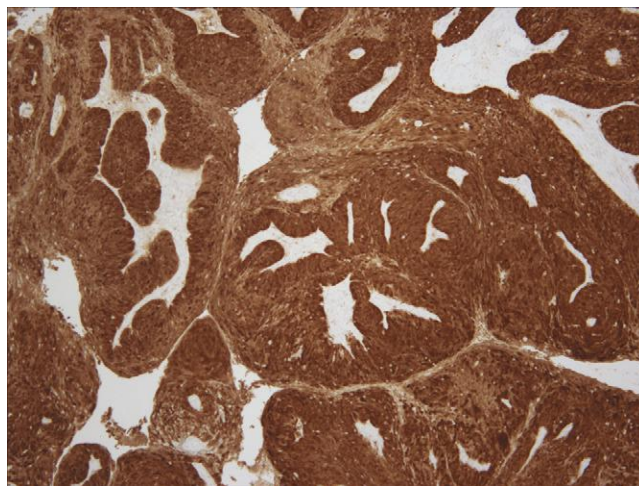
#### REFERENCES

- Ang KK, Harris J, Wheeler R, et al. Human papillomavirus and survival of patients with oropharyngeal cancer. *N Engl J Med.* 2010;363:24-35.
- El-Mofty SK, Patil S. Human papillomavirus (HPV)-related oropharyngeal nonkeratinizing squamous cell carcinoma: characterization of a distinct phenotype. *Oral Surg Oral Med Oral Pathol Oral Radiol Endod.* 2006;101:339-345.
- El-Mofty SK, Zhang MQ, Davila RM. Histologic identification of human papillomavirus (HPV)-related squamous cell carcinoma in cervical lymph nodes: a reliable predictor of the site of an occult head and neck primary carcinoma. *Head Neck Pathol.* 2008;2:163-168.
- Lewis Jr JS, Thorstad WL, Chernock RD, et al. p16 positive oropharyngeal squamous cell carcinoma: an entity with a favorable prognosis regardless of tumor HPV status. *Am J Surg Pathol.* 2010;34:1088-1096.
- Reimers N, Kasper HU, Weissenborn SJ, et al. Combined analysis of HPV-DNA, p16 and EGFR expression to predict prognosis in oropharyngeal cancer. *Int J Cancer.* 2007;120:1731-1738.



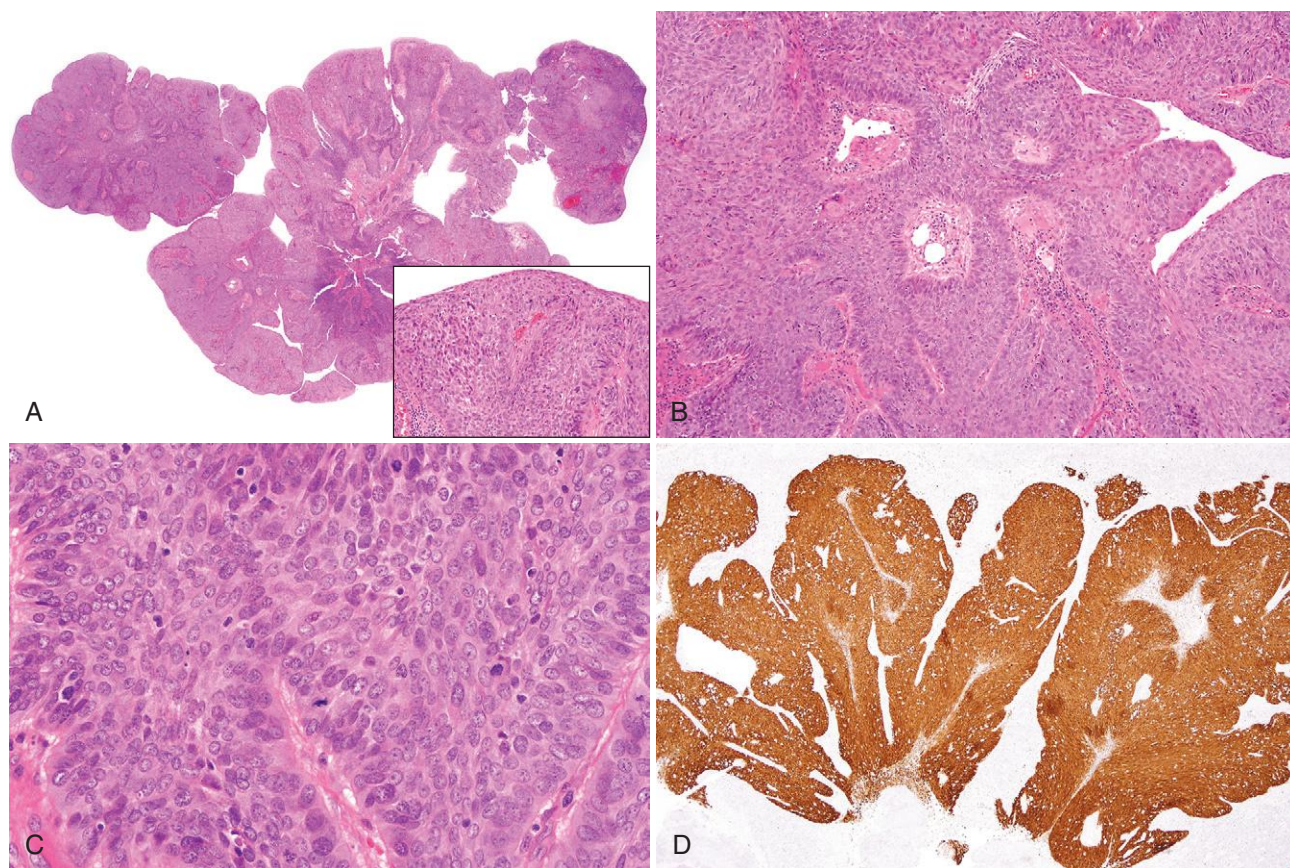


**FIGURE 11-36.** Human papillomavirus–associated carcinoma of the tonsil. **A**, Trabeculae and ribbons of squamous cells within tonsil. **B**, Tumor exhibits comedonecrosis and is infiltrated by lymphocytes. **C**, Pleomorphic nuclei, mitoses, and early necrosis. (**A**, Courtesy of Dr. Jeffrey Krane, Harvard Medical School, Boston, Mass.)



**FIGURE 11-37.** Human papillomavirus–associated carcinoma of the tonsil: tumor is strongly positive for p16. (Courtesy of Dr. Jeffrey Krane, Harvard Medical School, Boston, Mass.)





**FIGURE 11-38.** Human papillomavirus (HPV)-associated papillary squamous cell carcinoma. **A**, Nonkeratinizing tumor composed of full-thickness dysplastic epithelium in papillary configuration; tumor was positive for HPV-16. **B**, Complex arborizing ribbons and trabeculae of tumor cells. **C**, Nuclear pleomorphism and mitotic activity with no keratin formation. **D**, Tumor shows strong p16 positivity.

### ADENOID SQUAMOUS CELL CARCINOMA

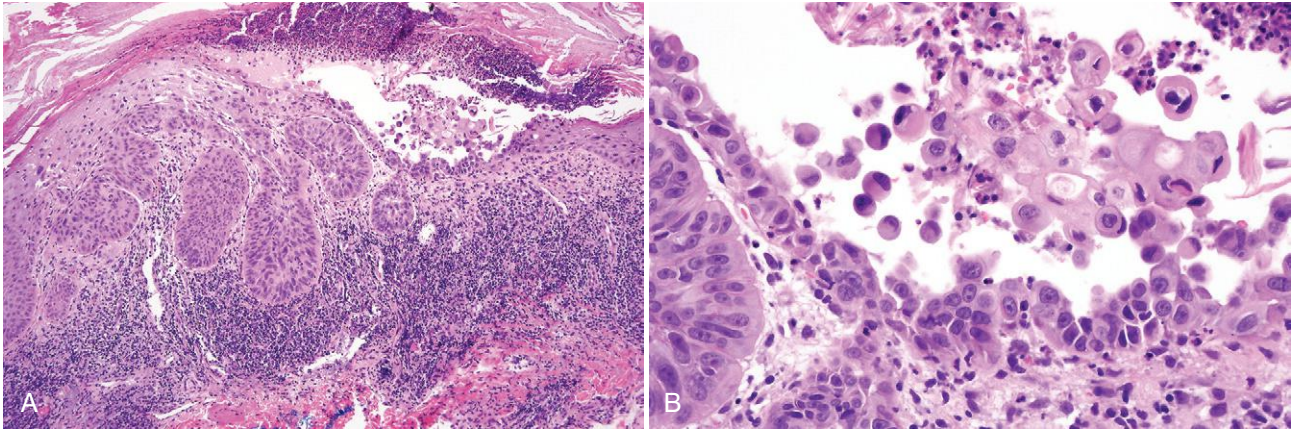
- Usually on the lower lip; male predominance
- Biphasic pattern; proliferation of malignant squamous epithelium with acantholysis (usually marked) and/or formation of pseudoglandular structures (Fig. 11-39); should recognize conventional keratinizing squamous cell carcinoma (Fig. 11-40); subtle acantholysis may suggest vascular lumen formation
- Differential diagnoses: adenocarcinomas of salivary gland or skin adnexal origin if conventional squamous cell carcinoma not present; true acantholytic lesions, such as focal acantholytic dyskeratosis, display dyskeratotic cells without cytologic atypia and are not invasive, although these must be distinguished from acantholytic carcinoma in situ; angiosarcomas are CD31 positive

- Prognosis: more aggressive behavior in the oral cavity than on sun-exposed skin

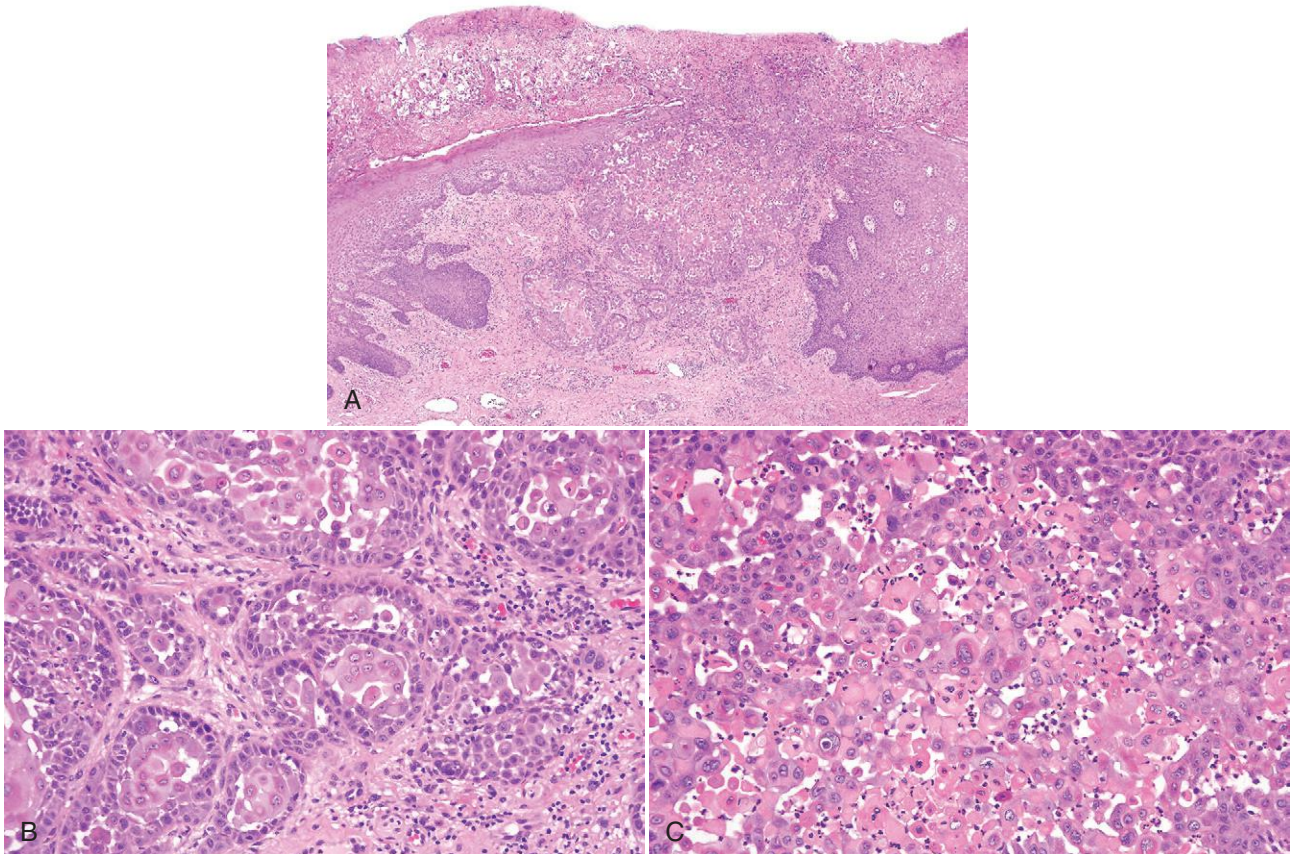
### REFERENCES

- Driemel O, Muller-Richter UD, Hakim SG, et al. Oral acantholytic squamous cell carcinoma shares clinical and histological features with angiosarcoma. *Head Face Med.* 2008;4:17.
- Ferlito A, Devaney KO, Milroy CM, et al. Mucosal adenoid squamous cell carcinoma of the head and neck. *Ann Otol Rhinol Laryngol.* 1996;105:409-413.
- Jones AC, Freedman PD, Kerpel SM. Oral adenoid squamous cell carcinoma: a report of three cases and review of the literature. *J Oral Maxillofac Surg.* 1993;51:676-681.
- Kusafuka K, Ebihara M, Ishiki H, et al. Primary adenoid squamous cell carcinoma of the oral cavity. *Pathol Int.* 2006;56:78-83.
- Papadopoulou E, Tosios KI, Nikitakis N, et al. Acantholytic squamous cell carcinoma of the gingiva: report of a case and review of the literature. *Oral Surg Oral Med Oral Pathol Oral Radiol Endod.* 2010;109:e67-71.





**FIGURE 11-39.** Adenoid squamous cell carcinoma of lip. **A**, Tumor is early invasive with a focus of acantholysis arising within carcinoma in situ. **B**, Pleomorphic acantholytic cells within carcinoma in situ.



**FIGURE 11-40.** Adenoid squamous cell carcinoma. **A**, Infiltrating squamous cell carcinoma with acantholysis. **B**, Pseudoglandular spaces containing acantholytic pleomorphic cells. **C**, Large, round, pleomorphic acantholytic cells with abundant eosinophilic cytoplasm.



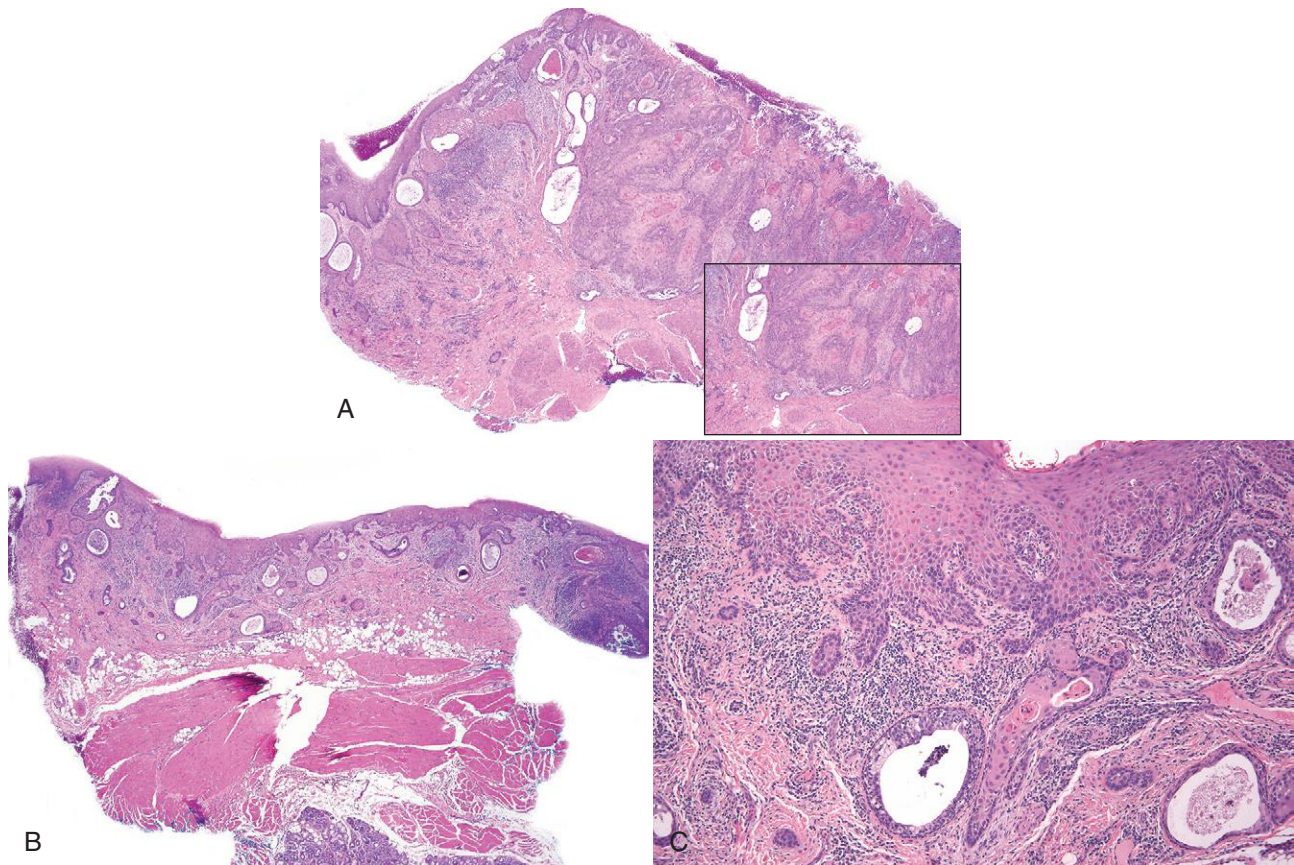
### ADENOSQUAMOUS CELL CARCINOMA

- Occurs most commonly in the posterior oral cavity in males, after which the larynx, floor of mouth, and tongue are common intraoral sites.
- Biphasic pattern; proliferation of malignant squamous and basaloid epithelial cells with the formation of ductlike structures containing mucous cells; often carcino-embryonic antigen (CEA), CAM 5.2, and CK7 positive); adenocarcinoma in situ or otherwise and conventional squamous cell carcinoma seen with overlying dysplasia (Figs. 11-41 and 11-42); perineural invasion is seen in some cases; 16% associated with high-risk HPV and p16 positivity.
- Differential diagnoses: mucoepidermoid carcinoma shows less cytologic atypia (except for high-grade lesions) and keratinizing squamous cell carcinoma is not identified.

- Prognosis is poor, with 45% exhibiting local recurrence, 65% with nodal metastases, and 40% to 50% dying of disease within 2 years.

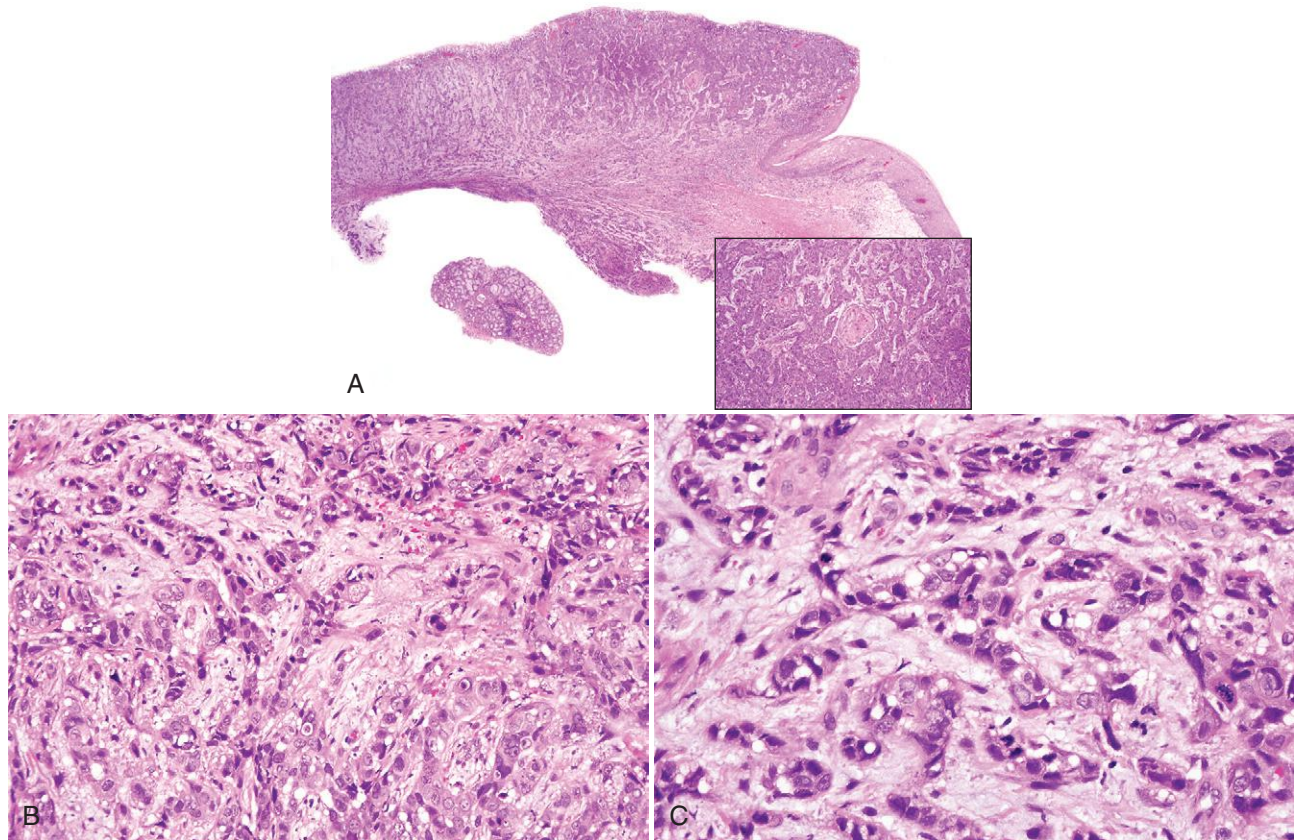
#### REFERENCES

- Alos L, Castillo M, Nadal A, et al. Adenosquamous carcinoma of the head and neck: criteria for diagnosis in a study of 12 cases. *Histopathology*. 2004;44:570-579.
- Gerughty RM, Hennigar GR, Brown FM. Adenosquamous carcinoma of the nasal, oral and laryngeal cavities. *Cancer*. 1968;6:1140-1155.
- Keelawat S, Liu CZ, Roehm PC, Barnes L. Adenosquamous carcinoma of the upper aerodigestive tract: a clinicopathologic study of 12 cases and review of the literature. *Am J Otolaryngol*. 2002;23:160-168.
- Masand RP, El-Mofty SK, Ma XJ, et al. Adenosquamous carcinoma of the head and neck: relationship to human papillomavirus and review of the literature. *Head Neck Pathol*. 2011;5:108-116.



**FIGURE 11-41.** Adenosquamous cell carcinoma. **A**, Adenocarcinoma with conventional keratinizing squamous cell carcinoma. **B**, Another area showing primarily adenocarcinoma. **C**, Ductal structures lined by atypical squamous cells and mucous cells adjacent to infiltrating keratinizing squamous cell carcinoma.





**FIGURE 11-42.** Adenosquamous cell carcinoma. **A**, Infiltrating keratinizing squamous cell carcinoma. **B**, Islands and cords of pleomorphic tumor cells forming small ductlike structures. **C**, Pleomorphic tumor cells with intracytoplasmic lumina.

## VERRUCOUS CARCINOMA

- Lesions are often seen on the alveolar ridge, mandibular sulcus, or buccal mucosa in patients who use smokeless tobacco.
- Papillary exophytic and endophytic proliferation of squamous epithelium with marked parakeratosis and bulbous frondlike rete ridges with parakeratin plugging.
- Bulbous, frondlike rete ridges with smooth, rounded outlines are bluntly invasive, pushing into the stroma on a broad advancing front without single cell infiltration; minimal cytologic atypia; a lymphocytic band and subbasal clefting may be seen at the interface (Figs. 11-43 and 11-44).
- HPV can be seen in some cases, but p16 studies are lacking.
- Differential diagnoses: bluntly invasive papillary well-differentiated squamous cell carcinoma shows significant epithelial atypia, often with keratin pearls and microabscesses at the tips of rete ridges; serial sectioning is advisable to identify areas of single cell stromal infiltration and microinvasion (Fig. 11-45); condylo-ma acuminatum may appear similar, especially if

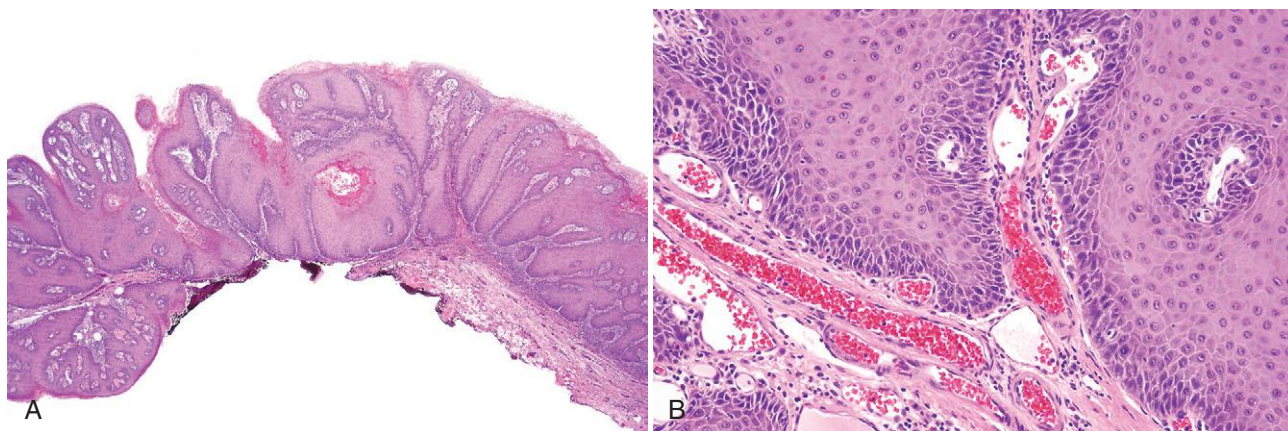
irritated and inflamed; cases of so-called hybrid verrucous carcinoma is likely a well-differentiated papillary squamous cell carcinoma.

- Prognosis: surgery is the treatment of choice; radiation therapy is controversial with reports of anaplastic transformation in some cases; correct diagnosis is key to appropriate therapy.

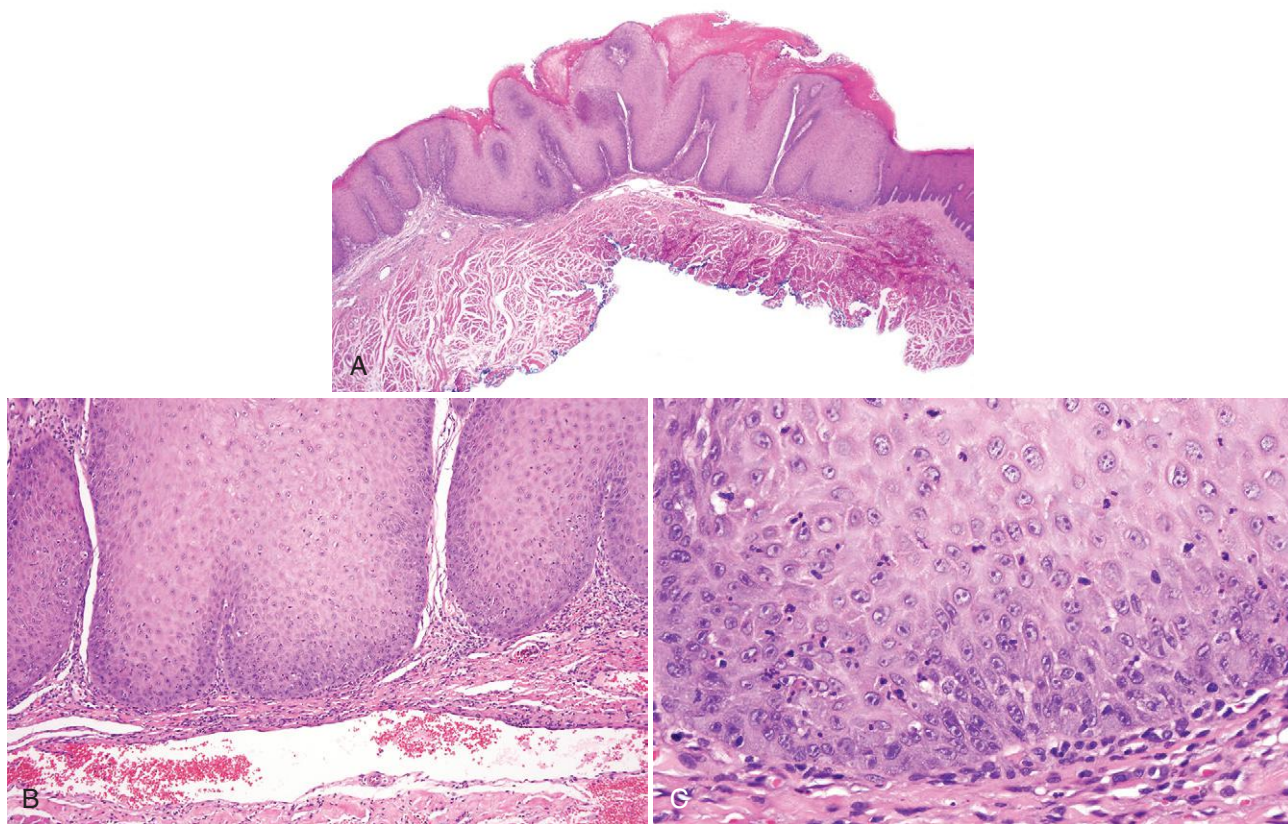
## REFERENCES

- Ferlito A, Devaney KO, Rinaldo A, Putzi MJ. Papillary squamous cell carcinoma versus verrucous squamous cell carcinoma of the head and neck. *Ann Otol Rhinol Laryngol.* 1999;108:318-322.
- Huang SH, Lockwood G, Irish J, et al. Truths and myths about radiotherapy for verrucous carcinoma of larynx. *Int J Radiat Oncol Biol Phys.* 2009;73:1110-1115.
- Koch BB, Trask DK, Hoffman HT, et al. National survey of head and neck verrucous carcinoma: patterns of presentation, care, and outcome. *Cancer.* 2001;92:110-120.
- McCoy JM, Waldron CA. Verrucous carcinoma of the oral cavity. *Oral Surg Oral Med Oral Pathol.* 1981;52:623-629.
- Oliveira DT, de Moraes RV, Fiamengui Filho JF, et al. Oral verrucous carcinoma: a retrospective study in Sao Paulo Region, Brazil. *Clin Oral Invest.* 2006;10:205-209.
- Walvekar RR, Chaukar DA, Deshpande MS, et al. Verrucous carcinoma of the oral cavity: A clinical and pathological study of 101 cases. *Oral Oncol.* 2009;45:47-51.



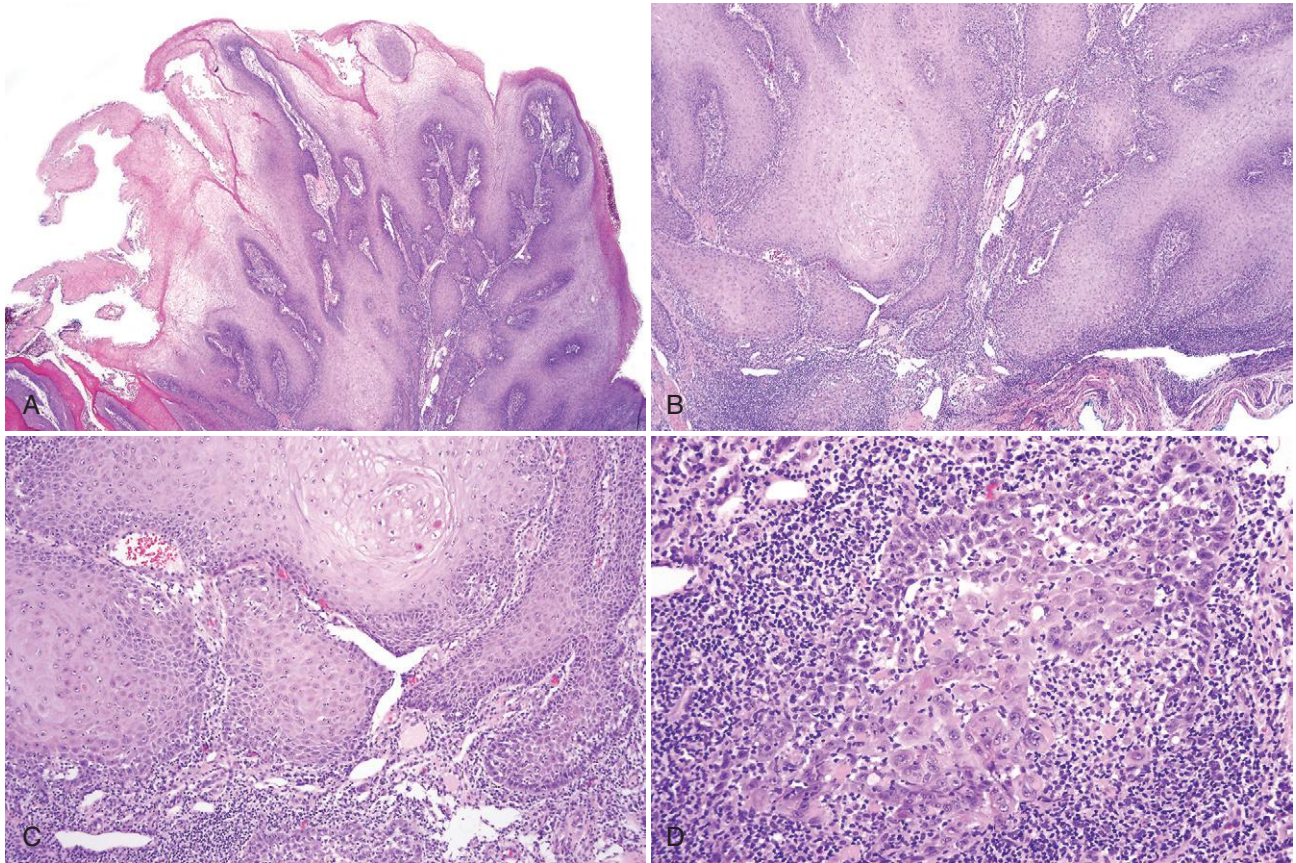


**FIGURE 11-43.** Verrucous carcinoma. **A**, Bluntly invasive endophytic growth with parakeratin plugging, frondlike bulbous rete ridges, and lymphocytic band at interface. **B**, Minimal cytologic atypia.



**FIGURE 11-44.** Verrucous carcinoma. **A**, Exophytic and endophytic papillary proliferation of epithelium with parakeratin plugging and bulbous rete ridges; cells have pale cytoplasm. **B**, Broad frondlike rete ridges with subepithelial cleft. **C**, Minimal cytologic atypia; cells have pale, glassy cytoplasm.





**FIGURE 11-45.** Well-differentiated papillary squamous cell carcinoma. **A**, Low-power view bears resemblance to verrucous carcinoma with hyperparakeratosis, bulbous rete ridges, and endophytic proliferation of pale epithelial cells. **B**, Moderate atypia and blunt infiltration of stroma with rounded, smooth, rete ridges in some areas; anastomosing complex architecture present. **C**, Base of rete ridges shows dyskeratosis; minimal cytologic atypia. **D**, One focus of highly atypical cells represents early microinvasive squamous cell carcinoma.

### PAPILLARY SQUAMOUS CELL CARCINOMA

- Papillary exophytic and endophytic proliferation of squamous epithelium that, unlike verrucous carcinoma, may show paraorthokeratosis or orthokeratosis, significant epithelial atypia, and often microabscesses at tips of bulbous rete ridges; tumor may be bluntly invasive or may invade as single cells or small islands of tumor cells (Figs. 11-46 and 11-47).
- A variant more common in the oropharynx resembles a sessile squamous papilloma with dysplasia; complex arborizing pattern and minimal-to-no surface keratin; blunt invasion rather than single cell infiltration of stroma is frequent; high-risk HPV and p16 has been identified in the majority of cases (Fig. 11-48; see Fig. 11-38, A-C).
- Differential diagnoses: well-differentiated squamous cell carcinoma with a keratoacanthomatous pattern (previously called keratoacanthoma) has a cup-shaped morphology with a central crater filled with keratin; cells have glassy cytoplasm, and infiltration of stroma may be similar to conventional squamous cell carcinoma or may be blunt (Fig. 11-49); this keratoacanthomatous pattern has been reported in carcinomas in children; pseudoepitheliomatous

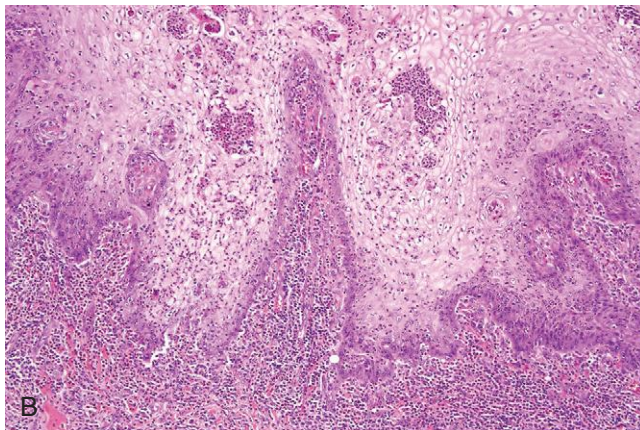
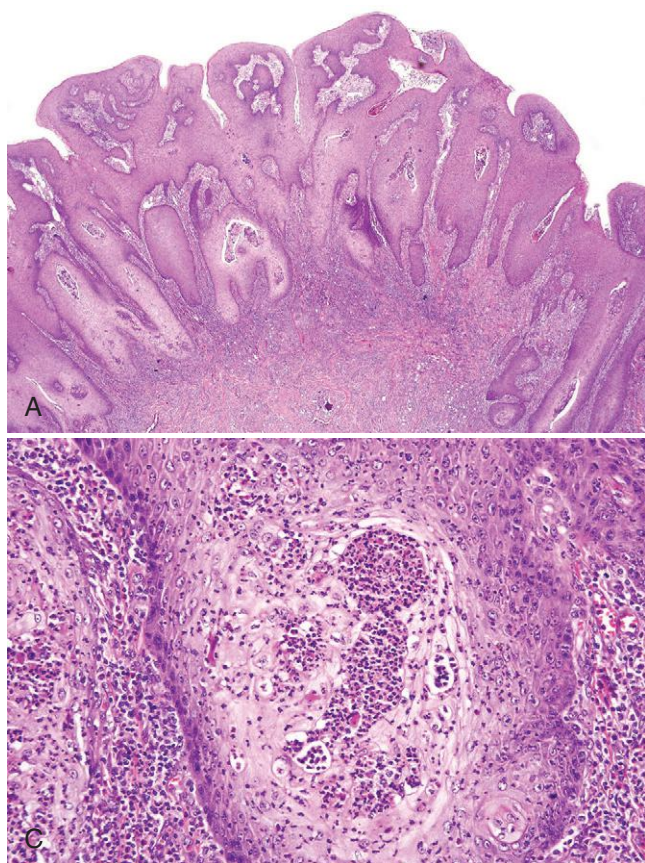
hyperplasia in reaction to candidiasis does not show the complex arborizing architecture and does not exhibit significant cytologic atypia.

- Prognosis: 44% of patients die of disease within 2 years; laryngeal tumors have a better prognosis than those at other sites.

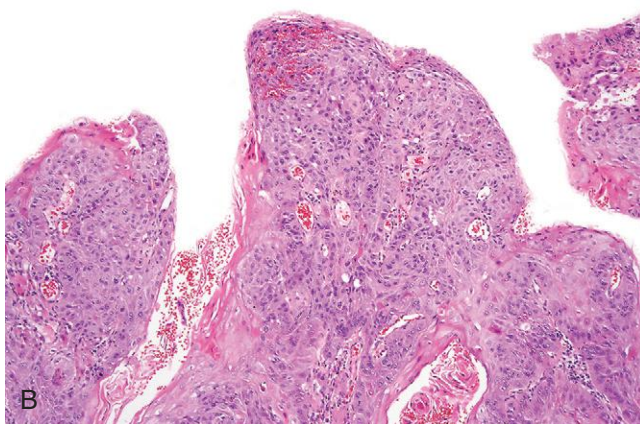
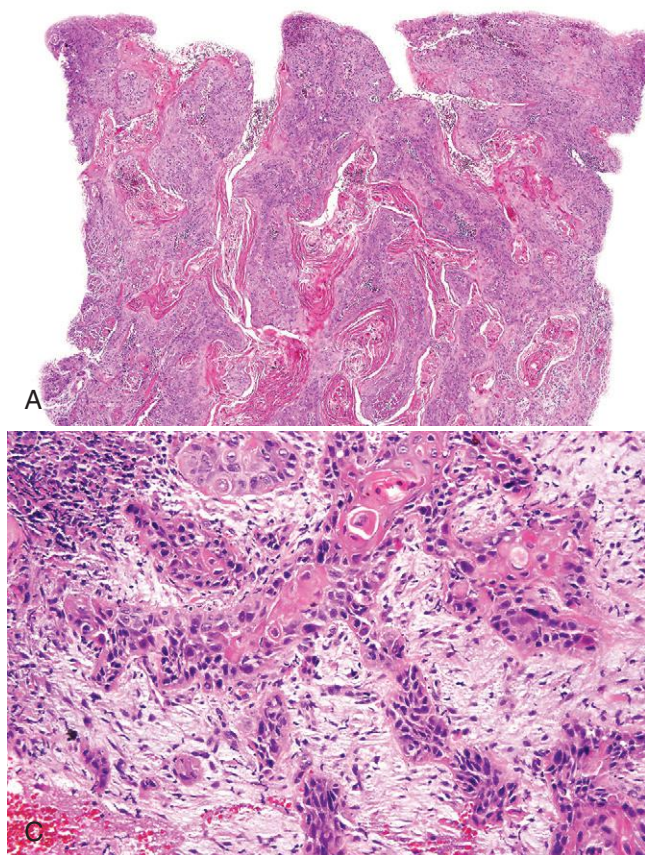
### REFERENCES

- Cobo F, Talavera P, Concha A. Review article: relationship of human papillomavirus with papillary squamous cell carcinoma of the upper aerodigestive tract: a review. *Int J Surg Pathol.* 2008;16:127-136.
- Jo VY, Mills SE, Stoler MH, Stelow EB. Papillary squamous cell carcinoma of the head and neck: frequent association with human papillomavirus infection and invasive carcinoma. *Am J Surg Pathol.* 2009;33:1720-1724.
- Karaa A, Khachemoune A. Keratoacanthoma: a tumor in search of a classification. *Int J Dermatol.* 2007;46:671-678.
- McKee P, Calonje E, Granter S, eds. *Pathology of the Skin.* 3rd ed. Philadelphia: Elsevier; 2005.
- Suarez PA, Adler-Storthz K, Luna MA, et al. Papillary squamous cell carcinomas of the upper aerodigestive tract: a clinicopathologic and molecular study. *Head Neck.* 2000;22:360-368.
- Thompson LD, Wenig BM, Heffner DK, Gnepp DR. Exophytic and papillary squamous cell carcinomas of the larynx: a clinicopathologic series of 104 cases. *Otolaryngol Head Neck Surg.* 1999;120:718-724.
- Woo VL, Kelsch RD, Su L, et al. Gingival squamous cell carcinoma in adolescence. *Oral Surg Oral Med Oral Pathol Oral Radiol Endod.* 2009;107:92-99.



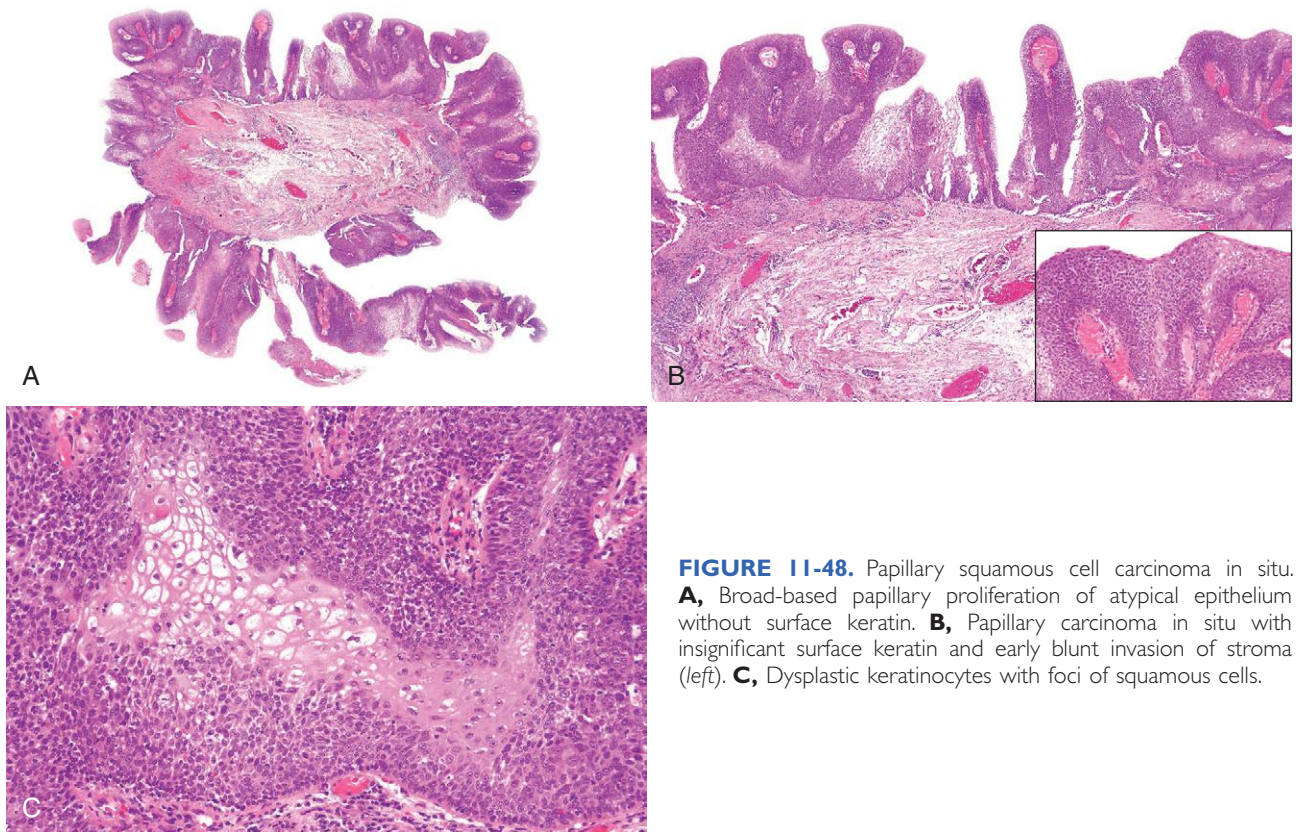


**FIGURE 11-46.** Papillary well-differentiated squamous cell carcinoma. **A**, Papillary tumor with little keratinization and many pale epithelial cells. **B**, Pale cells with significant cytologic atypia; many intraepithelial abscesses near tips of rete ridges. **C**, Atypical squamous cells with pale cytoplasm, intraepithelial abscesses, and eosinophils in the epithelium and stroma.

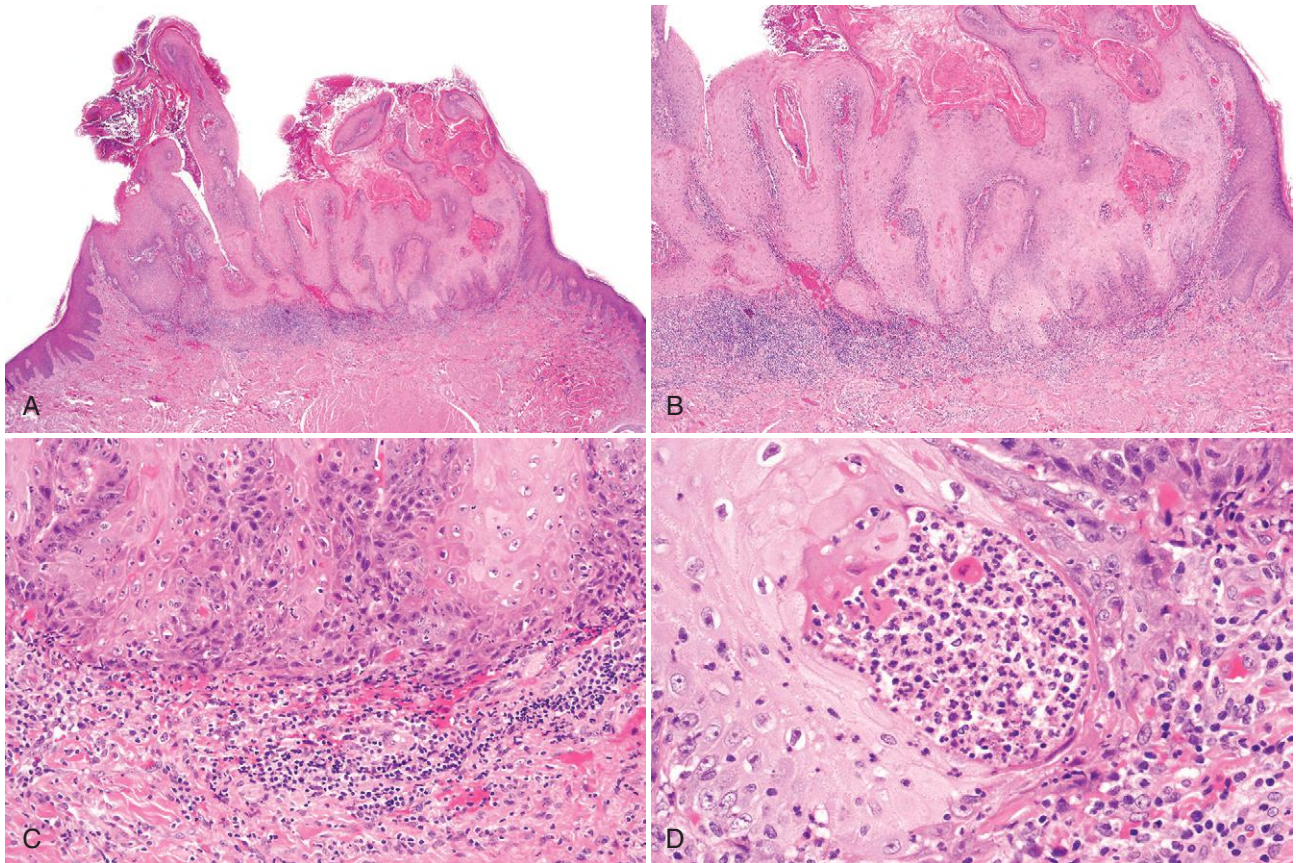


**FIGURE 11-47.** Papillary squamous cell carcinoma. **A**, Ribbons and trabeculae of atypical epithelial cells forming complex arborizing pattern with abundant parakeratin. **B**, Papillary projections have fibrovascular cores and abundant parakeratin. **C**, Deep component contains invasive pleomorphic islands of cells with dyskeratosis.





**FIGURE 11-48.** Papillary squamous cell carcinoma in situ. **A**, Broad-based papillary proliferation of atypical epithelium without surface keratin. **B**, Papillary carcinoma in situ with insignificant surface keratin and early blunt invasion of stroma (left). **C**, Dysplastic keratinocytes with foci of squamous cells.



**FIGURE 11-49.** Well-differentiated squamous cell carcinoma, keratoacanthomatous pattern. **A**, Papillary proliferation of pale squamous cells with endophytic, cupped morphology. **B**, Pale cells with broad pushing front and lymphocytic band. **C**, Pale cells with glassy cytoplasm and darker basaloid cells. **D**, Dyskeratotic cells and microabscesses at tips of rete ridges.



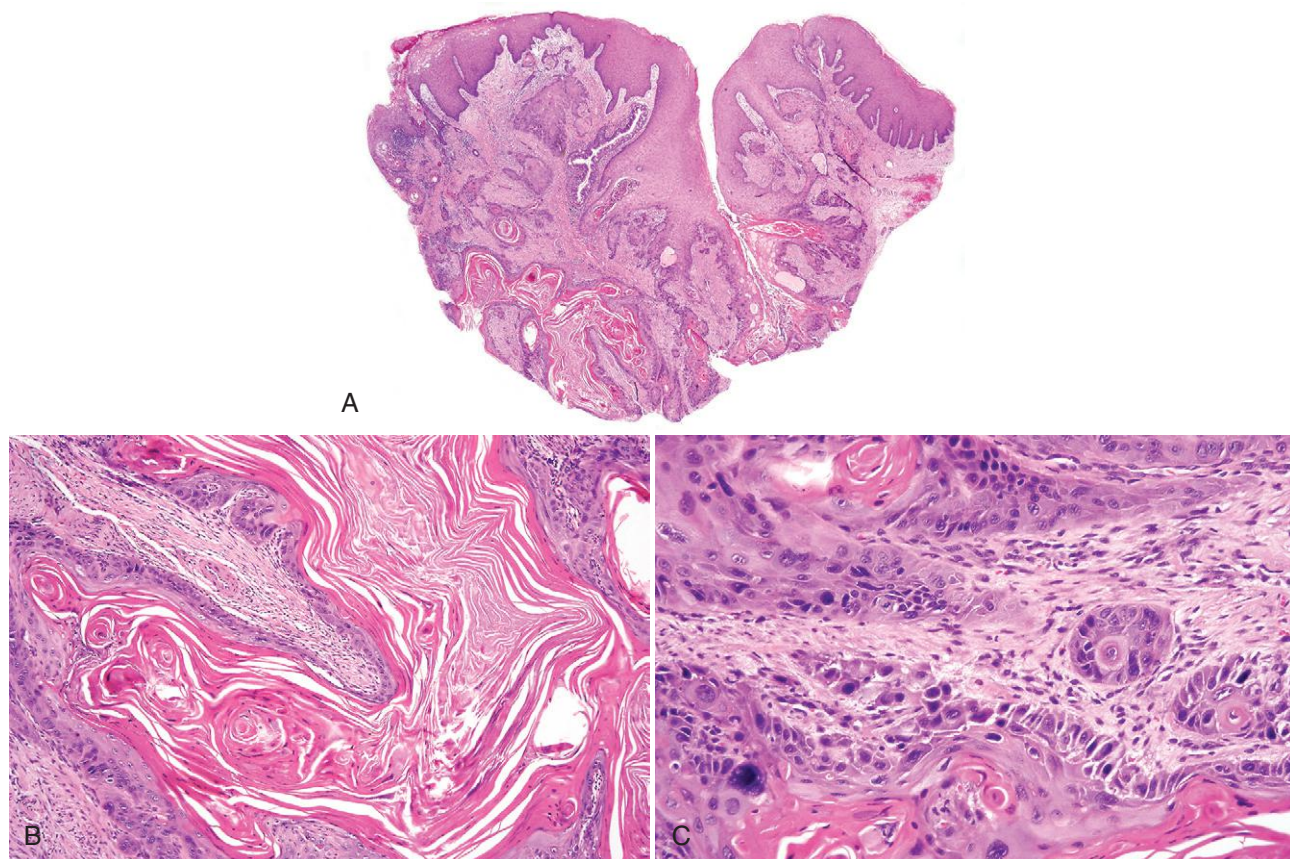
### CUNICULATE CARCINOMA (CARCINOMA CUNICULATUM)

- Lesions are most commonly reported on the plantar surface of the foot, and skin lesions are considered a variant of verrucous carcinoma.
- Lesion occurs on the gingiva/alveolar ridge and majority show direct intraosseous extension.
- Lesion is a rare variant of squamous cell carcinoma with thin trabecular and ribbon-like proliferation of squamous epithelium with complex arborizing morphology and convoluted irregular keratin-filled cysts to the extent that connection with the surface epithelium may be difficult to identify; variable cytologic atypia (Fig. 11-50).

- Differential diagnosis: verrucous carcinoma is less likely, because the epithelium lining cystlike structures is thin and shows significant atypia; some squamous cell carcinomas may form one or two cystic structures that are not tortuous (Fig. 11-51).
- Prognosis: some tumors behave indolently and do not metastasize, although this may depend on the degree and nature of stromal infiltration.

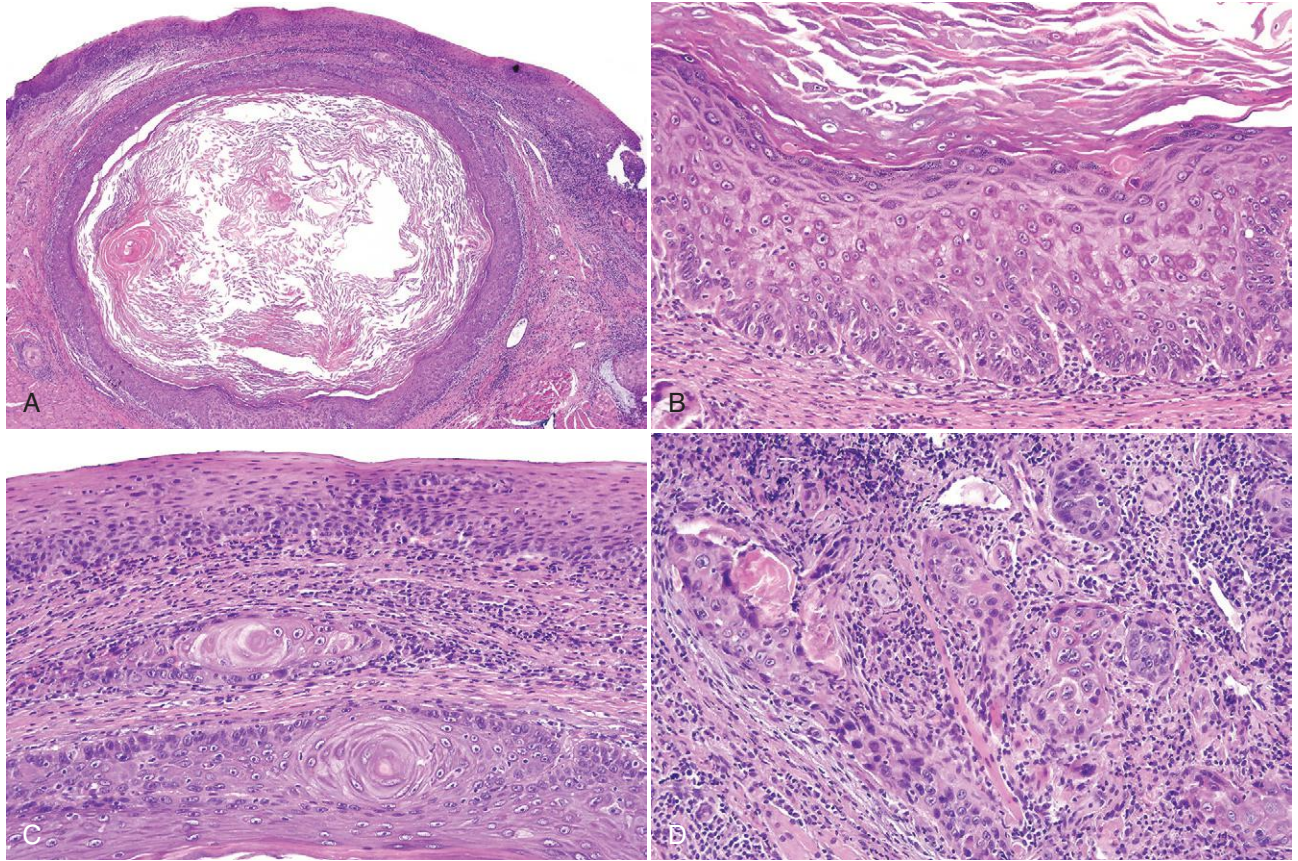
#### REFERENCES

- Allon D, Kaplan I, Manor R, Calderon S. Carcinoma cuniculatum of the jaw: a rare variant of oral carcinoma. *Oral Surg Oral Med Oral Pathol Oral Radiol Endod.* 2002;94:601-608.
- Kruse AL, Graetz KW. Carcinoma cuniculatum: a rare entity in the oral cavity. *J Craniofac Surg.* 2009;20:1270-1272.
- Pons Y, Kerrary S, Cox A, et al. Mandibular cuniculatum carcinoma: apropos of 3 cases and literature review. *Head Neck.* 2010.



**FIGURE 11-50.** Cuniculate carcinoma. **A**, Deeply ramifying, irregular cystic spaces filled with keratin; tumor arises from surface. **B**, Keratin-filled cysts surrounded by atypical epithelium. **C**, Pleomorphic tumor cells and stromal infiltration.





**FIGURE 11-51.** Cystic squamous cell carcinoma. **A**, Keratin-filled cyst lined by dysplastic epithelium; note invasive islands of tumor cells at the *right* and *left* margins of image. **B**, Cyst lining contains dysplastic cells. **C**, Surface epithelium exhibits mild dysplasia and islands of tumor cells infiltrate the stroma. **D**, Conventional infiltrating squamous cell carcinoma is noted.



# 12

# INFLAMMATORY SALIVARY GLAND DISORDERS

## CHAPTER CONTENTS

Mucocele 264

Salivary Duct Cyst (Salivary Retention Cyst, Sialocyst) 270

Sialolith (Salivary Calculus) 272

Cheilitis Glandularis (Stomatitis Glandularis, Cheilitis Glandularis Apostematosa) 275

Necrotizing Sialometaplasia 276

Subacute Necrotizing Sialadenitis 278

Autoimmune Sialadenitis 280

Adenomatoid (Acinar) Hyperplasia 283

Sclerosing Polycystic Adenosis 284

## MUCOCELE

Mucoceles in the oral cavity are cystlike collections of salivary mucin that spills out of a traumatized duct.

### Clinical Findings

- Mucoceles are most common in the first 3 decades of life.
- Dome-shaped, bluish, sessile nodules, mucoceles are commonly located on the lower labial mucosa (70% to 90%), ventral tongue (ranula), buccal mucosa, and floor of mouth; they wax and wane and are usually painless (Fig. 12-1, A-C); 44% of mucoceles resolve spontaneously.
- Superficial mucoceles are seen in patients with hyposalivation; they are most frequent on the palate (such as in patients with chronic graft-versus-host disease) and resemble painless blisters or vesicles, often leading to a clinical misdiagnosis of herpes infection (see Fig. 12-1, D); the latter are almost always extremely painful.

### Etiopathogenesis and Histopathologic Features

Mucoceles are pseudocysts that arise from trauma to the excretory salivary duct; this leads to escape of mucous into the surrounding soft tissues, which become walled off by granulation tissue and eventually organized by fibrous tissue.

- Cystlike cavity fills with mucin with variable numbers of neutrophils, muciphages, and, sometimes, eosinophilic spherules surrounded by condensed granulation tissue containing muciphages; these globules are mucicarmin positive and may represent mucin condensations; a feeder duct exhibiting squamous metaplasia may be seen; mucin may be inconspicuous within the wall (Figs. 12-2 and 12-3).

- Mucin may be present diffusely in the connective tissue (Fig. 12-4); lesions not removed intact manifest as fragments of granulation tissue with muciphages (Fig. 12-5); ventral tongue lesions tend not to have a thick wall of granulation tissue (Fig. 12-6).
- Minor salivary glands exhibit variable degrees of obstructive changes, namely acinar atrophy, ductal dilatation with inspissated secretions, periductal hyalinization, interstitial fibrosis, and interstitial lymphoplasmacytic infiltrate (Fig. 12-7).
- Organizing mucoceles consist of a solid mass of granulation tissue with muciphages; mucin generally is inconspicuous, and a mucin pool is absent (Fig. 12-8); muciphages may sometimes have clear cytoplasm (Fig. 12-9).
- Superficial mucoceles contain mucin pools that abut the overlying atrophic epithelium; a collarette of epithelium forms part of the wall of the mucocele (Figs. 12-10 and 12-11).
- Papillary synovium-like areas are sometimes seen (Fig. 12-12).

### Differential Diagnosis

- An organizing mucocele with a predominance of clear cells may resemble salivary gland neoplasm such as mucoepidermoid carcinoma or even clear cell carcinoma, but there is lack of stromal invasion by nests of neoplastic cells.
- Obstructive changes are often diffuse and should not be confused with autoimmune sialadenitis seen in Sjögren syndrome, in which obstructive changes are minimal and the lymphocytic infiltrate is strikingly periductal, at least in early stages (see later); focal periductal lymphocytic infiltrates are not uncommon in obstructive sialadenitis.



## Management

- Enucleation or excision of mucoceles, sometimes with overlying mucosa (especially superficial mucoceles), and excision of salivary glands in the vicinity, down to muscle
- May recur (rate of up to 8%) from further damage of salivary glands

## REFERENCES

Bermejo A, Aguirre JM, Lopez P, Saez MR. Superficial mucocele: report of 4 cases. *Oral Surg Oral Med Oral Pathol Oral Radiol Endod.* 1999;88:469-472.

Campana F, Sibaud V, Chauvel A, et al. Recurrent superficial mucoceles associated with lichenoid disorders. *J Oral Maxillofac Surg.* 2006;64:1830-1833.

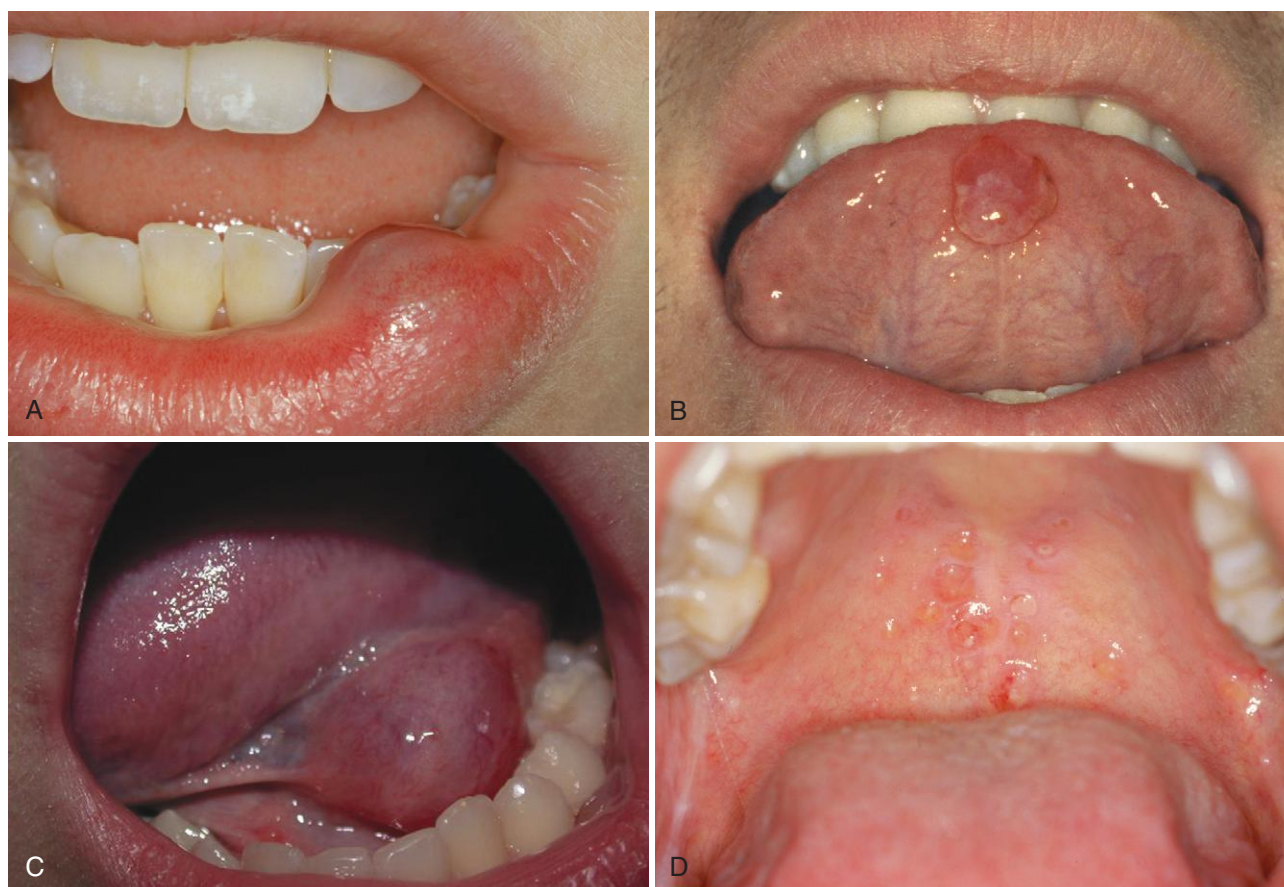Chi AC, Haigney 2nd RJ, Spagnoli DB, et al. Papillary synovial metaplasia-like change in oral mucoceles: a rare and previously undescribed histopathologic variant of a common oral lesion. *Oral Surg Oral Med Oral Pathol Oral Radiol Endod.* 2010;109:268-273.

Chi AC, Lambert 3rd PR, Richardson MS, Neville BW. Oral mucoceles: a clinicopathologic review of 1,824 cases, including unusual variants. *J Oral Maxillofac Surg.* 2010;69:1086-1093.

Minguez-Martinez I, Bonet-Coloma C, Ata-Ali-Mahmud J, et al. Clinical characteristics, treatment, and evolution of 89 mucoceles in children. *J Oral Maxillofac Surg.* 2010;68:e2468-e2471.

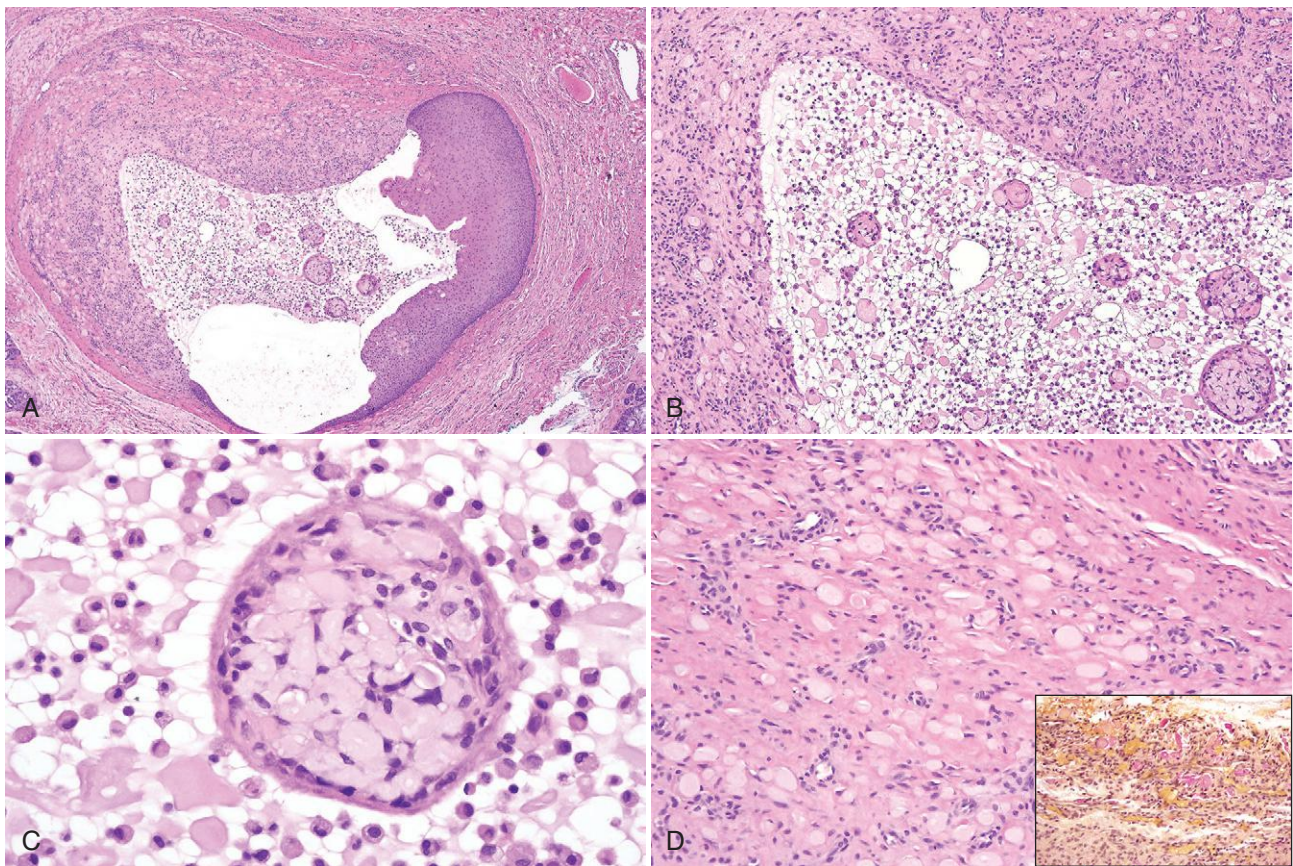
Sugerman PB, Savage NW, Young WG. Mucocele of the anterior lingual salivary glands (glands of Blandin and Nuhn): report of 5 cases. *Oral Surg Oral Med Oral Pathol Oral Radiol Endod.* 2000;90:478-482.

Treister NS, Cook Jr EF, Antin J, et al. Clinical evaluation of oral chronic graft-versus-host disease. *Biol Blood Marrow Transplant.* 2008;14:110-115.

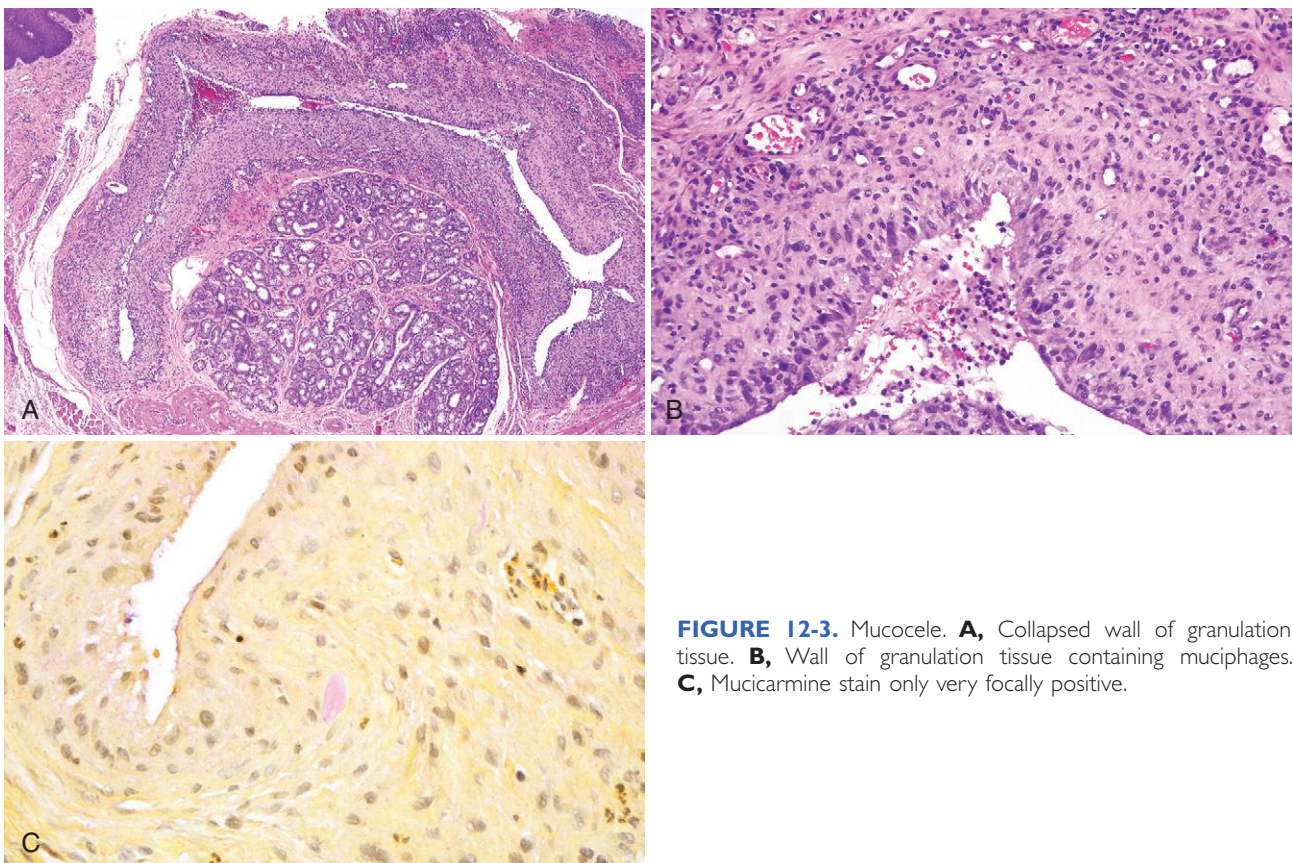


**FIGURE 12-1.** **A**, Mucocele on lower lip. **B**, Mucocele on ventral tongue. **C**, Ranula (floor of mouth mucocele). **D**, Superficial mucocele. (**C**, Courtesy of Dr. Bonnie Padwa, Harvard School of Dental Medicine, Boston, Mass.)



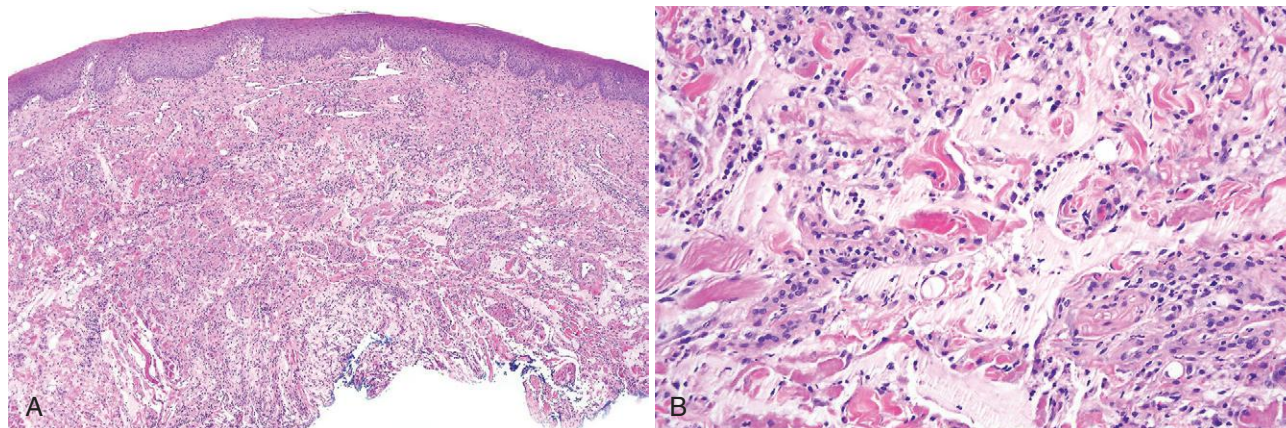


**FIGURE 12-2.** Mucocele. **A**, Pool of mucin containing eosinophilic globules surrounded by granulation tissue; part of feeder duct present. **B**, Surrounding granulation tissue contains eosinophilic globules. **C**, Hyaline spherules (myxoglobulosis) within mucin. **D**, Eosinophilic globules in connective tissue stain for mucicarmine (*inset*).

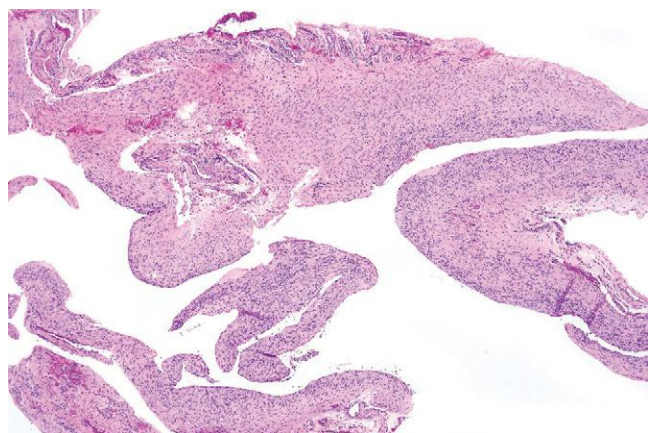


**FIGURE 12-3.** Mucocele. **A**, Collapsed wall of granulation tissue. **B**, Wall of granulation tissue containing muciphages. **C**, Mucicarmine stain only very focally positive.

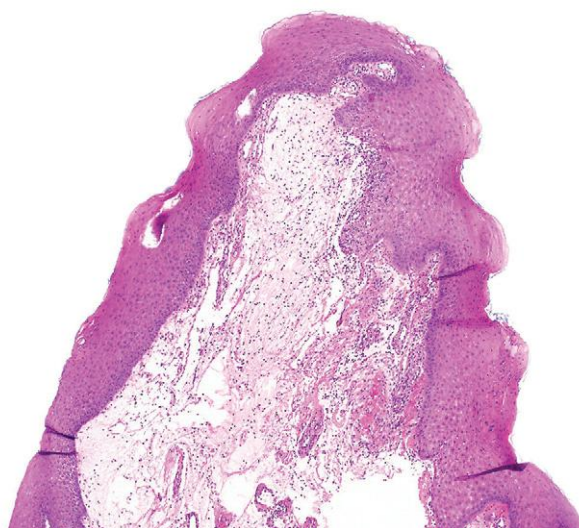




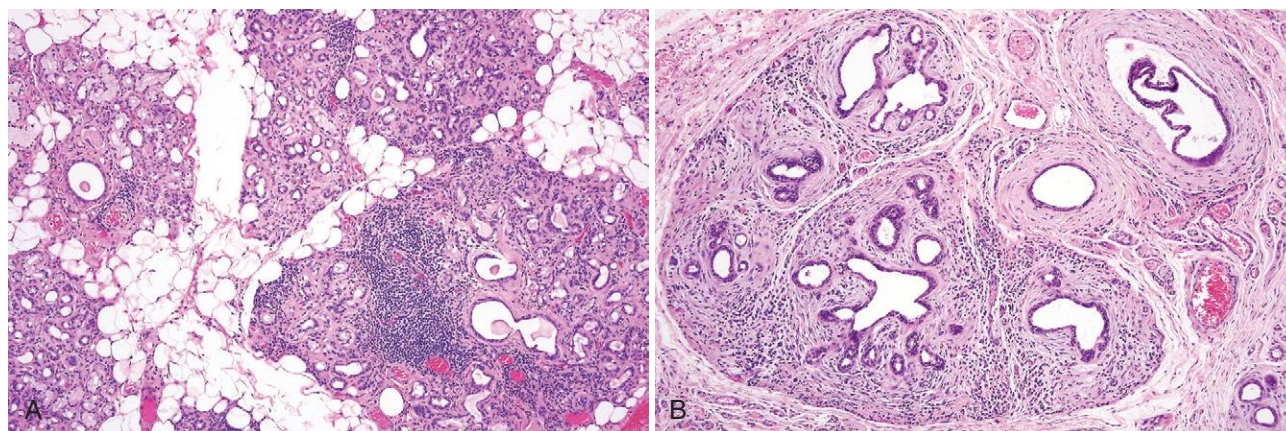
**FIGURE 12-4.** Mucocele. **A**, Mucin appears diffusely in the interstitium without distinct pooling. **B**, Abundant interstitial mucin with muciphages.



**FIGURE 12-5.** Mucocele: fragments of granulation tissue from a curetted specimen.

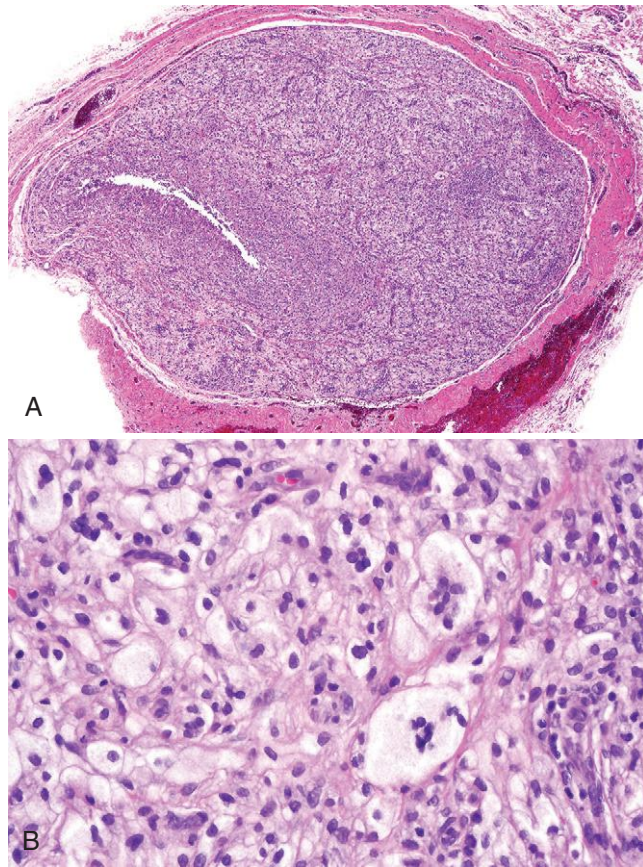


**FIGURE 12-6.** Mucocele of ventral tongue: pool of mucin and granulation tissue that is generally not as obviously walled off.

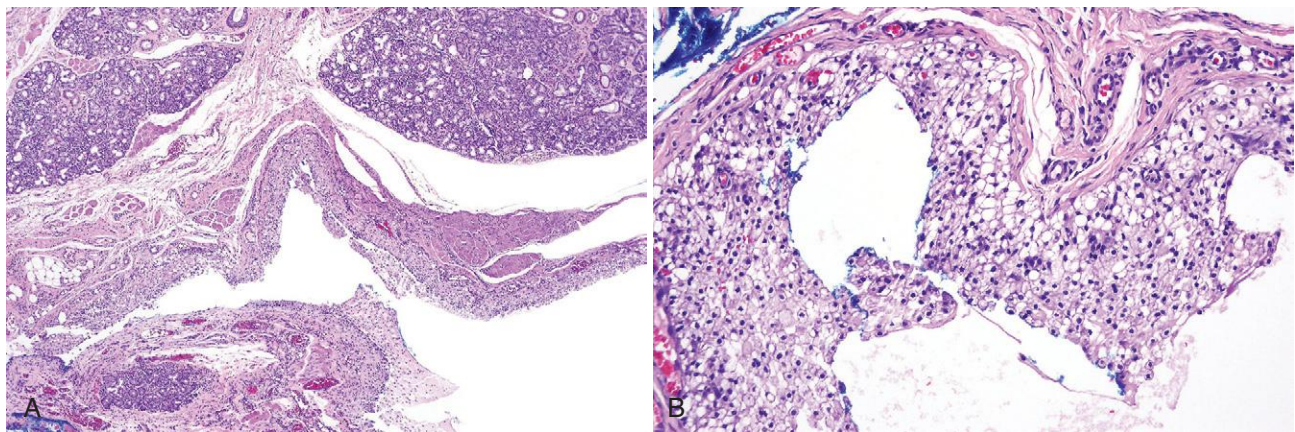


**FIGURE 12-7.** **A**, Chronic obstructive sialadenitis with diffuse involvement of glands. **B**, Acinar atrophy, ductal dilatation, interstitial fibrosis, and chronic inflammation.



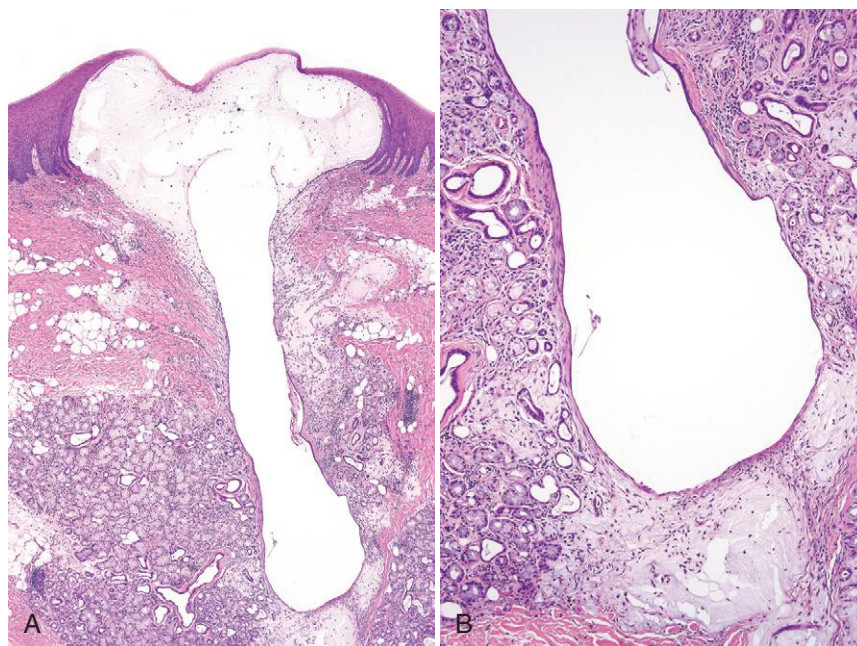


**FIGURE 12-8.** Organizing mucocele. **A**, Compact mass of granulation tissue with peripheral fibrosis. **B**, Compact granulation tissue with muciphages.

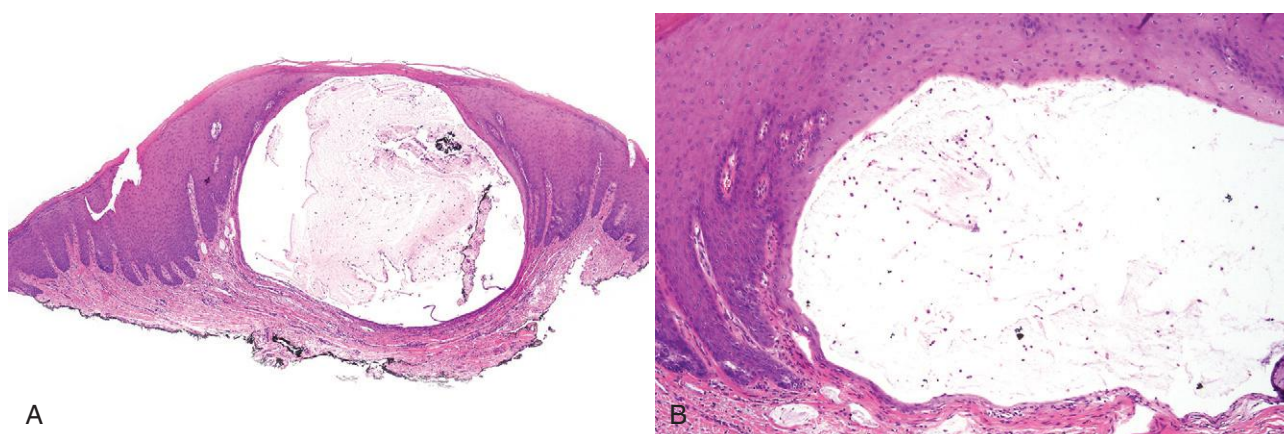


**FIGURE 12-9.** Mucocele. **A**, Granulation tissue containing clear cells. **B**, Granulation tissue wall with mucous and clear cells.

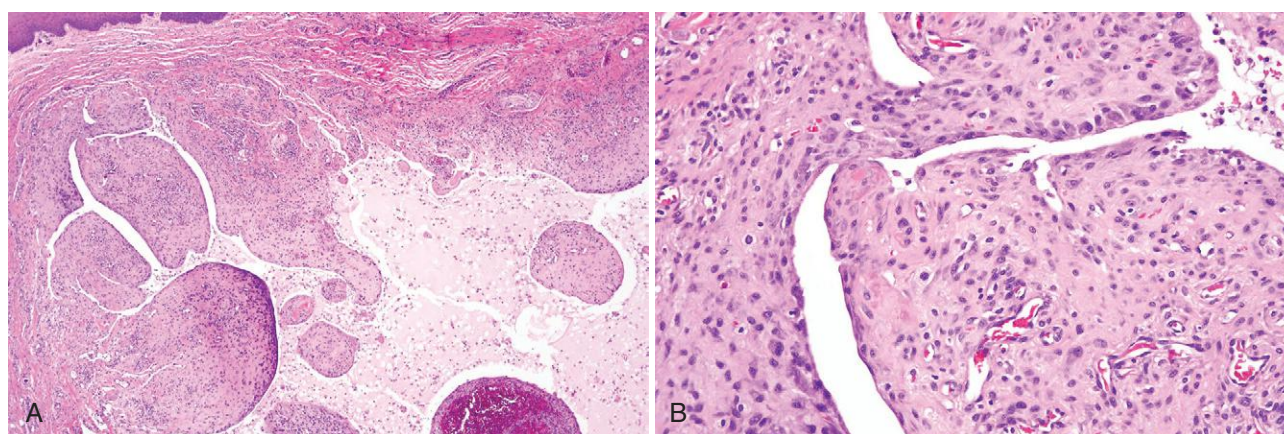




**FIGURE 12-10.** Superficial mucocele. **A**, Pool of mucin abutting and thinning the epithelium that forms a collarette. **B**, Mucin in the connective tissue.



**FIGURE 12-11.** Superficial mucocele. **A**, Mucin abuts and thins the epithelium; collarette present. **B**, Mucin partially enclosed by surface epithelium.



**FIGURE 12-12.** Mucocele. **A**, Papillary structures protrude into mucin pool. **B**, Synovium-like areas composed of fibroblasts, macrophages, and capillaries.



## SALIVARY DUCT CYST (SALIVARY RETENTION CYST, SIALOCYST)

### Clinical Findings

- Tends to occur in the maxillary and mandibular sulcus/vestibule (mucobuccal fold) and upper lip (where it is often associated with sialoliths) in adults
- Appears as bluish nodule that may feel hard if a sialolith is present

### Etiopathogenesis and Histopathologic Features

These true cysts arise from retention of secretions within a duct from a distal obstruction, or from presence of a sialolith.

- These cysts consist of cystically dilated excretory salivary duct that may be lined by a double layer of low cuboidal-to-columnar cells or may exhibit metaplastic change—squamous, ciliated cell, or oncocytic (oncocytic sialocyst); it may have slight papillary projections in the lining (Figs. 12-13 to 12-15); a sialolith may be present; variable lymphoplasmacytic infiltrate present.
- Oncocytic sialocystosis (papillary or otherwise) shows multiple cystic structures in both extralobular and

intralobular locations; surrounding minor glands exhibit obstructive changes (see Mucocele) (Figs. 12-16 and 12-17); should not be overdiagnosed as papillary cystadenoma.

### Differential Diagnosis

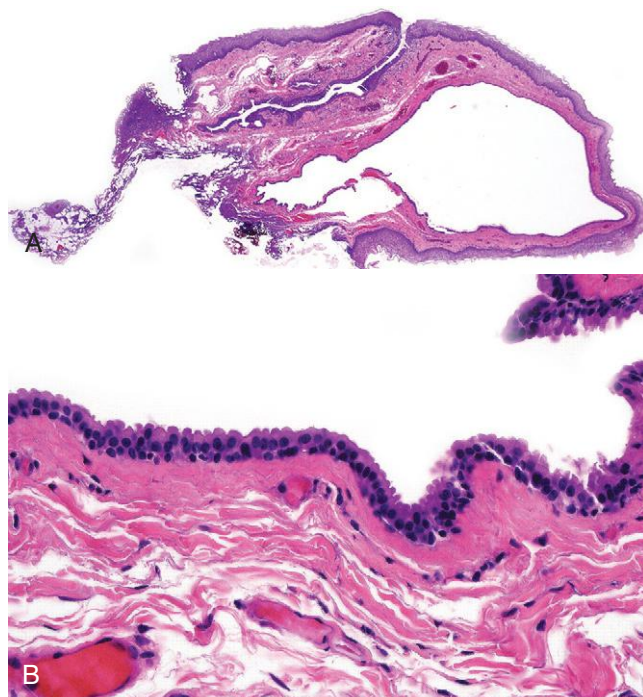
- Multifocality and lack of encapsulation or significant adenomatous component differentiates sialocystosis from cystadenoma, although distinction may be difficult (see Chapter 13).
- Gingival cyst of the adult is often mistaken for salivary duct cyst, but the latter does not occur on the attached gingiva, which has no salivary glands.

### Management

- Enucleation or excision with surrounding glands is curative.

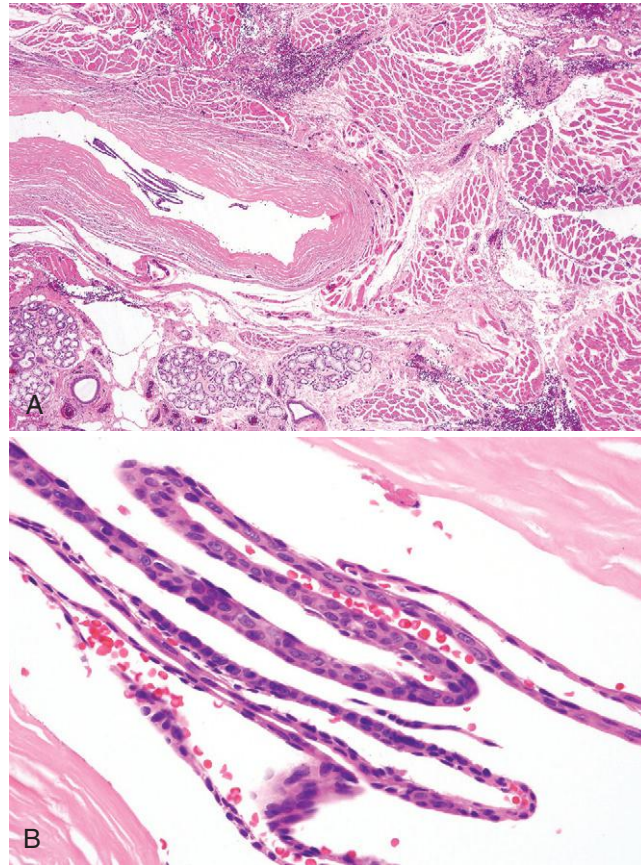
### REFERENCES

- Eversole LR. Oral sialocysts. *Arch Otolaryngol.* 1987;113:51-56.  
 Fantasia JE, Miller AS. Papillary cystadenoma lymphomatosum arising in minor salivary glands. *Oral Surg Oral Med Oral Pathol.* 1981;52:411-416.

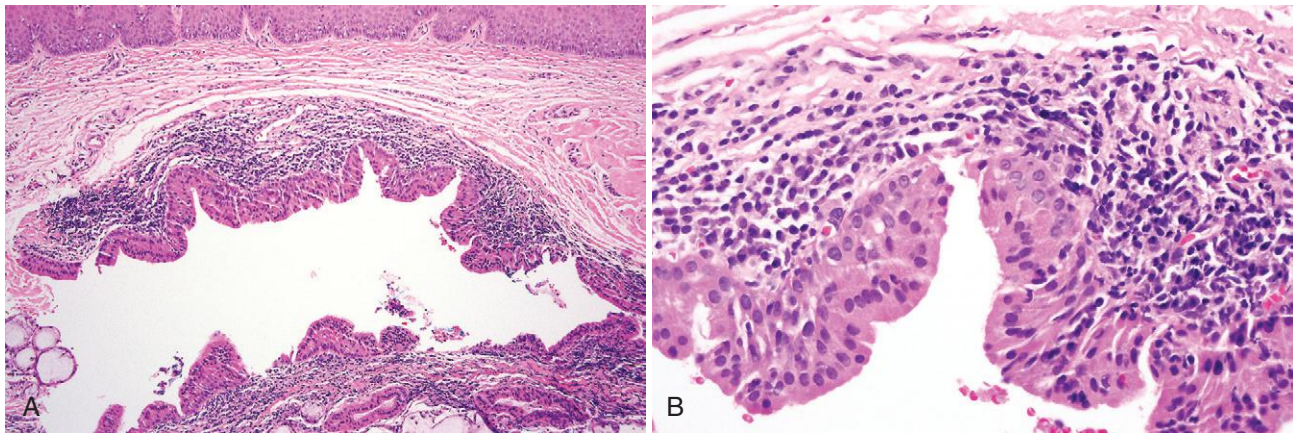


**FIGURE 12-13.** Salivary duct cyst. **A**, Note the adjacent normal excretory salivary duct. **B**, Lining consists of a double layer of low cuboidal-to-columnar cells.



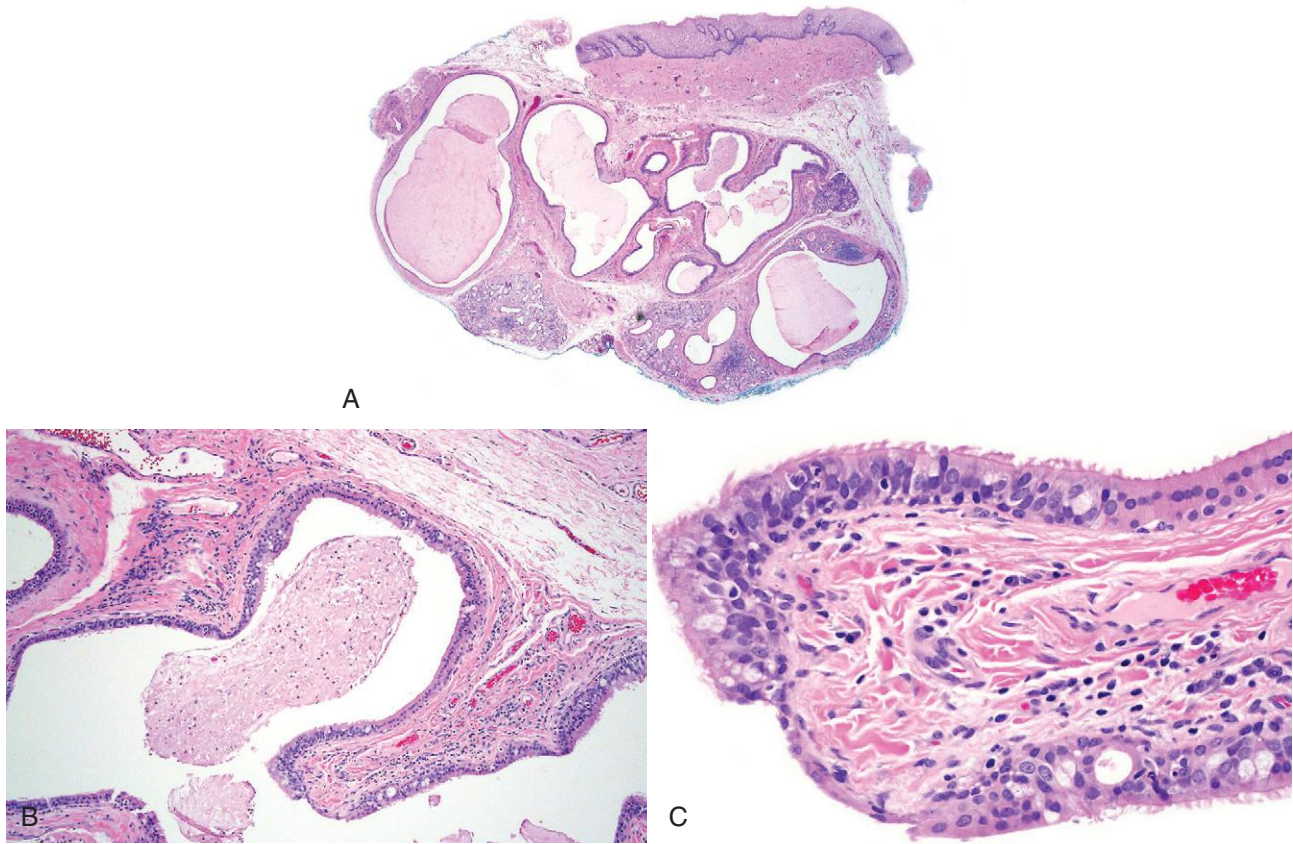


**FIGURE 12-14.** Salivary duct cyst. **A**, Cyst with thin lining and thickened, hyalinized basement membrane. **B**, Detached strips of epithelium composed of two to three layers of flattened cuboidal cells.

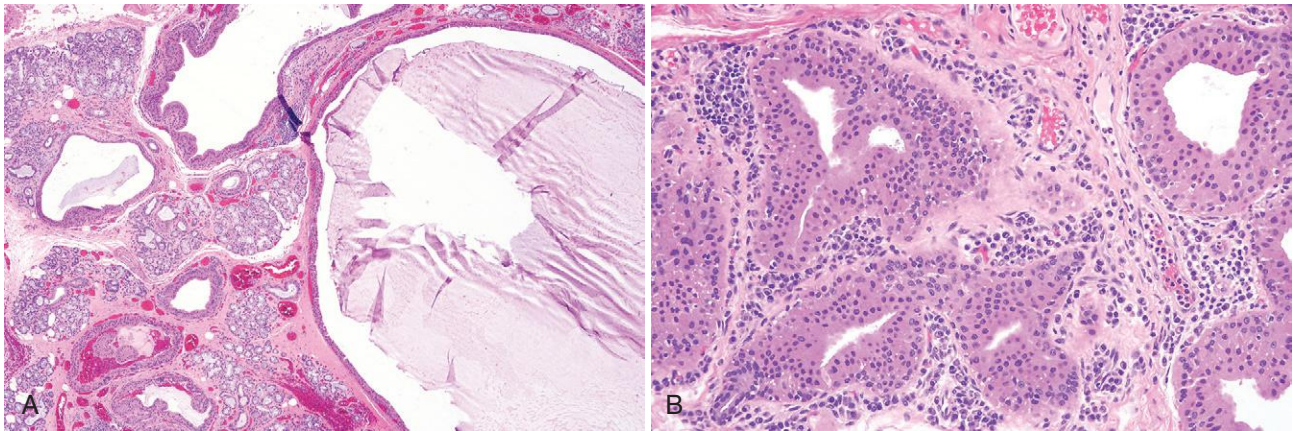


**FIGURE 12-15.** Oncocytic sialocyst. **A**, Undulating luminal surface and surrounding chronic inflammation. **B**, Lining composed of oncocytes with surrounding lymphoplasmacytic infiltrate.





**FIGURE 12-16.** Oncocytic sialocystosis. **A**, Extralobular and intralobular dilated ducts with marked sclerosing sialadenitis in surrounding glands. **B**, Ducts lined by uniformly thin epithelium. **C**, Lining is composed of pseudostratified columnar, ciliated, and mucous cells.



**FIGURE 12-17.** Oncocytic sialocystosis. **A**, Multiple dilated ducts in multiple lobules. **B**, Early dilatation of ducts exhibiting oncocytic metaplasia.

## SIALOLITH (SALIVARY CALCULUS)

### Clinical Findings

- Firm-to-hard nodule, usually asymptomatic (unless ruptured and inflamed), often in the upper lip in minor glands.
- Most common site in the major glands is the floor of mouth within Wharton (submandibular) duct,

causing pain from pressure just before meals (“meal symptoms”); may be seen on intraoral occlusal radiographs if it is sufficiently calcified (Fig. 12-18).

### Etiopathogenesis and Histopathologic Features

Sialoliths form from a central nidus of cellular debris, bacteria, or mucous plugs and are unassociated with hypercalcemic syndromes. They are more common in



the Wharton duct because of the length of the duct, its tortuous course, and the relatively thick mucinous secretions.

- Basophilic concentric lamellar and globular calcifications occur within a cystically dilated duct that exhibits squamous and often mucous cell metaplasia; suppuration may be seen if there is infection (Figs. 12-19 to 12-21); associated minor glands exhibit obstructive changes.
- Bacteria may be identified in rare cases (Fig. 12-22).

#### Differential Diagnosis

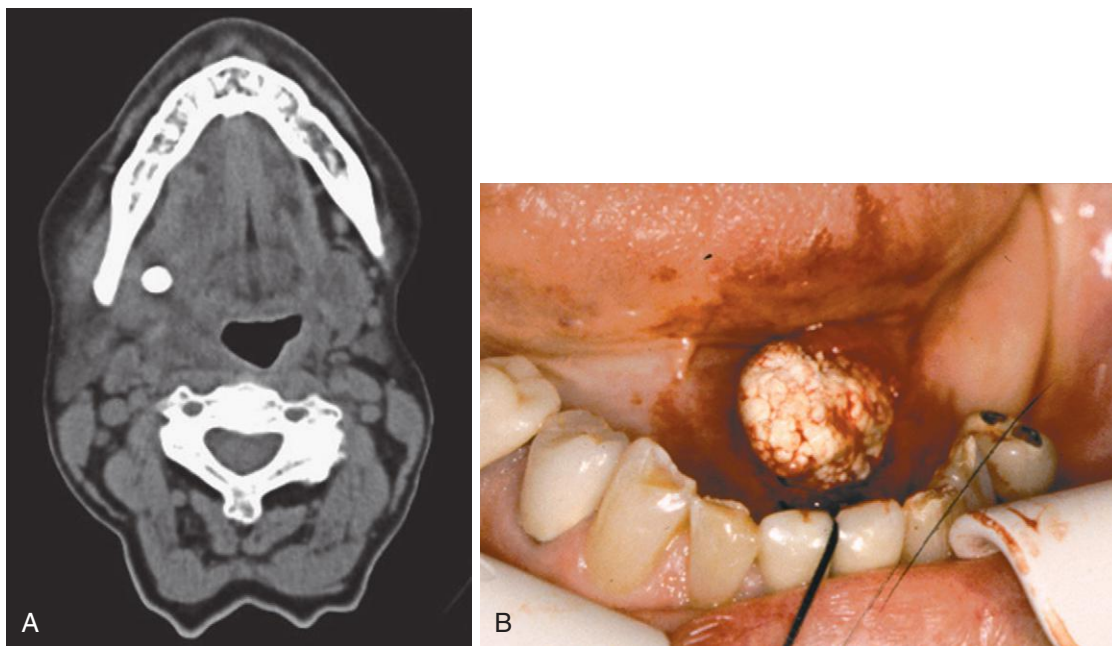
- Phleboliths are usually smaller; they do not have a globular component, and they are present within venules.

#### Management

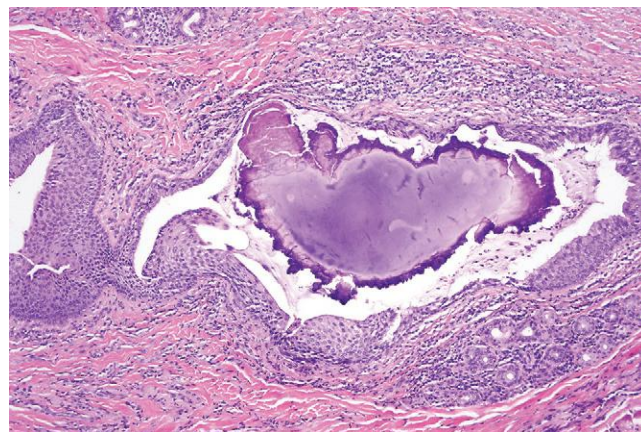
- Excision of the minor salivary glands with the sialolith is curative.
- Excision of the submandibular sialolith with exteriorization of the duct is curative; lithotripsy is also effective.

#### REFERENCES

- Anneroth G, Hansen LS. Minor salivary gland calculi. A clinical and histopathological study of 49 cases. *Int J Oral Surg*. 1983;12:80-89.
- Jensen JL, Howell FV, Rick GM, Correll RW. Minor salivary gland calculi. A clinicopathologic study of forty-seven new cases. *Oral Surg Oral Med Oral Pathol*. 1979;47:44-50.
- Zenk J, Bozzato A, Winter M, et al. Extracorporeal shock wave lithotripsy of submandibular stones: evaluation after 10 years. *Ann Otol Rhinol Laryngol*. 2004;113:378-383.

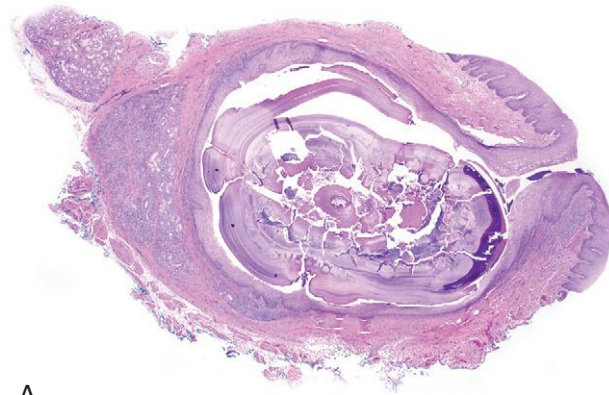


**FIGURE 12-18.** **A**, Axial CT scan of sialolith in submandibular duct. **B**, Sialolith of submandibular duct. (Courtesy of Dr. Bonnie Padwa, Children's Hospital, Boston, Mass.)

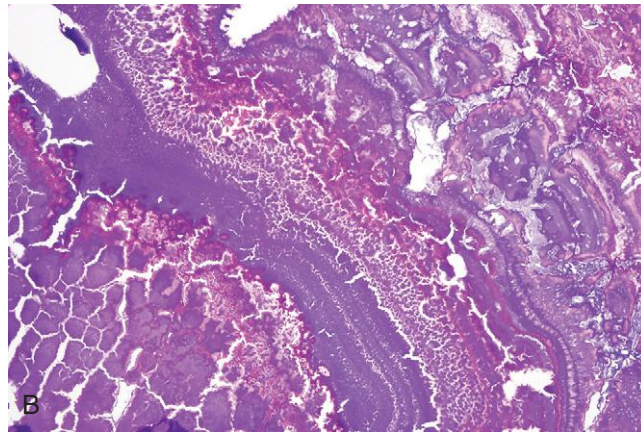


**FIGURE 12-19.** Sialolith: sialolith within ectatic duct with squamous metaplasia, partially ruptured, with surrounding inflammation.



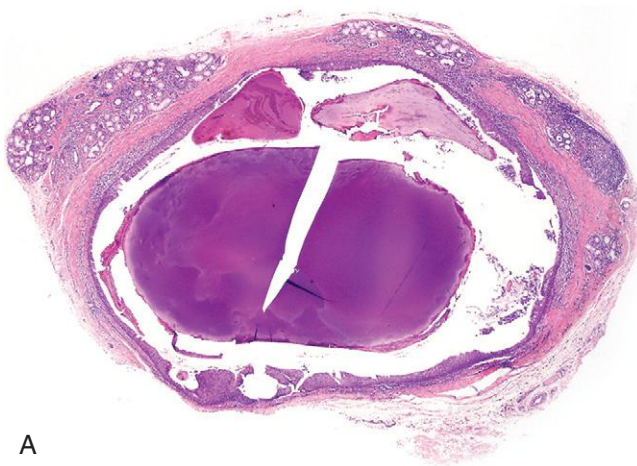


A

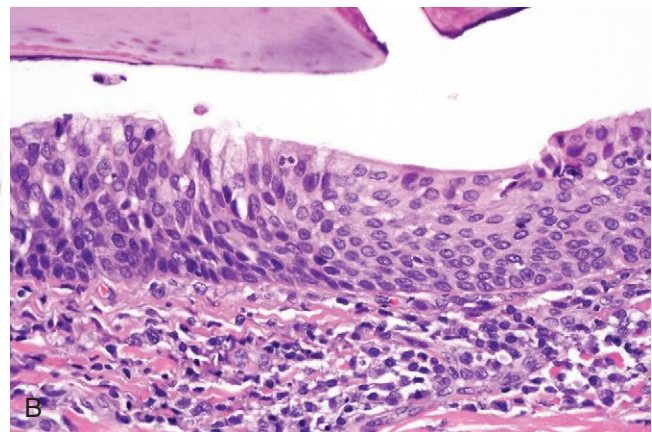


B

**FIGURE 12-20.** Sialolith. **A**, Sialolith within ectatic duct with squamous metaplasia that opens into the oral cavity. **B**, Lamellar and globular concretions.



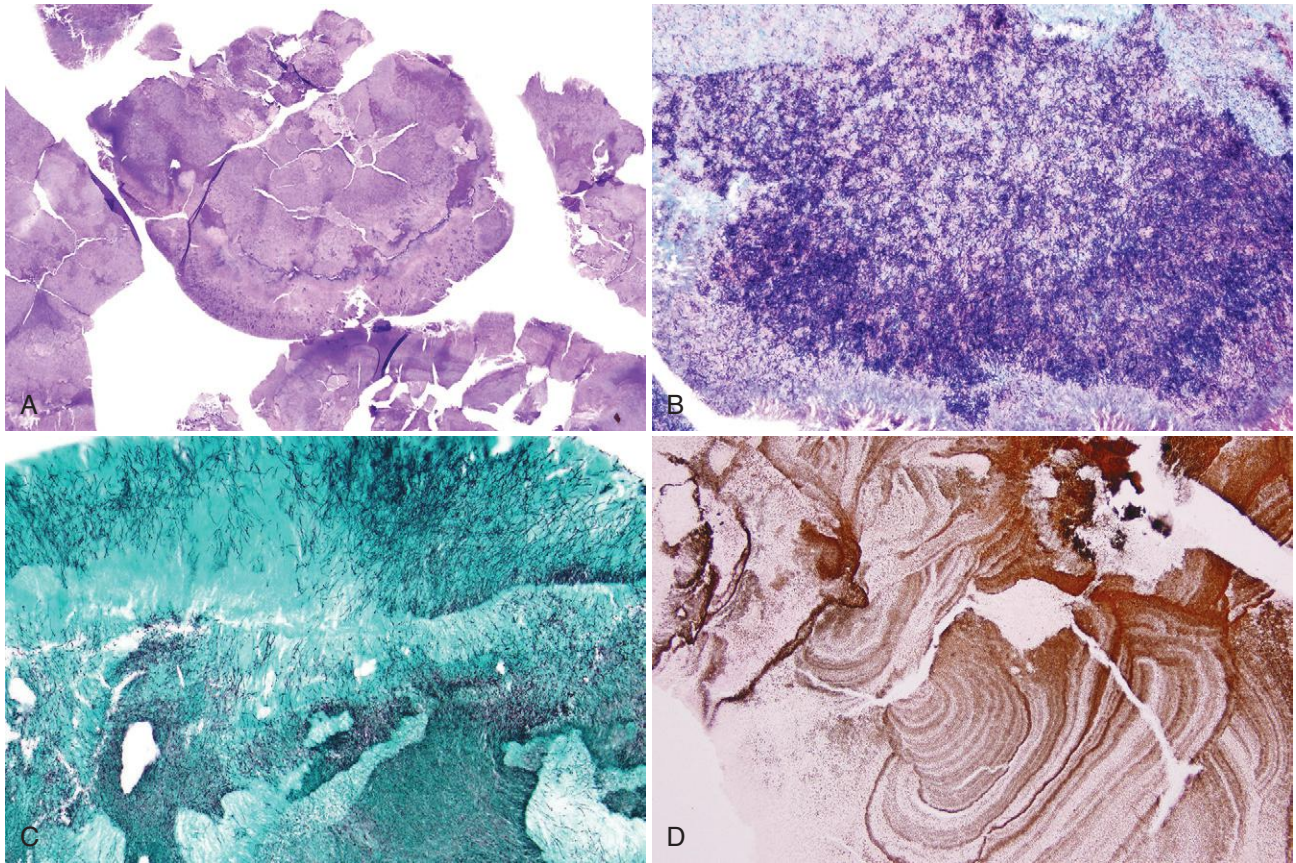
A



B

**FIGURE 12-21.** Sialolith. **A**, Sialolith within ectatic duct; minor salivary glands exhibit obstructive sialadenitis. **B**, Squamous and mucous cell metaplasia with chronic inflammation.





**FIGURE 12-22.** Fragments of a sialolith. **A**, Fragmented, calcified structure. **B**, Brown and Brenn stain showing many gram-positive cocci and rods. **C**, Gomori methenamine silver stain showing many filamentous bacteria. **D**, von Kossa stain showing lamellar calcifications.

## CHEILITIS GLANDULARIS (STOMATITIS GLANDULARIS, CHEILITIS GLANDULARIS APOSTEMATOSA)

### Clinical Findings

- Seen in older adults, usually males
- Asymmetric, often painful swelling or nodule, usually on the lower lip that typically becomes everted; usually concurrent actinic damage to lips (Fig. 12-23); simple, deep, and deep suppurative forms recognized

### Etiopathogenesis and Histopathologic Features

Chronic inflammation and suppuration involve the salivary ducts; etiology is unknown, although actinic damage may play a role.

- Cystically dilated excretory ducts show periductal acute and chronic inflammation and luminal suppuration (Fig. 12-24).
- Overlying mucosa may show dysplasia and/or invasive carcinoma.

### Differential Diagnosis

- Presence of a sialolith, ruptured salivary duct cyst, or trauma may produce similar changes.

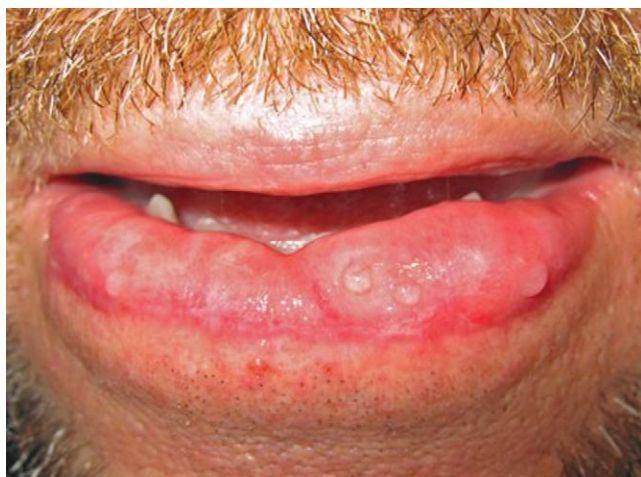### Management

- Antibiotics are used for infection if pain and/or supuration is present.
- Excision of lesion is curative; dysplasia in the epithelium must be treated appropriately.

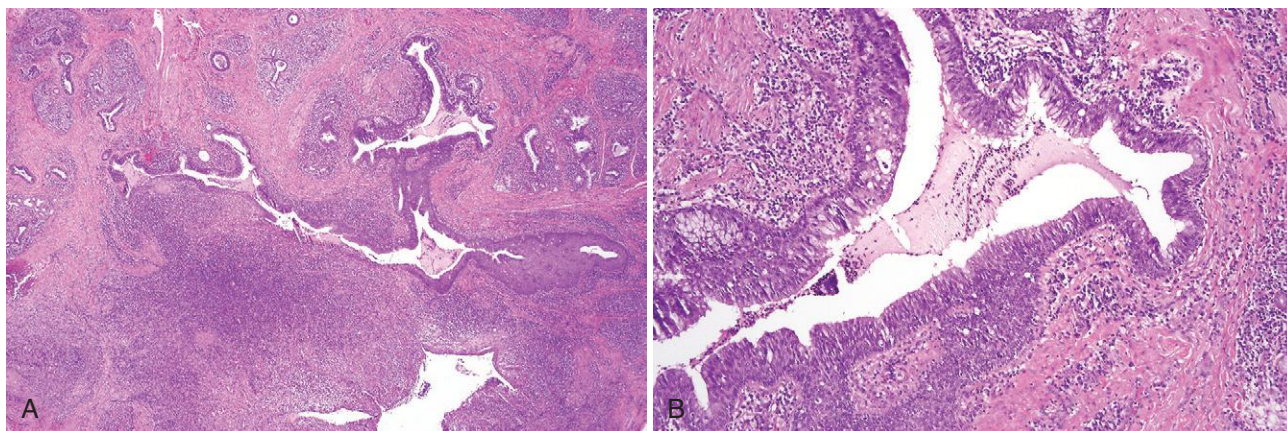
### REFERENCES

- Leao JC, Ferreira AM, Martins S, et al. Cheilitis glandularis: an unusual presentation in a patient with HIV infection. *Oral Surg Oral Med Oral Pathol Oral Radiol Endod.* 2003;95:142-144.
- Lourenco SV, Gori LM, Boggio P, Nico MM. Cheilitis glandularis in albinos: a report of two cases and review of histopathological findings after therapeutic vermilionectomy. *J Eur Acad Dermatol Venereol.* 2007;21:1265-1267.
- Nico MM, Nakano de Melo J, Lourenco SV. Cheilitis glandularis: a clinicopathological study in 22 patients. *J Am Acad Dermatol.* 2010;62:233-238.





**FIGURE 12-23.** Cheilitis glandularis of lower lip with actinic cheilitis. (Courtesy of Division of Dermatology, Brigham and Women's Hospital, Boston, Mass.)



**FIGURE 12-24.** Cheilitis glandularis. **A**, Tortuous and dilated ducts and surrounding glands exhibiting marked chronic sialadenitis. **B**, Luminal mucin and suppuration, and mucous cell metaplasia of ducts.

## NECROTIZING SIALOMETAPLASIA

### Clinical Findings

- Lesion is more common in males (3:1 male predominance) and usually occurs on the hard palate.
- Lesion starts as a swelling that breaks down over a few days to weeks to form necrotic and ulcerated tissue that sloughs; it may or may not be painful (Fig. 12-25).
- Patient may have history of a greater palatine anesthetic block; reported in patients with Raynaud disease, Buerger disease, and bulimia; rare cases are associated with an adjacent malignancy.

### Etiopathogenesis and Histopathologic Features

This condition is caused by ischemia and infarction of the glands.

- Preservation of the lobular architecture of the glands is an important finding that is not always present (Fig. 12-26, *A*)
- Early stage—spillage of mucin into the interstitium of the gland parenchyma; ghostly outlines of the acini with preserved basement membrane but erased acinar cell outlines (Fig. 12-27; see Fig. 12-26, *B*) are classic features.
- Late stage—squamous metaplasia of the ducts may be marked but without significant pleomorphism or abnormal mitoses (see Fig. 12-26, *C*).
- There is variable acute and chronic inflammation, necrosis, and secondary thrombosis.

### Differential Diagnosis

- Lack of significant cytologic atypia and abnormal mitoses rules out a squamous cell carcinoma.



- Subacute necrotizing sialadenitis shows marked mixed inflammation with focal necrosis.

**Management**

- Lesion resolves on its own without medical or surgical intervention by spontaneous exfoliation of the necrotic tissue; intralesional steroid therapy may be helpful.

**REFERENCES**

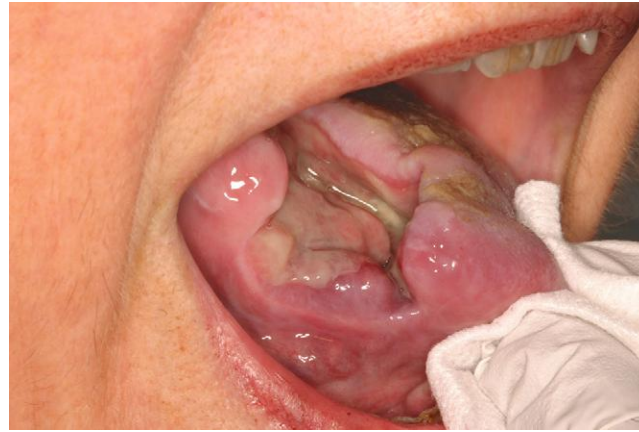Abrams AM, Melrose RJ, Howell FV. Necrotizing sialometaplasia. *Cancer*. 1973;32:130-135.

Brannon RB, Fowler CB, Hartman KS. Necrotizing sialometaplasia. A clinicopathologic study of sixty-nine cases and review of the literature. *Oral Surg Oral Med Oral Pathol*. 1991;72:317-325.

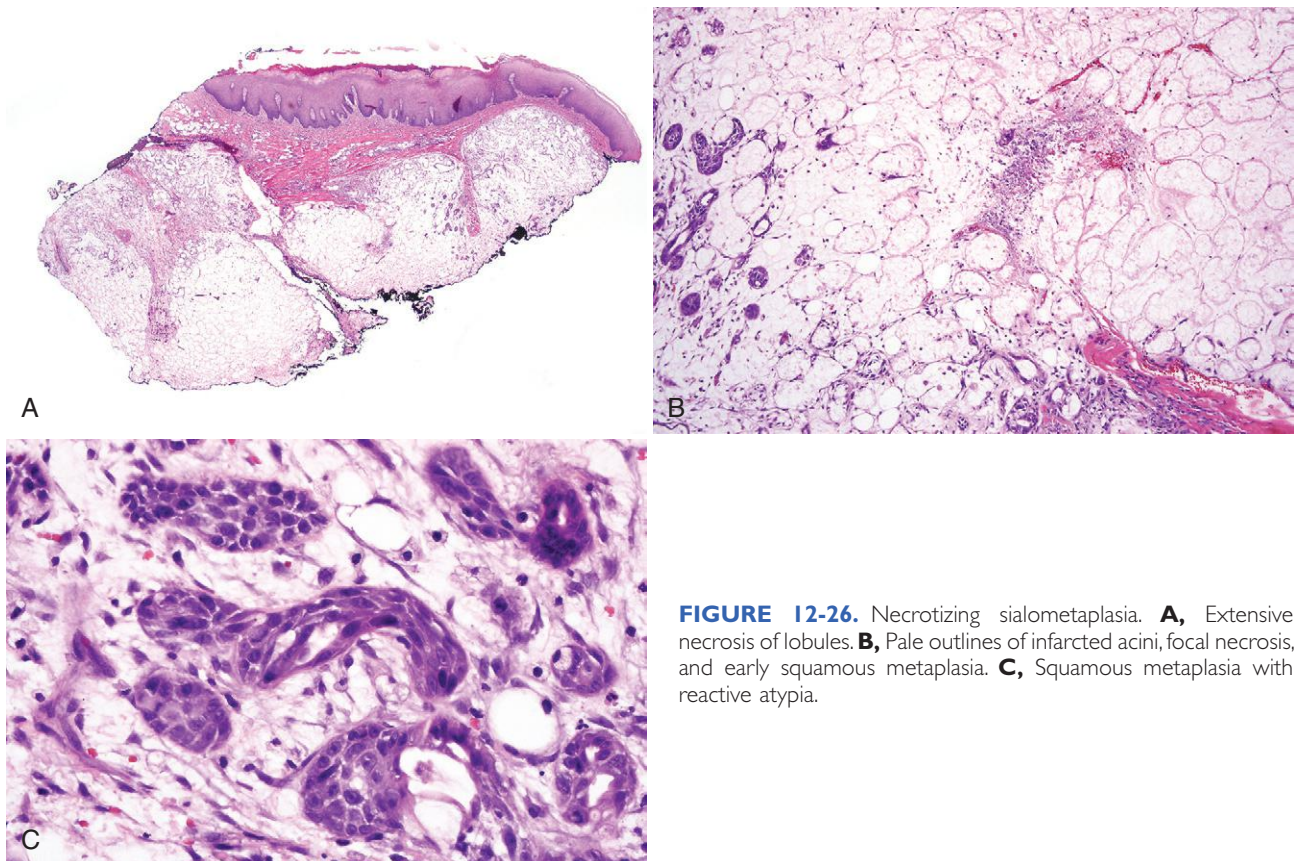
Dominguez-Malagon H, Mosqueda-Taylor A, Cano-Valdez AM. Necrotizing sialometaplasia of the palate associated with angiocentric T-cell lymphoma. *Ann Diagn Pathol*. 2009;13:60-64.

Lee DJ, Ahn HK, Koh ES, et al. Necrotizing sialometaplasia accompanied by adenoid cystic carcinoma on the soft palate. *Clin Exp Otorhinolaryngol*. 2009;2:48-51.

Schoning H, Emshoff R, Kreczy A. Necrotizing sialometaplasia in two patients with bulimia and chronic vomiting. *Int J Oral Maxillofac Surg*. 1998;27:463-465.

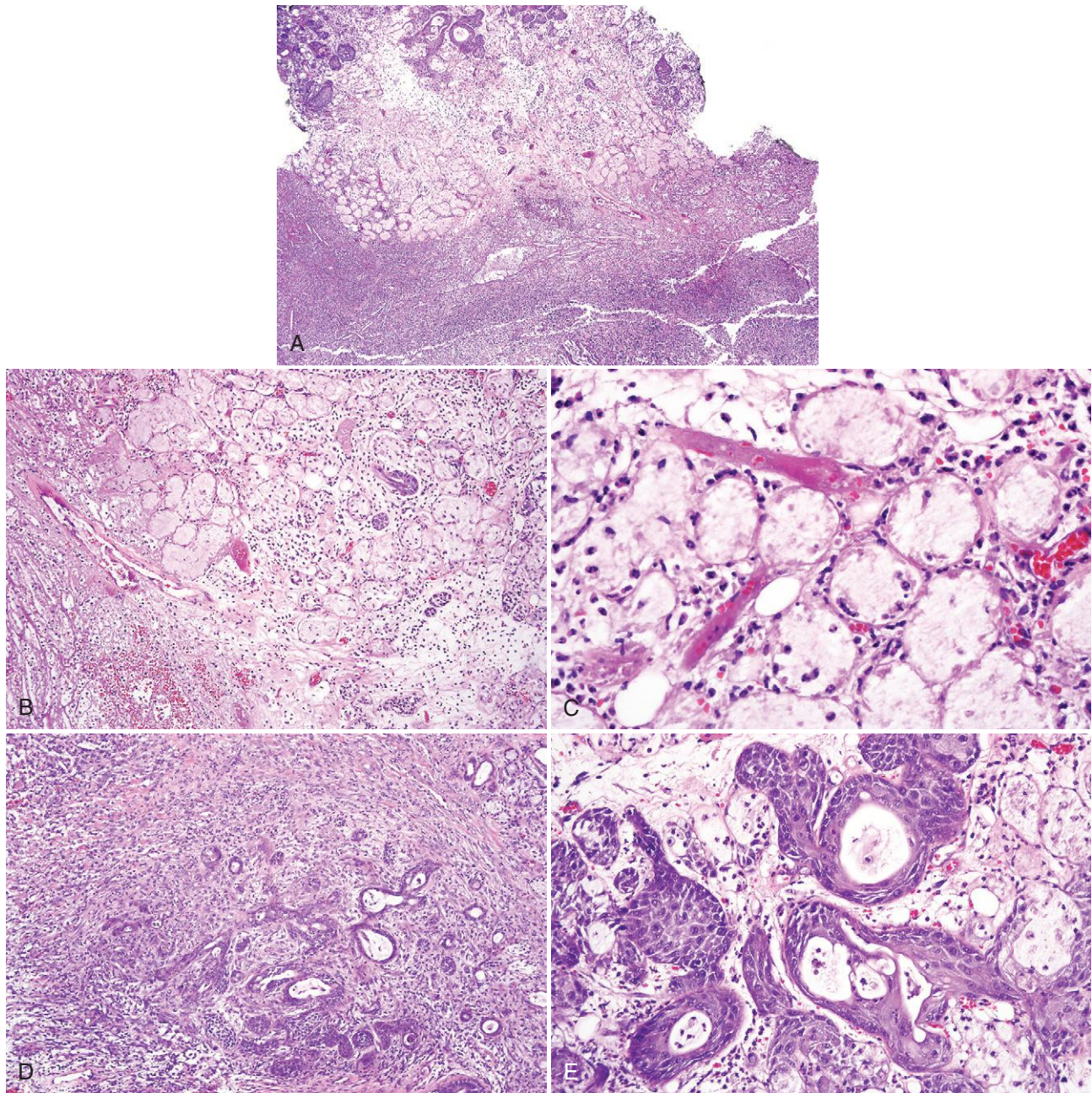


**FIGURE 12-25.** Necrotizing sialometaplasia: necrotic ulcer of the tongue.



**FIGURE 12-26.** Necrotizing sialometaplasia. **A,** Extensive necrosis of lobules. **B,** Pale outlines of infarcted acini, focal necrosis, and early squamous metaplasia. **C,** Squamous metaplasia with reactive atypia.





**FIGURE 12-27.** Necrotizing sialometaplasia. **A**, Diffuse necrosis and inflammation. **B**, Necrosis, inflammation, and infarction of acini. **C**, Pale outlines of acini and necrosis. **D**, Squamous metaplasia of ducts appearing pseudosarcomatoid. **E**, Squamous metaplasia of ducts with reactive atypia.

## SUBACUTE NECROTIZING SIALADENITIS

### Clinical Findings

- Lesions are diffuse, erythematous, usually nonulcerated, painful swellings of the hard palate (majority of cases), soft palate, tonsil, and (less commonly) buccal mucosa, tongue, and lip; usually occurs in young adults in the second and third decades.

### Etiopathogenesis and Histopathologic Features

The etiology is unknown, but infectious and hypersensitivity theories have been put forward. Some believe that this is a variant of necrotizing sialometaplasia, although this is unlikely.

- Diffuse interstitial infiltration by neutrophils, lymphocytes, plasma cells, histiocytes, and, often, eosinophils; possible inflammation of surrounding muscles



and nerves; maintenance of lobular architecture (Fig. 12-28, A and B)

- Multifocal acinar atrophy and necrosis secondary to inflammation; ductal dilatation with flattened ductal epithelium, loss of ductal integrity, and spillage of mucin (see Fig. 12-28, C)

#### Differential Diagnosis

- Necrotizing sialometaplasia is usually ulcerated but painless; it occurs in older patients, has a longer onset of many days to a few weeks, and is a more extensive lobular ischemic necrosis.
- Chronic sclerosing sialadenitis (Kuttner tumor) is seen mainly in the submandibular gland and is characterized by preservation of lobular architecture, florid lymphoid hyperplasia with geographic germinal centers, hypercellular interlobular fibrosis, acinar atrophy, and abundant IgG4 plasma cells;

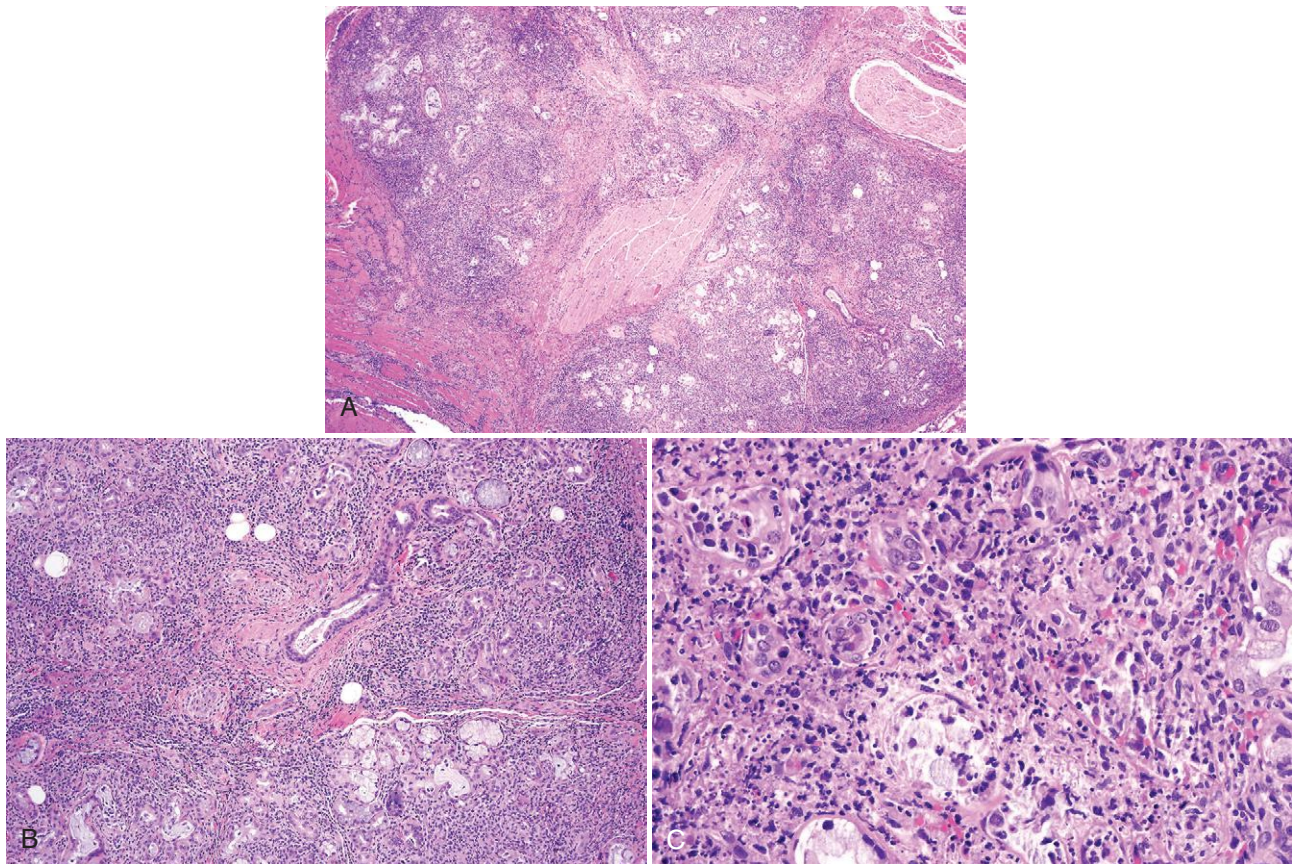
current thinking suggests that this represents IgG4-related sclerosing disease.

#### Management

- Self-limited and heals within a few weeks of the biopsy

#### REFERENCES

- Fowler CB, Brannon RB. Subacute necrotizing sialadenitis: report of 7 cases and a review of the literature. *Oral Surg Oral Med Oral Pathol Oral Radiol Endod.* 2000;89:600-609.
- Geyer JT, Ferry JA, Harris NL, et al. Chronic sclerosing sialadenitis (Kuttner's tumor) is an IgG4-associated disease. *Am J Surg Pathol.* 2010;34:202-210.
- Kitagawa S, Zen Y, Harada K, et al. Abundant IgG4-positive plasma cell infiltration characterizes chronic sclerosing sialadenitis (Kuttner's tumor). *Am J Surg Pathol.* 2005;29:783-791.
- Suresh L, Aguirre A. Subacute necrotizing sialadenitis: a clinicopathological study. *Oral Surg Oral Med Oral Pathol Oral Radiol Endod.* 2007;104:385-390.
- Werning JT, Waterhouse JP, Mooney JW. Subacute necrotizing sialadenitis. *Oral Surg Oral Med Oral Pathol.* 1990;70:756-759.



**FIGURE 12-28.** Subacute necrotizing sialadenitis. **A**, Maintenance of lobular architecture; marked interstitial inflammation. **B**, Acinar atrophy, interstitial fibrosis with acute and chronic inflammation. **C**, Necrosis of acini with acute inflammation.



## AUTOIMMUNE SIALADENITIS

Primary Sjögren syndrome involves the salivary and other exocrine glands, whereas secondary Sjögren syndrome exhibits concurrent involvement of other organ systems (such as with lupus erythematosus and rheumatoid arthritis).

### Clinical Features

- More than 80% are female, middle aged and older
- Dry eyes and dry mouth (keratoconjunctivitis sicca) and dry nasal passages
- Elevated antinuclear antibody, rheumatoid factor, and Ro and La antibodies; serum protein electrophoresis studies abnormal

### Etiopathogenesis and Histopathologic Features

Sjögren syndrome is an autoimmune disease characterized by T cell destruction of the exocrine glands and, in particular, the salivary glands.

- *Minor salivary glands*: periductal collections of 50 or more lymphocytes within a 1 mm<sup>2</sup> area called foci (Fig. 12-29); the higher the focus score, the more likely the diagnosis of Sjögren syndrome; as disease progresses, the lymphoid infiltrate replaces much of the gland parenchyma; lobular architecture is maintained; there is minimal evidence of nonspecific obstructive changes, such as significant ductal dilatation and interstitial fibrosis.
- If lymphocytes spill out of the lobules, forming a diffuse infiltrate with effacement of lobular architecture, work-up for lymphoma is indicated.
- *Major salivary gland*: lymphoepithelial sialadenitis is composed of islands and strands of epithelial cells in a diffuse lymphocytic infiltrate; lobular architecture is maintained; effacement of lobular architecture and proliferation of monocytoid lymphoid cells around

lymphoepithelial islands usually indicate presence of evolving lymphoma (usually marginal zone B-cell-type) (Figs. 12-30 and 12-31)

- Light chain restriction within plasma cells and heavy chain gene rearrangements are associated with progression to lymphoma.

### Differential Diagnosis

- Similar minor gland changes are seen in other connective tissue diseases.
- Lymphocytes in a periductal and interstitial location with prominent ductal ectasia and acinar atrophy are nonspecific findings or are caused by obstruction (Fig. 12-32).

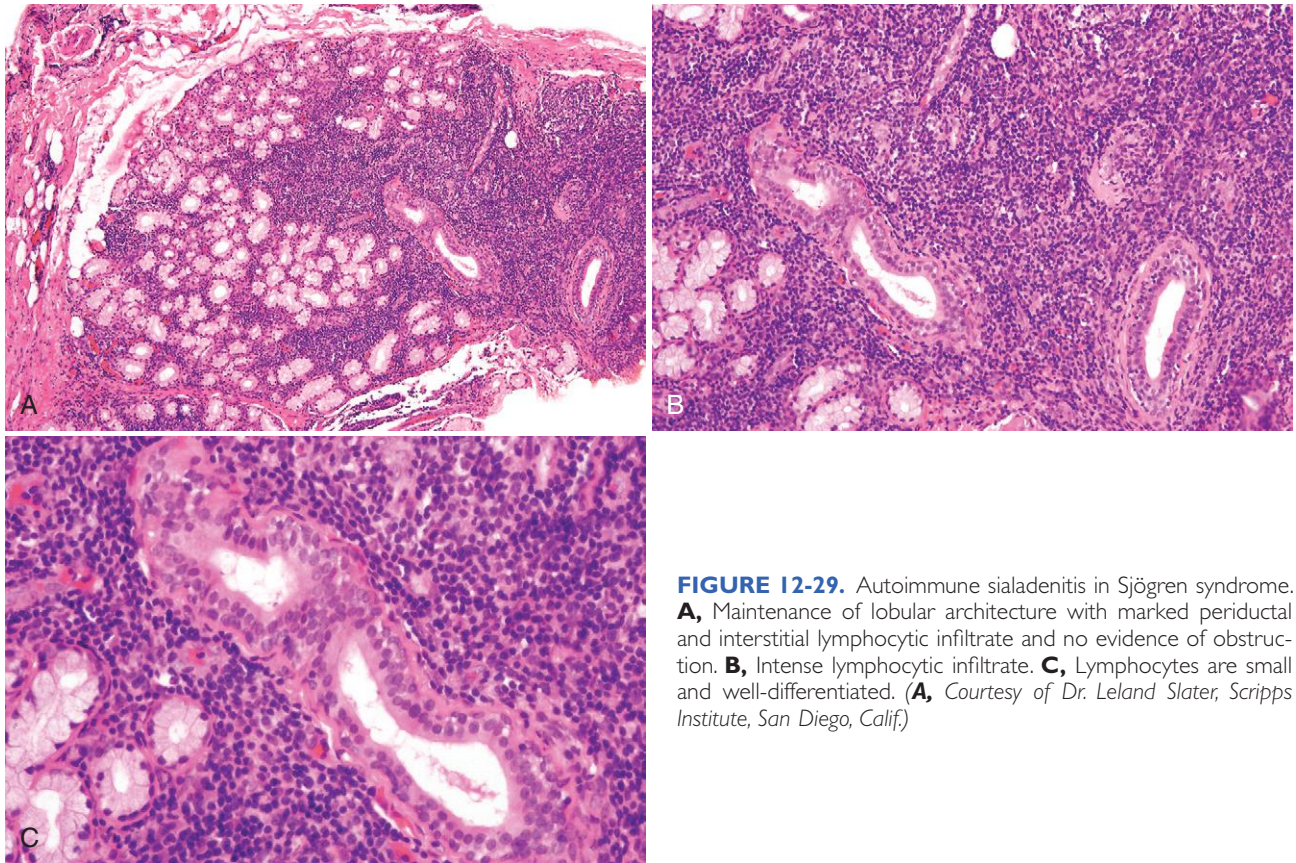
### Management

- Reduce discomfort from hyposalivation with cholinergic agents (such as bethanechol, pilocarpine, and cevimeline); provide careful follow-up to restore dry mouth caries.
- Provide follow-up for early detection of lymphoma (patients have up to a 44-fold increased risk).

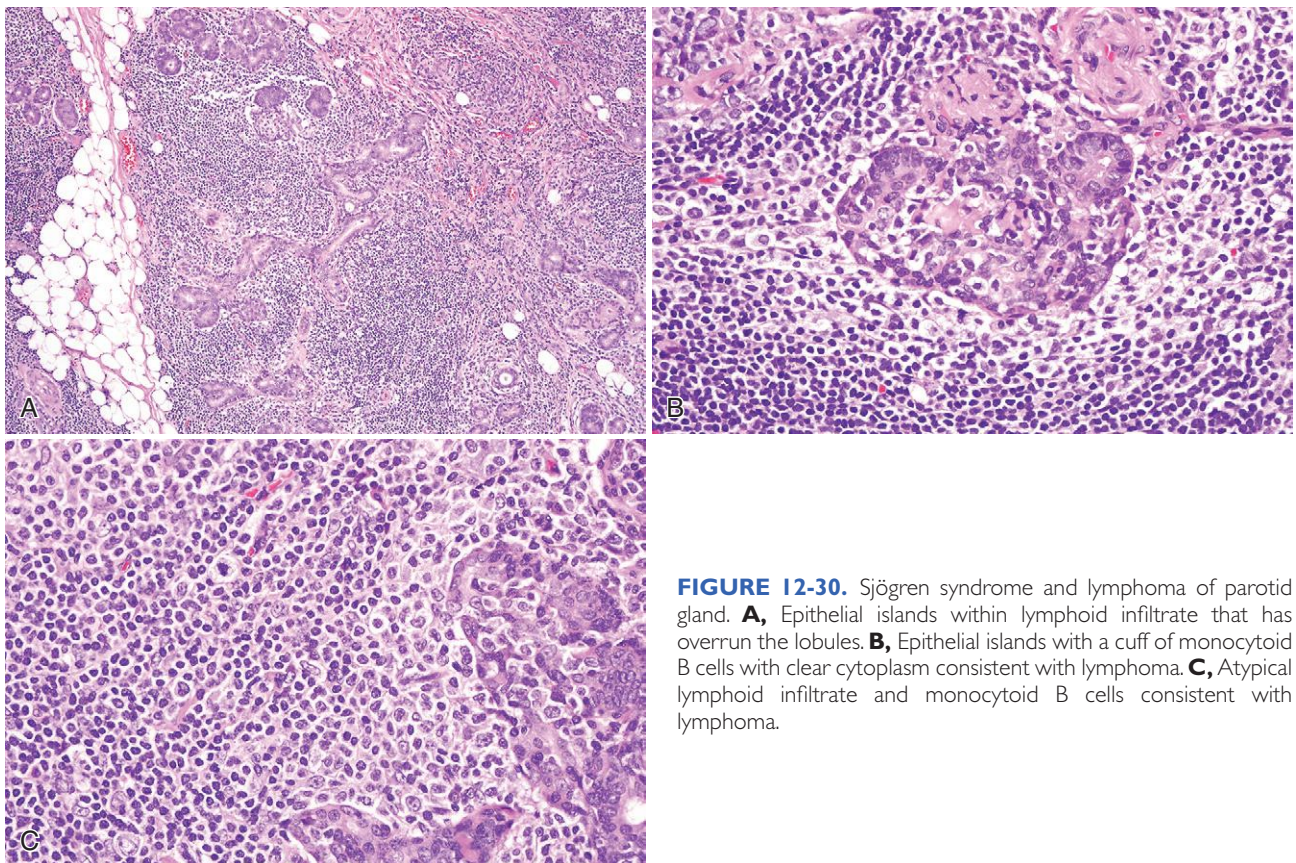
### REFERENCES

- Daniels TE. Salivary histopathology in diagnosis of Sjögren's syndrome. *Scand J Rheumatol Suppl.* 1986;61:36-43.
- Ellis G, Auclair P. *Tumors of the Salivary Glands*. Fourth Series ed. Silver Springs, Md: ARP Press; 2008.
- Giuca MR, Bonfigli D, Bartoli F, Pasini M. Sjögren's syndrome: correlation between histopathologic result and clinical and serologic parameters. *Minerva Stomatol.* 2010;59:149-154, 54-57.
- Jonsson R, Kroneld U, Backman K, et al. Progression of sialadenitis in Sjogren's syndrome. *Br J Rheumatol.* 1993;32:578-581.
- Jordan R, Diss TC, Lench NJ, et al. Immunoglobulin gene rearrangements in lymphoplasmacytic infiltrates of labial salivary glands in Sjogren's syndrome. A possible predictor of lymphoma development. *Oral Surg Oral Med Oral Pathol Oral Radiol Endod.* 1995;79:723-729.
- Jordan RC, Speight PM. Lymphoma in Sjogren's syndrome. From histopathology to molecular pathology. *Oral Surg Oral Med Oral Pathol Oral Radiol Endod.* 1996;81:308-320.



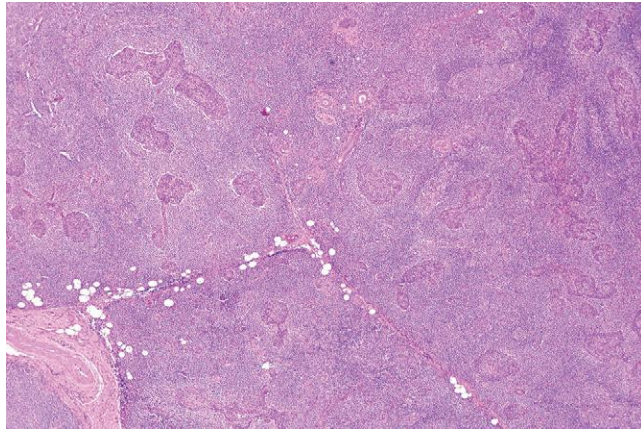


**FIGURE 12-29.** Autoimmune sialadenitis in Sjögren syndrome. **A**, Maintenance of lobular architecture with marked periductal and interstitial lymphocytic infiltrate and no evidence of obstruction. **B**, Intense lymphocytic infiltrate. **C**, Lymphocytes are small and well-differentiated. (**A**, Courtesy of Dr. Leland Slater, Scripps Institute, San Diego, Calif.)

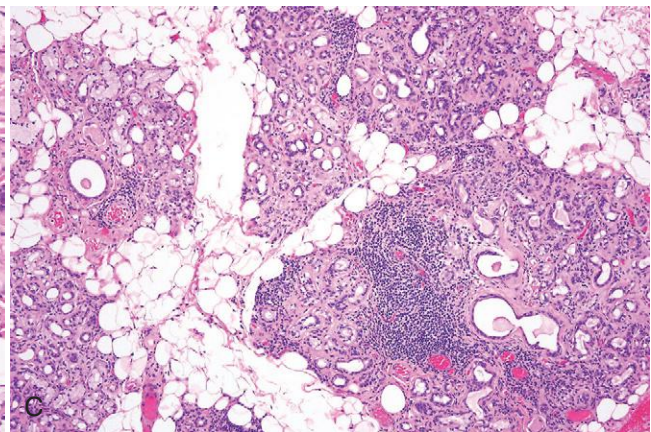
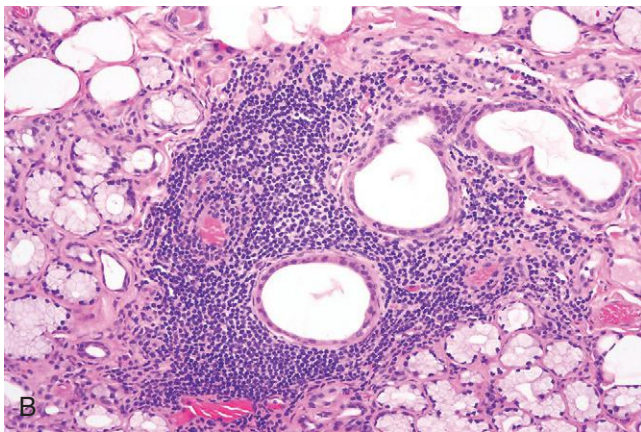
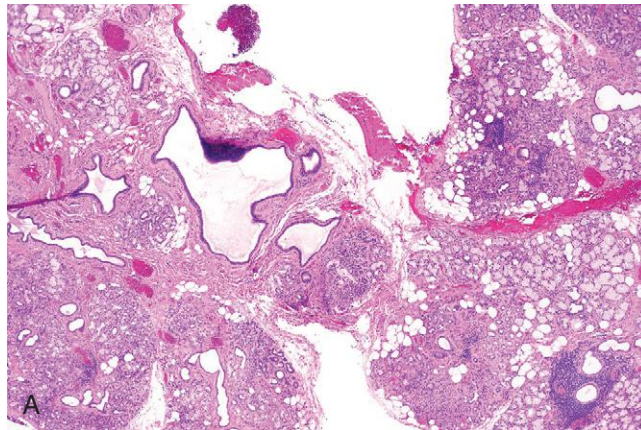


**FIGURE 12-30.** Sjögren syndrome and lymphoma of parotid gland. **A**, Epithelial islands within lymphoid infiltrate that has overrun the lobules. **B**, Epithelial islands with a cuff of monocytoid B cells with clear cytoplasm consistent with lymphoma. **C**, Atypical lymphoid infiltrate and monocytoid B cells consistent with lymphoma.





**FIGURE 12-31.** Lymphoma in Sjögren syndrome: marginal zone B-cell lymphoma has overrun the gland; lymphoepithelial islands are present.



**FIGURE 12-32.** Obstructive sialadenitis. **A**, Marked ductal dilatation and diffuse involvement of glands that maintain lobular architecture. **B**, Periductal inflammation present. **C**, Acinar atrophy, interstitial inflammation, and fibrosis.



## ADENOMATOID (ACINAR) HYPERPLASIA

Lesion represents an *acinar* hyperplasia as opposed to *adenomatoid* ductal hyperplasia that occurs mostly in the parotid gland.

### Clinical Findings

- Mostly found in adults; painless unilateral swelling of the palatal mucosa, usually without ulceration

### Etiopathogenesis and Histopathologic Features

This condition represents a reactive hyperplasia of acini, is often seen in smokers and denture wearers, and is found adjacent to neoplasms or necrotizing sialometaplasia.

- Hyperplasia and hypertrophy is of mucous acini that are back to back (Figs. 12-33 and 12-34).
- Mild focal fibrosis, ductal dilatation, and chronic inflammation may be present.

### Differential Diagnosis

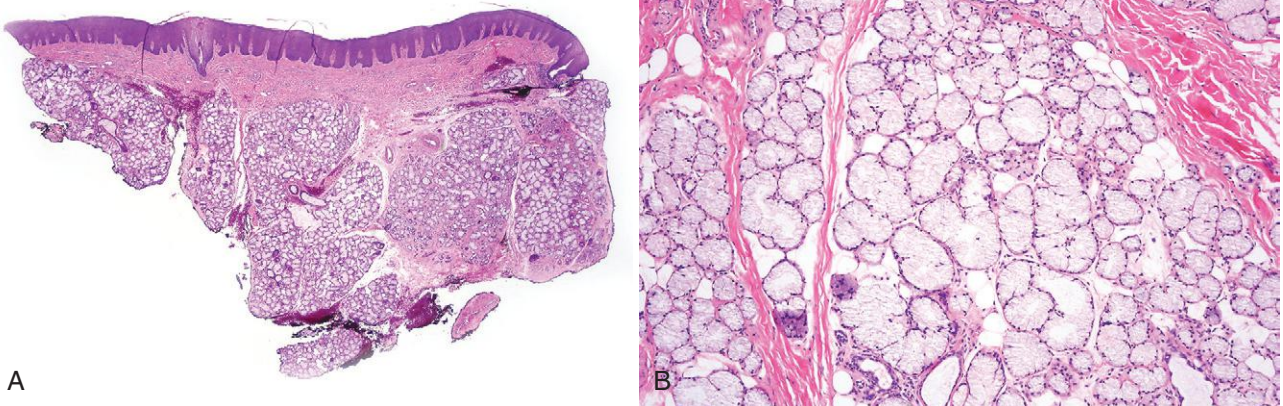
- As with ductal adenomatoid hyperplasia, this may be an indication of an adjacent salivary gland neoplasm in the vicinity.

### Management

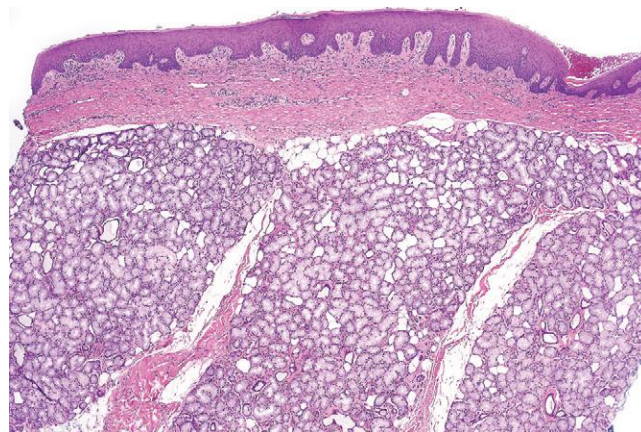
- Excision is the treatment of choice.

### REFERENCES

- Arafat A, Brannon RB, Ellis GL. Adenomatoid hyperplasia of mucous salivary glands. *Oral Surg Oral Med Oral Pathol.* 1981;52:51-55.
- Barrett AW, Speight PM. Adenomatoid hyperplasia of oral minor salivary glands. *Oral Surg Oral Med Oral Pathol Oral Radiol Endod.* 1995;79:482-487.
- Buchner A, Merrell PW, Carpenter WM, Leider AS. Adenomatoid hyperplasia of minor salivary glands. *Oral Surg Oral Med Oral Pathol.* 1991;71:583-587.
- Yu GY, Donath K. Adenomatous ductal proliferation of the salivary gland. *Oral Surg Oral Med Oral Pathol Oral Radiol Endod.* 2001; 91:215-221.



**FIGURE 12-33.** Adenomatoid hyperplasia of salivary glands. **A**, Hyperplastic mucous acini in the deep lamina propria. **B**, Hypertrophy and hyperplasia of mucous acini.



**FIGURE 12-34.** Adenomatoid hyperplasia of salivary glands: benign hyperplasia of acini.



## SCLEROSING POLYCYSTIC ADENOSIS

This is a rare salivary gland disorder usually seen in the major glands, and infrequently in the minor glands. Some clinicians consider it a pseudoneoplastic inflammatory condition, whereas others consider it a true neoplasm.

### Clinical Findings

- Nondescript movable nodule within the mucosa in adults in the fourth to fifth decade

### Etiopathogenesis and Histopathologic Features

There is a mixture of metaplastic and cystic changes suggestive of fibrocystic disease and sclerosing adenosis of the breast. A recent study suggests that these lesions are clonal. Changes in minor glands are not as marked, and lesions are not as sclerotic as those in major glands.

- Lesions demonstrate tubuloacinar hyperplasia with ducts of varying sizes, reactive cytologic atypia, marked interstitial fibrosis, hyalinization, and variable chronic inflammation; cribriform or microcystic pattern may be noted (Figs. 12-35, A and B, and 12-36, A).
- Dilated ducts exhibit oncocytic, apocrine-like, clear cell, and mucous cell metaplasia with inspissation of secretions and foamy macrophages (see Figs. 12-35, C and D, and 12-36, B); collagenous spherules may be present; large eosinophilic PAS-positive inclusions

are present in some acinar cells (altered zymogen granules) and within lumen.

### Differential Diagnosis

- Adenoma and adenocarcinoma are unlikely because of the diverse cytologic features of oncocytic and mucous cell metaplasia; adenocarcinoma exhibits invasion of surrounding tissues.

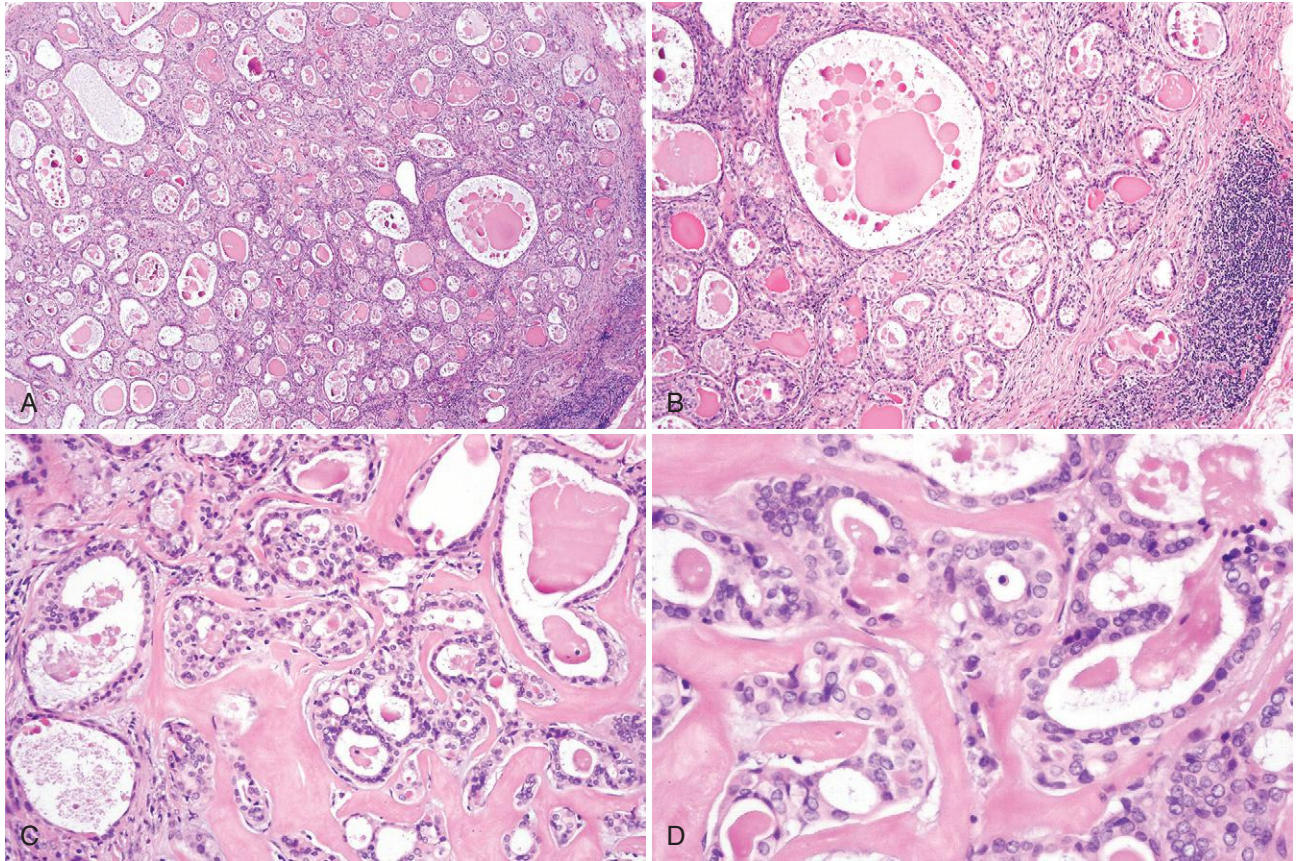
### Management

- Excision is treatment of choice and up to 30% of lesions recur, but carcinomatous transformation and metastases have not been reported.

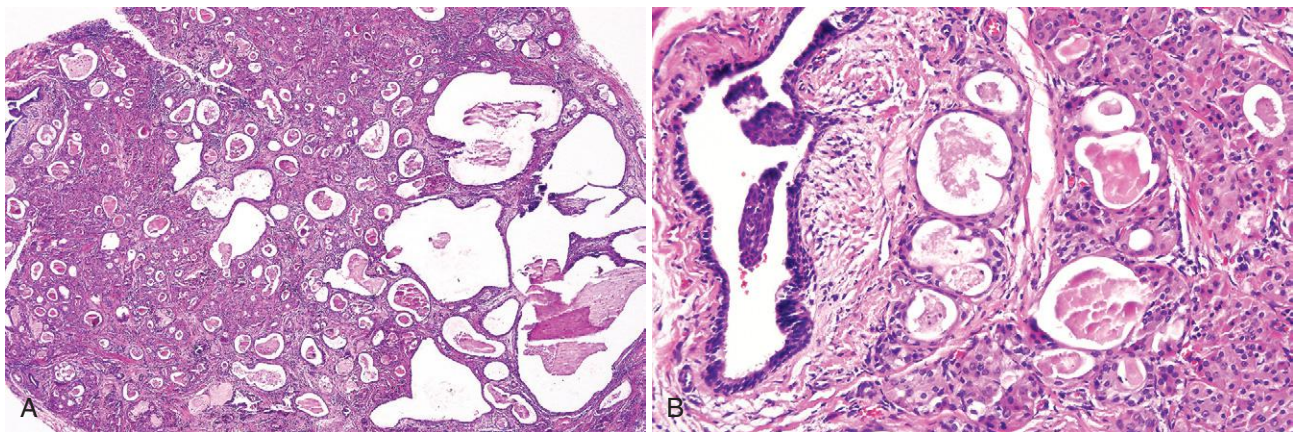
### REFERENCES

- Gnepp DR. Sclerosing polycystic adenosis of the salivary gland: a lesion that may be associated with dysplasia and carcinoma in situ. *Adv Anat Pathol.* 2003;10:218-222.
- Gnepp DR, Wang LJ, Brandwein-Gensler M, et al. Sclerosing polycystic adenosis of the salivary gland: a report of 16 cases. *Am J Surg Pathol.* 2006;30:154-164.
- Noonan VL, Kalmar JR, Allen CM, et al. Sclerosing polycystic adenosis of minor salivary glands: report of three cases and review of the literature. *Oral Surg Oral Med Oral Pathol Oral Radiol Endod.* 2007;104:516-520.
- Skalova A, Gnepp DR, Simpson RH, et al. Clonal nature of sclerosing polycystic adenosis of salivary glands demonstrated by using the polymorphism of the human androgen receptor (HUMARA) locus as a marker. *Am J Surg Pathol.* 2006;30:939-944.
- Smith BC, Ellis GL, Slater LJ, Foss RD. Sclerosing polycystic adenosis of major salivary glands. A clinicopathologic analysis of nine cases. *Am J Surg Pathol.* 1996;20:161-170.





**FIGURE 12-35.** Sclerosing polycystic adenosis. **A**, Ductal proliferation with inflammation and fibrosis. **B**, Lumina filled with secretions; fibrosis and chronic inflammation. **C**, Hyalinization may be prominent; oncocytes present. **D**, Cribriform pattern and cells with benign nuclear morphology.



**FIGURE 12-36.** Sclerosing polycystic adenosis. **A**, Dilated ducts of varying sizes, inflammation, and fibrosis. **B**, Oncocytic metaplasia.



# 13

## SALIVARY GLAND NEOPLASMS

### CHAPTER CONTENTS

BENIGN SALIVARY GLAND NEOPLASMS	286
Pleomorphic Adenoma and Myoepithelioma	286
Canalicular Adenoma	293
Cystadenoma, Papillary or Otherwise	295
Sialadenoma Papilliferum	298
Intraductal Papilloma	299
Inverted Ductal Papilloma	300
MALIGNANT SALIVARY GLAND NEOPLASMS	301
Mucoepidermoid Carcinoma	301
Adenoid Cystic Carcinoma	305
Polymorphous Low-Grade Adenocarcinoma	309
Acinic Cell Adenocarcinoma	313
Clear Cell Adenocarcinoma (Hyalinizing)	316
Adenocarcinoma, Not Otherwise Specified	318

Only the most common benign and malignant lesions of minor glands will be discussed in this section. Intraoral minor salivary gland neoplasms account for 1% to 2% of nonhospital-based biopsy services, with 60% of these being benign. There is a female predominance.

In general, benign salivary gland neoplasms are diagnosed by histomorphology alone. Ductal cells show cytoplasmic positivity for AE1/3, CAM5.2, cytokeratin (CK) 5/6, CK7, and CK19, and sometimes CK14. Myoepithelial cells are immunopositive for pancytokeratin, S-100 protein, CK14, glial fibrillary acidic protein (GFAP) (mostly in the myxoid areas), calponin, smooth muscle actin, smooth muscle myosin long chain, maspin, and p63 (p63 also stains basal cells). Serous acinar cells stain for gross cystic disease fluid protein-15. Most tumors are thought to arise from the intercalated duct reserve cell or its precursor that differentiates into acinar, myoepithelial, striated, and intercalated ductal cells. The excretory duct reserve cell differentiates into excretory ductal cells and gives rise to tumors such as mucoepidermoid carcinoma and salivary duct carcinoma.

### Benign Salivary Gland Neoplasms

#### Clinical Features

Benign salivary gland neoplasms manifest similarly regardless of the final histologic diagnosis. The pleomorphic adenoma (sometimes referred to as the benign

mixed tumor) and myoepithelioma are the most common intraoral benign neoplasms (60% to 80% of all cases), followed by canalicular adenoma and cystadenoma. These tumors are putatively thought to arise from intercalated duct reserve cells within the secretory unit.

- Neoplasms are usually seen in adults as a painless nodule or mass, often mobile, usually covered by normal mucosa, although trauma may cause overlying ulceration.
- Palate is the most common site, followed by upper lip (90% of canalicular adenomas occur at this site) (Fig. 13-1).

### PLEOMORPHIC ADENOMA AND MYOEPITHELIOMA

#### Etiopathogenesis and Histopathologic Features

This neoplasm putatively arises from the intercalated duct reserve cell (or its precursor) and differentiates toward ductal and myoepithelial elements, and it is the latter that gives this neoplasm its distinctive stromal appearance because of its ability to produce myxochondroid matrix, bone, and even fat. The term *myoepithelioma* is used by some pathologists to mean a myoepithelial cell–predominant neoplasm with few ducts, whereas other clinicians use that term only if no ducts are present, preferring the term *pleomorphic adenoma*, *myoepithelial predominant* for the former lesions.

- Partially or nonencapsulated tumor; proliferation of ducts with a cuff of epithelioid myoepithelial cells,



with the myoepithelial cells merging into the myxochondroid stroma (Fig. 13-2, A-E); infiltration of the capsule a common finding (see Fig. 13-2, F); some tumors are cellular with little stroma, or may look fairly homogeneous, whereas other tumors are predominantly myxoid (Figs. 13-3 and 13-4)

- Myoepithelial cells positive for CK5/6, CK14, S-100 protein, GFAP, p63, calponin, smooth muscle actin, and smooth muscle myosin long chain (Fig. 13-5)
- Keratin pearls, osseous material, foci of mucous cells, oncocytes, mature fat, and crystalline material variably present (Figs. 13-6 to 13-8)
- Myoepithelial cells may be epithelioid, spindle, plasmacytoid, or clear; plasmacytoid myoepithelial cells having abundant eosinophilic cytoplasm and eccentric nuclei that vary in shape and size, dispersed chromatin, and small or inconspicuous nucleoli (Figs. 13-9 and 13-10)
- Significant cytologic atypia (not just variation in nuclear shape and size) seen in atypical pleomorphic adenoma, intracapsular carcinoma, or noninvasive carcinoma ex pleomorphic adenoma

**Differential Diagnosis**

- Aprocrine chondroid syringoma of the skin may appear identical, although there may be apocrine decapitation secretion within ducts and follicular and sebaceous differentiation.
- Spindle cell lipoma or other benign mesenchymal neoplasm/hamartoma with bone, cartilage, and fat differentiation do not show immunopositivity for keratin within the spindle cells.
- Plasmacytomas have coarse “clock-face” chromatin and the zone of Hopf and are S-100 and cytokeratin negative and CD138 positive.

- Presence of significant hyalinization must prompt a search for carcinoma or adenocarcinoma ex pleomorphic adenoma; myoepithelial carcinoma has been reported infrequently intraorally (Figs. 13-11 and 13-12).

**Management and Prognosis**

- Excision with clear margins is treatment of choice, and the recurrence rate is insignificant for intraoral lesions.
- Malignant transformation may occur in long-standing tumors, although this is a rare phenomenon.

**REFERENCES**

Auclair PL, Ellis GL. Atypical features in salivary gland mixed tumors: their relationship to malignant transformation. *Mod Pathol.* 1996;9:652-657.

Buchner A, Merrell PW, Carpenter WM. Relative frequency of intraoral minor salivary gland tumors: a study of 380 cases from northern California and comparison to reports from other parts of the world. *J Oral Pathol Med.* 2007;36:207-214.

Cheuk W, Chan JK. Advances in salivary gland pathology. *Histopathology.* 2007;51:1-20.

Ellis GL, Auclair PL. *Tumors of the Salivary Glands.* Washington, D.C.: American Registry of Pathology; 2008.

Haskell HD, Butt KM, Woo SB. Pleomorphic adenoma with extensive lipometaplasia: report of three cases. *Am J Surg Pathol.* 2005;29:1389-1393.

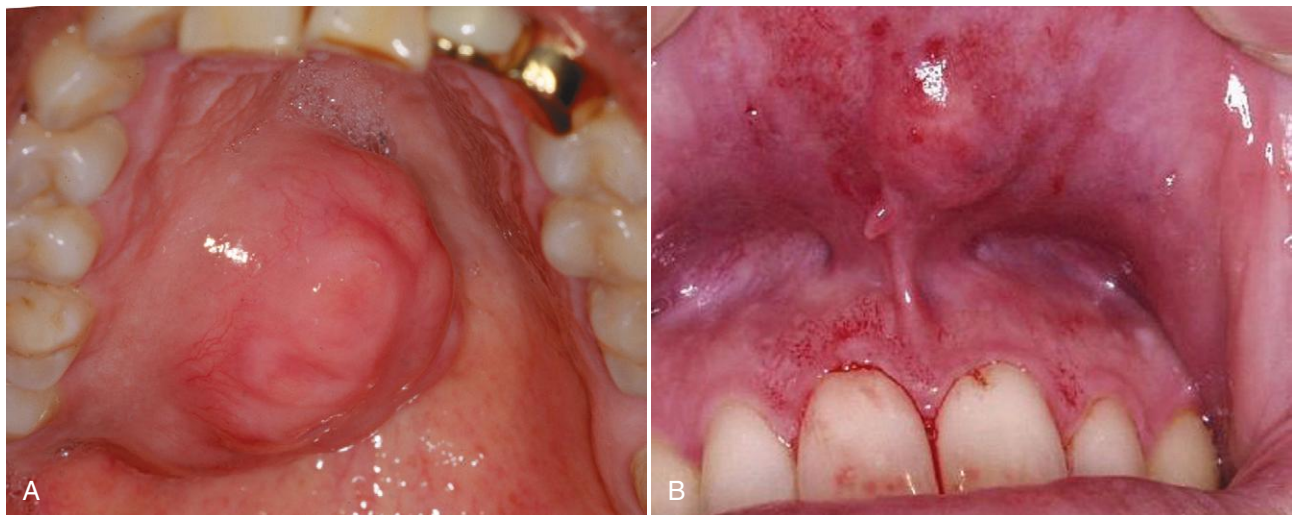
Lewis JE, Olsen KD, Sebo TJ. Carcinoma ex pleomorphic adenoma: pathologic analysis of 73 cases. *Hum Pathol.* 2001;32:596-604.

Reis-Filho JS, Simpson PT, Martins A, et al. Distribution of p63, cytokeratins 5/6 and cytokeratin 14 in 51 normal and 400 neoplastic human tissue samples using TARP-4 multi-tumor tissue microarray. *Virchows Arch.* 2003;443:122-132.

Savera AT, Sloman A, Huvos AG, Klimstra DS. Myoepithelial carcinoma of the salivary glands: a clinicopathologic study of 25 patients. *Am J Surg Pathol.* 2000;24:761-774.

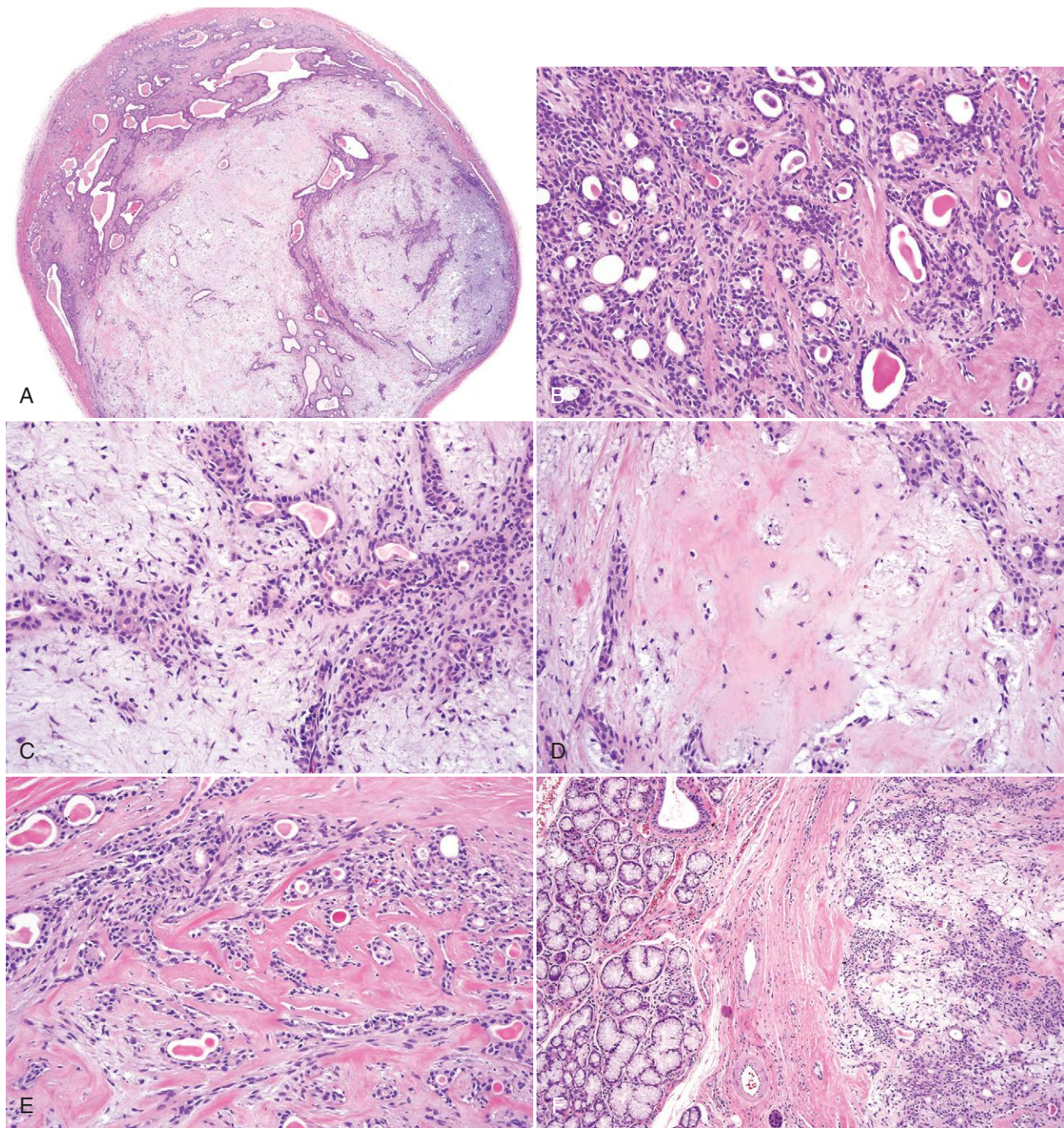
Sciubba JJ. Myoepithelioma of salivary glands: report of 23 cases. *Cancer.* 1982;47:562-572.

Yang S, Li L, Zeng M, et al. Myoepithelial carcinoma of intraoral minor salivary glands: a clinicopathological study of 7 cases and review of the literature. *Oral Surg Oral Med Oral Pathol Oral Radiol Endod.* 2010;110:85-193.



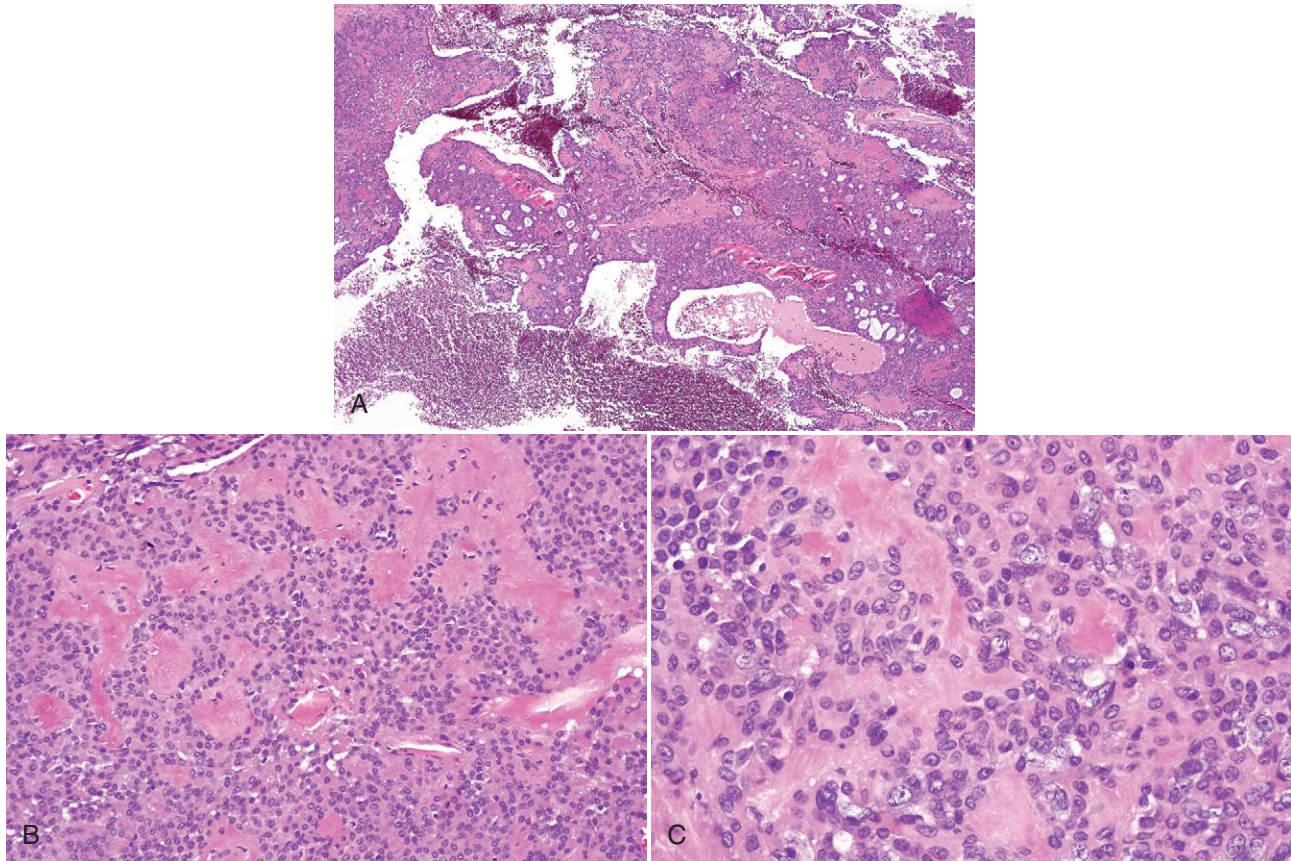
**FIGURE 13-1.** **A**, Pleomorphic adenoma of the palate. **B**, Canalicular adenoma of the upper labial mucosa. (Courtesy of Dr. John Sexton, private practice, Wellesley, Mass.)



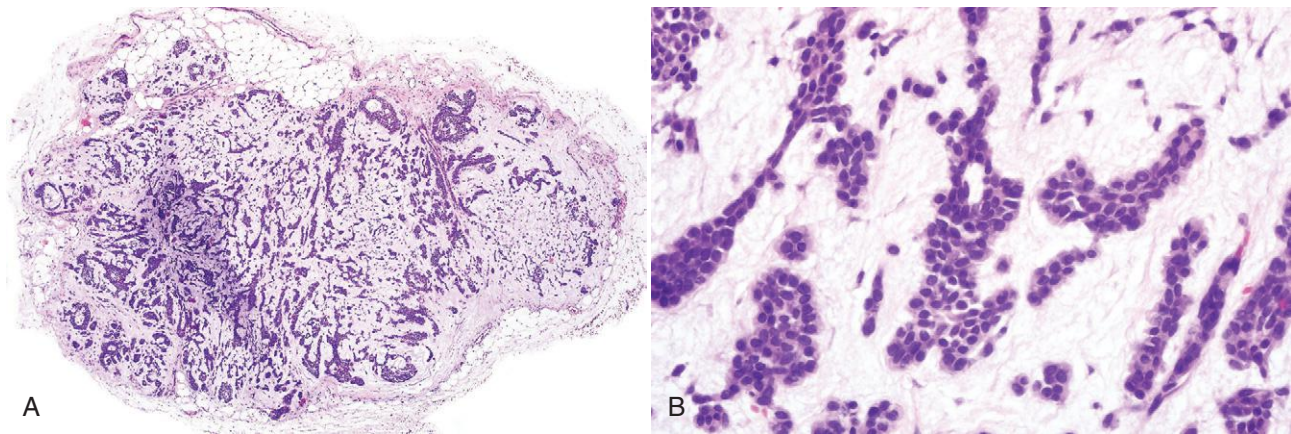


**FIGURE 13-2.** Pleomorphic adenoma. **A**, Encapsulated tumor with prominent myxochondroid areas. **B**, Ducts surrounded by myoepithelial cells that merge into hyalinized stroma. **C**, Ducts with surrounding epithelioid myoepithelial cells merge into myxoid stroma that contains spindled myoepithelial cells. **D**, Cartilage within the stroma. **E**, Densely hyalinized stroma with ducts and myoepithelial cuff. **F**, Tumor may focally infiltrate the capsule.



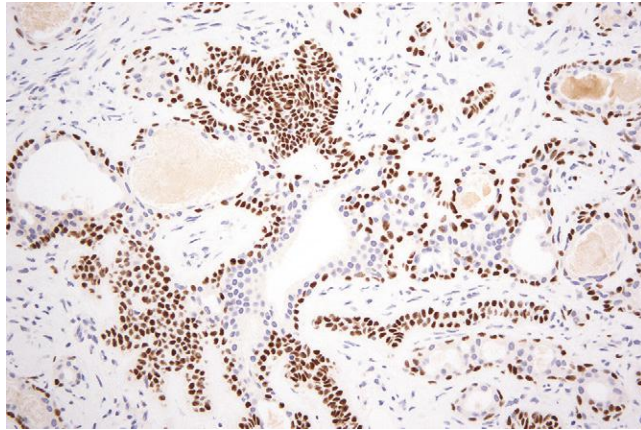


**FIGURE 13-3.** Pleomorphic adenoma. **A**, Fragmented tumor with ducts and hyalinized stroma. **B**, Sheets of epithelioid myoepithelial cells with hyalinized stroma. **C**, Myoepithelial cells often show variation in nuclear shape and size, but they still contain dispersed chromatin.

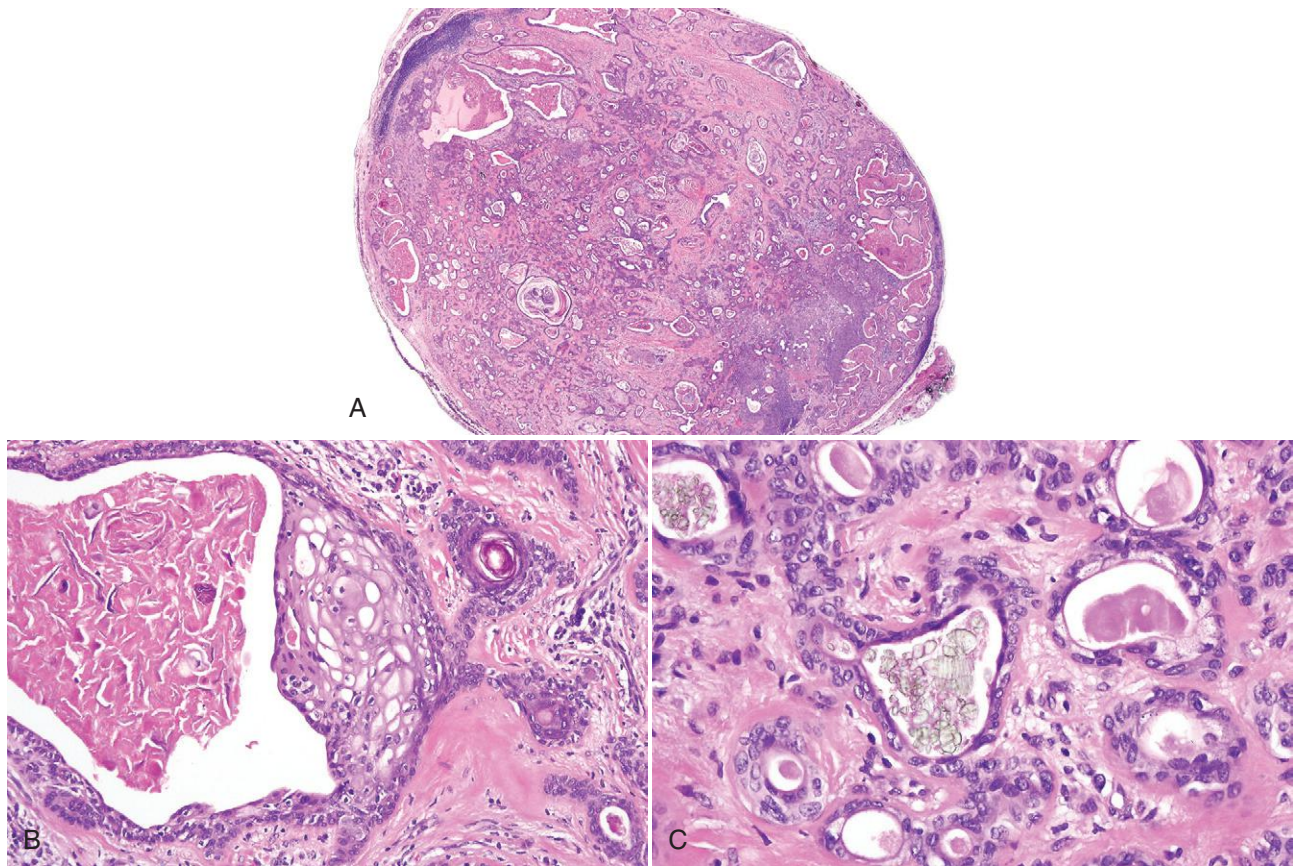


**FIGURE 13-4.** Myxoid pleomorphic adenoma. **A**, Myxoid tumors containing occasional ducts (top) with infiltration of fat. **B**, Epithelioid and spindled myoepithelial cells in myxoid stroma.



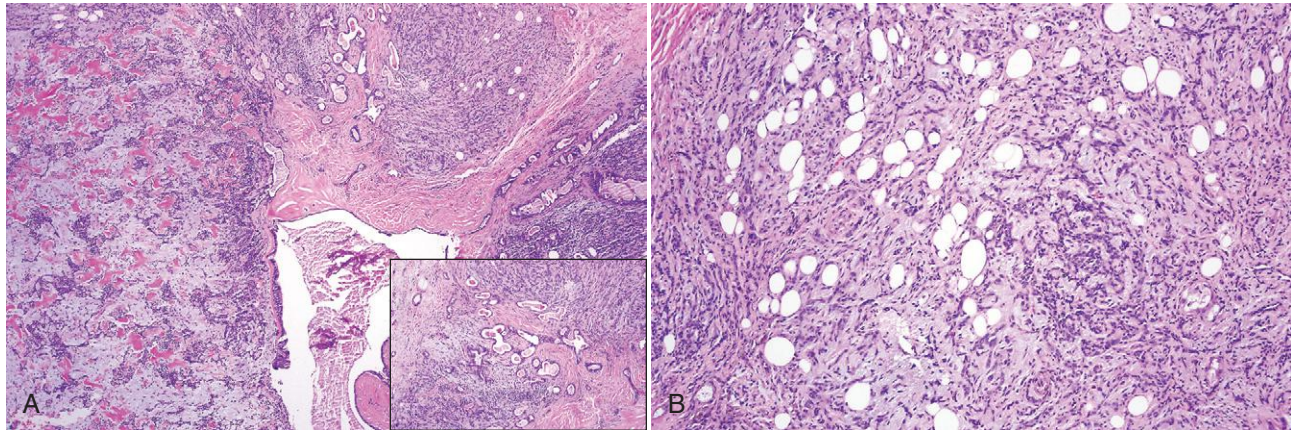


**FIGURE 13-5.** Pleomorphic adenoma: p63 is positive within myoepithelial cells surrounding ducts.

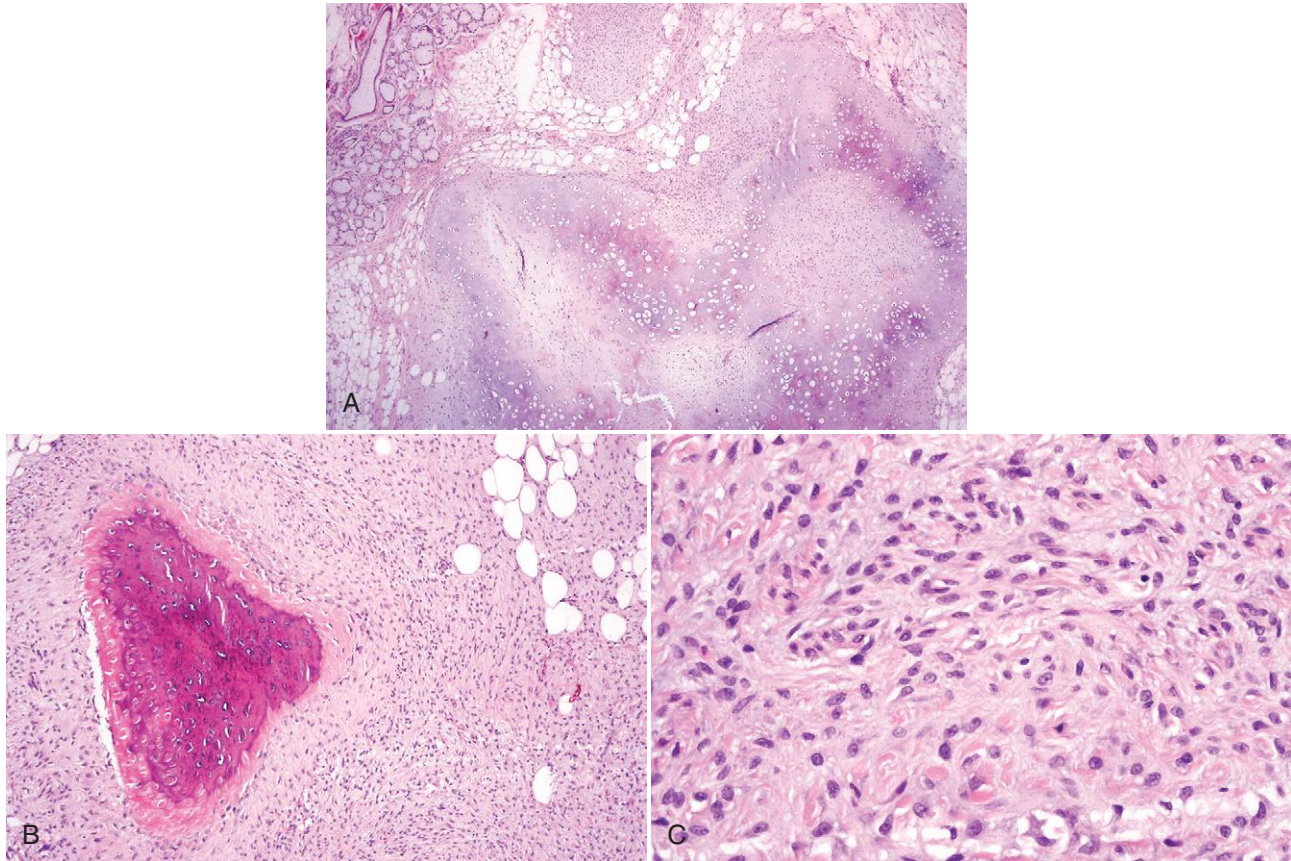


**FIGURE 13-6.** Pleomorphic adenoma. **A,** Pleomorphic adenoma with cystically dilated ducts. **B,** Squamous metaplasia and keratin formation. **C,** Mucous cells and crystalline bodies.



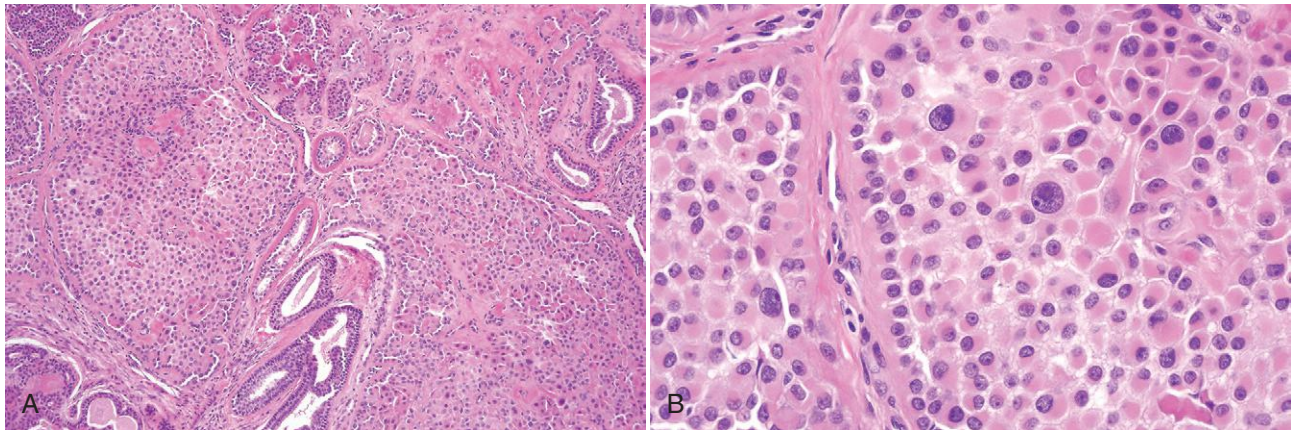


**FIGURE 13-7.** Pleomorphic adenoma. **A**, Proliferation of spindle cells, some ductal structures, and fat cells in myxoid and hyalinized stroma (*inset*). **B**, Mature lipocytes are interspersed with spindled myoepithelial cells.

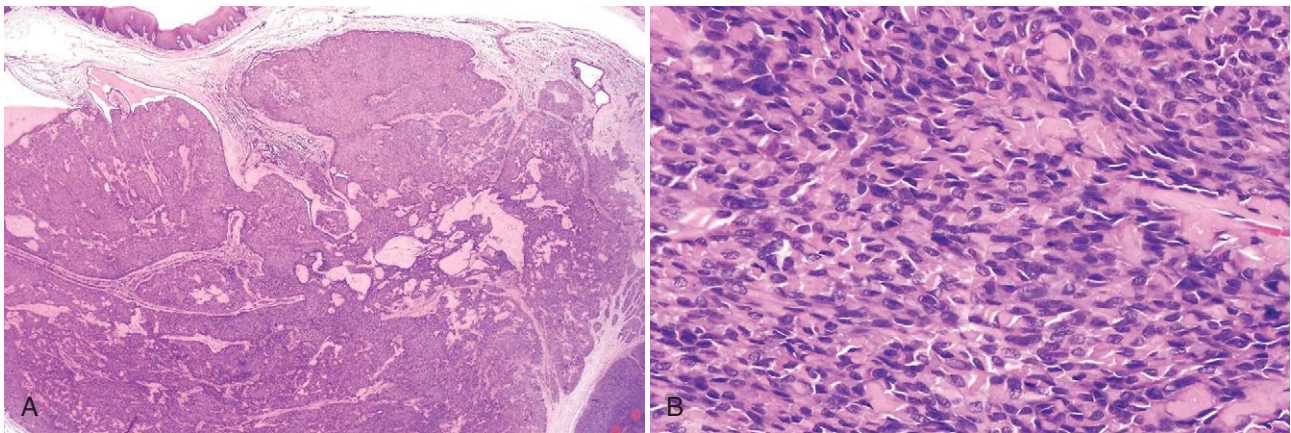


**FIGURE 13-8.** Spindle cell myoepithelioma of palate. **A**, Spindle cell proliferation with formation of cartilage and fat. **B**, Focal area of osseous metaplasia. **C**, Spindled myoepithelial cells in myxoid stroma.

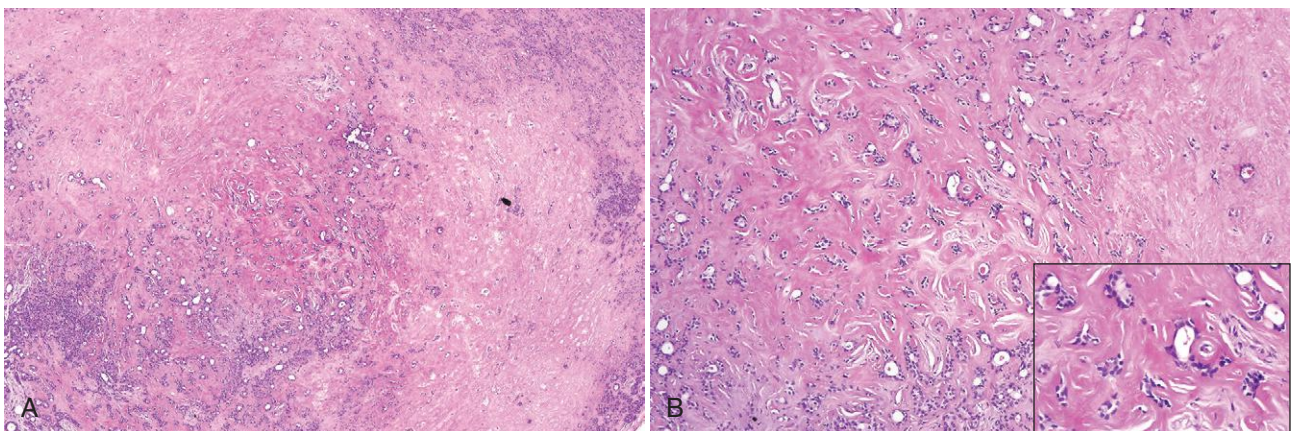




**FIGURE 13-9.** Pleomorphic adenoma. **A**, Sheets of plasmacytoid myoepithelial cells with focal duct formation. **B**, Cells with eccentric pleomorphic nuclei and abundant eosinophilic cytoplasm.

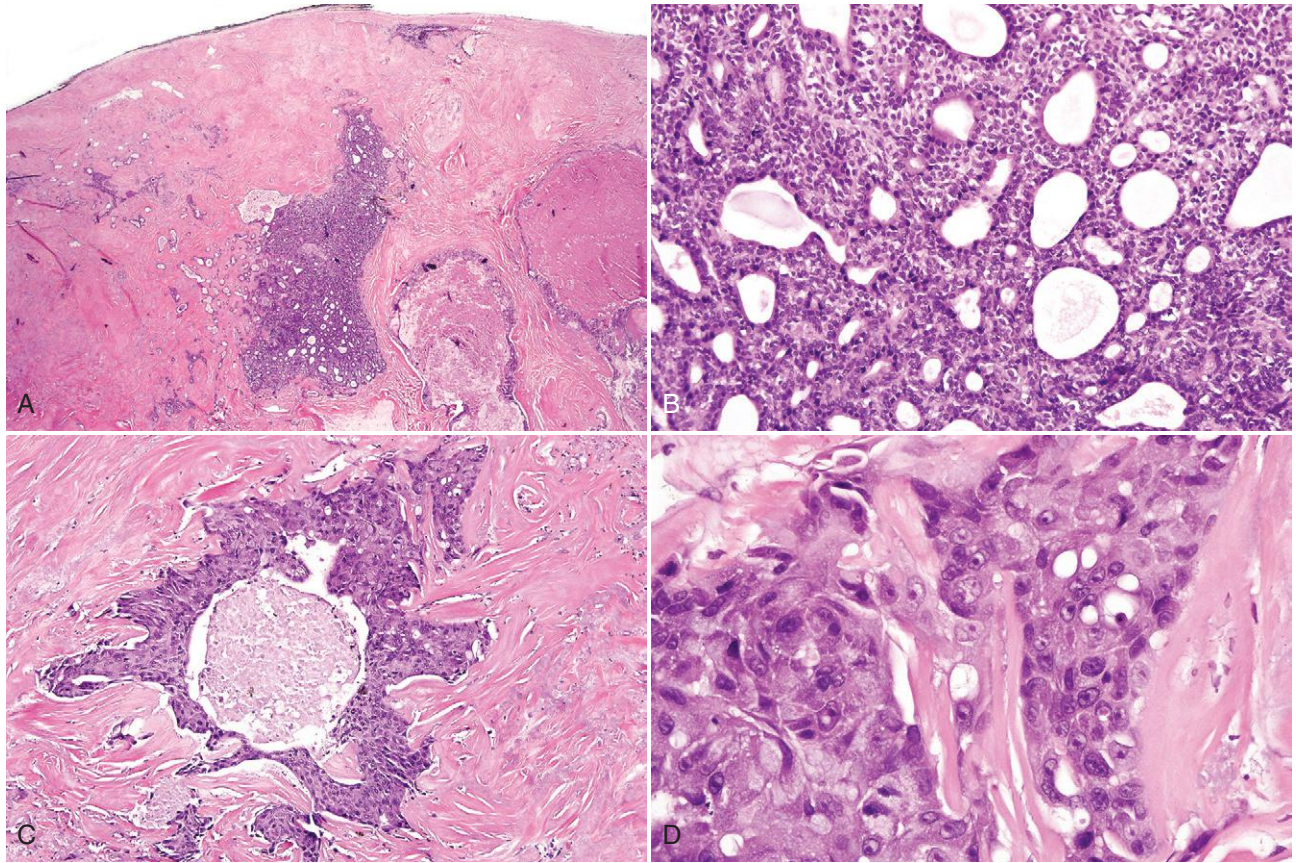


**FIGURE 13-10.** Myoepithelioma. **A**, Myoepithelioma showing sheets of myoepithelial cells without duct formation. **B**, Plasmacytoid myoepithelial cells with abundant eosinophilic cytoplasm.



**FIGURE 13-11.** Pleomorphic adenoma. **A**, Tumor with extensive hyalinization. **B**, Ducts exhibit benign cytology surrounded by densely hyalinized stroma (*inset*).





**FIGURE 13-12.** Carcinoma ex pleomorphic adenoma of the upper lip. **A**, Pleomorphic adenoma with extensive hyalinization and adenocarcinoma (right). **B**, Remnant pleomorphic adenoma. **C**, Adenocarcinoma with comedonecrosis. **D**, Adenocarcinoma with pleomorphic nuclei.

## CANALICULAR ADENOMA

### Etiopathogenesis and Histopathologic Features

This tumor is likely to arise from intercalated duct reserve cells with differentiation toward ductal cells with minimal-to-no myoepithelial differentiation.

- Encapsulated proliferation of basaloid cells, usually in two layers, in anastomosing trabeculae and ribbon-like strands that enclose narrow, elongated ducts and channels (canaliculi); adenoma may be focally cystic; cells have spindled nuclei with dispersed chromatin and small nucleoli; collagen-poor, mucinous/myxoid stroma, sometimes hyalinized with prominent ectatic capillaries (Figs. 13-13 and 13-14); some tumor strands have multiple layers of epithelium resembling trabecular basal cell adenoma of the major glands (Fig. 13-15); generally negative for p63, smooth muscle actin, and other myoepithelial markers, but may be positive for S-100 protein.
- Foci of early canalicular adenoma within adjacent gland lobules is not unusual.

### Differential Diagnosis

- Basal cell adenoma (usually in the major glands) has a distinct basal cell layer, lacks myxohyaline stroma, and often has basement membrane-like deposits.

- Low-grade adenocarcinoma lacks encapsulation and infiltrates adjacent structures.
- Ductal adenoma (striated duct adenoma) does not have the anastomosing strands of cells, but forms ducts that are p63 positive.
- Adenoid cystic carcinoma, tubular-type, contains angular, hyperchromatic nuclei and stains strongly for c-kit.

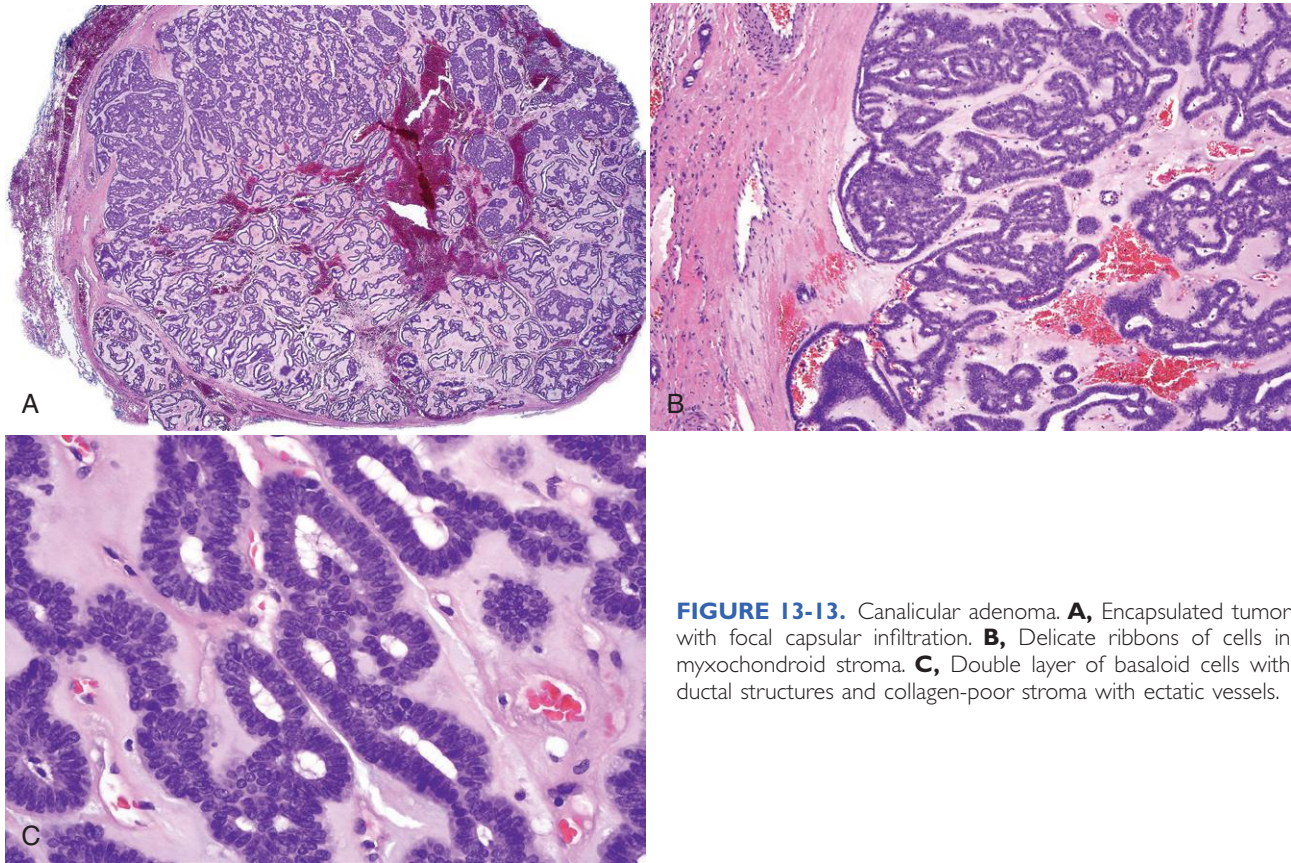
### Management

- Enucleation or excision with clear margins is curative.

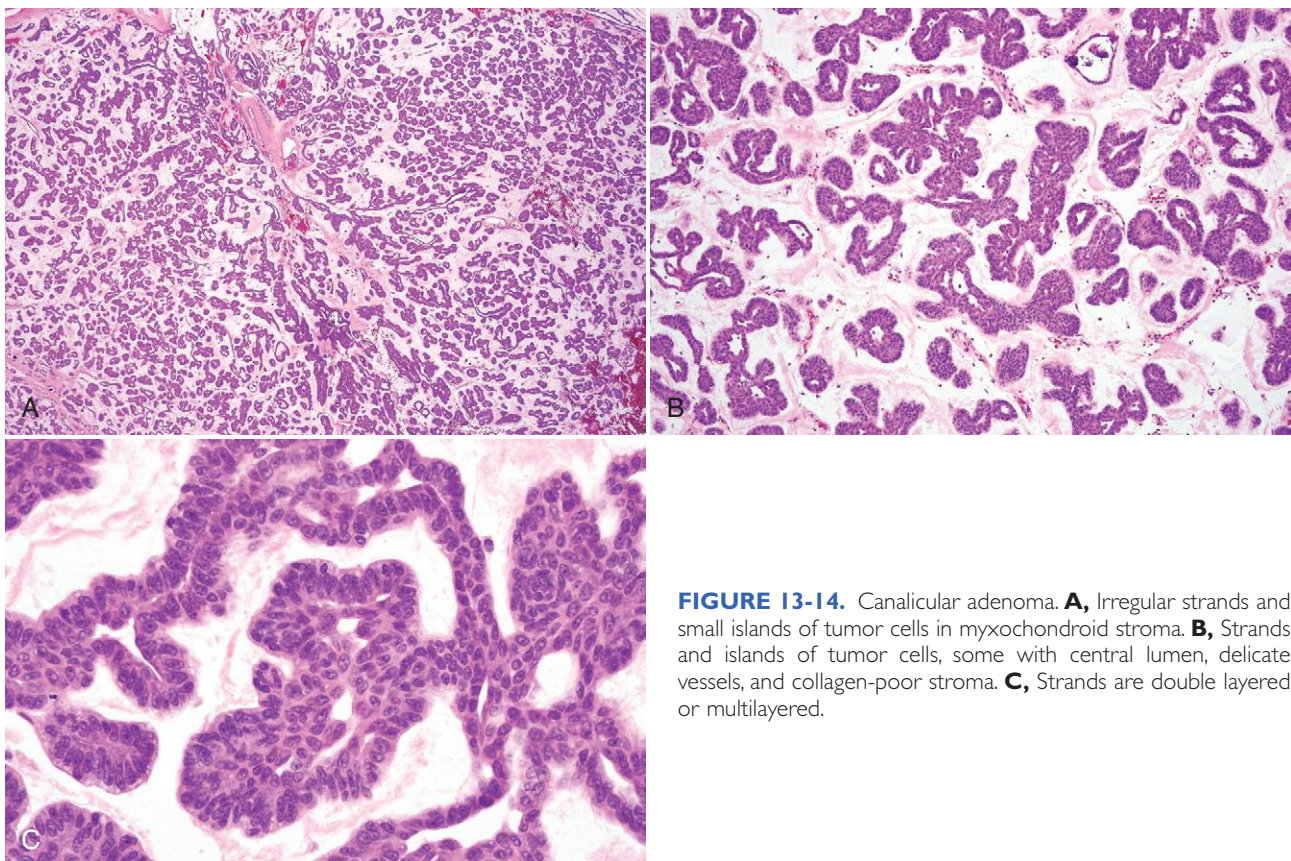
### REFERENCES

- Edwards PC, Bhuiya T, Kelsch RD. Assessment of p63 expression in the salivary gland neoplasms adenoid cystic carcinoma, polymorphous low-grade adenocarcinoma, and basal cell and canalicular adenomas. *Oral Surg Oral Med Oral Pathol Oral Radiol Endod.* 2004;97:613-619.
- Fantasia JE, Neville BW. Basal cell adenomas of the minor salivary glands. A clinicopathologic study of seventeen new cases and a review of the literature. *Oral Surg Oral Med Oral Pathol.* 1980;50:433-440.
- Ferreiro JA. Immunohistochemical analysis of salivary gland canalicular adenoma. *Oral Surg Oral Med Oral Pathol.* 1994;78:761-765.
- Weinreb I, Simpson RH, Skalova A, et al. Ductal adenomas of salivary gland showing features of striated duct differentiation ('striated duct adenoma'): a report of six cases. *Histopathology.* 2010;57:707-715.



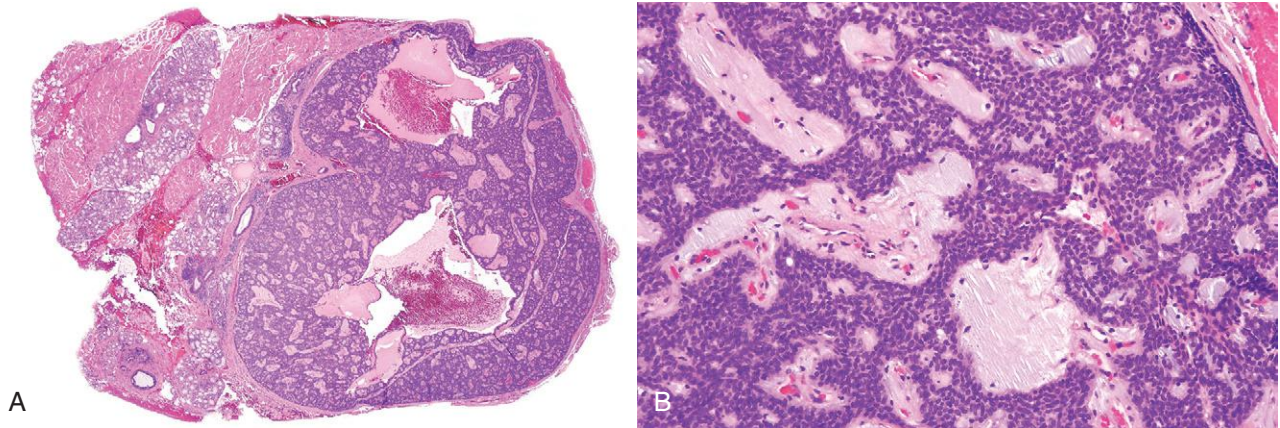


**FIGURE 13-13.** Canaliculal adenoma. **A**, Encapsulated tumor with focal capsular infiltration. **B**, Delicate ribbons of cells in myxochondroid stroma. **C**, Double layer of basaloid cells with ductal structures and collagen-poor stroma with ectatic vessels.



**FIGURE 13-14.** Canaliculal adenoma. **A**, Irregular strands and small islands of tumor cells in myxochondroid stroma. **B**, Strands and islands of tumor cells, some with central lumen, delicate vessels, and collagen-poor stroma. **C**, Strands are double layered or multilayered.





**FIGURE 13-15.** Canalicular adenoma. **A**, Encapsulated tumor with cystic change. **B**, Trabeculae of basaloid cells with plexiform pattern in collagen-poor stroma.

## CYSTADENOMA, PAPILLARY OR OTHERWISE

### Etiopathogenesis and Histopathologic Features

This tumor likely arises from the intercalated duct reserve cell.

- Encapsulated or well-circumscribed adenomatous proliferation of ducts, some of which form large cystic structures into which papillary structures with delicate fibrovascular cores protrude; cysts lined by one to two layers of low cuboidal-to-columnar cells, oncocytes, or mucous cells; nuclei have dispersed chromatin, small nucleoli, and insignificant mitotic activity (Figs. 13-16 to 13-18).

### Differential Diagnosis

- Reactive multifocal metaplasia of ducts (sialocystosis) is nonencapsulated and shows cystically dilated ducts in multiple salivary gland lobules without adenomatous proliferation (see Salivary Duct Cyst in Chapter 12) (Fig. 13-19).

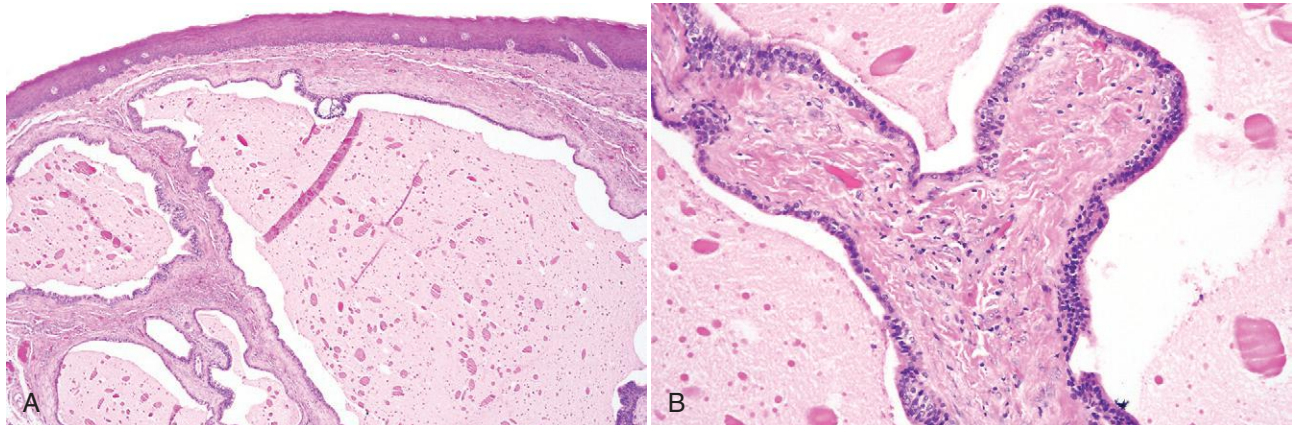
- Low-grade adenocarcinomas are nonencapsulated and infiltrative, although cytology may be bland.

### Management

- Excision or enucleation with clear margins is curative.

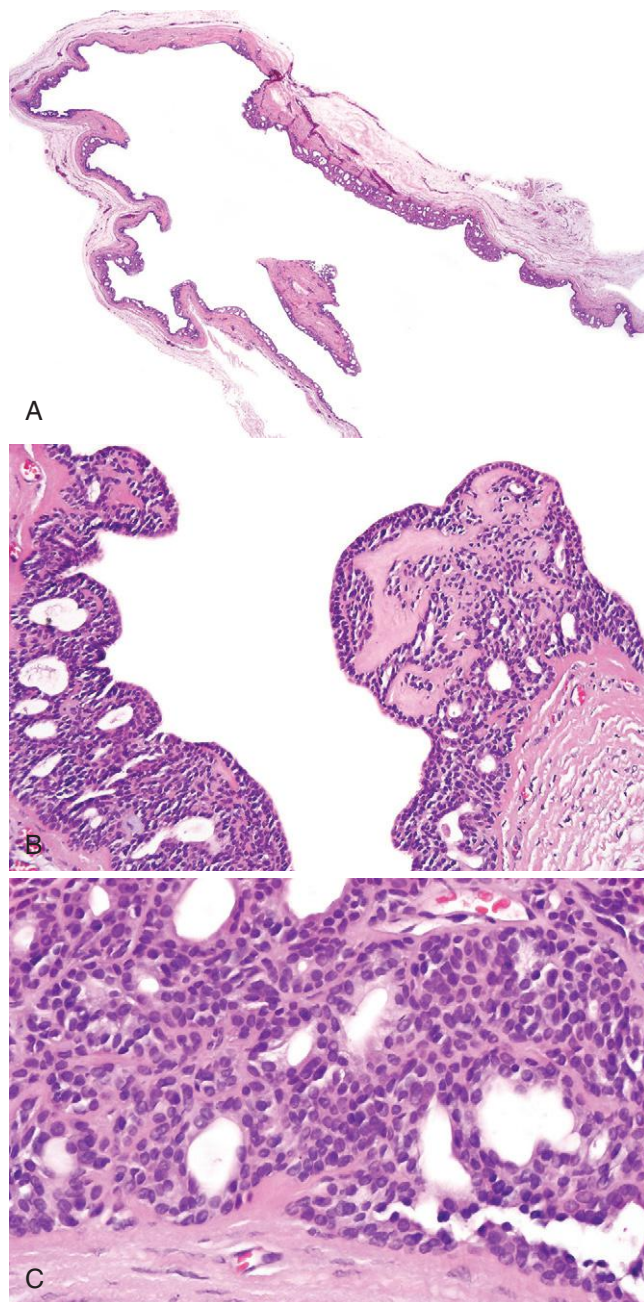
### REFERENCES

- Guccione JG, Redman RS, Calhoun NR, Saini N. Papillary cystadenoma of the palate: a case report and ultrastructural study. *J Oral Maxillofac Surg.* 1997;55:759-764.
- Kusafuka K, Ueno T, Kurihara K, et al. Cystadenoma of the palate: immunohistochemistry of mucins. *Pathol Int.* 2008;58:524-528.
- Lim CS, Ngu I, Collins AP, McKellar GM. Papillary cystadenoma of a minor salivary gland: report of a case involving cytological analysis and review of the literature. *Oral Surg Oral Med Oral Pathol Oral Radiol Endod.* 2008;105:e28-e33.
- Matsuzaka K, Kokubu E, Takeda E, et al. Papillary cystadenoma arising from the upper lip: a case report. *Bull Tokyo Dent Coll.* 2003;44:213-216.



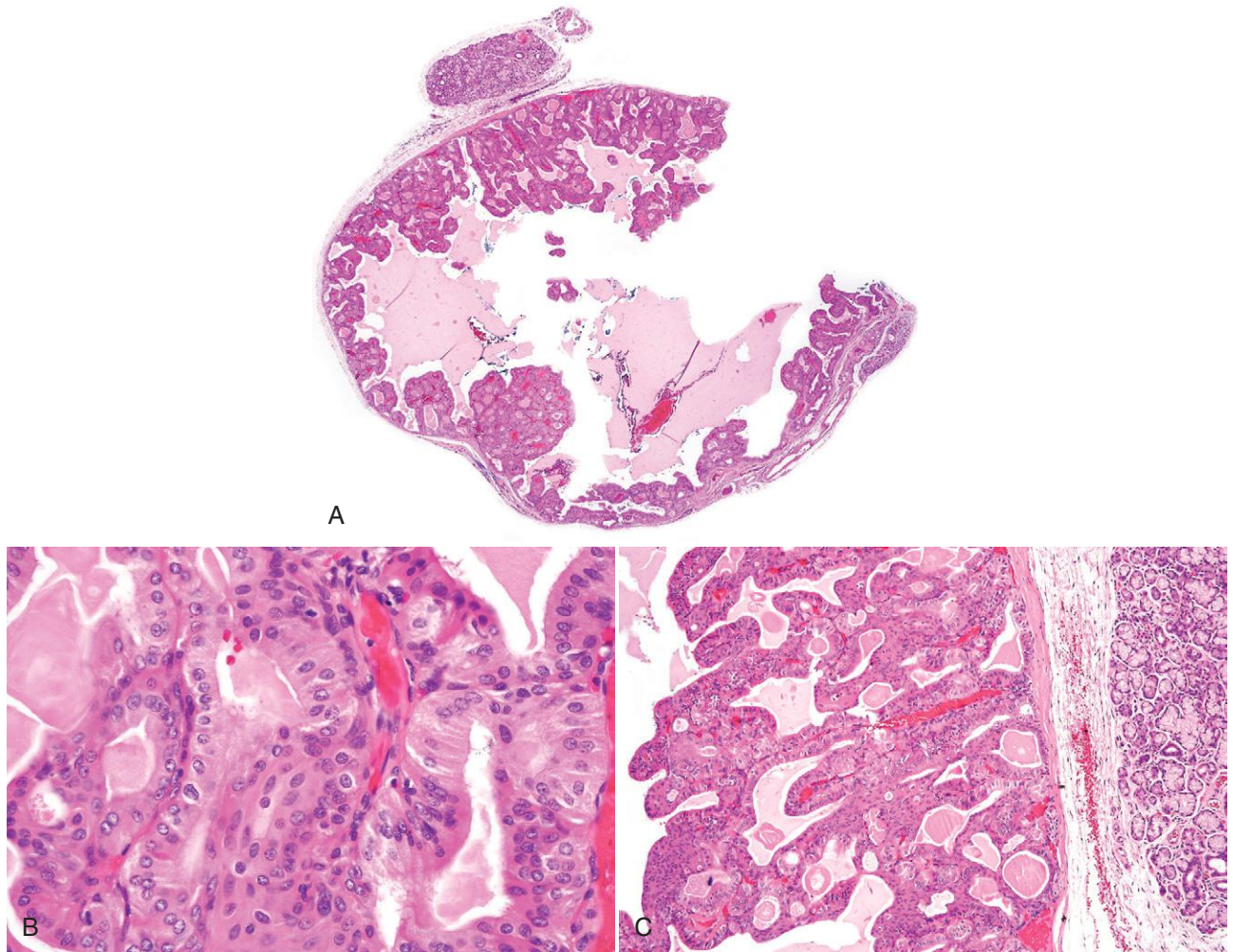
**FIGURE 13-16.** Cystadenoma. **A**, Proliferation of cysts of varying sizes with focal adenomatous plaques. **B**, Cysts lined by a double layer of columnar cells.



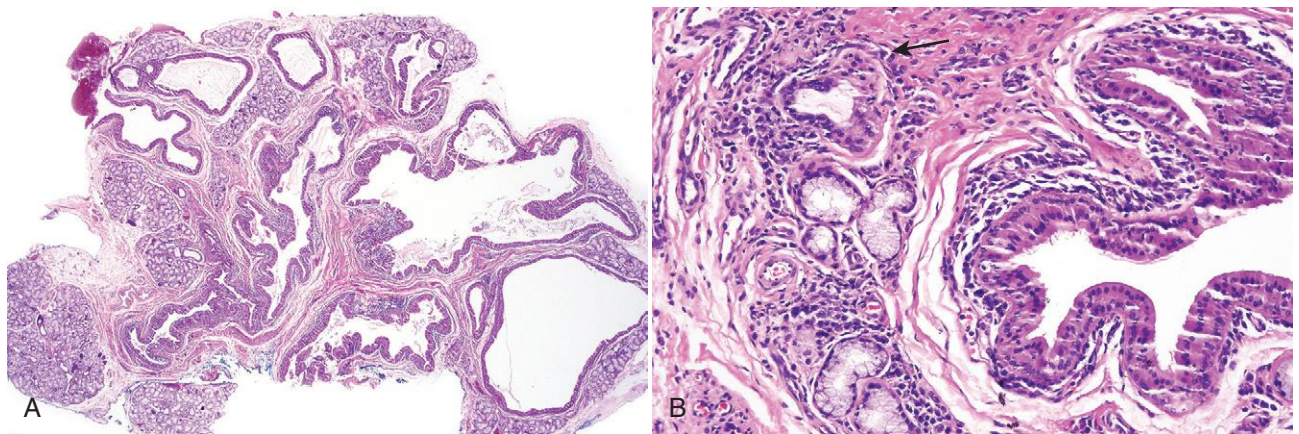


**FIGURE 13-17.** Cystadenoma. **A**, Single large cyst with adenomatous proliferation of lining epithelium in plaques. **B**, Adenomatous proliferation of lining epithelium forming small ducts with hyaline stroma. **C**, Cells have benign cytology.





**FIGURE 13-18.** Papillary oncocytic cystadenoma. **A**, Single large cyst with papillary and adenomatous proliferation of lining. **B**, Papillary proliferation of oncocytes with delicate fibrovascular cores. **C**, Oncocytes in adenomatous configuration with eosinophilic, granular cytoplasm.



**FIGURE 13-19.** Oncocytic sialocytosis. **A**, Salivary gland with dilated ducts within multiple gland lobules. **B**, Dilated ducts lined by a double layer of oncocytes and underlying plasma cells; early changes in adjacent glands (arrow).



## SIALADENOMA PAPILLIFERUM

There are three papillary conditions that involve the salivary gland ducts: sialadenoma papilliferum, ductal papilloma, and inverted papilloma. A possible cell of origin is the excretory duct reserve cell located in the distal portions of the excretory duct.

### Clinical Findings

- Rare lesion; most common location is the hard palate (80%) of middle-aged adults; buccal mucosa is second most common site.
- Lesion has a rough, warty appearance similar to papilloma.

### Etiopathogenesis and Histopathologic Features

This is the salivary gland equivalent of the syringocystadenoma papilliferum of the skin.

- Benign exophytic papillary proliferation of surface squamous epithelium in continuity with deep adenomatous hyperplasia and dilatation of ducts present at the base of the lesion; ducts are lined by two layers of low columnar-to-cuboidal cells with occasional mucous cells; luminal papillations are often present (Fig. 13-20); the degree of adenomatous proliferation varies.
- Ductal cells, as expected, stain for CK13 and CK19, and myoepithelial cells are present around the ducts.

### Differential Diagnosis

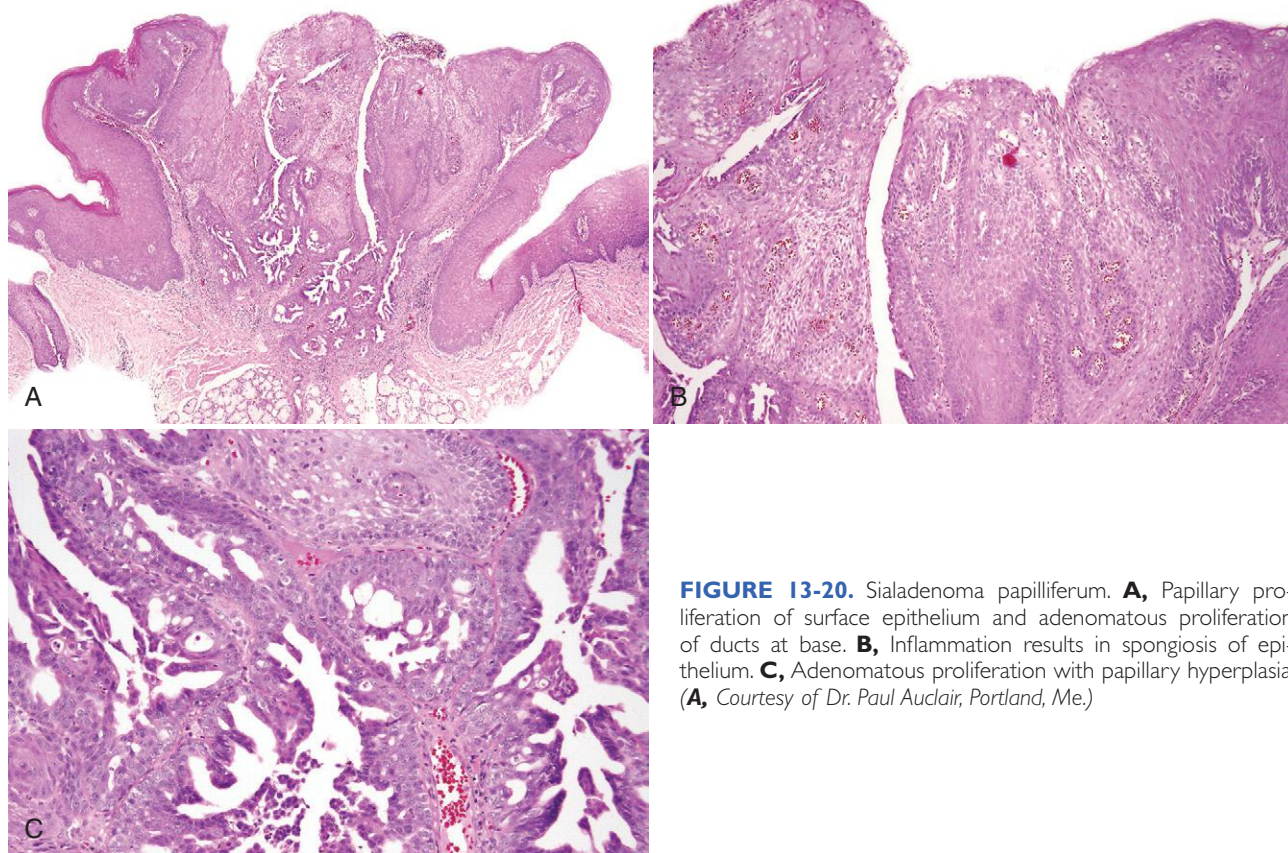
- May be mistaken for squamous papilloma if the biopsy is small and superficial and does not include the deeper adenomatoid hyperplasia.
- Focal adenomatous and papillary hyperplasia may be part of an inflammatory and metaplastic process (Fig. 13-21).
- Occasional lesions have shown development of dysplasia or other salivary gland malignancies, but these must be carefully distinguished from papillary adenocarcinomas that secondarily involve the surface mucosa.

### Management

- Excision is the treatment of choice; lesion does not recur.

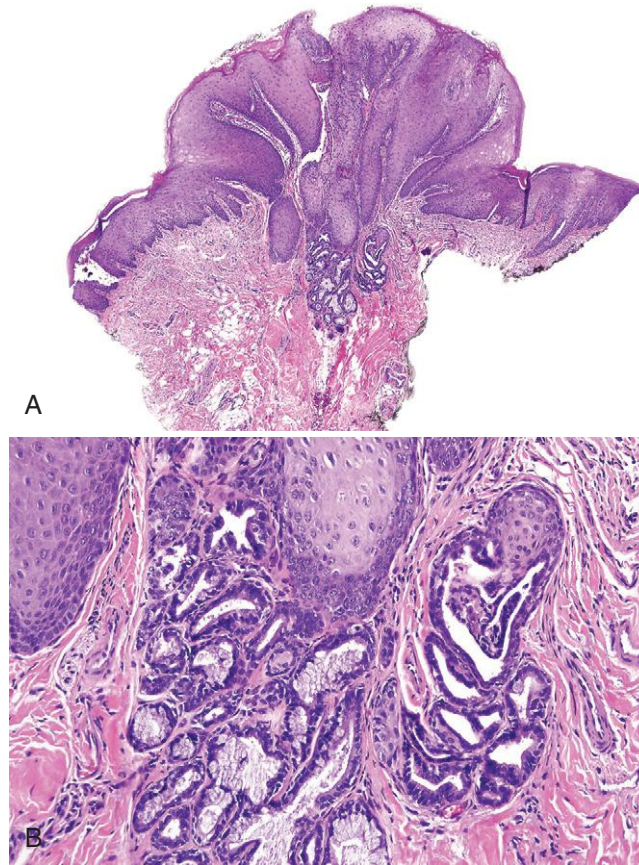
### REFERENCES

- Ide F, Kikuchi K, Kusama K, Kanazawa H. Sialadenoma papilliferum with potentially malignant features. *J Clin Pathol.* 2010;63:362-364.
- Liu W, Gnepp DR, de Vries E, et al. Mucoepidermoid carcinoma arising in a background of sialadenoma papilliferum: a case report. *Head Neck Pathol.* 2009;3:59-62.
- Maiorano E, Favia G, Ricco R. Sialadenoma papilliferum: an immunohistochemical study of five cases. *J Oral Pathol Med.* 1996;25:336-342.
- Ponniiah I. A rare case of sialadenoma papilliferum with epithelial dysplasia and carcinoma in situ. *Oral Surg Oral Med Oral Pathol Oral Radiol Endod.* 2007;104:e27-e29.
- Ubaidat MA, Robinson RA, Belding PJ, Merryman DJ. Sialadenoma papilliferum of the hard palate: report of 2 cases and immunohistochemical evaluation. *Arch Pathol Lab Med.* 2001;125:1595-1597.



**FIGURE 13-20.** Sialadenoma papilliferum. **A**, Papillary proliferation of surface epithelium and adenomatous proliferation of ducts at base. **B**, Inflammation results in spongiosis of epithelium. **C**, Adenomatous proliferation with papillary hyperplasia. (A, Courtesy of Dr. Paul Auclair, Portland, Me.)





**FIGURE 13-21.** Reactive adenomatous hyperplasia. **A**, Exophytic papillary epithelial hyperplasia. **B**, Slight adenomatous proliferation at base.

## INTRADUCTAL PAPILLOMA

### Clinical Findings

- Painless nodules or masses on the lips or buccal mucosa in middle-aged or older adults

### Histopathologic Features

- This lesion arises within a cystically dilated excretory salivary duct; within the lumen is a benign papillary proliferation of cuboidal and columnar cells, squamous cells, and mucous cells with fibrovascular cores; microcysts are often present; the point of origin/attachment to the duct lumen may be evident (Fig. 13-22).

### Differential Diagnosis

- Papillary cystadenoma consists of a proliferation of cysts and ductal structures that exhibit papillary structures (see earlier).

- Inverted ductal papilloma is endophytic and forms bulbous fronds of epithelium that pushes into the connective tissue (see earlier).

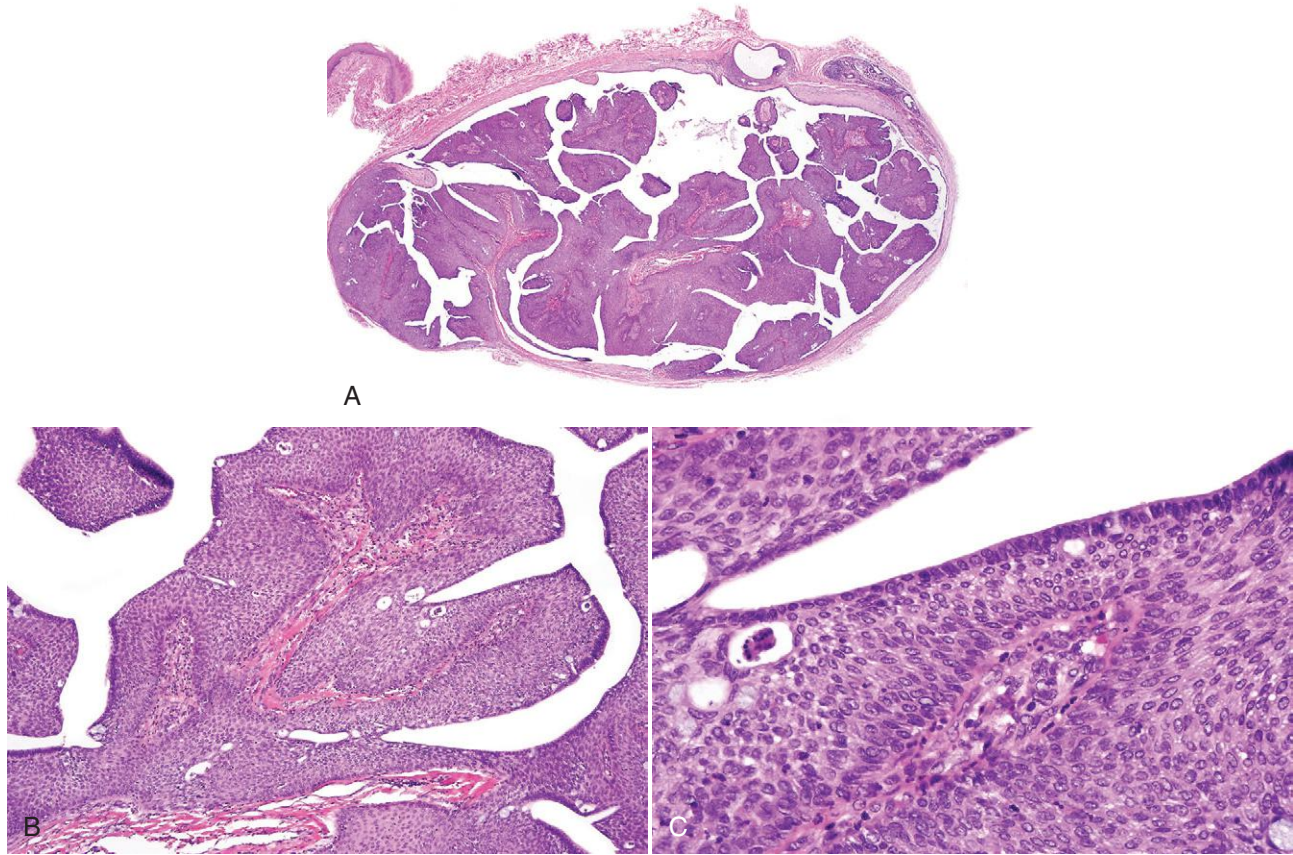
### Management and Prognosis

- Excision is curative.

### REFERENCES

- Brannon RB, Sciubba JJ, Giuliani M. Ductal papillomas of salivary gland origin: a report of 19 cases and a review of the literature. *Oral Surg Oral Med Oral Pathol Oral Radiol Endod.* 2001;92:68-77.
- Chen YK, Chen JY, Hsu HR, et al. Intraoral intraductal papilloma: a case report. *Gerodontology.* 2008;25:258-260.





**FIGURE 13-22.** Intraductal papilloma. **A**, Single, dilated excretory salivary duct with luminal papillary proliferation. **B**, Well-organized papillary structures with fibrovascular cores and microcysts. **C**, Surface luminal cells are cuboidal/columnar, and mucous cells are present.

## INVERTED DUCTAL PAPILLOMA

### Clinical Findings

- Lesion occurs in middle-aged or older adults; nodule is within lip and buccal mucosa in 70% of cases.

### Etiopathogenesis and Histopathologic Features

This lesion is similar to a sinonasal inverted papilloma.

- Unencapsulated, discrete lobular and endophytic proliferation of squamous epithelium arises from an excretory salivary duct; clefts within the lobules represent extensions of the duct, and they are lined by low cuboidal-to-columnar cells; clusters of mucous cells, oncocytes, and microcysts are often seen (Fig. 13-23).
- Lesions are positive for CK14 and CK19; rare cases show the presence of human papillomavirus-6 and -11.

### Differential Diagnosis

- Mucoepidermoid carcinomas may have a predominantly epidermoid component with only a few mucous cells but are infiltrative and often cystic.
- Intraductal papillomas generally have one large cyst with an intraluminal papilloma.

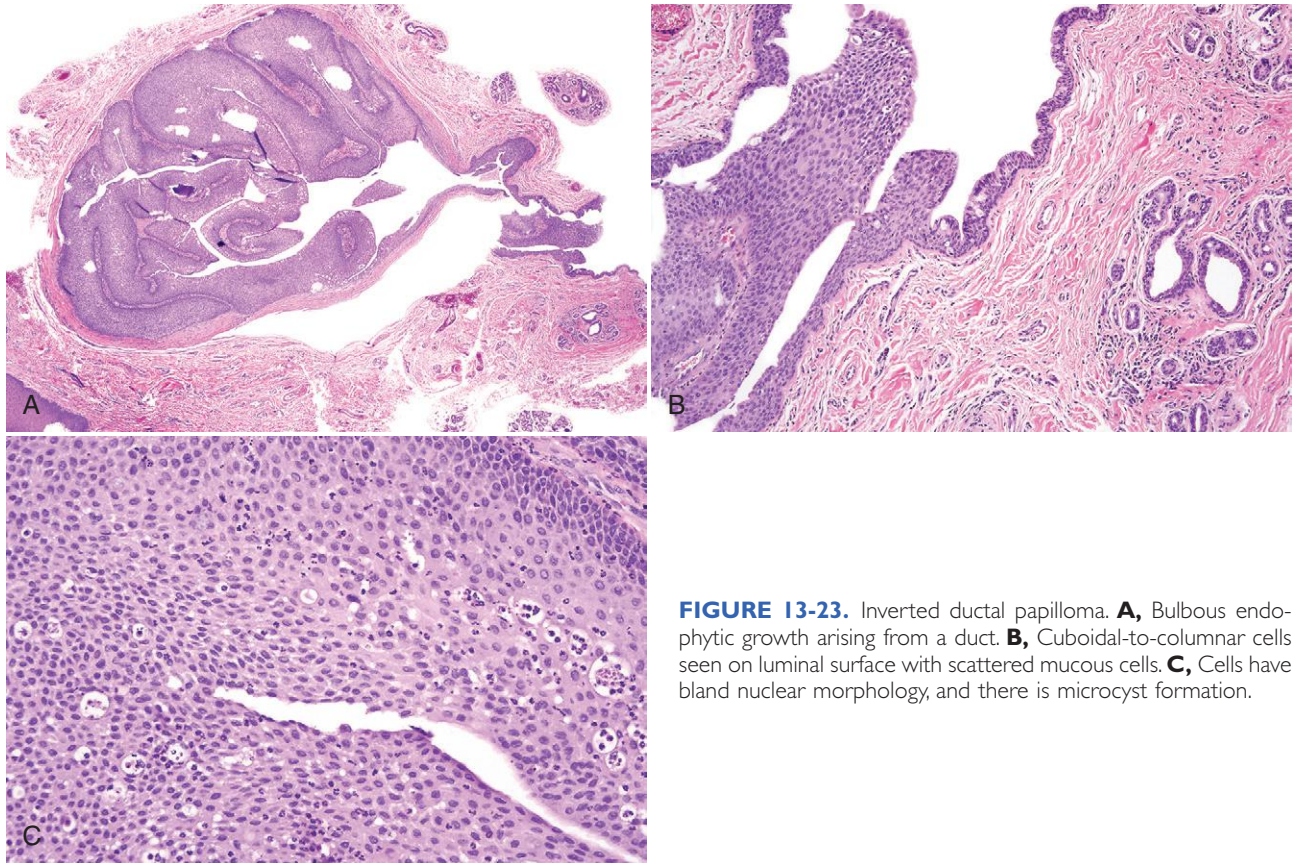
### Management and Prognosis

- Excision is curative; lesion does not tend to recur.

### REFERENCES

- Brannon RB, Sciubba JJ, Giuliani M. Ductal papillomas of salivary gland origin: a report of 19 cases and a review of the literature. *Oral Surg Oral Med Oral Pathol Oral Radiol Endod.* 2001;92:68-77.
- Haberland-Carrodeguas C, Fornatora ML, Reich RF, Freedman PD. Detection of human papillomavirus DNA in oral inverted ductal papillomas. *J Clin Pathol.* 2003;56:910-913.
- Kubota N, Suzuki K, Kawai Y, et al. Inverted ductal papilloma of minor salivary gland: case report with immunohistochemical study and literature review. *Pathol Int.* 2006;56:457-461.





**FIGURE 13-23.** Inverted ductal papilloma. **A**, Bulbous endophytic growth arising from a duct. **B**, Cuboidal-to-columnar cells seen on luminal surface with scattered mucous cells. **C**, Cells have bland nuclear morphology, and there is microcyst formation.

## Malignant Salivary Gland Neoplasms

### Clinical Features

The clinical appearance of malignant salivary gland neoplasms are similar, regardless of the final histologic diagnosis.

- Tumors appear as firm masses, mobile or tethered, ulcerated or cystic (especially mucoepidermoid carcinoma) on hard palate, upper lip, floor of mouth and tongue; usually in middle-aged and older adults, with 2:1 female predilection (Fig. 13-24).

The mucoepidermoid carcinoma is the most common intraoral salivary gland malignancy (also the most common in childhood); others include polymorphous low-grade adenocarcinoma, adenoid cystic carcinoma, acinic cell carcinoma, hyalinizing clear cell carcinoma, and cribriform adenocarcinoma of the tongue.

- Although tumors may show low recurrence and moderate to high survival rates at 5 years, recurrence and metastases often occur many years after the initial diagnosis.

### General Histopathologic Considerations

It is believed that most tumors arise from the intercalated duct reserve cell or its precursor with differentiation toward ductal, myoepithelial, acinar, oncocytic,

clear, and nonspecific glandular cells. The mucoepidermoid carcinoma arises from the excretory duct reserve cell or its precursor.

- Most malignant salivary gland tumors are diagnosed by pattern of growth and morphology; infiltration of the stroma and the adjacent glands and perineural invasion are important features.
- Benign-appearing tumor cells and lack of mitotic activity is the norm for many low-grade salivary gland malignancies.
- Tumor-associated lymphoid proliferation is particularly common in acinic cell carcinoma and mucoepidermoid carcinoma, and it should not be mistaken for metastasis within a lymph node.
- High Ki-67 index may be predictive of poorer survival in some tumors, such as adenoid cystic and acinic cell carcinomas, whereas low expression of c-kit and high expression of epidermal growth factor receptor may also be associated with poorer survival in some tumors.

## MUCOEPIDERMOID CARCINOMA

### Histopathologic Features

- Nonencapsulated proliferation of mucous, epidermoid, columnar, and intermediate cells that invade the stroma; cysts of varying sizes are usually present, and ductal structures are noted (Figs. 13-25, A-C and 13-26, A and B); some low-grade tumors consist of a



**TABLE 13-1** Parameters for Grading Mucoepidermoid Carcinoma

GOODE, ET AL. (AFIP)		BRANDWEIN, ET AL.	
Criteria	Points	Criteria	Points
Intracystic component <20%	2	Intracystic component <25%	2
Neural invasion	2	Perineural spread	3
Necrosis	3	Necrosis	3
≥4 mitoses/10 HPF	3	>4 mitoses/10 HPF	3
Anaplasia	4	Pronounced nuclear atypia	2
		Tumor invasion in small nests and islands	2
		Lymphatic and/or vascular invasions	3
		Bony invasion	3
<b>Grade</b>		<b>Grade</b>	
Low grade	0-4	Low grade	0
Intermediate grade	5-6	Intermediate grade	2-3
High grade	7 or more	High grade	4 or more

Data from Brandwein MS, Ivanov K, Wallace DI, et al. Mucoepidermoid carcinoma: a clinicopathologic study of 80 patients with special reference to histological grading. *Am J Surg Pathol.* 2001;25:835-845; Goode RK, Auclair PL, Ellis GL. Mucoepidermoid carcinoma of the major salivary glands: clinical and histopathologic analysis of 234 cases with evaluation of grading criteria. *Cancer.* 1998;82:1217-1224.  
HPF, High-power field.

single large cyst with tumor plaques in the lining; intermediate cells vary from the small cells with scant cytoplasm and dark nuclei to larger, polygonal cells with pale nuclei and inconspicuous nucleoli (see Fig. 13-25, D); perineural invasion may be present (see Fig. 13-25, E).

- Mucous cells are mucicarmine positive (see Fig. 13-26, C); there is insignificant myoepithelial differentiation.
- Clear cell (glycogen or mucin positive) (Fig. 13-27) and oncocytic variants (usually in the parotid gland) are noted, but small populations of these cells may be present in conventional mucoepidermoid carcinoma.
- Sclerosing mucoepidermoid carcinoma has been reported as a variant with marked sclerosis, stromal eosinophils, and tumor-associated lymphocyte proliferation (Fig. 13-28).
- Grading depends on the presence of cysts, mitotic activity, necrosis, hemorrhage, and perineural invasion and correlates with the prognosis; it is an important prognostic factor (Table 13-1); up to 80% of tumors are low grade; Ki-67 index is not predictive of grade.
- Presence of p53 may predict recurrence.

#### Differential Diagnosis

- Cystadenocarcinomas do not consist of predominantly epidermoid and mucous cells.
- Acinic cell adenocarcinoma has a more uniform appearance, is often papillary, and it contains cells with zymogen granules (periodic acid–Schiff [PAS] stain positive and diastase resistant).

#### Management and Prognosis

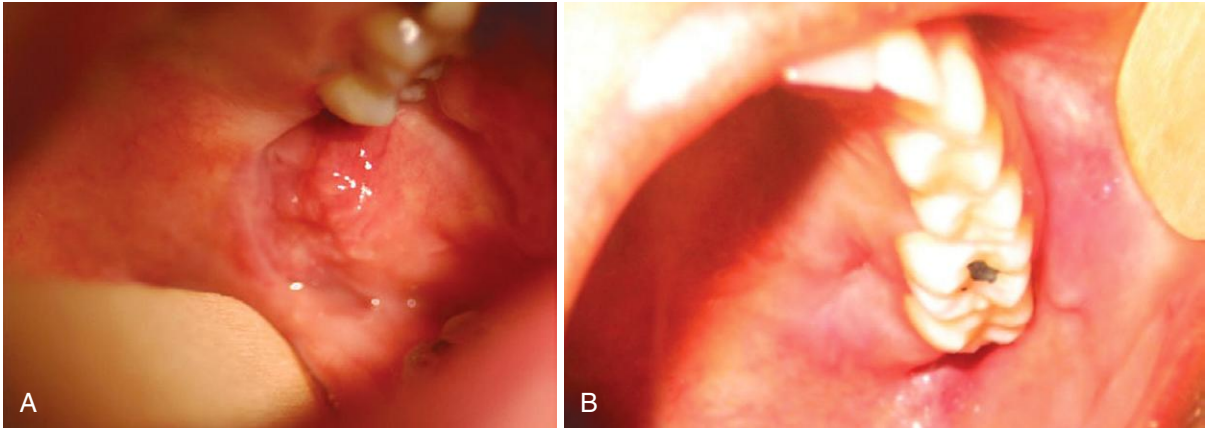
- Excision with clear margins is the treatment of choice; radiotherapy may help to improve local control in selected cases.

- Two histologic grading systems are currently in use with slight variation in criteria (see Table 13-1); 3% and 80% of intraoral low-grade and high-grade tumors, respectively, metastasize or lead to death of the patient.

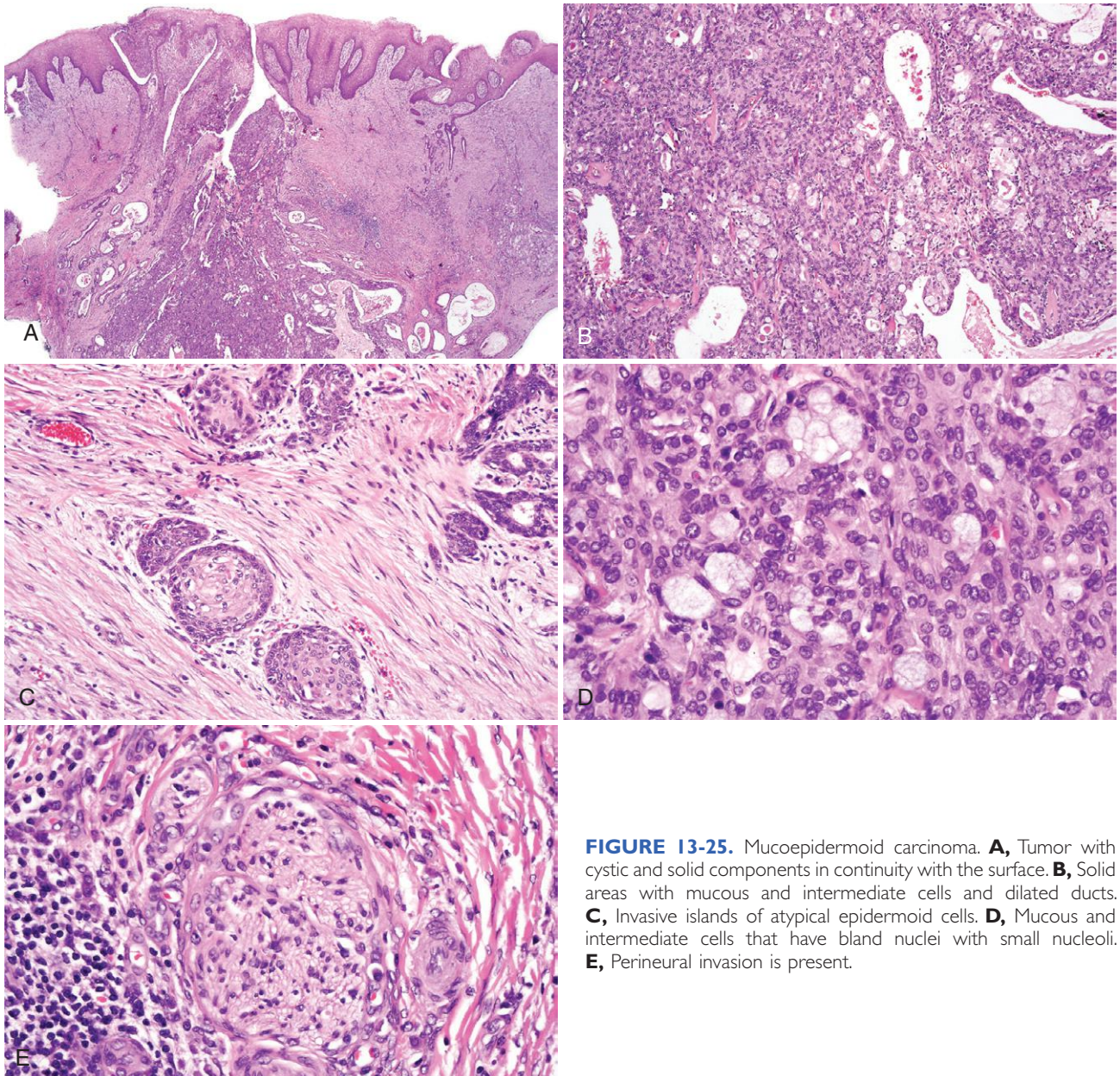
#### REFERENCES

- Abd Elhamid IS, Elmalahy MH. Image cytometric analysis of p53 and mdm-2 expression in primary and recurrent mucoepidermoid carcinoma of parotid gland: immunohistochemical study. *Diagn Pathol.* 2010;5:72.
- Aguiar MC, Bernardes VF, Cardoso SV, et al. A rare case of sclerosing mucoepidermoid carcinoma arising in minor salivary glands with immunohistochemical evaluation. *Minerva Stomatol.* 2008;57:453-457.
- Auclair PL. Tumor-associated lymphoid proliferation in the parotid gland. A potential diagnostic pitfall. *Oral Surg Oral Med Oral Pathol.* 1994;77:19-26.
- Brandwein MS, Ivanov K, Wallace DI, et al. Mucoepidermoid carcinoma: a clinicopathologic study of 80 patients with special reference to histological grading. *Am J Surg Pathol.* 2001;25:835-845.
- Brannon RB, Willard CC. Oncocytic mucoepidermoid carcinoma of parotid gland origin. *Oral Surg Oral Med Oral Pathol Oral Radiol Endod.* 2003;96:727-733.
- Buchner A, Merrell PW, Carpenter WM. Relative frequency of intraoral minor salivary gland tumors: a study of 380 cases from northern California and comparison to reports from other parts of the world. *J Oral Pathol Med.* 2007;36:207-214.
- Cheuk W, Chan JK. Advances in salivary gland pathology. *Histopathology.* 2007;51:1-20.
- Ellis GL, Auclair PL. *Tumors of the Salivary Glands.* Washington, D.C.: American Registry of Pathology; 2008.
- Ettl T, Schwarz S, Kleinsasser N, et al. Overexpression of EGFR and absence of C-KIT expression correlate with poor prognosis in salivary gland carcinomas. *Histopathology.* 2008;53:567-577.
- Goode RK, Auclair PL, Ellis GL. Mucoepidermoid carcinoma of the major salivary glands: clinical and histopathologic analysis of 234 cases with evaluation of grading criteria. *Cancer.* 1998;82:1217-1224.
- Luukka H, Klemi P, Leivo I, et al. Prognostic significance of Ki-67 and p53 as tumor markers in salivary gland malignancies in Finland: an evaluation of 212 cases. *Acta Oncol.* 2006;45:669-675.
- Veras EF, Sturgis E, Luna MA. Sclerosing mucoepidermoid carcinoma of the salivary glands. *Ann Diagn Pathol.* 2007;11:407-412.



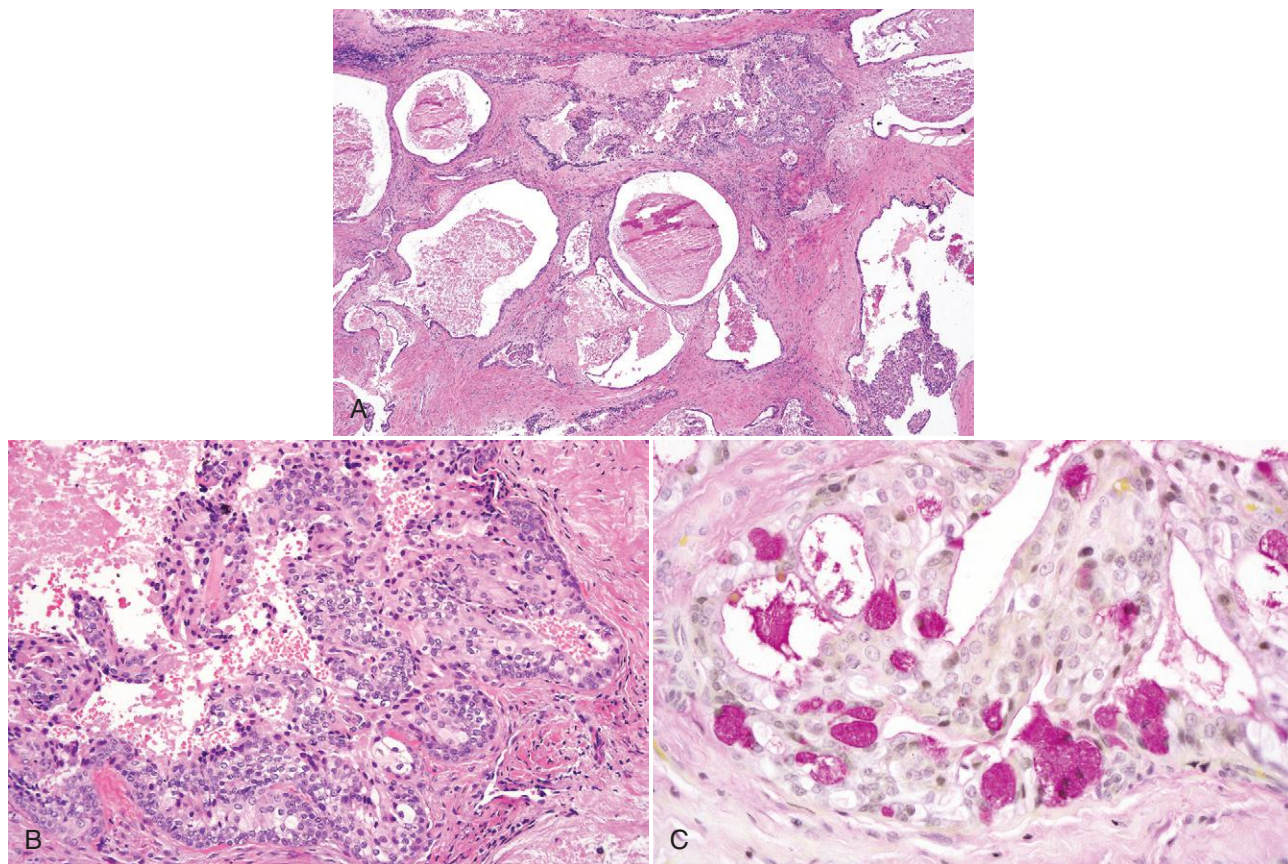


**FIGURE 13-24.** **A**, Mucoepidermoid carcinoma of buccal mucosa with ulceration. **B**, Polymorphous low-grade adenocarcinoma of the palate. (**A**, Courtesy of Dr. John Sexton, private practice, Wellesley, Mass; **B**, Courtesy of Dr. Thomas Dodson, Harvard Medical School, Boston, Mass.)

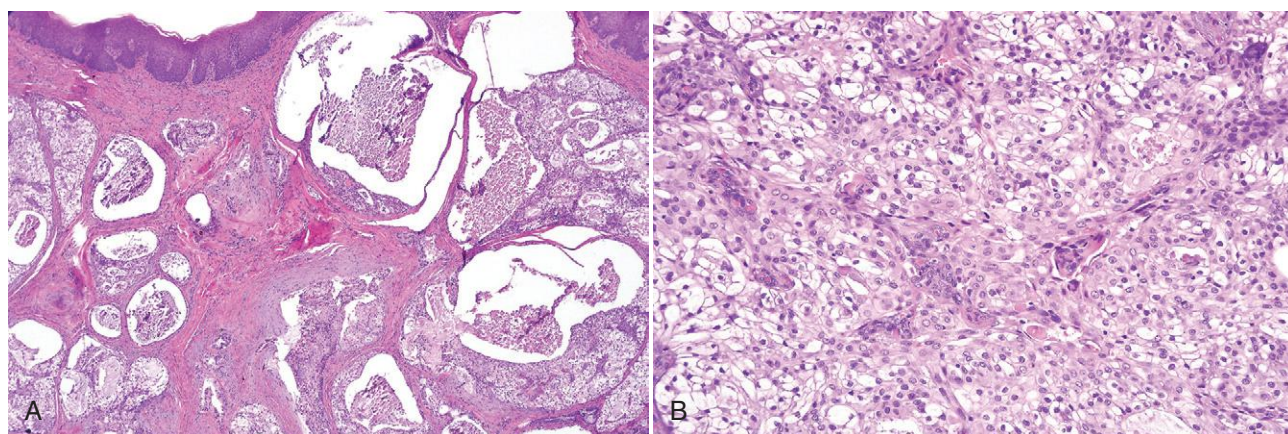


**FIGURE 13-25.** Mucoepidermoid carcinoma. **A**, Tumor with cystic and solid components in continuity with the surface. **B**, Solid areas with mucous and intermediate cells and dilated ducts. **C**, Invasive islands of atypical epidermoid cells. **D**, Mucous and intermediate cells that have bland nuclei with small nucleoli. **E**, Perineural invasion is present.



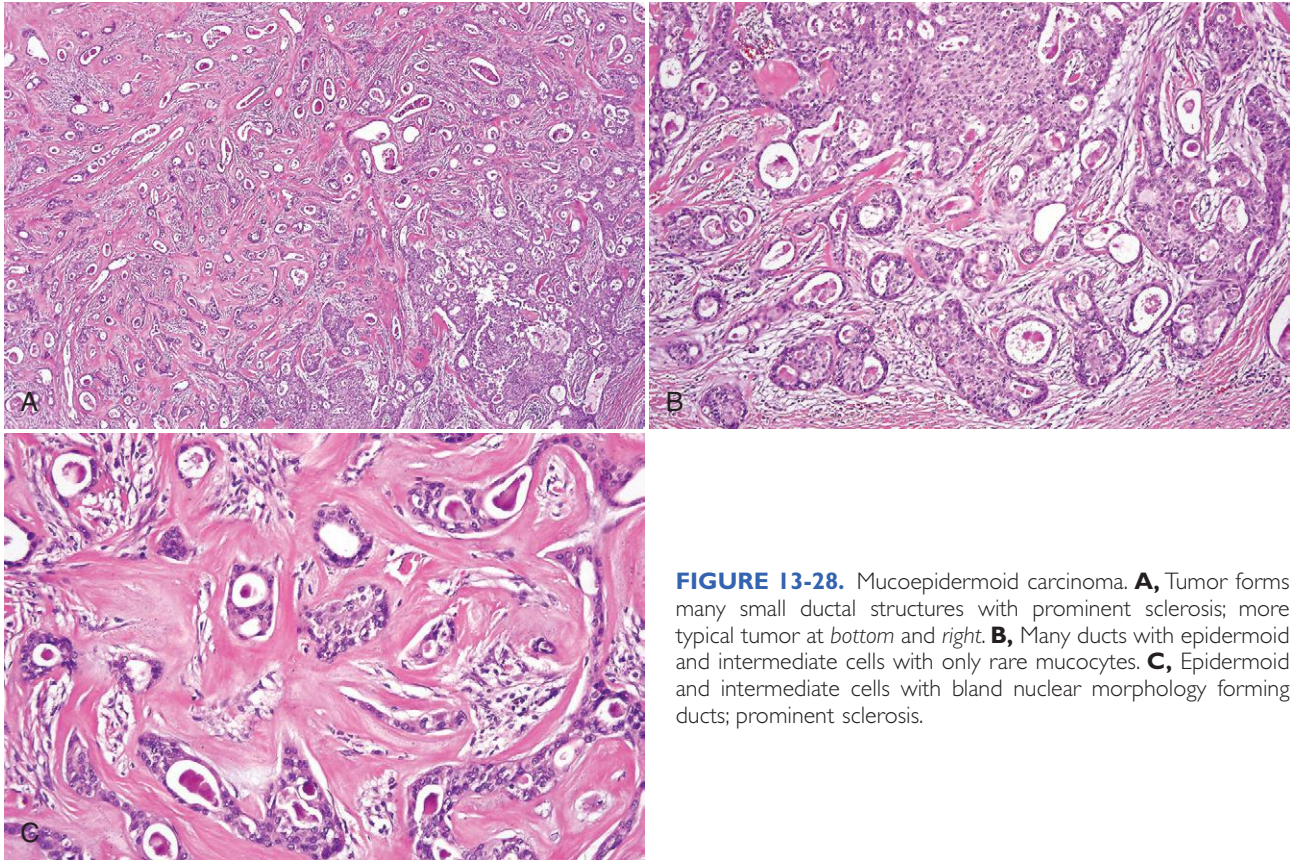


**FIGURE 13-26.** Mucoepidermoid carcinoma. **A**, Tumor forms many large cysts. **B**, Proliferation of mucous, epidermoid, and intermediate cells within cyst lining with stromal invasion. **C**, Mucicarmine stain reveals many mucous cells.



**FIGURE 13-27.** Mucoepidermoid carcinoma. **A**, Tumor with solid and cystic areas. **B**, Intermediate, epidermoid, and clear cells with only rare mucocytes.





**FIGURE 13-28.** Mucoepidermoid carcinoma. **A**, Tumor forms many small ductal structures with prominent sclerosis; more typical tumor at *bottom and right*. **B**, Many ducts with epidermoid and intermediate cells with only rare mucocytes. **C**, Epidermoid and intermediate cells with bland nuclear morphology forming ducts; prominent sclerosis.

## ADENOID CYSTIC CARCINOMA

### Histopathologic Features

- Cribriform (classic “Swiss cheese”) pattern: there are lobules and islands of tumor cells with multiple small pseudoducts or true ducts; pseudoducts contain glycosaminoglycans or basement membrane material and are surrounded by myoepithelial cells (Figs. 13-29, A-E, and 13-30, A-C); true ducts are composed of low cuboidal cells with eosinophilic cytoplasm, round nuclei, and indistinct nucleoli and are surrounded by myoepithelial cells; the latter have hyperchromatic, angulated nuclei and coarse chromatin, small nucleoli, and clear cytoplasm (primarily in the cribriform pattern).
- Tubular pattern: true ducts surrounded by myoepithelial cells; most tumors have a combination of cribriform and tubular patterns (Fig. 13-31).
- Solid pattern: cells are basaloid with less angulated nuclei, small nucleoli, and more mitotic activity; perineural invasion is present in one third of cases (see Fig. 13-30, D); tumors with >30% solid component have higher Ki-67 index, higher rate of recurrence, and poorer 5-year survival, and they should be reported as such.
- C-kit and p63 are consistently and strongly positive in the luminal and abluminal myoepithelial cells, respectively (see Fig. 13-29, F and G); CD43 is positive in 50% to 100% of cases and may be useful in diagnosis

of some problematic cases; lack of c-kit and high Ki-67 index may adversely affect survival.

- Dedifferentiation leads to foci of tumor cells with high-grade morphology and this occurrence is more common in the major glands.

### Differential Diagnosis

- Polymorphous low-grade adenocarcinoma has multiple patterns of growth and bland cytology; the cells do not usually stain significantly for myoepithelial markers, and they are only weakly positive for c-kit (see later).
- Epimyoeplithelial carcinoma is rare in the minor glands and the biphasic pattern of ductal cells with surrounding myoepithelial cells is fairly consistent throughout the tumor.

### Management and Prognosis

- Wide excision with clear margins is the treatment of choice.
- Overall 5-year and 15-year survival is 60% to 80% and 25% to 40%, respectively; tumors generally exhibit persistence and recurrence with late-onset metastases to the lungs, lymph nodes, and bones; tumors with greater than 30% solid component have a poorer prognosis; 10-year survival for p53-positive and -negative tumors is 8% and 34%, respectively; for c-kit, it is 12% and 34%, respectively.

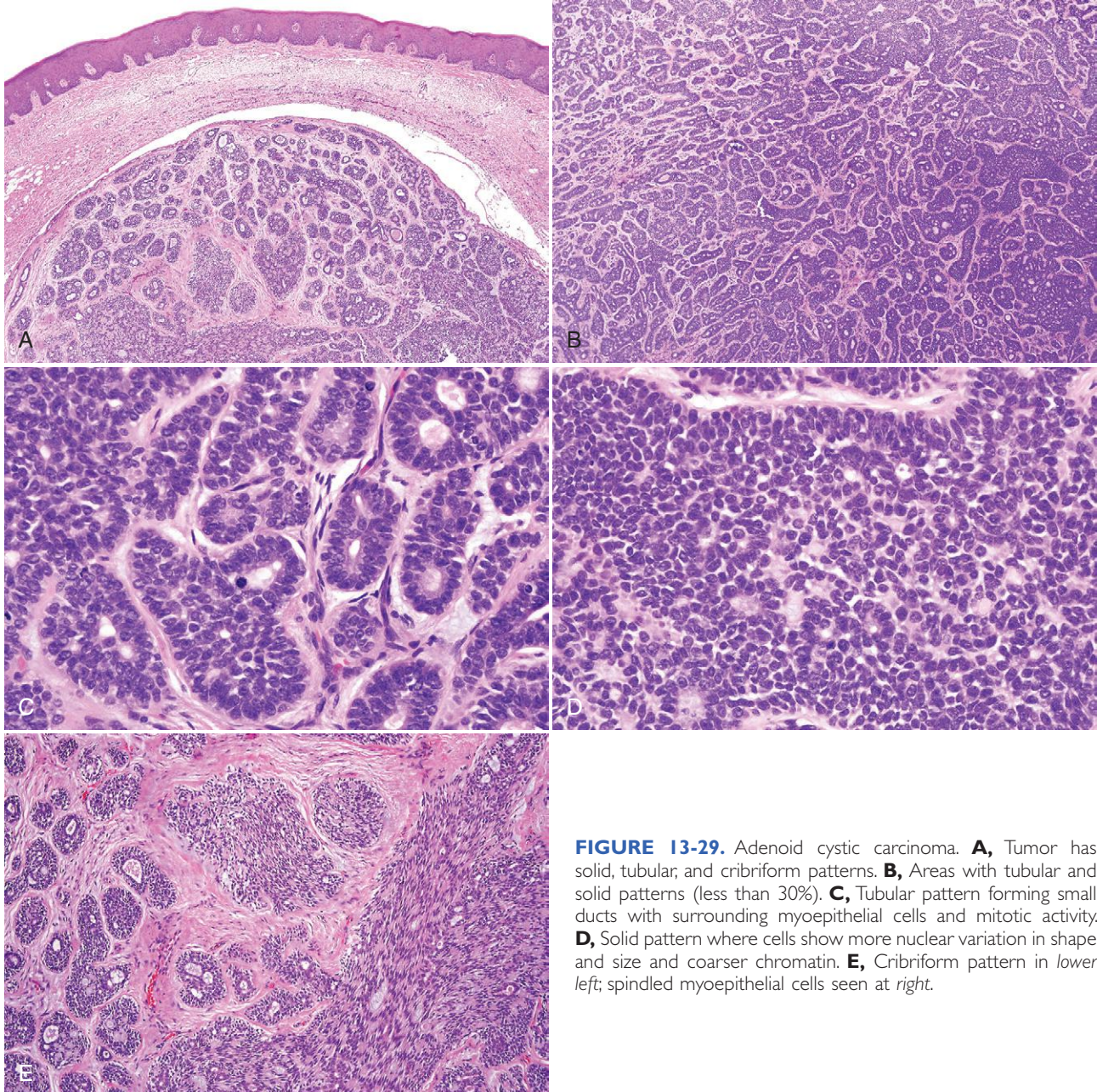


- Perineural invasion, oropharyngeal site (versus oral site), and high tumor stage adversely affect local recurrence rate and disease-free survival.

#### REFERENCES

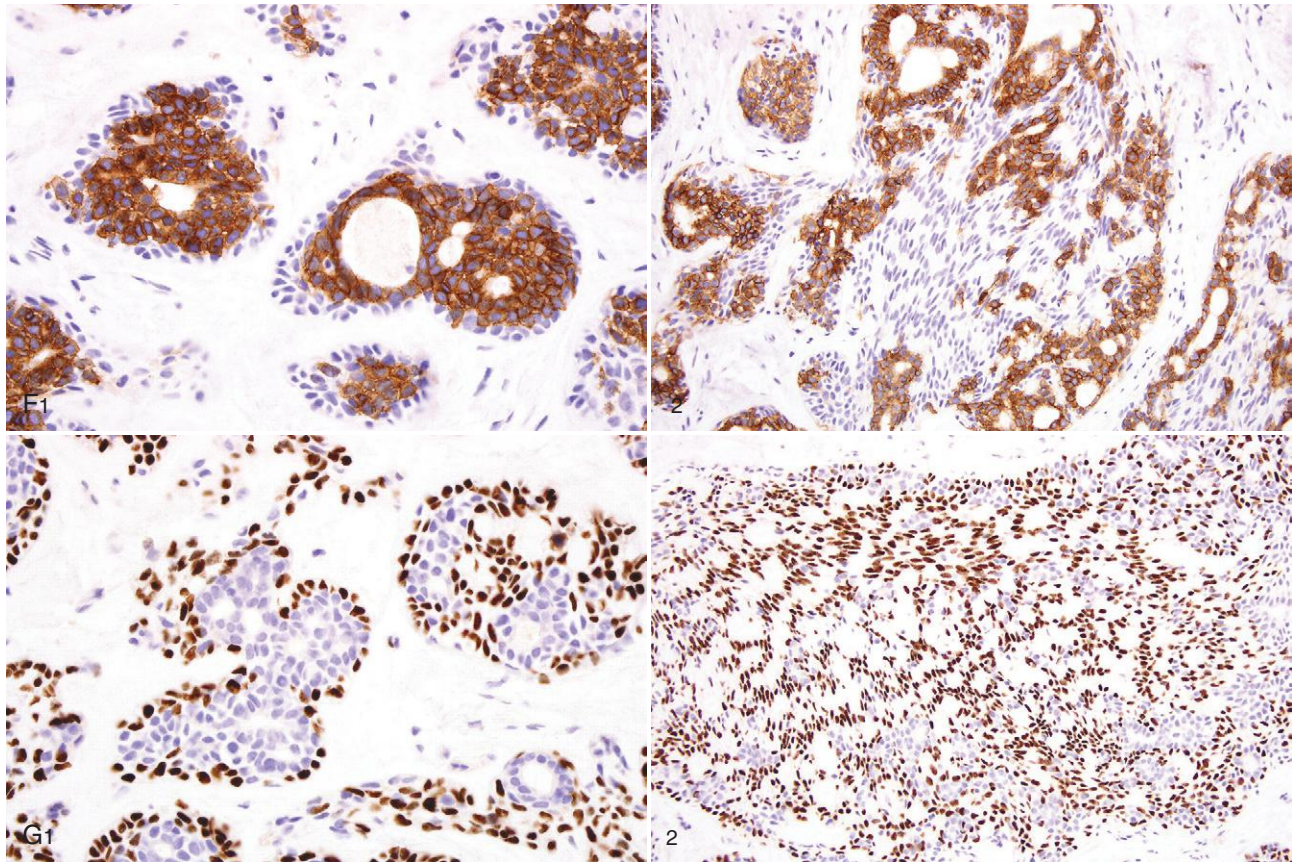
- Agarwal JP, Jain S, Gupta T, et al. Intraoral adenoid cystic carcinoma: prognostic factors and outcome. *Oral Oncol.* 2008;44:986-993.
- Edwards PC, Bhuiya T, Kelsch RD. C-kit expression in the salivary gland neoplasms adenoid cystic carcinoma, polymorphous low-grade adenocarcinoma, and monomorphic adenoma. *Oral Surg Oral Med Oral Pathol Oral Radiol Endod.* 2003;95:586-593.
- Ettl T, Schwarz S, Kleinsasser N, et al. Overexpression of EGFR and absence of C-KIT expression correlate with poor prognosis in salivary gland carcinomas. *Histopathology.* 2008;53:567-577.
- Greiner TC, Robinson RA, Maves MD. Adenoid cystic carcinoma. A clinicopathologic study with flow cytometric analysis. *Am J Clin Pathol.* 1989;92:711-720.
- Kokemueller H, Eckardt A, Brachvogel P, Hausamen JE. Adenoid cystic carcinoma of the head and neck—a 20 years experience. *Int J Oral Maxillofac Surg.* 2004;33:25-31.

- Luukka H, Klemi P, Leivo I, et al. Prognostic significance of Ki-67 and p53 as tumor markers in salivary gland malignancies in Finland: an evaluation of 212 cases. *Acta Oncol.* 2006;45:669-675.
- Mino M, Pilch BZ, Faquin WC. Expression of KIT (CD117) in neoplasms of the head and neck: an ancillary marker for adenoid cystic carcinoma. *Mod Pathol.* 2003;16:1224-1231.
- Prasad AR, Saveria AT, Gown AM, Zarbo RJ. The myoepithelial immunophenotype in 135 benign and malignant salivary gland tumors other than pleomorphic adenoma. *Arch Pathol Lab Med.* 1999;123:801-806.
- Seethala RR. An update on grading of salivary gland carcinomas. *Head Neck Pathol.* 2009;3:69-77.
- Seethala RR, Pasha TL, Raghunath PN, et al. The selective expression of CD43 in adenoid cystic carcinoma. *Appl Immunohistochem Mol Morphol.* 2008;16:165-172.
- Woo VL, Bhuiya T, Kelsch R. Assessment of CD43 expression in adenoid cystic carcinomas, polymorphous low-grade adenocarcinomas, and monomorphic adenomas. *Oral Surg Oral Med Oral Pathol Oral Radiol Endod.* 2006;102:495-500.



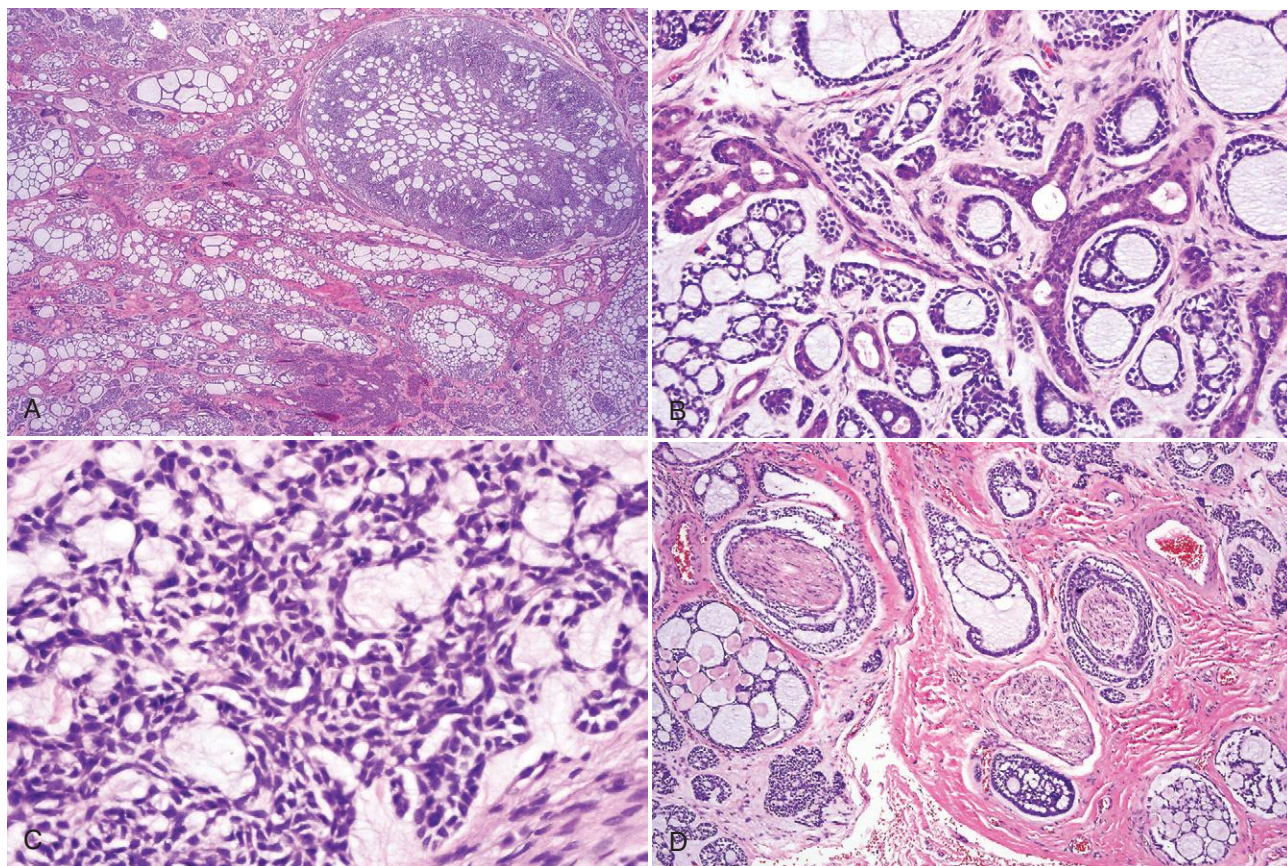
**FIGURE 13-29.** Adenoid cystic carcinoma. **A**, Tumor has solid, tubular, and cribriform patterns. **B**, Areas with tubular and solid patterns (less than 30%). **C**, Tubular pattern forming small ducts with surrounding myoepithelial cells and mitotic activity. **D**, Solid pattern where cells show more nuclear variation in shape and size and coarser chromatin. **E**, Cribriform pattern in lower left; spindle-shaped myoepithelial cells seen at right.





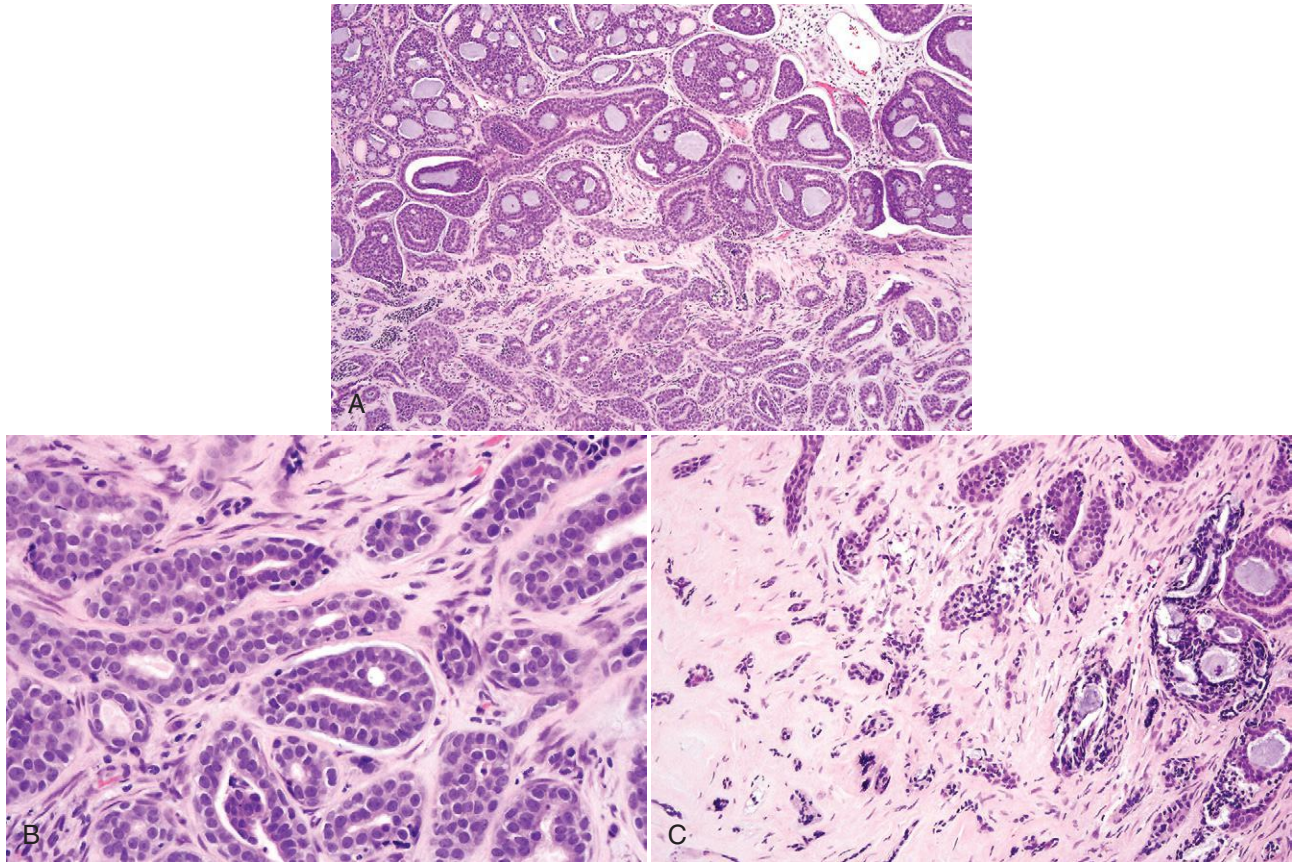
**FIGURE 13-29, cont'd.** **F**, Ductal cells are c-kit positive. **G**, Myoepithelial cells (including spindle cells) are p63 positive.





**FIGURE 13-30.** Adenoid cystic carcinoma. **A**, Prominent cribriform pattern with focal solid component (*bottom center*). **B**, Cribriform pattern has true ducts lined by eosinophilic cuboidal cells and pseudoducts surrounded by myoepithelial cells enclosing mucinous ground substance. **C**, Myoepithelial cells with angulated, hyperchromatic nuclei surround pseudoducts. **D**, Perineural invasion; hyalinized eosinophilic basement membrane-like material within pseudocysts.





**FIGURE 13-31.** Adenoid cystic carcinoma. **A**, Adenoid cystic carcinoma with cribriform (*top*) and tubular (*bottom*) patterns. **B**, Tubular area with ducts surrounded by myoepithelial cells. **C**, Small invasive tumor islands with surrounding sclerosis.

## POLYMORPHOUS LOW-GRADE ADENOCARCINOMA

This tumor represents 10% to 15% of all intraoral salivary gland neoplasms and 20% to 25% of malignant tumors.

### Histopathologic Features

- Infiltrative tumor is polymorphic in architecture, forming solid sheets, ducts, trabeculae, cribriform structures, and small islands and strands of cells; linear cords of cells in single array are often seen at the periphery of the tumor and near the mucosal surface; thin strands and cords of cells often have a swirling or target-like pattern; stroma is often myxochondroid (Figs. 13-32, *A* and *B*, 13-33, *A-C*, 13-34, *A-C*).
- Cells are isomorphic with indistinct cytoplasmic outlines, pale cytoplasm, ovoid-to-round nuclei with fine, dispersed chromatin, small nucleoli, and generally few-to-no mitoses (see Figs. 13-32, *C*, 13-33, *D*, and 13-34, *D*); stroma is variably hyalinized and myxoid; perineural invasion is common (50% to 75% of cases) but has little prognostic significance (see Figs. 13-33, *E*, and 13-34, *E*); invasion of bone is present in 25% of cases.

- Focal nests of oncocytes, clear cells, mucous cells and crystalloid bodies similar to pleomorphic adenoma may be seen; cells are weakly reactive for c-kit.

### Differential Diagnosis

- Pleomorphic adenoma and myoepithelioma may show capsular infiltration but no perineural invasion; presence of plasmacytoid myoepithelial cells, cartilage, and fat and bone support a diagnosis of pleomorphic adenoma.
- Adenoid cystic carcinoma cells have hyperchromatic, large nuclei with irregular outlines; pattern is more predictably cribriform, tubular, and solid and studies for c-kit are consistently and strongly positive within ductal cells.
- Tumors with a predominantly papillary growth pattern are more likely to be papillary adenocarcinomas.
- Cribriform adenocarcinoma (of minor salivary glands) is likely a separate entity, rather than a variant of polymorphous low-grade carcinoma, and tends to involve the tongue although not exclusively; lobular epithelial proliferation is in a cribriform, solid, and microcystic pattern with differentiation toward small, single-cell population showing myoepithelial differentiation; the tumor does not demonstrate



single filing or strands of cells seen in polymorphous low-grade adenocarcinoma; cells are isomorphic, and nuclei tend to be clear and overlap similar to papillary thyroid carcinoma; most tumors have already metastasized to cervical nodes when first diagnosed (Fig. 13-35); cells are positive for basal and myoepithelial cell markers (such as S-100 protein, vimentin, calponin, and p63), CK7, c-kit, and p16 and negative for thyroid transcription factor 1 (TTF-1) and EMA.

### Management and Prognosis

- Complete surgical excision is the treatment of choice; adjuvant radiation therapy is used in selected cases.
- Recurrence occurs in 9% to 30% of cases, often more than 5 years from diagnosis; metastases occur in up to 9% of cases; death from this tumor is rare.

### REFERENCES

Castle JT, Thompson LD, Frommelt RA, et al. Polymorphous low grade adenocarcinoma: a clinicopathologic study of 164 cases. *Cancer*. 1999;86:207-219.

Evans HL, Luna MA. Polymorphous low-grade adenocarcinoma: a study of 40 cases with long-term follow up and an evaluation of the importance of papillary areas. *Am J Surg Pathol*. 2000;24:1319-1328.

Hunter JB, Smith RV, Brandwein-Gensler M. Low-grade papillary adenocarcinoma of the palate: the significance of distinguishing it from polymorphous low-grade adenocarcinoma. *Head Neck Pathol*. 2008;2:316-323.

Michal M, Skalova A, Simpson RH, et al. Cribriform adenocarcinoma of the tongue: a hitherto unrecognized type of adenocarcinoma characteristically occurring in the tongue. *Histopathology*. 1999;35:495-501.

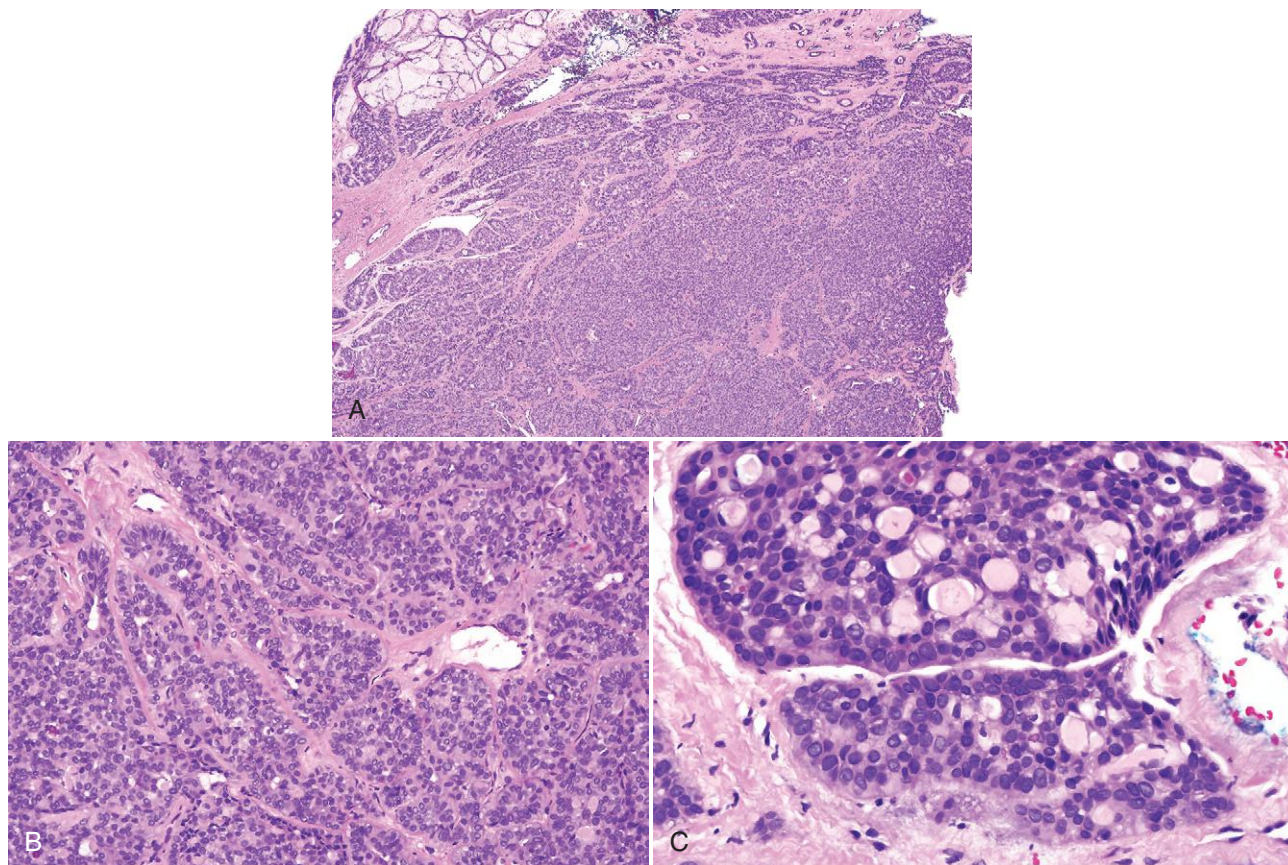
Penner CR, Folpe AL, Budnick SD. C-kit expression distinguishes salivary gland adenoid cystic carcinoma from polymorphous low-grade adenocarcinoma. *Mod Pathol*. 2002;15:687-691.

Perez-Ordóñez B, Linkov I, Huvos AG. Polymorphous low-grade adenocarcinoma of minor salivary glands: a study of 17 cases with emphasis on cell differentiation. *Histopathology*. 1998;32:521-529.

Seethala RR, Johnson JT, Barnes EL, Myers EN. Polymorphous low-grade adenocarcinoma: the University of Pittsburgh experience. *Arch Otolaryngol Head Neck Surg*. 2010;136:385-392.

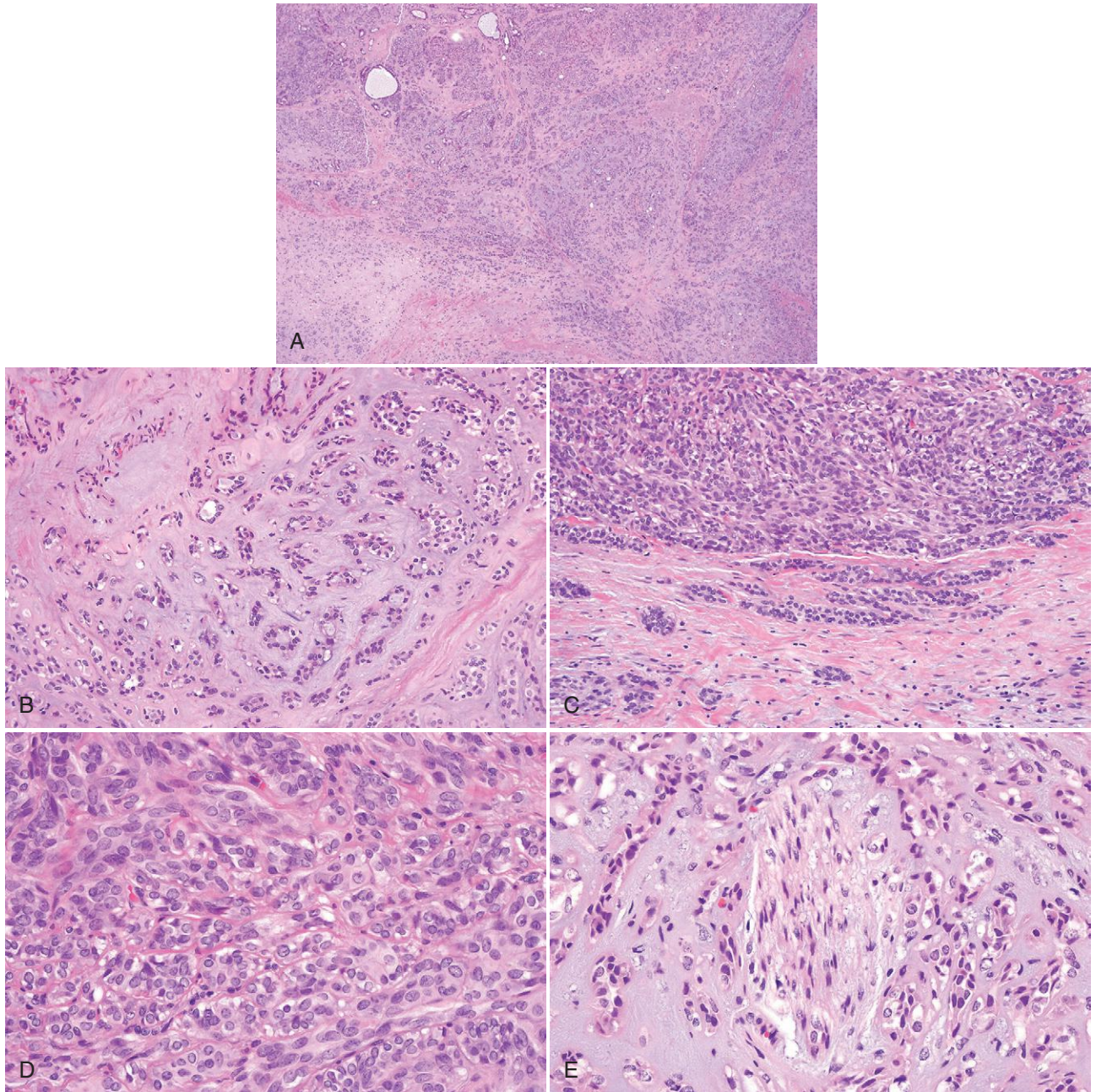
Skalova A, Sima R, Kaspirkova-Nemcova J Mgr, et al. Cribriform carcinoma of minor salivary gland origin principally affecting the tongue: characterization of new entity. *Am J Surg Pathol*. 2011;35:1168-1176.

Vincent SD, Hammond HL, Finkelstein MW. Clinical and therapeutic features of polymorphous low-grade adenocarcinoma. *Oral Surg Oral Med Oral Pathol*. 1994;77:41-47.



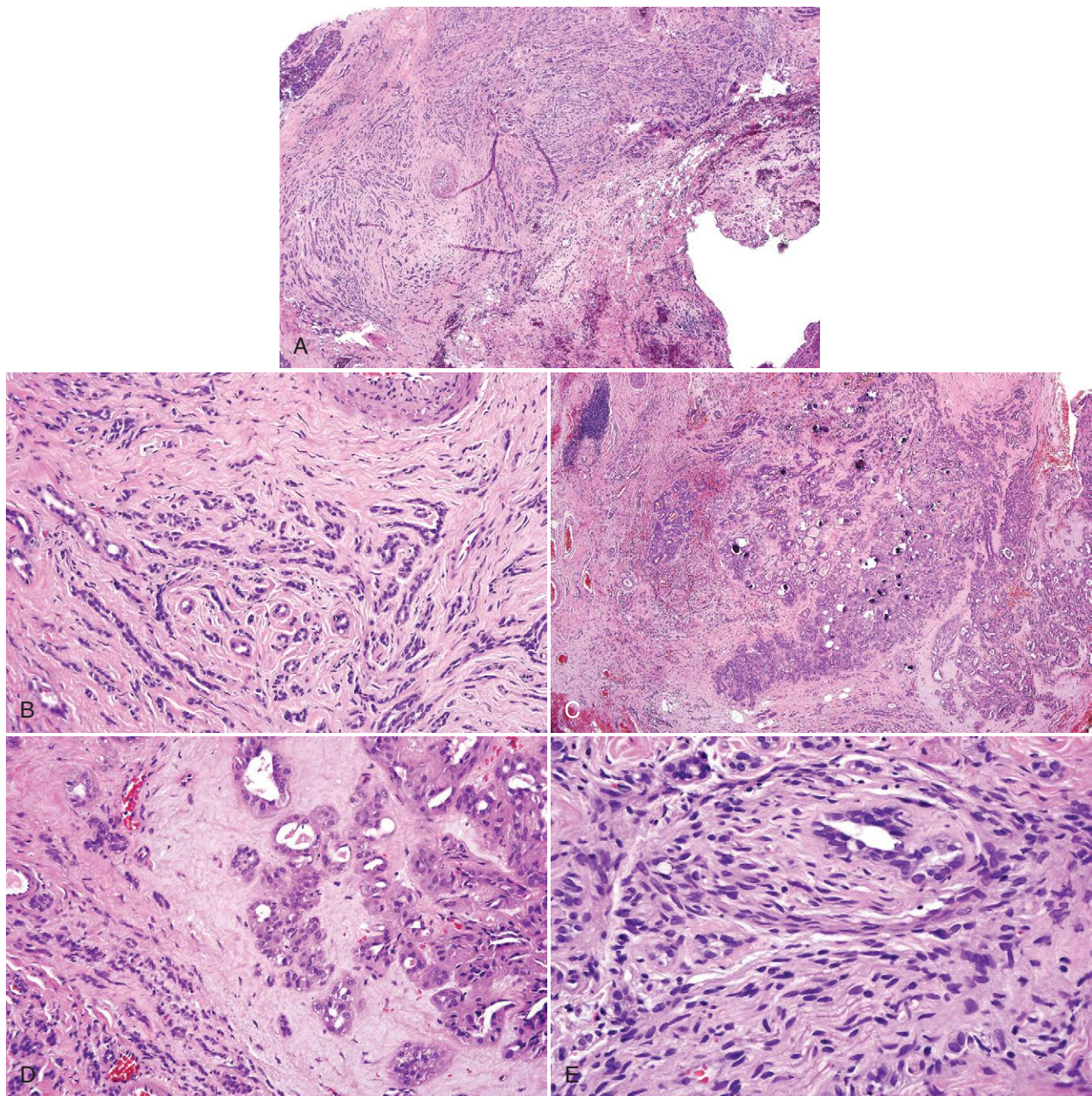
**FIGURE 13-32.** Polymorphous low-grade adenocarcinoma. **A**, Sheets, ducts, and cords of cells at the periphery and infiltration of adjacent glands. **B**, Ductal structures and nests and sheets of pale tumor cells with bland nuclei. **C**, Cribriform pattern; isomorphic cells with bland and small, inconspicuous nucleoli.





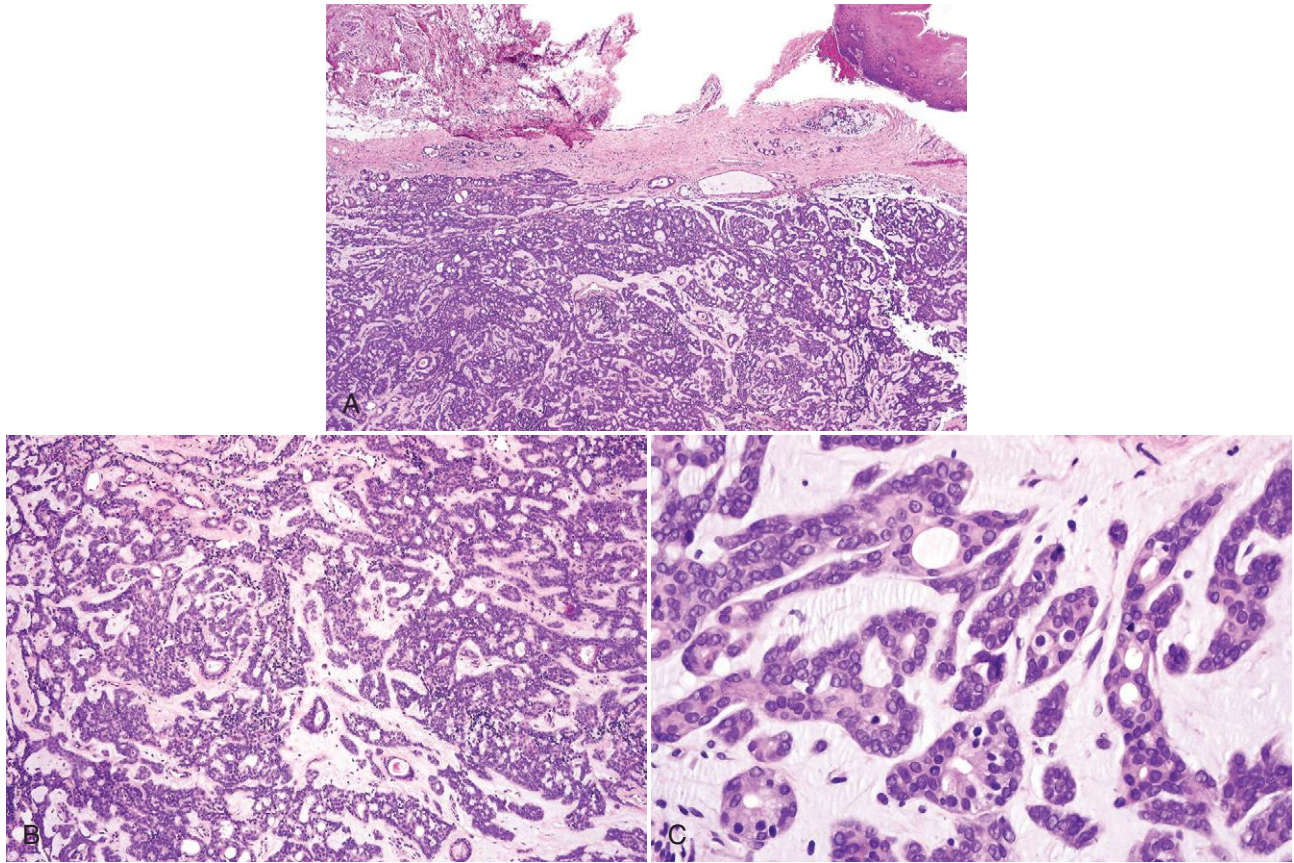
**FIGURE 13-33.** Polymorphous low-grade adenocarcinoma. **A**, Small islands of tumor cells in myxochondroid matrix. **B**, Ductal structures in myxochondroid stroma. **C**, Sheets and nests of tumor cells with some clear cells. **D**, Cells have pale or clear cytoplasm and nuclei with dispersed chromatin and small nucleoli. **E**, Perineural invasion; cells exhibit slight nuclear atypia.





**FIGURE 13-34.** Polymorphous low-grade adenocarcinoma. **A**, Strands and cords of cells and ducts with streaming pattern and fibrous stroma. **B**, Cords and strands of tumor cells in fibrous stroma. **C**, An area with ductal structures and dystrophic calcifications in myxochondroid stroma. **D**, Ductal structures with bland nuclear morphology in myxohyaline stroma. **E**, An area of intraneural invasion.





**FIGURE 13-35.** Cribriform adenocarcinoma (of the tongue). **A**, Darker-staining tumor than the polymorphous low-grade adenocarcinoma with infiltrative borders. **B**, Anastomosing trabeculae and cords of cells with reticular and cribriform pattern. **C**, Biphasic population of ductal cells and surrounding myoepithelial cells with overlapping nuclei.

## ACINIC CELL ADENOCARCINOMA

The buccal mucosa and lip are the two most common sites for this neoplasm. It is the second most common salivary gland malignancy in children after mucoepidermoid carcinoma and constitutes less than 5% of malignant intraoral salivary gland tumors. It is much more common in the major glands.

### Histopathologic Features

- Infiltrative tumor with four major patterns—solid, microcystic, papillary-cystic, and follicular; most tumors show a mixture of patterns.
- Archetypal tumor cell resembles serous cell with many hematoxyphilic zymogen granules and small, dark, eccentric nucleus (Fig. 13-36, A-D); may be present only in small numbers and PAS stain shows diastase-resistant granules (see Fig. 13-36, E); intercalated ductal cells form ducts, are smaller and cuboidal with amphophilic cytoplasm and central round-to-ovoid nuclei with dispersed chromatin and small nucleoli (Fig. 13-37); nonspecific glandular cells form a syncytium and appear somewhat nondescript; foci of mucous cells, vacuolated cells, and clear cells are frequently seen (Fig. 13-38).

- High Ki-67 index may be associated with poorer prognosis.
- Tumor-associated lymphoid proliferation is common and should not be misinterpreted as metastatic disease.
- Dedifferentiated tumors consist of undifferentiated and pleomorphic cells with higher mitotic activity (more common in major glands).

### Differential Diagnosis

- Mucoepidermoid carcinoma has epidermoid/squamous component and significant population of mucous cells.
- Papillary cystadenocarcinoma does not contain zymogen granules.

### Management and Prognosis

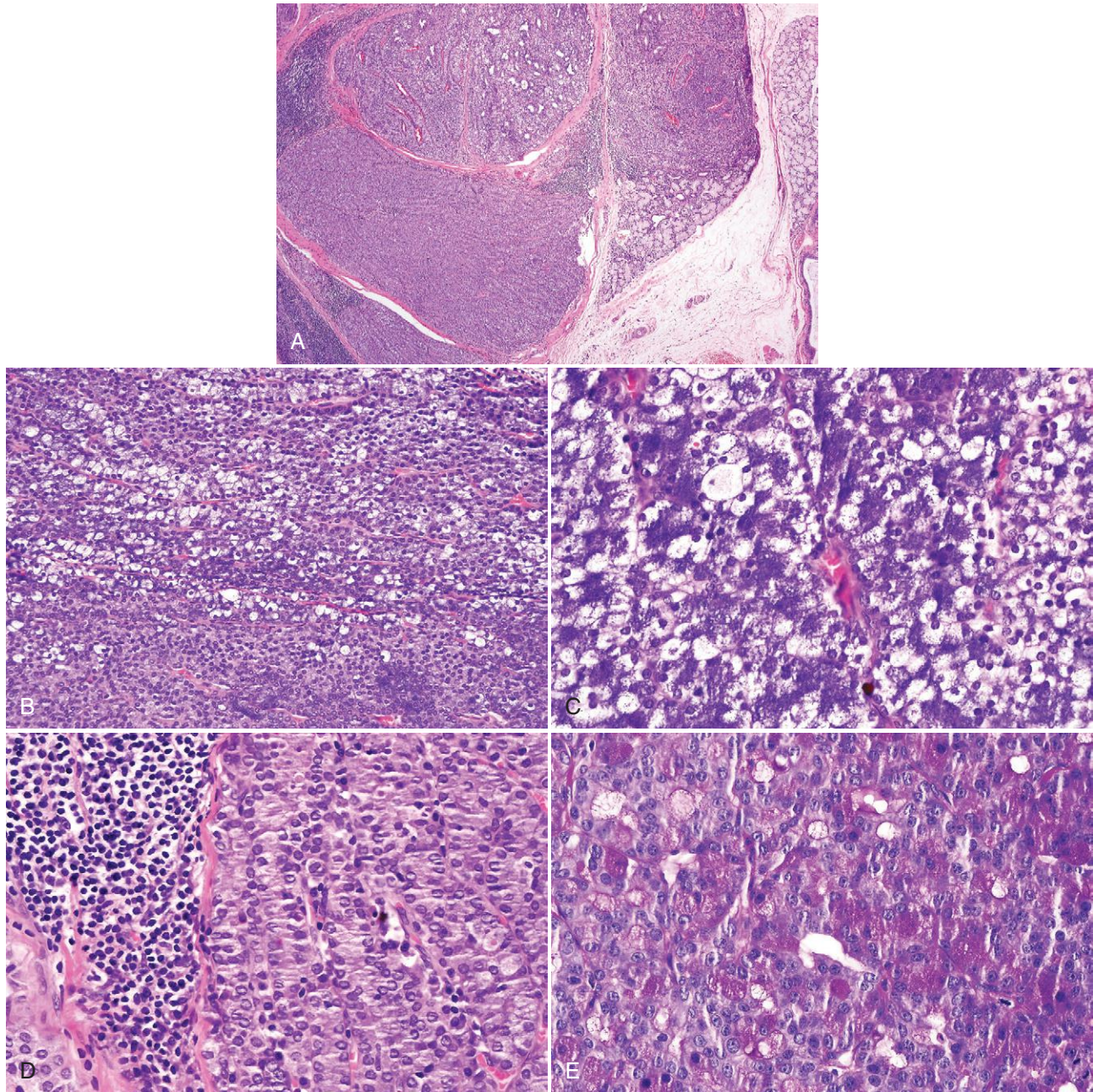
- Surgical excision is the treatment of choice; adjuvant radiation therapy may be helpful only in selected cases.
- Staging is probably the only parameter that correlates with prognosis; intraoral tumors tend to behave less aggressively compared with those in the major glands, where recurrence rate is 12%, metastatic rate is 8%, and 6% of patients die of their disease.



## REFERENCES

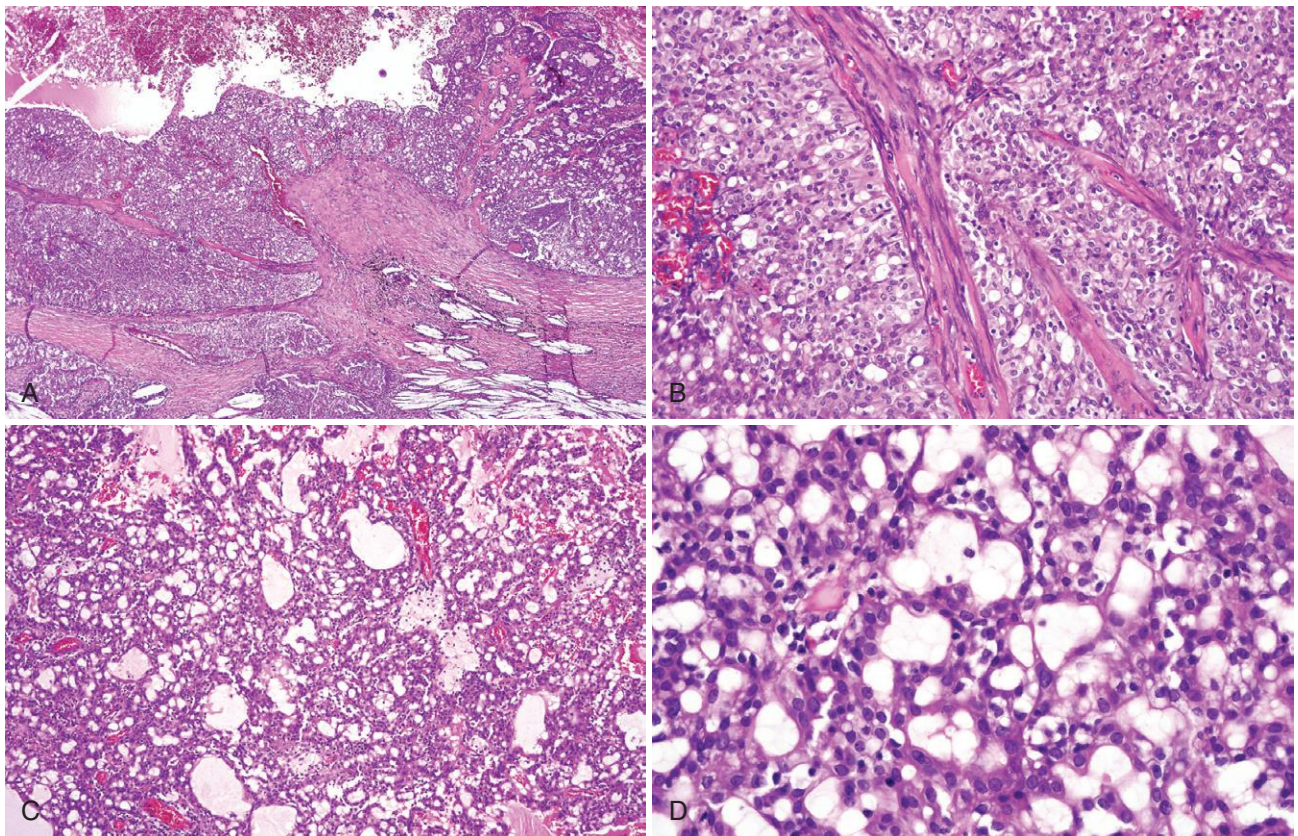
- Ellis GL, Corio RL. Acinic cell adenocarcinoma. A clinicopathologic analysis of 294 cases. *Cancer*. 1983;52:542-549.
- Castellanos JL, Lally ET. Acinic cell tumor of the minor salivary glands. *J Oral Maxillofac Surg*. 1982;40:428-431.
- Gardner DG, Bell ME, Wesley RK, Wysocki GP. Acinic cell tumors of minor salivary glands. *Oral Surg Oral Med Oral Pathol*. 1980;50:545-551.
- Hellquist HB, Sundelin K, Di Bacco A, et al. Tumour growth fraction and apoptosis in salivary gland acinic cell carcinomas. Prognostic implications of Ki-67 and bcl-2 expression and of in situ end labeling (TUNEL). *J Pathol*. 1997;181:323-329.

- Michal M, Skalova A, Simpson RH, et al. Well-differentiated acinic cell carcinoma of salivary glands associated with lymphoid stroma. *Hum Pathol*. 1997;28:595-600.
- Skalova A, Leivo I, Von Boguslawsky K, Saksela E. Cell proliferation correlates with prognosis in acinic cell carcinomas of salivary gland origin. Immunohistochemical study of 30 cases using the MIB 1 antibody in formalin-fixed paraffin sections. *J Pathol*. 1994;173:13-21.
- Triantafyllidou K, Iordanidis F, Psomaderis K, Kalimeras E. Acinic cell carcinoma of minor salivary glands: a clinical and immunohistochemical study. *J Oral Maxillofac Surg*. 2010;68:2489-2496.

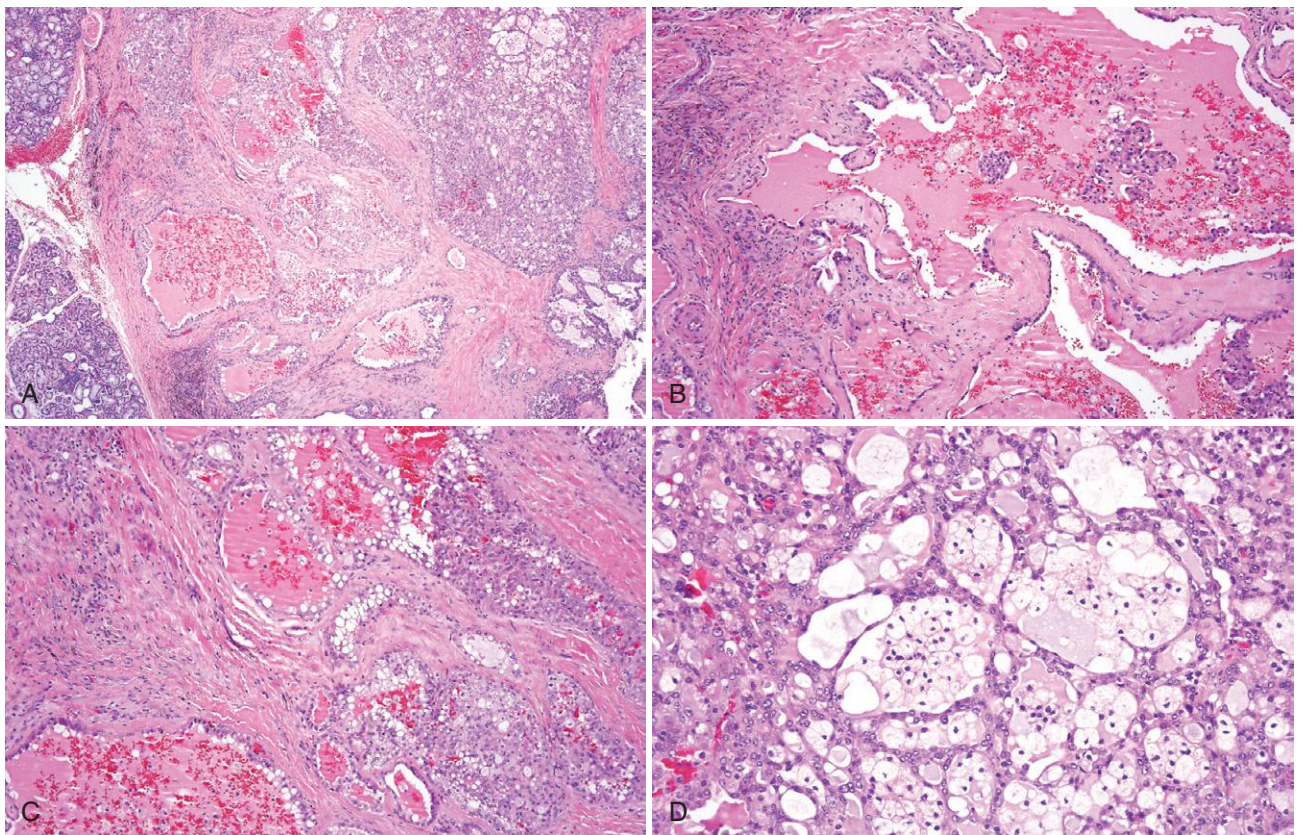


**FIGURE 13-36.** Acinic cell adenocarcinoma. **A**, Solid, lobular growth pattern with tumor-associated lymphoid stroma (left) and infiltration of normal glands. **B**, Well-differentiated acinar cells with dark granules, clear cells, and nonspecific glandular cells that form sheets (bottom). **C**, Cytoplasmic zymogen granules and clear cells. **D**, Tumor-associated lymphoid proliferation adjacent to nonspecific glandular cells. **E**, Zymogen granules are periodic acid-Schiff (PAS) positive and diastase resistant.





**FIGURE 13-37.** Acinic cell adenocarcinoma. **A**, Tumor forms large cystic and microcystic structures. **B**, Solid areas with rudimentary duct formation and nonspecific glandular cells. **C**, Small and large ducts in reticular pattern with microcystic spaces. **D**, Ductal and nonspecific glandular cells, both with bland nuclei.



**FIGURE 13-38.** Acinic cell adenocarcinoma. **A**, Focal areas that are papillary-cystic (*bottom right*). **B**, Tumor forms papillary structures within cyst lumen. **C**, Clear cells are noted focally. **D**, Microcystic and reticular pattern with many vacuolated cells.



## CLEAR CELL ADENOCARCINOMA (HYALINIZING)

### Histopathologic Features

- Infiltrative proliferation of sheets, cords, nests, and trabeculae of monomorphic clear cells that are round to polygonal with variable degrees of stromal hyalinization; ovoid nuclei with dispersed chromatin and small-to-inconspicuous nucleoli; mitoses are rare (Fig. 13-39, A-C); cells are glycogen rich (see Fig. 13-39, D and E); some cases are not hyalinized, and rare cases do not contain glycogen.
- One third of cases exhibit perineural invasion; atypia and necrosis are rare.
- All cases are AE1/3 positive; epithelial membrane antigen (EMA) is positive in the majority of cases, and carcinoembryonic antigen (CEA) is positive in some cases; myoepithelial markers are negative.

### Differential Diagnosis

- Clear cell mucoepidermoid carcinoma contains many mucous cells and epidermoid cells.
- Clear cell variant of acinic cell carcinoma has abundant PAS-stain positive, diastase-resistant zymogen granules within the tumor cells.
- Epithelial-myoepithelial carcinoma is rare in the oral cavity and is biphasic with ductal cells surrounded by clear myoepithelial cells.
- Clear cell myoepithelial neoplasms are diffusely immunopositive for myoepithelial markers.

- Metastatic renal cell carcinoma contains nests of tumor cells with numerous interspersed capillaries (Fig. 13-40).
- Clear cell odontogenic carcinoma occurs within bone, exhibits significant cytologic atypia, and is generally a high-grade lesion.

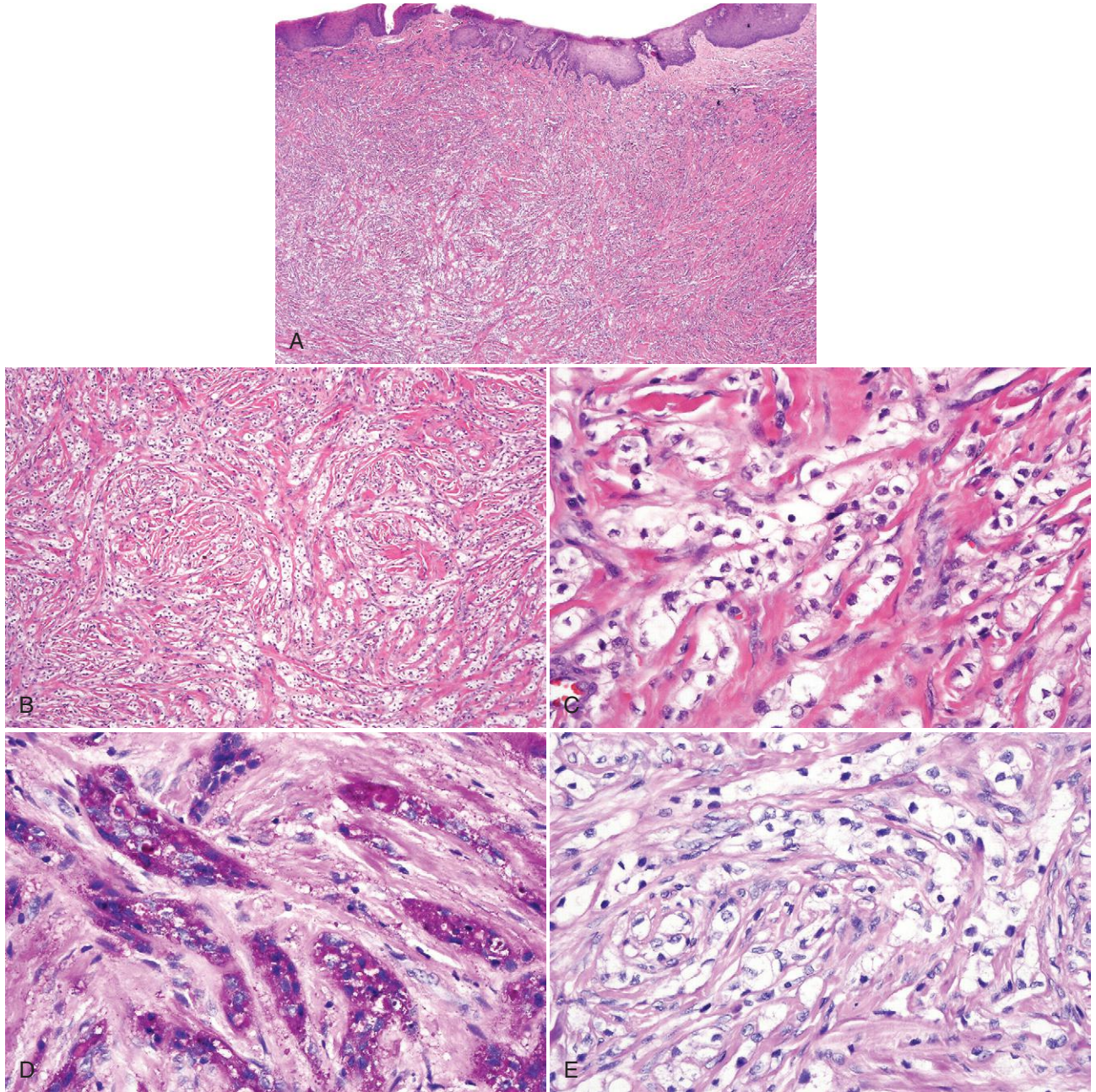
### Management and Prognosis

- Excision with clear margins is the treatment of choice; radiotherapy may be indicated.
- Metastases develop in 16% to 25% of patients; most metastases are to regional nodes, but patients do not die of the tumor.

### REFERENCES

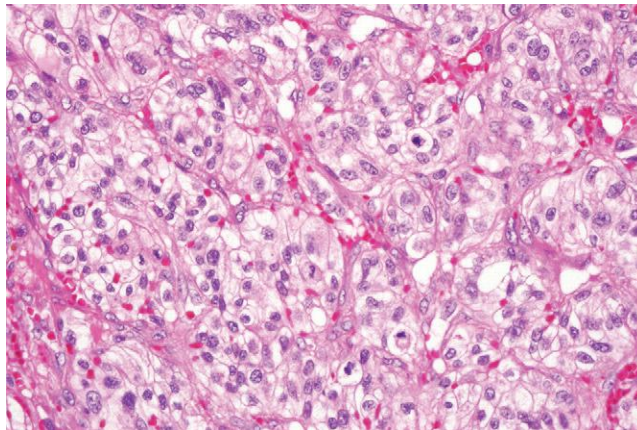
- Milchgrub S, Gnepp DR, Vuitch F, et al. Hyalinizing clear cell carcinoma of salivary gland. *Am J Surg Pathol.* 1994;18:74-82.
- O'Regan E, Shandilya M, Gnepp DR, et al. Hyalinizing clear cell carcinoma of salivary gland: an aggressive variant. *Oral Oncol.* 2004;40:348-352.
- O'Sullivan-Mejia ED, Massey HD, Faquin WC, Powers CN. Hyalinizing clear cell carcinoma: report of eight cases and a review of literature. *Head Neck Pathol.* 2009;3:179-185.
- Solar AA, Schmidt BL, Jordan RC. Hyalinizing clear cell carcinoma: case series and comprehensive review of the literature. *Cancer.* 2009;115:75-83.
- Wang B, Brandwein M, Gordon R, et al. Primary salivary clear cell tumors—a diagnostic approach: a clinicopathologic and immunohistochemical study of 20 patients with clear cell carcinoma, clear cell myoepithelial carcinoma, and epithelial-myoepithelial carcinoma. *Arch Pathol Lab Med.* 2002;126:676-685.





**FIGURE 13-39.** Hyalinizing clear cell carcinoma. **A**, Small islands of clear cells within hyalinized stroma with infiltrative pattern. **B**, Cords and nests of tumor cells with prominent stromal hyalinization. **C**, Cells with clear cytoplasm and irregular nuclear outlines. **D**, Cytoplasm contains abundant periodic acid-Schiff (PAS) stain positive granules. **E**, Granules of glycogen digested by diastase (PAS with diastase).





**FIGURE 13-40.** Metastatic renal cell carcinoma: nests of clear cells surrounded by dilated capillaries.

## ADENOCARCINOMA, NOT OTHERWISE SPECIFIED

Adenocarcinoma, not otherwise specified, constitutes less than 10% of cases of intraoral malignant salivary gland tumors, but this frequency varies greatly. The tumor forms ductal structures, but it does not fit any of the defined salivary gland malignancies and is therefore a diagnosis of exclusion.

### Histopathologic Features

- Adenocarcinoma, not otherwise specified, is an infiltrative neoplasm that forms ductal and glandular structures and may exhibit a variety of patterns including nests, tubules, cords and strands, trabeculae, or solid sheets (Fig. 13-41); because cytologic atypia is often minimal, the presence of infiltration at the tumor margin is one of the most important criteria that separates benign from malignant processes.

### Differential Diagnosis

- Defined salivary gland malignancies such as polymorphous low-grade adenocarcinoma that has a polymorphic pattern, or less common forms of well-known

entities, such as solid or tubular adenoid cystic carcinoma, should be ruled out.

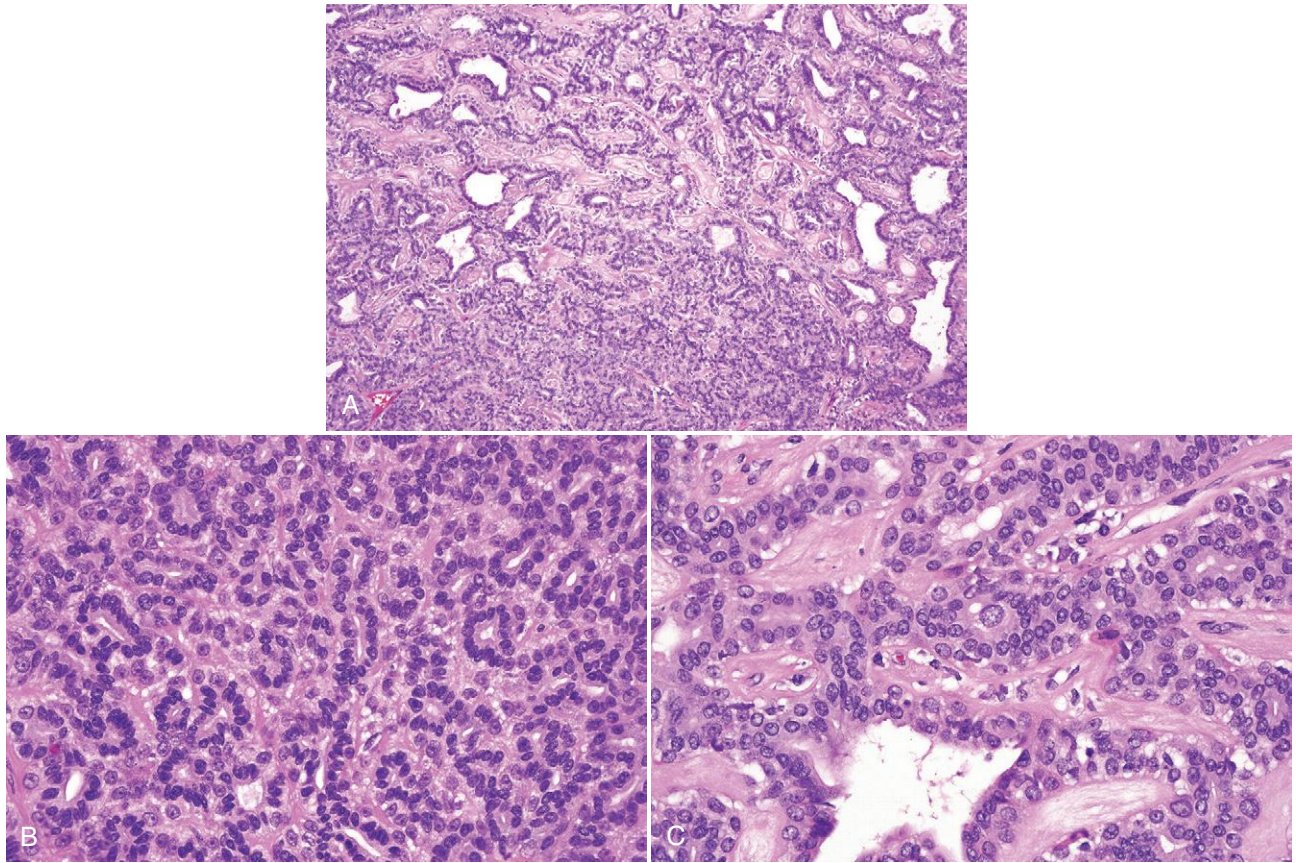
### Management and Prognosis

- Surgical excision is the treatment of choice with adjuvant radiation therapy for selected cases.
- As expected, tumors with high-grade cytology, necrosis, perineural invasion, and infiltration of normal structures are associated with locoregional recurrence.

### REFERENCES

- Buchner A, Merrell PW, Carpenter WM. Relative frequency of intraoral minor salivary gland tumors: a study of 380 cases from northern California and comparison to reports from other parts of the world. *J Oral Pathol Med.* 2007;36:207-214.
- Ellis GL, Auclair PL. *Tumors of the Salivary Glands.* Washington, D.C.: American Registry of Pathology; 2008.
- Matsuba HM, Mauney M, Simpson JR, et al. Adenocarcinomas of major and minor salivary gland origin: a histopathologic review of treatment failure patterns. *Laryngoscope.* 1988;98:784-788.
- Spiro RH, Huvois AG, Strong EW. Adenocarcinoma of salivary origin. Clinicopathologic study of 204 patients. *Am J Surg.* 1982;144:423-431.





**FIGURE 13-41.** Adenocarcinoma, not otherwise specified. **A**, Ductlike structures with a cuff of clear cells and hyalinized stroma. **B**, More solid areas but still with ductlike structures. **C**, Cells show variation in nuclear shape and size.



# 14

## ODONTOGENIC CYSTS

### CHAPTER CONTENTS

ODONTOGENIC CYSTS 320

INFLAMMATORY CYSTS 320

Apical and Lateral Radicular Cyst and Periapical Granuloma 320

Mandibular Buccal Bifurcation Cyst 327

DEVELOPMENTAL CYSTS 328

Dentigerous Cyst (Follicular Cyst) 328

Lateral Periodontal Cyst 333

Orthokeratinized Odontogenic Cyst 335

Odontogenic Cyst in a Globulomaxillary Location 337

Primordial Cyst 338

Glandular Odontogenic Cyst 338

The tooth develops from ingrowth of the lining of the primitive stomodeum called the dental lamina. The dental lamina forms tooth buds for the primary and the permanent dentition (Fig. 14-1), and after odontogenesis, remnant epithelium are left behind as rests. The epithelium of odontogenic cysts is thought to arise from stimulation of such residual odontogenic rests (e.g., rests of Serres in the gingiva or rests of Malassez around the tooth roots in the jawbones) (Fig. 14-2).

### Odontogenic Cysts

Cystic lesions in the jawbones are either odontogenic or nonodontogenic in their derivation. All odontogenic cysts are inflammatory, developmental, or, less commonly, neoplastic in nature, and the putative epithelium from which they derive may be rests of Malassez, dental lamina rests, reduced enamel epithelium, degenerated enamel organ, or, in rare cases, the epithelium of the surface mucosa (Fig. 14-3). In general, inflammatory odontogenic cysts have proliferative epithelium, and developmental odontogenic cysts have uniformly thin epithelium, although inflammation may lead to epithelial proliferation. The most common cyst is the radicular cyst (>50%), followed by the dentigerous cyst and keratocystic odontogenic tumor (odontogenic keratocyst).

### Inflammatory Cysts

#### APICAL AND LATERAL RADICULAR CYST AND PERIAPICAL GRANULOMA

A tooth that has caries involving the pulp or that has experienced direct trauma becomes devitalized and may develop a radiolucency at the apex of the root. This may represent an apical radicular cyst, periapical granuloma or scar, or abscess.

#### Clinical Findings

- A cyst may or may not manifest as a swelling, depending on the size; the tooth may or may not be painful; a well-circumscribed radiolucency is present at the apex (apical radicular) or on the side (lateral radicular) of a nonvital tooth; there may have been prior root canal (endodontic) therapy (Fig. 14-4, A and B).
- Residual cyst refers to any odontogenic cyst in the alveolar bone where a tooth had been extracted and is most often a residual apical radicular cyst (see Fig. 14-4, C)

#### Etiopathogenesis and Histopathologic Features

Inflammation from the pulp of necrotic teeth results in proliferation of rests of Malassez, which are remnants



of the Hertwig root sheath that helps form the roots of the teeth during odontogenesis.

- A radicular cyst is lined by nonkeratinized stratified squamous epithelium that usually proliferates in a plexiform or retiform pattern and exhibits spongiosis and neutrophilic exocytosis; the wall is composed of edematous granulation tissue and often scar tissue, many plasma cells, Russell bodies, lymphocytes, foamy macrophages, and sometimes abscesses are present (Fig. 14-5); curetted specimens may show only granulation tissue with focal lining epithelium (Fig. 14-6).
- Hyaline lamellar or globular structures of odontogenic origin (Rushton bodies) may be present within the epithelium (Fig. 14-7); epithelial loss is often associated with cholesterol granulomas.
- Foreign material from root canal filling is often seen: gutta percha is yellowish or brownish green, granular, and slightly refractile (Fig. 14-8); cements, in particular epoxy resin (such as AH Plus [Dentsply International, York, Pa], which contains zirconium and iron oxides and calcium tungstate), is usually refractile and crystalline in an eosinophilic background (Fig. 14-9); amalgam tattoo may be present from previous root apex excision (apicoectomy).
- Hyaline ring (pulse) granuloma (likely a foreign body reaction to exogenous material) consists of hyalinized rings with central and/or surrounding giant cells; foreign material is sometimes identified (Figs. 14-10 and 14-11).
- Radicular cysts from the apices of maxillary molars may be lined by respiratory epithelium (Fig. 14-12); fragments of sinus mucosa, however, signify an oroantral communication and must be reported; fragments of sinus inflammatory polyps may be present—exhibiting few to no mucous glands, eosinophilic coagulum, and eosinophils (Fig. 14-13).

**Differential Diagnosis**

- Any inflamed intraosseous, odontogenic, or other cyst may appear similar.
- If epithelium is not present, the diagnosis is periapical granuloma (Fig. 14-14); sheets of plasma cells are common in periapical granulomas, and they should not be overdiagnosed as plasmacytomas (Fig. 14-15).
- Periapical scar shows only fibrosis, sometimes with inflammation (Fig. 14-16).
- Chronic active periodontal disease appears similar histologically, but clinically, the tooth is surrounded by a periradicular radiolucency; disease starts either from an apical radicular cyst that grows very large and combines with an overlying periodontal bone defect or from periodontal disease starting from the surface of the bone and extending downwards to encompass the entire tooth.

**Management and Prognosis**

- Enucleation or curettage with apicoectomy (excision of the root tip) is curative.

**REFERENCES**

Gadbail AR, Chaudhary M, Patil S, Gawande M. Actual Proliferating Index and p53 protein expression as prognostic marker in odontogenic cysts. *Oral Dis.* 2009;15:490-498.

Jones AV, Craig GT, Franklin CD. Range and demographics of odontogenic cysts diagnosed in a UK population over a 30-year period. *J Oral Pathol Med.* 2006;35:500-507.

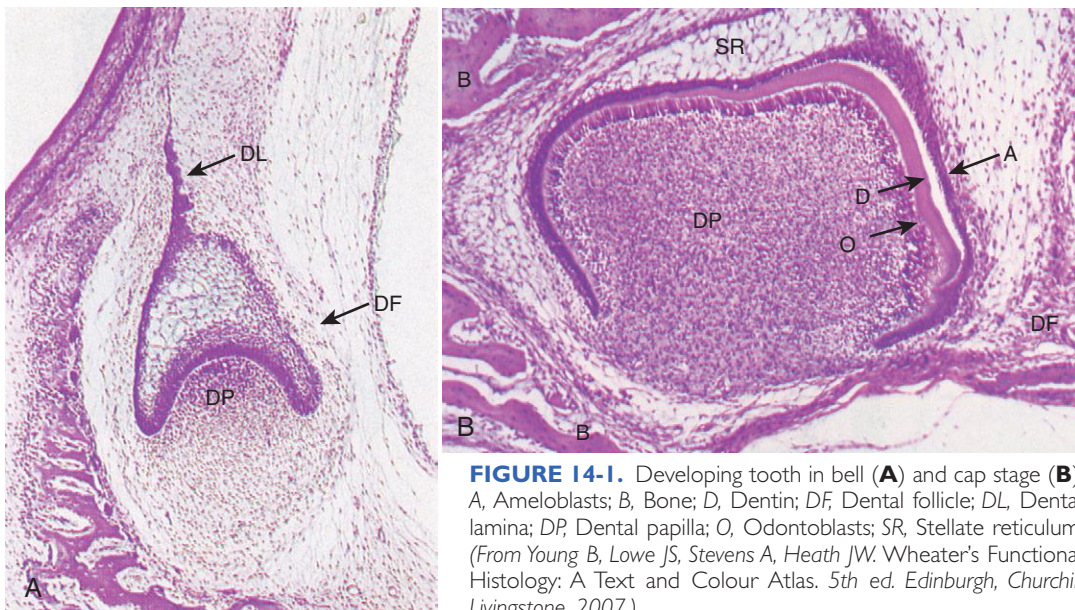
Neville BW, Damm DD, Allen CM, Bouquot J. *Oral and Maxillofacial Pathology.* 5th ed. Philadelphia, Saunders; 2009.

Philippou S, Ruhl GH, Mandelartz E. Scanning electron microscopic studies and x-ray microanalysis of hyaline bodies in odontogenic cysts. *J Oral Pathol Med.* 1990;19:447-452.

Philipsen HP, Reichart PA. Pulse or hyaline ring granuloma. Review of the literature on etiopathogenesis of oral and extraoral lesions. *Clin Oral Investig.* 2010;14:121-128.

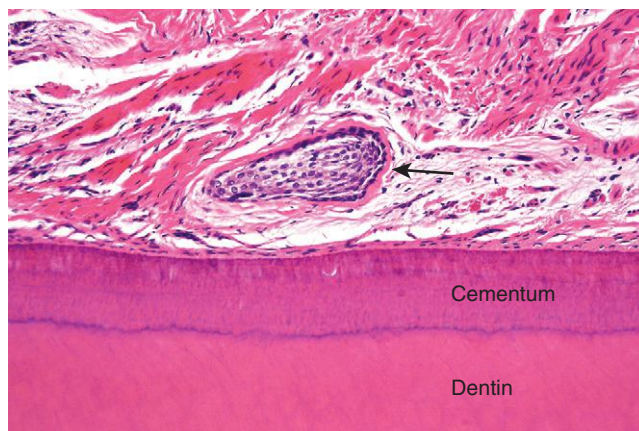Schulz M, von Arx T, Altermatt HJ, Bosshardt D. Histology of periapical lesions obtained during apical surgery. *J Endod.* 2009;35:634-642.

Tripi TR, Bonaccorso A, Rapisarda E, Bartoloni G. Proliferative activity in periapical lesions. *Aust Endod J.* 2003;29:31-33.

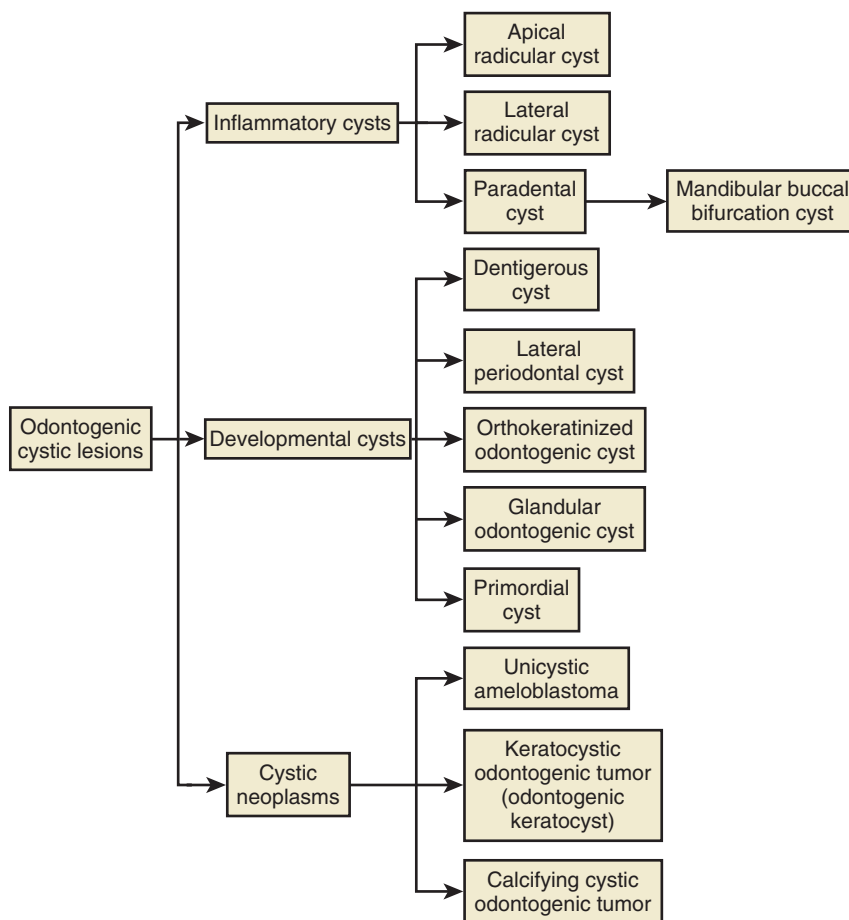


**FIGURE 14-1.** Developing tooth in bell (A) and cap stage (B): A, Ameloblasts; B, Bone; D, Dentin; DF, Dental follicle; DL, Dental lamina; DP, Dental papilla; O, Odontoblasts; SR, Stellate reticulum. (From Young B, Lowe JS, Stevens A, Heath JW. *Wheater's Functional Histology: A Text and Colour Atlas.* 5th ed. Edinburgh, Churchill Livingstone, 2007.)



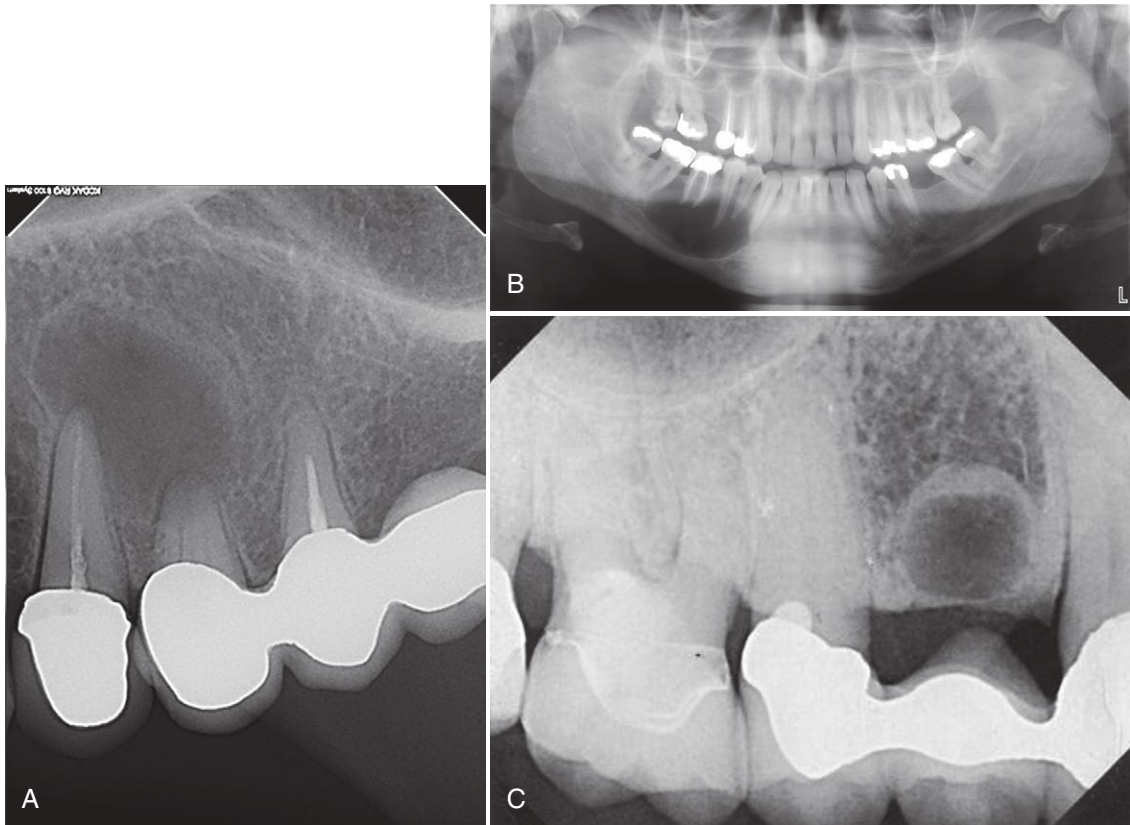


**FIGURE 14-2.** Rest of Malassez (arrow) in the periodontal ligament (fibrous tissue that attaches the tooth to bone).

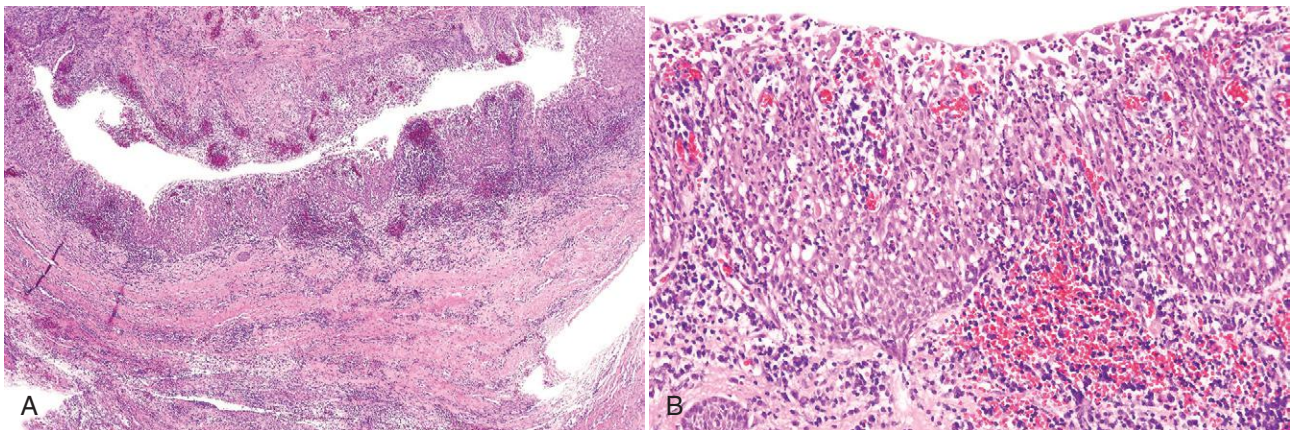


**FIGURE 14-3.** Classification of jaw cysts.



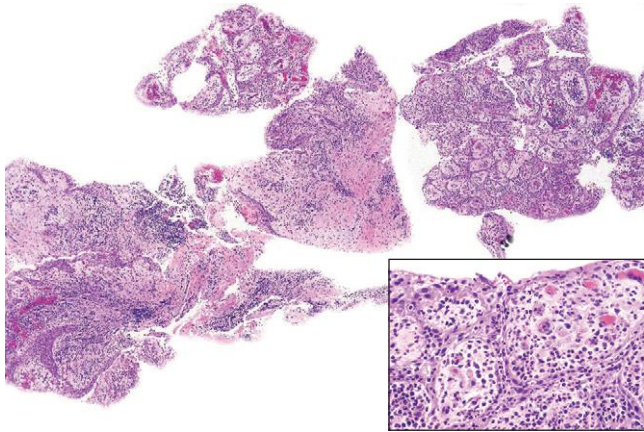


**FIGURE 14-4.** Apical radicular cyst. **A**, Circumscribed radiolucency at the apex of an endodontically treated left maxillary first premolar. **B**, Large circumscribed radiolucency centered around endodontically treated right lower first molar. **C**, Residual apical radicular cyst after extraction of the right maxillary first premolar. (**B**, Courtesy of Dr. Manuel Diaz, private practice, Houston, Tex.)

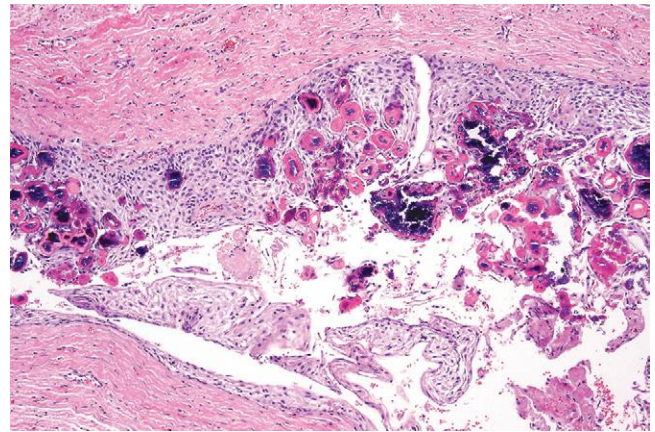


**FIGURE 14-5.** Apical radicular cyst. **A**, Cyst with inflammation. **B**, Lining consists of nonkeratinized stratified squamous epithelium with marked spongiosis and neutrophilic exocytosis.

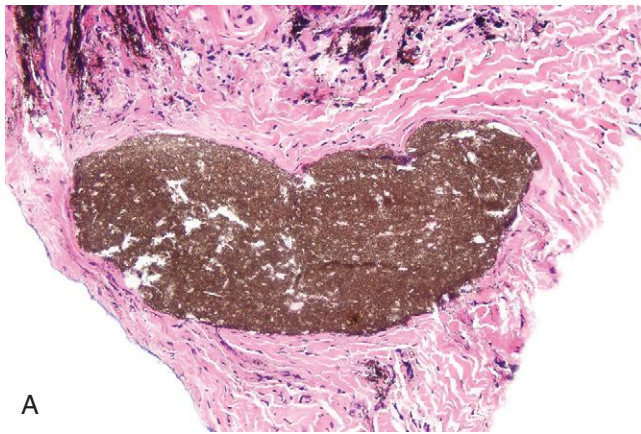




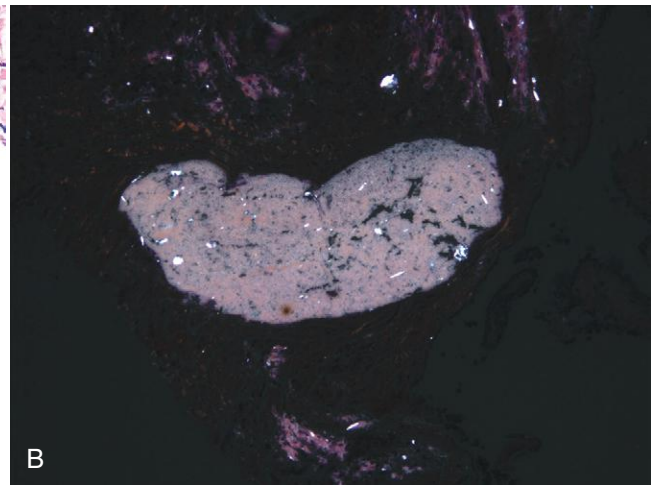
**FIGURE 14-6.** Apical radicular cyst in fragments with plexiform epithelial proliferation showing spongiosis and neutrophilic exocytosis (*inset*).



**FIGURE 14-7.** Apical radicular cyst with eosinophilic, hyaline, laminated Rushton bodies exhibiting dystrophic calcifications.

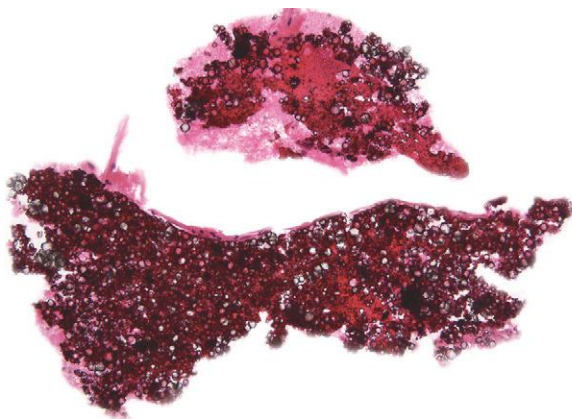


A

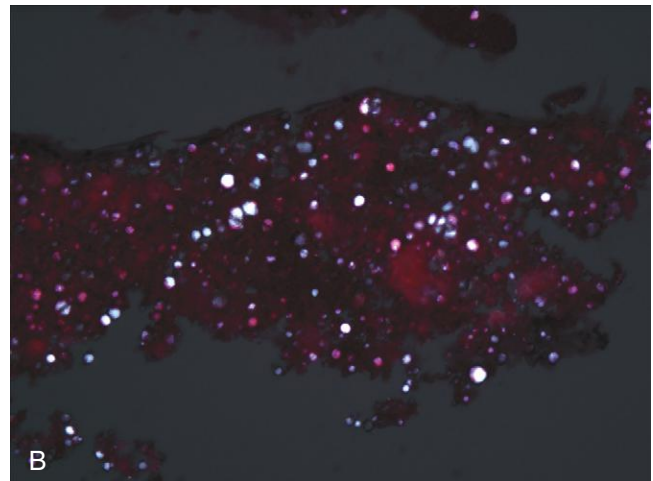


B

**FIGURE 14-8.** Gutta percha (root canal filler). **A**, Brown-green granular foreign body commonly seen in apical lesions. **B**, Gutta percha is slightly refractile, and root canal cement is more brightly refractile.



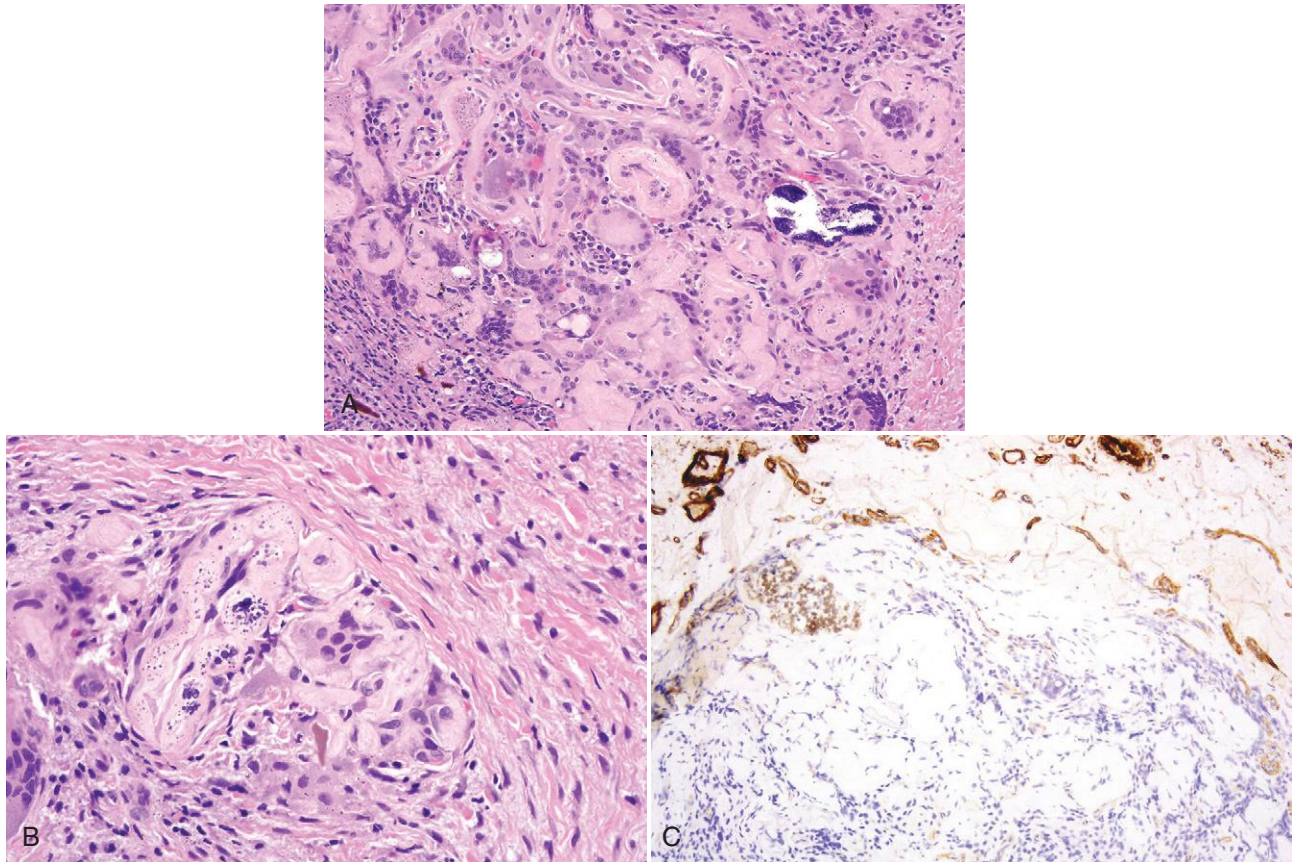
A



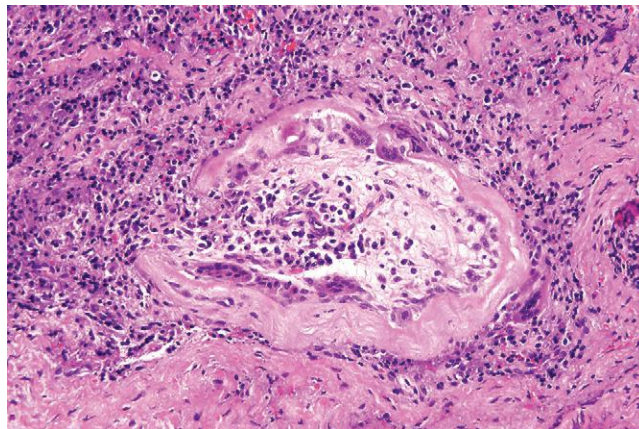
B

**FIGURE 14-9.** Periapical granuloma with AH Plus (Dentsply International, York, Penn.) cement. **A**, Crystalline particulate foreign material with eosinophilic background. **B**, Particulate material is brightly refractile in polarized light.



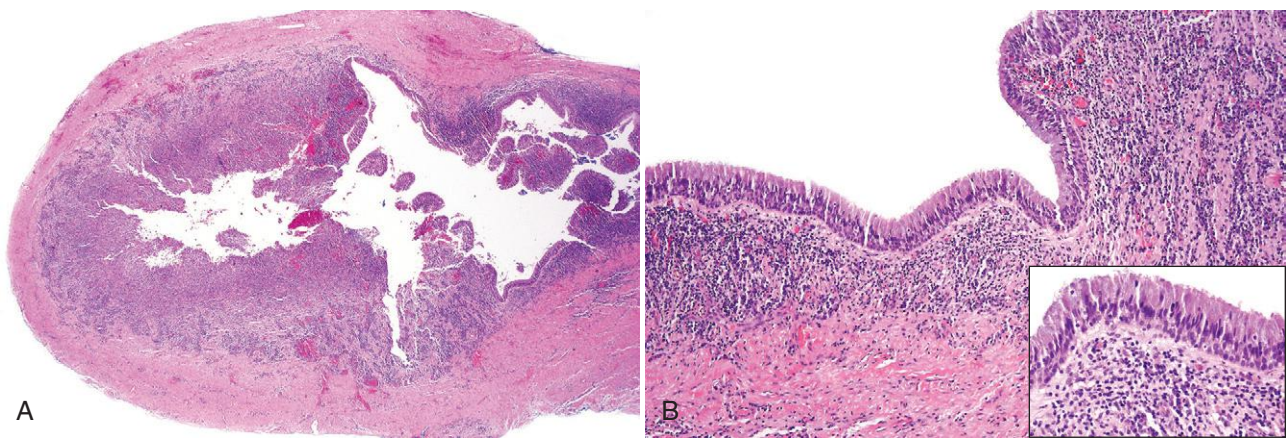


**FIGURE 14-10.** Giant cell hyaline rings. **A**, Hyalinized rings often with giant cells in the center. **B**, Hyaline rings with giant cells, calcifications, and brown foreign material. **C**, Hyaline material negative for type V collagen.

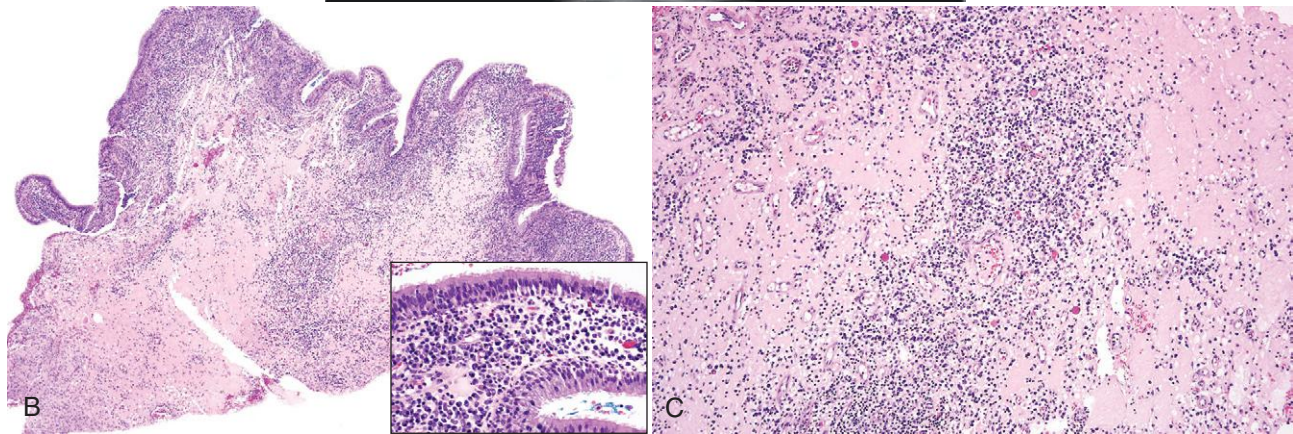
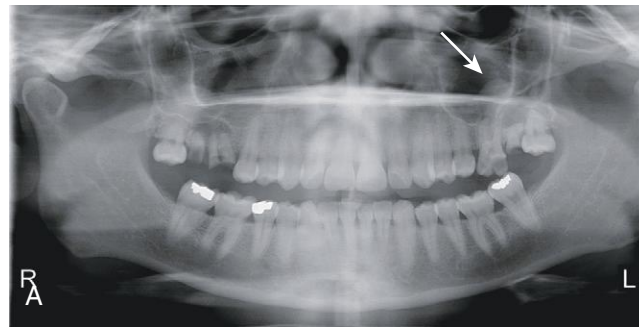


**FIGURE 14-11.** Giant cell hyaline rings showing center of rings composed of granulation tissue with giant cells at the periphery.

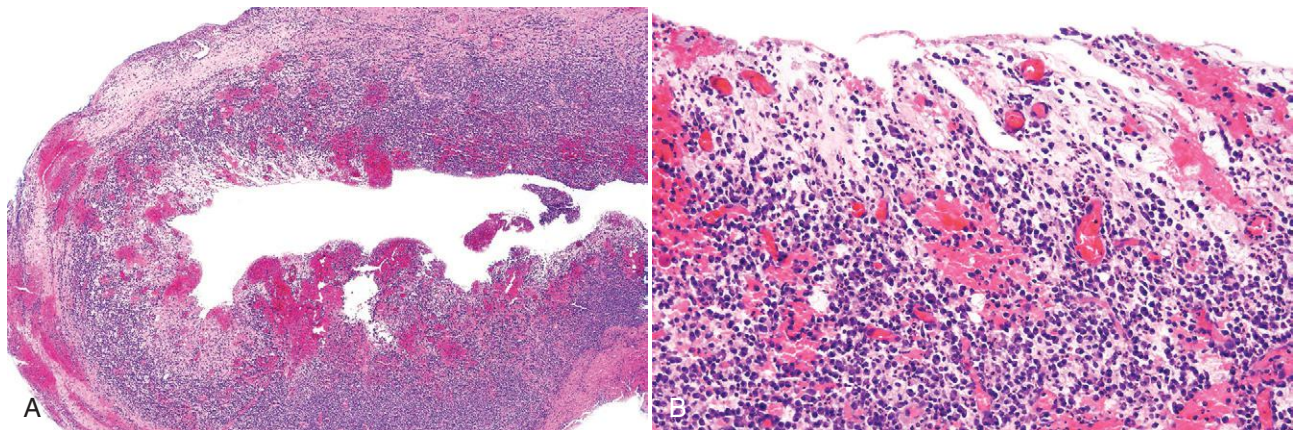




**FIGURE 14-12.** Apical radicular cyst at apex of maxillary first molar. **A**, Cyst is partially lined by respiratory epithelium but without any mucous glands. **B**, Typical pseudostratified columnar epithelium (*inset*).

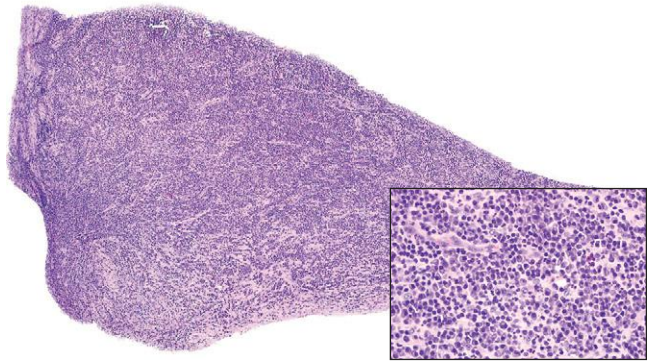


**FIGURE 14-13.** Sinus inflammatory polyp. **A**, Radiograph showing dome-shaped opacity (*arrow*) in the left sinus adjacent to carious left maxillary first molar and root tips of second molar. **B**, Mass of eosinophilic material and granulation tissue covered by respiratory epithelium with no mucous glands; many plasma cells and eosinophils (*inset*) (from **A**). **C**, Abundant eosinophilic amorphous material (from **A**). (**A**, Courtesy of Dr. Jeffrey Stone, private practice, Lowell, Mass.)

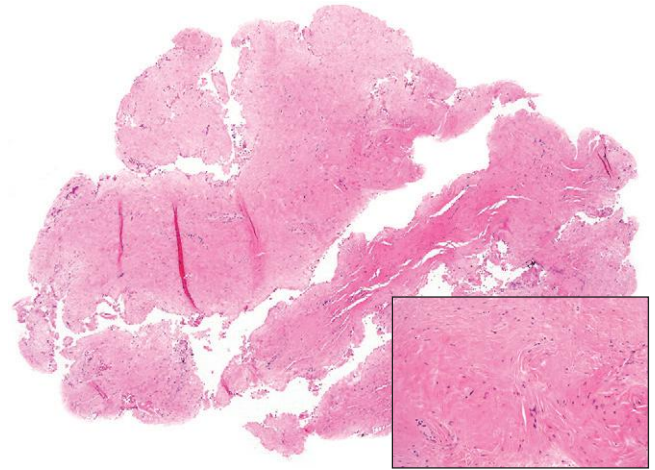


**FIGURE 14-14.** Periapical granuloma. **A**, Granulation tissue arranged around a cystlike cavity. **B**, Granulation tissue with acute and chronic inflammatory cells and no lining epithelium.





**FIGURE 14-15.** Periapical granuloma with sheets of plasma cells (inset).



**FIGURE 14-16.** Periapical scar: dense fibrous scar tissue (inset).

## MANDIBULAR BUCCAL BIFURCATION CYST

### Clinical Findings

- Children in the first decade (mean age of 7 years); 38% bilateral
- Swelling and pain in the area of the first permanent molar; radiolucency around a vital first molar that extends from the furcation (where roots diverge) to the apex of the tooth causing tilting of the roots lingually (best seen on occlusal radiograph); periosteal reaction usually present (Fig. 14-17)

### Etiopathogenesis and Histopathologic Features

Lining may derive from dental lamina rests or crevicular epithelium. Another theory of pathogenesis is that this arises from a laterally displaced dentigerous cyst, which could explain the high incidence of bilaterality.

- Similar to radicular cyst with proliferative epithelium and acute and chronic inflammation

### Differential Diagnosis

- Some clinicians consider the buccal bifurcation cyst a subcategory of paradental cysts, which are cysts located to the side of a tooth; the most common locations are on the buccal or distal aspect of an erupted third molar that occurs in patients in the second and

third decades are likely to represent a buccally or distally displaced and inflamed dentigerous cyst; some of these are associated with buccal enamel extensions that putatively cause periodontal pocketing; most patients have a history of third molar infection/pericoronitis.

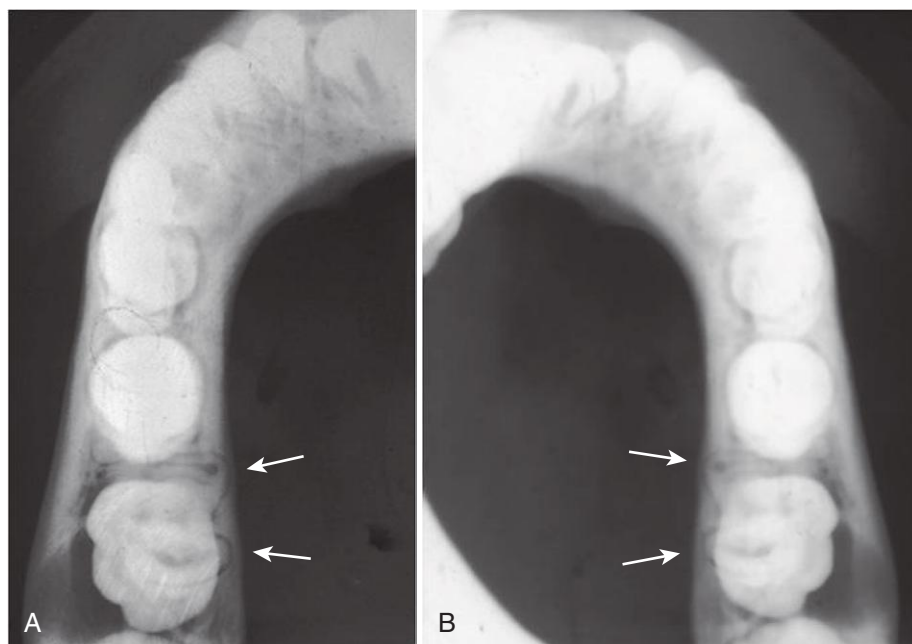
### Management and Prognosis

- Enucleation of the cyst without extraction of the tooth is curative for the buccal bifurcation cyst.
- Extraction of the tooth and enucleation of the paradental cyst associated with the third molar is curative.

### REFERENCES

- Ackermann G, Cohen MA, Altini M. The paradental cyst: a clinicopathologic study of 50 cases. *Oral Surg Oral Med Oral Pathol.* 1987;64:308-312.
- de Sousa SO, Correa L, Deboni MC, de Araujo VC. Clinicopathologic features of 54 cases of paradental cyst. *Quintessence Int.* 2001;32:737-741.
- Fowler CB, Brannon RB. The paradental cyst: a clinicopathologic study of six new cases and review of the literature. *J Oral Maxillofac Surg.* 1989;47:243-248.
- Pompura JR, Sandor GK, Stoneman DW. The buccal bifurcation cyst: a prospective study of treatment outcomes in 44 sites. *Oral Surg Oral Med Oral Pathol Oral Radiol Endod.* 1997;83:215-221.
- Thikkurissy S, Glazer KM, McNamara KK, Tatakis DN. Buccal bifurcation cyst in a 7-year-old: surgical management and 14-month follow-up. *J Periodontol.* 2010;81:442-446.





**FIGURE 14-17.** Mandibular buccal bifurcation cyst in one patient. **A**, Occlusal radiograph showing lingual displacement of roots of first molar on right and buccal radiolucency. **B**, Occlusal radiograph showing displacement of roots of first molar on left and buccal radiolucency. (Courtesy of Dr. Bernard Friedland, Harvard School of Dental Medicine, Boston)

## Developmental Cysts

These cysts are characterized by uniformly thin lining, although inflammation will cause epithelial proliferation with spongiosis and neutrophilic exocytosis. Melanin pigment is infrequently encountered within developmental odontogenic cysts. The pluripotentiality of the lining of dentigerous and other developmental odontogenic cysts is the likely origin of intraosseous salivary gland neoplasms, most of which are malignant. The most common is mucoepidermoid carcinoma, followed by adenoid cystic carcinoma.

### DENTIGEROUS CYST (FOLLICULAR CYST)

#### Clinical Findings

- Usually in the second and third decades; radiolucency associated with impacted teeth, usually the third molars, but also often the maxillary canines, premolars, and supernumerary teeth; well-demarcated unilocular radiolucency (Fig. 14-18)

#### Etiopathogenesis and Histopathologic Features

The epithelium is derived from reduced enamel epithelium (fused external and internal enamel epithelium after the tooth is formed) that has undergone squamous metaplasia as part of cystification. This epithelium is pluripotent and capable of producing mucous cells, ciliated cells, and glandular structures; intraosseous salivary gland neoplasms likely derive from these

pluripotent cells. Some radiolucencies described by clinicians as dentigerous cysts maintain a lining of reduced enamel epithelium and, by custom, a diagnosis of dentigerous cyst, although they may actually represent hyperplastic dental follicles.

- Lining consists of nonkeratinized stratified squamous epithelium 5 to 10 cells thick (Figs. 14-19); some radiolucencies described by clinicians as dentigerous cysts maintain a lining of reduced enamel epithelium, a double layer of luminal columnar cells, and basal low cuboidal cells with eosinophilic cytoplasm, and a diagnosis of dentigerous cyst is made, although they may actually represent hyperplastic dental follicles (Fig. 14-20). Inflammation results in epithelial proliferation and spongiosis, and cholesterol granulomas are often seen where epithelium is disrupted (Fig. 14-21); mucous cells or ciliated cells are sometimes present (Fig. 14-22); the wall consists of dental follicle (see later); the overlying oral mucosa may be inflamed, especially if the patient is symptomatic (pericoronitis).
- The dental follicle is composed of delicately and sometimes more densely collagenized fibrous tissue with a distinctly myxoid/mucinous background; islands and strands of odontogenic epithelium are present, often with clear cells that sometimes exhibit peripheral stromal hyalinization (Fig. 14-23); perivascular hyalinization is common (see Fig. 14-19); these may be lined by reduced enamel epithelium.
- Dental papilla from an impacted tooth is composed of myxoid tissue in a rounded configuration lined by



odontoblasts (Fig. 14-24); these are often mistaken for odontogenic myxoma.

- Between 1% and 2% of radionuclencies associated with impacted teeth are histologically keratocystic odontogenic tumors (odontogenic keratocysts); 1% to 2% represent other benign odontogenic neoplasms; less than 1% are associated with the development of mucoepidermoid carcinoma (see later), ameloblastoma, and infrequently, squamous cell carcinoma (Figs. 14-25 and 14-26) (see Chapter 15).
- Follicular hamartomas with dystrophic calcifications and epithelial rests are seen in patients (usually blacks) with amelogenesis imperfecta and gingival hyperplasia.

### Differential Diagnosis

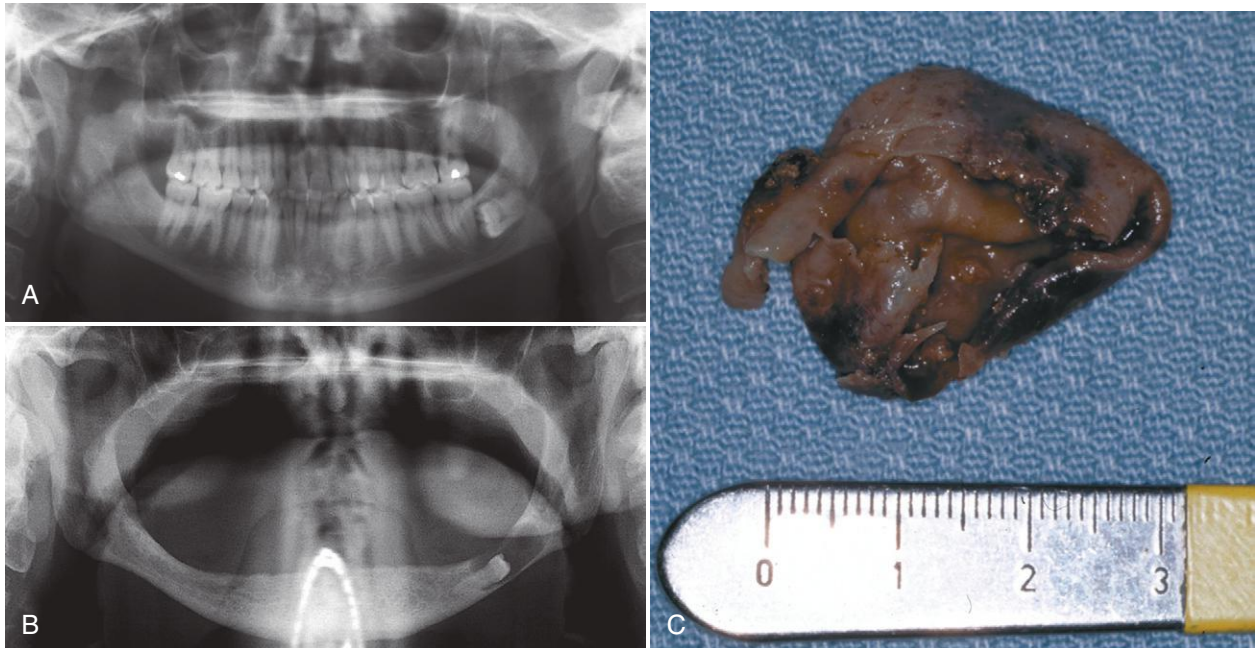
- Other developmental odontogenic cysts, if lined by nonkeratinized squamous epithelium, may appear similar.
- A diagnosis of hyperplastic dental follicle is made if follicular tissue is present that may or may not be lined by reduced enamel epithelium, if the clinical impression is such.
- Eruption cysts are bluish cystic areas overlying an erupting tooth with no intervening bone (Fig. 14-27); they are lined by nonkeratinized stratified squamous epithelium.
- Odontogenic myxomas are more uniformly myxoid without lining epithelium, and central odontogenic fibromas are more collagenous with islands and strands of odontogenic epithelium (see Chapter 15).

### Management

- Enucleation or curettage with removal of tooth is curative.

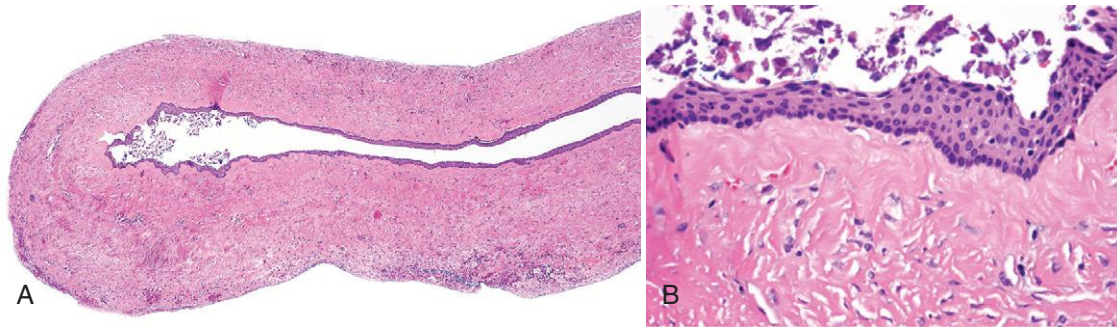
### REFERENCES

- Adeyemo WL. Do pathologies associated with impacted lower third molars justify prophylactic removal? A critical review of the literature. *Oral Surg Oral Med Oral Pathol Oral Radiol Endod.* 2006;102:448-452.
- Buchner A, David R, Carpenter W, Leider A. Pigmented lateral periodontal cyst and other pigmented odontogenic lesions. *Oral Dis.* 1996;2:299-302.
- Brookstone MS, Huvos AG. Central salivary gland tumors of the maxilla and mandible: a clinicopathologic study of 11 cases with an analysis of the literature. *J Oral Maxillofac Surg.* 1992;50:229-236.
- Elo JA, Slater LJ, Herford AS, et al. Squamous cell carcinoma radiographically resembling a dentigerous cyst: report of a case. *J Oral Maxillofac Surg.* 2007;65:2559-2562.
- Martinez-Madrigal F, Pineda-Daboin K, Casiraghi O, Luna MA. Salivary gland tumors of the mandible. *Ann Diagn Pathol.* 2000;4:347-353.
- Neville BW, Damm DD, Allen CM, Bouquot J. *Oral and Maxillofacial Pathology.* 5th ed. Philadelphia, Saunders; 2009.
- Rakprasitkul S. Pathologic changes in the pericoronal tissues of unerupted third molars. *Quintessence Int.* 2001;32:633-638.
- Roquebert D, Champsaur A, Gil del Real P, et al. Amelogenesis imperfecta, rough hypoplastic type, dental follicular hamartomas and gingival hyperplasia: report of a case from Central America and review of the literature. *Oral Surg Oral Med Oral Pathol Oral Radiol Endod.* 2008;106:92-98.
- Takeda Y, Oikawa Y, Furuya I, et al. Mucous and ciliated cell metaplasia in epithelial linings of odontogenic inflammatory and developmental cysts. *J Oral Sci.* 2005;47:77-81.
- Takeda Y, Yamamoto H. Case report of a pigmented dentigerous cyst and a review of the literature on pigmented odontogenic cysts. *J Oral Sci.* 2000;42:43-46.
- Zhang LL, Yang R, Zhang L, et al. Dentigerous cyst: a retrospective clinicopathological analysis of 2082 dentigerous cysts in British Columbia, Canada. *Int J Oral Maxillofac Surg.* 2010;39:878-882.

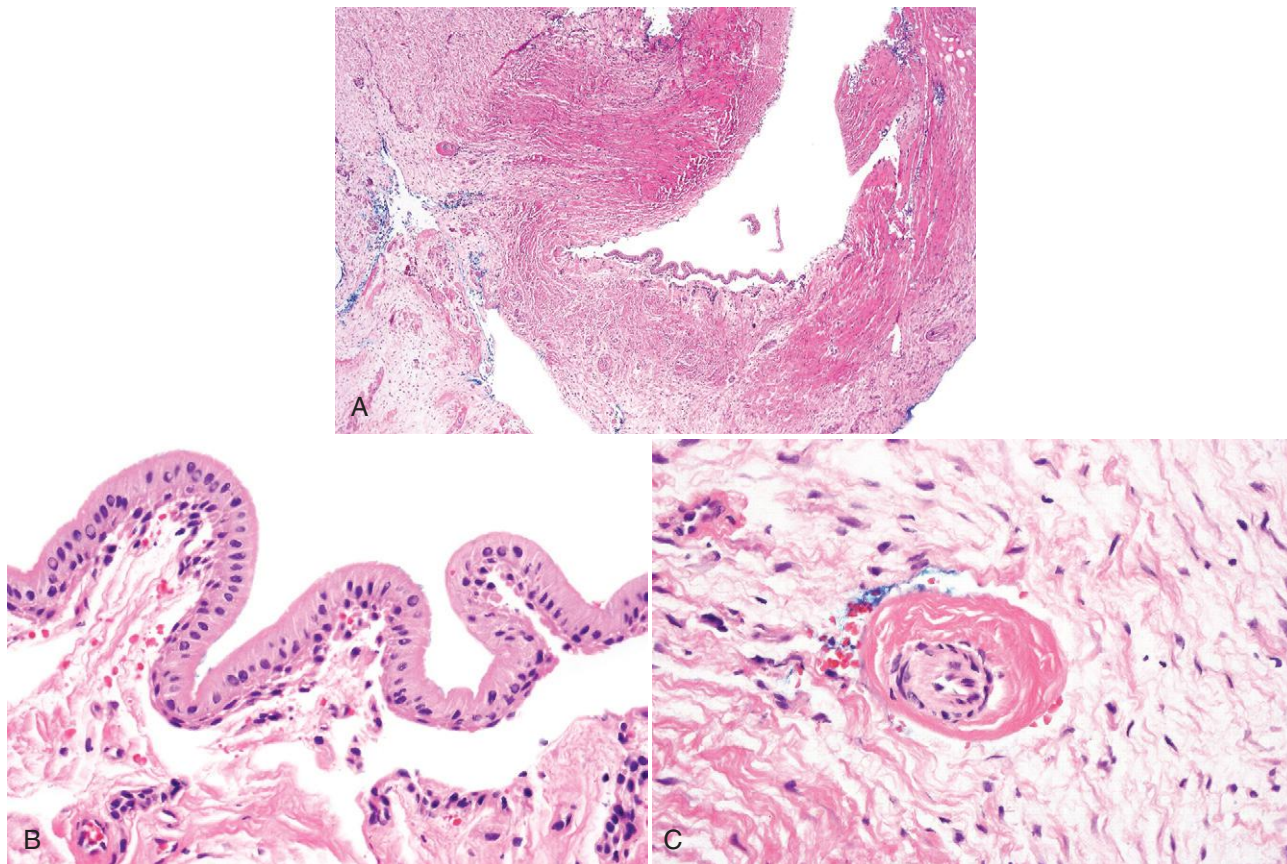


**FIGURE 14-18.** Dentigerous cyst. **A**, Panoramic radiograph showing unilocular radiolucency around impacted lower left third molar. **B**, Panoramic radiograph showing unilocular radiolucency around retained left mandibular premolar. **C**, Gross specimen consisting of hemorrhagic cystic sac. (**A** and **B**, Courtesy of Dr. Thomas Dodson, Harvard School of Dental Medicine, Boston, Mass; **C**, Courtesy of Dr. Bonnie Padwa, Harvard School of Dental Medicine, Boston, Mass.)



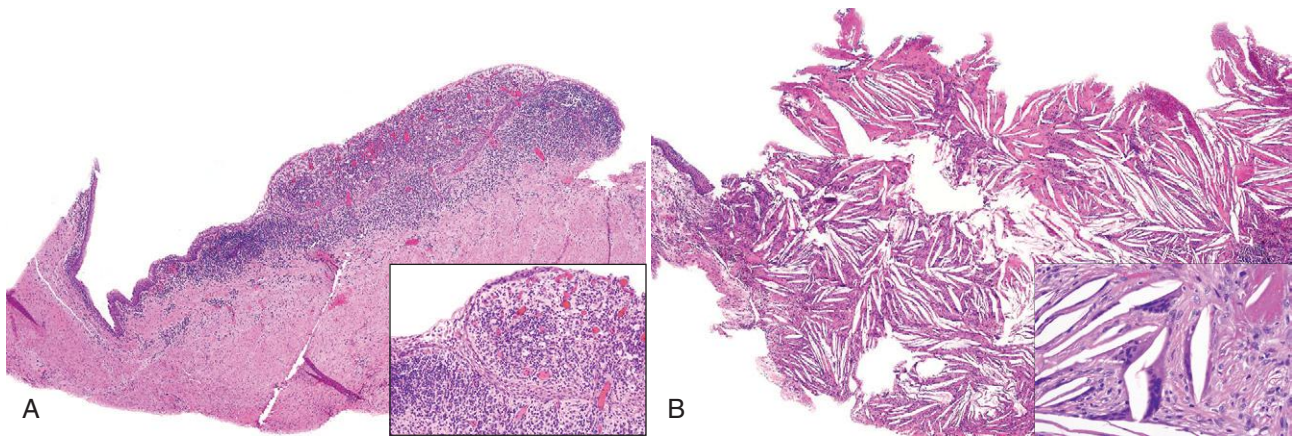


**FIGURE 14-19.** Dentigerous cyst. **A**, Cyst lined by uniformly thin epithelium with little mural inflammation. **B**, Lining is nonkeratinized stratified squamous epithelium.

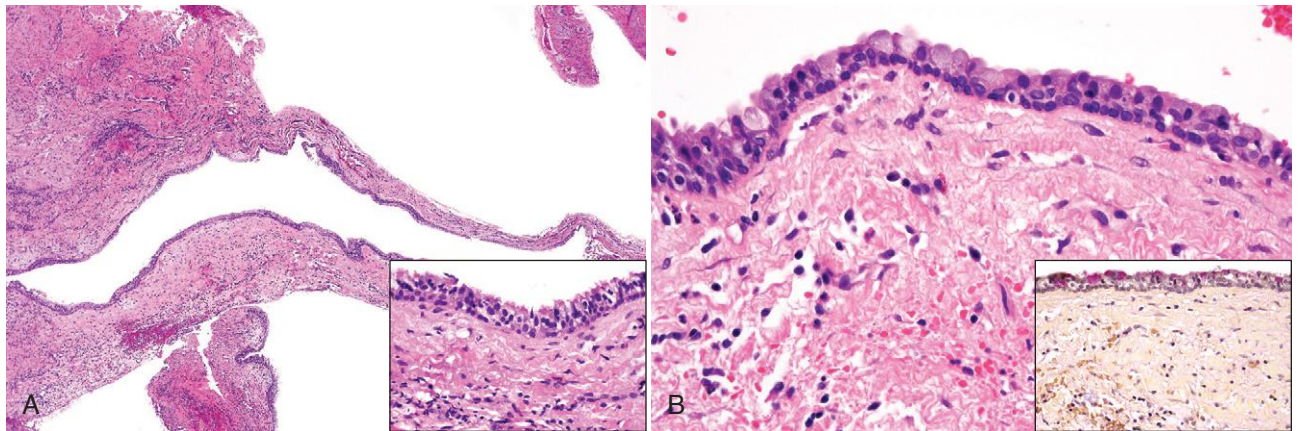


**FIGURE 14-20.** Hyperplastic dental follicle. **A**, Follicle is lined by thin epithelium. **B**, Reduced enamel epithelium has luminal columnar cells and low cuboidal basal cells. **C**, Perivascular hyalinization occurs frequently.

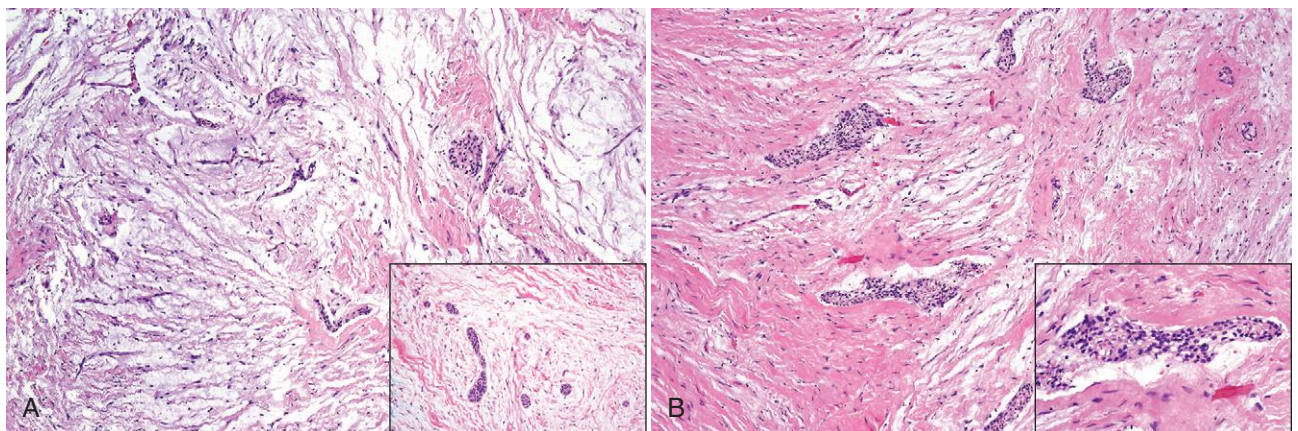




**FIGURE 14-21.** Dentigerous cyst. **A**, Cyst showing epithelial proliferation when inflamed (*inset*). **B**, Cholesterol granulomas associated with multinucleated giant cells often at areas of epithelial disruption (*inset*); intact epithelium at left (*inset*).

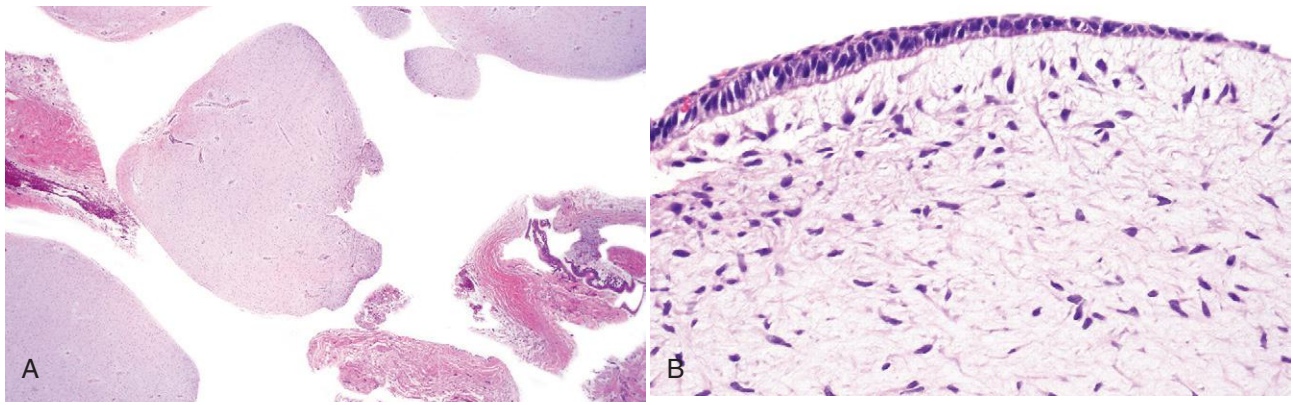


**FIGURE 14-22.** Dentigerous cyst. **A**, Uniformly thin epithelium composed of columnar, mucous, and ciliated cells (*inset*). **B**, Mucous cells confirmed with mucicarmine stain (*inset*).

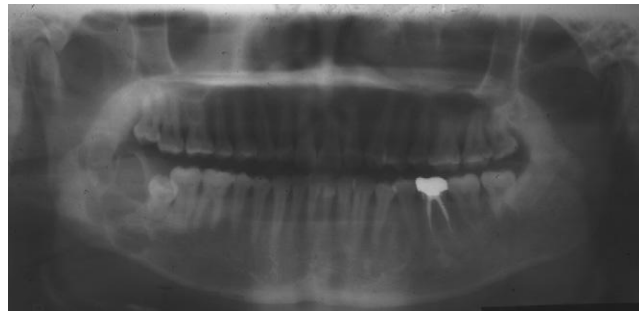

**FIGURE 14-23.** Dental follicle. **A**, Delicately collagenized tissue and myxoid stroma with odontogenic rests (*inset*). **B**, Periepithelial hyalinization and rests with clear cells (*inset*).

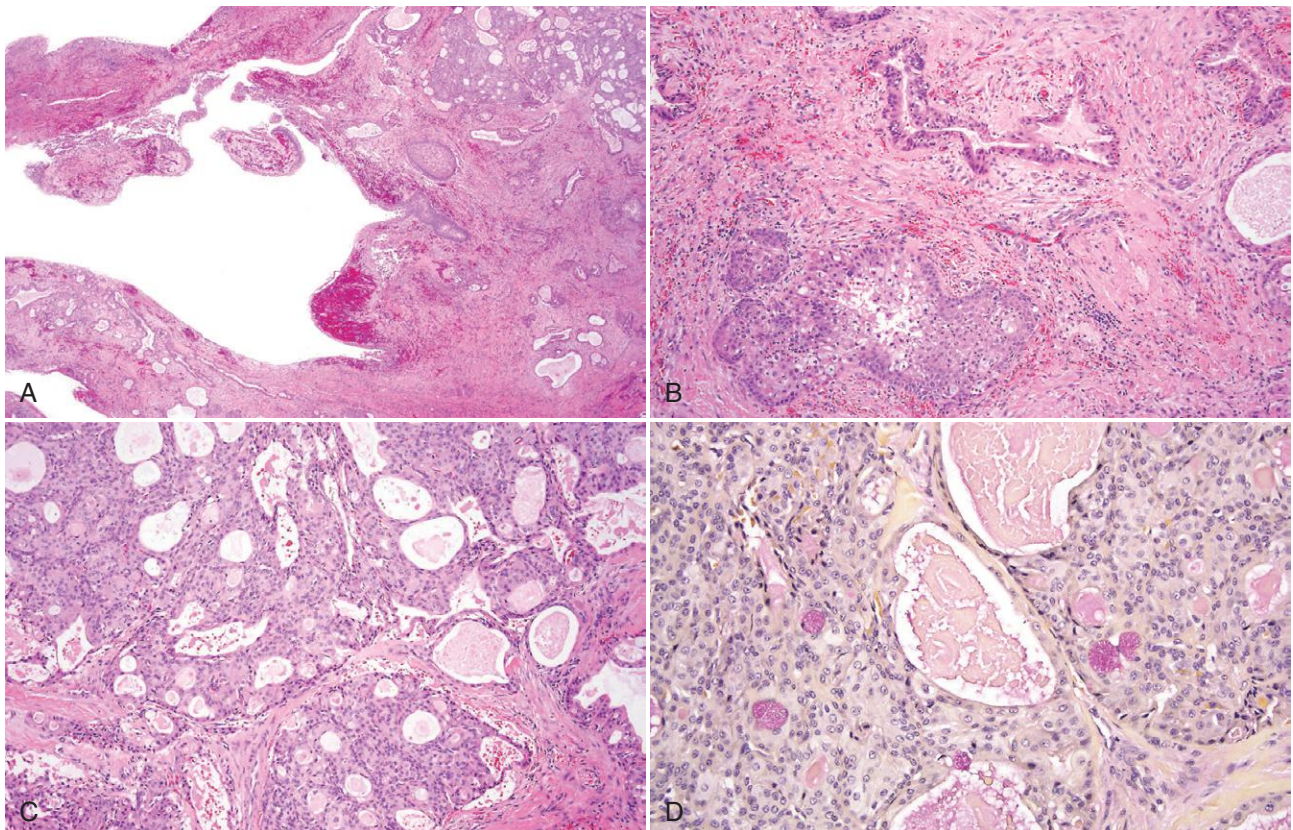




**FIGURE 14-24.** Dental papilla. **A**, Rounded fragments of primitive myxoid tissue; note dentigerous cyst lining and follicle on the *right*. **B**, Papilla is myxoid with plump, stellate fibroblasts, rimmed by a layer of columnar odontoblasts.

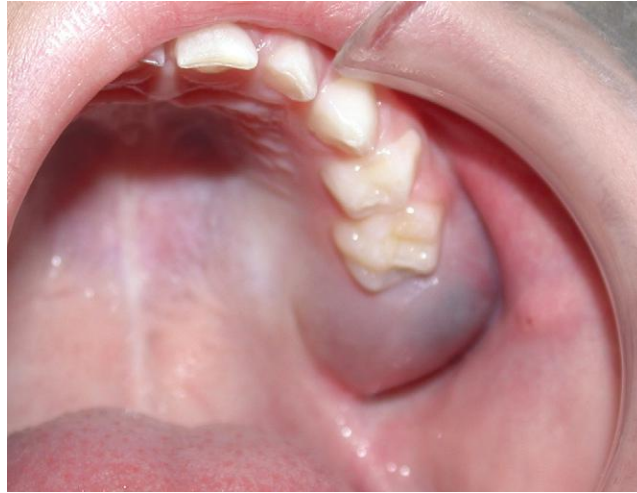

**FIGURE 14-25.** Mucoepidermoid carcinoma arising within a dentigerous cyst: panoramic radiograph shows a multiloculated radiolucency around impacted right mandibular third molar.



**FIGURE 14-26.** Mucoepidermoid carcinoma arising within a dentigerous cyst. **A**, Infiltrative islands of tumor cells adjacent to a portion of the cyst lining. **B**, Island of tumor cells adjacent to portion of a cyst lining exhibiting mucous cell metaplasia. **C**, Tumor consists of epidermoid, mucous, and intermediate cells with duct formation. **D**, Mucicarmine stain confirms presence of mucous cells.





**FIGURE 14-27.** Eruption cyst overlying erupting left maxillary first permanent molar. (Courtesy of Dr. Bonnie Padwa, Harvard School of Dental Medicine, Boston, Mass.)

## LATERAL PERIODONTAL CYST

### Clinical Findings

- Unilocular radiolucency is evident between two teeth that are vital; most common location is between the premolars, followed by the canine-lateral area (Fig. 14-28); rare cases are multifocal.
- Multiloculated radiolucency in the same locations may represent botryoid odontogenic cyst; mandible is involved in 80% of cases.

### Etiopathogenesis and Histopathologic Features

Epithelium is derived from rests of dental lamina.

- Epithelium is uniformly three to eight cells thick and composed of nonkeratinized stratified squamous or low cuboidal cells, with epithelial plaques composed of clear cells that contain glycogen and may have a swirling, whorled morphology (Figs. 14-29 and 14-30).
- Multilocular variant is botryoid odontogenic cyst (Fig. 14-31).

### Management and Prognosis

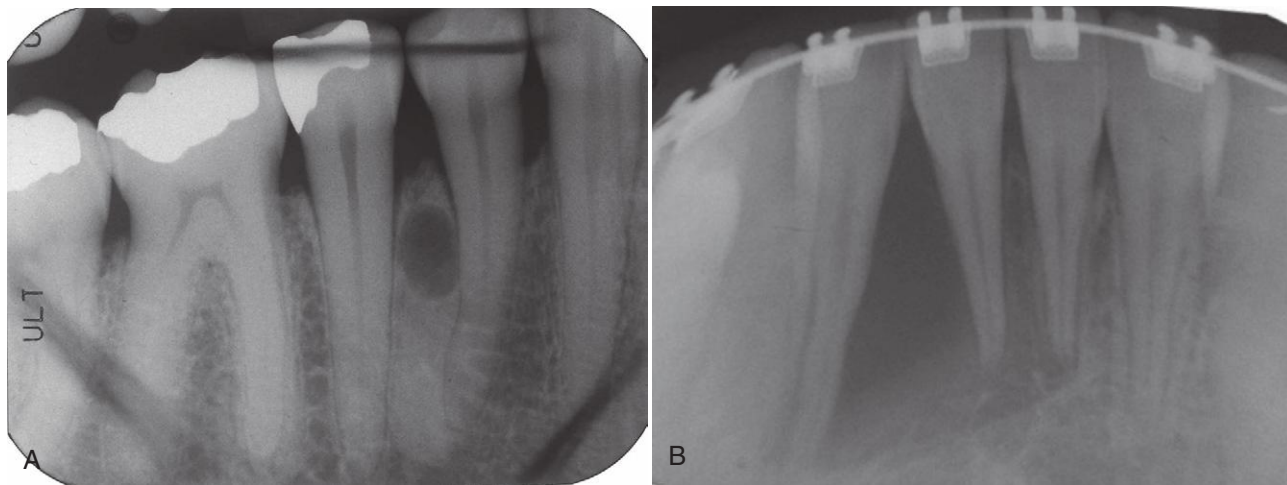
- Enucleation or curettage is curative for the conventional lateral periodontal cyst.

- Botryoid odontogenic cyst recurs in as many as 18% to 30% of cases, especially if multiloculated radiographically.

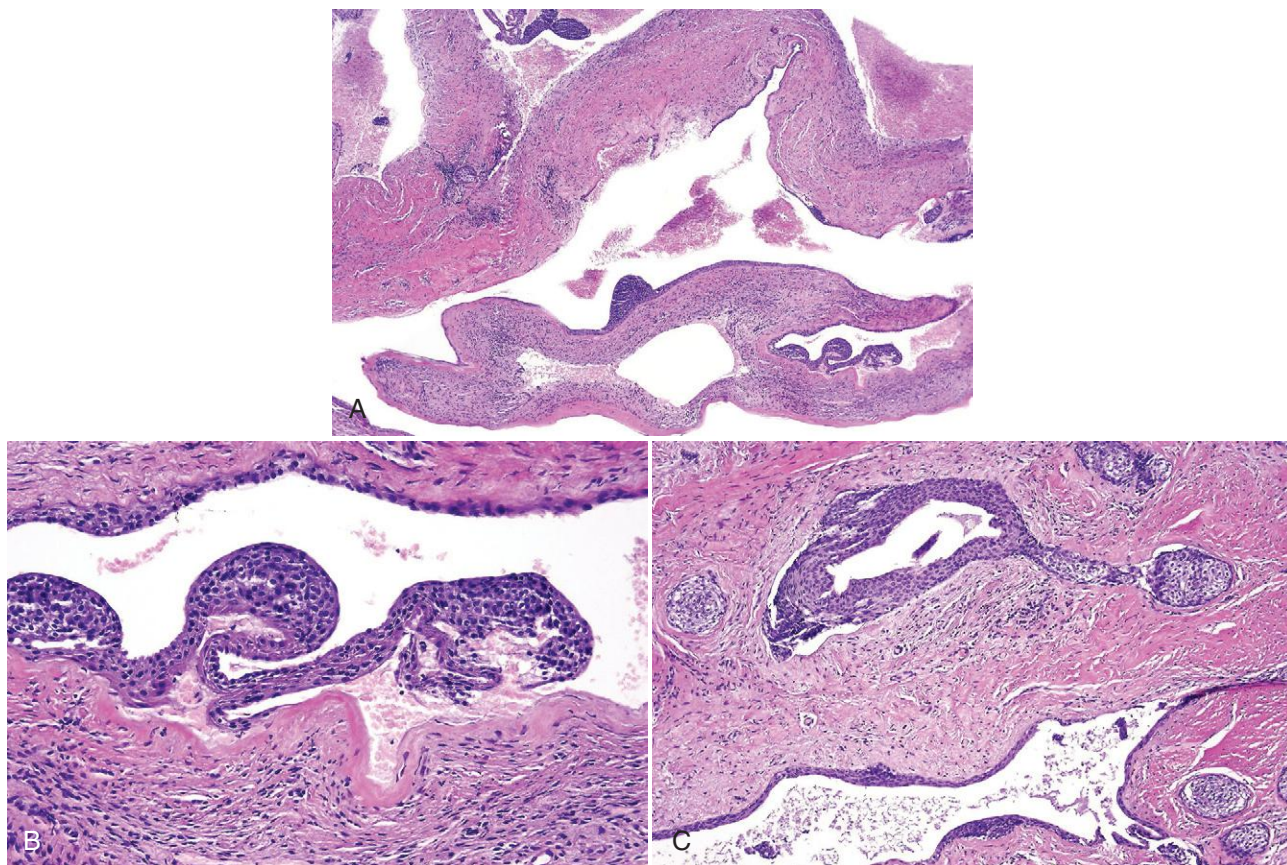
### REFERENCES

- Carter LC, Carney YL, Perez-Pudlewski D. Lateral periodontal cyst. Multifactorial analysis of a previously unreported series. *Oral Surg Oral Med Oral Pathol Oral Radiol Endod.* 1996;81:210-216.
- Cohen DA, Neville BW, Damm DD, White DK. The lateral periodontal cyst. A report of 37 cases. *J Periodontol.* 1984;55:230-234.
- Greer RO Jr, Johnson M. Botryoid odontogenic cyst: clinicopathologic analysis of ten cases with three recurrences. *J Oral Maxillofac Surg.* 1988;46:574-579.
- Gurol M, Burkes EJ Jr, Jacoway J. Botryoid odontogenic cyst: analysis of 33 cases. *J Periodontol.* 1995;66:1069-1073.
- Mendez P, Junquera L, Gallego L, Baladron J. Botryoid odontogenic cyst: clinical and pathological analysis in relation to recurrence. *Med Oral Patol Oral Cir Bucal.* 2007;12:E594-E598.
- Rasmusson LG, Magnusson BC, Borrmann H. The lateral periodontal cyst. A histopathological and radiographic study of 32 cases. *Br J Oral Maxillofac Surg.* 1991;29:54-57.
- Santos PP, Freitas VS, Freitas Bde A, et al. Botryoid odontogenic cyst: a clinicopathologic study of 10 cases. *Ann Diagn Pathol.* 2011;15:221-224.
- Siponen M, Neville BW, Damm DD, Allen CM. Multifocal lateral periodontal cysts: a report of 4 cases and review of the literature. *Oral Surg Oral Med Oral Pathol Endod.* 2011;111:225-233.



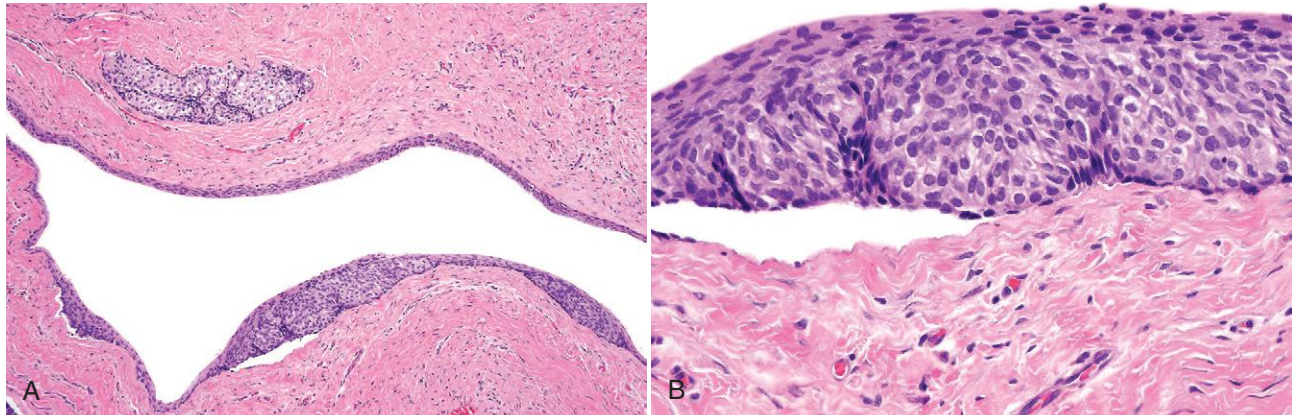


**FIGURE 14-28.** Lateral periodontal cyst. **A**, Well-defined radiolucency between the right vital mandibular premolars. **B**, Poorly defined radiolucency between the mandibular central incisors. (**A**, Courtesy of Dr. Amy Field, private practice, Lowell, Mass.)

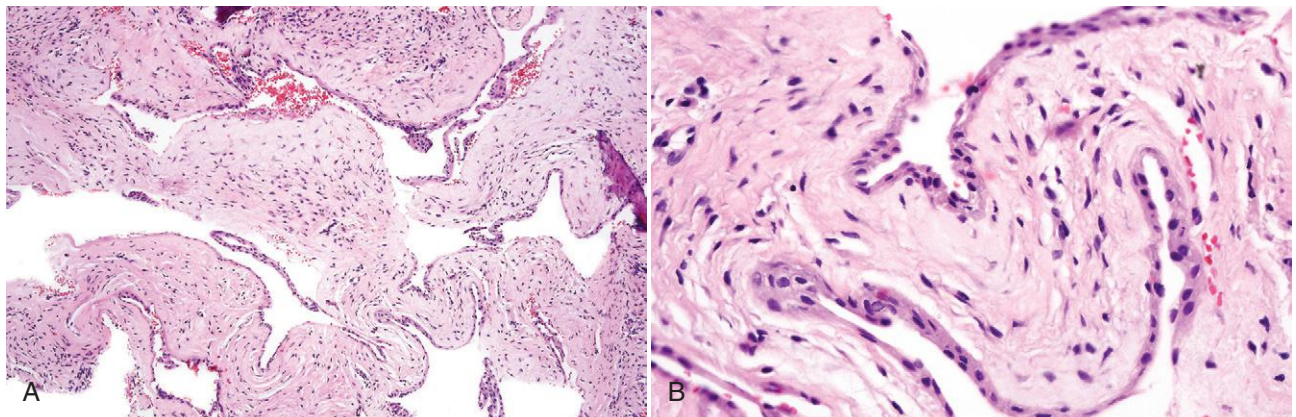


**FIGURE 14-29.** Lateral periodontal cyst. **A**, Cyst with uniformly thin lining and epithelial plaques. **B**, Epithelial plaques protrude into the lumen; lining epithelium is uniformly three to five cells thick, and basement membrane is thickened. **C**, Dental lamina rests composed of clear cells in the vicinity of the cyst.





**FIGURE 14-30.** Lateral periodontal cyst. **A**, Uniformly thin lining with epithelial plaques and odontogenic rest composed of clear cells. **B**, Epithelial plaque contains clear cells.



**FIGURE 14-31.** Botryoid odontogenic cyst. **A**, Multiple cysts lined by thin epithelium. **B**, Uniformly thin lining of low cuboidal cells with foci of clear cells.

## ORTHOKERATINIZED ODONTOGENIC CYST

This cyst is not to be confused with the keratocystic odontogenic tumor (odontogenic keratocyst) (see Chapter 15).

### Clinical Features

- Most common in third and fourth decades, with 3:1 male predilection; unilocular radiolucency in the posterior mandible/ramus (90%), one half of cases associated with impacted tooth (Fig. 14-32); no association with nevoid basal cell carcinoma syndrome

### Etiopathogenesis and Histopathologic Features

Cyst likely arises from dental lamina rests and resembles epithelial inclusion (epidermoid) cyst (see Chapter 2).

- Uniformly 5 to 15 cells thick with orthokeratin and granular layer; no palisading of basal cell nuclei and flat interface without inflammation; keratinaceous material in lumen; no satellite cysts in wall (Fig. 14-33); Ki-67 confined to scattered cells in the basal layer and p63 to basal and suprabasilar cells

### Differential Diagnosis

- If parakeratin is present even focally, a diagnosis of keratocystic odontogenic tumor (odontogenic keratocyst) must be made.

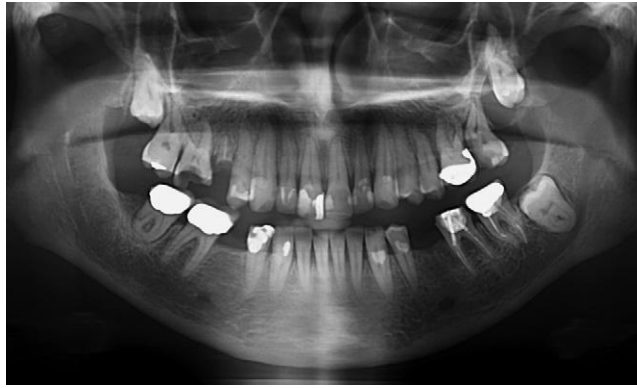### Management and Prognosis

- Excision or curettage is curative; recurrence rate is insignificant.

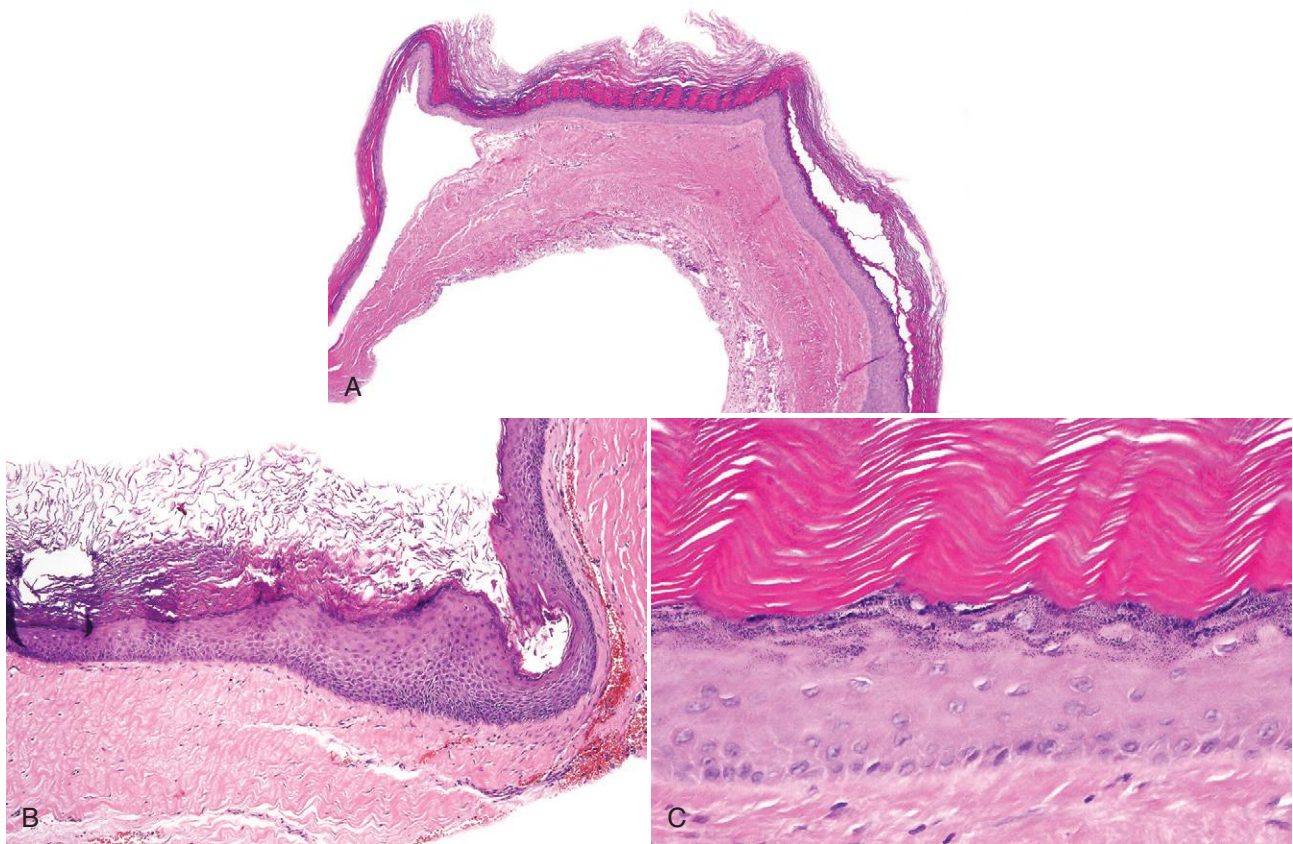
### REFERENCES

Crowley TE, Kaugars GE, Gunsolley JC. Odontogenic keratocysts: a clinical and histologic comparison of the parakeratin and orthokeratin variants. *J Oral Maxillofac Surg.* 1992;50:22-26.  
 Dong Q, Pan S, Sun LS, Li TJ. Orthokeratinized odontogenic cyst: a clinicopathologic study of 61 cases. *Arch Pathol Lab Med.* 2010; 134:271-275.  
 Siar CH, Ng KH. Orthokeratinised odontogenic keratocysts in Malaysians. *Br J Oral Maxillofac Surg.* 1988;26:215-220.  
 Vuhahula E, Nikai H, Ijuhin N, et al. Jaw cysts with orthokeratinization: analysis of 12 cases. *J Oral Pathol Med.* 1993;22:35-40.  
 Wright JM. The odontogenic keratocyst: orthokeratinized variant. *Oral Surg Oral Med Oral Pathol.* 1981;51:609-618.





**FIGURE 14-32.** Orthokeratinized odontogenic cyst associated with impacted left maxillary third molar.



**FIGURE 14-33.** Orthokeratinized odontogenic cyst. **A**, Cyst lined by thickly orthokeratinized epithelium of variable thickness with no inflammation. **B**, Epithelium is orthokeratinized with granular layer. **C**, Basal cells do not show palisading of nuclei.



## ODONTOGENIC CYST IN A GLOBULOMAXILLARY LOCATION

This cyst once was classified as a fissural cyst but has been reclassified as an odontogenic cyst because there is no fusion of fissures in this area, but rather erasure of the fissure by ectomesenchyme.

### Clinical Findings

- Pear-shaped radiolucency is evident between the canine and maxillary lateral incisor.

### Etiopathogenesis and Histopathologic Features

Two pieces of evidence that support an odontogenic origin are that approximately 10% are keratocystic odontogenic tumor (odontogenic keratocyst), and Rushton bodies are sometimes noted—two features not seen in fissural cysts. They may also histologically be radicular cysts, lateral periodontal cysts, or other developmental odontogenic cyst. It could even represent a lateral dentigerous cyst from the maxillary canine, which tends to erupt late, is often impacted and is often associated with a conventional dentigerous cyst. The

current practice is to identify the cyst specifically as one of the aforementioned entities, rather than use the term *globulomaxillary cyst*.

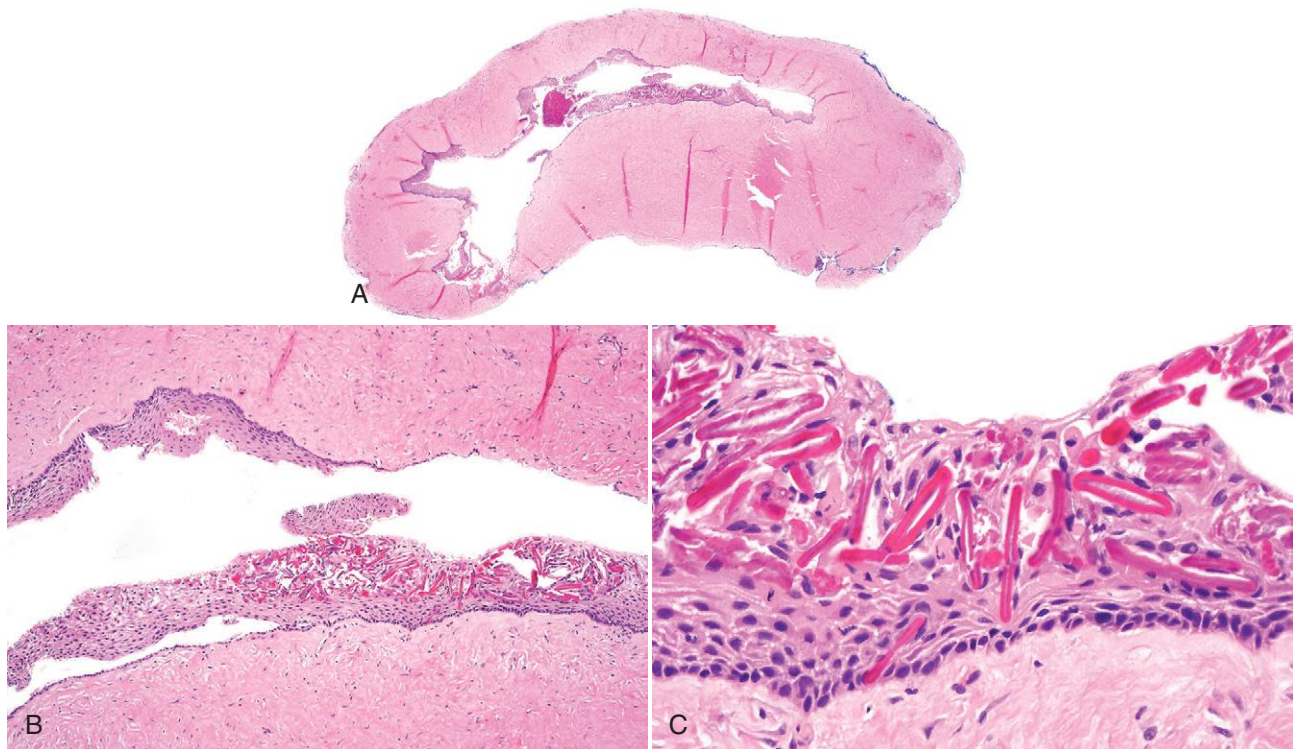
- Nondescript nonkeratinized stratified squamous epithelium of variable thickness; inflammation may be present; presence of Rushton bodies confirms odontogenic origin (Fig. 14-34); keratocystic odontogenic tumor (odontogenic keratocyst) must be reported as such.

### Management and Prognosis

- Excision is curative.

### REFERENCES

- Brannon RB. The odontogenic keratocyst. A clinicopathologic study of 312 cases. Part I. Clinical features. *Oral Surg Oral Med Oral Pathol.* 1976;42:54-72.
- D'Silva NJ, Anderson L. Globulomaxillary cyst revisited. *Oral Surg Oral Med Oral Pathol.* 1993;76:182-184.
- Neville BW, Damm DD, Allen CM, Bouquot J. *Oral and Maxillofacial Pathology.* 5th ed. Philadelphia, Saunders; 2009.
- Wysocki GP, Goldblatt LI. The so-called "globulomaxillary cyst" is extinct. *Oral Surg Oral Med Oral Pathol.* 1993;76:185-186.



**FIGURE 14-34.** Developmental odontogenic cyst. **A**, Cyst lined by uniformly thin epithelium with no mural inflammation; this is likely a lateral dentigerous cyst. **B**, Uniformly thin lining epithelium with Rushton bodies. **C**, Rushton bodies composed of brightly eosinophilic lamellar structures.



## PRIMORDIAL CYST

### Clinical Features

- Unilocular radiolucency that develops in place of a tooth (may be a supernumerary such as a mesiodens that occurs in the midline of the maxilla)

### Etiopathogenesis and Histopathologic Features

Epithelium is derived from degeneration of the enamel organ without formation of a tooth.

- Epithelium is nondescript nonkeratinized stratified squamous and generally 5 to 10 layers thick; mucous and ciliated cells may be present if an impacted tooth had been extracted from the same area.
- Approximately 45% to 50% of primordial cysts are keratocystic odontogenic tumor (odontogenic keratocyst), but these two terms should not be used interchangeably.

### Differential Diagnosis

- Residual dentigerous cyst should be considered if an impacted tooth had been extracted from the same area.

### Management and Prognosis

- Enucleation or complete curettage is curative for cysts lined by nonkeratinized epithelium (see [Chapter 15](#) for management of keratocystic odontogenic tumor [odontogenic keratocyst]).

### REFERENCES

- Brannon RB. The odontogenic keratocyst. A clinicopathologic study of 312 cases. Part I. Clinical features. *Oral Surg Oral Med Oral Pathol.* 1976;42:54-72.
- Neville BW, Damm DD, Allen CM, Bouquot J. *Oral and Maxillofacial Pathology.* 5th ed. Philadelphia, Saunders; 2009.

## GLANDULAR ODONTOGENIC CYST

Lesion may represent a cystic neoplasm because of its locally aggressive behavior and high recurrence rate, but at this time, it is still classified as a cyst.

### Clinical Findings

- Uniloculated or multiloculated radiolucency is seen in adults in the fifth to seventh decade; lesions occur more often in the mandible (80%) and cause jaw expansion; 60% of lesions involve anterior portions of the jaws, and multiloculated lesions tend to be larger; lesions are associated with tooth displacement or root resorption (25%-50%), or impacted tooth (11%) ([Fig. 14-35](#)); cortex perforation is seen in 60% of cases.

### Etiopathogenesis and Histopathologic Features

Lesion likely arises from rests of dental lamina.

- Lined by nonkeratinized stratified squamous or basaloid epithelium with scattered mucous cells and ductlike or microcystic structures; parts of the cyst may be lined by nondescript, uniformly thin epithelium

([Figs. 14-36, A-C](#)); multiple cystic compartments usually are present, and luminal cells and cells forming ducts are cuboidal with eosinophilic cytoplasm and often show evidence of secretory activity and “snouting” (see [Fig. 14-36, D](#)); epithelial plaques and clear cells often present; focal islands resembling mucoepidermoid carcinoma of unknown significance may be present.

- Lesion is positive for CK5/6 and CK7, and there is variable staining for calponin; lesion is negative for S-100 and SMA.

### Differential Diagnosis

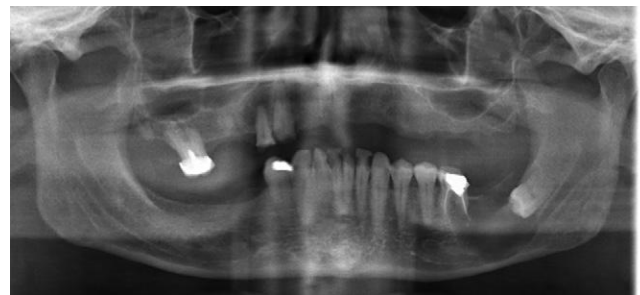- Dentigerous cyst may show mucous cell metaplasia and ductlike structures focally ([Fig. 14-37](#)).
- Mucoepidermoid carcinoma shows invasion of the stroma by large polygonal epidermoid cells, intermediate cells, and mucous cells.
- Cysts with epithelial plaques alone are more likely botryoid odontogenic or lateral periodontal cysts.

### Management and Prognosis

- Peripheral ostectomy, en bloc resection, or marginal resection are the treatments of choice; larger lesions, cortical perforation, and enucleation and curettage are associated with higher rate of recurrence that varies from 14% to 30%.

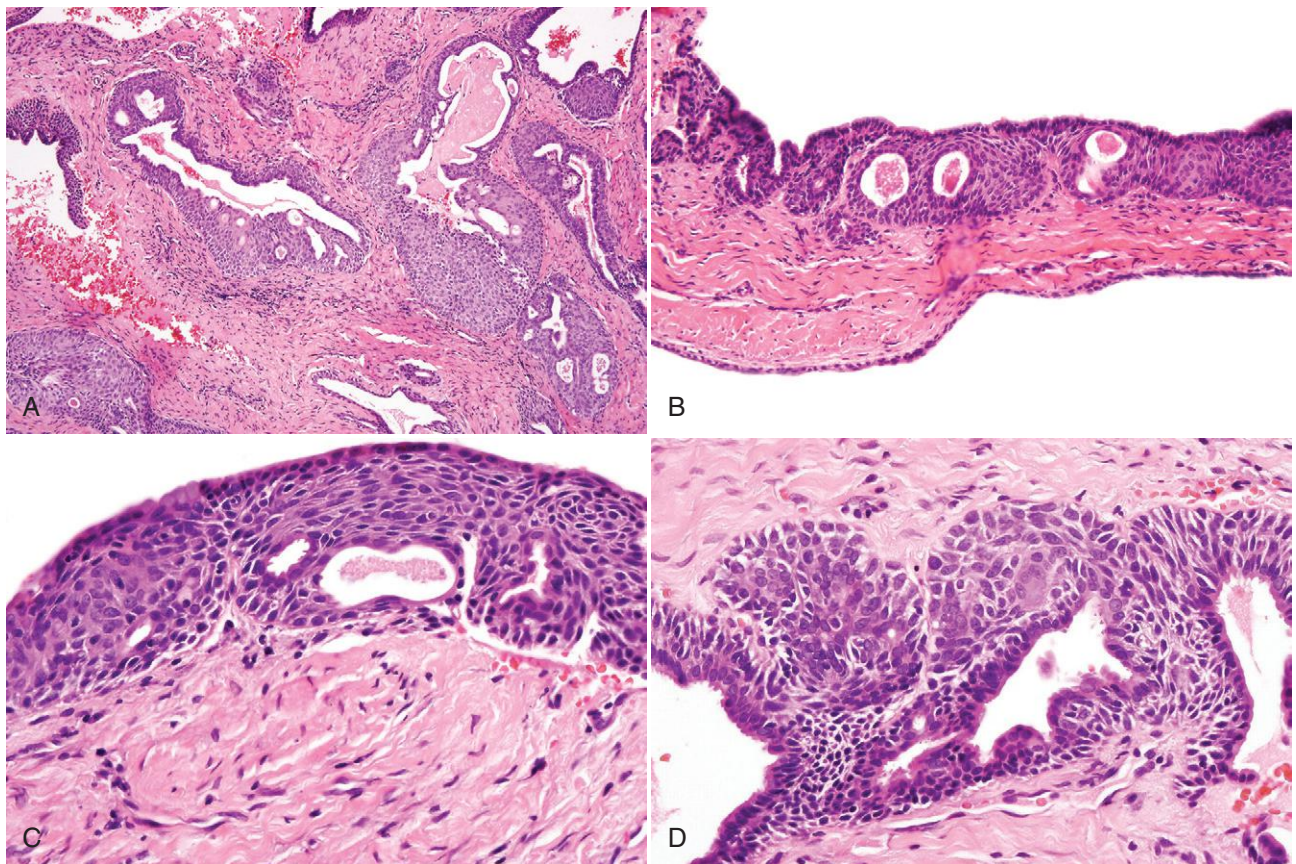
### REFERENCES

- Fowler CB, Brannon RB, Kessler HP, et al. Glandular odontogenic cyst: analysis of 46 cases with special emphasis on microscopic criteria for diagnosis. *Head Neck Pathol.* 2011. Epub ahead of print.
- Gratzinger D, Salama ME, Poh CF, Rouse RV. Ameloblastoma, calcifying epithelial odontogenic tumor, and glandular odontogenic cyst show a distinctive immunophenotype with some myoepithelial antigen expression. *J Oral Pathol Med.* 2008;37:177-184.
- Kaplan I, Gal G, Anavi Y, et al. Glandular odontogenic cyst: treatment and recurrence. *J Oral Maxillofac Surg.* 2005;63:435-441.
- Kaplan I, Anavi Y, Hirshberg A. Glandular odontogenic cyst: a challenge in diagnosis and treatment. *Oral Dis.* 2008;14:575-581.
- Pires FR, Chen SY, da Cruz Perez DE, et al. Cytokeratin expression in central mucoepidermoid carcinoma and glandular odontogenic cyst. *Oral Oncol.* 2004;40:545-551.
- Vered M, Allon I, Buchner A, Dayan D. Is maspin immunolocalization a tool to differentiate central low-grade mucoepidermoid carcinoma from glandular odontogenic cyst? *Acta Histochem.* 2010;112:161-168.

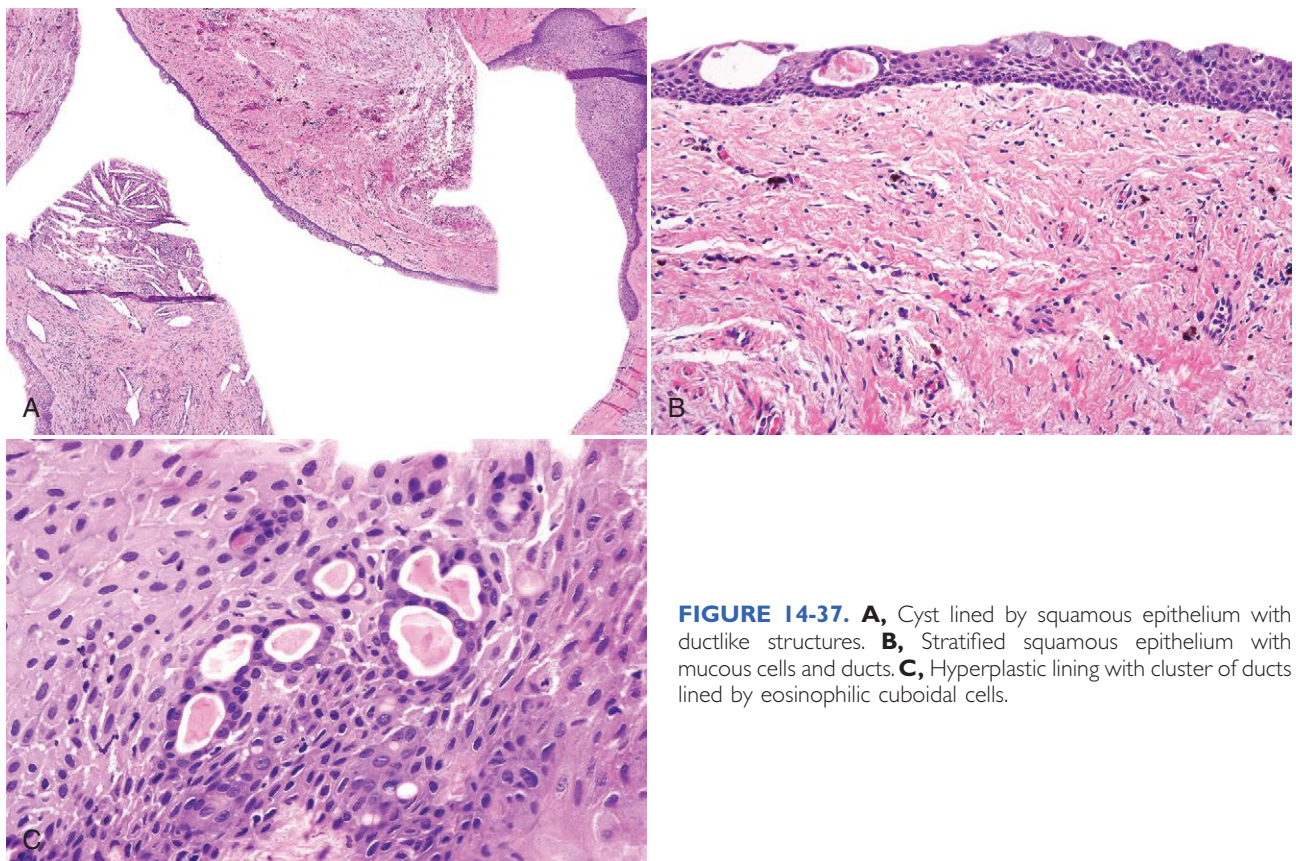


**FIGURE 14-35.** Glandular odontogenic cyst: unilocular radiolucency around impacted left mandibular third molar. (Courtesy of Dr. Robert Burns, private practice, Melbourne, Fla.)





**FIGURE 14-36.** Glandular odontogenic cyst. **A**, Multiple cystic structures lined by squamous and basaloid cells with ductlike structures. **B**, Simple thin cyst lining (*bottom*) and glandular cyst lining with ducts (*top*). **C**, Ducts lined by eosinophilic cuboidal cells; a few mucous cells are present. **D**, Luminal cells often showing secretory activity and "snouting."



**FIGURE 14-37.** **A**, Cyst lined by squamous epithelium with ductlike structures. **B**, Stratified squamous epithelium with mucous cells and ducts. **C**, Hyperplastic lining with cluster of ducts lined by eosinophilic cuboidal cells.



# 15

## ODONTOGENIC TUMORS

### CHAPTER CONTENTS

EPITHELIAL TUMORS WITHOUT ECTOMESENCHYME 340

Keratocystic Odontogenic Tumor (Odontogenic Keratocyst) 340

Ameloblastoma 345

Calcifying Epithelial Odontogenic Tumor (Pindborg Tumor) 351

Adenomatoid Odontogenic Tumor 353

Squamous Odontogenic Tumor 355

Ameloblastic Carcinoma 357

Primary Intraosseous Squamous Cell Carcinoma (Odontogenic) 358

Clear Cell Odontogenic Carcinoma 360

MIXED EPITHELIAL AND ECTOMESENCHYMAL TUMORS 362

Calcifying Cystic Odontogenic Tumor (Calcifying Odontogenic Cyst, Gorlin Cyst) and Dentinogenic Ghost Cell Tumor 362

Ameloblastic Fibroma 365

Ameloblastic Fibro-odontoma 368

Odontoma 370

MESENCHYMAL TUMORS 373

Central Odontogenic Fibroma 373

Odontogenic Myxoma 375

Granular Cell Odontogenic Tumor 377

Cementoblastoma 379

Odontogenic tumors are classified as follows: (1) those that produce mainly epithelium with mature fibrous stroma without ectomesenchyme; (2) those that produce epithelium with ectomesenchyme; and (3) those that produce mainly ectomesenchyme with or without epithelium (usually rests) (Fig. 15-1). Those that produce significant amounts of calcified tissues will contain radiopacities. Some odontogenic neoplasms exhibit histologic patterns of several tumors, and these are called combined, or hybrid odontogenic tumors. Any of these benign neoplasms may have peripheral (extraosseous), as well as malignant, counterparts, and only the more common malignant tumors will be discussed here. Epithelial tumors are likely to derive from rests of dental lamina, and mesenchymal tumors derive from precursor mesenchymal cells that recapitulate formation of the dental papilla, follicle, and osteocementum.

### Epithelial Tumors without Ectomesenchyme

#### KERATOCYSTIC ODONTOGENIC TUMOR (ODONTOGENIC KERATOCYST)

This entity has been reclassified as a cystic neoplasm because of its locally aggressive behavior, high proliferation indices, presence of p53 and p63 in suprabasal cells, and in cases associated with the nevoid basal cell carcinoma syndrome—as well as some sporadic cases—loss of heterozygosity of the tumor suppressor gene *PTCH*, mapped to chromosome 9q22.3-q31.



### Clinical Findings

- Forty percent of sporadic cases occur in the third and fourth decades with 2:1 male predilection.
- Radiolucency may be uniloculated (>80% of cases) or multiloculated, usually in the posterior mandible (70% of cases); one third to one quarter are associated with an impacted tooth; cyst contents are cheesy from keratin (Fig. 15-2, A).
- Nevoid basal cell carcinoma syndrome, an autosomal dominant condition associated with the *PTCH* gene (see Fig. 15-2, B and C), leads to multiple cystic lesions in the jaw; other findings include bifid rib, calcification of the falx cerebri, ovarian fibromas, palmar-plantar pitting, and medulloblastoma; this gene mutation is also seen in nonsyndromic keratocysts.

### Histopathologic Features

- Epithelium is uniformly 5 to 10 cells thick, with parakeratosis, often revealing a corrugated surface and palisading of the basal cell nuclei with a flat interface, sometimes with mild basal cell hyperplasia (Fig. 15-3, A and B); keratinaceous debris fills the lumen; however, if inflammation is present, these typical features are lost or may be subtle or focal; focal areas may be covered by orthokeratin (Fig. 15-4).
- Satellite cysts may be present within the wall and sometimes within the mucosa if the cortical plate is perforated; this may indicate a higher recurrence rate and should be reported (Fig. 15-5).
- High PCNA and Ki-67 indices and positivity for p53 and p63 involving suprabasal cells is seen when compared with other odontogenic cysts (see Fig. 15-3, C and D).
- Cytokeratin (CK)17 and CK19 have been identified in the basal and suprabasal cells and CK4 and CK13 in superficial cells; CK10 is also present.
- Marsupialization of the cyst and flushing with a caustic agent results in loss of the parakeratin layer resulting in nondescript stratified squamous lining.

### Differential Diagnosis

- Cysts lined entirely by orthokeratin do not exhibit palisaded basal cells and represent orthokeratinized odontogenic cysts with a low recurrence rate (see Chapter 14).

- Some basal cell hyperplasia is acceptable and, unless other features of atypia are present, should not be diagnosed as dysplasia.

### Management and Prognosis

- Recurrence rate varies from 10% to 40%, depending on how the tumor is managed; when compared with en bloc resection, enucleation with application of Carnoy's solution, peripheral ostectomy with application of Carnoy's solution, and marsupialization followed by cystectomy do not show significant differences in recurrence rate; curettage is not recommended.

### REFERENCES

- Agaram NP, Collins BM, Barnes L, et al. Molecular analysis to demonstrate that odontogenic keratocysts are neoplastic. *Arch Pathol Lab Med.* 2004;128:313-317.
- Aragaki T, Michi Y, Katsube K, et al. Comprehensive keratin profiling reveals different histopathogenesis of keratocystic odontogenic tumor and orthokeratinized odontogenic cyst. *Hum Pathol.* 2010; 41:1718-1725.
- August M, Faquin WC, Troulis MJ, Kaban LB. Dedifferentiation of odontogenic keratocyst epithelium after cyst decompression. *J Oral Maxillofac Surg.* 2003;61:678-683; discussion 683-684.
- Barnes L, Eveson J, Reichart P, Sidransky D, eds. *Pathology and Genetics of Head and Neck Tumors.* Lyon, France: IARC Press; 2005.
- Blanas N, Freund B, Schwartz M, Furst IM. Systematic review of the treatment and prognosis of the odontogenic keratocyst. *Oral Surg Oral Med Oral Pathol Oral Radiol Endod.* 2000;90:553-558.
- Boffano P, Ruga E, Gallesio C. Keratocystic odontogenic tumor (odontogenic keratocyst): preliminary retrospective review of epidemiologic, clinical, and radiologic features of 261 lesions from University of Turin. *J Oral Maxillofac Surg.* 2010;68:2994-2999.
- Brannon RB. The odontogenic keratocyst. A clinicopathologic study of 312 cases. Part II. Histologic features. *Oral Surg Oral Med Oral Pathol.* 1977;43:233-255.
- Buchner A, Merrell PW, Carpenter WM. Relative frequency of central odontogenic tumors: a study of 1,088 cases from Northern California and comparison to studies from other parts of the world. *J Oral Maxillofac Surg.* 2006;64:1343-1352.
- Gurgel CA, Ramos EA, Azevedo RA, et al. Expression of Ki-67, p53 and p63 proteins in keratocyst odontogenic tumours: an immunohistochemical study. *J Mol Histol.* 2008;39:311-316.
- Henley J, Summerlin DJ, Tomich C, et al. Molecular evidence supporting the neoplastic nature of odontogenic keratocyst: a laser capture microdissection study of 15 cases. *Histopathology.* 2005;47: 582-586.
- Kolar Z, Geierova M, Bouchal J, et al. Immunohistochemical analysis of the biological potential of odontogenic keratocysts. *J Oral Pathol Med.* 2006;35:75-80.
- Lo Muzio L, Santarelli A, Caltabiano R, et al. p63 expression in odontogenic cysts. *Int J Oral Maxillofac Surg.* 2005;34:668-673.



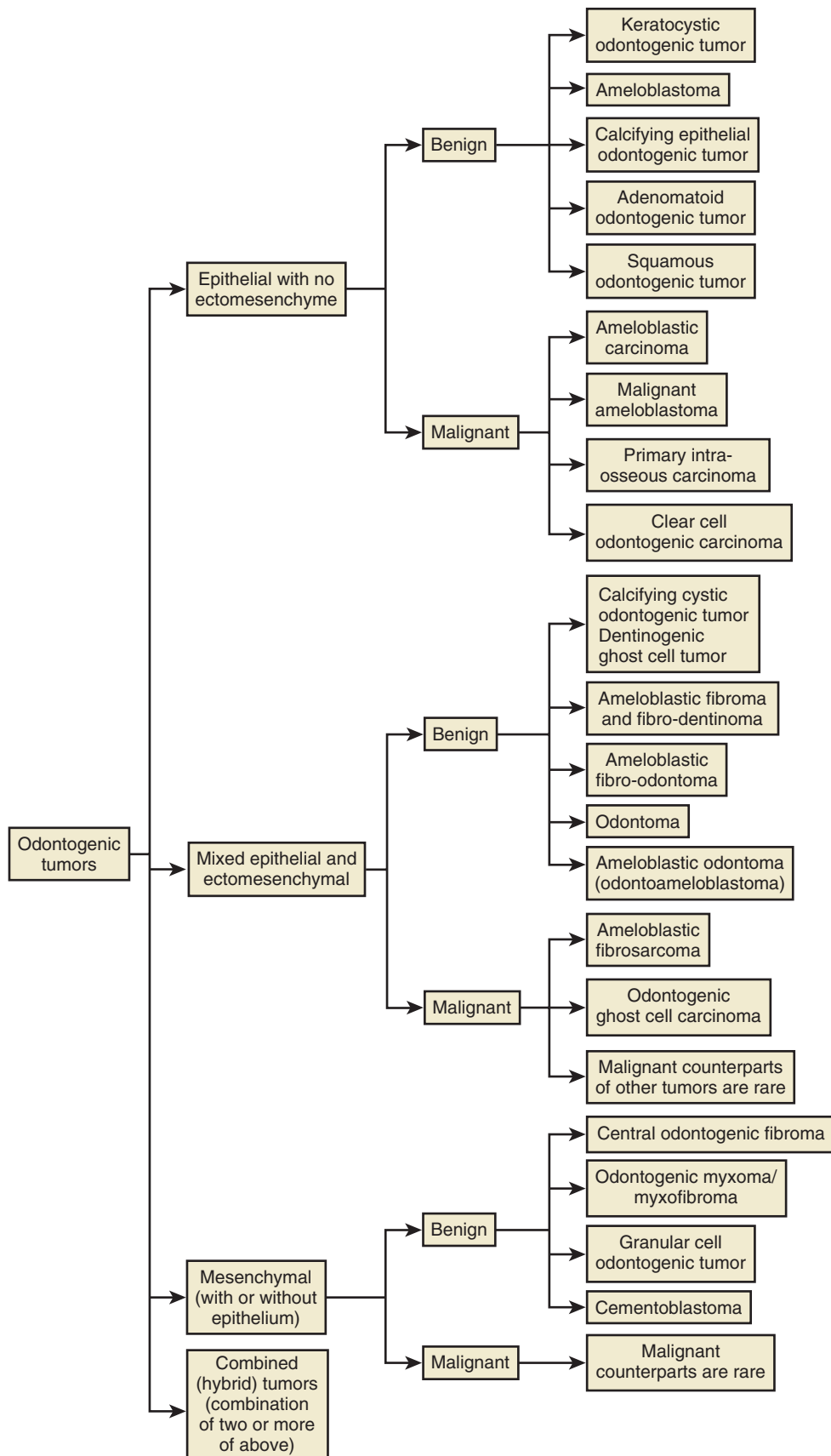
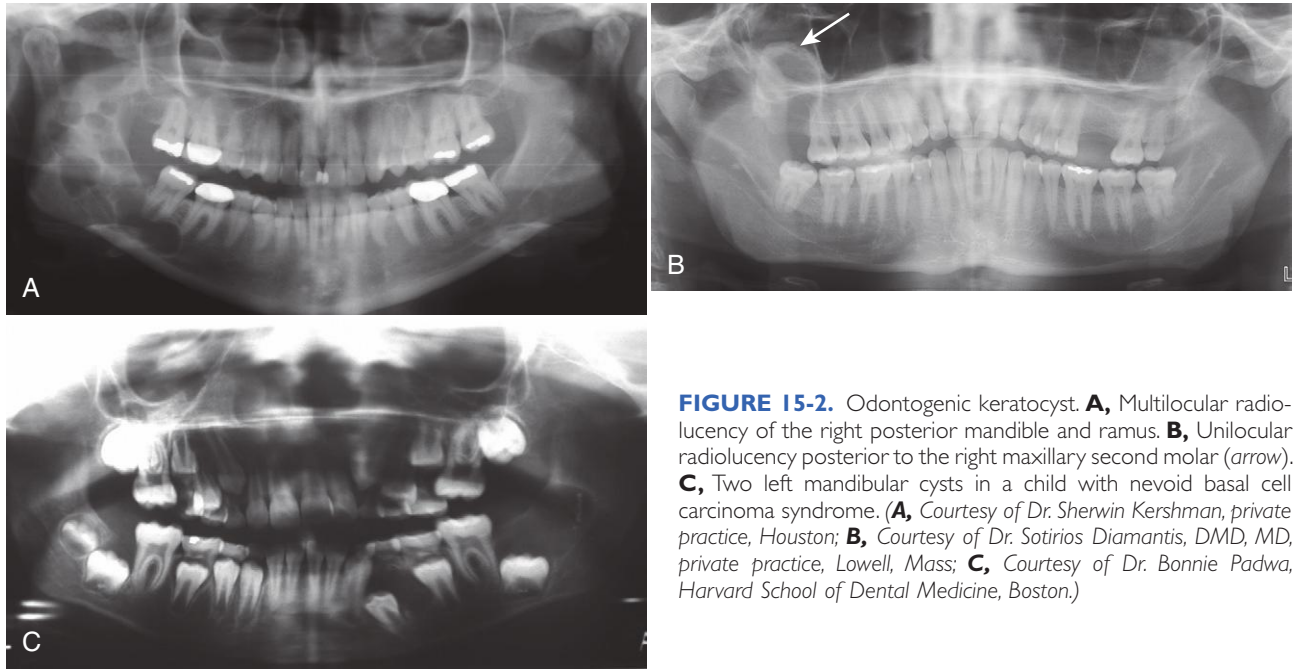
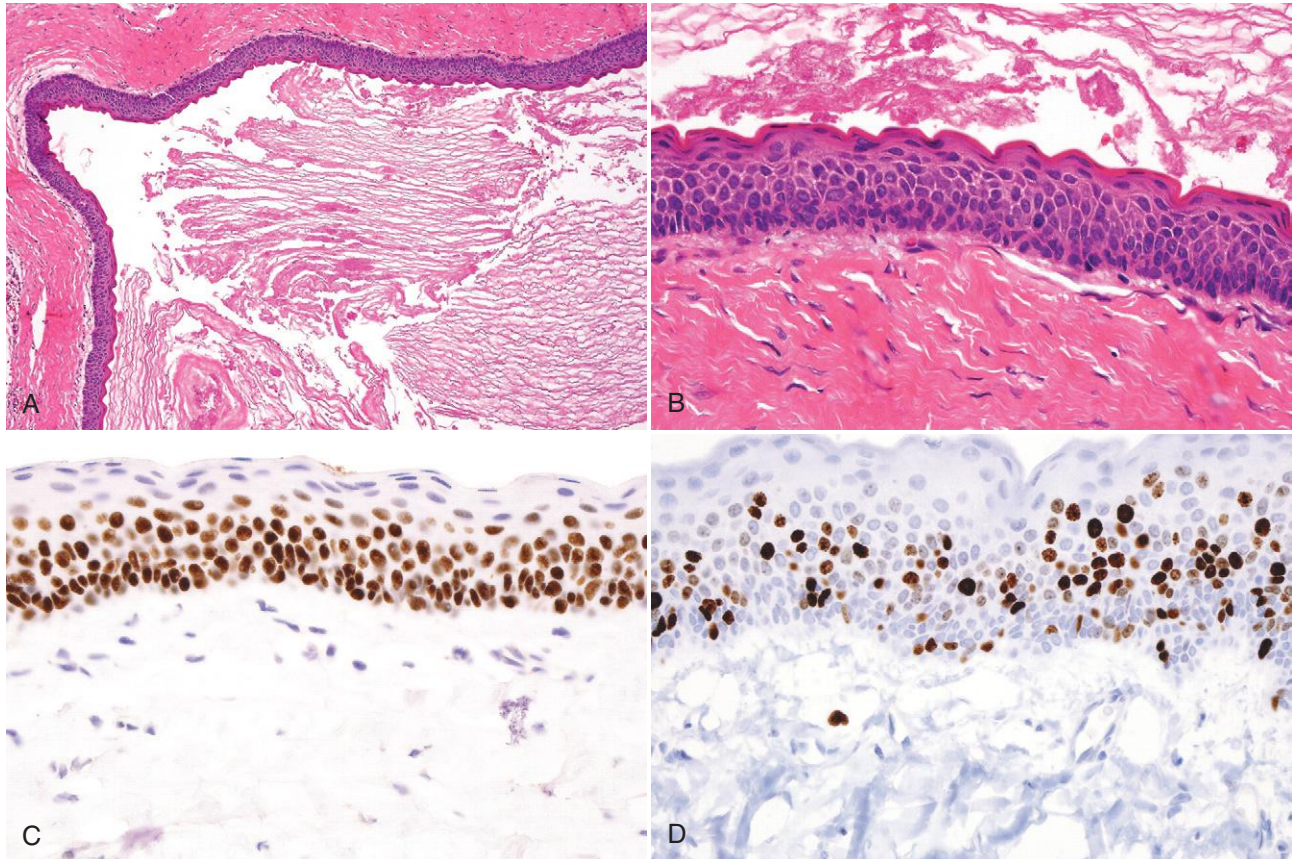


FIGURE 15-1. Classification of odontogenic tumors.



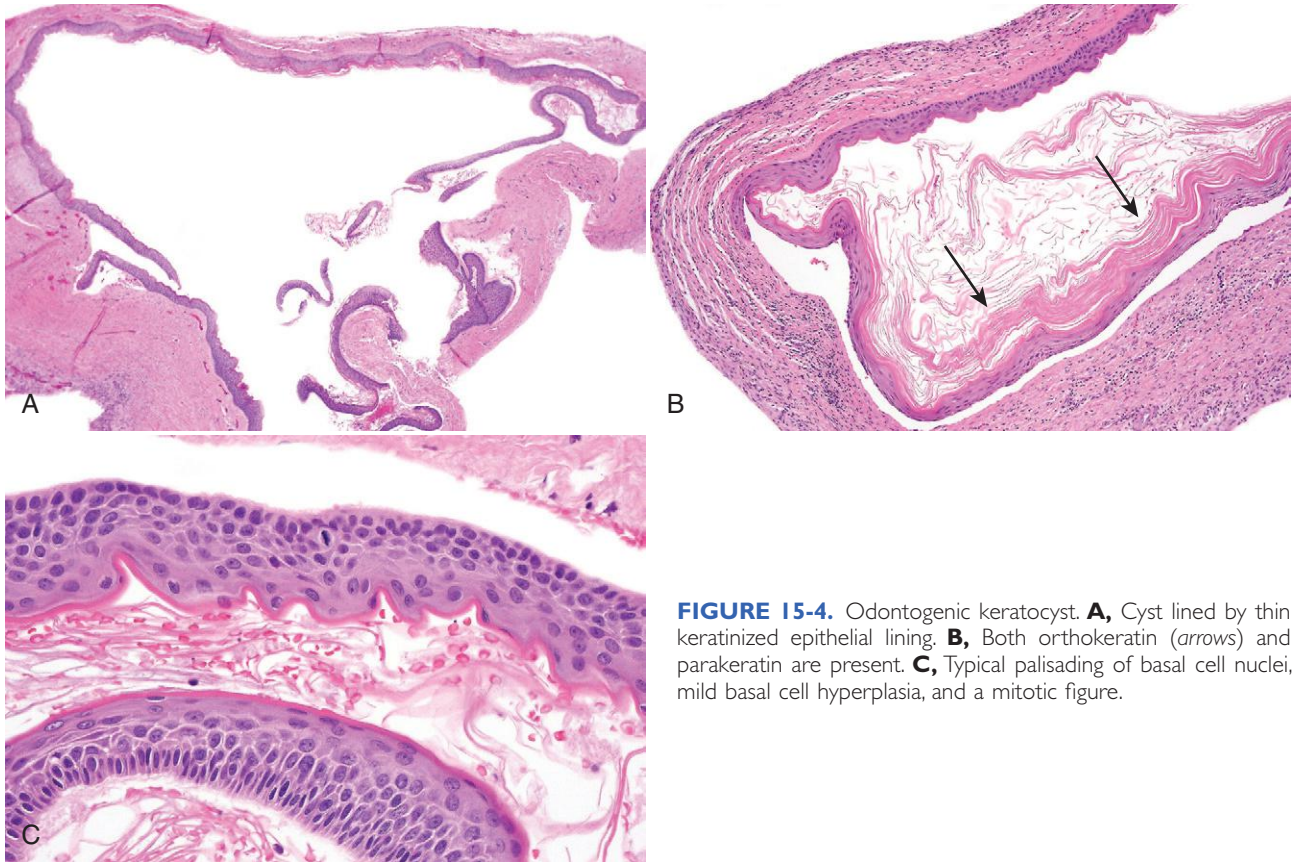


**FIGURE 15-2.** Odontogenic keratocyst. **A**, Multilocular radiolucency of the right posterior mandible and ramus. **B**, Unilocular radiolucency posterior to the right maxillary second molar (*arrow*). **C**, Two left mandibular cysts in a child with nevoid basal cell carcinoma syndrome. (**A**, Courtesy of Dr. Sherwin Kershman, private practice, Houston; **B**, Courtesy of Dr. Sotirios Diamantis, DMD, MD, private practice, Lowell, Mass; **C**, Courtesy of Dr. Bonnie Padwa, Harvard School of Dental Medicine, Boston.)

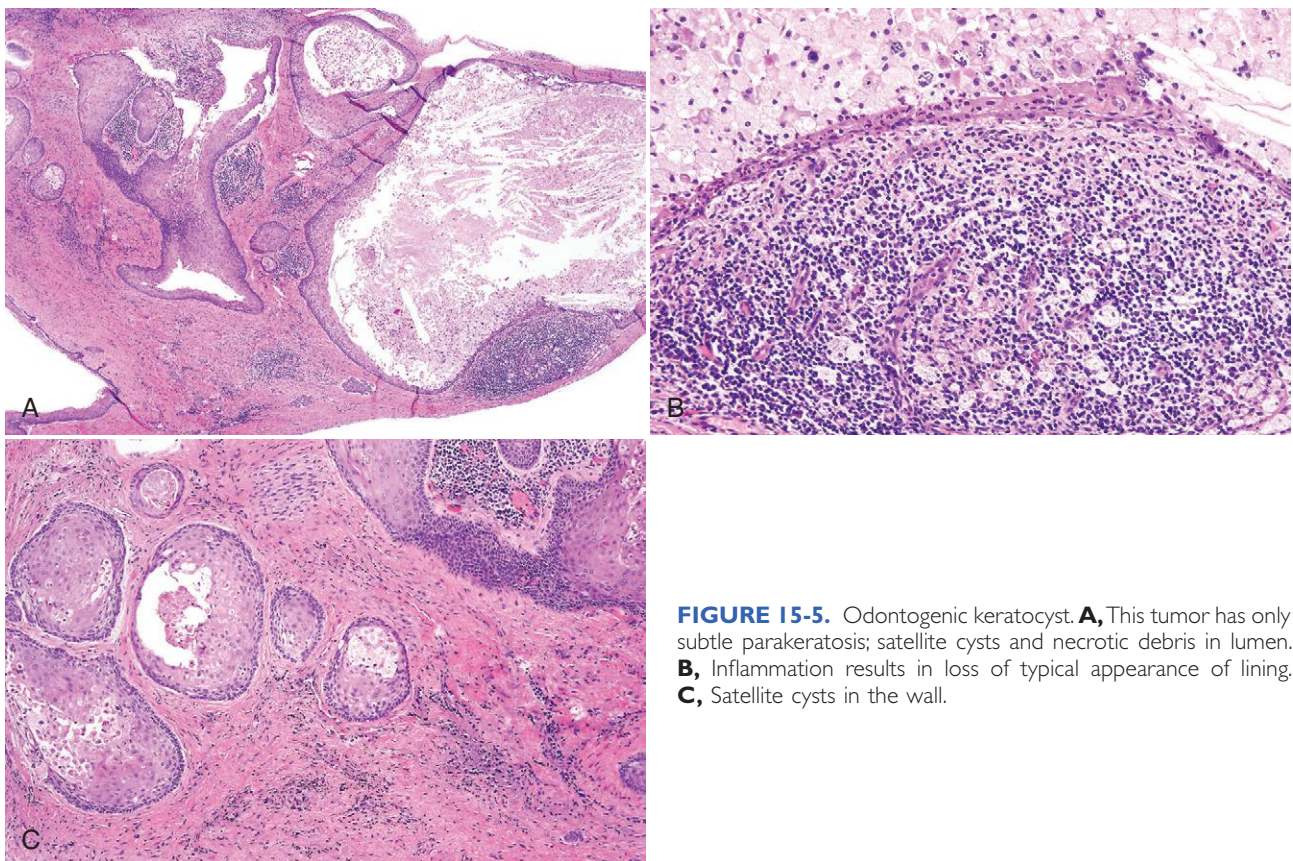


**FIGURE 15-3.** Odontogenic keratocyst. **A**, Cyst lined by uniformly thin epithelium with abundant keratin in lumen. **B**, Lining is 5 to 15 cells thick with parakeratosis, surface corrugations, and palisading of basal cell nuclei. **C**, Strong nuclear staining for p63 of most cells, excluding parakeratin. **D**, Strong nuclear staining for Ki-67 in at least 30% of nuclei scattered throughout the epithelium.





**FIGURE 15-4.** Odontogenic keratocyst. **A**, Cyst lined by thin keratinized epithelial lining. **B**, Both orthokeratin (arrows) and parakeratin are present. **C**, Typical palisading of basal cell nuclei, mild basal cell hyperplasia, and a mitotic figure.



**FIGURE 15-5.** Odontogenic keratocyst. **A**, This tumor has only subtle parakeratosis; satellite cysts and necrotic debris in lumen. **B**, Inflammation results in loss of typical appearance of lining. **C**, Satellite cysts in the wall.



## AMELOBLASTOMA

Central (intraosseous) ameloblastoma, the third most common odontogenic tumor next to keratocystic odontogenic tumor (odontogenic keratocyst) and odontoma, is a locally aggressive neoplasm, whereas the peripheral (extraosseous) ameloblastoma behaves in a benign fashion.

### Clinical Findings

- Solid type: generally seen in the fourth to fifth decade; uniloculated or multiloculated radiolucency, most often in the posterior mandible, although blacks may have a predilection for lesions in the anterior mandible (Fig. 15-6, A and B); may cause swelling of the face if large; described as a solid tumor at surgery, although microcystic spaces may be present; the scirrhous or desmoplastic variant presents as a mixed lucent-opaque mass in 50% of cases (suggesting a fibro-osseous lesion) in adults in the fifth and sixth decades; equal mandibular and maxillary frequency, often affecting the anterior maxilla; some ameloblastomas are associated with impacted teeth (see Fig. 15-6, C).
- Unicystic or unicystic plexiform type: uniloculated radiolucency in the posterior mandible is often associated with an impacted tooth, usually in the second and third decades (see Fig. 15-6, D), described as cystic at surgery.
- Peripheral ameloblastoma occurs as a gingival nodule (see Chapter 5); rare cases occur at extralingival sites such as the buccal mucosa.

### Histopathologic Features

Central ameloblastoma bears histologic and behavioral resemblance to basal cell carcinoma. They are classified by gross pattern and constituent cells.

- Solid ameloblastoma: *follicular type* shows islands of epithelial cells typically with peripheral basaloid cells showing reverse polarization of the nuclei; areas of cystic change within the epithelial islands are common; *plexiform type* shows anastomosing trabeculae and cords of epithelial cells with similar peripheral basaloid cell morphology, although this may be subtle (Figs. 15-7, A-C and 15-8).
- Variants are *classic* if the center of the islands show loose, stellate reticulum-like areas; *acanthomatous* if there are large, eosinophilic squamous cells or keratinization (Fig. 15-9; see Fig. 15-7, D); *granular cell* if cells with granular cytoplasm rich in lysosomes are present (Figs. 15-10 and 15-11); *keratoameloblastoma* if there is keratin production; and *basal cell-type* if basaloid cells predominate (uncommon type); classic and acanthomatous types are the most common and often coexist.
- Desmoplastic or scirrhous ameloblastoma is a variant of the follicular ameloblastoma, classic type, where islands of epithelium appear compressed by markedly desmoplastic stroma; tumors often show a combination of follicular and desmoplastic types (Fig. 15-12).

- Unicystic ameloblastoma: cyst lining is generally 5 to 15 cells thick and has the following features (Vickers-Gorlin criteria): palisaded basal cell nuclei with reverse polarization, stellate reticulum-like cells within the lining and eosinophilic (acanthomatous) luminal cells (Fig. 15-13); these changes are identical to those seen in cystic change within epithelial islands in solid ameloblastoma (see Fig. 15-9, C).
- Plexiform unicystic ameloblastoma is similar to the unicystic type, except that there is a plexiform proliferation of ameloblastomatous epithelium in an intraluminal or intramural pattern (Fig. 15-14, A-C); inflammation results in loss of the diagnostic features of this lesion and may lead to misdiagnosis of this cystic tumor as a radicular cyst or an inflamed non-specific odontogenic cyst (see Fig. 15-14, D and E).

### Differential Diagnosis

- Dentigerous cyst or other odontogenic cyst does not exhibit the Vickers-Gorlin criteria as noted; however, if the unicystic ameloblastoma is inflamed, these criteria may be lost.
- Squamous odontogenic tumor does not show palisading of the peripheral basal cells.
- Metastatic carcinoma is differentiated from desmoplastic ameloblastoma by the presence of frankly malignant cells consistent with the primary malignancy and lacks the palisading and reverse polarization of basal cells.
- Ameloblastic carcinoma shows obvious features of malignancy with hypercellularity, pleomorphic cells, many mitotic figures, and sometimes necrosis.

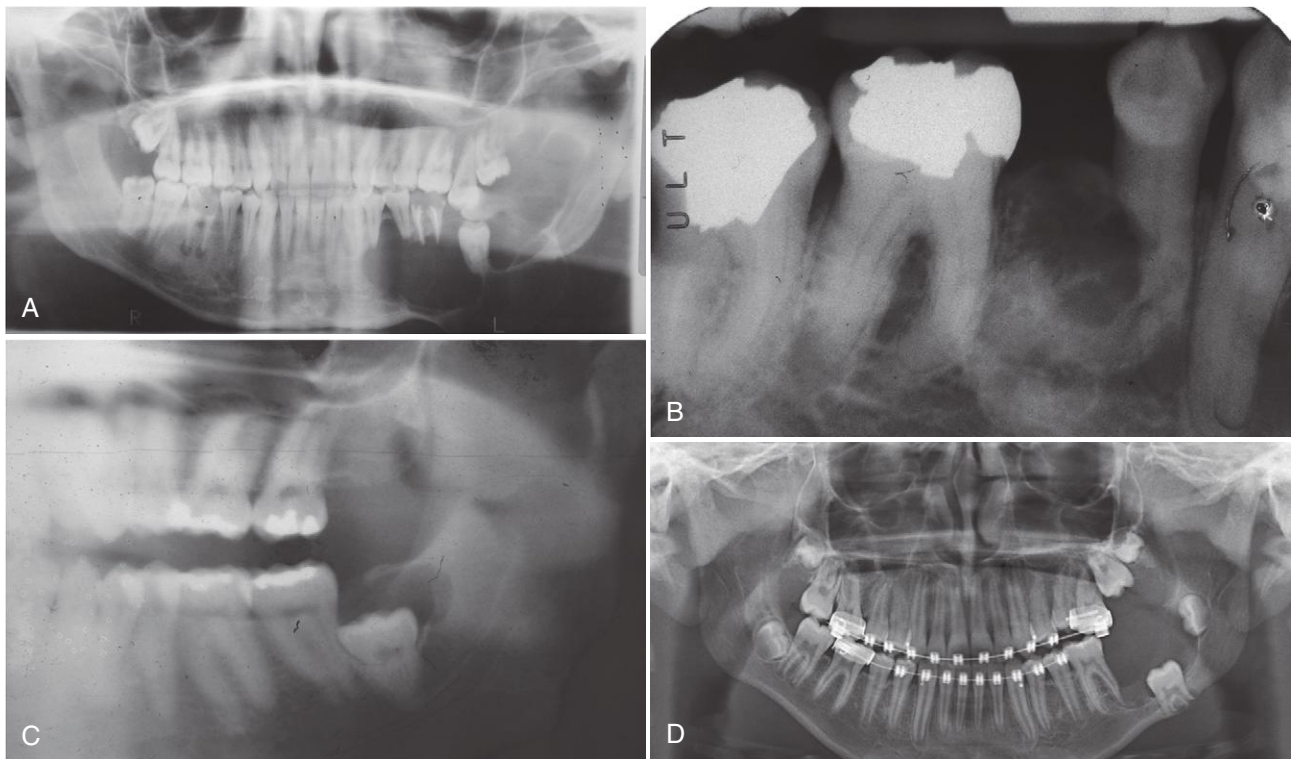
### Management and Prognosis

- Solid lesions: recurrence rate is 17% if the tumor is resected and 35% if the tumor is curetted/enucleated; en bloc resection is the treatment of choice.
- For unicystic lesions, recurrence rates for those without and with mural proliferation are 6% and 37%, respectively; enucleation can be curative in many, but not all, cases, depending on the histopathology.
- Malignant transformation occurs in less than 1% of cases.

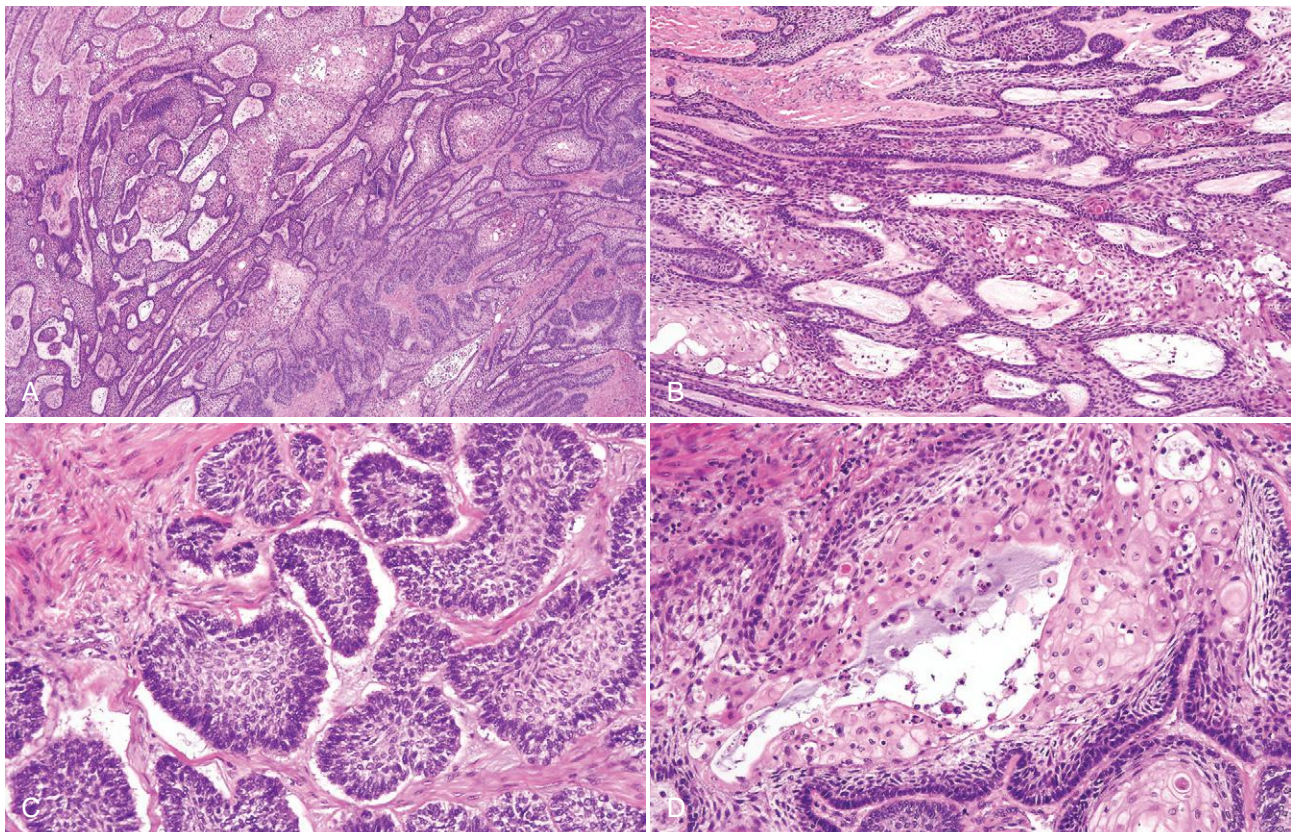
### REFERENCES

- Ide F. Peripheral ameloblastoma of the buccal mucosa. *Oral Surg Oral Med Oral Pathol Oral Radiol Endod.* 2010;108:577-579 (letter).
- Kishino M, Murakami S, Fukuda Y, Ishida T. Pathology of the desmoplastic ameloblastoma. *J Oral Pathol Med.* 2001;30:35-40.
- Li TJ, Wu YT, Yu SF, Yu GY. Unicystic ameloblastoma: a clinicopathologic study of 33 Chinese patients. *Am J Surg Pathol.* 2000;24:1385-1392.
- Philipsen HP, Reichart PA. Unicystic ameloblastoma. A review of 193 cases from the literature. *Oral Oncol.* 1998;34:317-325.
- Philipsen HP, Reichart PA, Takata T. Desmoplastic ameloblastoma (including "hybrid" lesion of ameloblastoma). Biological profile based on 100 cases from the literature and own files. *Oral Oncol.* 2001;37:455-460.
- Reichart PA, Philipsen HP, Sonner S. Ameloblastoma: biological profile of 3677 cases. *Eur J Cancer B Oral Oncol.* 1995;31B:86-99.
- Waldron CA, el-Mofty SK. A histopathologic study of 116 ameloblastomas with special reference to the desmoplastic variant. *Oral Surg Oral Med Oral Pathol.* 1987;63:441-451.



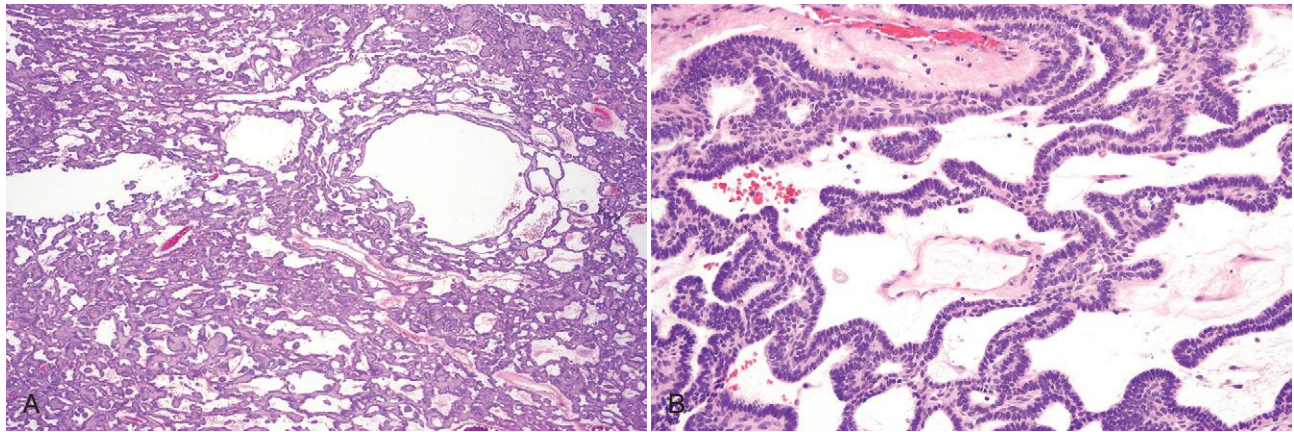


**FIGURE 15-6.** Ameloblastoma. **A**, Multiloculated radiolucency displacing the left mandibular second molar. **B**, Multiloculated radiolucency in an area of previously extracted tooth. **C**, Dentigerous cyst that incidentally had ameloblastoma in the wall. **D**, Plexiform unicystic ameloblastoma: unilocular radiolucency displacing mandibular second molar. (**A**, Courtesy of Dr. Thomas Dodson, Harvard School of Dental Medicine, Boston; **D**, Courtesy of Dr. Euger Lin, private practice, Marlboro, Mass.)

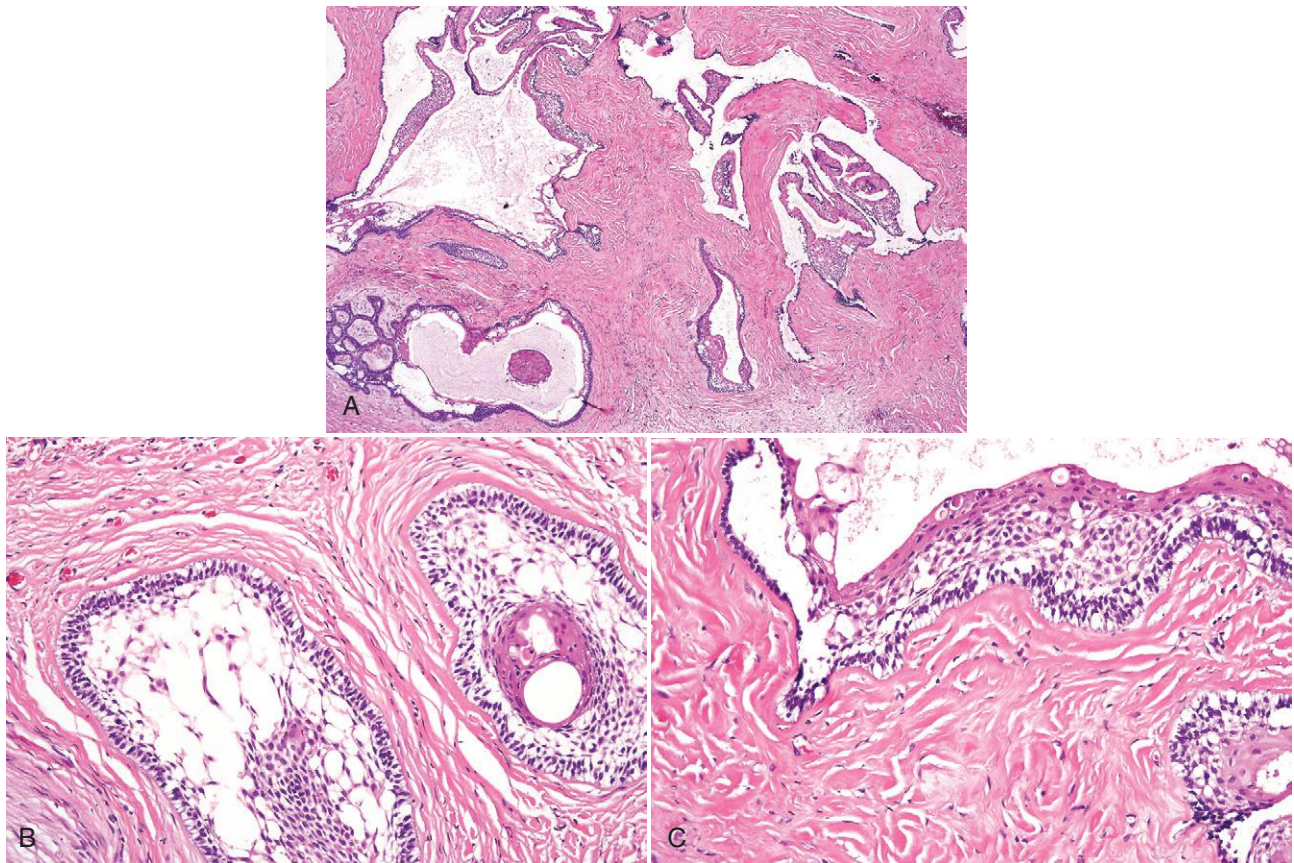


**FIGURE 15-7.** Ameloblastoma, mixed pattern. **A**, Follicular pattern with islands of tumor cells and surrounding fibrous tissue. **B**, Plexiform pattern with anastomosing trabeculae of cells encircling islands of fibrous tissue. **C**, Follicular pattern with palisading of basal cells and reverse nuclear polarization. **D**, Follicular pattern, acanthomatous type with cystic change.



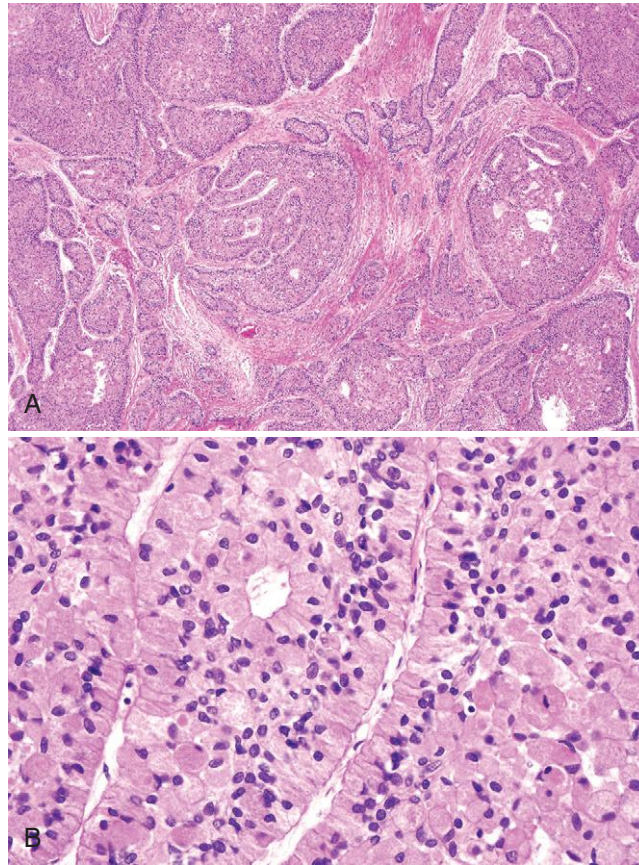


**FIGURE 15-8.** Ameloblastoma, plexiform pattern. **A**, Interlacing trabeculae and strands of cells enclosing islands of fibrovascular tissue. **B**, Strands of tumor cells show nuclear palisading and reverse polarization; stroma is myxoid.

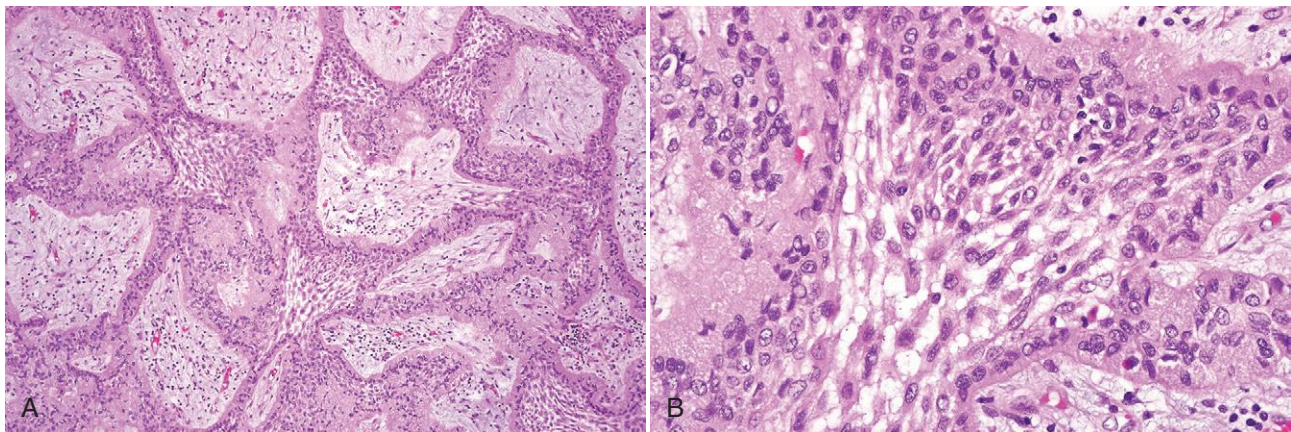


**FIGURE 15-9.** Ameloblastoma, follicular pattern. **A**, Center of tumor islands exhibit prominent cystic change. **B**, Classic and acanthomatous areas with early cystic change. **C**, Eosinophilic luminal cells overlie stellate reticulum-like areas and basal cells exhibit reverse nuclear polarization.



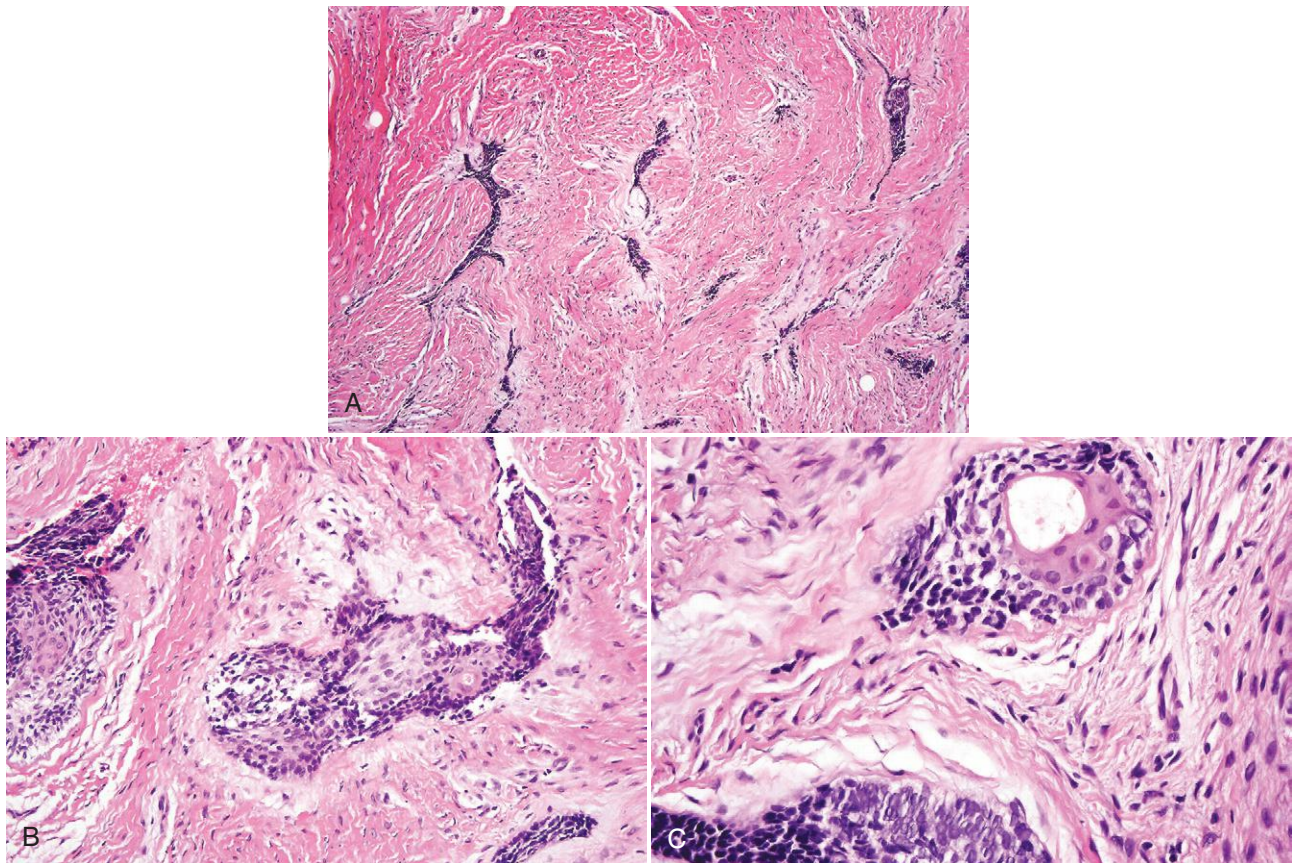


**FIGURE 15-10.** Ameloblastoma, follicular pattern. **A**, Islands of tumor containing pale, eosinophilic granular cells with palisaded basal cells. **B**, Both basal cells (with reverse nuclear polarization) and cells in center of islands have granular cytoplasm.

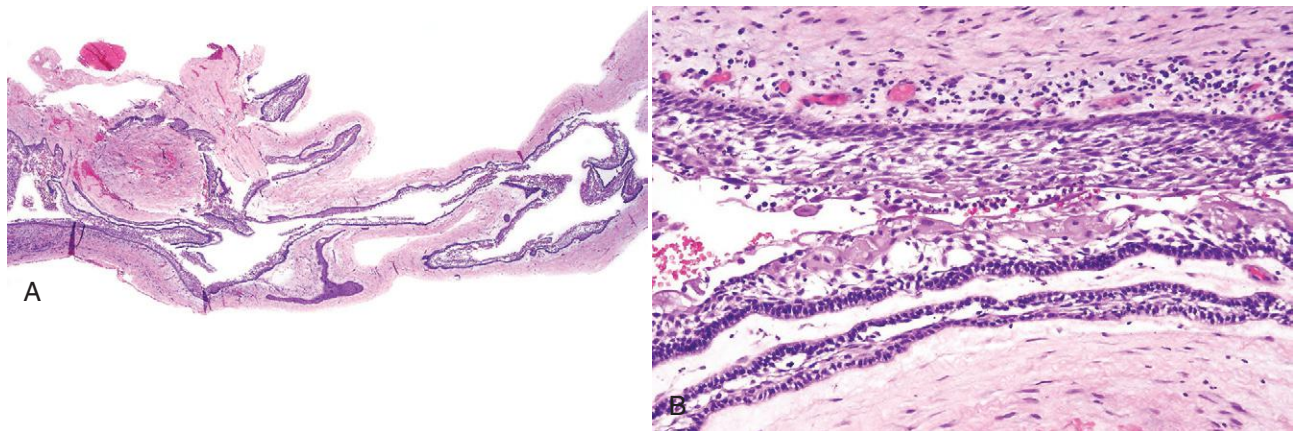


**FIGURE 15-11.** Ameloblastoma, plexiform pattern. **A**, Anastomosing trabeculae of epithelium with palisaded basal nuclei and pale granular cells in a plexiform pattern. **B**, Variant is classic and granular cell type.



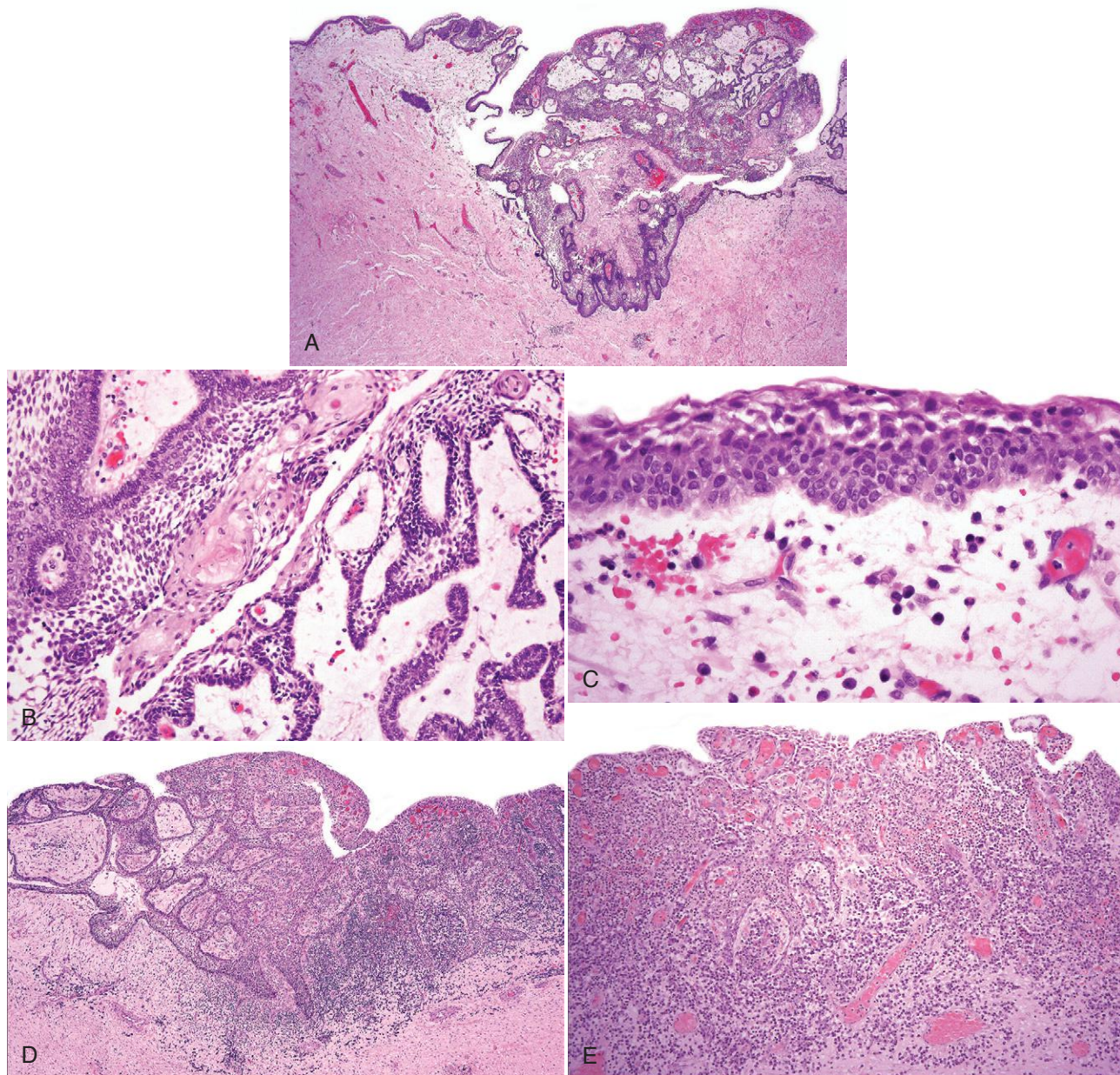


**FIGURE 15-12.** Desmoplastic ameloblastoma. **A**, Irregularly shaped islands of darkly staining tumor cells and scirrhous stroma. **B**, Compressed islands of basaloid cells with focal reverse nuclear polarization. **C**, Islands of basaloid cells with focal acanthomatous and microcystic change.



**FIGURE 15-13.** Unicystic ameloblastoma. **A**, Single large cystic space with prominent basal cells in lining and no inflammation. **B**, Eosinophilic luminal cells overlie stellate reticulum–like areas, and basal cells exhibit palisaded nuclei.





**FIGURE 15-14.** Plexiform unicystic ameloblastoma. **A**, Single cystic structure with plexiform luminal and slight endophytic mural epithelial proliferation. **B**, Plexiform epithelial proliferation exhibiting classic and acanthomatous histology. **C**, Thin lining showing early stellate reticulum–like changes. **D**, Inflamed area of cyst on *right* with loss of typical features of ameloblastoma. **E**, Inflammation leads to nonspecific spongiosis and leukocyte exocytosis, easily leading to a misdiagnosis.



## CALCIFYING EPITHELIAL ODONTOGENIC TUMOR (PINDBORG TUMOR)

### Clinical Findings

- Occurs in adults in the third to fifth decade; appears as lucent or mixed radiolucent and radiopaque mass of the posterior mandible (70%) (Fig. 15-15, A); 60% are associated with an impacted tooth (Fig. 15-15, B); 5% to 6% are extrasosseous; this tumor is locally aggressive and may perforate the cortical plate.

### Histopathologic Features

This tumor recapitulates the stratum intermedium of the enamel organ.

- Cords, islands, and sometimes sheets of large, often polygonal cells with abundant eosinophilic cytoplasm are evident; variation in nuclear shape and size and pseudoinclusions are common, but mitotic activity is not seen unless malignant; congophilic amyloid-like material is always identified (Figs. 15-16 and 15-17); clear cells appear in 8% of tumors, although a variant contains predominantly clear cells.
- Variable amount of calcification occurs, in spite of the name, and this sometimes takes the form of concentric lamellar rings (Liesegang rings); calcifications are less commonly encountered in extrasosseous forms; there is moderate fibrosis.
- Foci of this tumor are often seen within an adenomatoid odontogenic tumor.

### Differential Diagnosis

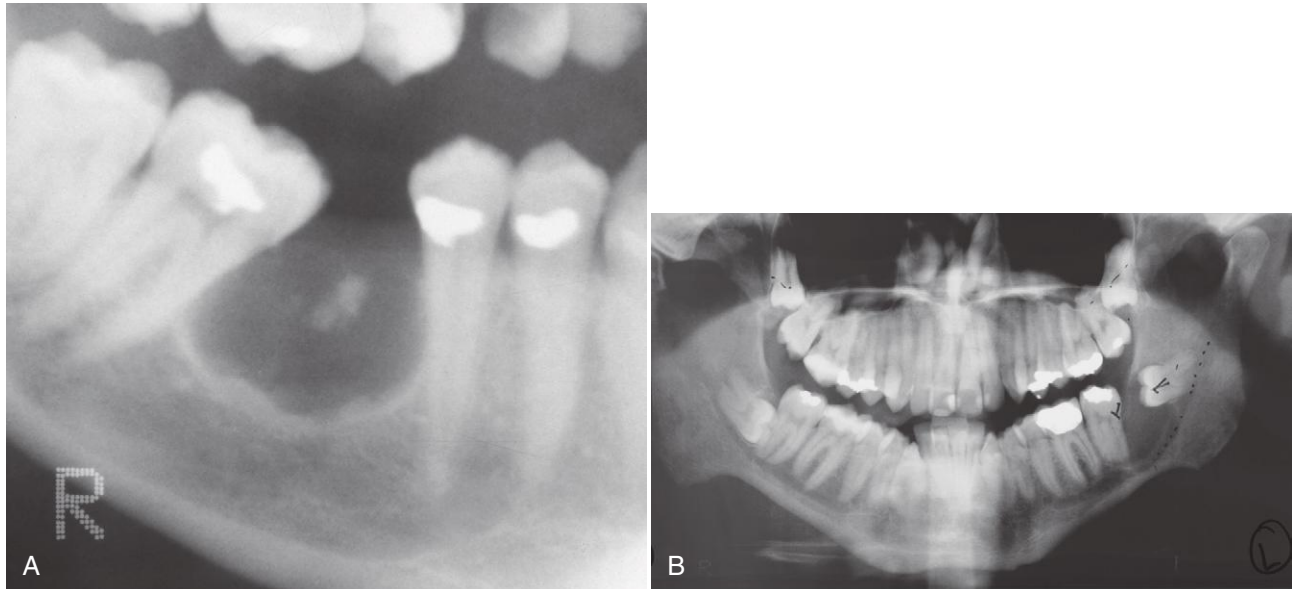
- Malignant calcifying epithelial odontogenic tumor exhibits hypercellularity, hyperchromatic nuclei with coarse chromatin, and other features of malignancy.
- Metastatic carcinomas have significantly more atypia, mitotic activity, and desmoplasia.
- Primary clear cell odontogenic carcinoma does not produce amyloid and exhibits significant nuclear atypia.

### Management and Prognosis

- Complete excision or enucleation is the treatment of choice; recurrence rate is up to 15%; clear cell variant may be more prone to occur.

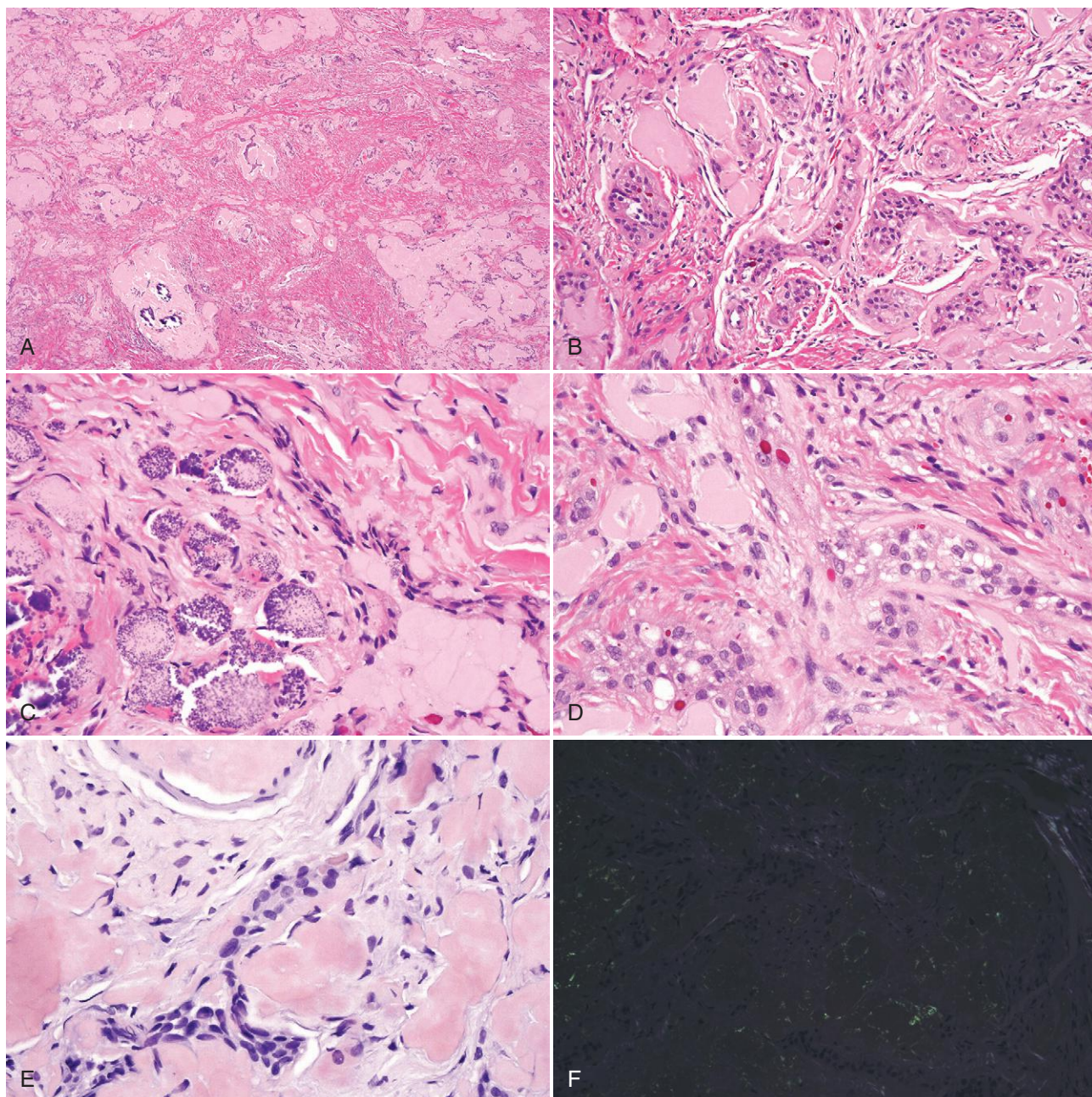
### REFERENCES

- Anavi Y, Kaplan I, Citir M, Calderon S. Clear-cell variant of calcifying epithelial odontogenic tumor: clinical and radiographic characteristics. *Oral Surg Oral Med Oral Pathol Oral Radiol Endod.* 2003;95:332-339.
- Demian N, Harris RJ, Abramovitch K, et al. Malignant transformation of calcifying epithelial odontogenic tumor is associated with the loss of p53 transcriptional activity: report of a case with review of the literature. *J Oral Maxillofac Surg.* 2010;68:1964-1973.
- Kawano K, Ono K, Yada N, et al. Malignant calcifying epithelial odontogenic tumor of the mandible: report of a case with pulmonary metastasis showing remarkable response to platinum derivatives. *Oral Surg Oral Med Oral Pathol Oral Radiol Endod.* 2007;104:76-81.
- Philipsen HP, Reichart PA. Adenomatoid odontogenic tumour: facts and figures. *Oral Oncol.* 1999;35:125-131.
- Philipsen HP, Reichart PA. Calcifying epithelial odontogenic tumour: biological profile based on 181 cases from the literature. *Oral Oncol.* 2000;36:17-26.



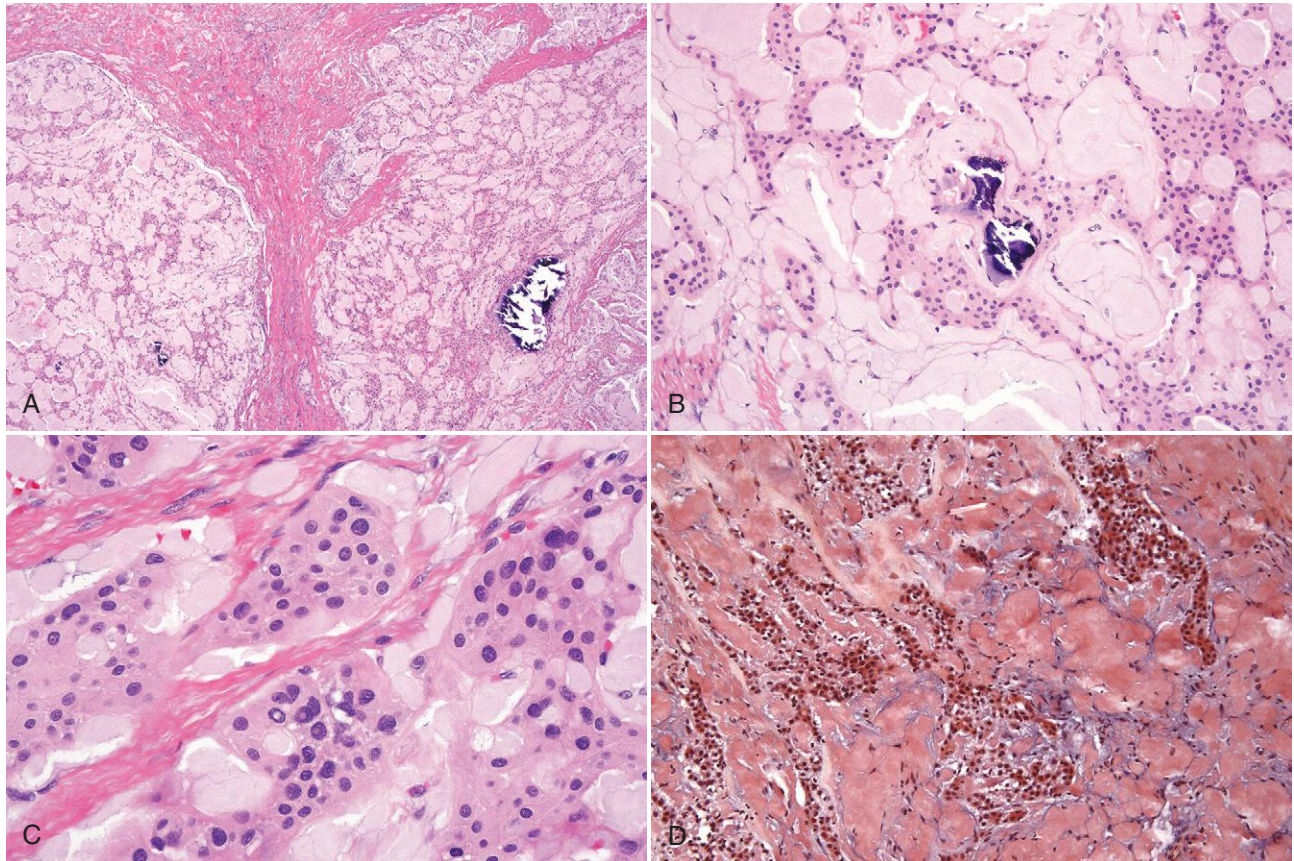
**FIGURE 15-15.** Calcifying epithelial odontogenic tumor: **A**, Circumscribed radiolucency with small central radiopacity in the area of previously extracted right mandibular first molar. **B**, Circumscribed radiolucency around the crown of impacted left mandibular third molar. (Courtesy of Dr. Leonard Waldman, private practice, Nashua, N.H.)





**FIGURE 15-16.** Calcifying epithelial odontogenic tumor: **A**, Islands of epithelial cells surrounded by amyloid with moderate fibrosis; focal calcifications. **B**, Islands of epithelial cells and amyloid. **C**, Dystrophic calcification in amyloid. **D**, Tumor islands with some clear cells; nuclei are bland. **E**, Amyloid is congophilic (Congo Red stain). **F**, Apple green birefringence of the amyloid.





**FIGURE 15-17.** Calcifying epithelial odontogenic tumor. **A**, Plexiform pattern of tumor cells with abundant amyloid and focal calcifications. **B**, Tumor cells have abundant eosinophilic cytoplasm; abundant amyloid and calcifications. **C**, Variation in nuclear shape and size with nuclear pseudoinclusions. **D**, Amyloid is congophilic (Congo Red stain).

## ADENOMATOID ODONTOGENIC TUMOR

### Clinical Findings

- Occurs in second decade of life with male predilection of 2:1; radiolucency and variable radiopacity present around the crown of impacted tooth (follicular type) (Fig. 15-18); two thirds of cases are in the maxilla, and two thirds are associated with the canine; extrafollicular tumors (not associated with a tooth) also occur, and extraosseous forms are rare.

### Histopathologic Features

- Thickly encapsulated proliferation of nodules, whorls, and strands of spindled, columnar, and polygonal epithelial cells often with pale or clear cytoplasm; solid and reticular areas are present; ductlike structures and basophilic droplets of enameloid are characteristic, sometimes forming rosette-like structures (Figs. 15-19, A-C and 15-20, A-C); there is little fibrous stroma.
- Ductlike structures are CK19 positive and pseudolumina contain eosinophilic secretions or enameloid

(see Figs. 15-19, D and E and 15-20, D); calcifications, some of which may be ringlike, may be seen (see Fig. 15-20, E); amyloid and calcifying epithelial odontogenic tumorlike areas are common (see later).

- Wall may have myxoid follicular tissue or be densely collagenized.

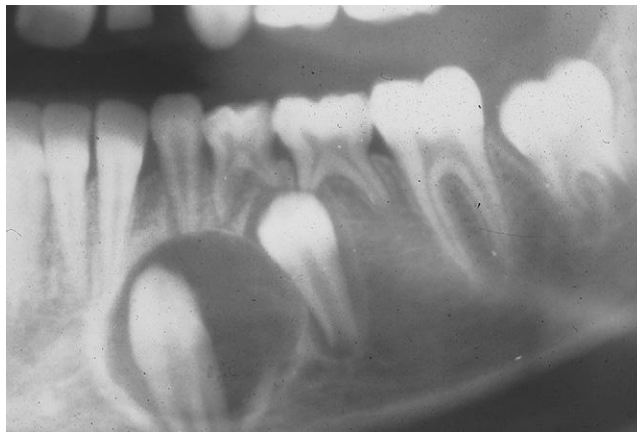
### Management and Prognosis

- Excision is curative; recurrence rate is insignificant.

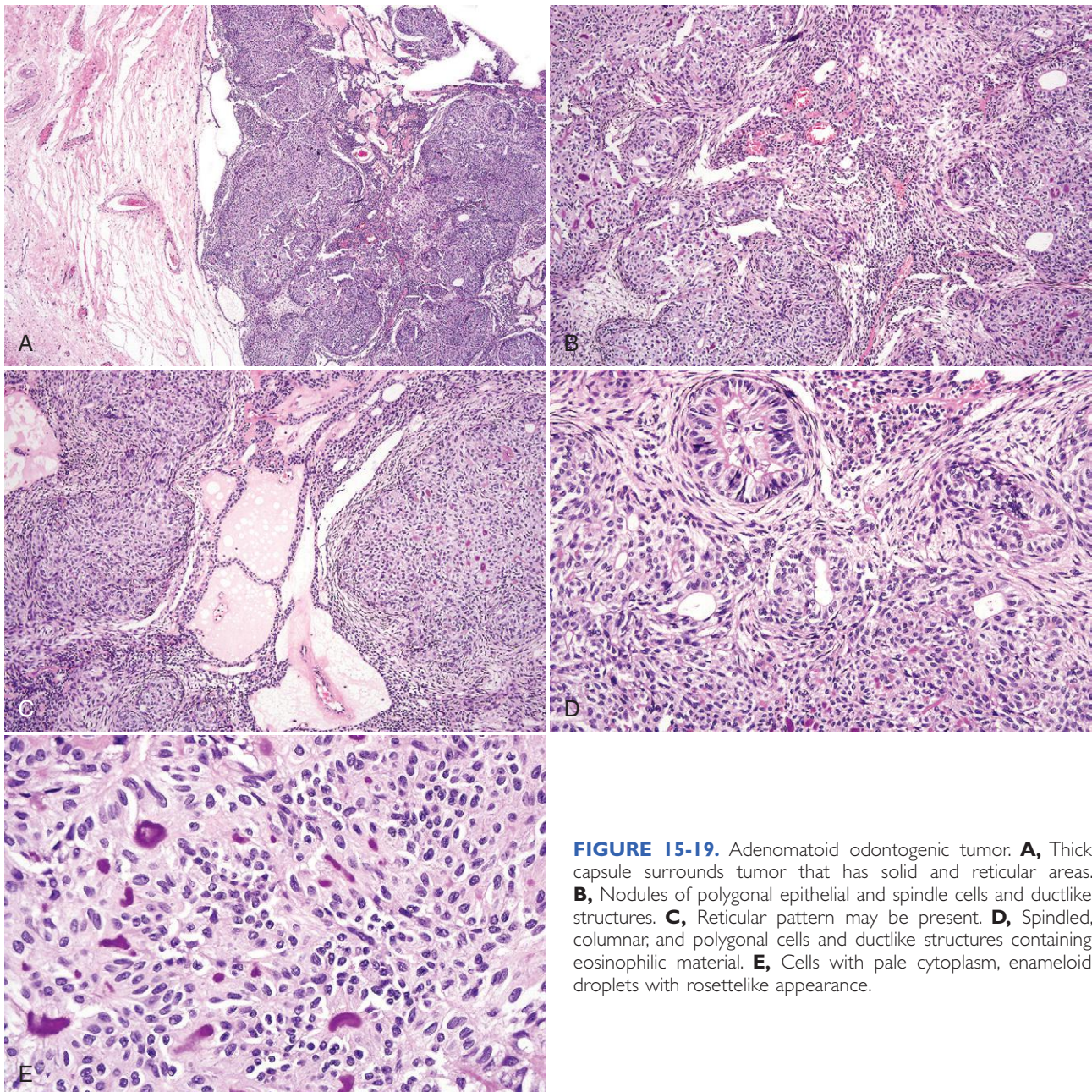
### REFERENCES

- Leon JE, Mata GM, Fregnani ER, et al. Clinicopathological and immunohistochemical study of 39 cases of adenomatoid odontogenic tumour: a multicentric study. *Oral Oncol.* 2005;41:835-842.
- Mosqueda-Taylor A, Carlos-Bregni R, Ledesma-Montes C, et al. Calcifying epithelial odontogenic tumor-like areas are common findings in adenomatoid odontogenic tumors and not a specific entity. *Oral Oncol.* 2005;41:214-215.
- Philipsen HP, Reichart PA, Siar CH, et al. An updated clinical and epidemiological profile of the adenomatoid odontogenic tumour: a collaborative retrospective study. *J Oral Pathol Med.* 2007;36:383-393.
- Rick GM. Adenomatoid odontogenic tumor. *Oral Maxillofac Surg Clin North Am.* 2004;16:333-354.



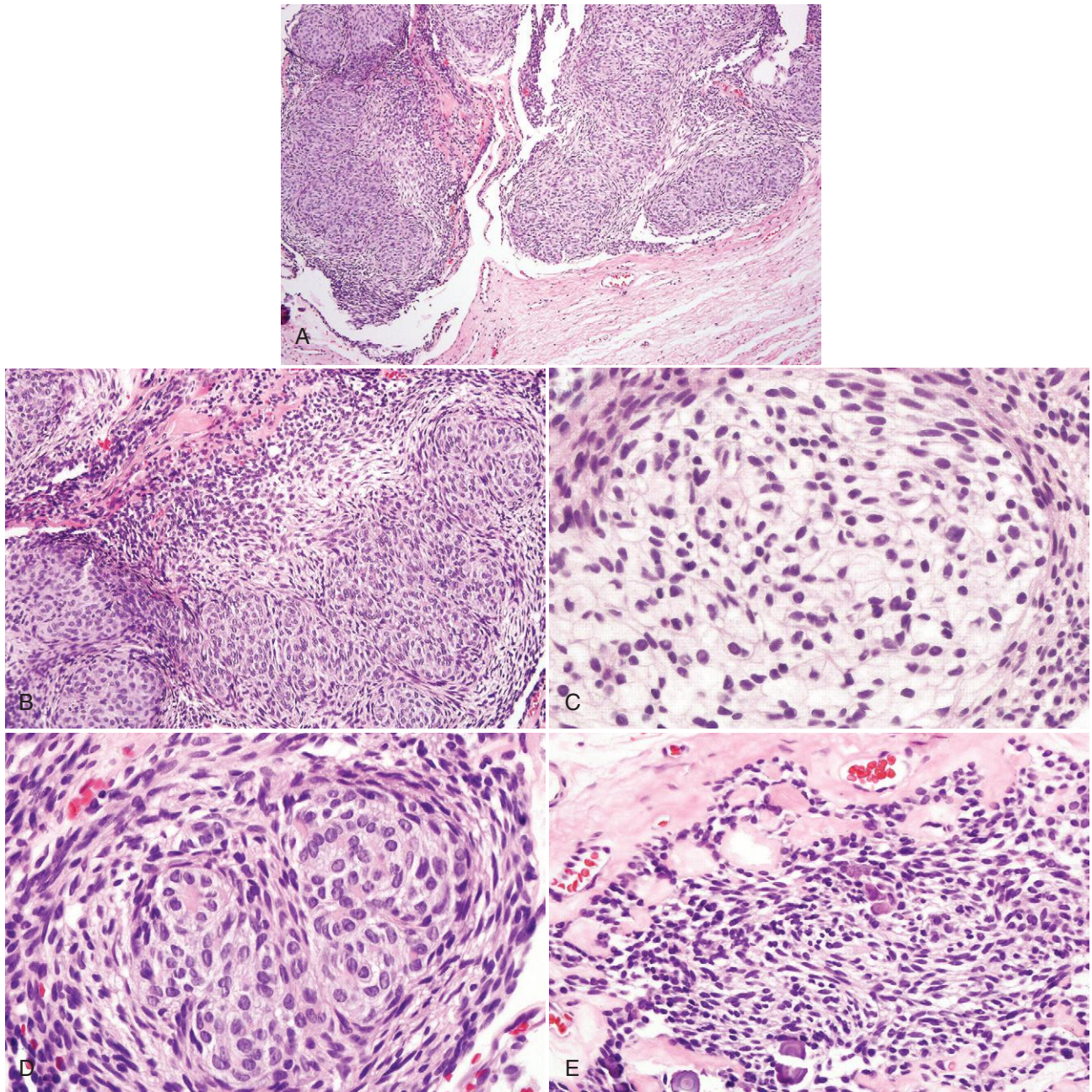


**FIGURE 15-18.** Adenomatoid odontogenic tumor: well-circumscribed radiolucency around impacted mandibular permanent canine. (Courtesy of Dr. Sadru Kabani, private practice, Cambridge, Mass.)



**FIGURE 15-19.** Adenomatoid odontogenic tumor: **A**, Thick capsule surrounds tumor that has solid and reticular areas. **B**, Nodules of polygonal epithelial and spindle cells and ductlike structures. **C**, Reticular pattern may be present. **D**, Spindled, columnar, and polygonal cells and ductlike structures containing eosinophilic material. **E**, Cells with pale cytoplasm, enameloid droplets with rosettelike appearance.





**FIGURE 15-20.** Adenomatoid odontogenic tumor. **A**, Thick capsule surrounds tumor. **B**, Whorls of polygonal and spindle cells without ductlike structures. **C**, Islands of clear cells. **D**, Subtle ductlike structures with enameloid. **E**, Calcifications and reticular pattern at the margin (top).

## SQUAMOUS ODONTOGENIC TUMOR

### Clinical Findings

- Third to fourth decade; well-demarcated radiolucency are equally distributed in the posterior mandible or anterior maxilla around the roots of teeth; one third are multicentric.

### Histopathologic Features

- Irregularly shaped islands of mature squamous epithelium with dyskeratotic cells; some islands may exhibit cystic change or may contain eosinophilic amorphous secretions; fibrous stroma is abundant; unlike ameloblastoma, the peripheral cells are squamous or flattened cuboidal cells (Figs. 15-21 and 15-22).



### Differential Diagnosis

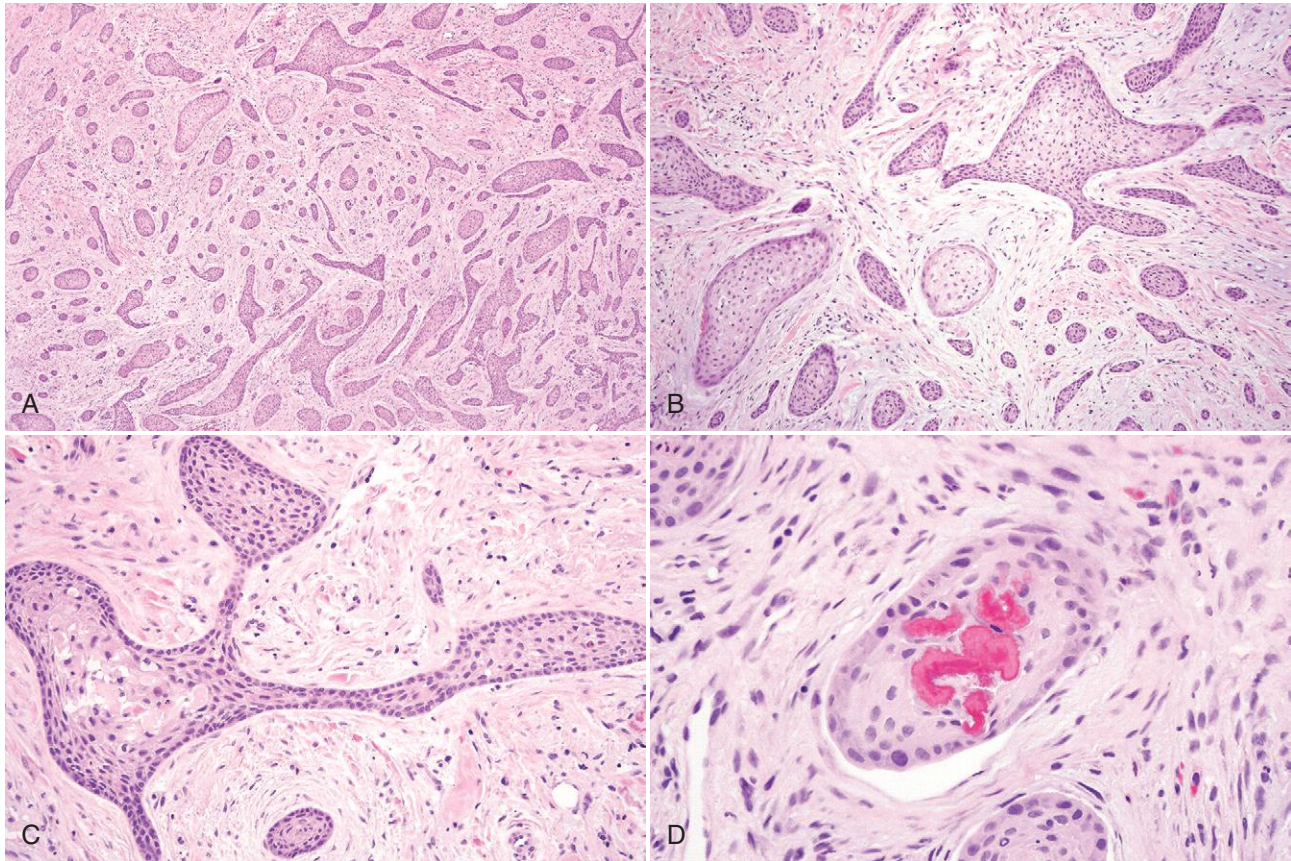
- Follicular ameloblastoma, acanthomatous type, shows palisading of basal cell nuclei.
- Primary intraosseous and metastatic carcinomas show significant cytologic atypia.
- Squamous odontogenic-like proliferations composed of similar irregular islands of benign epithelium are sometimes seen in the walls of radicular cysts.

### Management and Prognosis

- Enucleation, curettage, or excision is curative; recurrence is rare.

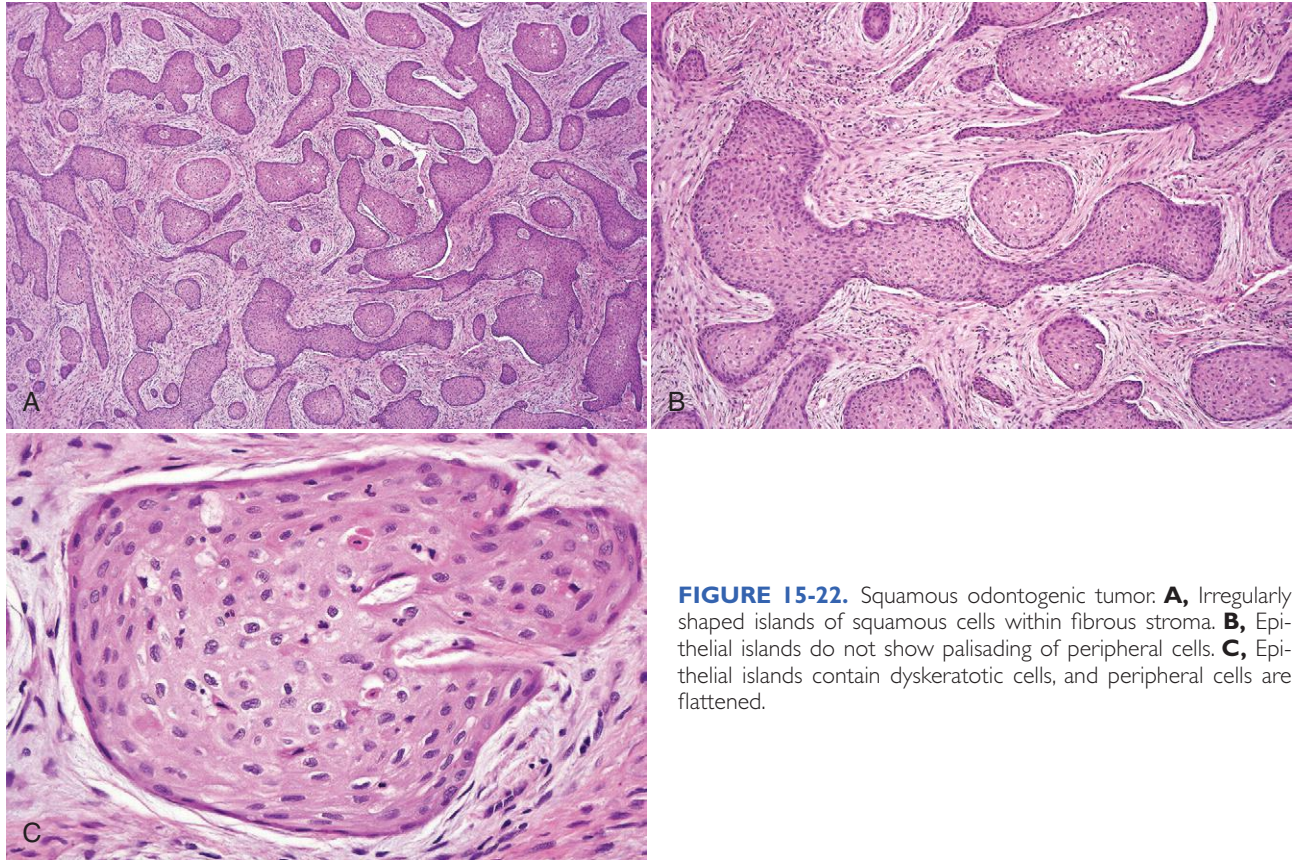
### REFERENCES

- Goldblatt LI, Brannon RB, Ellis GL. Squamous odontogenic tumor. Report of five cases and review of the literature. *Oral Surg Oral Med Oral Pathol.* 1982;54:187-196.
- Kim K, Mintz SM, Stevens J. Squamous odontogenic tumor causing erosion of the lingual cortical plate in the mandible: a report of 2 cases. *J Oral Maxillofac Surg.* 2007;65:1227-1231.
- Lin YL, White DK. Squamous odontogenic tumor. *Oral Maxillofac Surg Clin North Am.* 2004;16:355-357.
- Philipsen HP, Reichart PA. Squamous odontogenic tumor (SOT): a benign neoplasm of the periodontium. A review of 36 reported cases. *J Clin Periodontol.* 1996;23:922-926.
- Wright JM Jr. Squamous odontogenic tumorlike proliferations in odontogenic cysts. *Oral Surg Oral Med Oral Pathol.* 1979;47:354-358.



**FIGURE 15-21.** Squamous odontogenic tumor. **A**, Islands of squamous epithelium within fibrous stroma. **B**, Irregularly shaped islands of squamous cells within delicately fibrous stroma; one resembles a fish. **C**, Peripheral cells are low cuboidal or squamous without palisading or reverse polarization of nuclei; dyskeratotic cells are noted, and there is dyscohesion. **D**, Epithelial islands may contain brightly eosinophilic hyaline material reminiscent of Rushton bodies.





**FIGURE 15-22.** Squamous odontogenic tumor: **A**, Irregularly shaped islands of squamous cells within fibrous stroma. **B**, Epithelial islands do not show palisading of peripheral cells. **C**, Epithelial islands contain dyskeratotic cells, and peripheral cells are flattened.

## AMELOBLASTIC CARCINOMA

Ameloblastic carcinoma displays all the features of ameloblastoma, except that it has malignant cytology; metastatic ameloblastoma, a very rare condition, shows minimal cytologic atypia but has metastasized.

### Clinical Findings

- Third to fifth decade; 2:1 male predilection; pain, mucosal ulceration and paresthesia often noted; more than two thirds occur in mandible, mostly posterior.

### Histopathologic Features

The majority of ameloblastic carcinomas arise de novo; those that arise from preexisting ameloblastomas are considered secondary or dedifferentiated lesions.

- These tumors exhibit follicular (most common), plexiform, or trabecular pattern; infiltrative islands of tumor cells exhibit peripheral cell palisading, and reverse nuclear polarization with central stellate reticulum–like areas that are hypercellular; comedonecrosis, mitotic activity, and pleomorphic cells are present, and sometimes peripheral palisading is lost (Fig. 15-23); Ki-67 index is high; clear cells, ghost cells, and keratinization may be seen with focal dentinoid production (see Fig. 15-23).

### Differential Diagnosis

- Primary intraosseous carcinoma and de novo ameloblastic carcinoma are likely related lesions, with the

former showing less ameloblastic differentiation, in that basal cell palisading or formation of stellate reticulum–like areas is minimal or insignificant.

- Metastatic carcinoma must be ruled out.

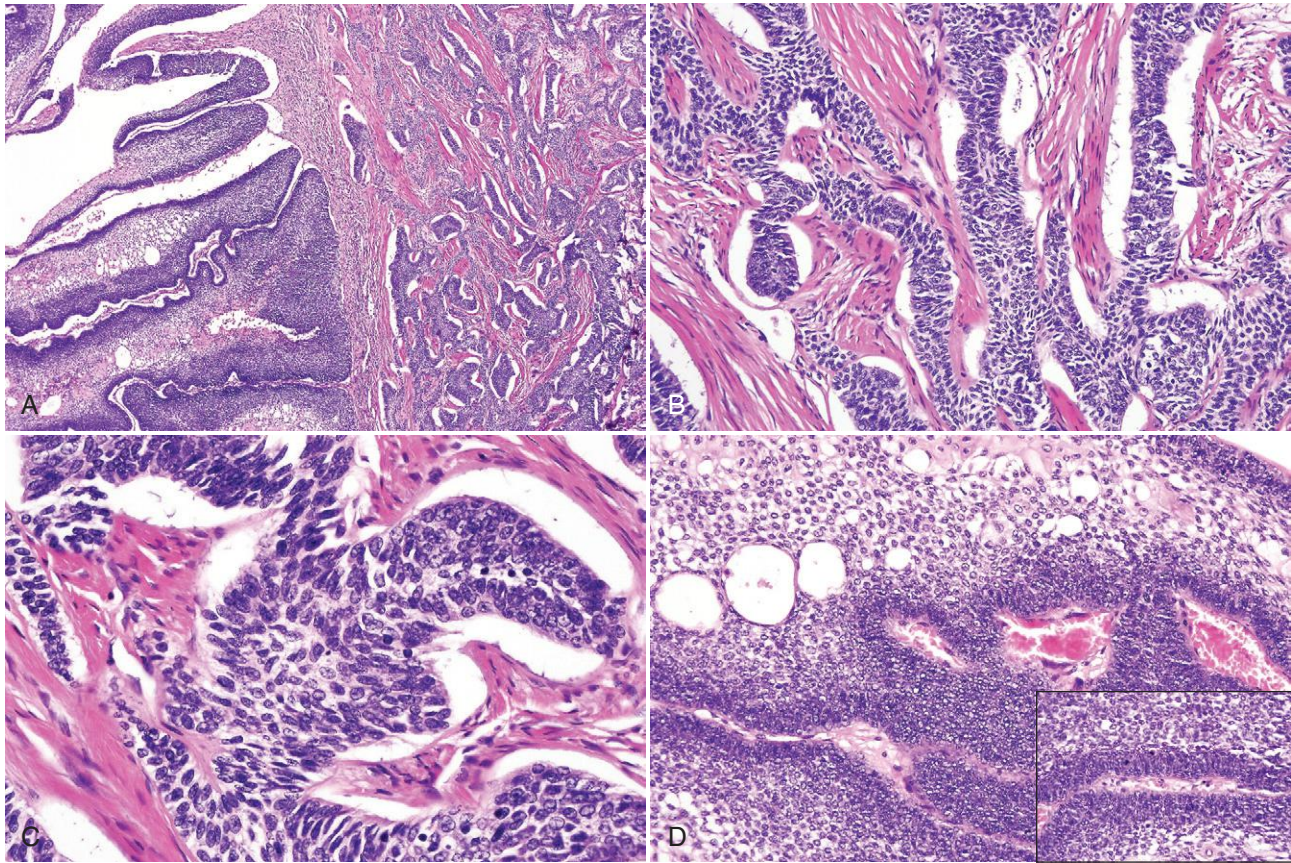
### Management and Prognosis

- En bloc resection with radiation or chemotherapy as appropriate results in 30% recurrence rate; 22% develop metastases, and half of those exhibit distant metastases to lungs, bone, and brain; 5-year survival with and without metastases is approximately 20% and 70%, respectively.

### REFERENCES

- Barnes L, Eveson J, Reichart P, Sidransky D, eds. *Pathology and Genetics of Head and Neck Tumors*. Lyon, France: IARC Press; 2005.
- Corio RL, Goldblatt LI, Edwards PA, Hartman KS. Ameloblastic carcinoma: a clinicopathologic study and assessment of eight cases. *Oral Surg Oral Med Oral Pathol*. 1987;64:570-576.
- Cox DP, Muller S, Carlson GW, Murray D. Ameloblastic carcinoma ex ameloblastoma of the mandible with malignancy-associated hypercalcemia. *Oral Surg Oral Med Oral Pathol Oral Radiol Endod*. 2000;90:716-722.
- Hall JM, Weathers DR, Unni KK. Ameloblastic carcinoma: an analysis of 14 cases. *Oral Surg Oral Med Oral Pathol Oral Radiol Endod*. 2007;103:799-807.
- Ndukwe KC, Adebisi EK, Ugboko VI, et al. Ameloblastic carcinoma: a multicenter Nigerian study. *J Oral Maxillofac Surg*. 2010;68:2111-2114.
- Yoon HJ, Hong SP, Lee JI, et al. Ameloblastic carcinoma: an analysis of 6 cases with review of the literature. *Oral Surg Oral Med Oral Pathol Oral Radiol Endod*. 2009;108:904-913.





**FIGURE 15-23.** Ameloblastic carcinoma. **A**, Recognizable follicular ameloblastoma, acanthomatous type, on *left* but exhibits hypercellularity; dedifferentiated infiltrative tumor on *right*. **B**, Infiltrative less well-differentiated area of tumor with minimal palisading of peripheral cells. **C**, Infiltrative area of tumor is hypercellular with pleomorphic cells. **D**, Area of more typical ameloblastoma with hypercellularity, hyperchromatic nuclei, and mitoses (*inset*).

## PRIMARY INTRAOSSEOUS SQUAMOUS CELL CARCINOMA

### Clinical Features

- Occurs in the sixth and seventh decades; 2 to 3:1 male predilection; 80% posterior mandible, 10% anterior maxilla; poorly demarcated radiolucency of the mandible, often perforating cortex; pain, mobility of teeth, and paresthesia common.

### Histopathologic Features

Tumors may arise *de novo* within the bone, from odontogenic cysts or odontogenic tumors (especially the keratocystic odontogenic tumor [odontogenic keratocyst]). Ameloblastic carcinoma is also a primary odontogenic carcinoma, albeit with characteristic features.

- Tumors present as infiltrative islands of squamous cells with minimal to moderate keratinization and may not be well differentiated; those arising from the lining of keratocystic odontogenic tumor (odontogenic keratocysts) are often keratinizing (Fig. 15-24); clear cells are present in 25% of cases, follicular pattern in 25%, and palisading peripheral cells in 8%; the lining of this tumor or other odontogenic

cyst exhibits varying degrees of dysplasia; tumors may manifest as verrucous or papillary squamous carcinoma (Fig. 15-25).

### Differential Diagnosis

- Ameloblastic carcinoma shows obvious palisading of the peripheral cells; differentiation between this and primary intraosseous carcinoma may be moot because both are primary carcinomas in bone of odontogenic epithelial origin.
- Primary squamous cell carcinoma of overlying the mucosa or from the maxillary sinus and metastatic squamous cell carcinoma must be ruled out.
- Mucoepidermoid carcinoma contains mucous cells and is not generally keratinizing; ductal structures may be present.
- Squamous odontogenic tumor exhibits benign histology and is not invasive and not keratinizing.

### Management and Prognosis

- Resection is the treatment of choice, with adjuvant radiation therapy and chemotherapy as appropriate; recurrence rate is 20% to 60%; 10% develop distant

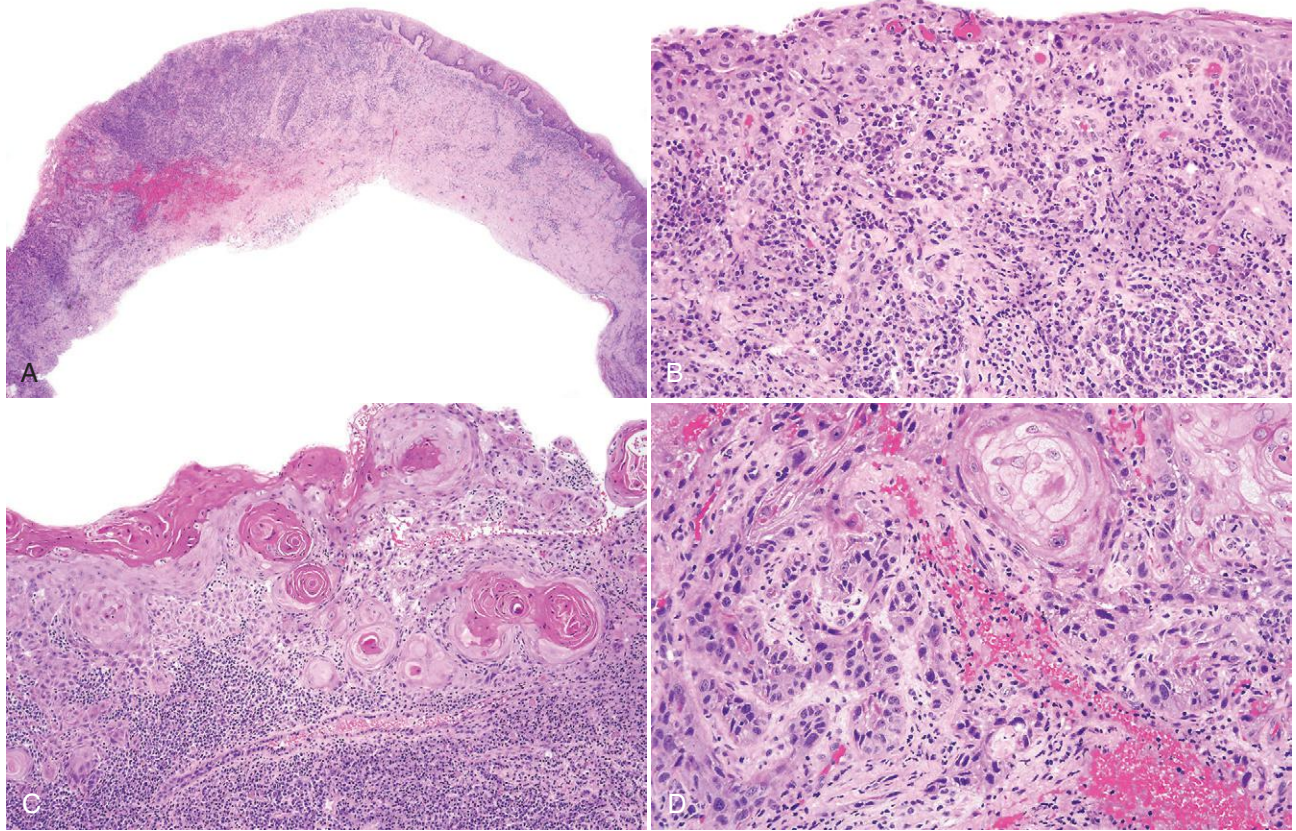


metastases to lungs, bones, and brain; one third of patients die of disease.

#### REFERENCES

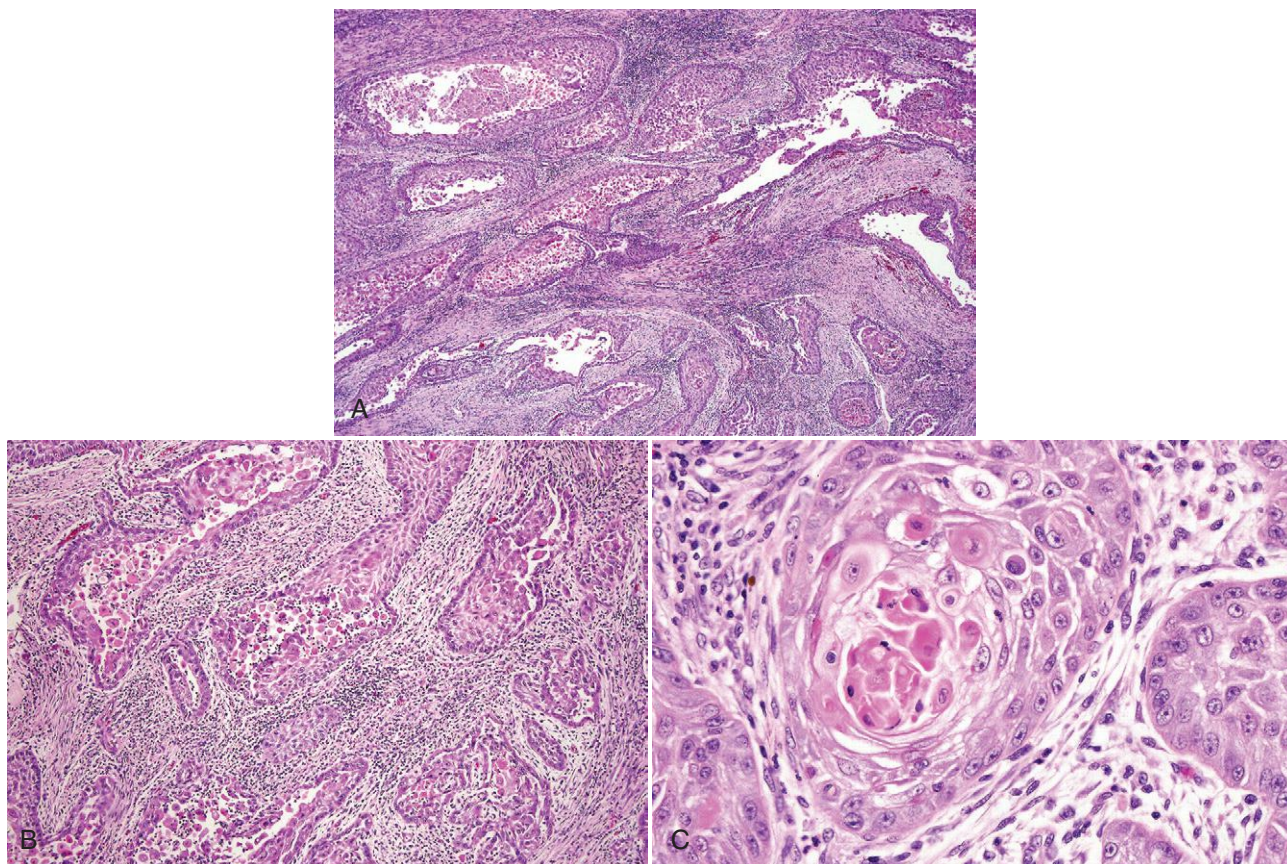
- Barnes L, Eveson J, Reichart P, Sidransky D, eds. *Pathology and Genetics of Head and Neck Tumors*. Lyon, France: IARC Press; 2005.
- Bodner L, Manor E, Shear M, van der Waal I. Primary intraosseous squamous cell carcinoma arising in an odontogenic cyst—a clinicopathologic analysis of 116 reported cases. *J Oral Pathol Med*. 2011; epub ahead of print.

- Chaisuparat R, Coletti D, Kolokythas A, et al. Primary intraosseous odontogenic carcinoma arising in an odontogenic cyst or de novo: a clinicopathologic study of six new cases. *Oral Surg Oral Med Oral Pathol Oral Radiol Endod*. 2006;101:194-200.
- Huang JW, Luo HY, Li Q, Li TJ. Primary intraosseous squamous cell carcinoma of the jaws. Clinicopathologic presentation and prognostic factors. *Arch Pathol Lab Med*. 2009;133:1834-1840.
- Lugakingira M, Pytynia K, Kolokythas A, Miloro M. Primary intraosseous carcinoma of the mandible: case report and review of the literature. *J Oral Maxillofac Surg*. 2010;68:2623-2629.



**FIGURE 15-24.** Primary intraosseous squamous cell carcinoma. **A**, Cystic lining showing malignant transformation on the left. **B**, Poorly differentiated infiltrating carcinoma arising from cyst lining. **C**, Other areas show keratinizing and infiltrating carcinoma arising from cyst lining that is dysplastic. **D**, Tumor exhibits keratin pearl formation and contains pleomorphic cells.





**FIGURE 15-25.** Primary intraosseous squamous cell carcinoma. **A**, Infiltrating islands of carcinoma with an ameloblastomatous appearance. **B**, Some, but not all, islands show palisading of basal cells; squamous cells exhibit prominent dyskeratosis. **C**, Keratin pearl formation and nuclear atypia without peripheral palisaded cells.

## CLEAR CELL ODONTOGENIC CARCINOMA

### Clinical Findings

- Sixth decade; 2:1 female predisposition; 75% occur in the mandible; pain, loosening of teeth, and paresthesia are often present, and it presents as a poorly demarcated radiolucency.

### Histopathologic Features

- This is an infiltrative tumor that is composed of islands and lobules of round or polyhedral cells with well-defined borders and pale eosinophilic or clear cytoplasm, and small round-to-ovoid hyperchromatic nuclei with small nucleoli; atypia may be minimal, and mitoses may be present (Fig. 15-26); cells contain glycogen and are positive for cytokeratin (AE1/AE3, CK5/6, and CK19 among others) and EMA and are negative for S-100 protein and myoepithelial markers; stroma is fibrous; if the pale eosinophilic cells are more prominent, the term *biphasic* type is sometimes used; often, the peripheral cells exhibit subtle palisading of the basal cell nuclei, reminiscent of ameloblastoma.

### Differential Diagnosis

- Clear cell calcifying epithelial odontogenic tumor has amyloid in the stroma.
- Clear cell mucoepidermoid carcinoma has mucous and epidermoid components, even if present focally.
- Clear cell variant of acinic cell adenocarcinoma has cells that contain periodic acid–Schiff (PAS)-positive, diastase-resistant zymogen granules.
- Clear cell adenocarcinoma of salivary gland origin may show glandular differentiation and is extremely uncommon as a primary intraosseous tumor.
- Epithelial-myoepithelial carcinoma is usually biphasic and contains myoepithelial cells.
- Metastatic renal cell carcinoma has nests of atypical clear cells that are CD10 and renal cell carcinoma antigen positive, with surrounding dilated vessels; other metastatic tumors can be ruled out with appropriate immunohistochemical stains and identification of primary site.



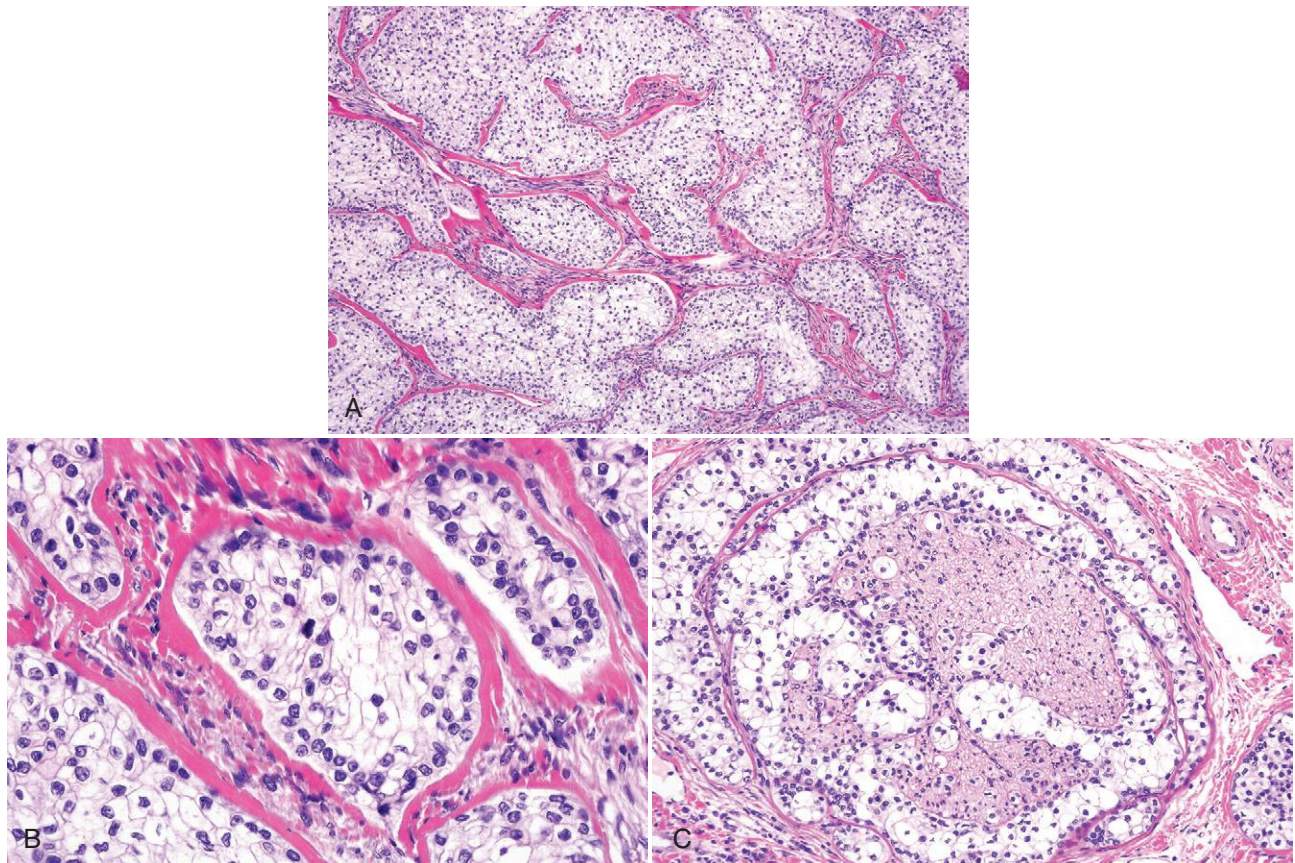
### Management and Prognosis

- En bloc resection is the treatment of choice, and adjuvant radiotherapy is used for selected cases; there is a recurrence rate of 30% of resected and 87% of curretted/enucleated lesions; metastases are to lymph nodes, lung, and bones, and 25% of patients die of the disease.

### REFERENCES

- August M, Faquin W, Troulis M, Kaban L. Clear cell odontogenic carcinoma: evaluation of reported cases. *J Oral Maxillofac Surg.* 2003;61:580-586.
- Barnes L, Eveson J, Reichart P, Sidransky D, eds. *Pathology and Genetics of Head and Neck Tumors.* Lyon, France: IARC Press; 2005.

- Bilodeau EA, Hoschar AP, Barnes EL, et al. Clear cell carcinoma and clear cell odontogenic carcinoma: a comparative clinicopathologic and immunohistochemical study. *Head Neck Pathol.* 2011;5: 101-107.
- Brandwein M, Said-Al-Naief N, Gordon R, Urken M. Clear cell odontogenic carcinoma: report of a case and analysis of the literature. *Arch Otolaryngol Head Neck Surg.* 2002;128:1089-1095.
- Iezzi G, Rubini C, Fioroni M, Piattelli A. Clear cell odontogenic carcinoma. *Oral Oncol.* 2002;38:209-213.
- Li TJ, Yu SF, Gao Y, Wang EB. Clear cell odontogenic carcinoma: a clinicopathologic and immunocytochemical study of 5 cases. *Arch Pathol Lab Med.* 2001;125:1566-1571.
- Zhang J, Liu L, Pan J, et al. Clear cell odontogenic carcinoma: report of 6 cases and review of the literature. *Med Oncol.* 2010; epub ahead of print.



**FIGURE 15-26.** Clear cell odontogenic carcinoma. **A**, Lobules of clear cells separated by hyalinized fibrous septa. **B**, Cells have clear cytoplasm, mild nuclear atypia, and subtle palisading of nuclei at periphery of lobule; a mitosis is present. **C**, Perineural and intraneural invasion present in this tumor.



## Mixed Epithelial and Ectomesenchymal Tumors

### CALCIFYING CYSTIC ODONTOGENIC TUMOR (CALCIFYING ODONTOGENIC CYST, GORLIN CYST) AND DENTINOGENIC GHOST CELL TUMOR

#### Clinical Features

- Fifty percent occur in the second and third decades; the cystic tumor manifests as a unilocular radiolucency (mixed lucency/opacity if associated with odontoma) usually of the anterior maxilla or the posterior mandible; tumor is often associated with an unerupted tooth (Fig. 15-27).
- Both the cystic tumor (85% of all cases) and dentinogenic ghost cell tumor (solid variant) also occur at peripheral (extrasosseous) sites (see Chapter 15).

#### Histopathologic Features

The equivalent skin lesion is the calcifying epithelioma of Malherbe or pilomatrixoma. The following histologic subtypes are recognized:

- *Simple cystic*: single cyst lined by squamous or stellate reticulum-like cells with slight palisading of basal cells; ghost cells are present and exhibit eosinophilic cytoplasm, an empty space in place of the nucleus, and sometimes dystrophic calcifications; eosinophilic dentinoid is variably present and often juxtaepithelial (Fig. 15-28); melanin pigment is seen infrequently; lesions are often associated with an odontoma; the simple cystic and odontoma-associated lesions represent 65% and 22%, respectively, of all lesions; some cysts show significant proliferation of the cyst lining.
- *Ameloblastomatous*: in addition to simple cystic features, there is proliferation of ameloblastoma-like cords, islands, and sheets of epithelium with palisading of basal cell nuclei with reverse polarization within the wall (Fig. 15-29).

- *Dentinogenic ghost cell tumor*: similar components without a cystic structure; ghost cells are abundant, and there may be extensive dentinoid deposition and extensive calcifications (Fig. 15-30); some tumors may have areas resembling ameloblastoma.

#### Differential Diagnosis

- Ghost cell odontogenic carcinoma is infiltrative and exhibits mitotic activity, nuclear atypia, and/or necrosis. Lesions may arise de novo or from a preexisting cystic or solid tumor and sometimes from recurrent lesions.

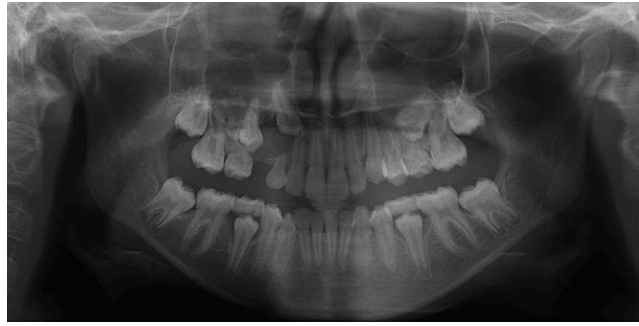
#### Management and Prognosis

- Enucleation/excision is the treatment of choice; the cystic variant has a recurrence rate of 5%, and the solid variant of 17%; solid tumors should be treated with wider margins of excision.

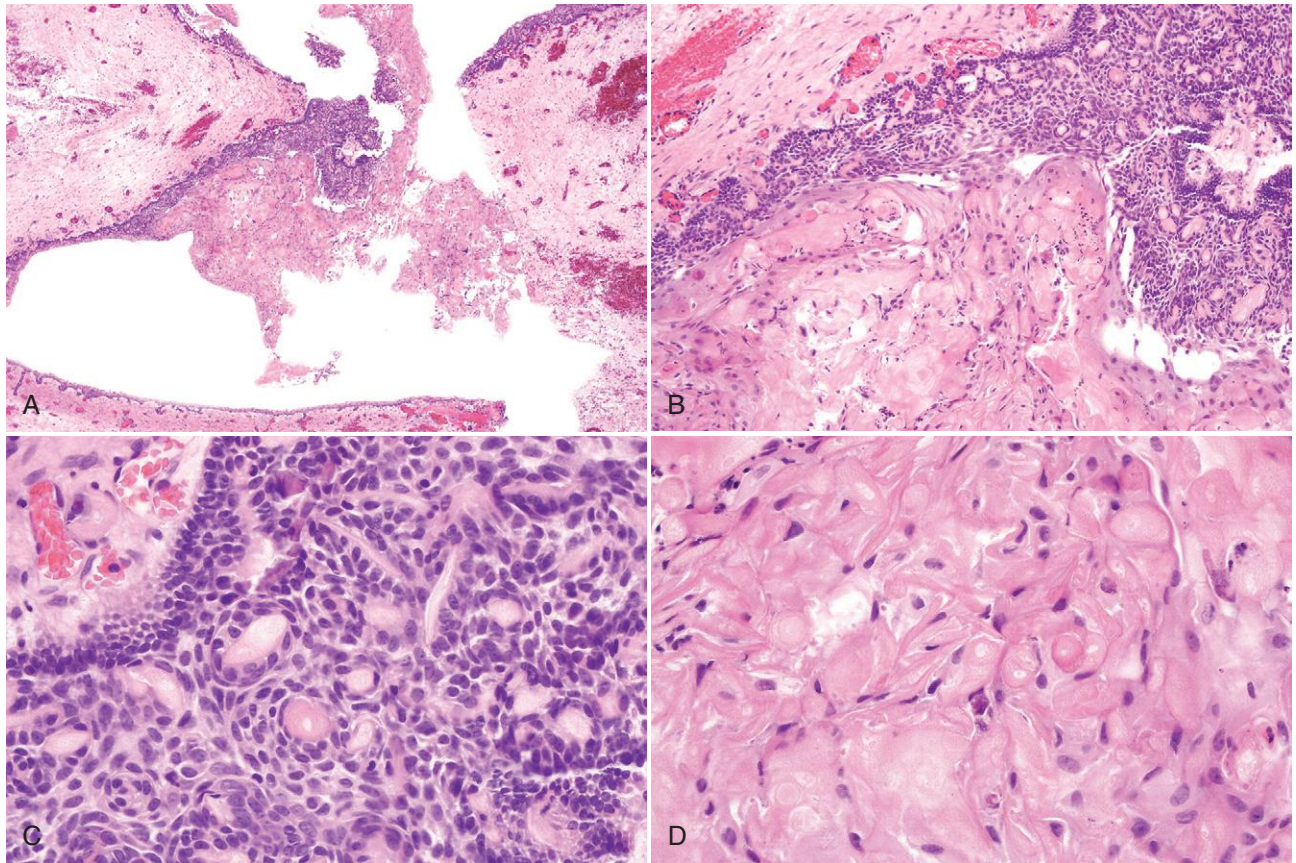
#### REFERENCES

- Barnes L, Eveson J, Reichart P, Sidransky D, eds. *Pathology and Genetics of Head and Neck Tumors*. Lyon, France: IARC Press; 2005.
- Buchner A. The central (intraosseous) calcifying odontogenic cyst: an analysis of 215 cases. *J Oral Maxillofac Surg*. 1991;49:330-339.
- Goldenberg D, Sciubba J, Tufano RP. Odontogenic ghost cell carcinoma. *Head Neck*. 2004;26:378-381.
- Hong SP, Ellis GL, Hartman KS. Calcifying odontogenic cyst. A review of ninety-two cases with reevaluation of their nature as cysts or neoplasms, the nature of ghost cells, and subclassification. *Oral Surg Oral Med Oral Pathol*. 1991;72:56-64.
- Ledesma-Montes C, Gorlin RJ, Shear M, et al. International collaborative study on ghost cell odontogenic tumours: calcifying cystic odontogenic tumour, dentinogenic ghost cell tumour and ghost cell odontogenic carcinoma. *J Oral Pathol Med*. 2008;37:302-308.
- Li TJ, Yu SF. Clinicopathologic spectrum of the so-called calcifying odontogenic cysts: a study of 21 intraosseous cases with reconsideration of the terminology and classification. *Am J Surg Pathol*. 2003;27:372-384.
- Li BH, Cho YA, Kim SM, et al. Recurrent odontogenic ghost cell carcinoma (OGCC) at a reconstructed fibular flap: A case report with immunohistochemical findings. *Med Oral Patol Oral Cir Bucal*. 2011;16:e651-e656.
- Sun G, Huang X, Hu Q, et al. The diagnosis and treatment of dentinogenic ghost cell tumor. *Int J Oral Maxillofac Surg*. 2009;38:1179-1183.



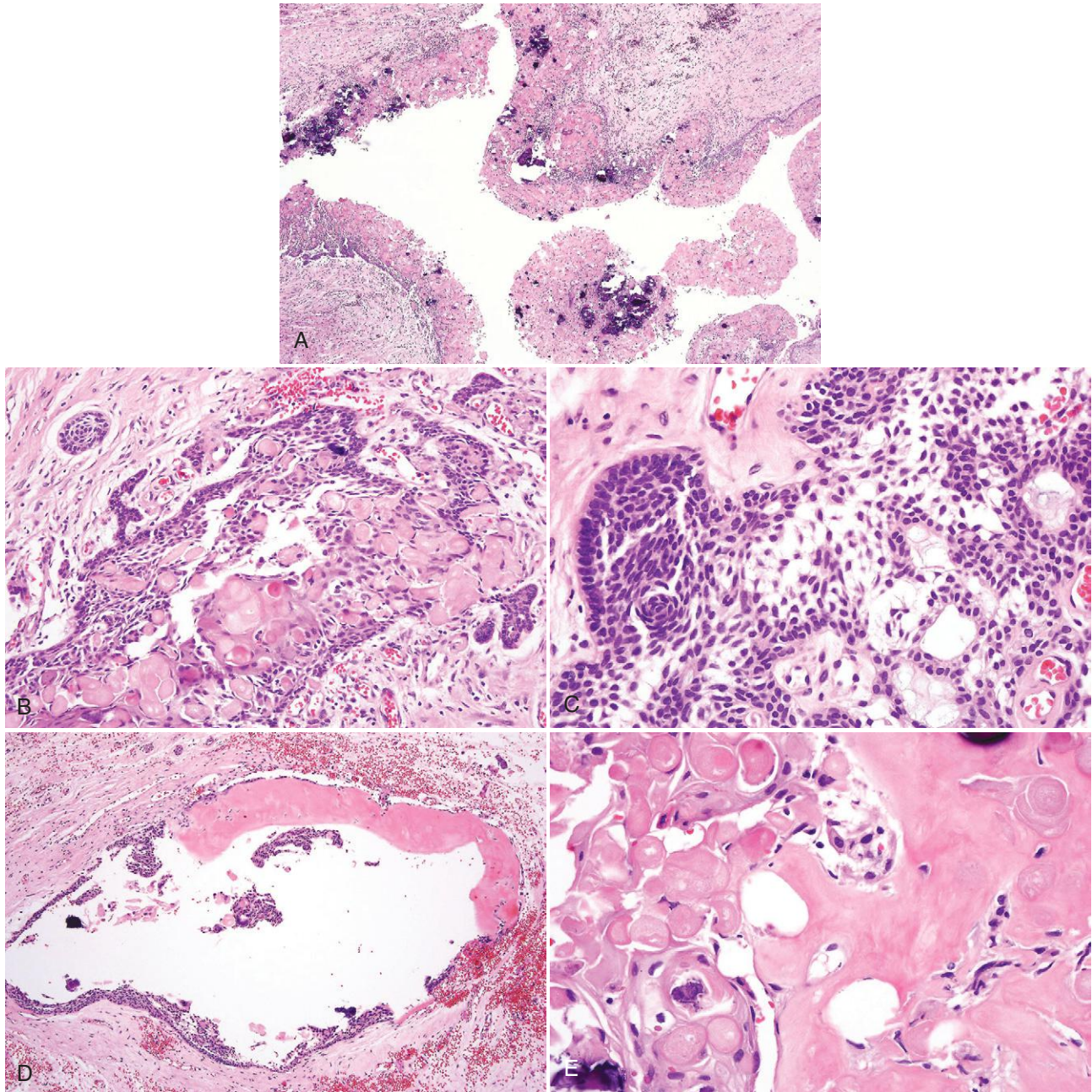


**FIGURE 15-27.** Calcifying cystic odontogenic tumor: associated with impacted canine. (Courtesy of Dr. Hugh Phillis, Tufts University School of Dental Medicine, Boston.)



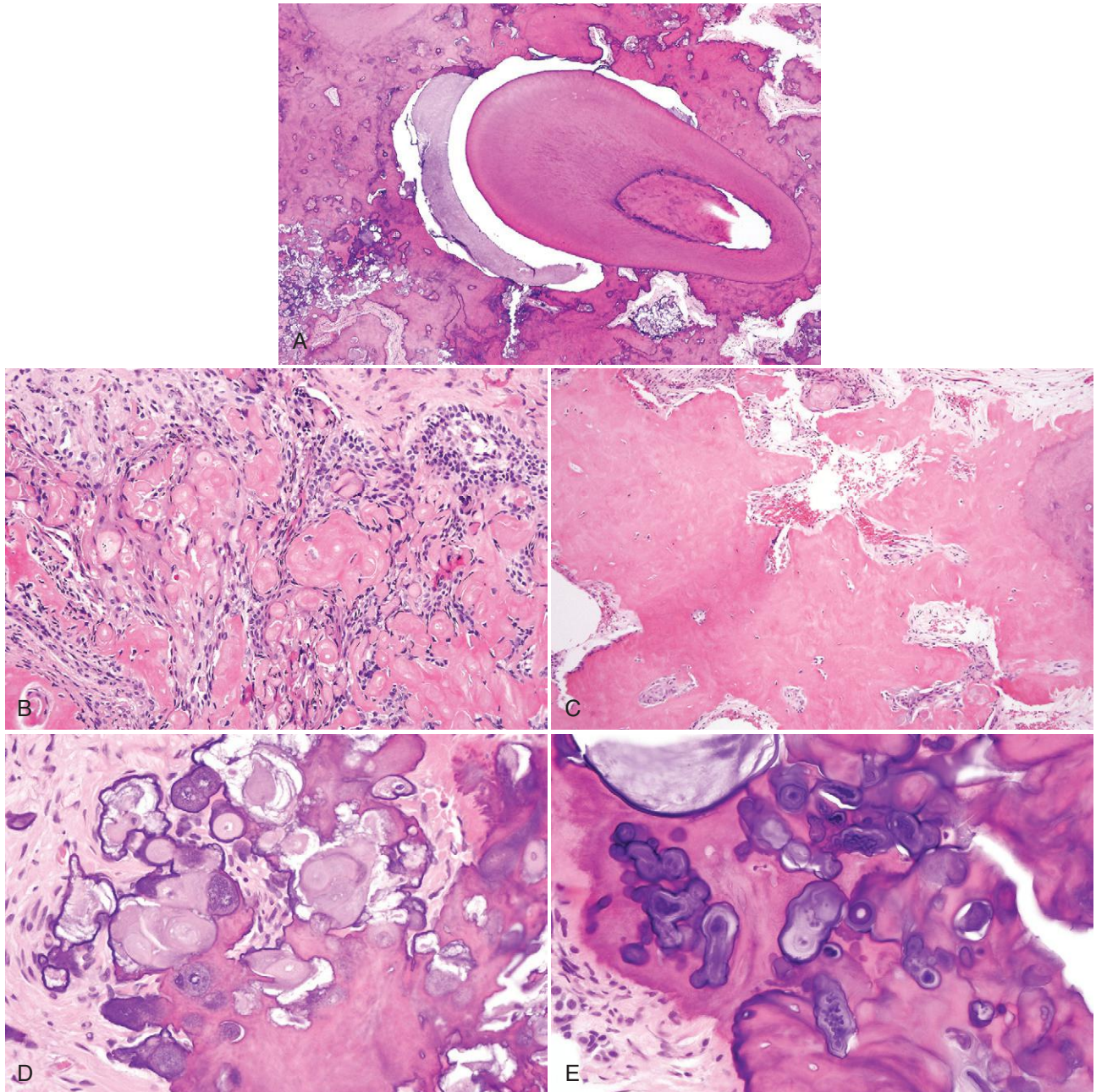
**FIGURE 15-28.** Calcifying cystic odontogenic tumor: **A**, Simple cystic type. **B**, Epithelial proliferation and ghost cells. **C**, Lining epithelium with a few ghost cells; basal cells are slightly palisaded. **D**, Typical ghost cells with abundant eosinophilic cytoplasm and space where the nucleus should be.





**FIGURE 15-29.** Calcifying cystic odontogenic tumor: **A**, Cyst with many ghost cells and dystrophic calcifications. **B**, Epithelial proliferation with ghost cells. **C**, Ameloblastomatous areas with basal cell nuclear palisading and stellate reticulum–like areas. **D**, Juxtaepithelial dentinoid deposition. **E**, Dentinoid encircling ghost cells that exhibit early dystrophic calcifications.





**FIGURE 15-30.** Dentinogenic ghost cell tumor with odontoma. **A**, Toothlike structure with pale cap of enamel matrix surrounded by calcified dentinoid. **B**, Odontogenic epithelium with ghost cells. **C**, Masses of dentinoid with early calcifications (*right*) and some epithelium and ghost cells. **D**, Ghost cells undergoing calcification surrounded by dentinoid. **E**, Concentric Liesegang-ring calcifications.

## AMELOBLASTIC FIBROMA

### Clinical Findings

- Most common in the first and second decades of life, manifesting as swelling of the jaw: unilocular (sometimes multilocular) radiolucency usually in the mandible (75%); 90% found in the posterior aspects of the jaws (Fig. 15-31)

### Histopathologic Features

Differentiation is toward ameloblastoma and dental papilla.

- Ameloblastoma with reverse polarization of basal cells and stellate reticulum–like areas is evident; in addition, there is a cellular proliferation of spindled and stellate fibroblast-like cells with dispersed nuclear



chromatin and small or inconspicuous nuclei in an extremely myxoid/mucinous background (Fig. 15-32).

- If dentinoid is present, the diagnosis is ameloblastic fibrodentinoma.

#### Differential Diagnosis

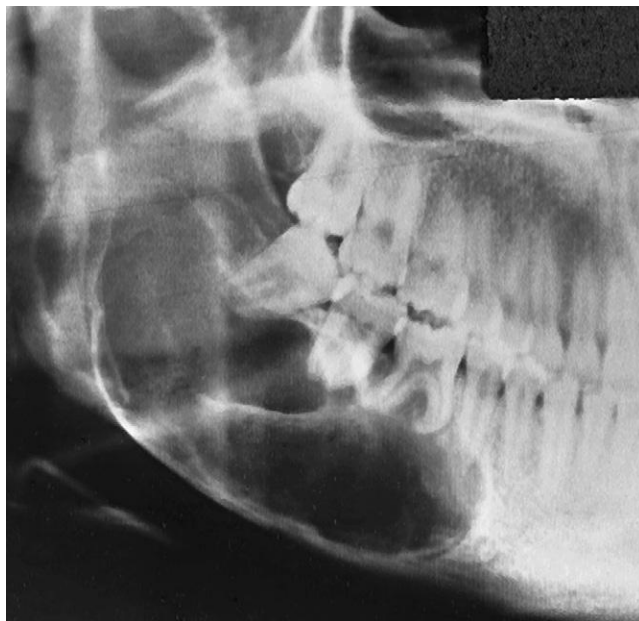
- Ameloblastic fibro-odontoma has identical soft tissue histopathology, but an odontoma is also present.
- Ameloblastic fibrosarcoma contains islands of benign epithelium typical for ameloblastoma, but there is a hypercellular proliferation of the spindle cells that show malignant morphology with hyperchromatic atypical nuclei, mitoses, and sometimes necrosis (Fig. 15-33); 44% of ameloblastic fibrosarcoma arise from preexisting ameloblastic fibroma and these occur in the fourth decade and later, whereas de novo ameloblastic fibrosarcoma occurs 1 decade earlier.

#### Management and Prognosis

- Excision or resection is the treatment of choice; recurrence is 33%; approximately 10% undergo malignant transformation to ameloblastic fibrosarcoma with younger presentation associated with increased risk; tumors do not tend to metastasize.

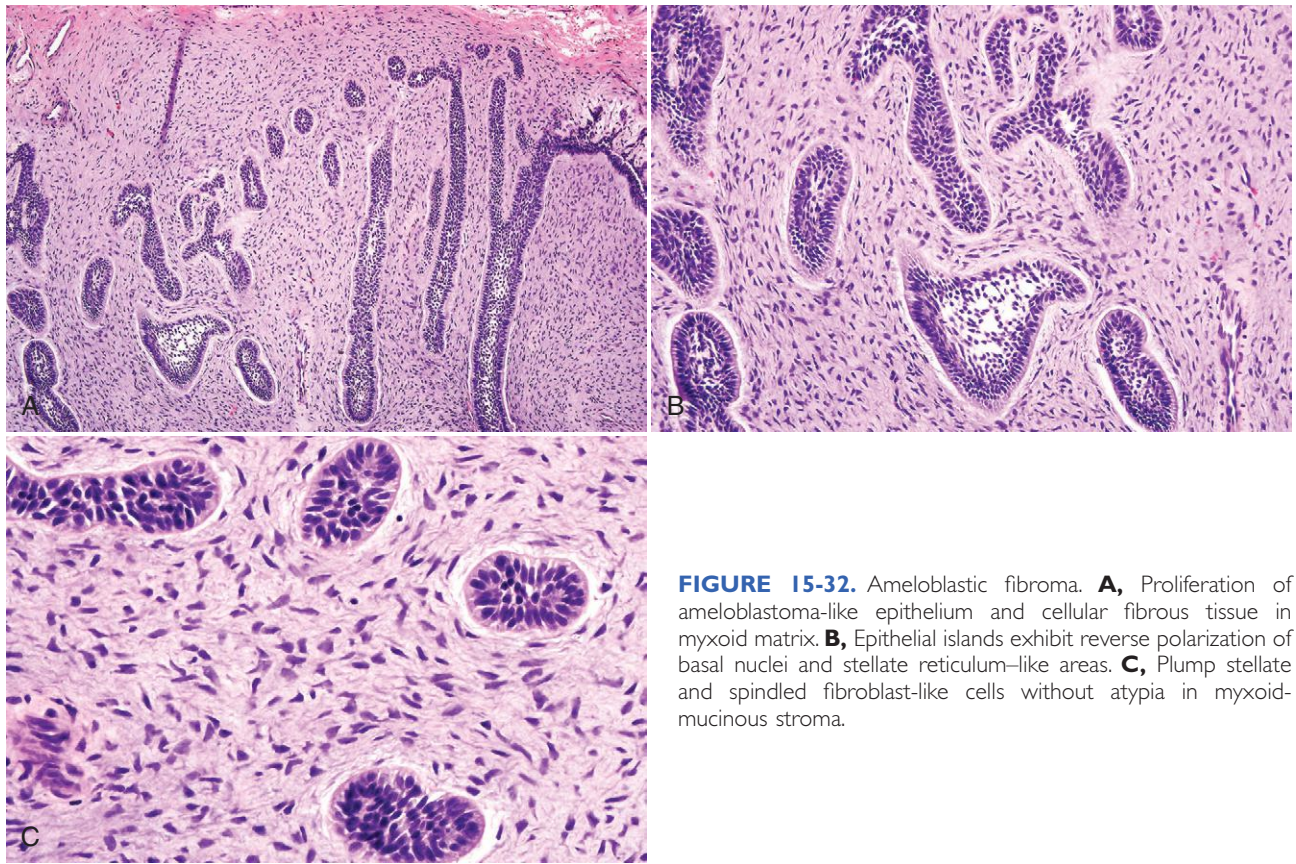
#### REFERENCES

- Abughazaleh K, Andrus KM, Katsnelson A, et al. Peripheral ameloblastic fibroma of the maxilla. *Oral Surg Oral Med Oral Pathol Oral Radiol Endod.* 2008;105:e36-e48.
- Chen Y, Wang JM, Li TJ. Ameloblastic fibroma: a review of published studies with special reference to its nature and biological behavior. *Oral Oncol.* 2007;43:960-969.
- Kobayashi K, Murakami R, Fujii T, Hirano A. Malignant transformation of ameloblastic fibroma to ameloblastic fibrosarcoma: case report and review of the literature. *J Craniomaxillofac Surg.* 2005;33:352-355.
- Muller S, Parker DC, Kapadia SB, et al. Ameloblastic fibrosarcoma of the jaws. A clinicopathologic and DNA analysis of five cases and review of the literature with discussion of its relationship to ameloblastic fibroma. *Oral Surg Oral Med Oral Pathol Oral Radiol Endod.* 1995;79:469-477.
- Philipsen HP, Reichart PA, Praetorius F. Mixed odontogenic tumours and odontomas. Considerations on interrelationship. Review of the literature and presentation of 134 new cases of odontomas. *Oral Oncol.* 1997;33:86-99.
- Slater LJ. Odontogenic sarcoma and carcinosarcoma. *Semin Diagn Pathol.* 1999;16:325-332.
- Takeda Y, Sato H, Satoh M, et al. Immunohistochemical expression of neural tissue markers (neuron-specific enolase, glial fibrillary acidic protein, S100 protein) in ameloblastic fibrodentinoma: a comparative study with ameloblastic fibroma. *Pathol Int.* 2000;50:610-615.
- Trodahl JN. Ameloblastic fibroma. A survey of cases from the Armed Forces Institute of Pathology. *Oral Surg Oral Med Oral Pathol.* 1972;33:547-558.

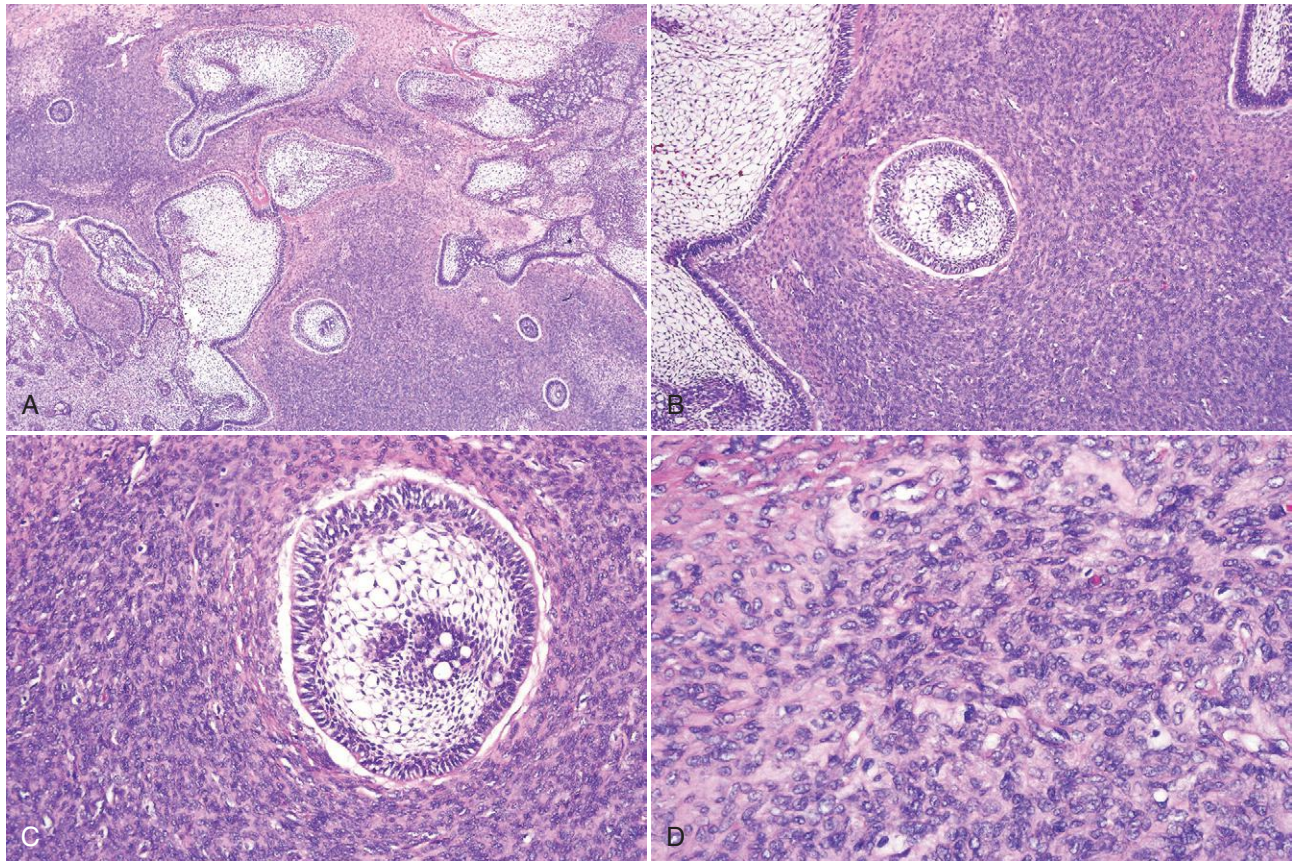


**FIGURE 15-31.** Ameloblastic fibroma: multiloculated radiolucency of the right posterior mandible body and ramus. (From White SC, Pharoah MJ: *Oral Radiology: Principles and Interpretation*. 6th ed. St. Louis, Mosby, 2009, p 381.)





**FIGURE 15-32.** Ameloblastic fibroma. **A**, Proliferation of ameloblastoma-like epithelium and cellular fibrous tissue in myxoid matrix. **B**, Epithelial islands exhibit reverse polarization of basal nuclei and stellate reticulum-like areas. **C**, Plump stellate and spindle fibroblast-like cells without atypia in myxoid-mucinous stroma.



**FIGURE 15-33.** Ameloblastic fibrosarcoma. **A**, Ameloblastoma and hypercellular stroma. **B**, Typical ameloblastoma with stellate reticulum-like areas and cellular proliferation of spindle cells. **C**, Ameloblastoma with reverse nuclear polarization of basal cells and atypical spindle cells. **D**, Atypical spindle cells with pleomorphic nuclei.



## AMELOBLASTIC FIBRO-ODONTOMA

Some pathologists believe that ameloblastic fibro-odontoma and odontoma are a spectrum of the same condition, with odontoma being the more mature lesion; other pathologists consider them to be separate entities. There is no evidence at this time to suggest that one matures into the other.

### Clinical Features

- Most cases (98%) occur in the first and second decades, with a mean age of 9 years; 54% occur in the posterior mandible, and 20% occur in the posterior maxilla; the most common presentation is a radiopacity overlying a tooth (often a permanent mandibular first molar), causing failure of eruption (Fig. 15-34).

### Histopathologic Features

This tumor recapitulates the developing tooth with a prominent soft tissue component.

- Typical ameloblastic fibroma (Figs. 15-35, *A* and *B* and 15-36, *A* and *B*) with an odontoma; odontoma is usually of the complex type, consisting of haphazard deposition of tubular dentin, dentinoid, enamel matrix (“fish scale” appearance), cementum, ringlike calcifications, and odontogenic epithelium (see Figs. 15-35, *C-F* and 15-36, *C-F*).
- S-100 protein–positive, melanin-containing stromal cells may be present.

### Differential Diagnosis

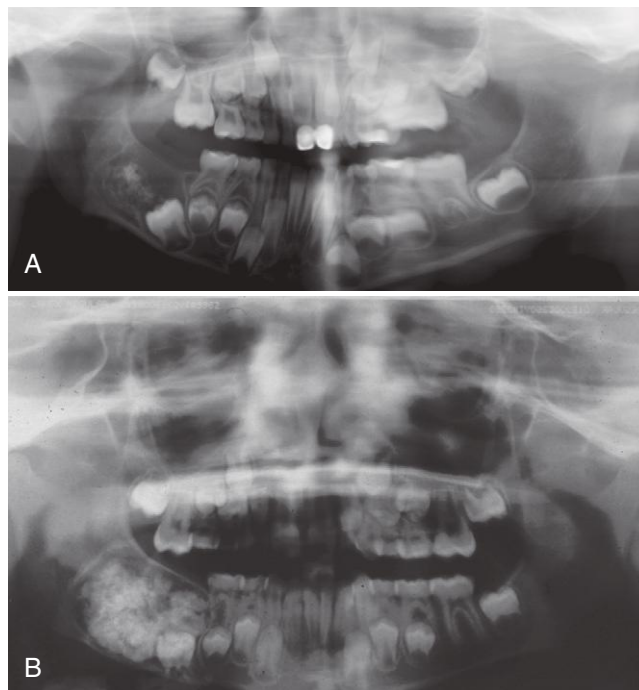
- Ameloblastic fibroma does not produce enamel, dentin, or cementum; ameloblastic fibrodentinoma produces dentinoid but not enamel matrix or tubular dentin.
- Odontoma has minimal soft tissue component and no ameloblastoma-like component.

### Management and Prognosis

- Enucleation or excision is curative.

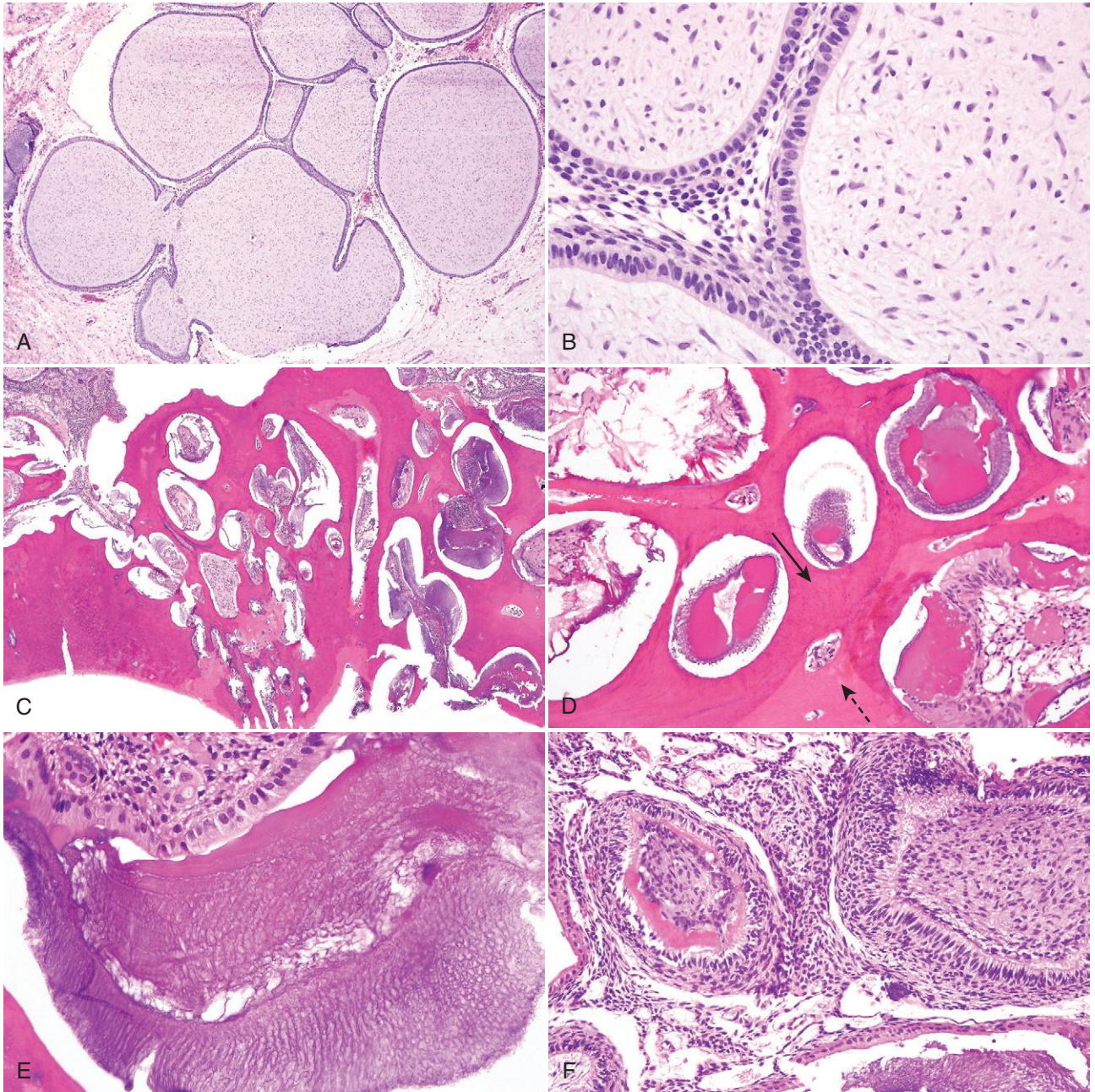
### REFERENCES

- Barnes L, Eveson J, Reichart P, Sidransky D, eds. *Pathology and Genetics of Head and Neck Tumors*. Lyon, France: IARC Press; 2005.
- Cohen DM, Bhattacharyya I. Ameloblastic fibroma, ameloblastic fibro-odontoma, and odontoma. *Oral Maxillofac Surg Clin North Am*. 2004;16:375-384.
- Philipsen HP, Reichart PA, Praetorius F. Mixed odontogenic tumours and odontomas. Considerations on interrelationship. Review of the literature and presentation of 134 new cases of odontomas. *Oral Oncol*. 1997;33:86-99.
- Phillips MD, Closmann JJ, Baus MR, et al. Hybrid odontogenic tumor with features of ameloblastic fibro-odontoma, calcifying odontogenic cyst, and adenomatoid odontogenic tumor: a case report and review of the literature. *J Oral Maxillofac Surg*. 2010;68:470-474.
- Slootweg PJ. An analysis of the interrelationship of the mixed odontogenic tumors—ameloblastic fibroma, ameloblastic fibro-odontoma, and the odontomas. *Oral Surg Oral Med Oral Pathol*. 1981;51:266-276.
- Takeda Y, Sato H, Satoh M, et al. Immunohistochemical expression of neural tissue markers (neuron-specific enolase, glial fibrillary acidic protein, S100 protein) in ameloblastic fibrodentinoma: a comparative study with ameloblastic fibroma. *Pathol Int*. 2000; 50:610-615.



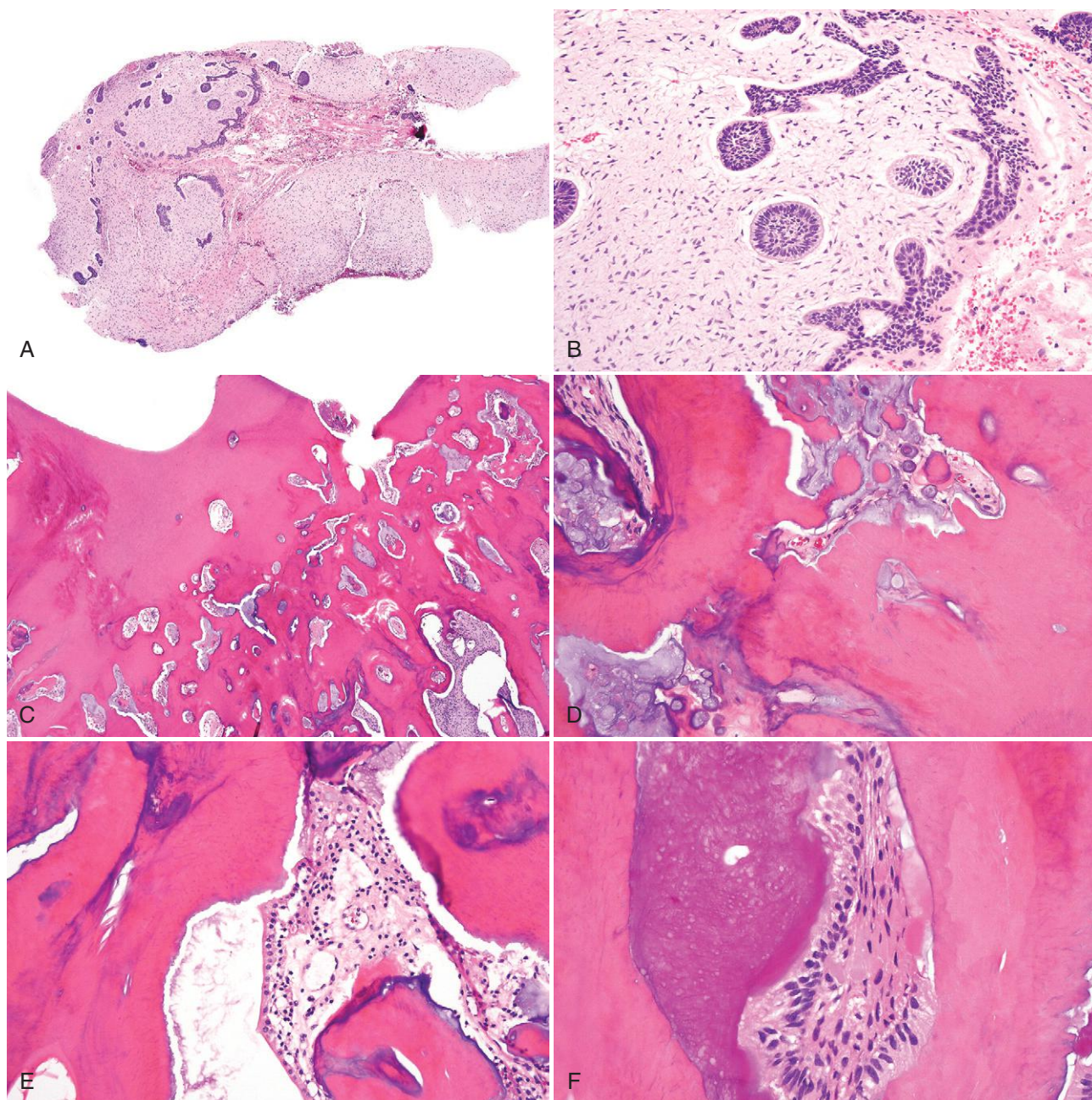
**FIGURE 15-34.** Ameloblastic fibro-odontoma. **A**, Well-circumscribed radiolucency with radiopacities above crown of inferiorly displaced right permanent first molar. **B**, Well-circumscribed radiolucency with dense radiopaque mass above crown of inferiorly displaced right permanent first molar. (**A**, Courtesy of Dr. Lawrence M. Juvet, private practice, Brockton, Mass.)





**FIGURE 15-35.** Ameloblastic fibro-odontoma. **A**, Area of ameloblastic fibroma with proliferation of epithelium and spindle cells in myxoid stroma. **B**, Ameloblastoma-like epithelium with palisading of basal cell and stellate reticulum-like areas; many stellate fibroblast-like cells in myxoid stroma. **C**, Odontoma composed of masses of tubular dentin and dentinoid. **D**, Dentin (*solid arrow*), dentinoid (*dashed arrow*), enamel matrix (basophilic material), and odontogenic epithelium. **E**, Enamel matrix with fish-scale appearance. **F**, Proliferation of polygonal, columnar, and spindled odontogenic epithelium with amorphous dentinoid suggestive of abortive odontogenesis.





**FIGURE 15-36.** Ameloblastic fibro-odontoma. **A**, Ameloblastic fibroma with proliferation of epithelium and spindle cells in myxoid stroma. **B**, Ameloblastoma-like epithelium with palisading of basal cells and stellate reticulum-like areas; many stellate fibroblast-like cells in myxoid stroma. **C**, Masses of dentin. **D**, Tubular dentin and ringlike calcifications. **E**, Tubular dentin and odontogenic epithelium. **F**, Tubular dentin, enamel matrix, and odontogenic epithelium.

## ODONTOMA

This is the most common odontogenic tumor.

### Clinical Features

- Lesion usually occurs in the second and third decades; complex odontomas are most common in the posterior mandible and anterior maxilla; compound odontomas are most common in the anterior maxilla; the mesiodens is a supernumerary or anomalous tooth located between maxillary central incisors.

- Radiopacity or radiopacities are visible with surrounding rim of radiolucency; recognizable tooth structures or denticles are present in compound odontomas; complex odontomas manifest as globular calcified masses (Fig. 15-37).

### Histopathologic Features

Odontomas are considered hamartomas, and they recapitulate the development of a tooth, either in an organized (compound odontoma) or disorganized (complex odontoma) fashion.



- Compound odontoma: enamel matrix (basophilic fish-scale appearance), tubular dentin, cementum, and dental papilla (myxoid/mucinous material with stellate fibroblasts) present in the configuration of a tooth with varying amounts of odontogenic epithelium; the term *anomalous tooth* is sometimes used for a single, tooth-like structure (Fig. 15-38); a dental follicle surrounds the lesion.
- Complex odontoma is composed of dental hard tissues admixed with eosinophilic dentinoid, cemento-osseous material, strands and islands of odontogenic epithelium, and dental papillae in haphazard fashion (Fig. 15-39); ghost cells (11% to 16% of cases), ring-like calcifications, enameloid, amyloid-like material, and ductlike structures may be present; rare cases contain melanin.
- Odontomas may be associated with other odontogenic lesions, in particular, calcifying cystic odontogenic tumor or adenomatoid odontogenic tumor.

#### Differential Diagnosis

- Ameloblastic fibro-odontoma has areas of ameloblastic fibroma.
- Ameloblastic odontoma (odontoameloblastoma) contains an odontoma and an area of typical ameloblastoma and may behave aggressively.

#### Management and Prognosis

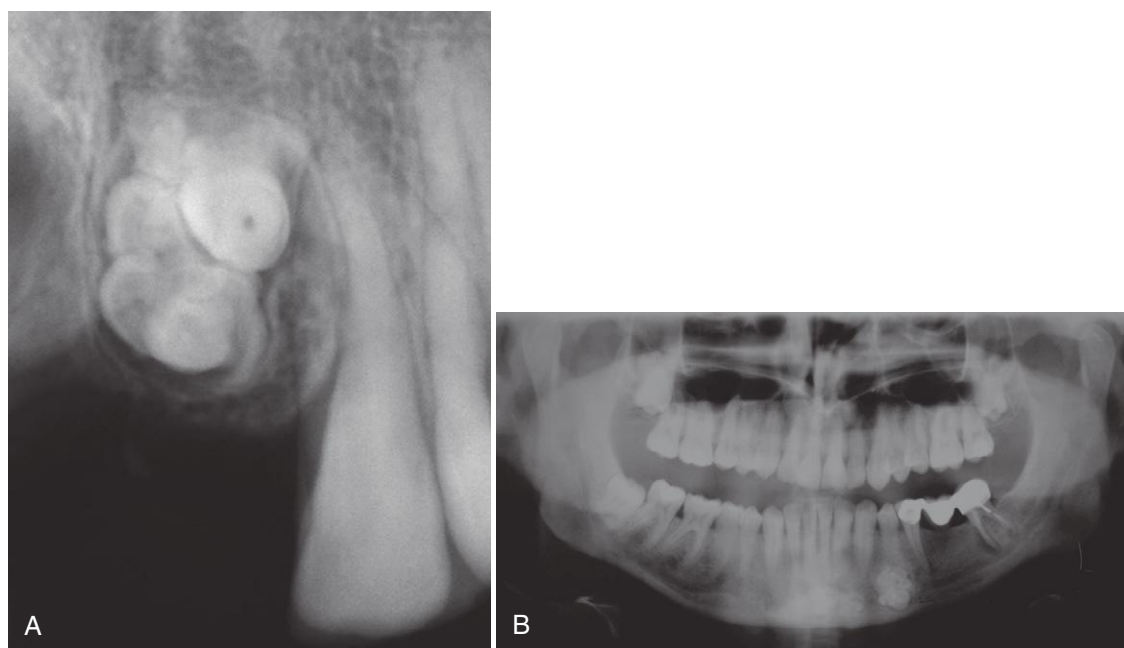
- Excision is curative.

#### (Hybrid) Odontogenic Tumors

Some odontogenic tumors exhibit features of several different tumors. Common features are ameloblastic epithelium (basal palisading cells with stellate reticulum-like areas), nondescript odontogenic epithelium, ghost cells, ductlike structures similar to adenomatoid odontogenic tumor, deposition of dentinoid, cementum, or amyloid-like material, and ringlike calcifications. These structures may be organized into classifiable tumors such as calcifying epithelial odontogenic tumor or adenomatoid odontogenic tumor.

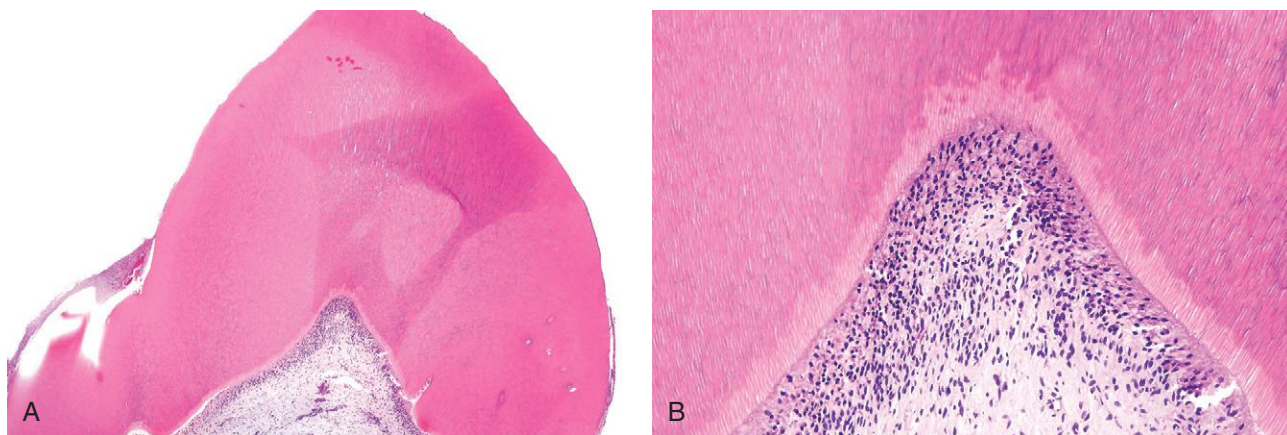
#### REFERENCES

- Cohen DM, Bhattacharyya I. Ameloblastic fibroma, ameloblastic fibro-odontoma, and odontoma. *Oral Maxillofac Surg Clin North Am.* 2004;16:375-384.
- Phillips MD, Closmann JJ, Baus MR, et al. Hybrid odontogenic tumor with features of ameloblastic fibro-odontoma, calcifying odontogenic cyst, and adenomatoid odontogenic tumor: a case report and review of the literature. *J Oral Maxillofac Surg.* 2010;68:470-474.
- Philipsen HP, Reichart PA, Praetorius F. Mixed odontogenic tumours and odontomas. Considerations on interrelationship. Review of the literature and presentation of 134 new cases of odontomas. *Oral Oncol.* 1997;33:86-99.
- Slootweg PJ. An analysis of the interrelationship of the mixed odontogenic tumors—ameloblastic fibroma, ameloblastic fibro-odontoma, and the odontomas. *Oral Surg Oral Med Oral Pathol.* 1981;51:266-276.
- Takeda Y, Sato H, Satoh M, et al. Immunohistochemical expression of neural tissue markers (neuron-specific enolase, glial fibrillary acidic protein, S100 protein) in ameloblastic fibrodentinoma: a comparative study with ameloblastic fibroma. *Pathol Int.* 2000;50:610-615.
- Tomizawa M, Otsuka Y, Noda T. Clinical observations of odontomas in Japanese children: 39 cases including one recurrent case. *Int J Paediatr Dent.* 2005;15:37-43.

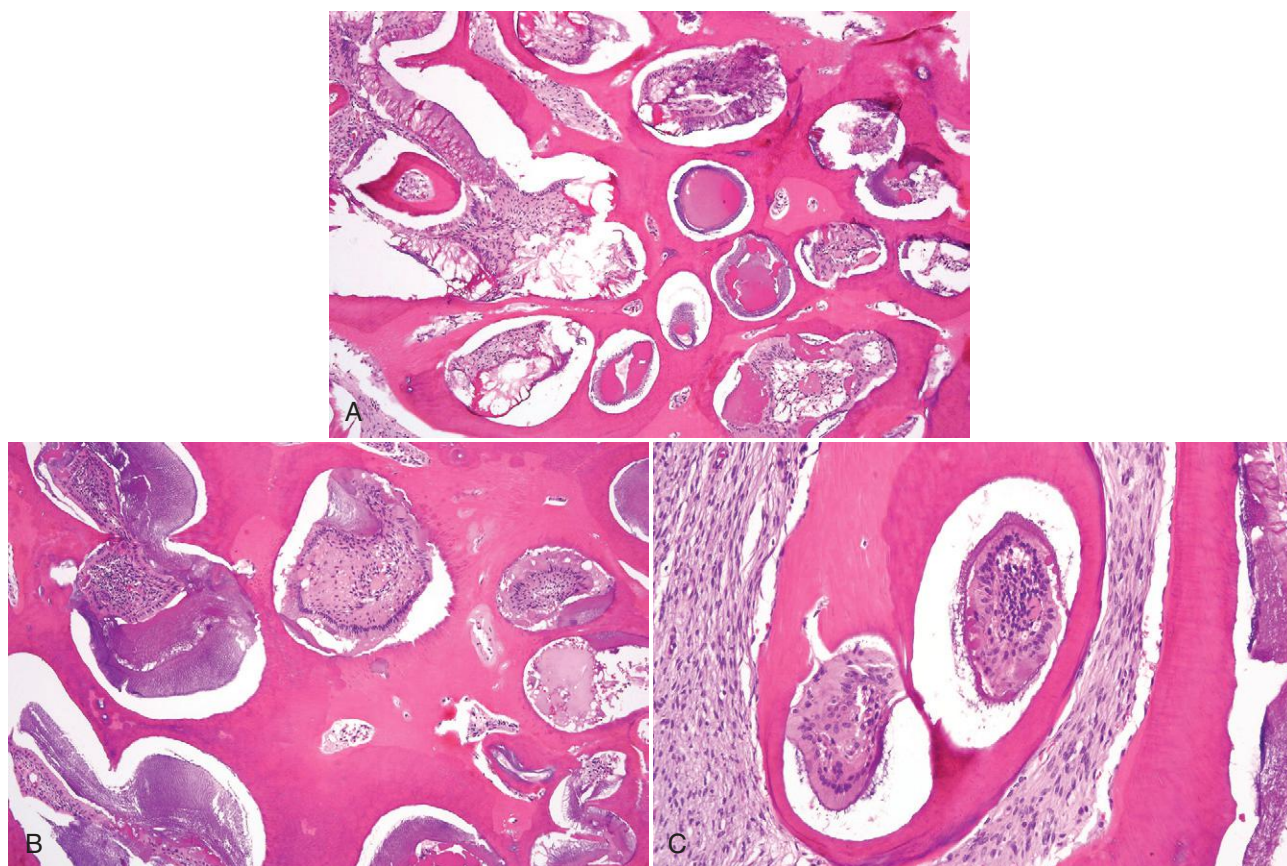


**FIGURE 15-37.** **A**, Compound odontoma; recognizable toothlike structures with thin, radiolucent rim. **B**, Complex odontoma; globular masses of calcified material near the apex of the left mandibular first premolar. (**A**, Courtesy of Dr. John Sexton, private practice, Wellesley, Mass; **B**, Courtesy of Dr. Bruce Sullivan, private practice, Norwood, Mass.)





**FIGURE 15-38.** Compound odontoma (from Fig.15-37, A). **A**, Toothlike structure with dentinal tubules, enamel matrix (left), and dental papilla. **B**, Tubular dentin formed by odontoblasts within myxoid and primitive dental papilla.



**FIGURE 15-39.** Complex odontoma. **A**, Haphazard arrangement of tubular dentin, strands of pale eosinophilic odontogenic epithelium, and basophilic enamel matrix. **B**, Basophilic enamel matrix, tubular dentin, and fibrous tissue. **C**, Tubular dentin, columnar, pale eosinophilic odontogenic epithelium, and fibrous stroma.



## Mesenchymal Tumors

### CENTRAL ODONTOGENIC FIBROMA

These lesions are classified as simple or epithelium-poor type (mostly fibrous tissue with little epithelium or dentinoid) and World Health Organization (WHO) classification or as complex or epithelium-rich type (epithelium invariably present, sometimes with dentinoid). Odontogenic fibroma devoid of epithelial rests is either very rare, if it exists at all, or represents dental follicle.

#### Clinical Features

- Occurs in fourth decade; unilocular radiolucency is present, usually in the mandible (Fig. 15-40); peripheral (extraosseous) counterpart is discussed in Chapter 5.

#### Histopathologic Features

Differentiation is toward dental follicle-like tissue.

- Proliferation of fibroblast-like spindle cells in a densely or delicately collagenized stroma; some tumors have a myxoid stroma; odontogenic epithelium may be sparse and often contains clear cells; hyaline globules (basement membrane-like material) or ductlike structures may be present (Fig. 15-41); eosinophilic material (dentinoid) may be present (Fig. 15-42); epithelium is positive for AE1/AE3, CK14, CK19, and other cytokeratins.
- Areas similar to central giant cell granuloma (see Chapter 16) are sometimes present.

#### Differential Diagnosis

- Cases that look similar to odontogenic fibroma occurring around the crowns of impacted teeth are almost always hyperplastic dental follicles.

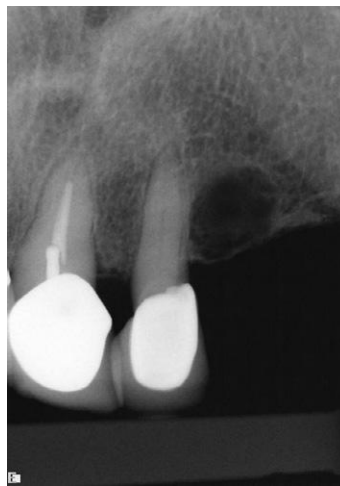- Odontogenic fibromyxoma, which tends to be epithelium poor and very myxoid, does not produce dentinoid.
- Desmoplastic fibroma is more densely collagenized and does not contain epithelium or dentinoid; it is often beta-catenin positive and behaves in a locally aggressive fashion.
- Metastatic carcinoma exhibits cytologic atypia and desmoplasia around epithelial islands.

#### Management and Prognosis

- Enucleation or curettage is the primary mode of treatment; recurrence rate is 4%; lesions associated with giant cell granuloma are particularly prone to recur (in up to 13% of cases).

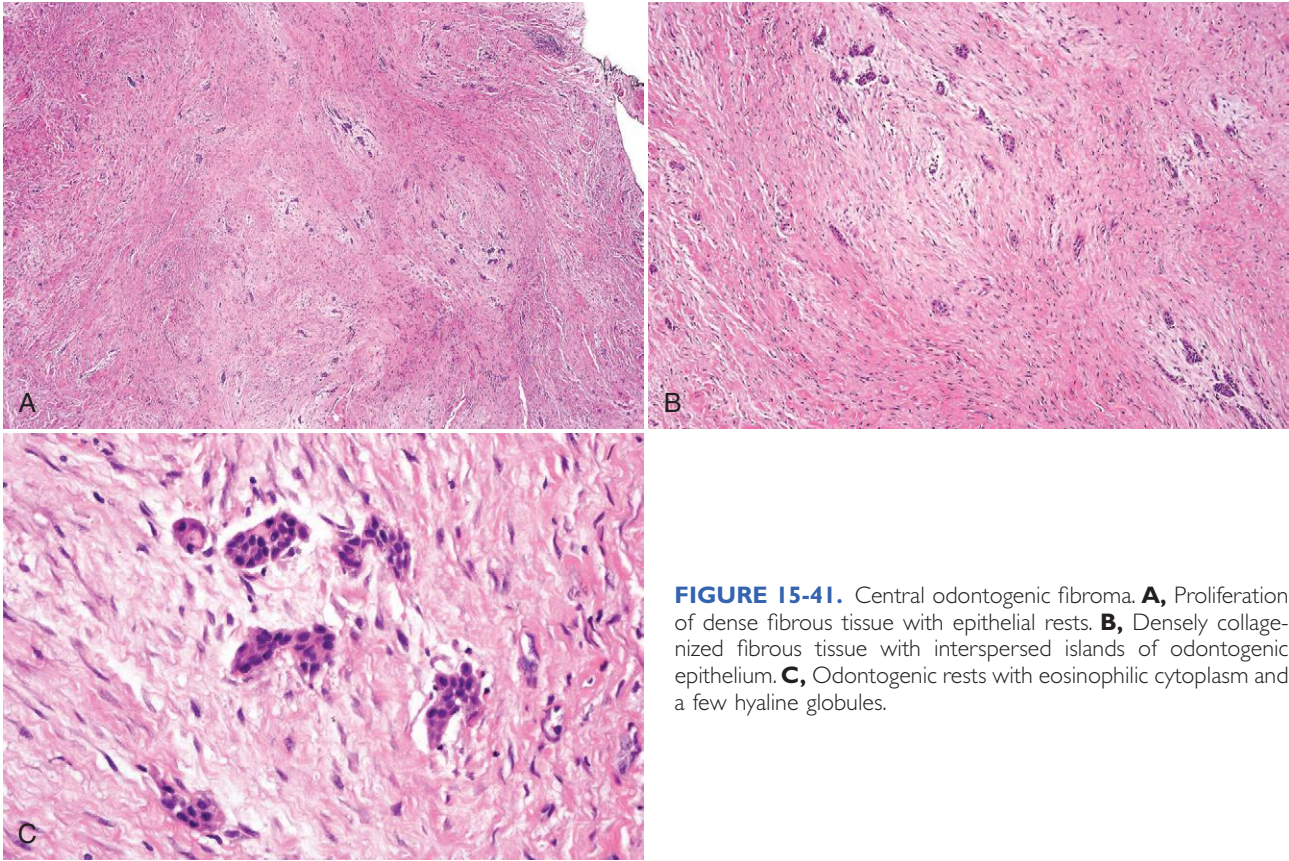
#### REFERENCES

- Brannon RB. Central odontogenic fibroma, myxoma (odontogenic myxoma, fibromyxoma), and central odontogenic granular cell tumor. *Oral Maxillofac Surg Clin North Am.* 2004;16:359-374.
- Gardner DG. Central odontogenic fibroma current concepts. *J Oral Pathol Med.* 1996;25:556-561.
- Handlers JP, Abrams AM, Melrose RJ, Danforth R. Central odontogenic fibroma: clinicopathologic features of 19 cases and review of the literature. *J Oral Maxillofac Surg.* 1991;49:46-54.
- Mosqueda-Taylor A, Martinez-Mata G, Carlos-Bregni R, et al. Central odontogenic fibroma: new findings and report of a multicentric collaborative study. *Oral Surg Oral Med Oral Pathol Endod.* 2011; 112:349-358.
- Odell EW, Lombardi T, Barrett AW, et al. Hybrid central giant cell granuloma and central odontogenic fibroma-like lesions of the jaws. *Histopathology.* 1997;30:165-171.
- Raubenheimer EJ, Noffke CE. Central odontogenic fibroma-like tumors, hypodontia, and enamel dysplasia: review of the literature and report of a case. *Oral Surg Oral Med Oral Pathol Oral Radiol Endod.* 2002;94:74-77.
- Younis RH, Schepher MA, Lindquist CC, Levy B. Hybrid central odontogenic fibroma with giant cell granuloma-like component: case report and review of literature. *Head Neck Pathol.* 2008;2: 222-226.

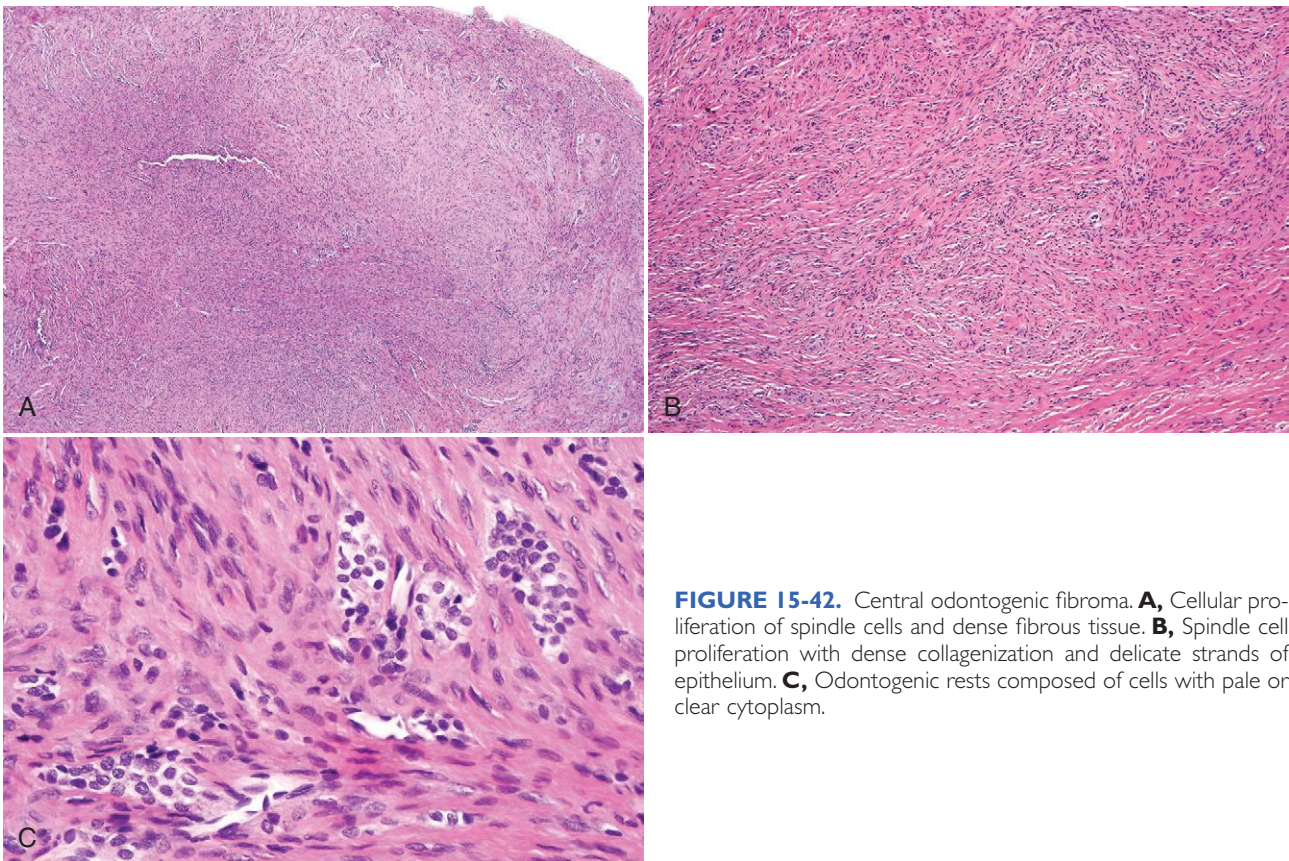


**FIGURE 15-40.** Central odontogenic fibroma manifesting as radiolucency at site of previously extracted left maxillary canine. (Courtesy of Dr. Evetta Shwartzman, private practice, Canton, Mass.)





**FIGURE 15-41.** Central odontogenic fibroma. **A**, Proliferation of dense fibrous tissue with epithelial rests. **B**, Densely collagenized fibrous tissue with interspersed islands of odontogenic epithelium. **C**, Odontogenic rests with eosinophilic cytoplasm and a few hyaline globules.



**FIGURE 15-42.** Central odontogenic fibroma. **A**, Cellular proliferation of spindle cells and dense fibrous tissue. **B**, Spindle cell proliferation with dense collagenization and delicate strands of epithelium. **C**, Odontogenic rests composed of cells with pale or clear cytoplasm.



## ODONTOGENIC MYXOMA

### Clinical Findings

- Occurs in second to fourth decade; often causing jaw bone expansion, with 2:1 female predilection; lesion is a poorly circumscribed, multilocular, or honey-combed radiolucency (60%), usually in the posterior maxilla or mandible; lesions are often associated with root resorption and perforation of the cortex; many are described as having a tennis racket appearance radiographically (Fig. 15-43).
- Mandibular lesions may involve the ramus extensively and maxillary lesions often involve the sinus.

### Histopathologic Features

This tumor recapitulates the dental papilla.

- Unencapsulated and infiltrative proliferation of spindle, bipolar, and stellate cells with bland nuclei is present within a mucinous/myxoid stroma that contains abundant hyaluronic acid; islands of odontogenic epithelium are noted in less than 10% of cases, although they are revealed by AE1/AE3 and CK14 staining in 25% of cases (Fig. 15-44); perivascular hyalinization may be seen, usually with no calcified product formed, although there is one report of extensive calcifications.
- Spindle cells are S-100 negative; approximately 45% are SMA positive and up to 25% are HHF45 positive, suggesting the presence of myofibroblasts; mast cells are present in more than 70% of cases.

### Differential Diagnosis

- Dental papilla (immature dental pulp from a developing tooth or odontoma) is often mistaken for

myxoma; a rim of odontoblasts is present at the periphery of the dental papilla, which has an ovoid shape (Fig. 15-45).

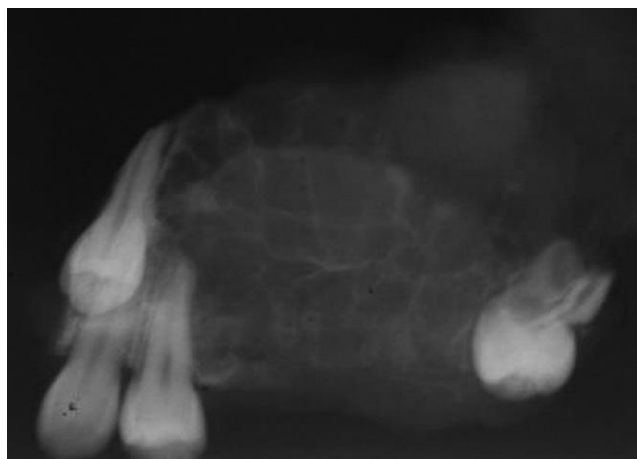- Intraosseous nerve sheath tumors are S-100 positive.
- Chondromyxoid fibromas contain chondroid areas, are less homogeneous with areas of cellularity, and are often multilobular.

### Management and Prognosis

- Marginal resection is recommended for smaller tumors and segmental resection is recommended for larger tumors.
- Recurrence rate is up to 33%, depending on the mode of therapy.

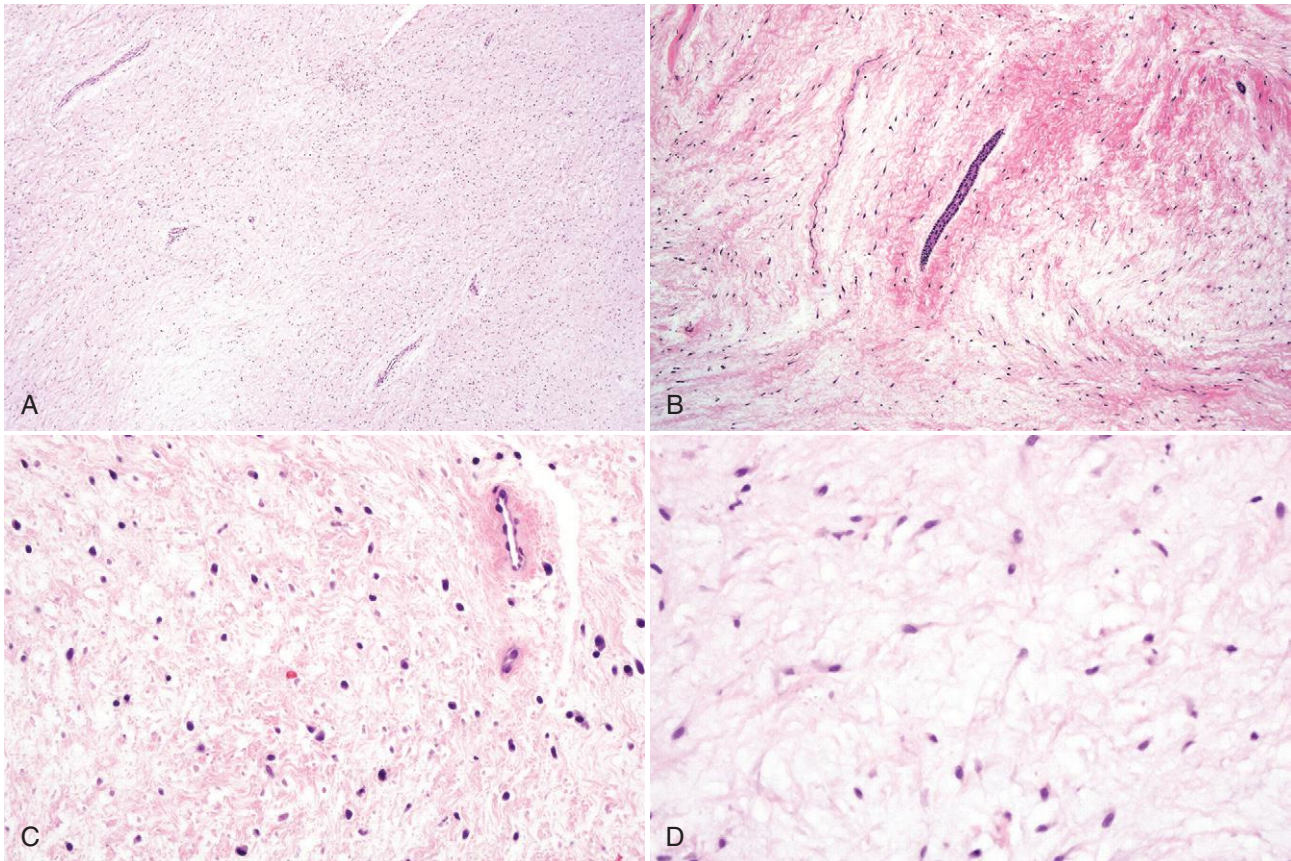
### REFERENCES

- Barker BF. Odontogenic myxoma. *Semin Diagn Pathol.* 1999;16:297-301.
- Lin YL, Basile JR. A case of odontogenic myxoma with unusual histological features mimicking a fibro-osseous process. *Head Neck Pathol.* 2010;4:253-256.
- Li TJ, Sun LS, Luo HY. Odontogenic myxoma: a clinicopathologic study of 25 cases. *Arch Pathol Lab Med.* 2006;130:1799-1806.
- Martinez-Mata G, Mosqueda-Taylor A, Carlos-Bregni R, et al. Odontogenic myxoma: clinico-pathological, immunohistochemical and ultrastructural findings of a multicentric series. *Oral Oncol.* 2008;44:601-607.
- Noffke CE, Raubenheimer EJ, Chabikuli NJ, Bouckaert MM. Odontogenic myxoma: review of the literature and report of 30 cases from South Africa. *Oral Surg Oral Med Oral Pathol Oral Radiol Endod.* 2007;104:101-109.
- Simon EN, Merckx MA, Vuhahula E, et al. Odontogenic myxoma: a clinicopathological study of 33 cases. *Int J Oral Maxillofac Surg.* 2004;33:333-337.

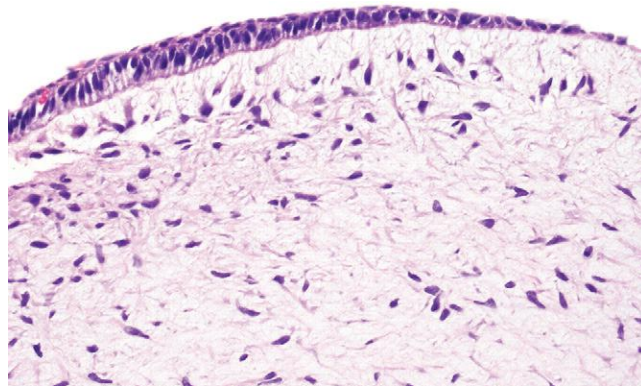


**FIGURE 15-43.** Odontogenic myxoma: radiolucency of maxilla with honeycomb or tennis racket appearance. (From White SC, Pharoah MJ: *Oral Radiology: Principles and Interpretation*, 6th ed. St. Louis, Mosby, 2009, p 381.)





**FIGURE 15-44.** Odontogenic myxoma. **A**, Proliferation of spindle cells in myxoid stroma. **B**, Some areas may be more collagenized. **C**, Focal perivascular hyalinization and many mast cells are noted. **D**, Cells are spindled or stellate.



**FIGURE 15-45.** Dental papilla: myxoid tissue with spindled and stellate fibroblasts focally rimmed by odontoblasts.



## GRANULAR CELL ODONTOGENIC TUMOR

### Clinical Findings

- Occurs in the fifth to sixth decade; there is 3:1 female predilection; radiolucency in the mandible (75%) is usually posterior; rarely, lesions are peripheral (extraosseous).

### Histopathologic Features

- Sheets and lobules of large, round cells with abundant eosinophilic, granular cytoplasm, eccentric round or ovoid nuclei with some variation in shape and size, and inconspicuous nucleoli; fibrovascular tissue is present between granular cells; islands of odontogenic epithelium do not exhibit palisading of basal cells, and clear cells may be present; cementum-like droplets are occasionally present (Figs. 15-46 and 15-47).
- Granular cells are S-100 protein negative and CD68 positive.

### Differential Diagnosis

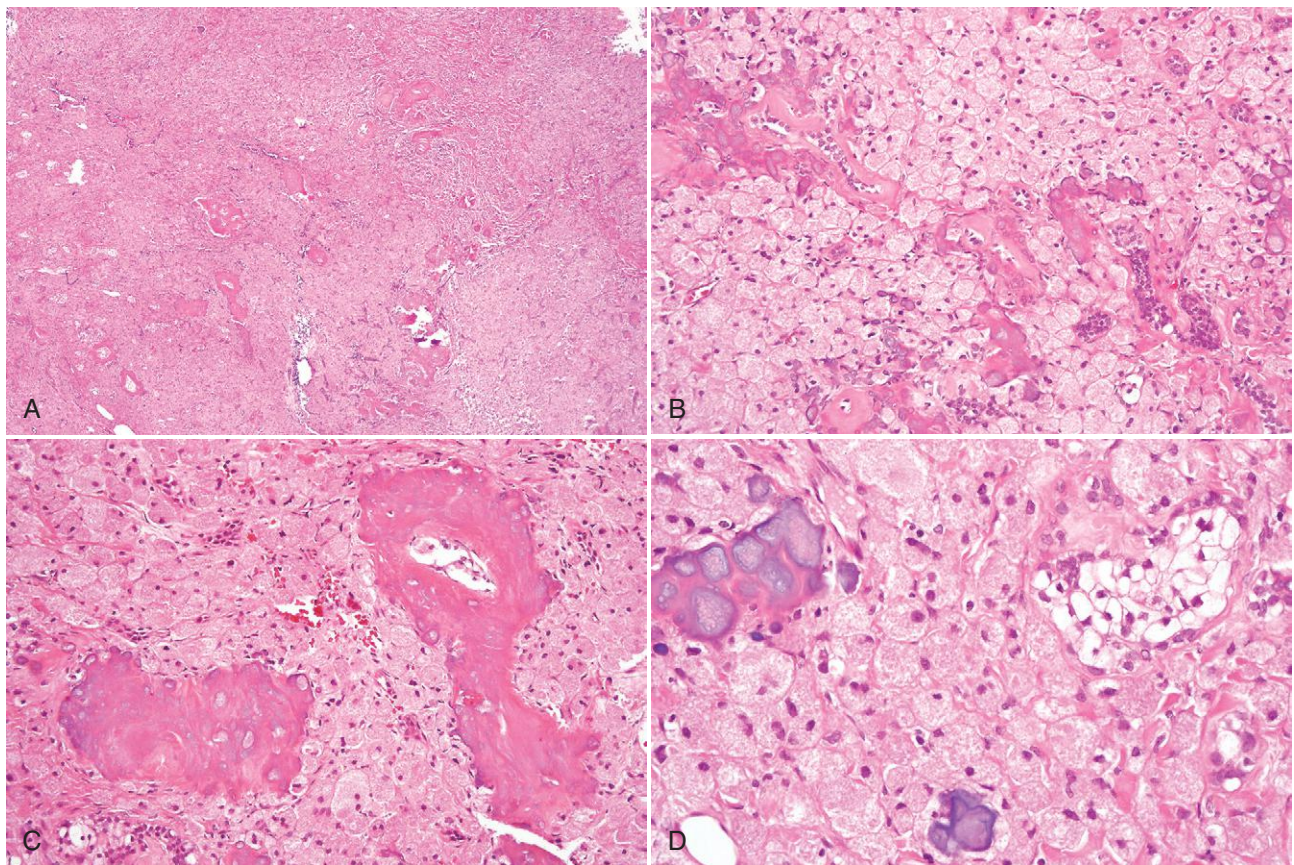
- Ameloblastoma, granular cell type, exhibits palisading and reverse nuclear polarization of basal cells.

### Management and Prognosis

- Enucleation or curettage is the treatment of choice; recurrence is rare.

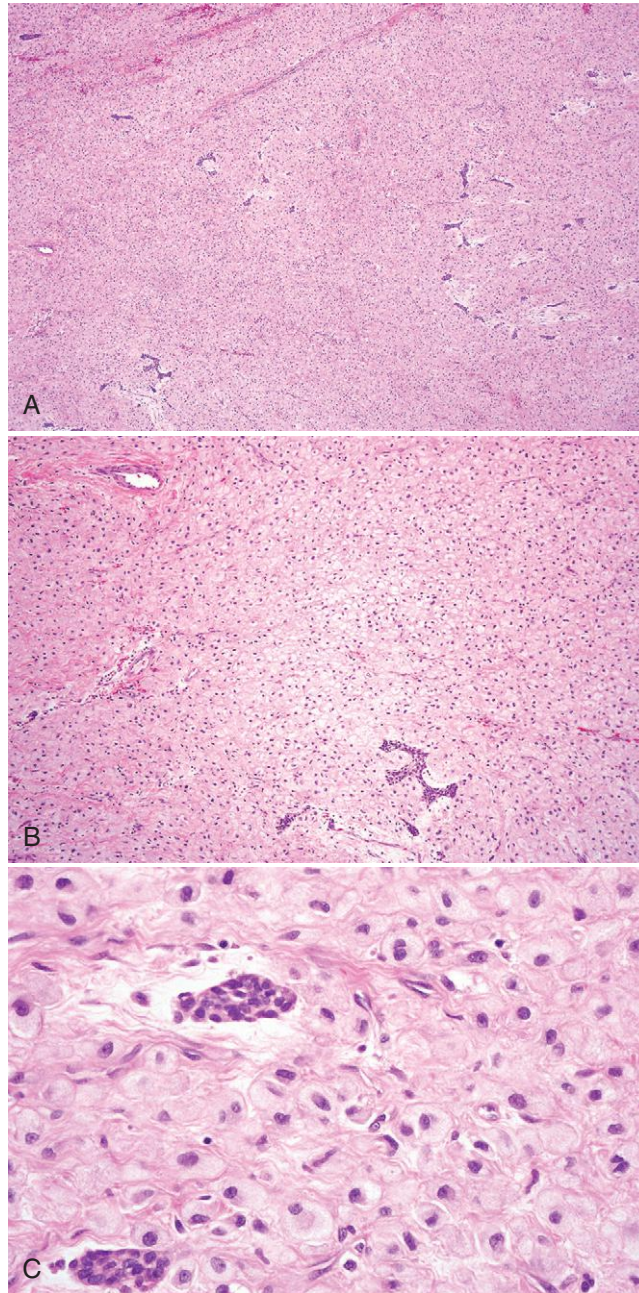
### REFERENCES

- Brannon RB, Goode RK, Eversole LR, Carr RF. The central granular cell odontogenic tumor: report of 5 new cases. *Oral Surg Oral Med Oral Pathol Oral Radiol Endod.* 2002;94:614-621.
- Brannon RB. Central odontogenic fibroma, myxoma (odontogenic myxoma, fibromyxoma), and central odontogenic granular cell tumor. *Oral Maxillofac Surg Clin North Am.* 2004;16:359-374.
- Lotay HS, Kalmar J, DeLeeuw K. Central odontogenic fibroma with features of central granular cell odontogenic tumor. *Oral Surg Oral Med Oral Pathol Oral Radiol Endod.* 2010;109:e63-e66.
- Mesquita AT, Santos CR, Gomez RS, et al. Central granular cell odontogenic tumor: a histopathologic and immunohistochemical study. *Ann Diagn Pathol.* 2009;13:405-412.
- Rinaggio J, Cleveland D, Koshy R, et al. Peripheral granular odontogenic fibroma. *Oral Surg Oral Med Oral Pathol Oral Radiol Endod.* 2007;104:676-679.



**FIGURE 15-46.** Granular cell odontogenic tumor. **A**, Sheets of granular cells, eosinophilic deposits, and epithelial islands. **B**, Periepithelial dentinoid and globular calcifications; epithelial islands that do not show palisading of peripheral cells. **C**, Granular cells surround dentinoid that is not periepithelial. **D**, Granular cells have benign nuclei; epithelial rest is composed of clear cells, and calcifications are evident.





**FIGURE 15-47.** Granular cell odontogenic tumor. **A**, Sheets of granular cells with epithelial nests; calcifications are not present. **B**, Sheets of granular cells with epithelial nests that do not show palisading of peripheral cells. **C**, Benign odontogenic epithelium and granular cells with binucleation and slight nuclear atypia.



## CEMENTOBLASTOMA

### Clinical Findings

- Lesion occurs in second and third decades; mandible is two to three times more often affected than maxilla; more than 60% of patients report pain and/or swelling.
- Radiopaque mass (with surrounding lucent rim) is fused to the apex of a permanent tooth, usually mandibular first molar (50%); lamina dura is usually continuous around tooth and lesion; root resorption is often present (Fig. 15-48); some lesions are mixed lucent-opaque and infrequently, lucent only.
- Tooth may have been extracted and the root fractured, leaving behind a radiopaque mass in an edentulous area.

### Histopathologic Features

Differentiation of tumor is toward cementoblasts, which deposit cementum; its bone-forming counterpart is osteoblastoma.

- Proliferation of cementoblasts (that appear similar to osteoblasts), which lay down cementum and woven bonelike material in masses and radiating columns, the latter best seen at the periphery; resting and reversal lines may be present, and root may be resorbed (Figs. 15-49, A-C and 15-50, A-C); cementoblasts are large with eccentric nuclei that may be slightly atypical, but contain dispersed chromatin and small nucleoli; osteoclast-like cells and dilated vessels may be seen (see Figs. 15-49, D and E and 15-50, D and E).

### Differential Diagnosis

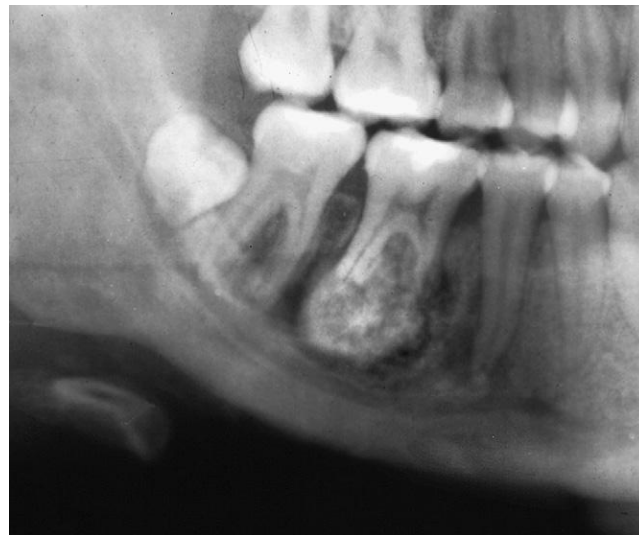- Osteoblastoma does not have the same relationship with a tooth and, in particular, the peripheral radiating cementum seams.
- Cemento-osseous dysplasia in the early stage exhibits a cellular spindle cell population; it is sclerotic and dense in the later stage but does not exhibit the parallel cementum seams.
- Hypercementosis manifests as thickened cellular and acellular cementum attached to the tooth without proliferation of cementoblasts.

### Management and Prognosis

- Excision or en bloc resection of the tumor with the tooth is the treatment of choice; recurrence rate is 20%.

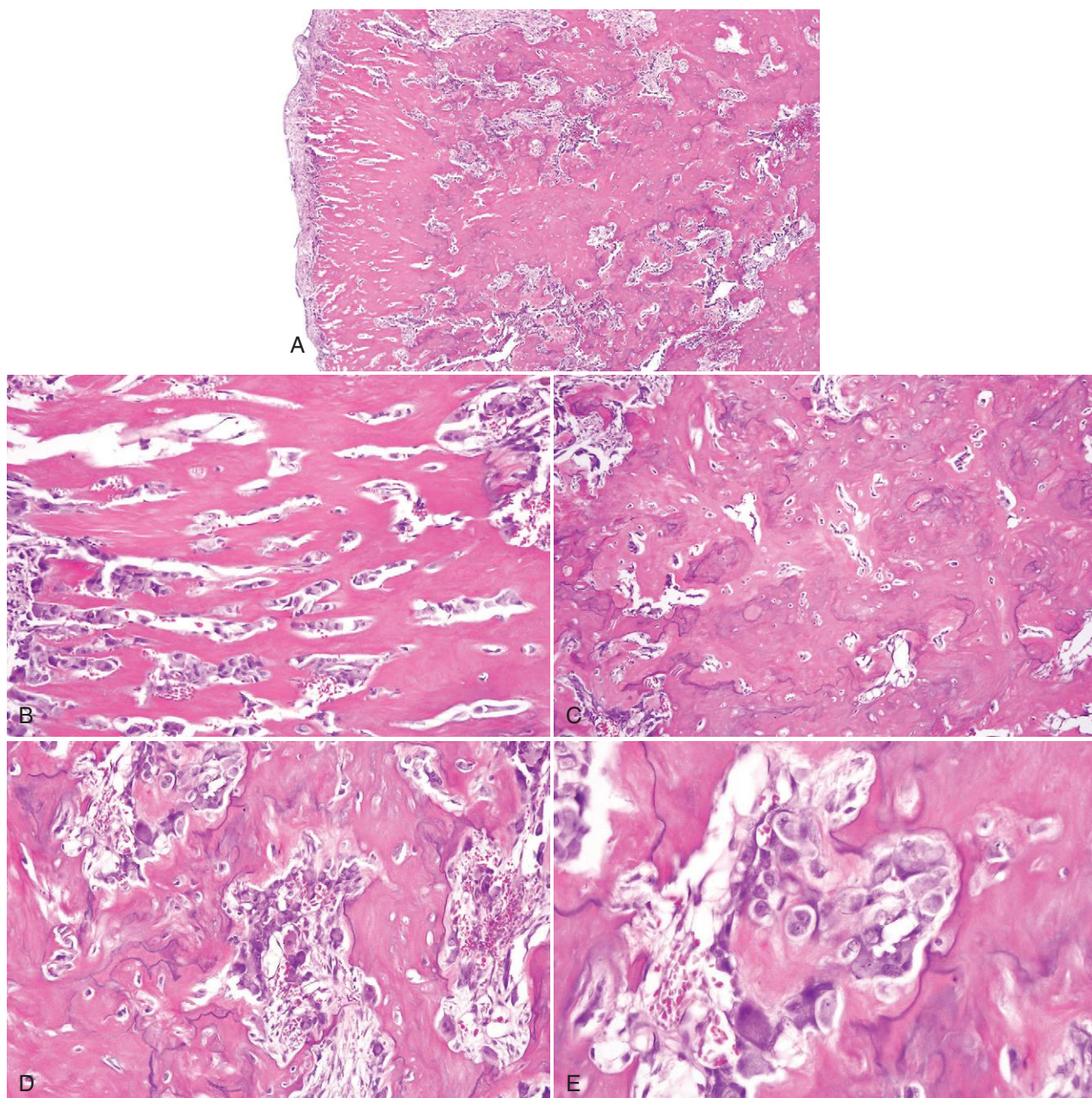
### REFERENCES

- Brannon RB, Fowler CB, Carpenter WM, Corio RL. Cementoblastoma: an innocuous neoplasm? A clinicopathologic study of 44 cases and review of the literature with special emphasis on recurrence. *Oral Surg Oral Med Oral Pathol Oral Radiol Endod.* 2002; 93:311-320.
- Hirai E, Yamamoto K, Kounoe T, et al. Benign cementoblastoma of the anterior maxilla. *J Oral Maxillofac Surg.* 2010;68:671-674.
- Ulmansky M, Hjorting-Hansen E, et al. Benign cementoblastoma. A review and five new cases. *Oral Surg Oral Med Oral Pathol.* 1994;77:48-55.
- Vieira AP, Meneses JM Jr, Maia RL. Cementoblastoma related to a primary tooth: a case report. *J Oral Pathol Med.* 2007;36:117-119.



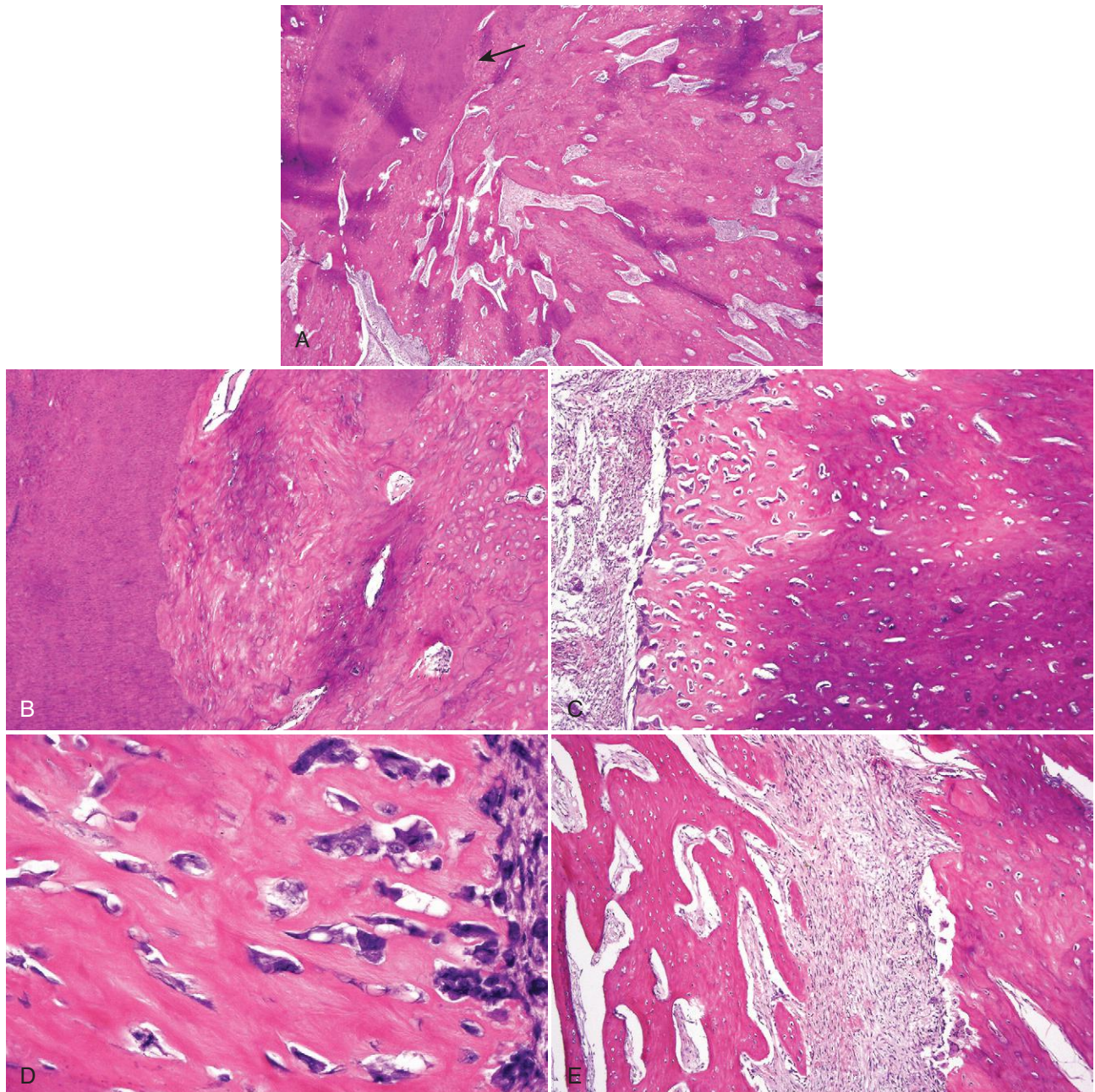
**FIGURE 15-48.** Cementoblastoma: radiopaque mass at the apices of the right mandibular first molar with radiolucent rim and resorption of the roots. (From White SC, Pharoah MJ: *Oral Radiology: Principles and Interpretation*. 6th ed. St. Louis, Mosby, 2009, p 381.)





**FIGURE 15-49.** Cementoblastoma. **A**, Periphery of encapsulated tumor shows radiating trabeculae of cementum. **B**, Proliferation of large cementoblasts between parallel cementum seams. **C**, Some areas resemble woven bone with resting and reversal lines. **D**, Multiple layers of cementoblasts and osteoclast-like cells. **E**, Plump, atypical-appearing cementoblasts with benign nuclei and dispersed chromatin.





**FIGURE 15-50.** Cementoblastoma. **A**, Tumor is attached to the root of the tooth, which shows resorption (*arrow*). **B**, Tumor has eroded and fused with the dentin of tooth (*left*). **C**, Encapsulated mass of cementum without radiating trabeculae of cementum. **D**, Large cementoblasts with large, eccentric, atypical nuclei and inconspicuous nucleoli. **E**, Fibrous capsule separates woven bone (*left*) from tumor osteocementum (*right*); many osteoclasts are noted.



# 16

# NONODONTOGENIC INTRAOSSIOUS LESIONS

## CHAPTER CONTENTS

Tori and Exostoses	382
Fibro-osseous Lesions	385
Paget Disease of Bone (Osteitis Deformans)	396
Central Giant Cell Granuloma (Aggressive and Nonaggressive Giant Cell Lesion, Central Giant Cell Lesion, Central Giant Cell Reparative Granuloma)	398
Cherubism	401
Desmoplastic Fibroma	402
Osteosarcoma (Osteogenic Sarcoma)	403
Chondrosarcoma	407
Plasma Cell Myeloma (Multiple Myeloma)	411
Langerhans Cell Histiocytosis	416
Osteonecrosis and Osteomyelitis	417
Myospherulosis (Spherulocytosis, Spherulocystic Disease of Skin)	422
Hematopoietic Bone Marrow Defect (Osteoporotic Bone Marrow Defect)	423
NONODONTOGENIC CYSTS AND CYSTLIKE LESIONS	424
Nasopalatine Duct (Incisive Canal) Cyst	424
Surgical Ciliated Cyst (Postoperative Maxillary Cyst)	426
Median Palatal (Palatine) Cyst	427
Aneurysmal Bone Cyst	428
Simple Bone Cyst (Traumatic Bone Cyst, Idiopathic Bone Cavity)	430
Stafne Bone Cavity (Lingual Salivary Gland Depression)	431

## TORI AND EXOSTOSES

### Clinical Findings

- Tori: 2% to 10% of adults; exophytic, hard, uninodular or multinodular bony masses covered by mucosa that may be ulcerated from trauma; torus palatinus and torus mandibularis on the midline of palate and lingual mandible (usually bilateral and symmetric), respectively (Fig. 16-1, A and B); often site of bisphosphonate-associated osteonecrosis
- Exostoses: 27% of adults; male predilection (5:1); outgrowths of bone, nodular or sessile frequently on buccal aspects of mandible and maxilla or ascending arch of the palate and more than 90% having concurrent tori (see Fig. 16-1, C and D); exostoses possibly show rapid growth in some patients

### Etiopathogenesis and Histopathologic Features

Tori and exostoses are likely developmental in nature, influenced by genetic and environmental factors with racial predisposition.

- Dense lamellar bone with well-spaced small osteocytes, fibrovascular tissue in haversian canals, variable osteoblastic rimming, especially if inflamed (Fig. 16-2); fatty marrow often present
- Long, sweeping collagen bundles (lamellae) noted under polarized light (Fig. 16-3)

### Differential Diagnosis

- Dense bone island, bone scar, or idiopathic osteosclerosis is not exophytic and is an asymptomatic intraosseous radiopacity not related to teeth that is discovered



on routine radiography (Fig. 16-4, A); biopsy is not necessary unless the lesion is radiographically progressive; histopathology is similar and bone is often sclerotic.

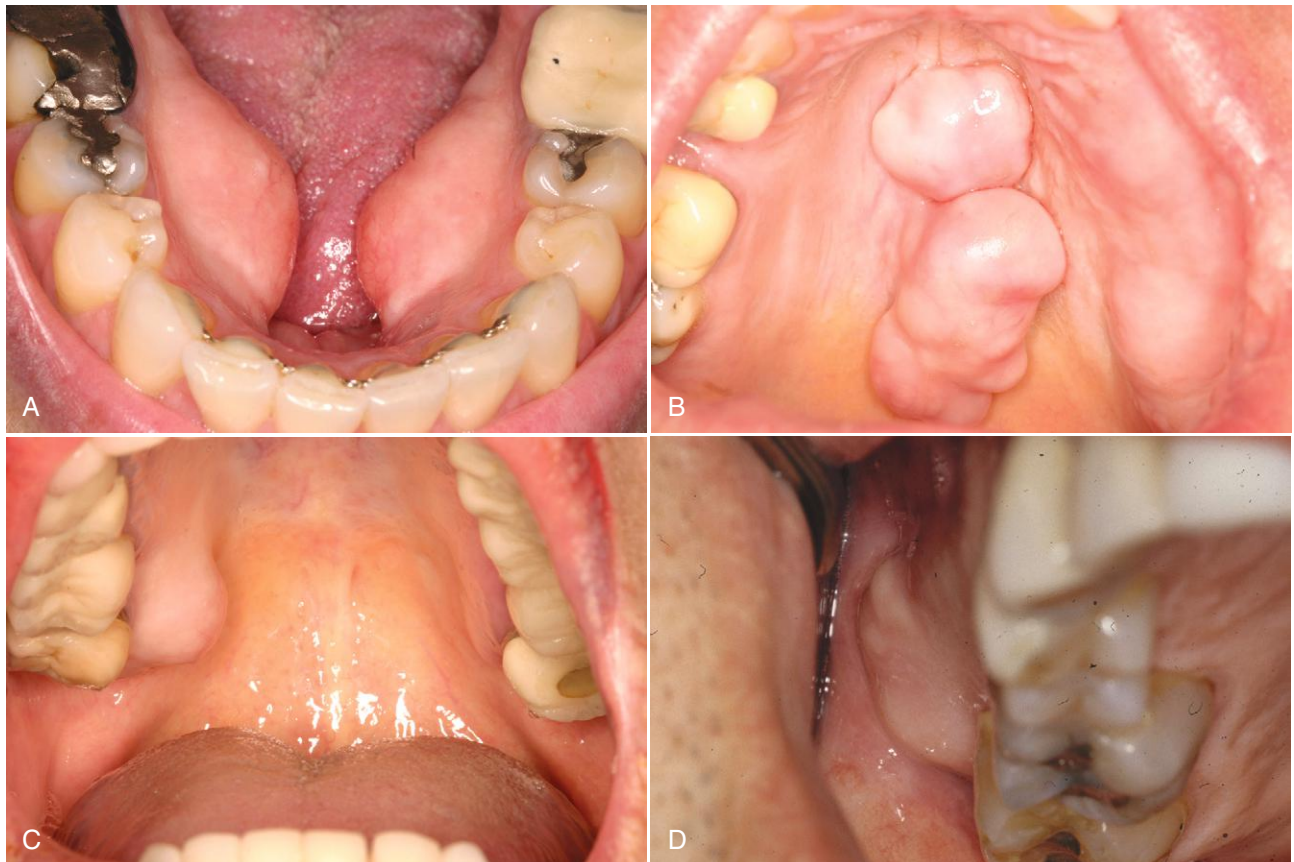- Condensing osteitis is similar to idiopathic osteosclerosis but is found at or very close to the apices of teeth and is likely reactive to chronic occlusal trauma or low-grade inflammation or odontogenic infection; biopsy is not necessary (see Fig. 16-4, B).
- True osteomas are associated with Gardner syndrome (autosomal dominant condition associated with mutation in the APC gene and development of colonic polyps and carcinoma, desmoid tumors, supernumerary teeth, and skin cysts).

### Management and Prognosis

- Excision is performed usually because patient wants a denture made, or if lesion is constantly ulcerated from trauma.

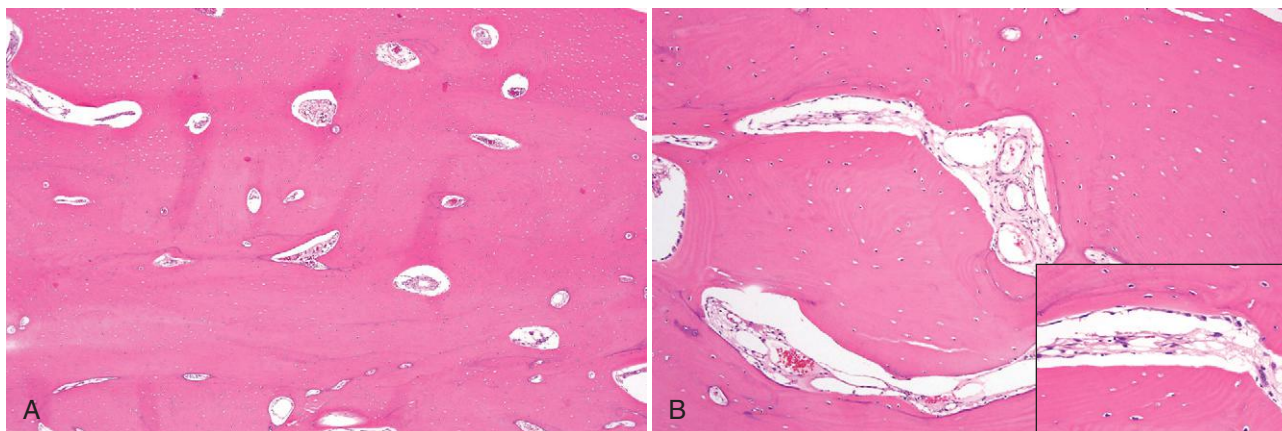
### REFERENCES

- Chohayeb AA, Volpe AR. Occurrence of torus palatinus and mandibularis among women of different ethnic groups. *Am J Dent.* 2001;14:278-280.
- Haugen LK. Palatine and mandibular tori. A morphologic study in the current Norwegian population. *Acta Odontol Scand.* 1992;50:65-77.
- Jainkittivong A, Langlais RP. Buccal and palatal exostoses: prevalence and concurrence with tori. *Oral Surg Oral Med Oral Pathol Oral Radiol Endod.* 2000;90:48-53.
- Seah YH. Torus palatinus and torus mandibularis: a review of the literature. *Aust Dent J.* 1995;40:318-321.
- White S, Pharoah M. *Oral Radiology: Principles and Interpretation.* 6th ed. St. Louis: Mosby; 2009.
- Yonetsu K, Yuasa K, Kanda S. Idiopathic osteosclerosis of the jaws: panoramic radiographic and computed tomographic findings. *Oral Surg Oral Med Oral Pathol Oral Radiol Endod.* 1997;83:517-521.




**FIGURE 16-1.** **A**, Torus mandibularis: bilaterally symmetric sessile bony masses on the lingual aspect of the mandible. **B**, Torus palatinus: multinodular bony masses on the midline of the palate. **C**, Palatal exostosis: bony mass on the ascending arch of palate. **D**, Buccal exostosis: unilateral sessile bony mass on the buccal aspect of the maxilla.

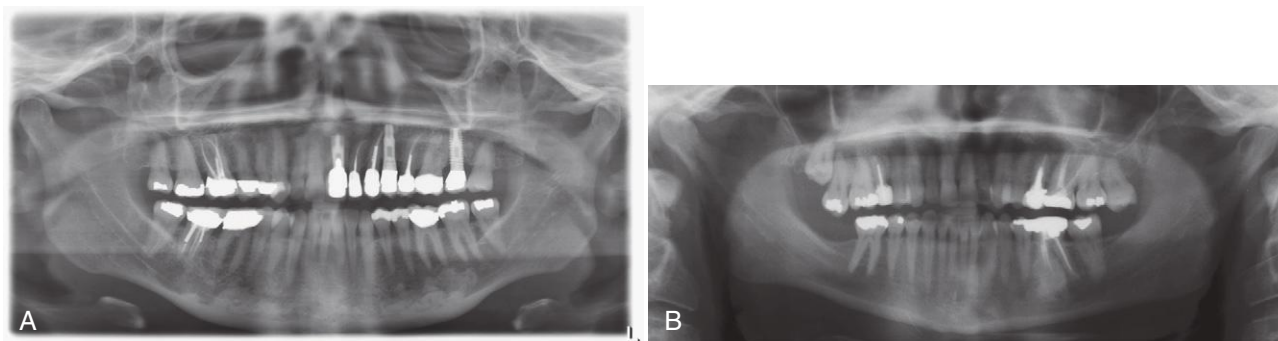




**FIGURE 16-2.** Torus. **A**, Dense viable lamellar bone. **B**, Small osteocytes within bone, fibrovascular haversian systems, and focal osteoblastic rimming (*inset*).



**FIGURE 16-3.** Torus: polarized light reveals long sweeping fascicles of collagen.



**FIGURE 16-4.** **A**, Idiopathic osteosclerosis: radiopacities in the left mandible not related to apices of teeth. **B**, Condensing osteitis: poorly demarcated uniform radiopacity around the roots of endodontically treated left mandibular first molar. (**A**, Courtesy of Dr. Thomas Mone, private practice, Braintree, Mass.)



## FIBRO-OSSEOUS LESIONS

Fibro-osseous lesions are a heterogeneous group of lesions composed of osseous dysplasias, inflammatory conditions, and neoplasms, characterized by a proliferation of fibroblast-like cells and deposition of osseous or cementum-like material. Their histologic features overlap, depending on the stage in which the biopsies are obtained, and an accurate diagnosis can be rendered only after correlation of clinical and radiographic data. Differentiation between lesions is essential so that appropriate therapy can be instituted. The lesions considered here are fibrous dysplasia, cemento-osseous dysplasia, cemento-ossifying fibroma, aggressive ossifying fibroma, and familial gigantiform cementoma. Nomenclature for these lesions continues to evolve.

### Clinical Findings

- Please see Table 16-1 and Figs. 16-5 to 16-10.

### Etiopathogenesis and Histopathologic Features

Fibrous dysplasia is associated with a mutation in the GNAS gene that results in alterations in proliferation and differentiation of preosteoblasts; there are monostotic (85% to 90% of cases) and polyostotic types; the latter is seen in McCune-Albright syndrome and is often associated with endocrinopathies and skin

pigmentation. The other conditions have not been shown to be consistently associated with gene mutations, although familial gigantiform cementoma is an inherited disorder.

- *Fibrous dysplasia* consists of a proliferation of benign fibrous tissue and either small, delicate, or curvilinear trabeculae of woven bone in early lesions, or thicker and denser trabeculae of woven or lamellar bone in mature lesions; osteoblastic rimming and occasional osteoclasts may be seen focally, especially in early and inflamed lesions; there is variable vascularity (Figs. 16-11 and 16-12); aneurysmal bone cyst-like areas may be seen.
- *Cemento-osseous dysplasia* consists of a cellular proliferation of spindled benign fibroblast-like cells and deposition of osteoid, woven bone, cementum droplets, or a mixture thereof; mature lesions consist of a mass of cementum that has a rounded, globular appearance with few cementocytes (sclerotic cemental mass) (Figs. 16-13 to 16-15); cells that rim bone and cementum are often osteoblast-like.
- *Cemento-ossifying fibroma* consists of cellular proliferation of spindled fibroblast-like cells that deposit osteoid, trabeculae of woven bone, and cementum droplets in varying proportions; osteoblastic rimming is common (Fig. 16-16).

TABLE 16-1 Clinical Findings in Benign Fibro-osseous Lesions

Condition	Age	Site	Radiographic Appearance
Fibrous dysplasia	Second and third decades with painless expansion of bone and swelling of midface; older patients with persistent mature lesions; pregnancy may cause exacerbation	>90% of cases monostotic; unilateral affecting maxilla and often maxillary sinus and contiguous facial bones; sometimes with displacement of orbital floor; less common in the mandible	Diffuse ground-glass appearance of bone that merges with normal bone (see Fig. 16-5); loss of lamina dura; if in mandible, inferior alveolar canal may be displaced if long-standing
Focal cemento-osseous dysplasia	Occurs in white or black females in fourth to fifth decade; no swelling	Apex of vital tooth, usually mandibular first or second molar	Periapical radiolucency with increasing opacities as it matures; sclerotic rim in continuity with lamina dura (see Fig. 16-6, A)
Variant: periapical cemento-osseous dysplasia	Usually occurs in black females in fourth to fifth decade; no swelling	Apices of anterior mandibular incisors or canines; teeth vital	Same as above (see Fig. 16-6, B)
Multifocal (florid) cemento-osseous dysplasia	Usually occurs in black females in fourth to fifth decade; may develop swelling if simple bone cysts occur	Apices of vital teeth in multiple quadrants	Same as focal cemento-osseous dysplasia involving multiple teeth (see Fig. 16-7); simple bone cysts occur in long-standing lesions
Cemento-ossifying fibroma	Adults with increasing swelling of the face	60% to 70% occur in the body of the mandible	Well-demarcated radiolucency usually unassociated with teeth with variable radiopacities (see Fig. 16-8)
Aggressive (juvenile) ossifying fibroma	Usually occurs in first and second decade with psammomatoid type in slightly younger patients; rapidly developing facial swelling	Psammomatoid type affects maxilla and bones of paranasal sinuses Trabecular type affects maxilla and mandible equally	Usually fairly large radiolucency, generally well-demarcated with variable radiopacities sometimes with destruction of cortical plates (see Fig. 16-9)
Familial gigantiform cementoma	Autosomal dominant or sporadic; arises in childhood causing severe facial deformity by adulthood; some lesions do not cause jaw expansion	Involves at least two quadrants and usually all four	Expansile radiolucency with radiopacities (see Fig. 16-10)



- *Aggressive ossifying fibroma (desmo-osteoblastoma)* consists of a cellular proliferation of plump and stellate fibroblast-like cells with large, slightly atypical nuclei, clusters of multinucleated giant cells, and fresh hemorrhage; trabecular variant has abundant woven bone surrounding large osteocytes with many osteoblasts (Figs. 16-17 and 16-18); psammomatoid variant has many basophilic cementum droplets or psammomatoid bodies, most of which are of uniform size (Fig. 16-19); this subtype appears similar to familial gigantiform cementoma.
- *Familial gigantiform cementoma* is similar to ossifying fibroma, especially psammomatoid type.

### Differential Diagnosis

- Cementoblastoma shows a proliferation of cementoblasts (resembling osteoblasts) with radiating seams of cementum (see Chapter 15).
- Osteoblastoma shows a proliferation of osteoblasts composed of large cells with eccentric nuclei, often multilayered against the bone, osteoclasts on the same trabeculae, and prominent ectatic vessels (Fig. 16-20); bone is basophilic, sometimes with many resting and reversal lines.
- Renal osteodystrophy from secondary hyperparathyroidism may manifest with similar histology to fibrous dysplasia; clinical features of renal failure with hypercalcemia differentiate the two.

### Management and Prognosis

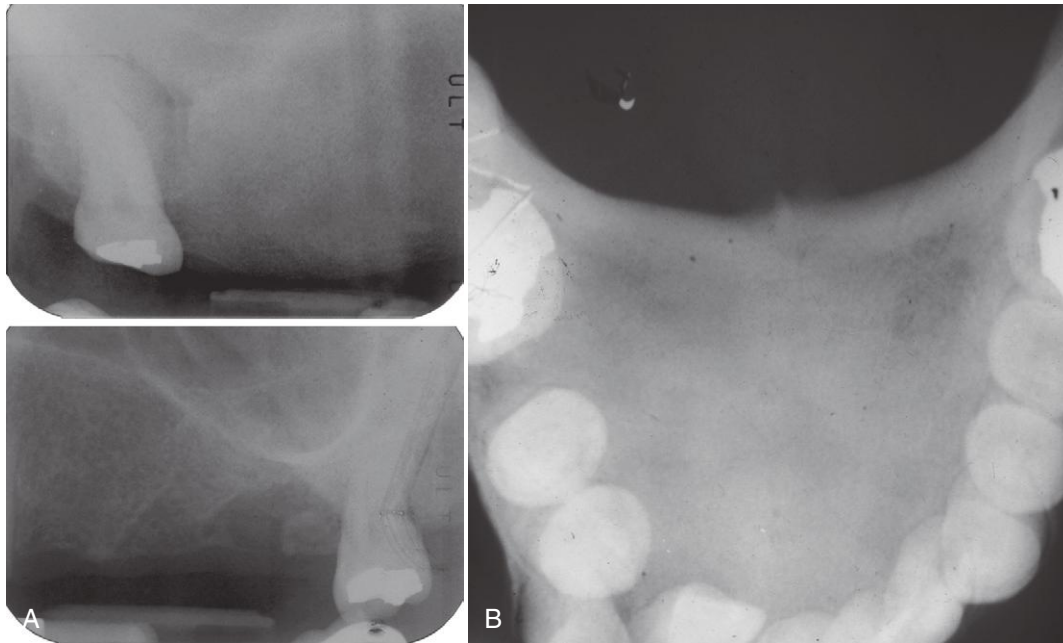
- Fibrous dysplasia: recontouring is for aesthetics only.
- Cemento-osseous dysplasia: no treatment necessary; however, sclerotic masses of cementum are hypovascular and extractions may lead to osteomyelitis; simple bone cysts are associated with long-standing lesions (Fig. 16-21).
- Cemento-ossifying fibroma: curettage, enucleation, or excision is curative.

- Aggressive ossifying fibroma: wide excision is the treatment of choice; recurrence is 30% to 50%, primarily because of incomplete excision.

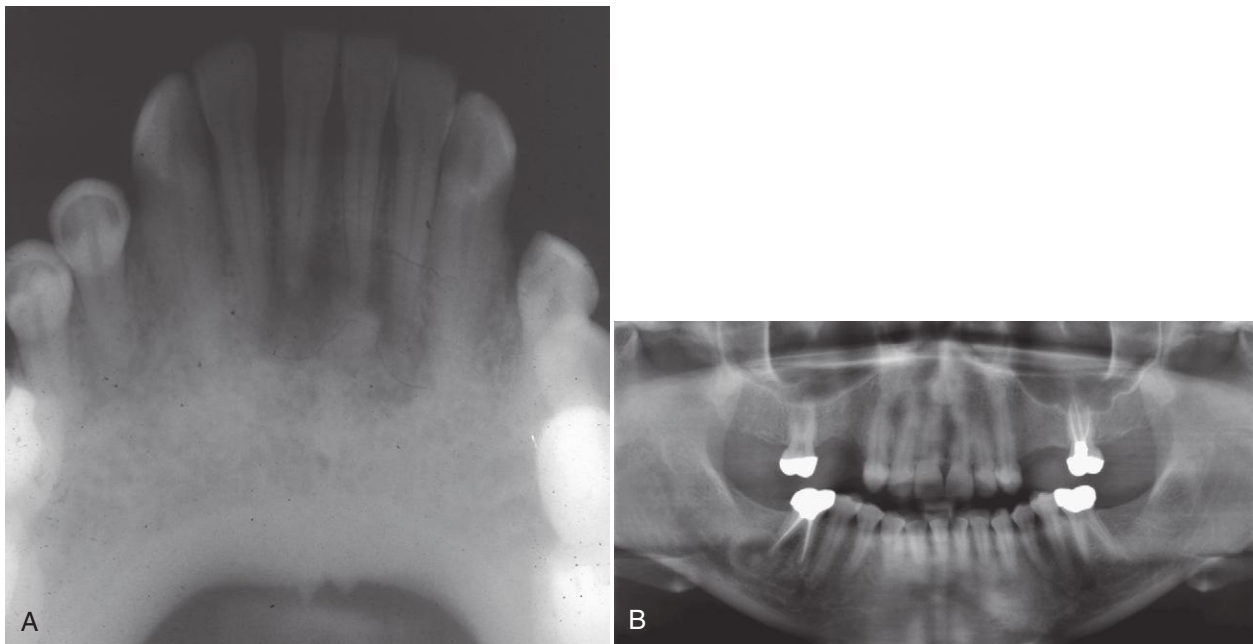
### REFERENCES

- Abdelsayed RA, Eversole LR, Singh BS, Scarbrough FE. Gigantiform cementoma: clinicopathologic presentation of 3 cases. *Oral Surg Oral Med Oral Pathol Oral Radiol Endod.* 2001;91:438-444.
- Alawi F. Benign fibro-osseous diseases of the maxillofacial bones. A review and differential diagnosis. *Am J Clin Pathol.* 2002;118 (suppl):S50-S70.
- Damm DD, Neville BW, McKenna S, et al. Macrognathia of renal osteodystrophy in dialysis patients. *Oral Surg Oral Med Oral Pathol Oral Radiol Endod.* 1997;83:489-495.
- El-Mofty S. Psammomatoid and trabecular juvenile ossifying fibroma of the craniofacial skeleton: two distinct clinicopathologic entities. *Oral Surg Oral Med Oral Pathol Oral Radiol Endod.* 2002;93: 296-304.
- Eversole LR, Leider AS, Nelson K. Ossifying fibroma: a clinicopathologic study of sixty-four cases. *Oral Surg Oral Med Oral Pathol.* 1985; 60:505-511.
- Eversole R, Su L, ElMofty S. Benign fibro-osseous lesions of the craniofacial complex. A review. *Head Neck Pathol.* 2008;2:177-202.
- MacDonald-Jankowski D. Fibrous dysplasia: a systematic review. *Dentomaxillofac Radiol.* 2009;38:196-215.
- Macdonald-Jankowski DS, Li TK. Fibrous dysplasia in a Hong Kong community: the clinical and radiological features and outcomes of treatment. *Dentomaxillofac Radiol.* 2009;38:63-72.
- Rosbach HC, Letson D, Lacson A, et al. Familial gigantiform cementoma with brittle bone disease, pathologic fractures, and osteosarcoma: a possible explanation of an ancient mystery. *Pediatr Blood Cancer.* 2005;44:390-396.
- Su L, Weathers DR, Waldron CA. Distinguishing features of focal cemento-osseous dysplasias and cemento-ossifying fibromas. I. A pathologic spectrum of 316 cases. *Oral Surg Oral Med Oral Pathol Oral Radiol Endod.* 1997;84:301-309.
- Su L, Weathers DR, Waldron CA. Distinguishing features of focal cemento-osseous dysplasia and cemento-ossifying fibromas. II. A clinical and radiologic spectrum of 316 cases. *Oral Surg Oral Med Oral Pathol Oral Radiol Endod.* 1997;84:540-549.
- Summerlin DJ, Tomich CE. Focal cemento-osseous dysplasia: a clinicopathologic study of 221 cases. *Oral Surg Oral Med Oral Pathol.* 1994;78:611-620.
- Young SK, Markowitz NR, Sullivan S, et al. Familial gigantiform cementoma: classification and presentation of a large pedigree. *Oral Surg Oral Med Oral Pathol.* 1989;68:740-747.



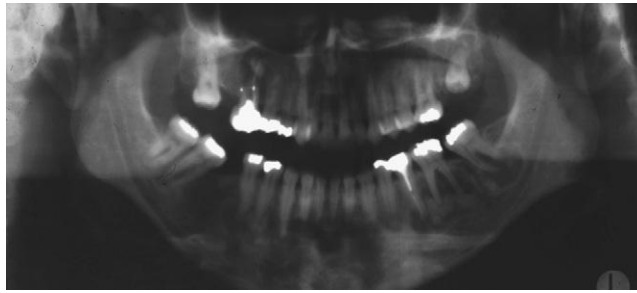


**FIGURE 16-5.** Fibrous dysplasia. **A**, Periapical films showing ground-glass appearance of the right maxilla (*top panel*) and normal trabeculation on the left (*bottom panel*). **B**, Ground-glass appearance of mandibular bone. (**A**, Courtesy of Dr. Bernard Friedland, Harvard School of Dental Medicine, Boston, Mass; **B**, Courtesy of Dr. Stanley Hirsch, Case Western Reserve University, Cleveland, Ohio.)

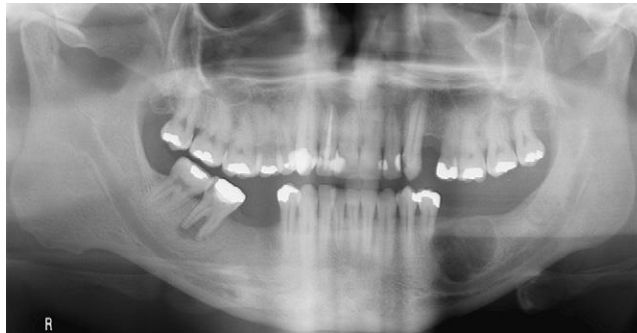

**FIGURE 16-6.** Focal cemento-osseous dysplasia. **A**, Variant: periapical cemento-osseous dysplasia. Radiolucency at the apices of vital mandibular anterior teeth with faint opacities. **B**, Circumscribed radiolucency with sclerotic rim and central calcification around the distal root of the right mandibular first molar. (Courtesy of Dr. Rafik Abdelsayed, Medical College of Georgia, School of Dentistry, Augusta, Ga.)

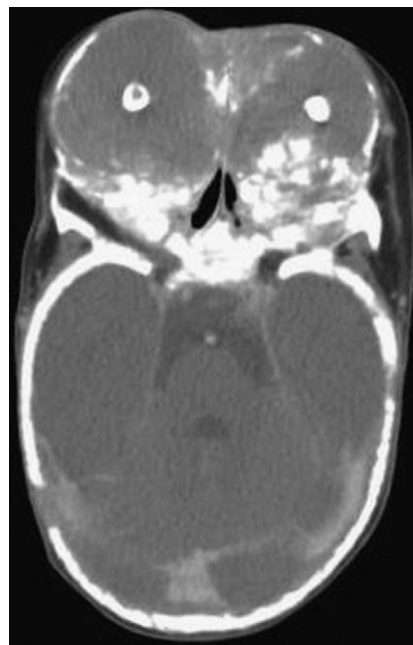



**FIGURE 16-7.** Multifocal cemento-osseous dysplasia: multiple radiolucencies with variable opacities around the apices of multiple teeth in the mandible and maxilla.

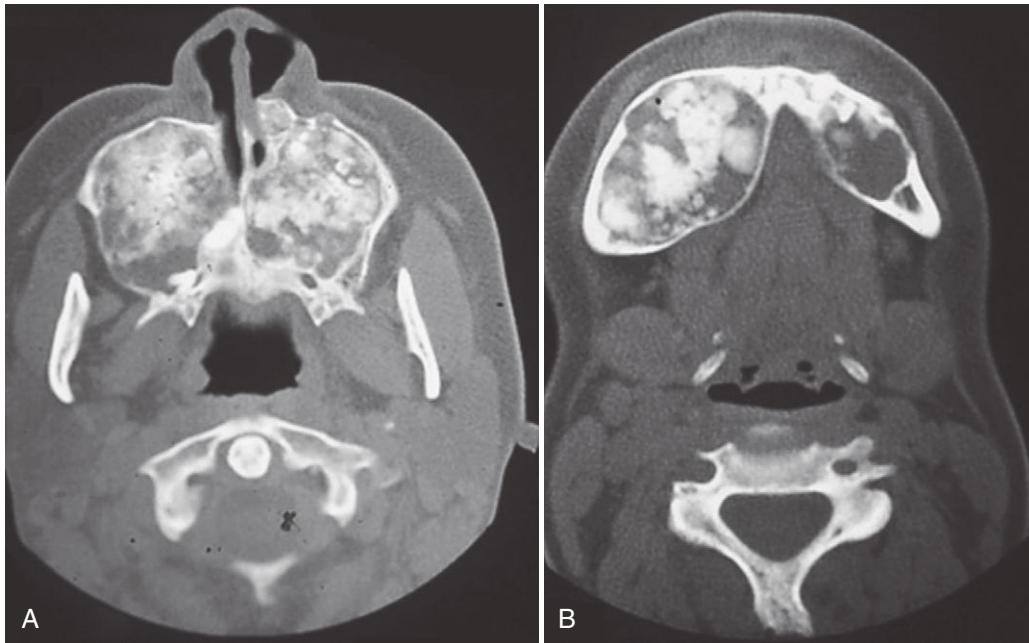


**FIGURE 16-8.** Central cemento-ossifying fibroma: single, large, well-demarcated radiolucency in the body of the left mandible.

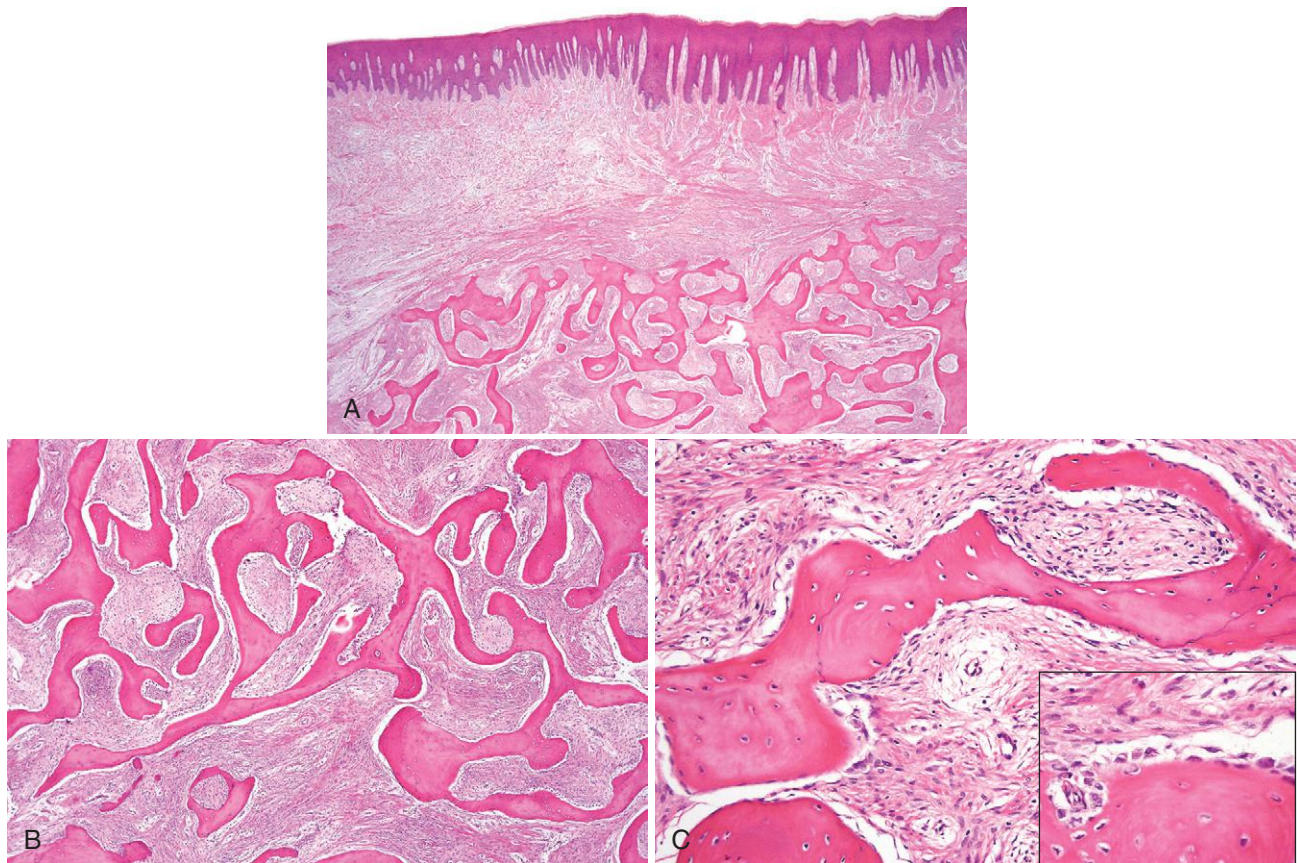


**FIGURE 16-9.** Aggressive ossifying fibroma: huge radiolucent and radiopaque lesion of the maxilla. (Courtesy of Dr. Bonnie Padwa, Harvard School of Dental Medicine, Boston, Mass.)



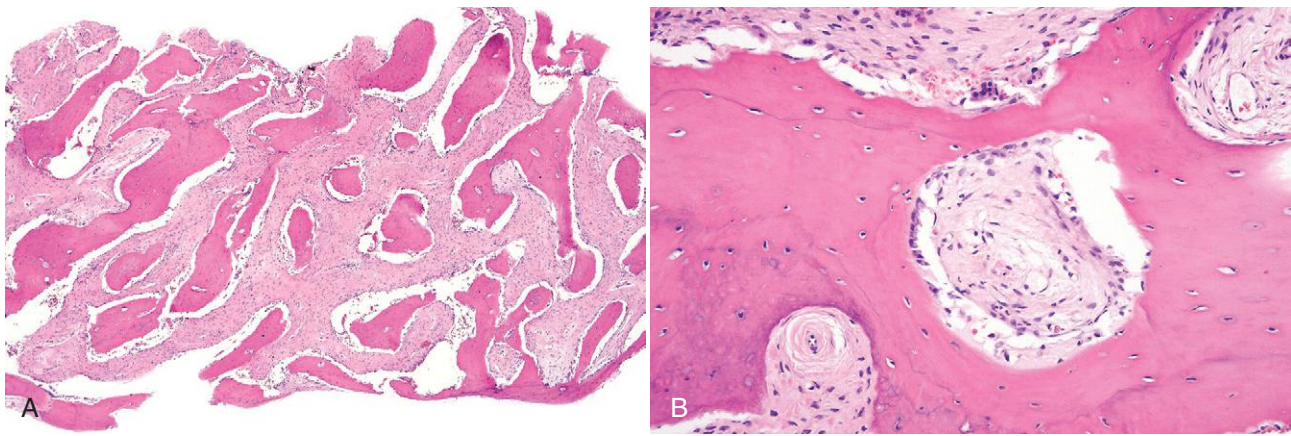


**FIGURE 16-10.** Familial gigantiform cementomas: marked expansion of maxilla (**A**) and mandible (**B**) by radiolucent-radiopaque process. (From Abdelsayed RA, Eversole LR, Singh BS, Scarbrough FE. *Gigantiform cementoma: clinicopathologic presentation of 3 cases*. Oral Surg Oral Med Oral Pathol Oral Radiol Endod. 2001;91:438-444.)

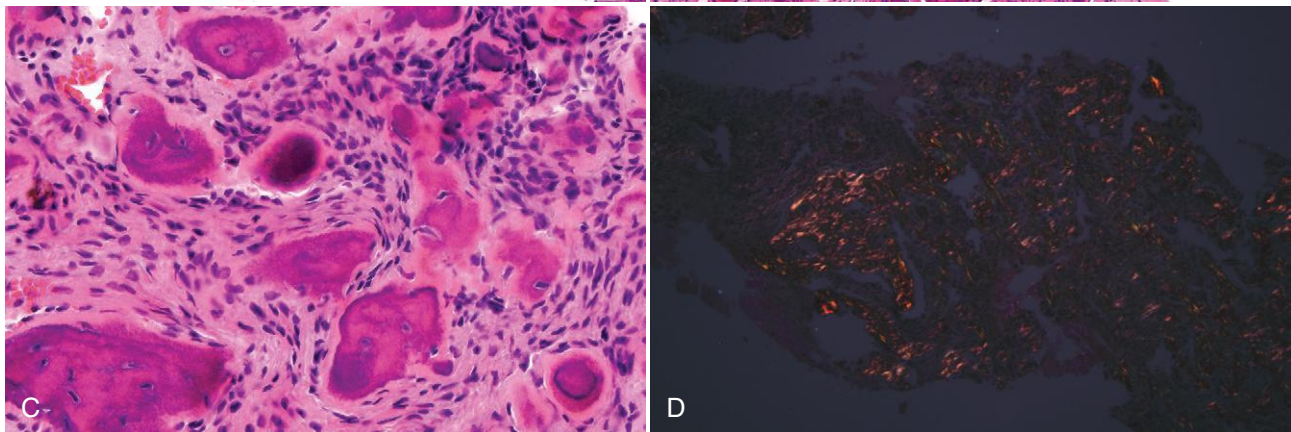
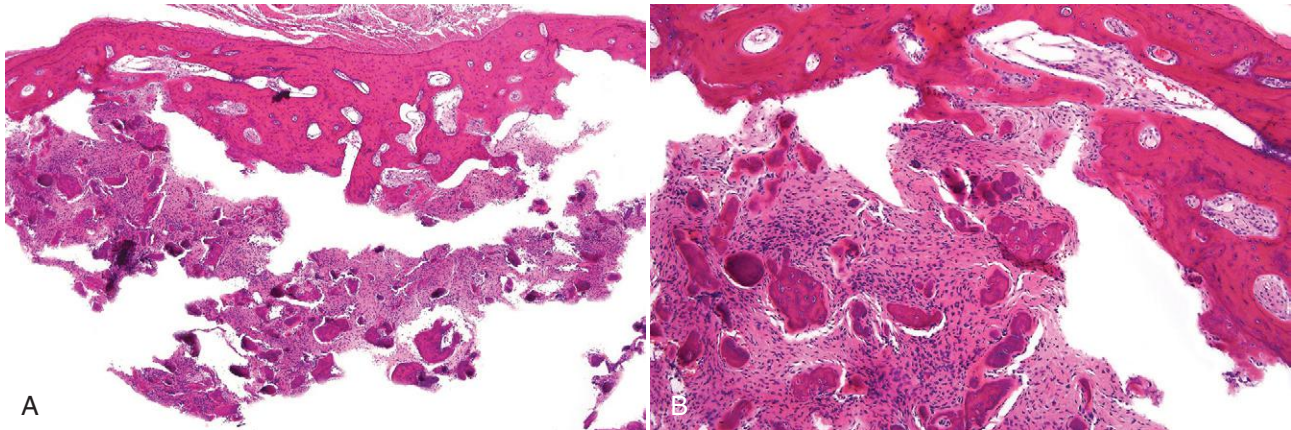


**FIGURE 16-11.** Fibrous dysplasia. **A**, Delicate trabeculae of bone in fibrous stroma, abutting the mucosa with no intervening cortical lamellar bone. **B**, Delicate interlacing trabeculae of woven bone in fibrous stroma. **C**, Woven bone with plump osteocytes, focal osteoblastic rimming, and mild chronic inflammation (*inset*).



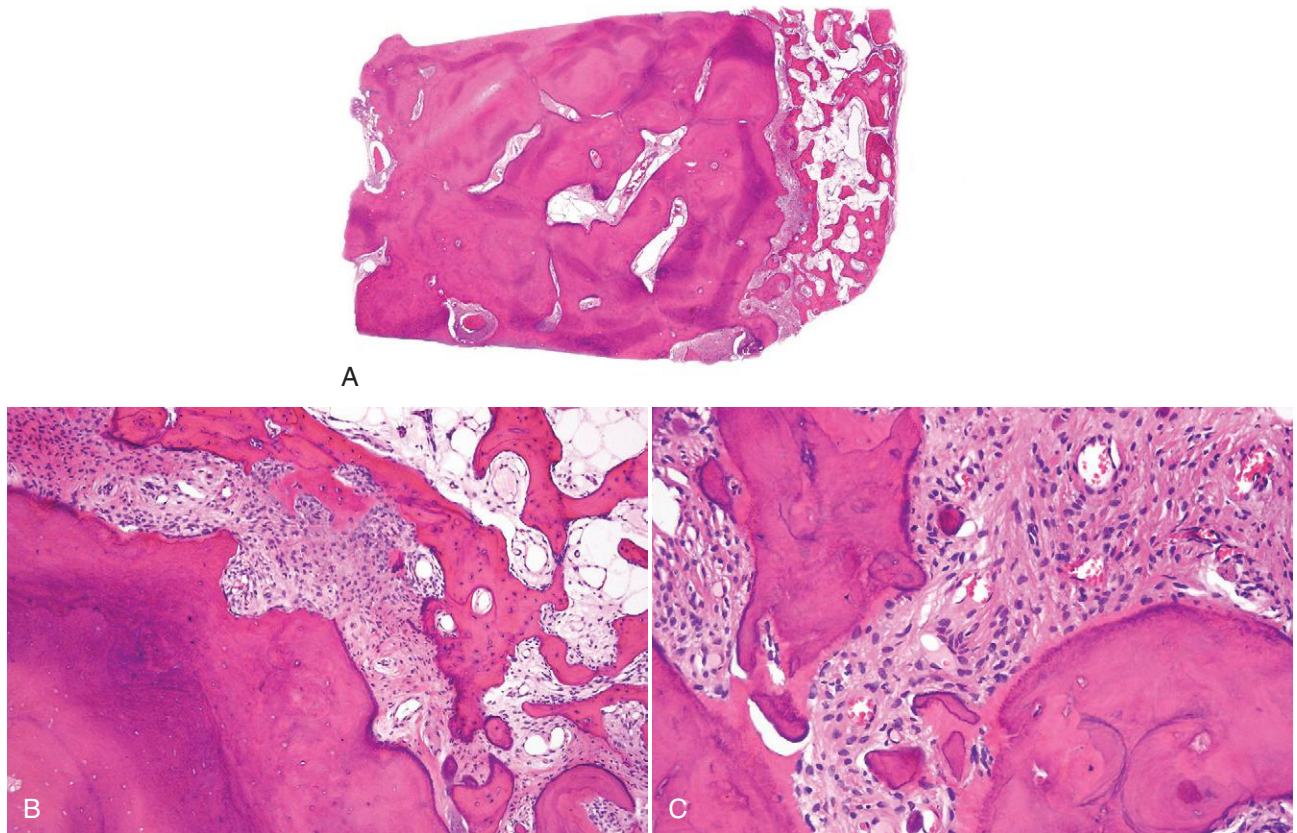


**FIGURE 16-12.** Fibrous dysplasia in 50-year-old patient. **A**, Thicker trabeculae of bone with more densely fibrous tissue. **B**, Focal osteoblastic rimming and osteoclastic activity. **C**, Polarized light reveals parallel delicate lamellae.

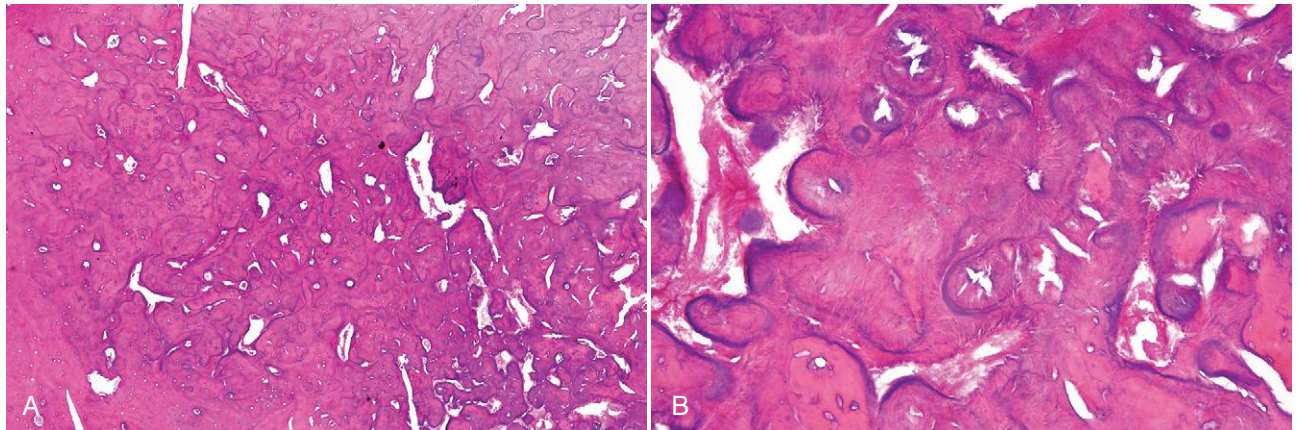


**FIGURE 16-13.** Focal cemento-osseous dysplasia. **A**, Nonencapsulated lesion abutting normal lamellar bone (top). **B**, Proliferation of spindle cells with cementum droplets and woven bone. **C**, Plump spindle cells with acellular cementum droplets and woven bone. **D**, Polarized light reveals short collagen bundles.



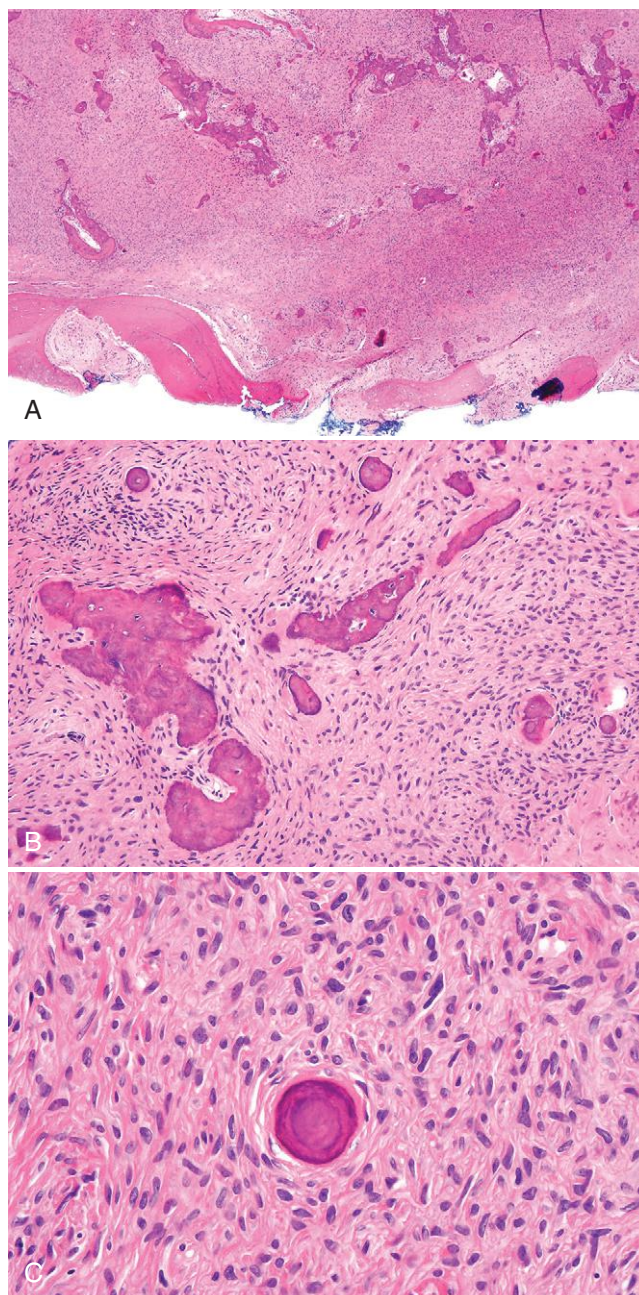


**FIGURE 16-14.** Focal cemento-osseous dysplasia. **A**, Mature lesion with large sclerotic cemental mass adjacent to cellular zone and lamellar cortical bone. **B**, Focal area of cellular spindle cell proliferation adjacent to dense, hypocellular osteocementum. **C**, Spindle cells and globular cementum with eosinophilic border of osteoid-like material.



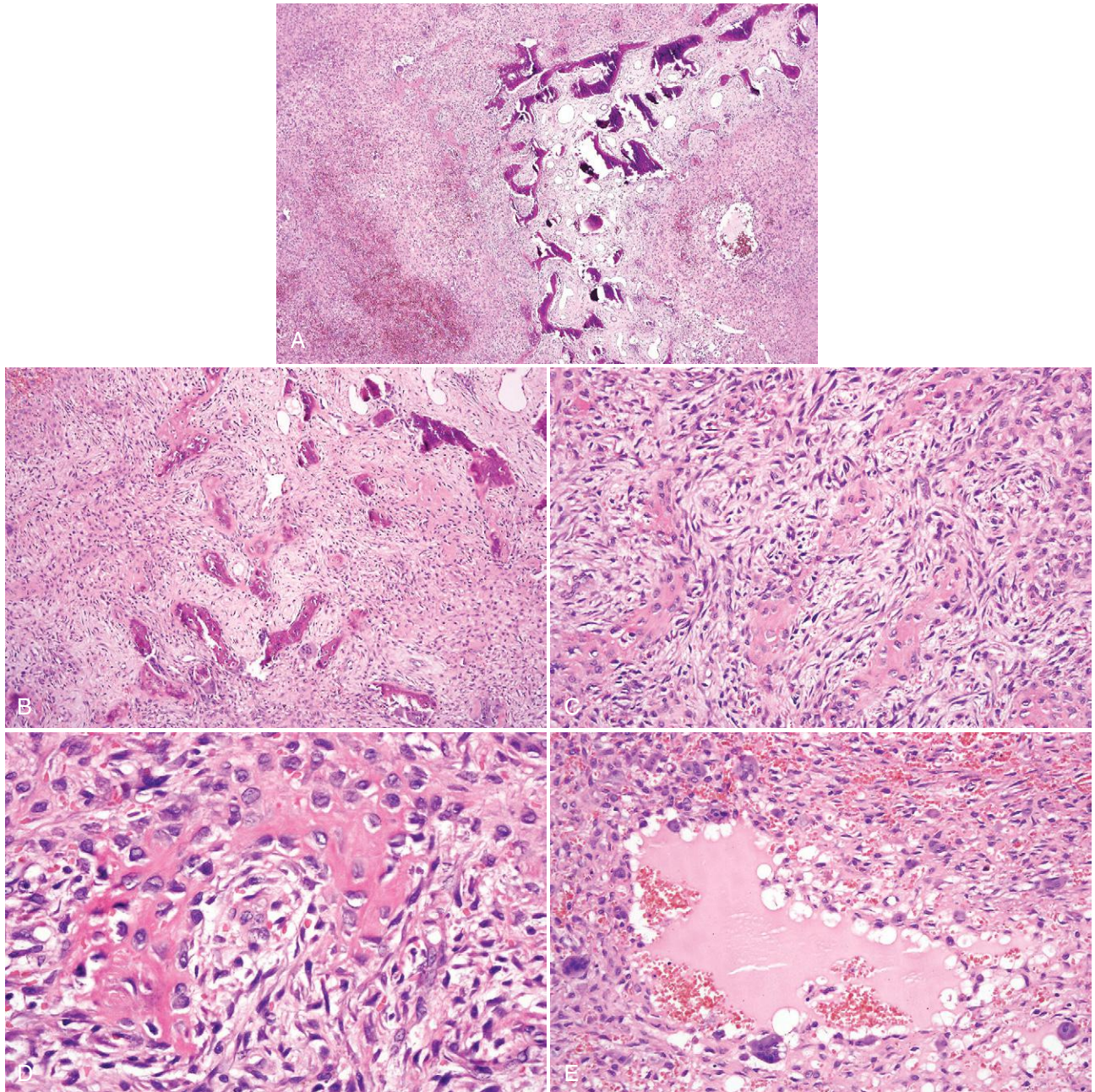
**FIGURE 16-15.** Focal cemento-osseous dysplasia. **A**, Mature lesion composed of masses of globular hypocellular cementum with many resting and reversal lines (sclerotic cemental mass). **B**, Acellular globular cementum (sclerotic cemental mass).





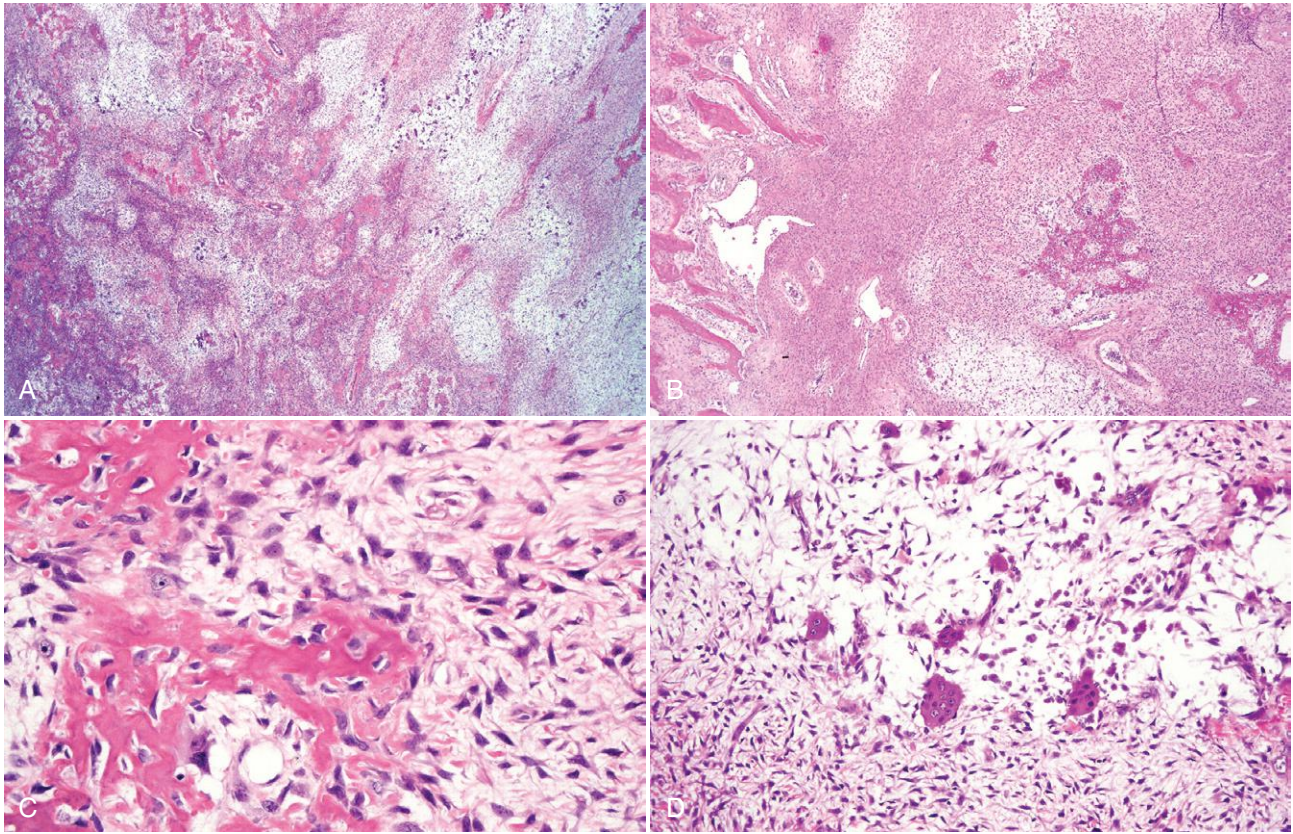
**FIGURE 16-16.** Central cemento-ossifying fibroma. **A**, Proliferation of spindle cells with deposition of osteoid, woven bone, and cementum with focal capsule (left, against rim of cortical bone). **B**, Trabeculae of woven bone with plump osteocytes and acellular cementum droplets and woven bone. **C**, Cementum droplet with surrounding benign fibroblasts.



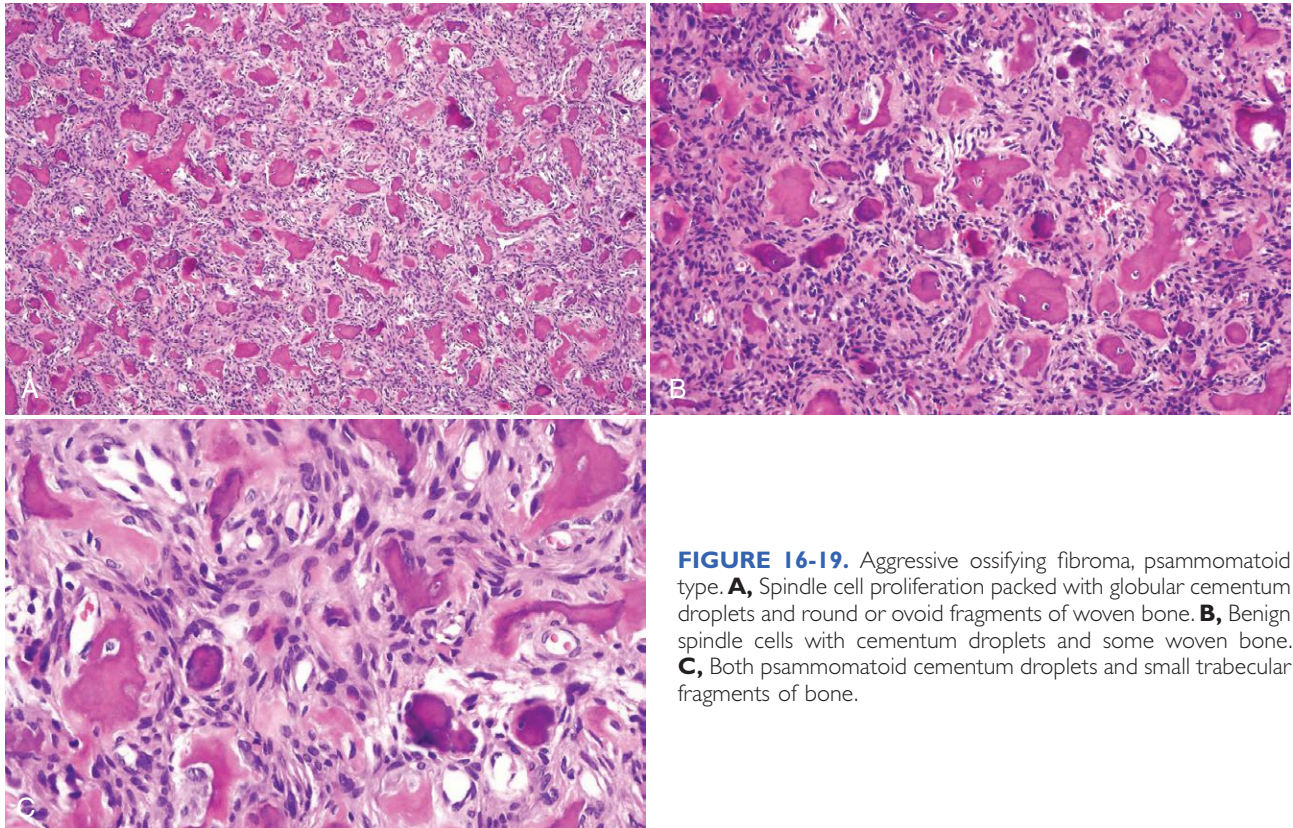


**FIGURE 16-17.** Aggressive ossifying fibroma, trabecular type. **A**, Cellular proliferation of spindle cells with osteoid and woven bone formation. **B**, Osteoid, woven bone, spindle cells, and giant cells. **C**, Osteoid and woven bone containing plump osteocytes and osteoblasts surrounded by spindle cells. **D**, Plump osteocytes, osteoblasts, and cellular stroma with spindled and stellate cells. **E**, Early aneurysmal bone cystlike areas.



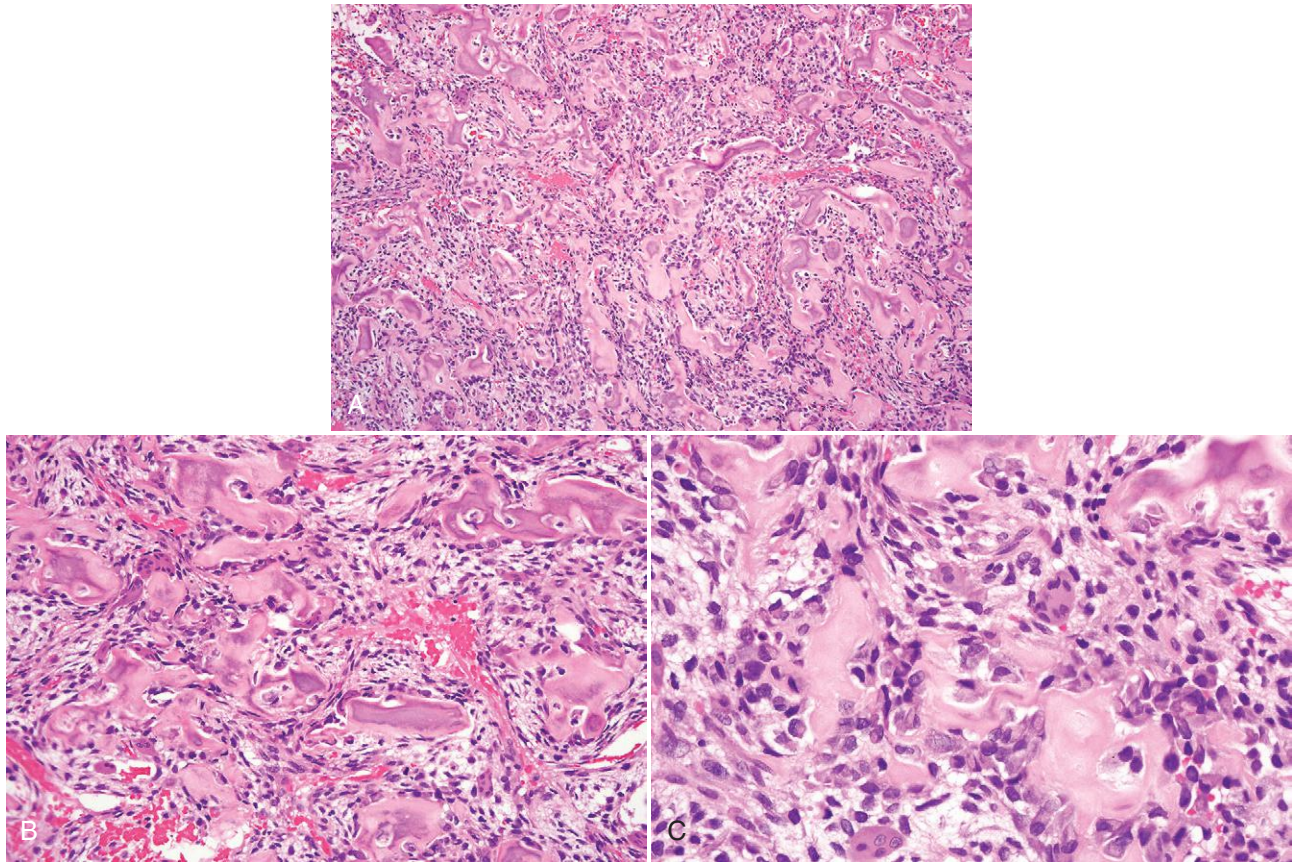


**FIGURE 16-18.** Aggressive ossifying fibroma, trabecular type. **A**, Cellular proliferation of spindle cells with osteoid and woven bone formation. **B**, Osteoid formation and reactive or residual bone at *left*; areas of loose myxoid stroma within cellular areas. **C**, Osteoid and woven bone with plump osteocytes and osteoblasts; stellate and spindle cells within stroma. **D**, Clusters of multinucleated giant cells within myxoid stroma.

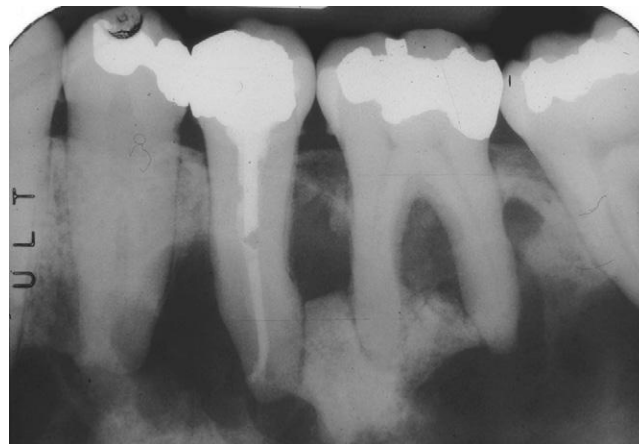

**FIGURE 16-19.** Aggressive ossifying fibroma, psammomatoid type. **A**, Spindle cell proliferation packed with globular cementum droplets and round or ovoid fragments of woven bone. **B**, Benign spindle cells with cementum droplets and some woven bone. **C**, Both psammomatoid cementum droplets and small trabecular fragments of bone.





**FIGURE 16-20.** Osteoblastoma. **A**, Trabeculae of woven bone with a hematoxyphilic hue in a cellular stroma. **B**, Proliferation of plump osteoblasts and osteoclasts within a vascular stroma. **C**, Multiple layers of osteoblasts with osteoclasts on the same lacunae.



**FIGURE 16-21.** Simple bone cyst arising in multifocal (florid) cemento-osseous dysplasia. This is periapical film from patient in Figure 16-7; patient developed swelling of the face, and on exploration, an empty cavity was noted around the osseous mass surrounding the tooth.



## PAGET DISEASE OF BONE (OSTEITIS DEFORMANS)

Paget disease of bone is a metabolic bone disease that leads to disorganized deposition of bone that is dense but has poor mechanical strength and, therefore, is prone to fractures.

### Clinical Findings

- Affects 1% to 2% of the white population (usually men) older than age 55, with highest frequency in the United Kingdom and lowest frequency in Asia; familial history in 15% to 40% of cases; first sign may be bone pain and headaches; deposition of bone around skull foramina may lead to neurologic symptoms, such as hearing or visual loss; poor fit of dentures or hats and spacing between teeth may occur from expansion of skull and jaw bones.
- Radiographs in early stages show osteoporotic changes; in the mixed stage, there is thickening of bones with mixed radiolucency and radiopacity (“cotton wool appearance”) with bone sclerosis being more marked as disease progresses (Fig. 16-22).
- High levels of bone-specific alkaline phosphatase and urine hydroxyproline are noted.

### Etiopathogenesis and Histopathologic Findings

Both genetic and environmental influences have been identified. Some cases are inherited in an autosomal dominant fashion; sequestosome, a gene that encodes p62 (a protein involved in NF $\kappa$ B signaling) is present in 20% to 50% of inherited and 5% to 20% of sporadic cases; increased number and activity of osteoclasts leads to initial resorption of bone and osteoporotic appearance (osteoclastic stage), followed by compensatory but overproduction of lamellar bone in a haphazard fashion with prominent vascularity (mixed osteoclastic-osteoblastic stage), and finally, “burnt out” stage with fibrosis of connective tissue; the role of paramyxovirus and other viruses (such as measles and distemper virus) as a trigger is controversial.

- The haphazard deposition of bone results in a mosaic pattern and many resting and reversal lines; numerous giant, irregular-shaped, hypernucleated osteoclasts are present; many osteoblasts are noted on surface of bone trabeculae, and there is marked hypervascularity in the mixed stage (Fig. 16-23).
- Giant cell tumors occur infrequently in association with this disease.
- Microtubular inclusions are seen on ultrastructural studies.

### Differential Diagnosis

- Osteoblastoma may look similar with many osteoclasts (although these are not usually hypernucleated), osteoblasts, and hypervascular stroma, but radiographs show a diffuse process in Paget disease.

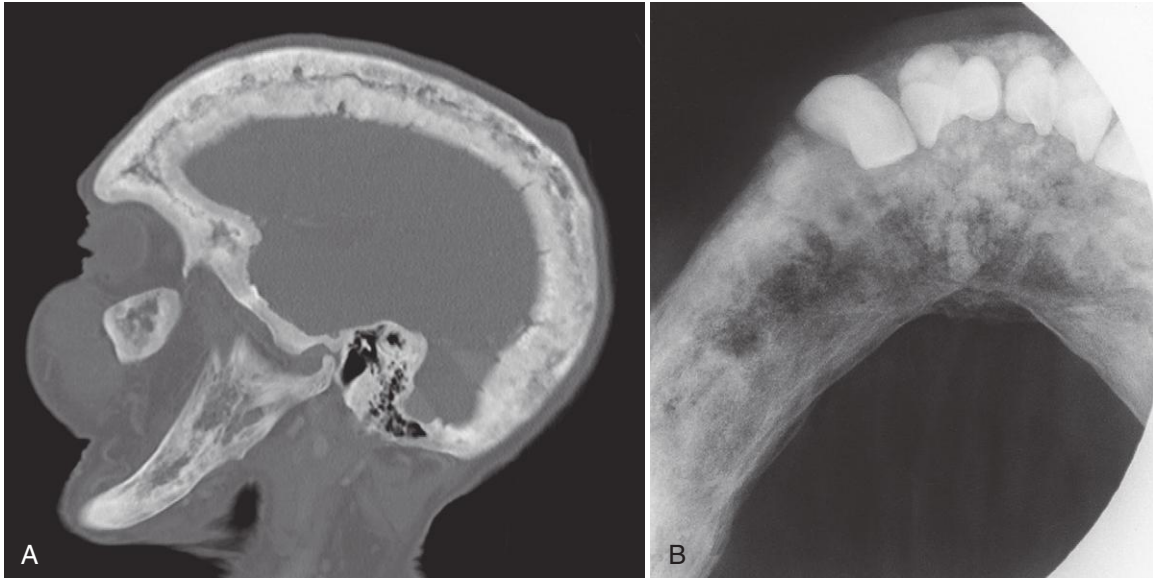
### Management and Prognosis

- Treatment is with antiresorptive drugs, such as bisphosphonates (first line of treatment), or calcitonin; antiinflammatory agents for management of pain, and surgery for correction of deformities.
- Less than 1% of cases develop osteosarcoma (usually osteoblastic type).

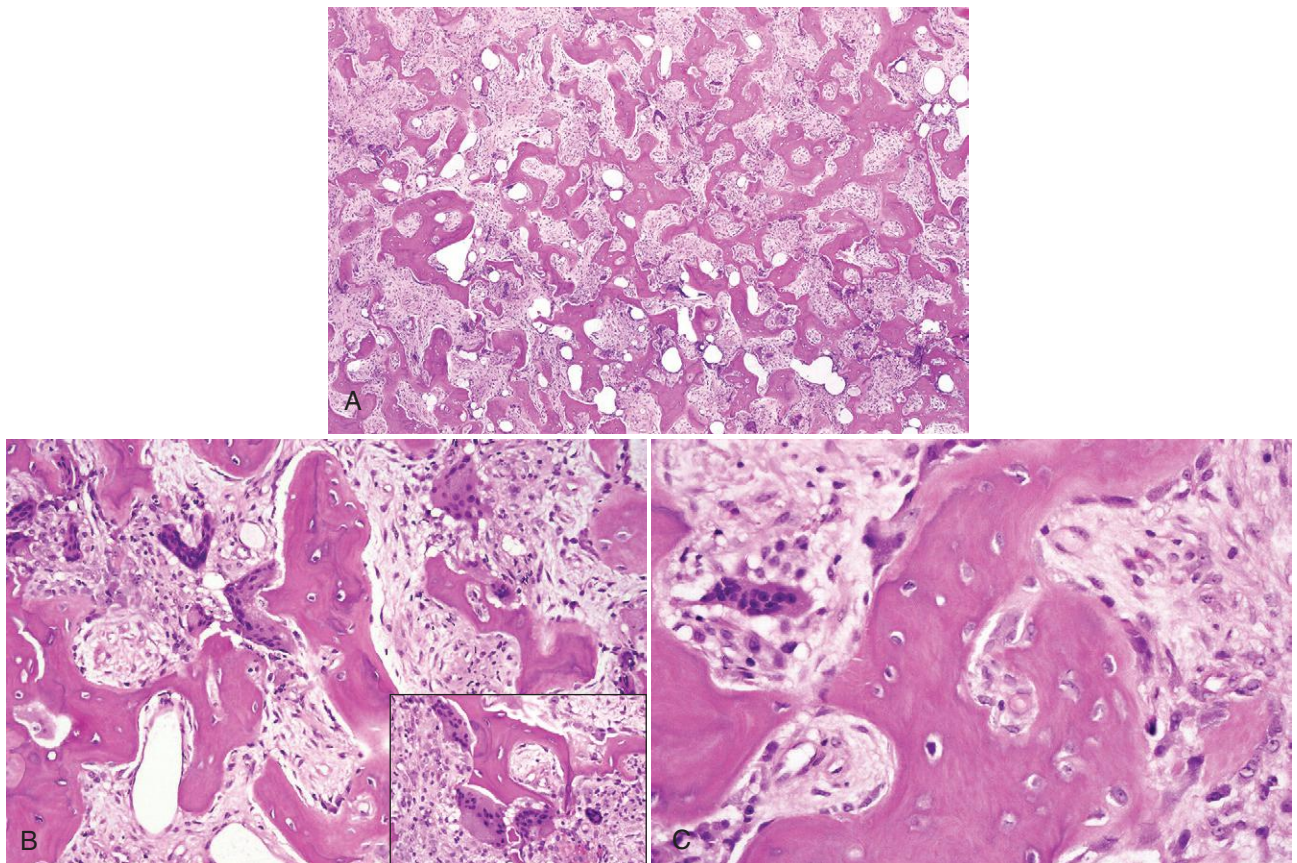
### REFERENCES

- Bullough P. *Orthopaedic Pathology*. 5th ed. St. Louis: Mosby; 2010.
- Hansen MF, Seton M, Merchant A. Osteosarcoma in Paget's disease of bone. *J Bone Miner Res*. 2006;21(suppl 2):P58-P63.
- Hoch B, Hermann G, Klein MJ, et al. Giant cell tumor complicating Paget disease of long bone. *Skeletal Radiol*. 2007;36:973-978.
- Morissette J, Laurin N, Brown JP. Sequestosome 1: mutation frequencies, haplotypes, and phenotypes in familial Paget's disease of bone. *J Bone Miner Res*. 2006;21(suppl 2):P38-P44.
- Ralston SH, Langston AL, Reid IR. Pathogenesis and management of Paget's disease of bone. *Lancet*. 2008;372:155-163.
- Roodman GD. Insights into the pathogenesis of Paget's disease. *Ann N Y Acad Sci*. 2010;1192:176-180.
- Seitz S, Priemel M, Zustin J, et al. Paget's disease of bone: histologic analysis of 754 patients. *J Bone Miner Res*. 2009;24:62-69.





**FIGURE 16-22.** Paget disease of bone (osteitis deformans). **A**, Sagittal CT shows thickened cranial bones, maxilla and mandible, and an increase in bone density. **B**, Occlusal radiograph shows mottled radiolucency/opacity of the mandible. (From White SC, Pharoah MJ: Oral Radiology: Principles and Interpretation. 6th ed. St. Louis, Mosby, 2009.)



**FIGURE 16-23.** Paget disease of bone (osteitis deformans). **A**, Anastomosing trabeculae of woven bone with many osteoclasts and prominent dilated vessels. **B**, Giant hypernucleated osteoclasts, dilated vessels, and bony trabeculae with resting and reversal lines. **C**, Many osteoblasts are present laying down osteoid. (**A**, Courtesy of Dr. Charles E. Tomich, Indiana University of School of Dentistry, Indianapolis, Ind.)



## CENTRAL GIANT CELL GRANULOMA (AGGRESSIVE AND NONAGGRESSIVE GIANT CELL LESION, CENTRAL GIANT CELL LESION, CENTRAL GIANT CELL REPARATIVE GRANULOMA)

Data suggest that the nonaggressive and aggressive giant cell granulomas and lesions of the maxillofacial complex have similar clinical presentations and treatment outcomes when compared, respectively, with the nonaggressive and aggressive axial-appendicular giant cell lesions; therefore, they may represent the same disease process.

### Clinical Findings

- Lesions occur in the first to third decade of life, often presenting as a unilocular or multilocular radiolucency of the mandible (75% of cases), usually in the anterior or body (Fig. 16-24, A).
- Aggressive type is less than 5 cm, recurs (primary criteria) or shows at least three of the following secondary criteria: rapid growth, root resorption, tooth displacement and thinning, or perforation of the cortical plate (see Fig. 16-24, B).
- Multiple giant cell lesions are often seen in Noonan-like multiple giant cell lesion syndrome (associated with *PTPN11* and *SOS1* mutations, among others) and in hyperparathyroidism.

### Etiopathogenesis and Histopathologic Features

Cells are derived from mesenchymal stromal cells that differentiate along the monocyte-macrophage-osteoclast lineage. No consistent genetic abnormalities have been noted, although frequent telomeric associations have been reported in giant cell tumor of bone.

- Proliferation of mononuclear cells and clusters of multinucleated osteoclast-like giant cells with abundant fresh hemorrhage, siderophages, and reactive osteoid and woven bone formation; giant cells have 20 to 30 nuclei; mononuclear cells often show mitotic activity (Figs. 16-25 and 16-26).
- More extensive vasculature may correlate with aggressive lesions.
- Most giant cells and approximately 10% of mononuclear cells stain for tartrate-resistant acid phosphatase, CD68, cathepsin, and MMP-9; in situ hybridization studies show mRNA for osteoprotegerin within giant cells and RANK and RANKL within stromal cells; both show variable staining for glucocorticoid and calcitonin receptors.

### Differential Diagnosis

- Brown tumor of hyperparathyroidism is indistinguishable from central giant cell granuloma; high parathormone levels and serum calcium differentiate the two conditions.

- Giant cell tumors of bone tend to have sheets rather than clusters of giant cells, which contain more nuclei, although distinction may be difficult; differences in histopathology may predict more aggressive behavior.
- Aneurysmal bone cyst consists of large blood-filled spaces lined by giant cells.
- Cherubism is distinguished by its typical bilateral presentation.
- Abundant woven bone deposition may suggest a fibro-osseous lesion, but giant cells usually are not a feature in the latter.

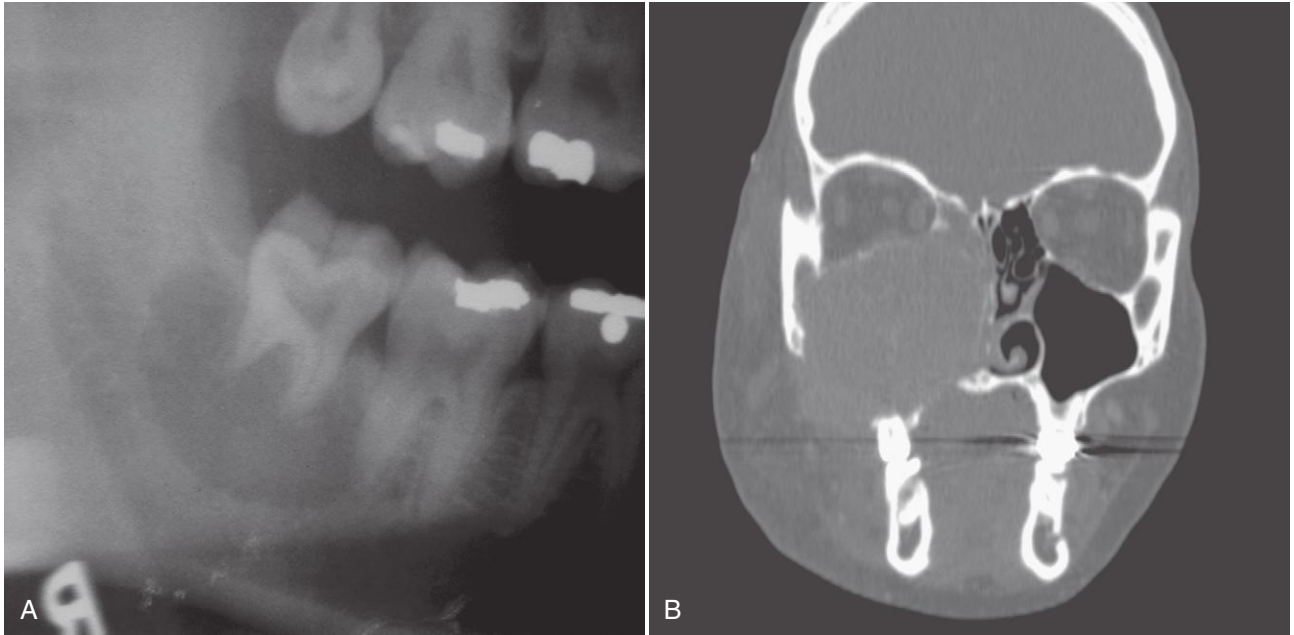
### Management and Prognosis

- Recurrence in 10% to 70% of cases depending on mode of therapy.
- Curettage, excision, resection, intralesional steroid injections, calcitonin nasal spray; enucleation and/or tumor debulking with adjuvant interferon- $\alpha$  therapy have been successful in resolving lesions completely (Fig. 16-27).
- Other treatment modalities are bisphosphonate and imatinib therapy.

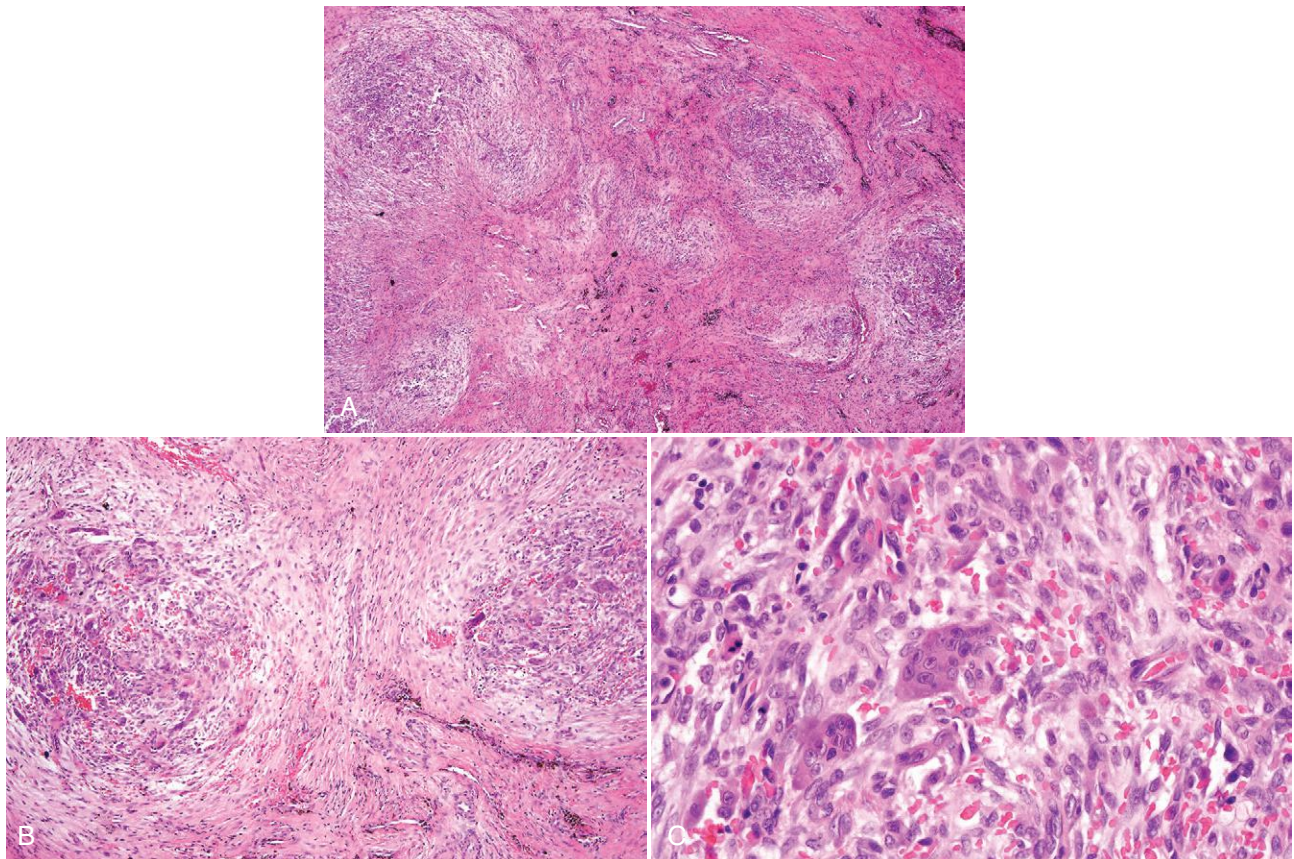
### REFERENCES

- Auclair PL, Cuenin P, Kratochvil FJ, et al. A clinical and histomorphologic comparison of the central giant cell granuloma and the giant cell tumor. *Oral Surg Oral Med Oral Pathol.* 1988;66:197-208.
- Chuong R, Kaban LB, Kozakewich H, Perez-Atayde A. Central giant cell lesions of the jaws: a clinicopathologic study. *J Oral Maxillofac Surg.* 1986;44:708-713.
- de Lange J, van Rijn RR, van den Burg H, et al. Regression of central giant cell granuloma by a combination of interferon and imatinib: a case report. *Br J Oral Maxillofac Surg.* 2009;47:59-61.
- Dewsnup NC, Susarla SM, Abulikemu M, et al. Immunohistochemical evaluation of giant cell tumors of the jaws using CD34 density analysis. *J Oral Maxillofac Surg.* 2008;66:928-933.
- Gebre-Medhin S, Broberg K, Jonson T, et al. Telomeric associations correlate with telomere length reduction and clonal chromosome aberrations in giant cell tumor of bone. *Cytogenet Genome Res.* 2009;124:121-127.
- Gleason BC, Kleinman PK, Debelenko LV, et al. Novel karyotypes in giant cell-rich lesions of bone. *Am J Surg Pathol.* 2007;31:926-932.
- Kaban LB, Troulis MJ, Wilkinson MS, et al. Adjuvant antiangiogenic therapy for giant cell tumors of the jaws. *J Oral Maxillofac Surg.* 2007;65:2018-2024; discussion 2024.
- Liu B, Yu SF, Li TJ. Multinucleated giant cells in various forms of giant cell containing lesions of the jaws express features of osteoclasts. *J Oral Pathol Med.* 2003;32:367-375.
- Resnick CM, Margolis J, Susarla SM, et al. Maxillofacial and axial/appendicular giant cell lesions: unique tumors or variants of the same disease? A comparison of phenotypic, clinical, and radiographic characteristics. *J Oral Maxillofac Surg.* 2010;68:130-137.
- Tobon-Arroyave SI, Franco-Gonzalez LM, Isaza-Guzman DM, et al. Immunohistochemical expression of RANK, GR $\alpha$  and CTR in central giant cell granuloma of the jaws. *Oral Oncol.* 2005;41:480-488.
- Vered M, Buchner A, Dayan D. Immunohistochemical expression of glucocorticoid and calcitonin receptors as a tool for selecting therapeutic approach in central giant cell granuloma of the jawbones. *Int J Oral Maxillofac Surg.* 2006;35:756-760.
- Whitaker SB, Waldron CA. Central giant cell lesions of the jaws. A clinical, radiologic and histopathologic study. *Oral Surg Oral Med Oral Pathol.* 1993;75:199-208.



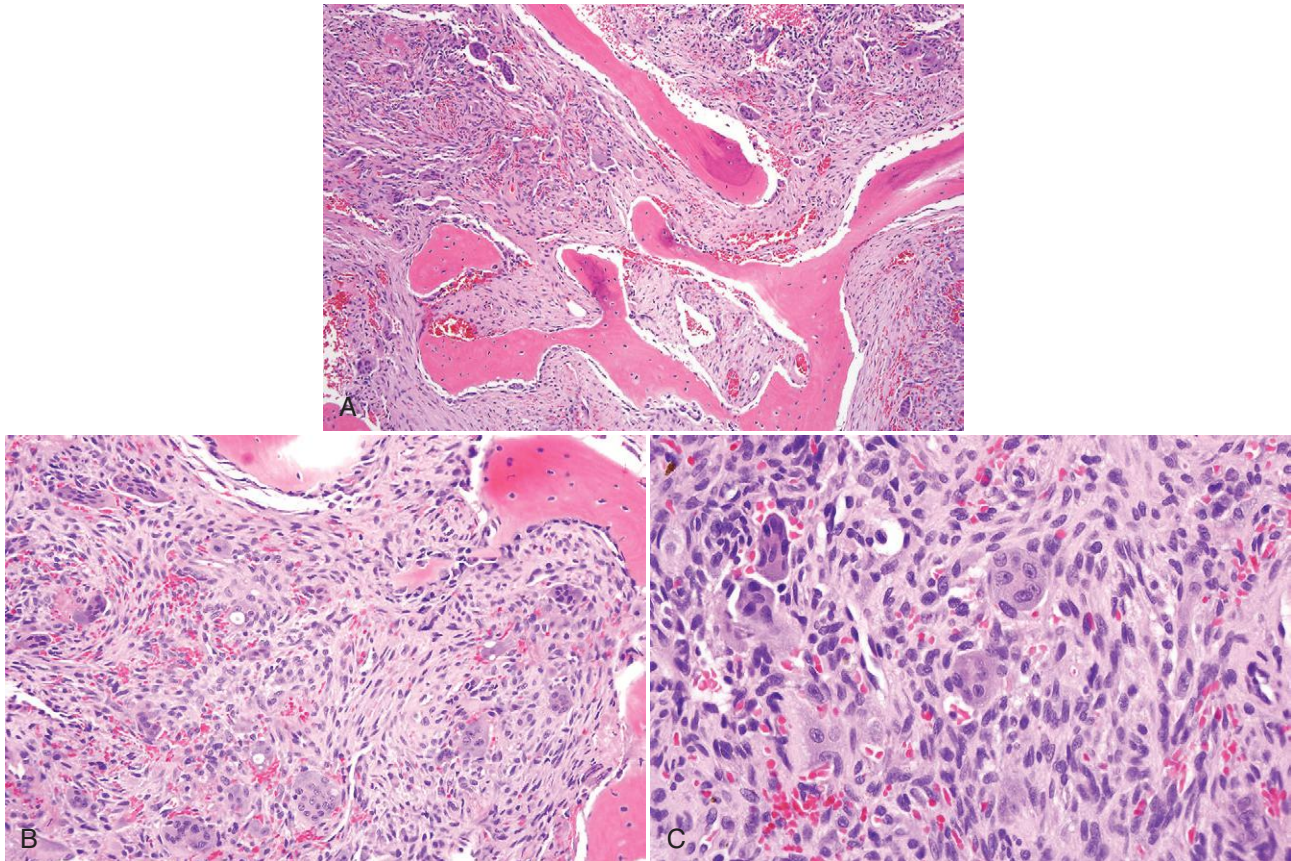


**FIGURE 16-24.** **A**, Nonaggressive central giant cell granuloma. Panoramic radiograph shows radiolucency at the apex of right mandibular second molar. **B**, Aggressive central giant cell granuloma. Recurrent tumor of right maxilla involving maxillary and ethmoid sinuses and nasal cavity. (**A**, Courtesy of Dr. Leonard B. Kaban and W. C. Guralnick, Harvard School of Dental Medicine and Massachusetts General Hospital, Boston, Mass; **B**, Courtesy of Dr. Leonard B. Kaban and Dr. Maria Toulis, Harvard School of Dental Medicine and Massachusetts General Hospital, Boston, Mass.)

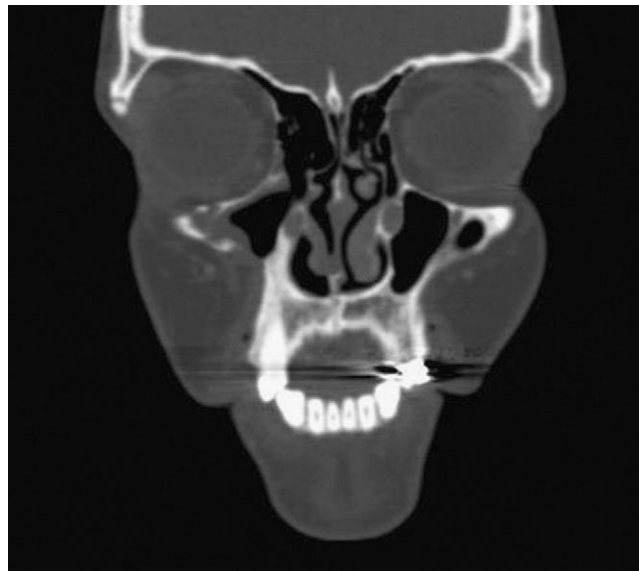

**FIGURE 16-25.** Central giant cell granuloma. **A**, Nodules of giant cells, fibrosis, and hemosiderin deposits. **B**, Nodular aggregates of giant cells and spindled mononuclear cells with fibrosis and hemosiderin deposits. **C**, Mononuclear cells with benign nuclei and osteoclast-like giant cells with hemorrhage.





**FIGURE 16-26.** Central giant cell granuloma. **A**, Giant cells, hemorrhage, and abundant reactive bone. **B**, Mononuclear cells, clusters of giant cells, hemorrhage, and reactive bone formation with osteoblastic rimming. **C**, Mononuclear and osteoclast-like giant cells and hemorrhage.



**FIGURE 16-27.** Aggressive central giant cell granuloma (same patient as in Figure 16-24, B): coronal CT exhibits resolution of right maxillary lesion 3 years after enucleation and 2 years after completion of treatment with systemic interferon therapy. (Courtesy of Dr. Leonard B. Kaban and Dr. Maria Troulis, Harvard School of Dental Medicine and Massachusetts General Hospital, Boston, Mass.)



## CHERUBISM

### Clinical Findings

- Condition occurs most frequently in first decade; bilateral multiloculated radiolucencies of the posterior mandible and ascending ramus often result in tooth displacement, delayed tooth eruption, and loosening of teeth (Fig. 16-28); involvement of the maxilla causes eyes to turn upward, resembling a cherub; a unilateral lesion may be the first presentation.
- Lesions cause bony expansion and swelling up to age 12; symptoms are usually quiescent for a few years and then regress over many years beginning in adolescence.

### Etiopathogenesis and Histopathologic Features

Cherubism is an autosomal dominant condition caused in many, but not all, cases by a mutation in the *SH3BP2* gene on chromosome 4p16.3 that encodes c-Abl-binding protein; tumor necrosis factor may mediate bone loss.

- Clusters of multinucleated osteoclast-like giant cells and proliferation of spindled and mononuclear cells are present in a delicately fibrous stroma; foci of hemorrhage and perivascular hyalinization are common (Fig. 16-29).

### Differential Diagnosis

- Central giant cell granuloma generally has more giant cells and, importantly, is a solitary lesion in the anterior and body of mandible.
- Noonan syndrome (characterized by short stature, cardiac defects, chest deformity, and facial dysmorphism such as hypertelorism, downward slanting palpebral fissures, and low-set, posteriorly placed ears)

is associated with mutations in *PTPN11* gene in 50% of cases; Noonan-like multiple giant cell lesion syndrome shows overlap with Noonan syndrome but also presents with giant cell lesions, and some have mutations in the *PTPN11* or *SOS1* gene.

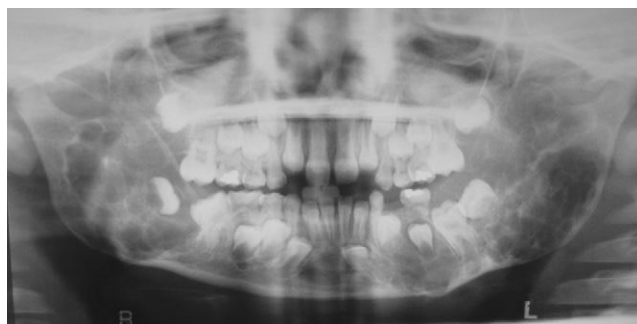
- Aneurysmal bone cyst has blood-filled spaces rimmed by giant cells.

### Management and Prognosis

- Recontouring of the bone is for aesthetics only; rare cases respond to calcitonin and most symptoms regress.

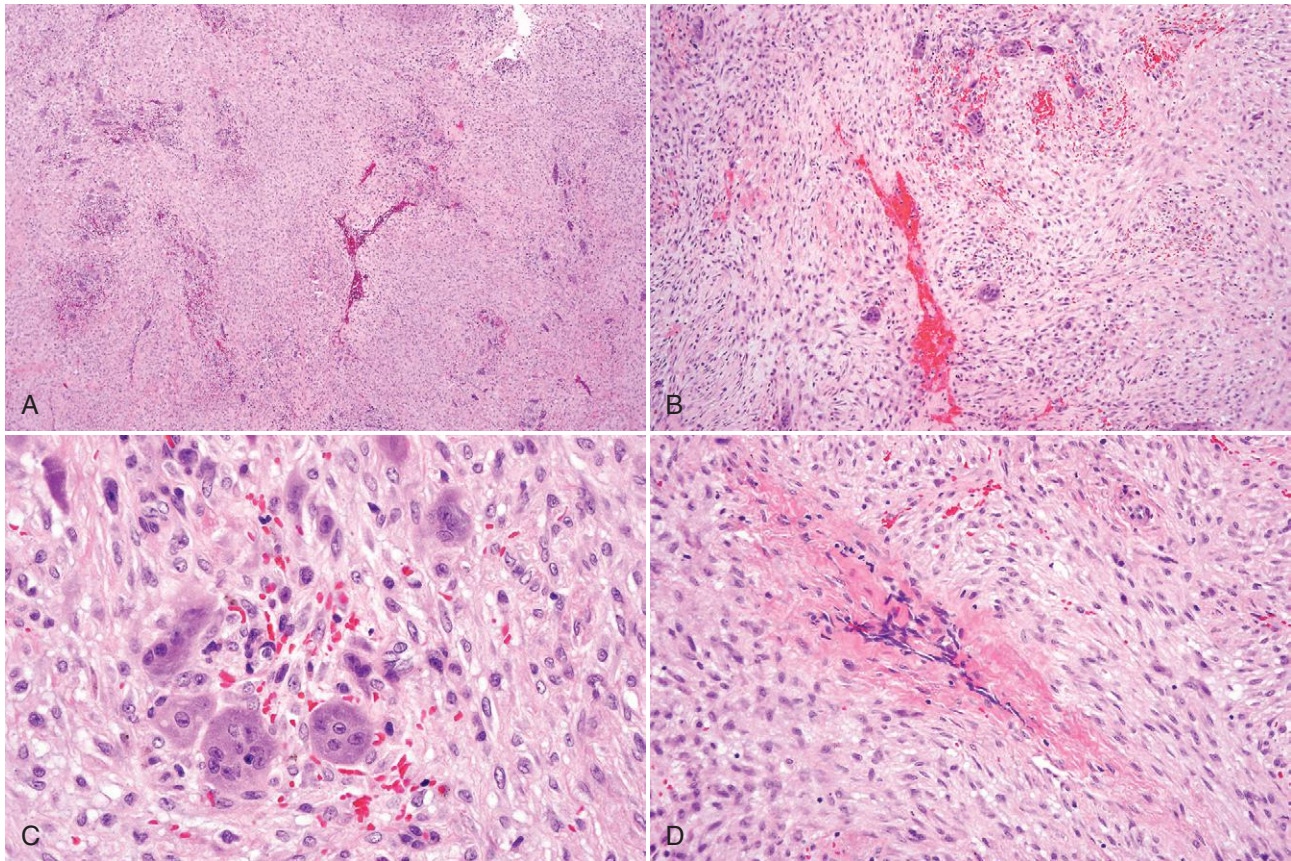
### REFERENCES

- Bufalino A, Carrera M, Carlos R, Coletta RD. Giant cell lesions in Noonan syndrome: case report and review of the literature. *Head Neck Pathol.* 2010;4:174-177.
- Carvalho Silva E, Carvalho Silva GC, Vieira TC. Cherubism: clinicoradiographic features, treatment, and long-term follow-up of 8 cases. *J Oral Maxillofac Surg.* 2007;65:517-522.
- de Lange J, van den Akker HP, Scholtemeijer M. Cherubism treated with calcitonin: report of a case. *J Oral Maxillofac Surg.* 2007;65:1665-1667.
- Hanna N, Parfait B, Talaat IM, et al. *SOS1*: a new player in the Noonan-like/multiple giant cell lesion syndrome. *Clin Genet.* 2009;75:568-571.
- Meng XM, Yu SF, Yu GY. Clinicopathologic study of 24 cases of cherubism. *Int J Oral Maxillofac Surg.* 2005;34:350-356.
- Tartaglia M, Gelb BD. Noonan syndrome and related disorders: genetics and pathogenesis. *Annu Rev Genomics Hum Genet.* 2005;6:45-68.
- Ueki Y, Tiziani V, Santanna C, et al. Mutations in the gene encoding c-Abl-binding protein *SH3BP2* cause cherubism. *Nat Genet.* 2001;28:125-126.
- Ueki Y, Lin CY, Senoo M, et al. Increased myeloid cell responses to M-CSF and RANKL cause bone loss and inflammation in *SH3BP2* "cherubism" mice. *Cell.* 2007;128:71-83.
- Von Wowern N. Cherubism: a 36-year long-term follow-up of 2 generations in different families and review of the literature. *Oral Surg Oral Med Oral Pathol Oral Radiol Endod.* 2000;90:765-772.



**FIGURE 16-28.** Cherubism manifesting with bilateral multiloculated radiolucencies of the mandibular rami and body. (Courtesy of Dr. Bonnie Padwa, Children's Hospital Boston, Boston, Mass.)





**FIGURE 16-29.** Cherubism. **A**, Clusters of multinucleated giant cells and diffuse proliferation of spindled mononuclear cells in delicately collagenized stroma. **B**, Clusters of giant cells and diffuse background of spindled mononuclear cells, fresh hemorrhage, and eosinophilic fibrinous material. **C**, Osteoclast-like giant cells and spindled mononuclear cells. **D**, Perivascular deposits of eosinophilic fibrinoid material.

## DESMOPLASTIC FIBROMA

This lesion is an intraosseous counterpart of desmoid-type fibromatosis (aggressive fibromatosis or extraabdominal desmoid).

### Clinical Findings

- Lesion occurs in 85% of patients who are younger than 30 years; 85% of lesions are in mandible; jaw swelling occurs, sometimes with pain; well-defined radiolucency with cortical perforation and extension into soft tissues is seen in 30% of cases.

### Etiopathogenesis and Histopathologic Features

Lesion likely arises from mesenchymal stem cells within bone and in rare cases demonstrate trisomy 8 and 20. The absence of involvement of APC- $\beta$ -catenin pathway suggests that, although it morphologically resembles desmoid-type fibromatosis, it develops via a different tumorigenic pathway.

- Proliferation of spindled fibroblasts and myofibroblasts in a richly collagenized stroma with sweeping fascicles and variable hyalinization; relatively paucicellular, minimal to no cytologic atypia, and mitoses

may be present (Fig. 16-30); positive for smooth muscle actin in more than 50% of cases; occasionally desmin positive

- $\beta$ -catenin positive in cytoplasm in up to 50% of cases, but nuclear staining rare

### Differential Diagnosis

- Benign fibrous histiocytoma has a whorled, storiform pattern with histiocytes and multinucleated giant cells.
- Muscle tumors are more cellular, and cells have abundant eosinophilic cytoplasm; neural tumors are positive for neural markers.

### Management and Prognosis

- Excision with clear margins is treatment of choice, with 5% recurrence; curettage results in 30% recurrence.

### REFERENCES

Bridge JA, Swarts SJ, Buresh C, et al. Trisomies 8 and 20 characterize a subgroup of benign fibrous lesions arising in both soft tissue and bone. *Am J Pathol.* 1999;154:729-733.

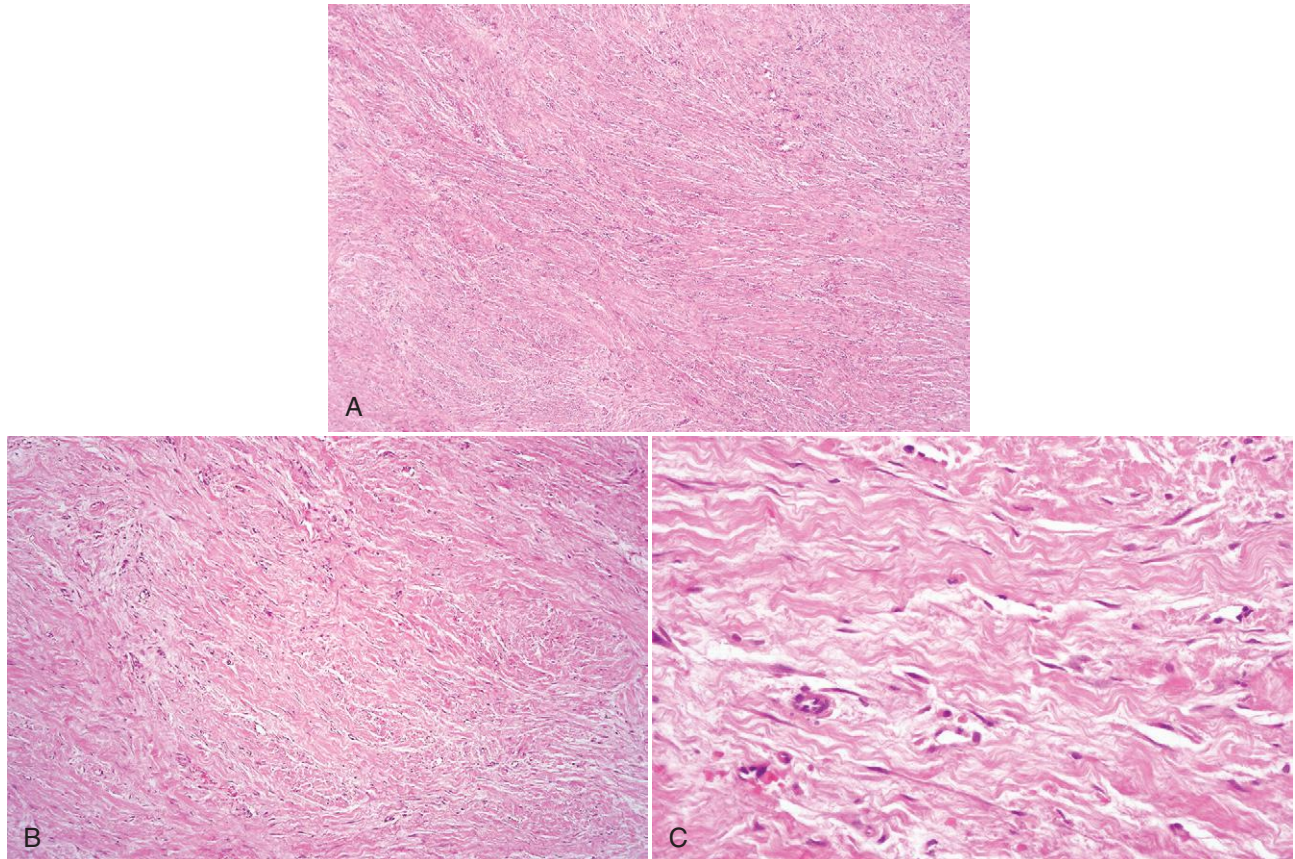


Carlson JW, Fletcher CD. Immunohistochemistry for beta-catenin in the differential diagnosis of spindle cell lesions: analysis of a series and review of the literature. *Histopathology*. 2007;51:509-514.

Fletcher C, Unni K, Mertens F, eds. *World Health Organization Pathology and Genetics: Tumours of Soft Tissue and Bone*. 3rd ed. Lyon, France: IARC Press; 2006.

Hauben EI, Jundt G, Cleton-Jansen AM, et al. Desmoplastic fibroma of bone: an immunohistochemical study including beta-catenin expression and mutational analysis for beta-catenin. *Hum Pathol*. 2005;36:1025-1030.

Said-Al-Naief N, Fernandes R, Louis P, et al. Desmoplastic fibroma of the jaw: a case report and review of literature. *Oral Surg Oral Med Oral Pathol Oral Radiol Endod*. 2006;101:82-94.



**FIGURE 16-30.** Desmoplastic fibroma. **A**, Sweeping fascicles of collagen with spindle cells. **B**, Dense collagen, almost keloidal in nature; pauci cellular stroma. **C**, Spindle cells are benign appearing.

## OSTEOSARCOMA (OSTEOGENIC SARCOMA)

Osteosarcoma is the most common primary non-hematopoietic malignancy of bone and the second most common intraosseous malignancy after multiple myeloma. There are two forms: intramedullary and surface-juxtacortical. In general, intramedullary gnathic osteosarcomas occur 10 to 20 years later than long bone osteosarcoma, and they tend to be medium- or high-grade tumors.

### Clinical Findings

- Lesion occurs in the third to fourth decade with pain, swelling, and paresthesia; equally distributed in mandible and maxilla; lesion may erode bone to involve soft tissues; mixed lucent-opaque lesion appears with poorly defined borders (Fig. 16-31, A); intraoral

periapical radiographs show widening of periodontal ligament space; parosteal osteosarcomas are enlarging masses attached to surface of the jaw bones (see Fig. 16-31, B); a sun burst-like osteophytic reaction is seen on radiographs if the periosteum is involved.

### Etiopathogenesis and Histopathologic Features

Chromosomal aberrations involving chromosomes 1, 11, 14, 15, 17, and 19 have been noted in osteosarcoma of long bones. Secondary osteosarcoma may develop in preexisting Paget disease of bone or with a history of radiation. Patients who develop osteosarcoma with a history of hereditary retinoblastoma or Li-Fraumeni syndrome with mutations in RB1 tumor suppressor gene and TP53 gene, respectively, have poorer prognosis.

Intramedullary lesions are usually chondroblastic, osteoblastic, or fibroblastic (least common); giant cell,



small cell, telangiectatic, and dedifferentiated types are rare; pediatric cases may be primarily osteoblastic; up to 80% are high-grade tumors.

- Atypical osteoblasts lay down irregular, lacy, basophilic trabeculae of malignant osteoid and woven bone; cells have large nuclei and nucleoli that are hyperchromatic (Fig. 16-32); atypical cartilage formation is seen in the chondroblastic type, and the fibroblastic type contains atypical spindle cells (Fig. 16-33).
- Parosteal (low-grade juxtacortical) osteosarcoma is a low-grade osteosarcoma that is easily mistaken for a benign fibro-osseous lesion; thick anastomosing trabeculae of bone are surrounded by fibrous tissue with minimal atypia; very focal osteoblastic rimming is present, and there is infiltration of the cortex; 25% to 50% show cartilage formation with ossification (Figs. 16-34 and 16-35); dedifferentiation occurs in 15% to 20% of cases, and this is associated with a poorer prognosis; MDM2 and CKD4 positivity has been noted in more than 80% of cases.
- Intramedullary low-grade osteosarcoma lesions also show spindle cell proliferation with deposition of osteoid or cementum-like material; dedifferentiation occurs in long bone tumors.
- Periosteal osteosarcoma is chondroblastic osteosarcoma of intermediate grade.
- High-grade juxtacortical osteosarcoma reveals cells that are more atypical, and chondroblastic types are difficult to differentiate from periosteal osteosarcoma.

### Differential Diagnosis

- Osteoblasts in osteoblastoma are less atypical, and bone trabeculae are more regular in contour and more uniform overall; prominent vasculature and osteoclasts are noted; histopathologic differentiation between the two may be difficult, but osteoblastoma presents as a circumscribed lucent-opaque lesion.
- Aggressive ossifying fibroma may show atypical osteoblasts but overall is fairly uniform in appearance and malignant bone is not formed.
- Fibrous dysplasia does not show significant atypia, and it may be difficult to distinguish from low-grade fibrous dysplasia-like osteosarcoma; however, the latter is often CDK4 and MDM2 positive.
- Chondrosarcoma does not usually produce malignant osteoid, although lesions may calcify.

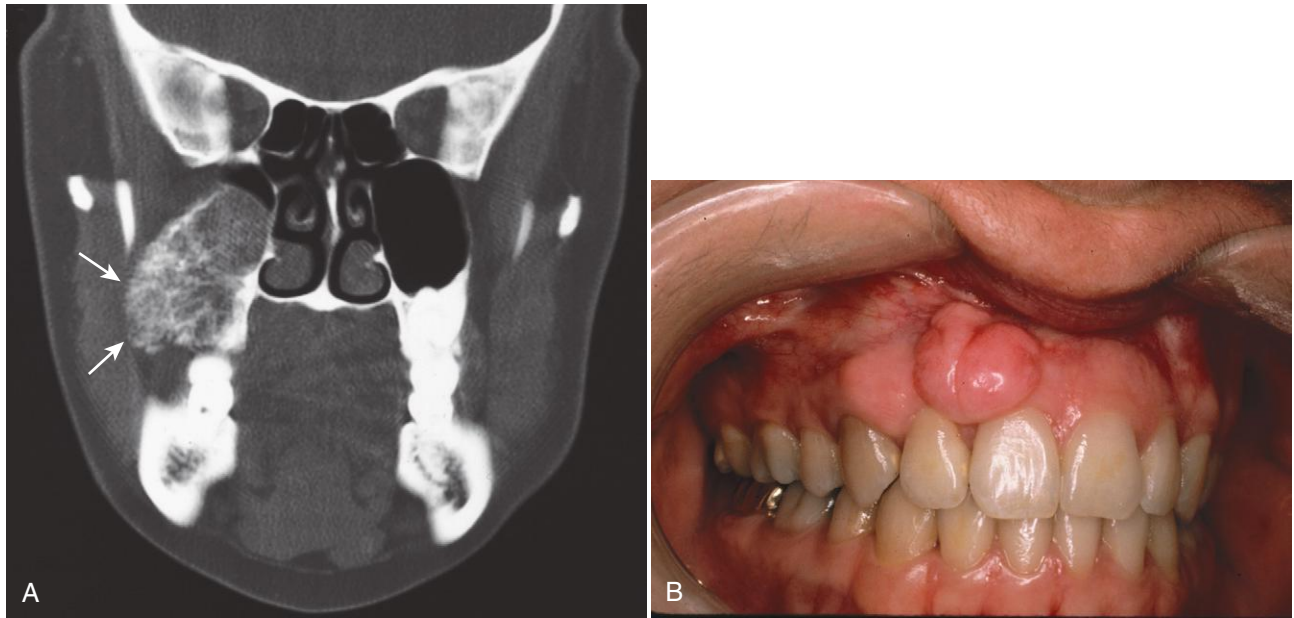
### Management and Prognosis

- Surgery and adjuvant chemotherapy is the treatment of choice; 5-year survival is 60%, and recurrence rate is 40% with 17% distant metastases.
- Prognosis is worsened with high histologic grade, involvement of margins, recurrence, advanced age, and in secondary osteosarcomas; in the long bones, long-term survival is 80% to 90% versus 15% for those who respond (>90% necrosis in tumor) to those who do not respond (<90% necrosis) to preoperative therapy.
- Parosteal osteosarcoma has better prognosis, with 90% 5-year survival; dedifferentiation is associated with a higher rate of metastasis, especially to the lungs.

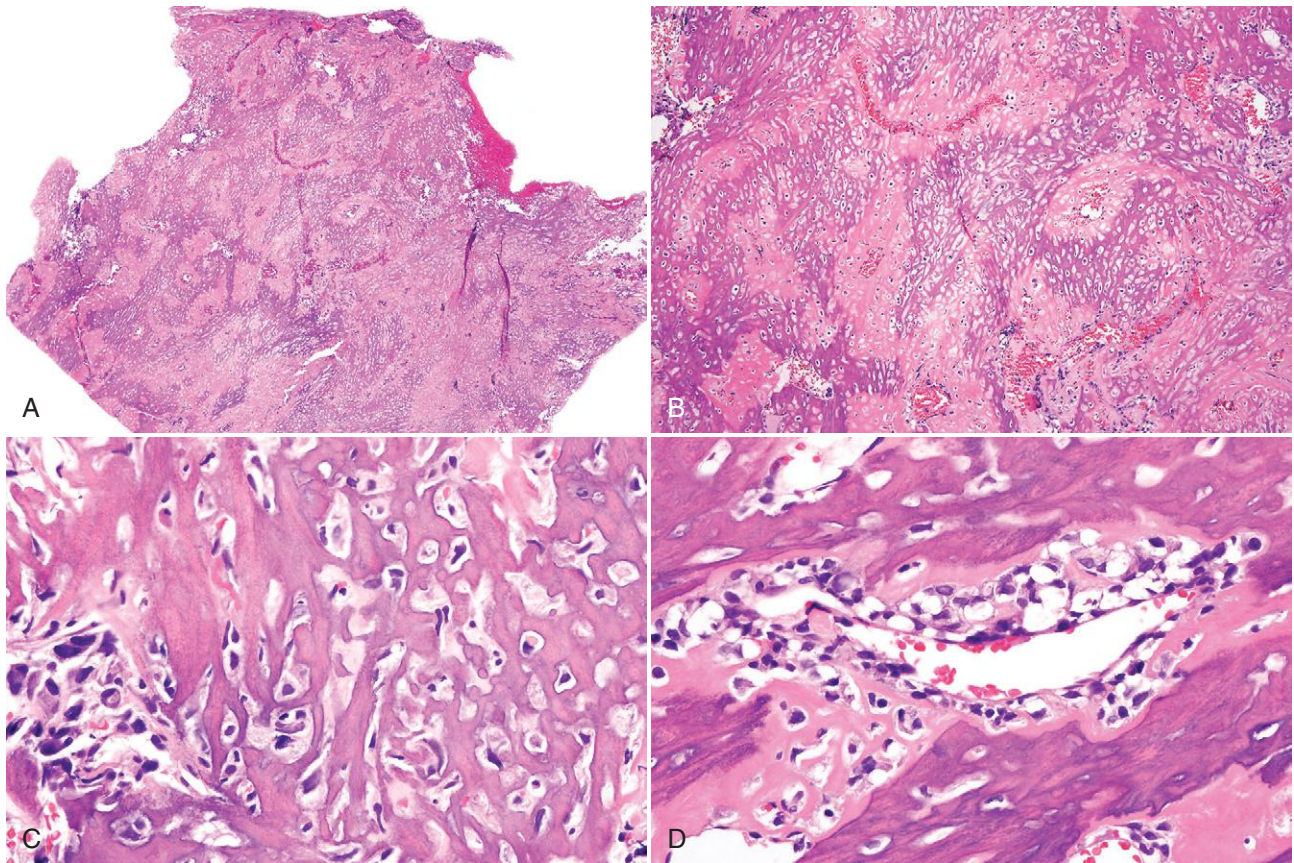
### REFERENCES

- Bertoni F, Bacchini P, Staals EL, Davidovitz P. Dedifferentiated parosteal osteosarcoma: the experience of the Rizzoli Institute. *Cancer*. 2005;103:2373-2382.
- Bennett JH, Thomas G, Evans AW, Speight PM. Osteosarcoma of the jaws: a 30-year retrospective review. *Oral Surg Oral Med Oral Pathol Oral Radiol Endod*. 2000;90:323-332.
- Canadian Society of Otolaryngology-Head and Neck Surgery Oncology Study Group. Osteogenic sarcoma of the mandible and maxilla: a Canadian review (1980-2000). *J Otolaryngol*. 2004;33:139-144.
- Demicco EG, Deshpande V, Nielsen GP, et al. Well-differentiated osteosarcoma of the jaw bones: a clinicopathologic study of 15 cases. *Am J Surg Pathol*. 2010;34:1647-1655.
- Dujardin F, Binh MB, Bouvier C, et al. MDM2 and CDK4 immunohistochemistry is a valuable tool in the differential diagnosis of low-grade osteosarcomas and other primary fibro-osseous lesions of the bone. *Mod Pathol*. 2011;624-637.
- Fletcher C, Unni K, Mertens F, eds. *World Health Organization Pathology and Genetics: Tumours of Soft Tissue and Bone*. 3rd ed. Lyon, France: IARC Press; 2006.
- Gadwal SR, Gannon FH, Fanburg-Smith JC, et al. Primary osteosarcoma of the head and neck in pediatric patients: a clinicopathologic study of 22 cases with a review of the literature. *Cancer*. 2001;91:598-605.
- Granowski-LeCornu M, Chuang S, Kaban LB, et al. Osteosarcoma of the jaws: factors influencing prognosis. *J Oral Maxillofac Surg*. 2011;69:2368-2375.
- Hewitt KM, Ellis G, Wiggins R, Bentz BG. Parosteal osteosarcoma: case report and review of the literature. *Head Neck*. 2008;30:122-126.
- Mardinger O, Givol N, Talmi YP, Taicher S. Osteosarcoma of the jaw. The Chaim Sheba Medical Center experience. *Oral Surg Oral Med Oral Pathol Oral Radiol Endod*. 2001;91:445-451.
- Nissanka EH, Amaratunge EA, Tilakaratne WM. Clinicopathological analysis of osteosarcoma of jaw bones. *Oral Dis*. 2007;13:82-87.
- Oda D, Bavisotto LM, Schmidt RA, et al. Head and neck osteosarcoma at the University of Washington. *Head Neck*. 1997;19:513-523.
- Okada K, Frassica FJ, Sim FH, et al. Parosteal osteosarcoma. A clinicopathological study. *J Bone Joint Surg Am*. 1994;76:366-378.



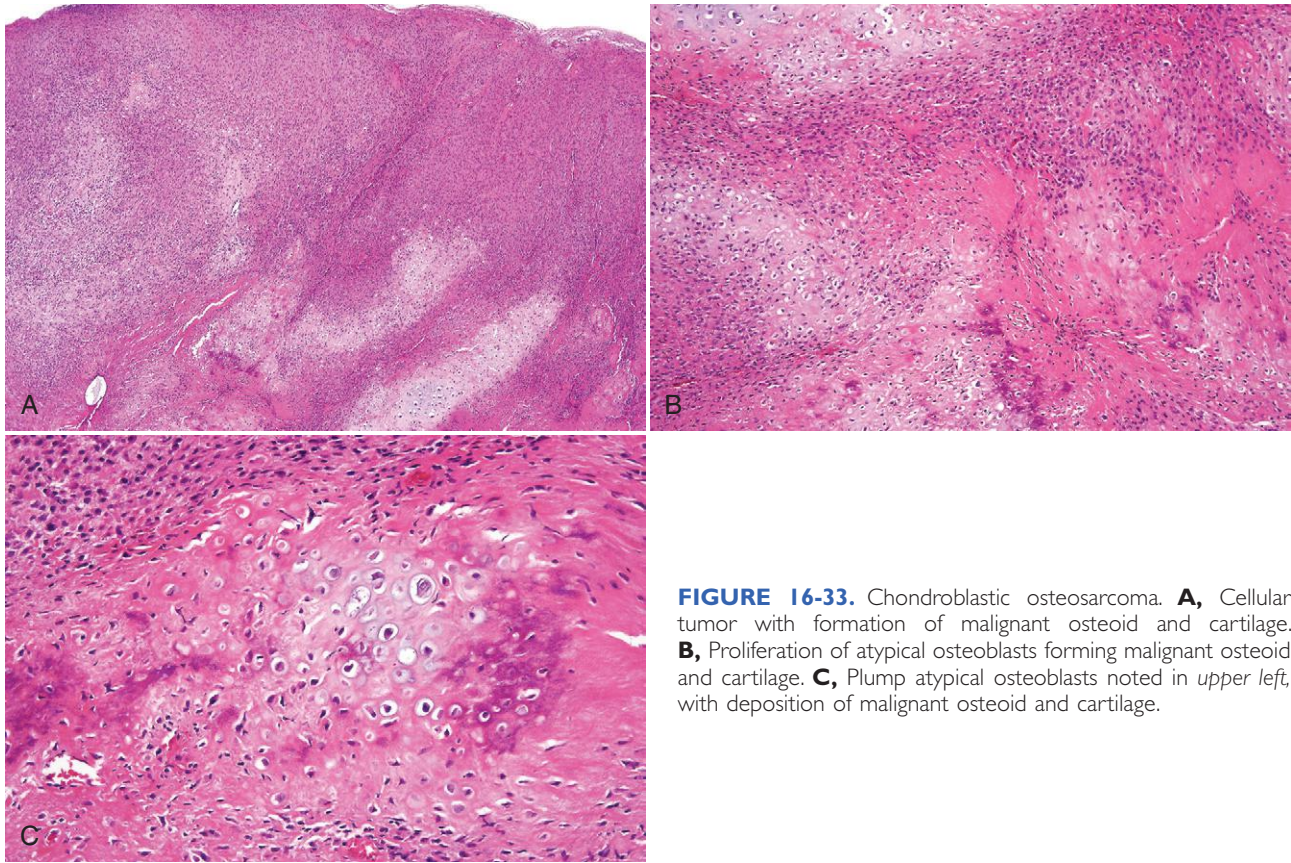


**FIGURE 16-31.** **A**, Intramedullary osteosarcoma. Coronal CT shows bone-producing tumor of the right maxilla with delicate bone spicules. **B**, Parosteal (low-grade) osteosarcoma. Exophytic, nodular tumor on the surface of the bone. (**A**, From White SC, Pharoah MJ: *Malignant diseases of the jaws*. In: *Oral Radiology, Principles and Interpretation*. 6th ed. St. Louis, Mosby, 2008; **B**, Courtesy of Department of Diagnostic Sciences, Baylor College of Dentistry, Houston, Tex.)

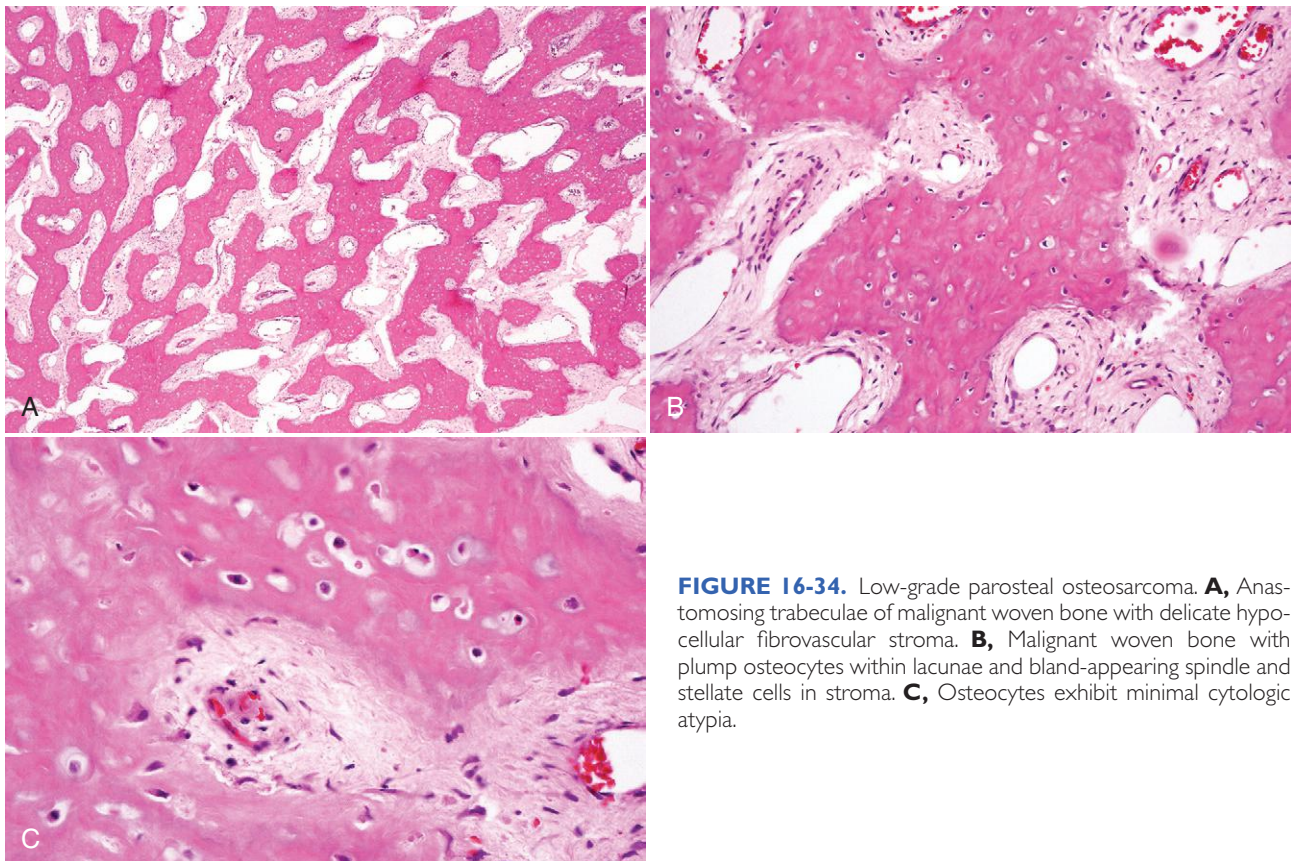


**FIGURE 16-32.** Osteoblastic osteosarcoma. **A**, Atypical osteoid and woven bone. **B**, Interlacing broad trabeculae of osteoid (eosinophilic) and woven bone (basophilic) with large lacunae. **C**, Lacy trabeculae of woven bone containing atypical osteoblasts and osteocytes with pleomorphic nuclei. **D**, Many atypical osteoblasts and osteocytes within osteoid and woven bone.



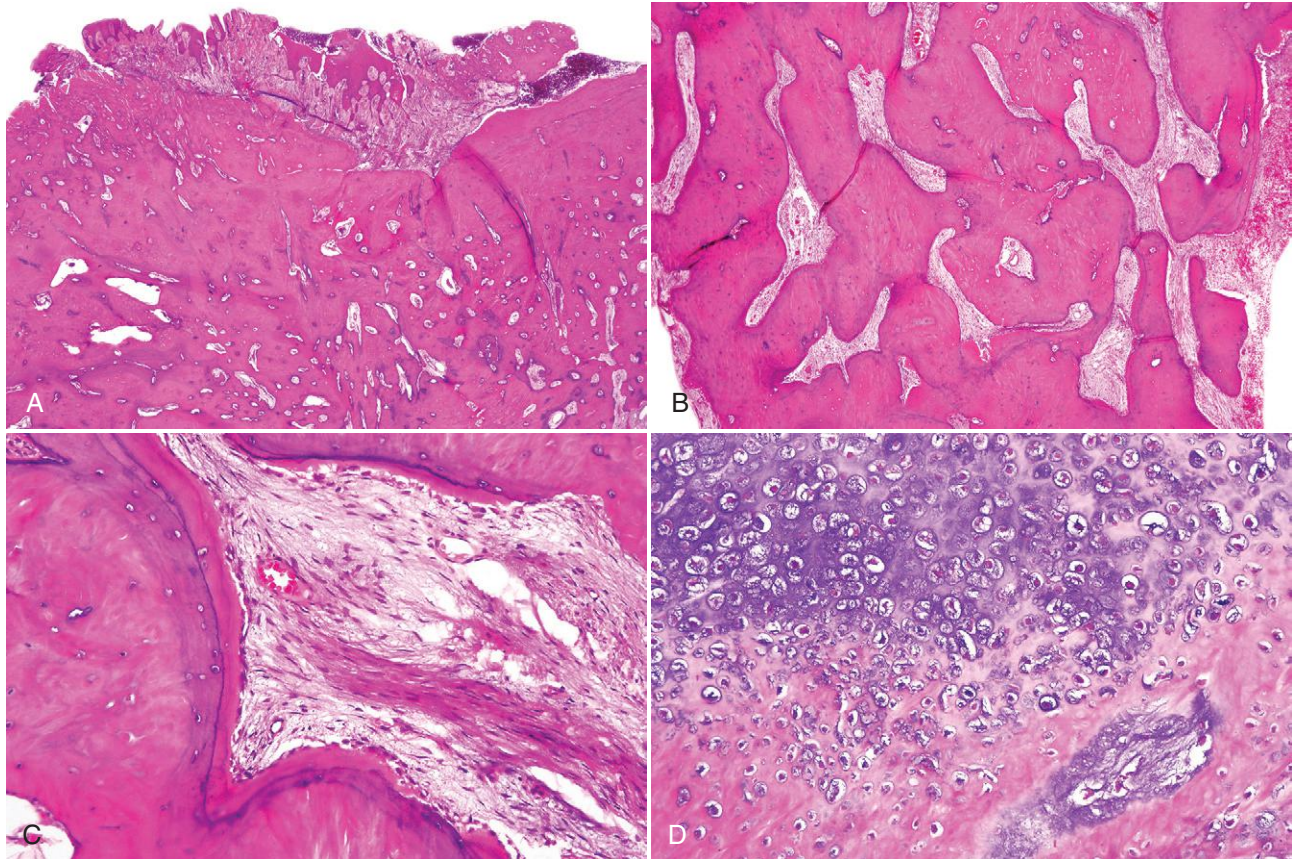


**FIGURE 16-33.** Chondroblastic osteosarcoma. **A**, Cellular tumor with formation of malignant osteoid and cartilage. **B**, Proliferation of atypical osteoblasts forming malignant osteoid and cartilage. **C**, Plump atypical osteoblasts noted in upper left, with deposition of malignant osteoid and cartilage.



**FIGURE 16-34.** Low-grade parosteal osteosarcoma. **A**, Anastomosing trabeculae of malignant woven bone with delicate hypocellular fibrovascular stroma. **B**, Malignant woven bone with plump osteocytes within lacunae and bland-appearing spindle and stellate cells in stroma. **C**, Osteocytes exhibit minimal cytologic atypia.





**FIGURE 16-35.** Low-grade parosteal osteosarcoma. **A**, Sclerotic mass of atypical bone lying in the lamina propria, completely replacing the normal cortex. **B**, Anastomosing seams of bone with intervening relatively hypocellular fibrovascular tissue. **C**, Bone rimmed by a single layer of bland-appearing osteoblasts with bland spindle cells in the stroma. **D**, Focal area of cartilaginous differentiation.

## CHONDROSARCOMA

Cartilaginous tumors within the jaw bones should be considered chondrosarcomas until proved otherwise because benign intraosseous chondroid tumors are extremely rare; in soft tissues, cartilaginous rests may be found in the nasopalatine area, within denture-related fibrous hyperplasia (epulis fissuratum), and within other neoplasms such as lipomas and pleomorphic adenomas.

### Clinical Findings

- Conventional chondrosarcoma: fifth and sixth decade; pain and swelling of the jaw; poorly demarcated destructive radiolucency with most cases showing coarse calcifications (Fig. 16-36)
- Mesenchymal chondrosarcoma: frequent in second decade; one third extraosseous; rib and jaw bones being two common sites
- Twenty-five percent to 30% of patients with Ollier disease (enchondromatosis) and Maffucci syndrome (enchondromatosis and vascular lesions) develop chondrosarcoma

### Etiopathogenesis and Histopathologic Features

Conventional chondrosarcoma may show amplification of 12q13 and loss of 9p21; identical robertsonian translocation der(13;21)(q10;q10) has been identified in some cases of mesenchymal chondrosarcoma.

- *Conventional chondrosarcoma*: proliferation of atypical chondrocytes and cartilage that permeate medullary spaces; chondrocytic atypia takes the form of binucleation and multinucleation, nuclear pleomorphism and hyperchromatism, and more than one chondrocyte within a lacuna; dystrophic ossification is a common finding, but there is no deposition of malignant osteoid or woven bone (Fig. 16-37); chondroblasts are SOX9 and podoplanin (D2-40) positive; graded 1 (least atypia) to 3 (markedly pleomorphic cells often with necrosis and mitoses); grade 1 and combined grades 2 and 3 tumors have a recurrence rate of 89% and 53%, respectively; CD44 more highly expressed in higher grade tumors and associated with poorer prognosis
- Clear cell, dedifferentiated, and periosteal variants



- *Mesenchymal chondrosarcoma*: biphasic pattern of recognizable cartilage and proliferation of small, darkly staining round cells; chondrocytes within cartilage exhibit atypia; small round cells with distinct cytoplasmic outlines, scant cytoplasm (sometimes clear), and hyperchromatic round-to-ovoid nuclei arranged in nests with surrounding dilated vessels (hemangiopericytoma pattern) or solid sheets (Fig. 16-38), dystrophic calcifications are noted, but no malignant bone produced.
- Cells are CD99 positive, S-100 protein positive only in the chondroid areas, and SOX9 positive in both areas; EMA negative; type II collagen is a sensitive marker for this tumor.

### Differential Diagnosis

- Chondroblastic osteosarcoma (intramedullary and periosteal types) produces malignant woven bone and osteoid and not just dystrophic calcifications.
- Presence of cartilage (may need serial sections to locate) in mesenchymal chondrosarcoma rules out other small round cell tumors such as lymphoma, rhabdomyosarcoma, Ewing sarcoma, neuroblastoma, and malignant solitary fibrous tumor, as does presence of type II collagen
- Chordoid chordoma is cytokeratin and EMA positive and podoplanin (D2-40) negative.

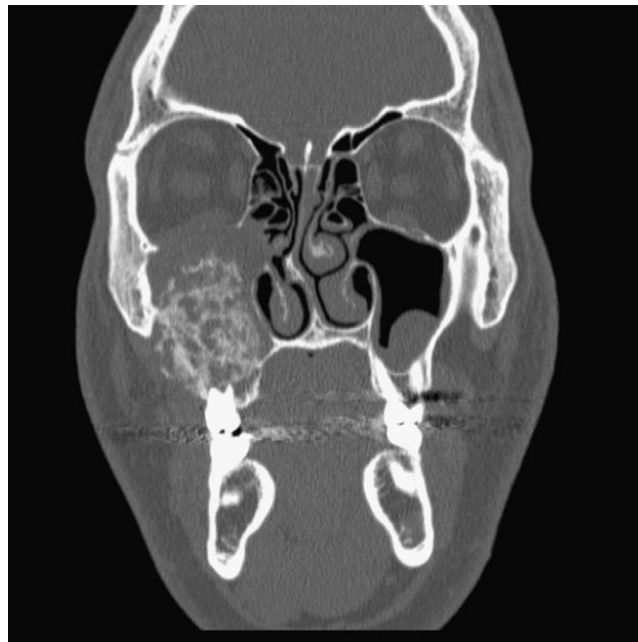
### Management and Prognosis

- Wide en bloc resection with or without adjuvant radiotherapy and chemotherapy is recommended treatment.

- Recurrence rate is 30% to 40%, with metastases often to lungs and death from disease.
- Five-year survival is approximately 85% for juxtacortical, 75% for conventional, 70% for myxoid, and 50% for mesenchymal subtypes.

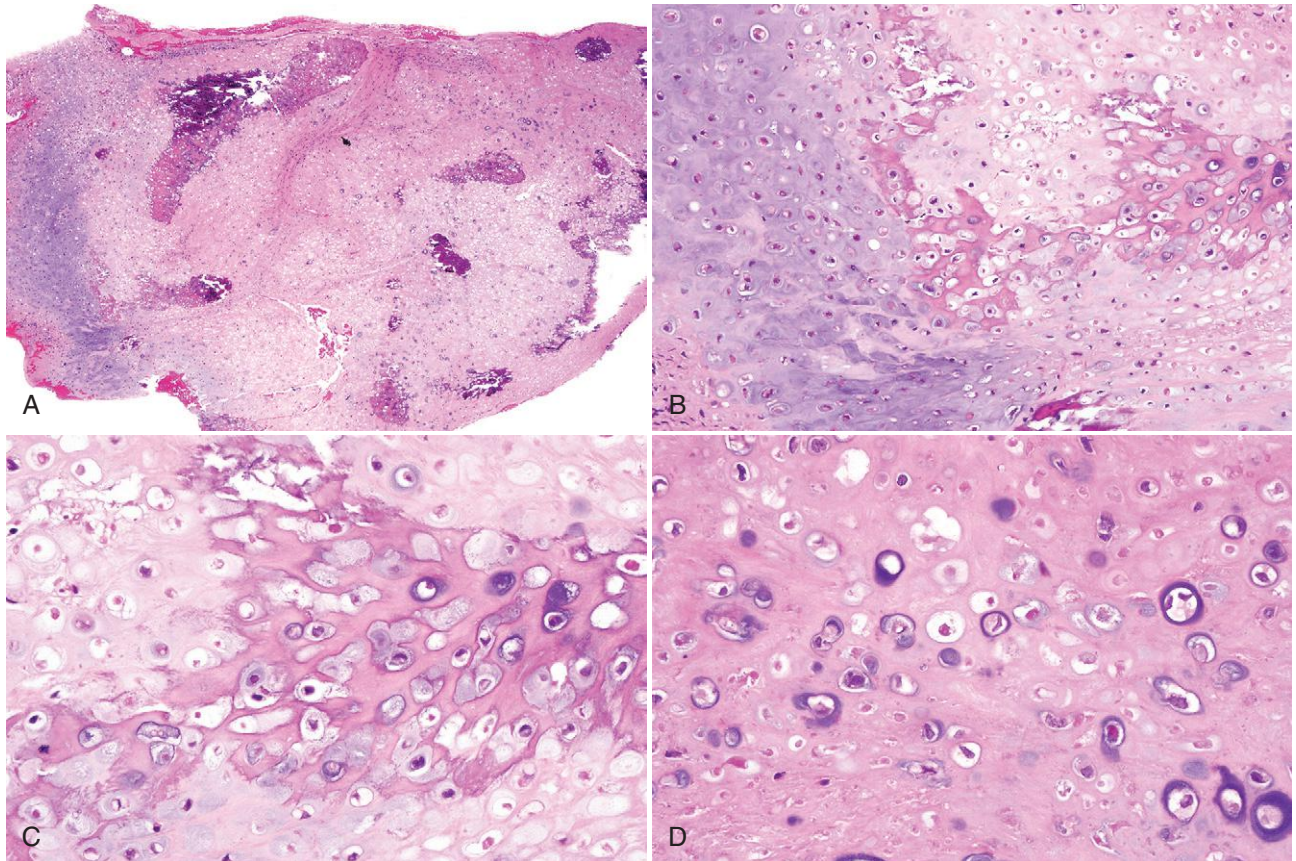
### REFERENCES

- Damron TA, Ward WG, Stewart A. Osteosarcoma, chondrosarcoma, and Ewing's sarcoma: National Cancer Data Base Report. *Clin Orthop Relat Res*. 2007;459:40-47.
- Fletcher C, Unni K, Mertens F, eds. *World Health Organization Pathology and Genetics: Tumours of Soft Tissue and Bone*. 3rd ed. Lyon, France: IARC Press; 2006.
- Heyse TJ, Malcherzyk D, Moll R, et al. CD44: survival and metastasis in chondrosarcoma. *Osteoarthritis Cartilage*. 2010;18:849-856.
- Kim MJ, Cho KJ, Ayala AG, Ro JY. Chondrosarcoma: with updates on molecular genetics. *Sarcoma*. 2011;2011:405-437.
- Knott PD, Gannon FH, Thompson LD. Mesenchymal chondrosarcoma of the sinonasal tract: a clinicopathological study of 13 cases with a review of the literature. *Laryngoscope*. 2003;113:783-790.
- Koch BB, Karnell LH, Hoffman HT, et al. National cancer database report on chondrosarcoma of the head and neck. *Head Neck*. 2000;22:408-425.
- Muller S, Soder S, Oliveira AM, et al. Type II collagen as specific marker for mesenchymal chondrosarcomas compared to other small cell sarcomas of the skeleton. *Mod Pathol*. 2005;18:1088-1094.
- Pellitteri PK, Ferlito A, Fagan JJ, et al. Mesenchymal chondrosarcoma of the head and neck. *Oral Oncol*. 2007;43:970-975.
- Staals EL, Bacchini P, Bertoni F. Dedifferentiated central chondrosarcoma. *Cancer*. 2006;106:2682-2691.



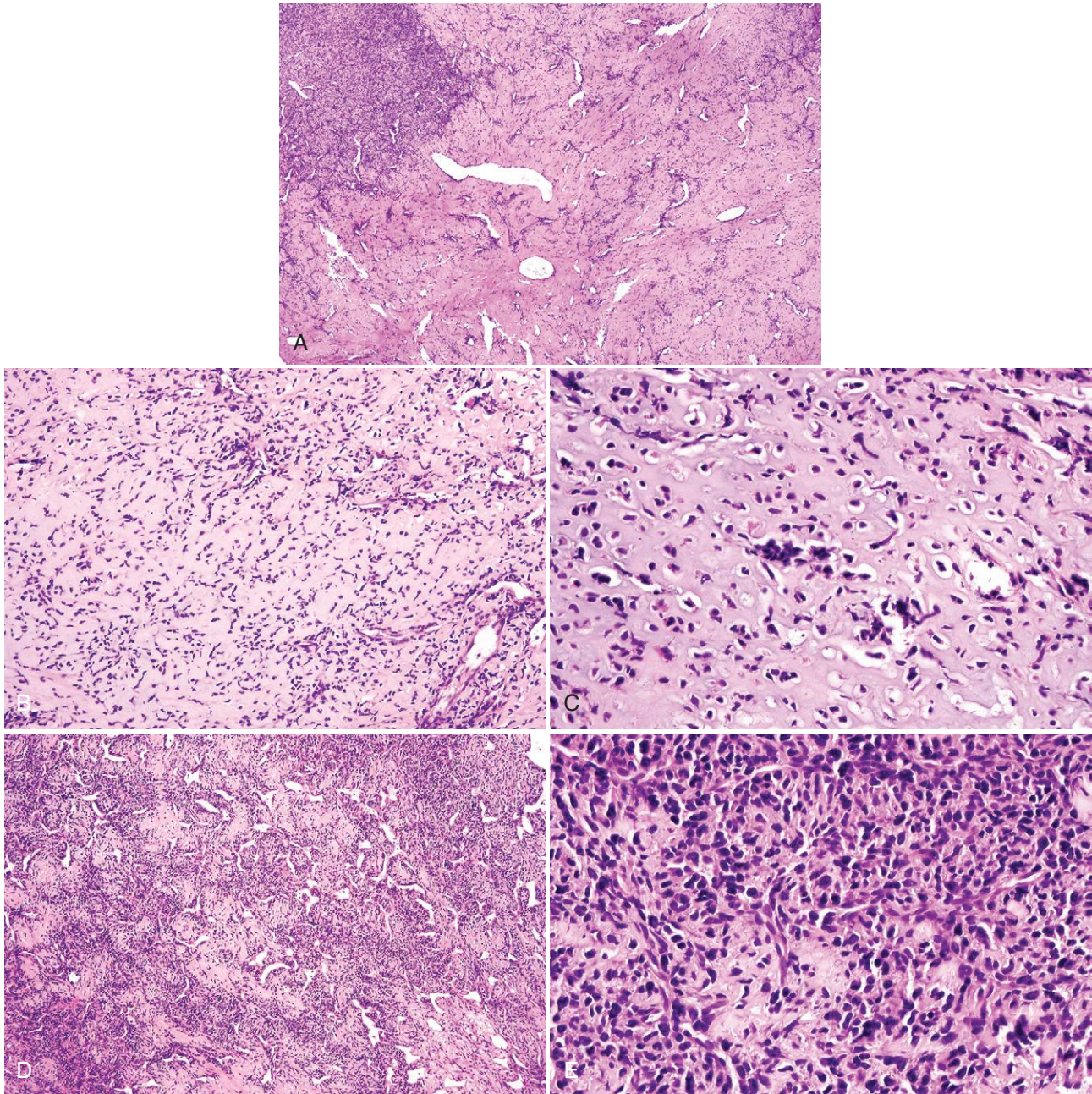
**FIGURE 16-36.** Mesenchymal chondrosarcoma. Coronal CT scan shows poorly defined, destructive mass with delicate calcifications of the right maxilla with involvement of the orbital floor. (From Pellitteri PK, Ferlito A, Fagan JJ, et al: *Mesenchymal chondrosarcoma of the head and neck*. *Oral Oncol*. 2007;43:970-975.)





**FIGURE 16-37.** Chondrosarcoma. **A**, Sheets of cartilage with ossification. **B**, Hyaline cartilage with dystrophic ossification. **C**, Dystrophic ossification within cartilage containing atypical chondrocytes. **D**, Atypical chondrocytes with binucleation and nuclear pleomorphism.





**FIGURE 16-38.** Mesenchymal chondrosarcoma. **A**, Foci of small hyperchromatic cells juxtaposed with chondroid matrix with spindle cells and dilated vessels (hemangiopericytoma pattern). **B**, Chondroid matrix with atypical cells. **C**, Atypical chondrocytes with hyperchromatic and pleomorphic nuclei in chondroid matrix. **D**, Hyperchromatic small cells clustered around dilated vessels. **E**, Atypical small round cells with hyperchromatic nuclei.



## PLASMA CELL MYELOMA (MULTIPLE MYELOMA)

Plasma cell myeloma is the most common intraosseous malignancy, and variants include solitary plasmacytoma, extramedullary plasmacytoma, nonsecretory myeloma, indolent myeloma, smoldering myeloma, monoclonal gammopathy of unknown significance, and plasma cell leukemia.

### Clinical Findings

- Occurs in sixth and seventh decades and is twice as common in females and is more common in blacks; the lesion seldom occurs in the jaw without other bones being involved; disease causes bone pain, hypercalcemia, fractures, and anemia from renal involvement.
- Lytic, punched-out lesions occur in the jawbones and calvaria (Fig. 16-39, A); extension into soft tissue forms fleshy masses (see Fig. 16-39, B and C); patients may present with waxy, yellowish, firm amyloid nodules, especially of the tongue (see Fig. 16-39, D).
- M-component in peripheral blood and urine is present in 99% of cases; 50% are IgG, 20% to 25% IgA; monoclonal light chain (Bence Jones protein) is found in serum or urine in 75% of cases.

### Etiopathogenesis and Histopathologic Features

Plasma cell myeloma is a malignant clonal proliferation of plasma cells. Disease occurring in POEMS (polyneuropathy, organomegaly, endocrinopathy, monoclonal gammopathy, and skin changes) syndrome are associated with human herpesvirus type 8.

- Sheets of plasma cells are present, with many dilated vessels; plasma cells, if well differentiated, these have abundant amphophilic cytoplasm, eccentric nuclei, clumped chromatin against the nuclear membrane (clock face appearance) and perinuclear zone of Hopf (Golgi apparatus) (Fig. 16-40); Russell bodies (eosinophilic bodies filled with immunoglobulin) may be noted, nuclear atypia may be significant, and there may be Dutcher bodies (PAS-positive nuclear pseudoinclusions).
- Cells are positive for CD38, CD138, and CD79a, with light chain restriction (see Fig. 16-40, C and D); they are usually CD20 and CD45 negative and may be positive for CD56.

### Differential Diagnosis

- Oral plasmablastic lymphoma (mostly in HIV-positive patients) usually manifests on the gingiva or palate (typical for other oral lymphomas) and sometimes in the jawbones; there is no immunoglobulin spike; tinged body macrophages lead to a starry-sky appearance; cells have moderate cytoplasm, large eccentric nuclei, prominent central or peripheral nucleoli, with similar profile to plasma cells being CD138, MUM1, and CD38, positive and CD20 negative (Fig. 16-41); mitotic activity is frequent, and tumors have a high KI-67 index; the majority of cases are Epstein-Barr virus (EBV)-encoded RNA positive;

oral plasmablastic lymphomas associated with HIV infection have a different immunoprofile from extracranial lesions that are not HIV associated.

- Non-Hodgkin lymphoma (>90% B cell) occurs in jaw bones in 30% to 50% of cases; usually large, diffuse B-cell type (60% to 70%) and are CD20 positive (Figs. 16-42 and 16-43); 60% show IgH gene rearrangement and 20% show Bcl-2 translocation; those that exhibit germinal center markers (CD10 and Bcl6) have a better prognosis.
- Ewing sarcoma consists of sheets of small, round cells, sometimes with clear cytoplasm (containing glycogen) and delicate, granular chromatin, that are CD99 positive; characterized by reciprocal translocation t(11:22)(q24;q12) involving the *EWS* gene on chromosome 22 and the *FLI-1* gene on chromosome 11; median age is in the second decade (Figs. 16-44 and 16-45).

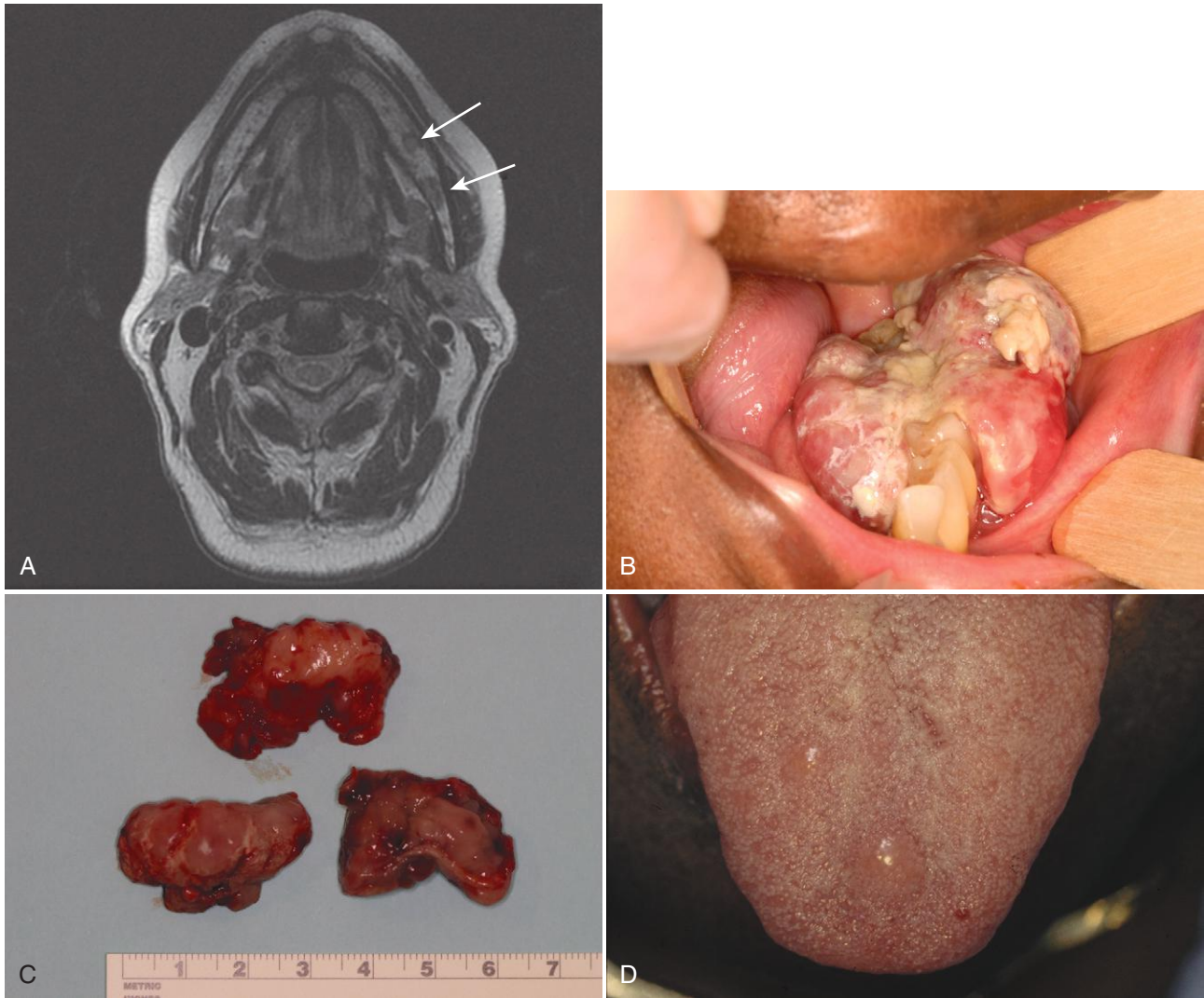
### Management and Prognosis

- Treatment for plasma cell myeloma is chemotherapy, bisphosphonates, thalidomide and related drugs, corticosteroids, bortezomib, radiation, and stem cell transplantation.
- Median survival is 3 years; 10% of patients have a 10-year survival.

### REFERENCES

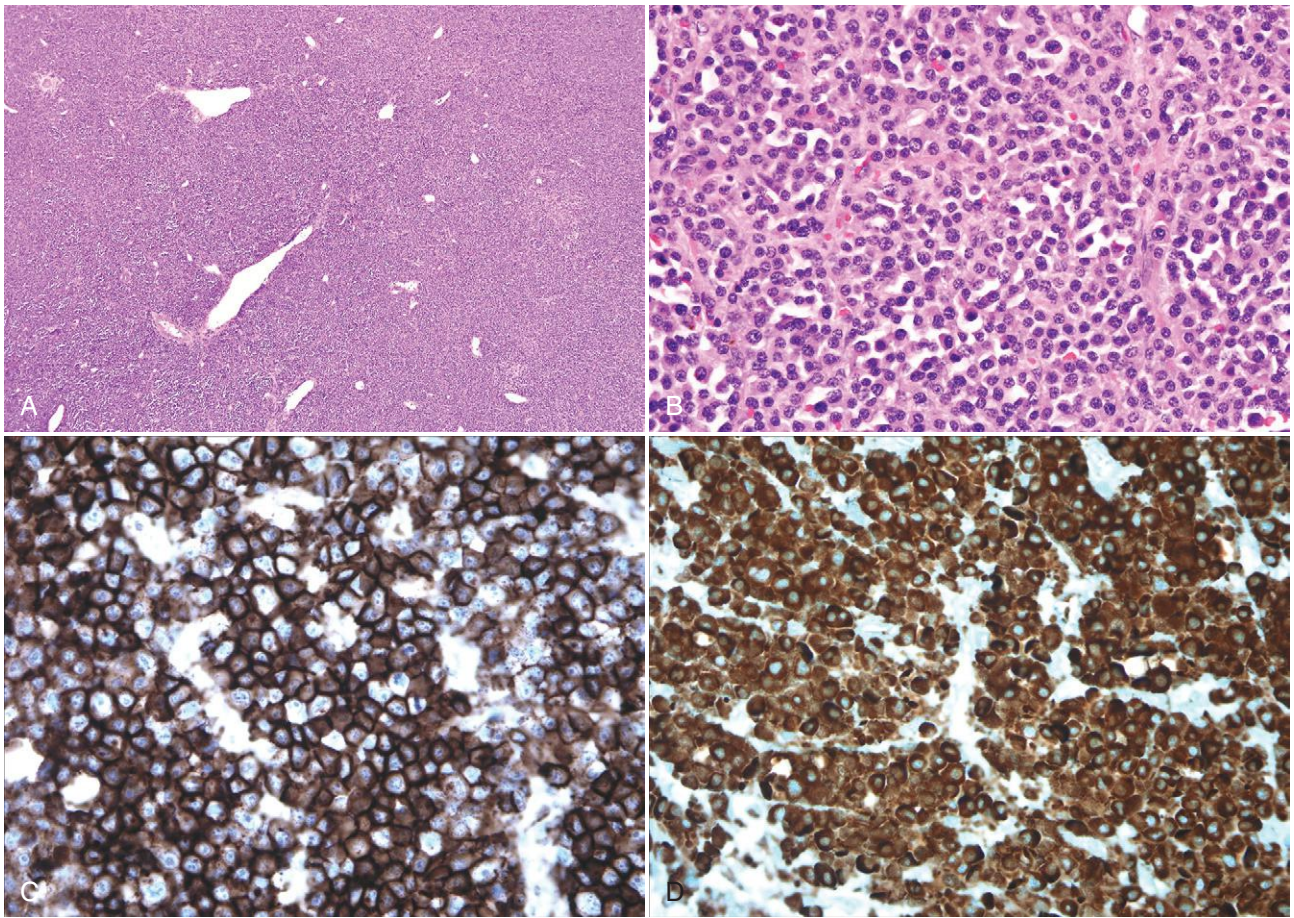
- Bhattacharyya I, Chehal HK, Cohen DM. Primary diffuse large B-cell lymphoma of the oral cavity: germinal center classification. *Head Neck Pathol.* 2010;4:181-191.
- Boy SC, van Heerden MB, Raubenheimer EJ, van Heerden WF. Plasmablastic lymphomas with light chain restriction—plasmablastic extramedullary plasmacytomas? *J Oral Pathol Med.* 2010;39:435-439.
- Castillo JJ, Winer ES, Stachurski D, et al. Clinical and pathological differences between human immunodeficiency virus-positive and human immunodeficiency virus-negative patients with plasmablastic lymphoma. *Leuk Lymphoma.* 2010;51:2047-2053.
- Fletcher C, Unni K, Mertens F, eds. *World Health Organization Pathology and Genetics: Tumours of Soft Tissue and Bone.* 3rd ed. Lyon, France: IARC Press; 2006.
- Folpe AL, Chand EM, Goldblum JR, Weiss SW. Expression of Fli-1, a nuclear transcription factor, distinguishes vascular neoplasms from potential mimics. *Am J Surg Pathol.* 2001;25:1061-1066.
- Kane S, Khurana A, Parulkar G, et al. Minimum diagnostic criteria for plasmablastic lymphoma of oral/sinonasal region encountered in a tertiary cancer hospital of a developing country. *J Oral Pathol Med.* 2009;38:138-144.
- Kemp S, Gallagher G, Kabani S, et al. Oral non-Hodgkin's lymphoma: review of the literature and World Health Organization classification with reference to 40 cases. *Oral Surg Oral Med Oral Pathol Oral Radiol Endod.* 2008;105:194-201.
- Rafaniello Raviele P, Pruneri G, Maiorano E. Plasmablastic lymphoma: a review. *Oral Dis.* 2009;15:38-45.
- Solomides CC, Miller AS, Christman RA, et al. Lymphomas of the oral cavity: histology, immunologic type, and incidence of Epstein-Barr virus infection. *Hum Pathol.* 2002;33:153-157.
- van der Waal RI, Huijgens PC, van der Valk P, van der Waal I. Characteristics of 40 primary extranodal non-Hodgkin lymphomas of the oral cavity in perspective of the new WHO classification and the International Prognostic Index. *Int J Oral Maxillofac Surg.* 2005;34:391-395.
- Vega F, Chang CC, Medeiros LJ, et al. Plasmablastic lymphomas and plasmablastic plasma cell myelomas have nearly identical immunophenotypic profiles. *Mod Pathol.* 2005;18:806-815.
- Whaley JT, Indelicato DJ, Morris CG, et al. Ewing tumors of the head and neck. *Am J Clin Oncol.* 2010;33:321-326.



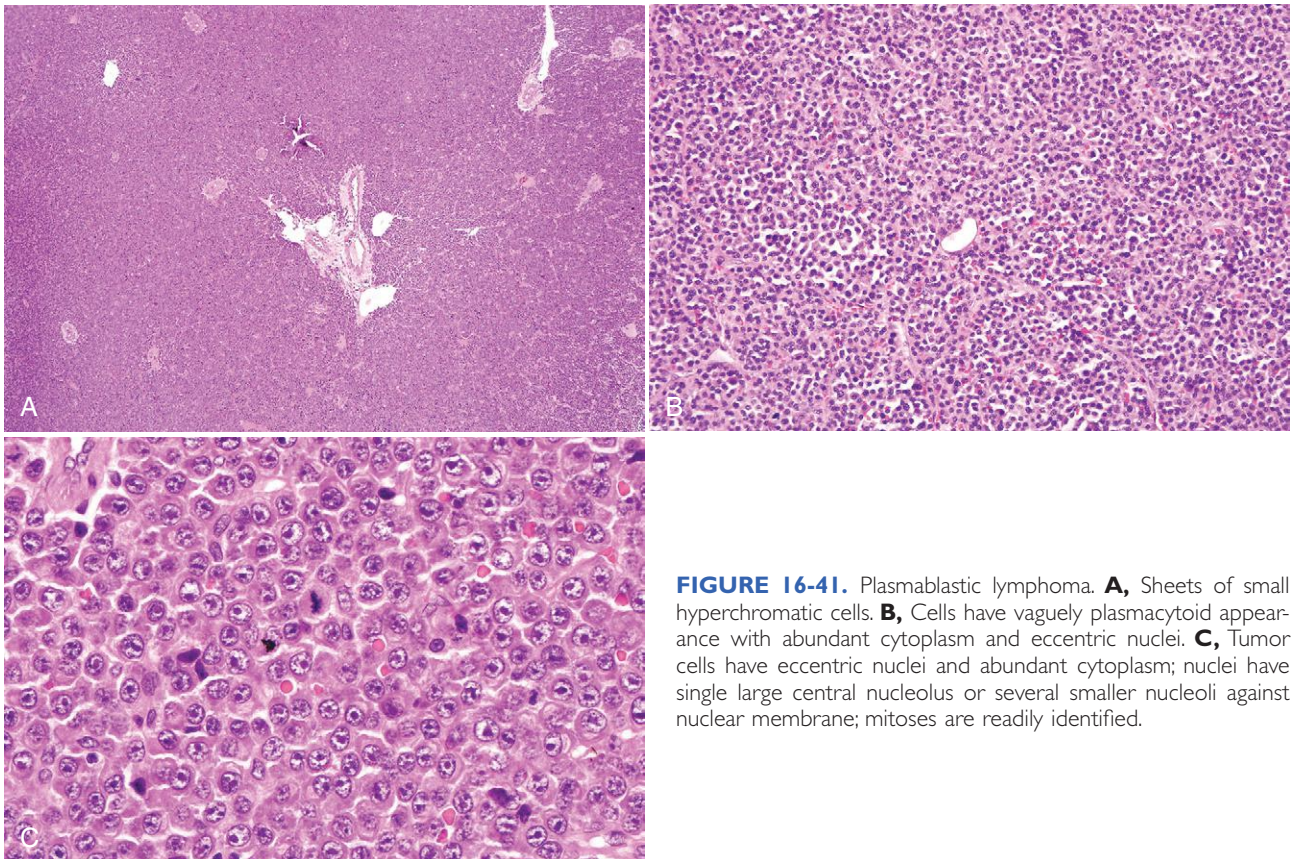


**FIGURE 16-39.** Plasma cell myeloma. **A**, Multiple punched-out lytic lesions of the mandible. **B**, Large rapidly enlarging soft tissue mass in a patient with plasma cell myeloma. **C**, Gross specimen with fleshy appearance from patient shown in part **B**. **D**, Multiple yellow, waxy amyloid nodules of the tongue.



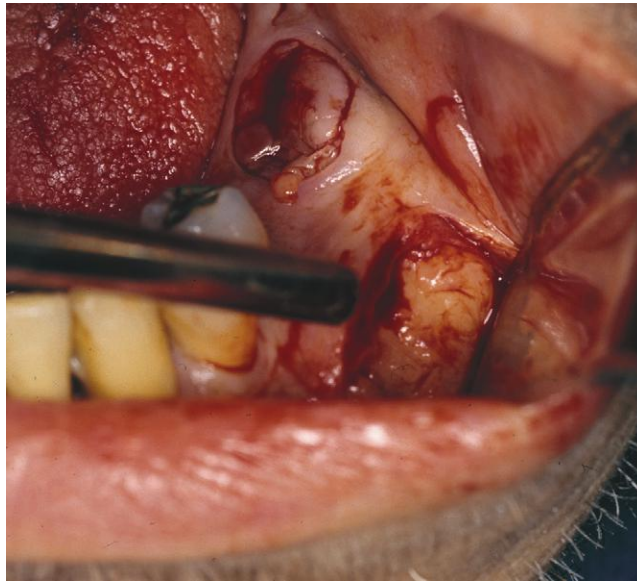


**FIGURE 16-40.** Plasma cell myeloma. **A**, Sheets of uniform small, round cells with dilated vessels. **B**, Atypical plasma cells with atypical eccentric nuclei. **C**, Cells are CD138 positive. **D**, Cells are uniformly positive for lambda light chain.

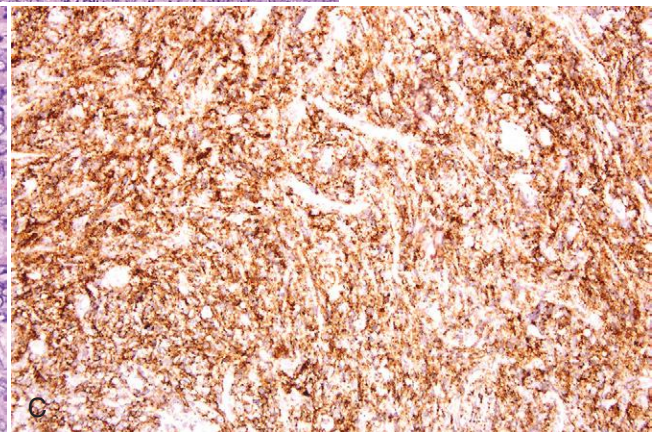
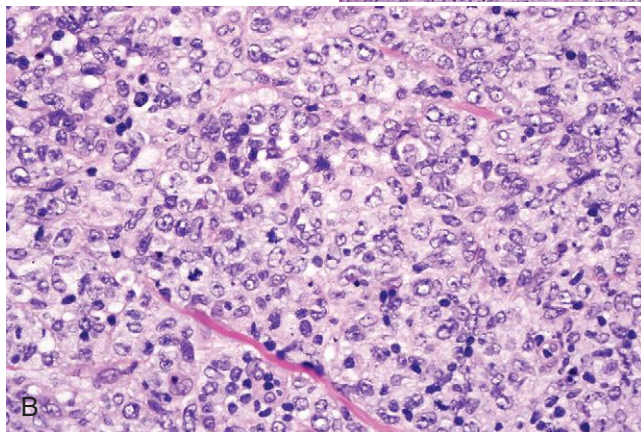
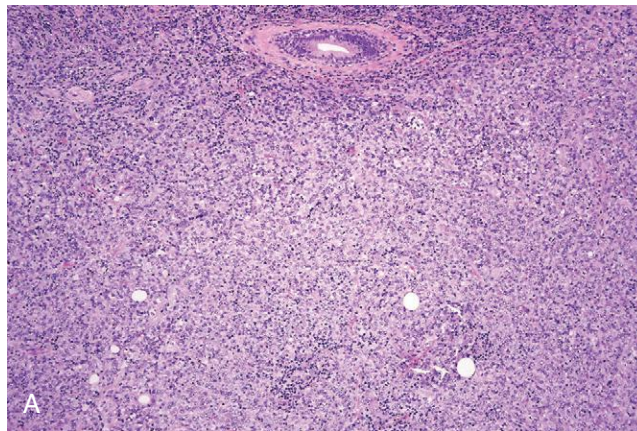


**FIGURE 16-41.** Plasmablastic lymphoma. **A**, Sheets of small hyperchromatic cells. **B**, Cells have vaguely plasmacytoid appearance with abundant cytoplasm and eccentric nuclei. **C**, Tumor cells have eccentric nuclei and abundant cytoplasm; nuclei have single large central nucleolus or several smaller nucleoli against nuclear membrane; mitoses are readily identified.



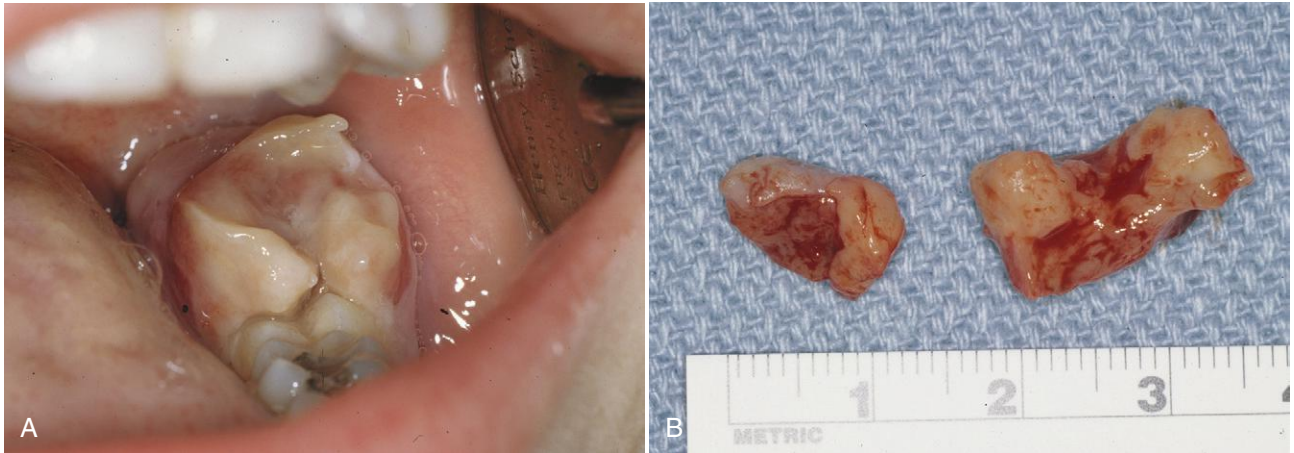


**FIGURE 16-42.** B-cell lymphoma: fleshy mass eroding through cortex of mandible.

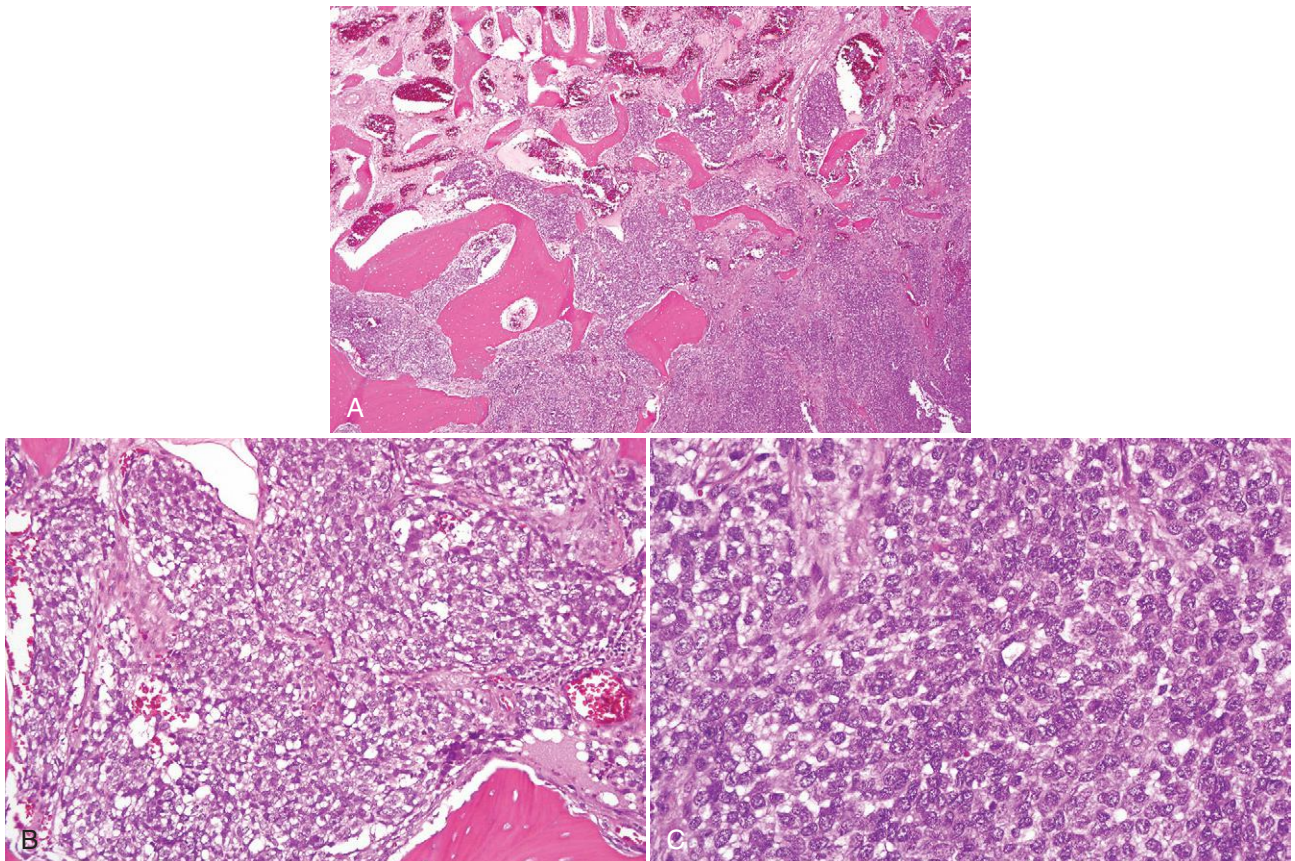


**FIGURE 16-43.** B-cell lymphoma. **A,** Sheets of pale cells. **B,** Cells have moderate amounts of pale cytoplasm and large, atypical nuclei. **C,** Cells are CD20 positive.





**FIGURE 16-44.** Ewing sarcoma. **A**, Fleshy ulcerated mass growing out of the mandibular alveolus. **B**, Tumor has a fleshy appearance (from patient shown in part A).



**FIGURE 16-45.** Ewing sarcoma. **A**, Sheets of small round cells infiltrating bone trabeculae, some of which are fragments of sequestra. **B**, Sheets of cells with pale to clear cytoplasm and inconspicuous nuclei. **C**, Cells with clear cytoplasm and finely granular chromatin.



## LANGERHANS CELL HISTIOCYTOSIS

This disease ranges from a single lesion that may regress to severe multisystem involvement that may be fatal. Approximately 60% to 70% of patients have restricted single-system disease (unifocal or multifocal, often with diabetes insipidus) and the rest have multisystem disease that may be low risk without organ dysfunction or high risk with organ dysfunction. Single-system and multisystem disease is most commonly seen in children, with single-system pulmonary disease affecting adults in the third and fourth decades. Primary involvement of bone, skin, and lymph nodes, occurring unifocally or multifocally, is often seen in restricted single-system disease.

### Clinical Findings

- Disease occurs in first and second decades; jaws are the third most commonly affected site after the skull and the femur; there is loosening of teeth locally; radiograph may show nondescript periapical radiolucency or floating teeth because of severe bone loss (Fig. 16-46); rarely, lesions are in soft tissue only.

### Etiopathogenesis and Histopathologic Features

This is a tumor of Langerhans cells, an antigen-presenting cell. Some lesions are clonal or caused by dysregulation of Langerhans cells, whereas those that occur in the lung in adults associated with smoking may be reactive.

- Sheets of epithelioid histiocyte-like cells are present with abundant, pale eosinophilic cytoplasm and grooved or reniform (“coffee bean”) nuclei; many eosinophils are present (Fig. 16-47, A-C); T cells, macrophages, and multinucleated giant cells are often seen.
- Cells are positive for CD1a, CD207 (langerin), and S-100 protein; Birbeck granules (tennis racket-shaped

bodies) are a typical ultrastructural finding, and they form after ligand-binding to langerin (see Fig. 16-47, D and E).

### Differential Diagnosis

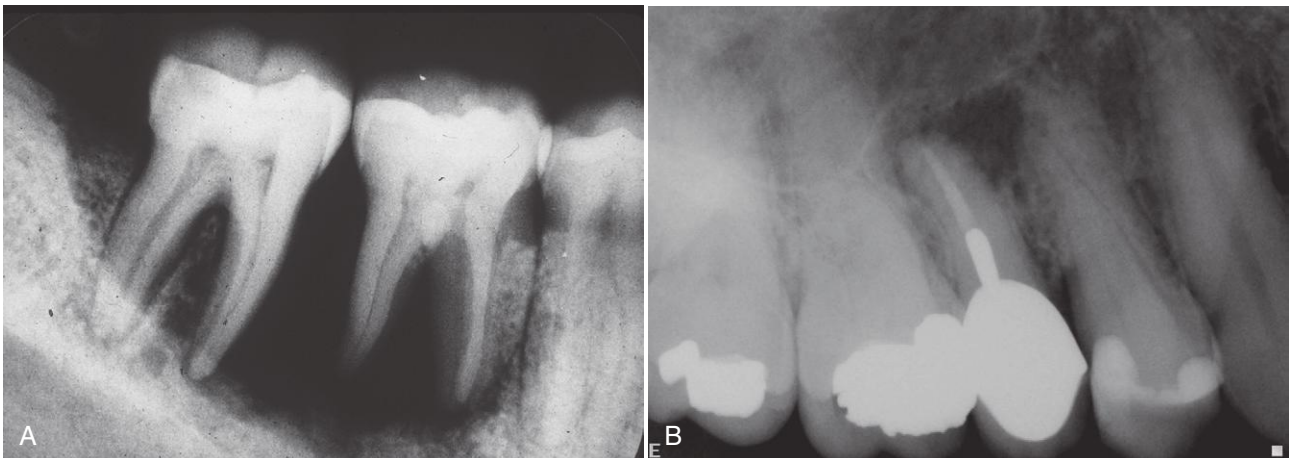
- Traumatic ulcerative granuloma (eosinophilic granuloma of tongue) does not significantly stain for Langerhans cells.
- Nonspecific macrophage-dense infiltrates in periapical lesions do not usually contain eosinophils and do not stain for Langerhans cells.

### Management and Prognosis

- Curettage is often curative; other treatments include indomethacin (bone lesions often PGE2 positive), bisphosphonates and chemotherapy (prednisone and vinblastine); reactivation occurs in 25% of patients with multifocal bone disease and is correlated with the presence of diabetes insipidus.

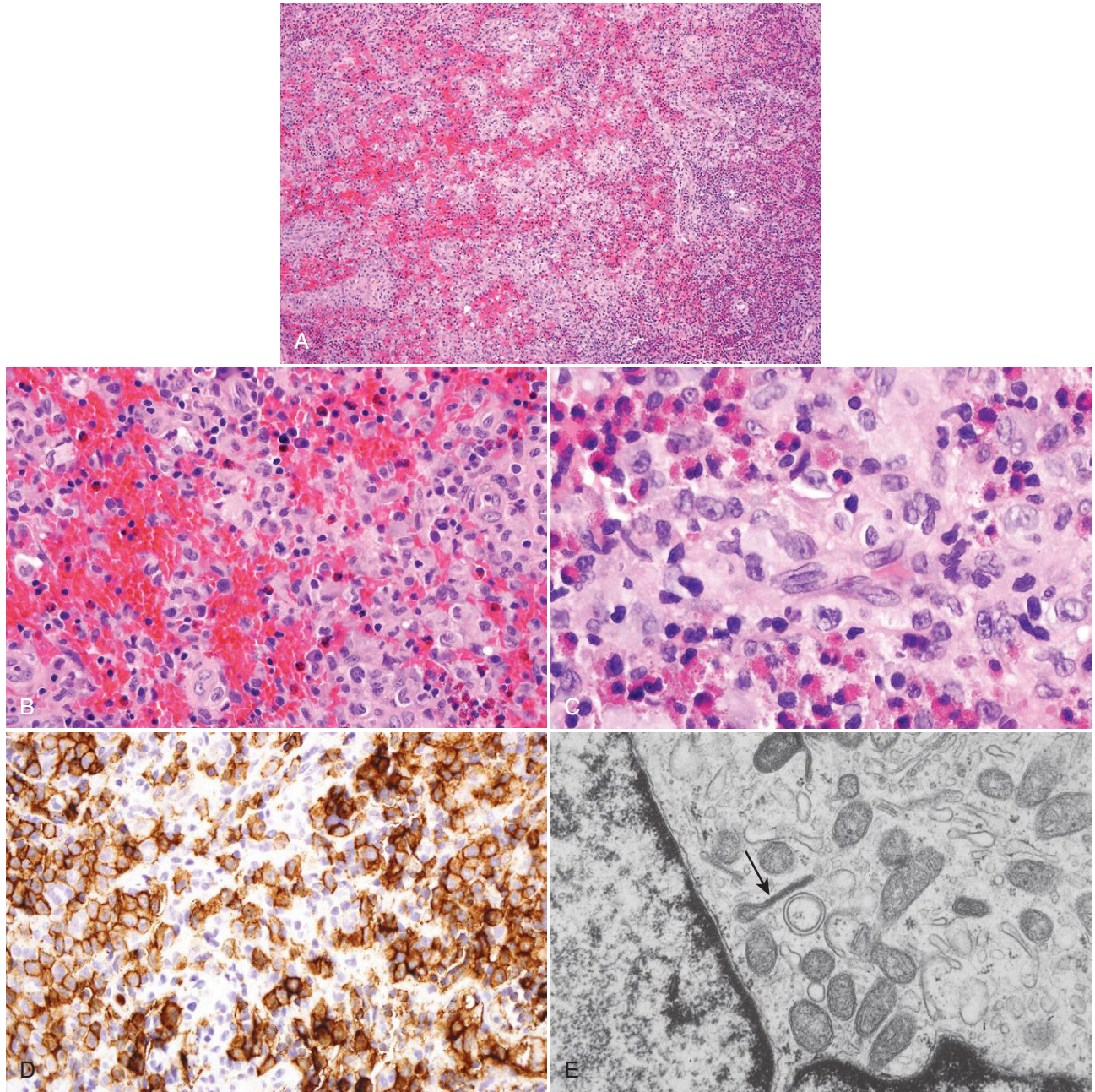
### REFERENCES

- Abla O, Egeler RM, Weitzman S. Langerhans cell histiocytosis: current concepts and treatments. *Cancer Treat Rev.* 2010;36:354-359.
- Eckardt A, Schultze A. Maxillofacial manifestations of Langerhans cell histiocytosis: a clinical and therapeutic analysis of 10 patients. *Oral Oncol.* 2003;39:687-694.
- Egeler RM, van Halteren AG, Hogendoorn PC, et al. Langerhans cell histiocytosis: fascinating dynamics of the dendritic cell-macrophage lineage. *Immunol Rev.* 2010;234:213-232.
- Favara BE, Feller AC, Pauli M, et al. Contemporary classification of histiocytic disorders. The WHO Committee On Histiocytic/Reticulum Cell Proliferations. Reclassification Working Group of the Histiocyte Society. *Med Pediatr Oncol.* 1997;29:157-166.
- Hartman KS. Histiocytosis X: a review of 114 cases with oral involvement. *Oral Surg Oral Med Oral Pathol.* 1980;49:38-54.
- Kilpatrick SE, Wenger DE, Gilchrist GS, et al. Langerhans' cell histiocytosis (histiocytosis X) of bone. A clinicopathologic analysis of 263 pediatric and adult cases. *Cancer.* 1995;76:2471-2484.



**FIGURE 16-46.** Langerhans cell histiocytosis. **A**, Focal severe bone loss and radiolucency giving the impression of floating teeth. **B**, Nondescript periapical radiolucency. (Courtesy of Dr. Carlene Tsai, private practice, Salem, Mass.)





**FIGURE 16-47.** Langerhans cell histiocytosis. **A**, Sheets of pale epithelioid cells. **B**, Langerhans cells have abundant pale cytoplasm and irregular nuclear outlines; a mitotic figure is present. **C**, Cells have reniform or grooved "coffee bean" nuclei. **D**, Cells are positive for CD1a. **E**, Birbeck granule noted (arrow).

## OSTEONECROSIS AND OSTEOMYELITIS

Osteonecrosis of the jaw has a number of etiologies, with medication-induced osteonecrosis of the jaws being a recently recognized and fairly common cause of devitalization of bone (Table 16-2). Osteonecrosis may, but not invariably, result in osteomyelitis.

Unlike in other bones, infection and inflammation of the jaw bones (osteitis) is a common occurrence,

because teeth frequently become infected, either from caries or periodontal disease, with spread of such infection into the bone. Periapical lesions, such as periapical granuloma and apical radicular cysts when large, result in intramedullary inflammation, usually without sequestrum formation. Even large periapical abscesses heal after curettage, often without the necessity for prolonged antibiotic coverage.

Acute (painful) and chronic (usually painless) suppurative osteomyelitis of the jaws are usually the



TABLE 16-2 Etiologies for Osteonecrosis of the Jaws

Etiology	Clinical Findings	Management and Prognosis
Medication-induced: bisphosphonates and denosumab (antiosteoclastic), bevacizumab (antivascular endothelial growth factor); occurs in 1–3% of cancer patients on bisphosphonates and 1 in 2000–5000 patients on bisphosphonates for nononcologic indications.	Staging (for bisphosphonates group): Osa or Oss: no bone exposure, may have sinus tracts, periodontal pocketing, and/or radiographic findings; may or may not be painful Stage 1: bone exposure, no symptoms Stage 2: bone exposure, symptomatic Stage 3: extensive necrosis and/or pathologic fracture Maxilla:mandible = 1:2; often at sites of extraction, odontogenic infection, or tori	Stages Osa and 1: chlorhexidine rinse and follow-up; nonsurgical sequestrectomy (dislodgement of bone) Stages Oss, 2 and 3: chlorhexidine rinse, antibiotic therapy (amoxicillin, clindamycin, or metronidazole), nonsurgical or surgical sequestrectomy/excision; pain control Prognosis: Metachronous or recurrent lesions often noted
Radiation injury (damage to osteoclast precursors and sclerosis of vessels; hypovascularity); up to 5% frequency after irradiation with > 6000 cGys.	Exposed bone Maxilla:mandible = 1:9 (mandible has less collateral circulation compared with maxilla)	Surgical excision, antibiotics, chlorhexidine rinse, hyperbaric oxygen, pain control Prognosis: often difficult to control with recurrence common
<b>Mechanical trauma</b>		
Intubation-associated or spontaneous benign sequestration of lingual plate	Both on mylohyoid ridge	Nonsurgical sequestrectomy or allow bone to exfoliate; chlorhexidine rinse; topical analgesia Prognosis: does not recur
<b>Chemical trauma</b>		
Cocaine Caustic dental materials (e.g., root canal)	Cocaine necrosis often seen on palate Site where dental materials placed	Cocaine necrosis: plastic surgery Dental materials: topical steroid therapy and gentle salt water rinses Prognosis: recurrence if cocaine habit maintained
<b>Infection</b>		
Nonspecific/odontogenic	Nonspecific: site of odontogenic infection	Nonspecific: antibiotics, curettage, débridement, surgery, pain control
Varicella zoster	Varicella: exposed bone, unilateral, with preceding gingival/palatal ulceration	Varicella: may need to excise if does not exfoliate; antibiotics, chlorhexidine rinse, pain control Prognosis: no recurrence
Noma, necrotizing ulcerative stomatitis/ NUS	Noma/NUS: around teeth and soft tissues; immunocompromised or HIV-related	Noma/NUS: improve nutrition and boost immune system, antibiotics, plastic surgery to correct soft tissue defects Prognosis: may recur if underlying medical issues not adequately addressed
Sclerotic bone disease such as mature cemento-osseous dysplasia (especially multifocal type), Paget disease, and osteopetrosis (hypovascular bone) in presence of odontogenic infection	Where bone disease and odontogenic infection coincide with/without history of extraction and oral surgery	Antibiotics, curettage, débridement, surgery, pain control Prognosis: may recur

result of odontogenic infections and are associated with sequestrum formation. Diffuse sclerosing osteomyelitis with an obvious source of infection and primary chronic osteomyelitis (seen as part of SAPHO [synovitis, acne, pustulosis, hyperostosis, osteomyelitis] syndrome) are either asymptomatic or cause a dull ache in the mandible and are not usually associated with an obvious infection.

### Clinical Findings

- Please see Table 16-2.
- *Osteonecrosis*: presence of bony sequestrum, usually exposed, with or without pain (Fig. 16-48, A and B); radiographs reveal mottled radiolucency/radiopacity and often sequestrum; in the case of bisphosphonate-related osteonecrosis, chronic sinus tracts and nonhealing extraction sockets are common

manifestations, and radiographs reveal thickened lamina dura and osteosclerosis (see Fig. 16-48, C-F).

- Benign sequestration of lingual plate consists of small, 1- to 4-mm sequestra only (see Fig. 16-48, G).
- *Osteomyelitis*: radiologic findings are similar to osteonecrosis but less often with exposed bone, although sinus tracts and pain are almost always present; usually occurs after extractions, and is almost always associated with a history of dental infection or, less commonly, a poorly healed fracture.

### Etiopathogenesis and Histopathologic Features

Etiologies of osteonecrosis include suppression of bone turnover, vascular compromise, and trauma (see Table 16-2).

- *Bisphosphonate-related osteonecrosis and osteoradionecrosis*: nonviable bony sequestra with empty lacunae and



ragged borders, usually with extensive bacterial colonization especially with *Actinomyces* species as a biofilm (Fig. 16-49); a diagnosis of actinomycosis (actinomycotic osteomyelitis) should be made only if sulfur granules are present, surrounded by suppuration; *Eikenella corrodens* is often present; osteoclasts are often noted in spite of antiosteoclastic activity of bisphosphonates; osteomyelitis may develop with acute and chronic inflammation and granulation tissue (Fig. 16-50).

- *Acute suppurative osteomyelitis*: nonviable bony sequestra and granulation tissue with acute and chronic inflammation.
- *Chronic osteomyelitis*: anastomosing trabeculae of viable bone that may be sclerotic with many resting and reversal lines, stromal fibrosis, and chronic inflammation; a preexisting sclerotic cemental mass may be present.

### Differential Diagnosis

- A search should be made for primary bone malignancy (such as myeloma) or metastatic disease for those with bisphosphonate-related osteonecrosis; recurrent squamous cell carcinoma is a consideration for those with radiation-induced osteonecrosis.

### Management and Prognosis

- Osteonecrosis: see Table 16-2; nonviable bone is often readily removed by nonsurgical sequestrectomy or

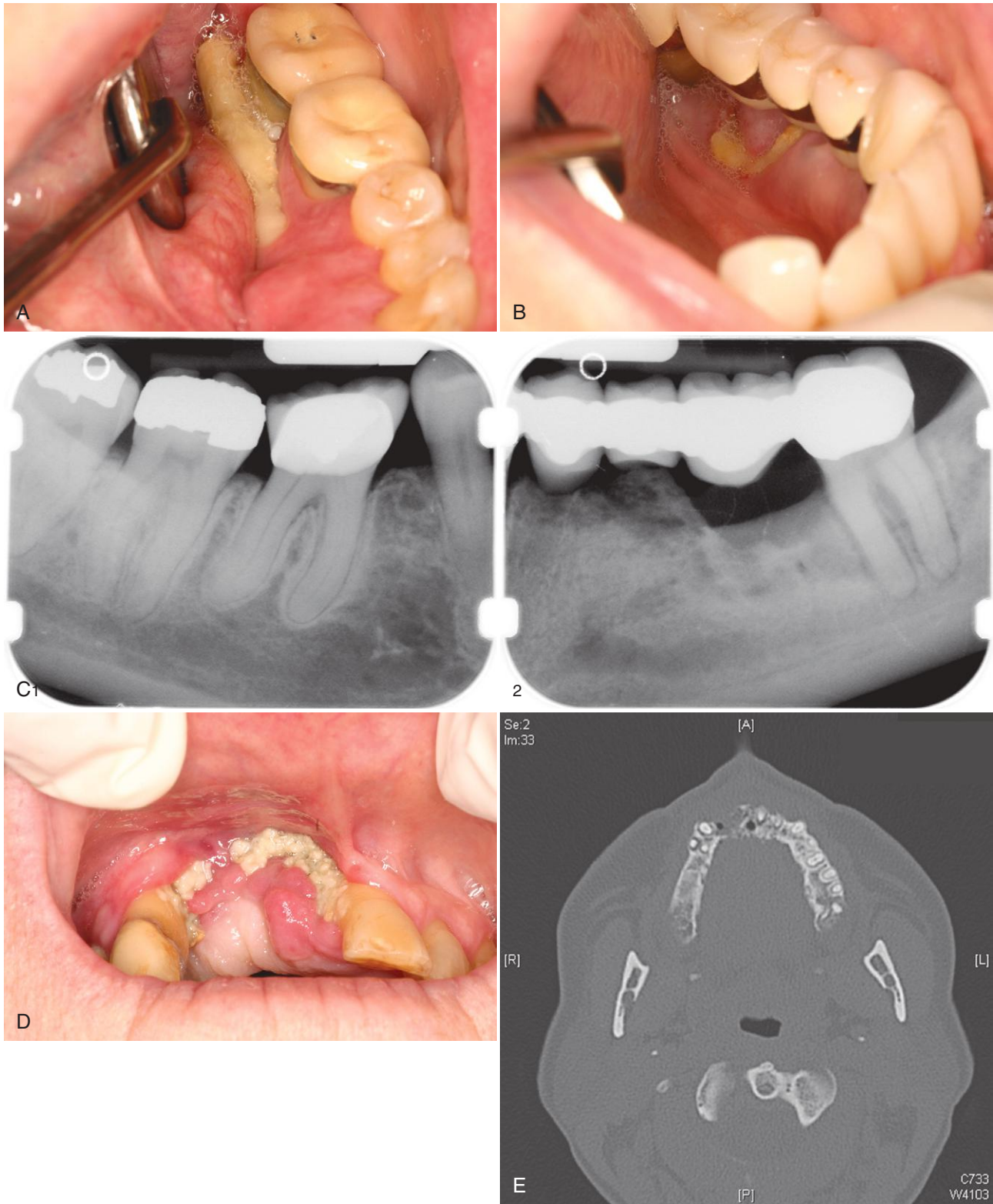
dislodgement (Fig. 16-51); this yields a specimen similar to that in Figure 16-49 with little soft tissue.

- Osteomyelitis: sequestrectomy, long-term antibiotics, and possibly hyperbaric oxygen are recommended treatments.

### REFERENCES

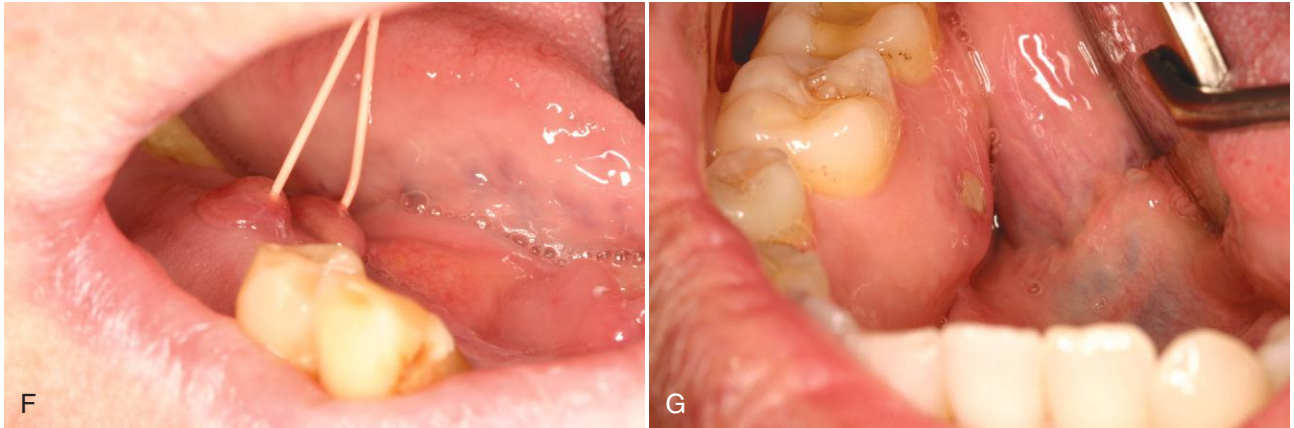
- Almazrooa SA, Woo SB. Bisphosphonate and nonbisphosphonate-associated osteonecrosis of the jaw: a review. *J Am Dent Assoc.* 2009;140:864-875.
- Eversole R, Su L, ElMofty S. Benign fibro-osseous lesions of the craniofacial complex. A review. *Head Neck Pathol.* 2008;2:177-202.
- Hansen T, Kunkel M, Weber A, Kirkpatrick CJ. Osteonecrosis of the jaws in patients treated with bisphosphonates—histomorphologic analysis in comparison with infected osteoradionecrosis. *J Oral Pathol Med.* 2006;35:155-160.
- Hansen T, Kirkpatrick CJ, Walter C, Kunkel M. Increased numbers of osteoclasts expressing cysteine proteinase cathepsin K in patients with infected osteoradionecrosis and bisphosphonate-associated osteonecrosis—a paradoxical observation? *Virchows Arch.* 2006;449:448-454.
- Kumar SK, Gorur A, Schaudinn C, et al. The role of microbial biofilms in osteonecrosis of the jaw associated with bisphosphonate therapy. *Curr Osteoporos Rep.* 2010;8:40-48.
- Migliorati CA, Woo SB, Hewson I, et al. A systematic review of bisphosphonate osteonecrosis (BON) in cancer. *Support Care Cancer.* 2010;18:1099-2106.
- Neville BW, Damm DD, Allen CM, Bouquot J. *Oral and Maxillofacial Pathology.* 5th ed. Philadelphia, Saunders; 2009.
- Ruggiero SL, Dodson TB, Assael LA, et al. American Association of Oral and Maxillofacial Surgeons position paper on bisphosphonate-related osteonecrosis of the jaws—2009 update. *J Oral Maxillofac Surg.* 2009;67:2-12.
- Woo SB, Hande K, Richardson PG. Osteonecrosis of the jaw and bisphosphonates. *N Engl J Med.* 2005;353:99-102.



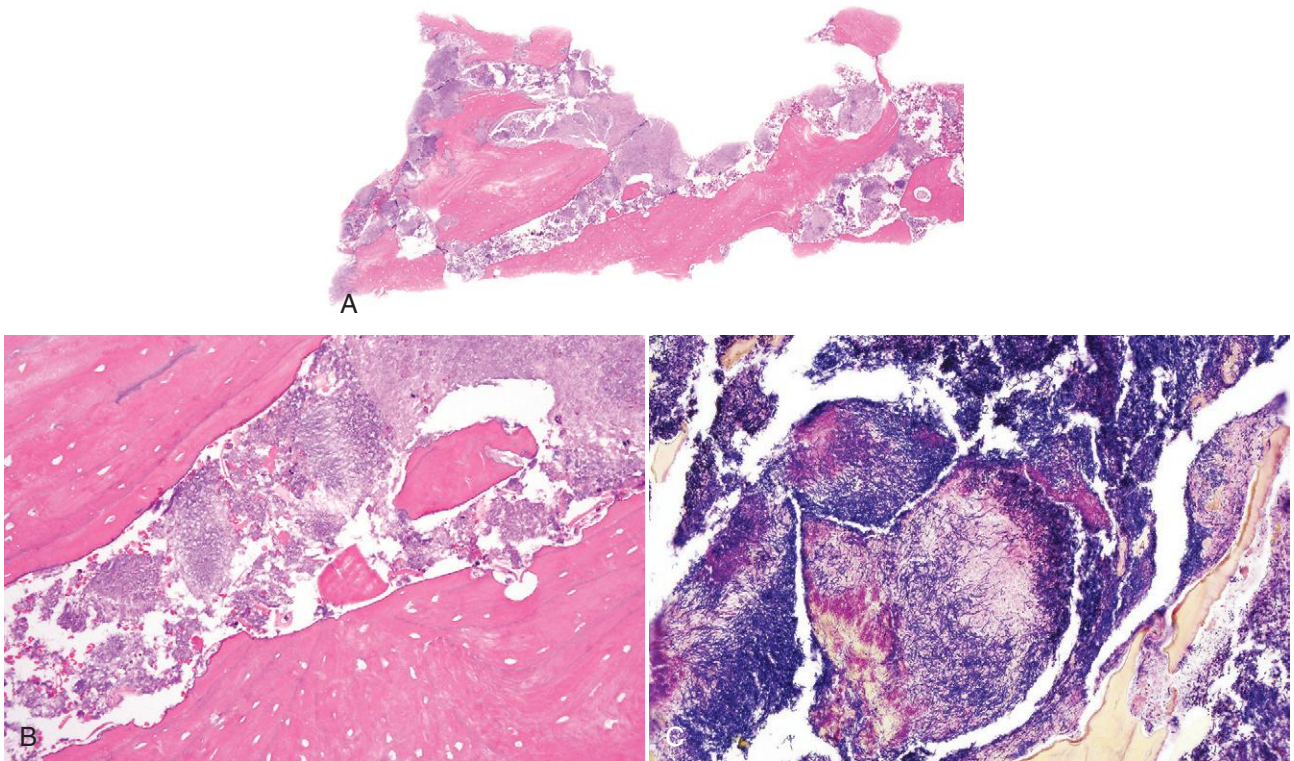


**FIGURE 16-48.** Bisphosphonate-related osteonecrosis. **A**, Typical exposed sequestrum located on the mylohyoid ridge. **B**, Sequestrum located beneath a subpontic exostosis. **C**, Radiograph showing necrotic subpontic exostosis (*right panel*) and teeth with thickened lamina dura on the opposite side (*left panel*). **D**, Necrotic bone on the anterior maxillary ridge. **E**, CT scan of patient from part **D** showing mottled lucency of anterior ridge extending to the palate.



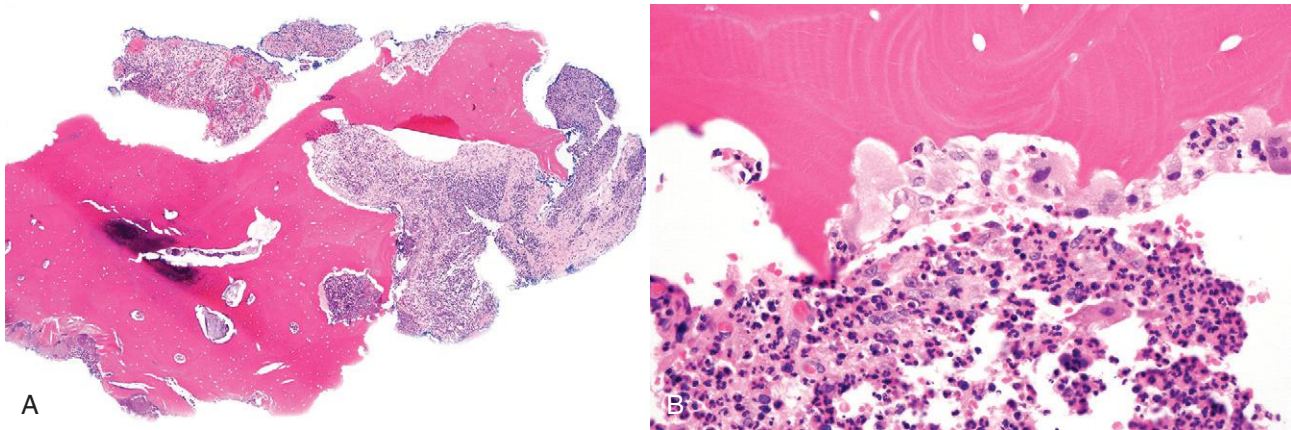


**FIGURE 16-48, cont'd.** **F**, Sinus tracts are common findings, and they may be the only finding in early lesions; in this case, sequestrum is noted posteriorly. **G**, Benign sequestration of the lingual plate (3 mm of necrotic bone, readily removed).

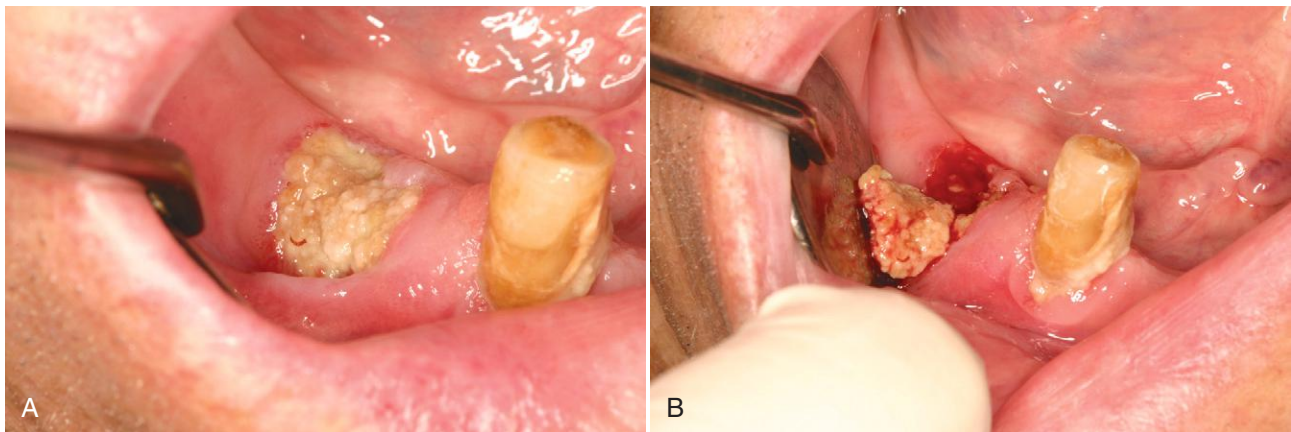


**FIGURE 16-49.** Bisphosphonate-related osteonecrosis. **A**, Nonviable bony sequestrum with ragged margins surrounded by bacterial biofilm. **B**, Dense colonies of filamentous bacteria. **C**, Brown and Brenn stain reveals filamentous bacteria consistent with colonization by *Actinomycetes* but does not constitute actinomycosis because there are no sulfur granules and there is no suppuration.





**FIGURE 16-50.** Bisphosphonate-related osteonecrosis and osteomyelitis. **A**, Nonviable bony sequestrum surrounded by granulation tissue with abscesses. **B**, Nonviable bone rimmed by osteoclasts are noted within Howship lacunae; abscesses are present.



**FIGURE 16-51.** Bisphosphonate-related osteonecrosis. **A**, Nonviable sequestrum on mandibular ridge. **B**, Bone fragment is readily dislodged leaving behind a bed of hemorrhagic granulation tissue.

## MYOSPHERULOSIS (SPHERULOCYTOSIS, SPHERULOCYSTIC DISEASE OF SKIN)

### Clinical Findings

- Radiolucency is visible at the site of a previous tooth extraction, and there is a history of the site being packed or treated for dry socket; lesion may be present for years; the tissue specimen appears tarry, oily, and black.
- Lesion is common in sinuses that have been packed and after chronic intralesional injections of the skin.

### Etiopathogenesis and Histopathologic Features

Myospherulosis is caused by petrolatum—or lanolin-based packing products (usually used in conjunction with antibiotics)—that undergoes an emulsification process with red blood cells.

- Altered erythrocytes appear as yellowish-brown spherical or crescent-shaped bodies within clear cystlike spaces (leached out lipid material); there is surrounding fibrosis and foreign body reaction (Fig. 16-52, A);

some have “parent bodies” within which are endobodies (see Fig. 16-52, B).

### Differential Diagnosis

- Fungal organisms stain with methenamine silver or PAS.

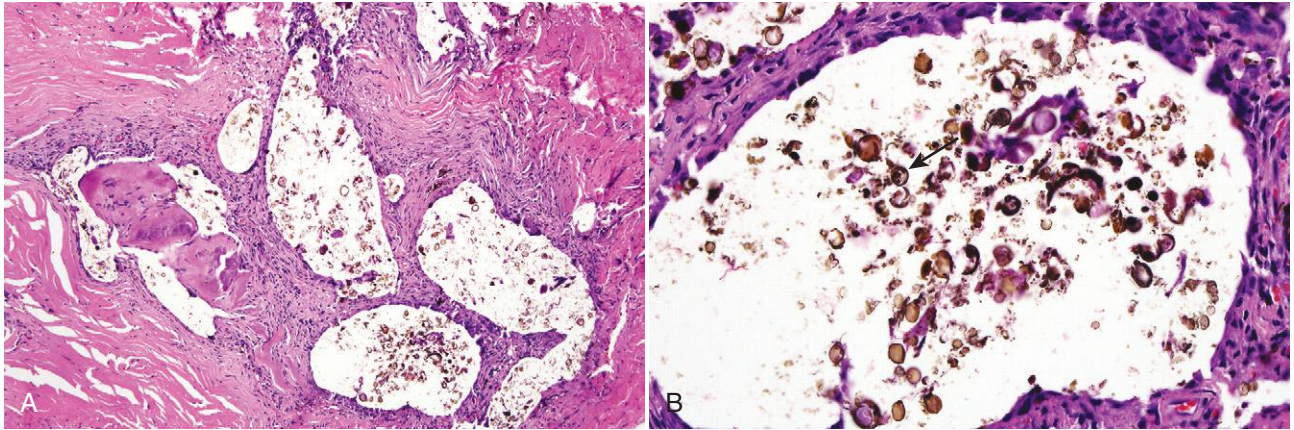
### Management and Prognosis

- Curettage is curative.

### REFERENCES

- Culviner WT, Leonard DW, Wilhelmsen CL, Bolger WE. Experimental myospherulosis of the paranasal sinuses: a histologic rabbit study. *Am J Rhinol.* 2000;14:131-137.
- Dunlap CL, Barker BF. Myospherulosis of the jaws. *Oral Surg Oral Med Oral Pathol.* 1980;50:238-243.
- Flagothier C, Pierard GE, Quatresooz P. Cutaneous myospherulosis and membranous lipodystrophy: extensive presentation in a patient with severe steroid-induced dermal atrophy. *J Eur Acad Dermatol Venerol.* 2006;20:457-460.
- Kakizaki H, Shimada K. Experimental study of the cause of myospherulosis. *Am J Clin Pathol.* 1993;99:249-256.
- Lynch DP, Newland JR, McClendon JL. Myospherulosis of the oral hard and soft tissues. *J Oral Maxillofac Surg.* 1984;42:349-355.
- Sindwani R, Cohen JT, Pilch BZ, Metson RB. Myospherulosis following sinus surgery: pathological curiosity or important clinical entity? *Laryngoscope.* 2003;113:1123-1127.





**FIGURE 16-52.** Myospherulosis. **A**, Clear spaces containing yellow-brown particulate material surrounded by histiocytic and giant cell reaction with fibrous and hyalinized stroma. **B**, Spherical and crescent-shaped bodies and smaller fragments of similarly pigmented debris; parent body with smaller endobodies inside (arrow).

## HEMATOPOIETIC BONE MARROW DEFECT (OSTEOPOROTIC BONE MARROW DEFECT)

### Clinical Findings

- Radiolucency in the posterior mandible, usually 0.5 to 1.0 cm, asymptomatic, often in the area of previously extracted mandibular third molar, discovered on routine radiography (Fig. 16-53).

### Etiopathogenesis and Histopathologic Features

Hematopoietic marrow may represent reactive hyperplasia because of increased demand, aberrant bone regeneration, or residual fetal marrow.

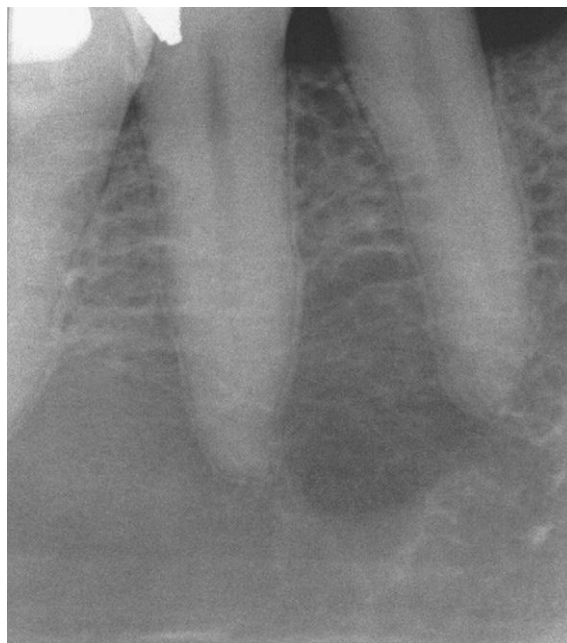
- Normal hematopoietic marrow is present with all three lineages—megakaryocytes, erythrocyte precursors, and myelocytes—in various stages of maturation; fatty marrow may be present (Fig. 16-54).

### Management and Prognosis

- No treatment is required.

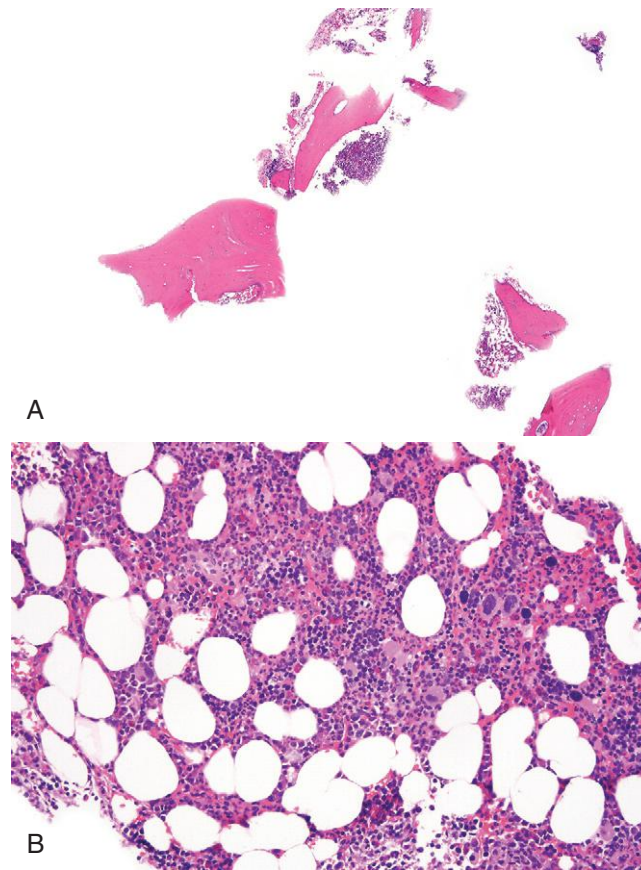
### REFERENCES

- Lipani CS, Natiella JR, Greene GW Jr. The hematopoietic defect of the jaws: a report of sixteen cases. *J Oral Pathol.* 1982;11:411-416.
- Neville BW, Damm DD, Allen CM, Bouquot J. *Oral and Maxillofacial Pathology.* 5th ed. Philadelphia, Saunders; 2009.



**FIGURE 16-53.** Hematopoietic bone marrow defect: poorly circumscribed subtle radiolucency around roots of premolars and molar (best seen lower left).





**FIGURE 16-54.** Hematopoietic bone marrow defect. **A**, Fragments of viable bone and hematopoietic marrow. **B**, Megakaryocytes, erythrocyte precursors, and myelocytes are present.

## Nonodontogenic Cysts and Cystlike Lesions

Some lesions are true cysts derived from remnants of embryogenesis, whereas others are pseudocysts (Fig. 16-55).

### NASOPALATINE DUCT (INCISIVE CANAL) CYST

#### Clinical Findings

- Cysts may be round, ovoid, or heart shaped (because of the superimposed nasal spine seen in intraoral radiographs); symmetric radiolucency appears between the maxillary central incisors causing root divergence; adults in fourth and fifth decades are susceptible, and adjacent teeth are vital (Fig. 16-56).

#### Etiopathogenesis and Histologic Features

The epithelium derives from remnants of the nasopalatine duct that runs from the floor of the posterior nasal cavity anteriorly to the midline of the palate.

- Lining is nonkeratinized stratified squamous, low cuboidal, or pseudostratified, columnar and ciliated with scattered mucous cells; the basement membrane may be densely hyalinized; the nasopalatine neurovascular bundle is usually present (Fig. 16-57).

#### Differential Diagnosis

- Cyst removed in the same area but not within bone is the cyst of the incisive papilla, and this has similar histology (see Chapter 2).

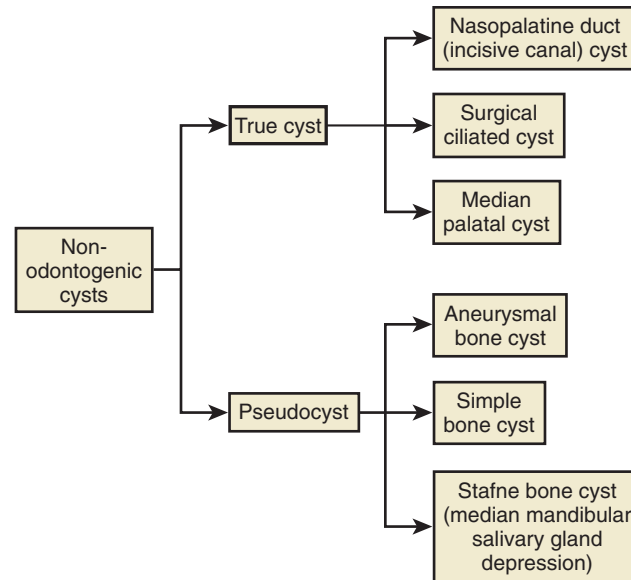
#### Management and Prognosis

- Excision is curative.

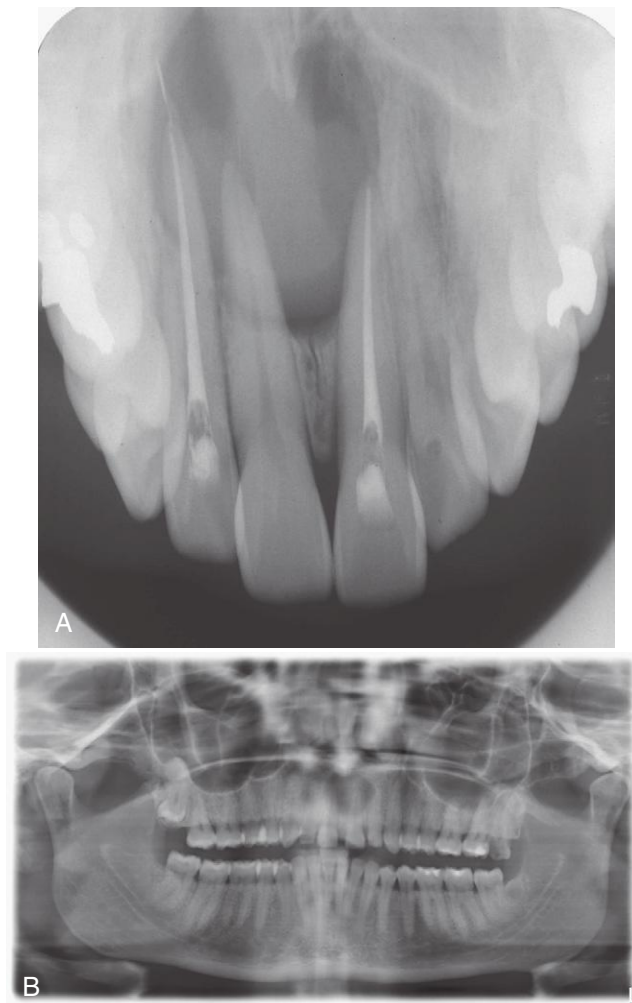
#### REFERENCES

- eI-Bardaie A, Nikai H, Takata T. Pigmented nasopalatine duct cyst. Report of 2 cases. *Int J Oral Maxillofac Surg.* 1989;18:138-139.
- Escoda Francoli J, Almendros Marques N, Berini Aytés L, Gay Escoda C. Nasopalatine duct cyst: report of 22 cases and review of the literature. *Med Oral Patol Oral Cir Bucal.* 2008;13:E438-E443.
- Swanson KS, Kaugars GE, Gunsolley JC. Nasopalatine duct cyst: an analysis of 334 cases. *J Oral Maxillofac Surg.* 1991;49:268-271.



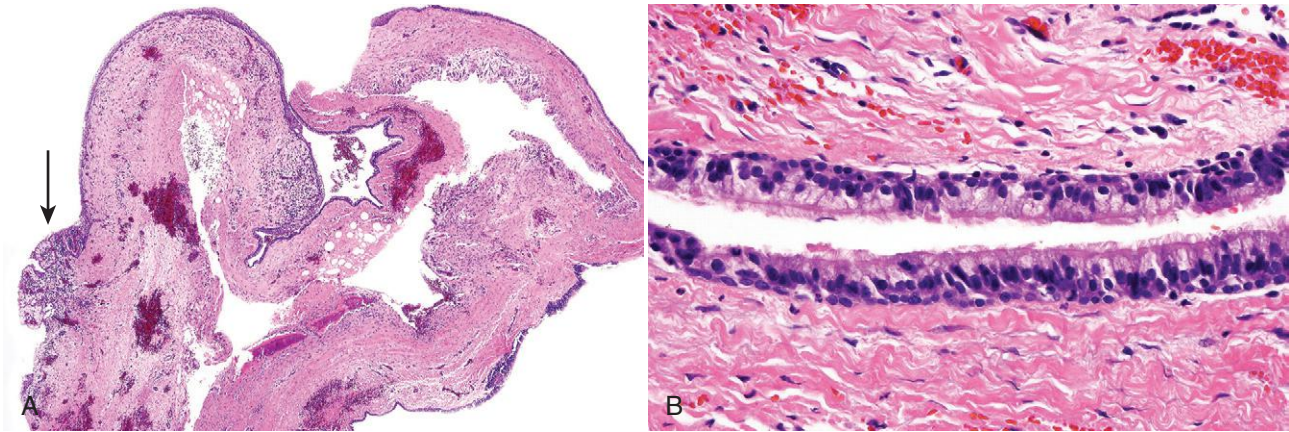


**FIGURE 16-55.** Classification of nonodontogenic cysts and cyst-like lesions.



**FIGURE 16-56.** Nasopalatine duct cyst. **A**, Symmetric, heart-shaped radiolucency in this occlusal radiograph between the upper central incisors, which are vital. (Courtesy of Dr. Martin Elson, Cranston, RI.) **B**, Ovoid radiolucency in panoramic radiograph in the midline between the central incisors, which are vital.





**FIGURE 16-57.** Nasopalatine duct cyst. **A**, Cyst lined by uniformly thin epithelium; epithelium becomes proliferative if inflamed (arrow). **B**, Lining composed of ciliated pseudostratified columnar epithelium.

## SURGICAL CILIATED CYST (POSTOPERATIVE MAXILLARY CYST)

### Clinical Findings

- Cyst occurs in third to sixth decade; it manifests as a unilocular radiolucency of the posterior maxilla with a history of surgery involving the sinuses (Fig. 16-58); cyst is rarely reported in the mandible; up to 20% of patients in the Japanese population develop this cyst after surgery.

### Etiopathogenesis and Histopathologic Features

The cyst epithelium is derived from surgical (traumatic) implantation of sinus respiratory epithelium during surgical procedures such as a Le Fort I or Caldwell-Luc procedure. Mandibular cysts occur if mandibular surgery is performed immediately after sinomaxillary surgery using the same instruments.

- Lining consists of ciliated pseudostratified columnar and cuboidal epithelium two to five cells thick with mucous cells in most cases; transitional and squamous epithelium may be present; variable (usually mild) inflammation occurs in the wall (Figs. 16-59 and 16-60).

### Differential Diagnosis

- Apical radicular cyst (see Chapter 14) in the posterior maxilla may be lined by respiratory epithelium, but it is always associated with a nonvital tooth without a history of sinus surgery.

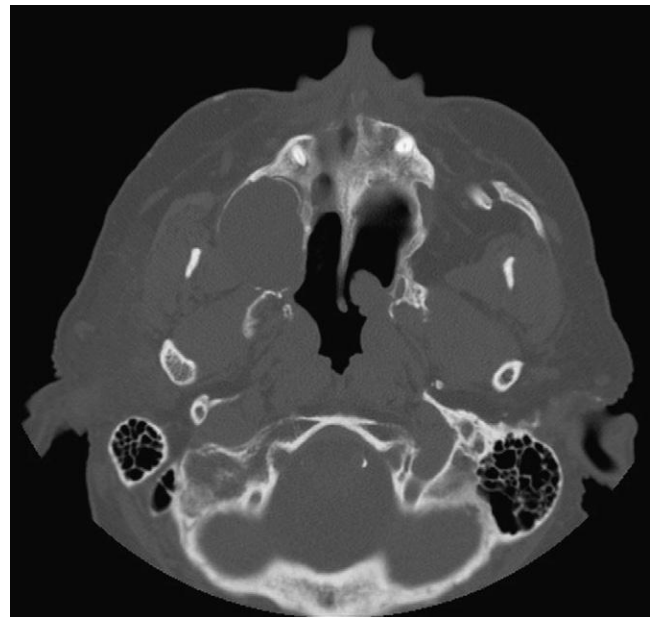
### Management and Prognosis

- Excision is curative.

### REFERENCES

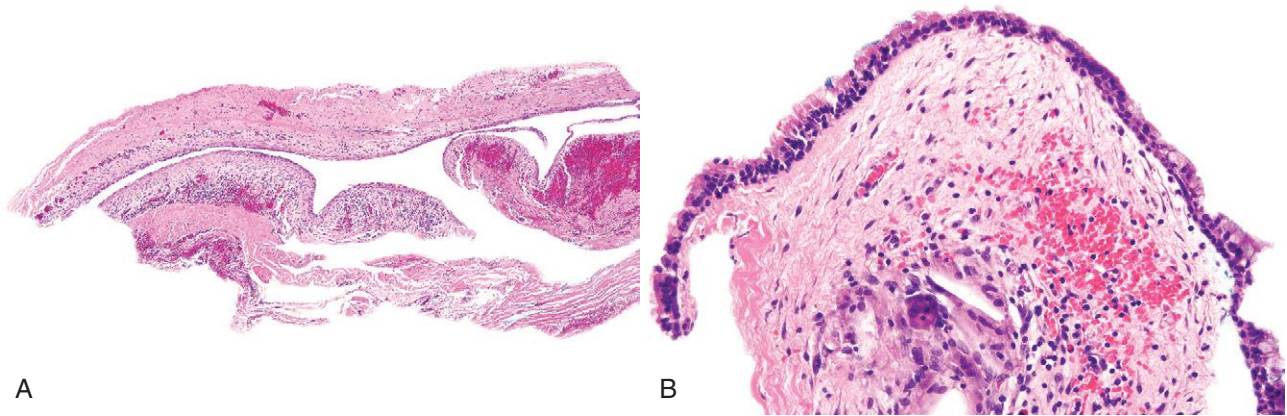
Kaneshiro S, Nakajima T, Yoshikawa Y, et al. The postoperative maxillary cyst: report of 71 cases. *J Oral Surg.* 1981;39:191-198.

Koutlas IG, Gillum RB, Harris MW, Brown BA. Surgical (implantation) cyst of the mandible with ciliated respiratory epithelial lining: a case report. *J Oral Maxillofac Surg.* 2002;60:324-325.  
 Maruyama M, Onodera K, Ooya K. A histopathological and lectin-histochemical study of the lining epithelium in postoperative maxillary cysts. *Oral Dis.* 2002;8:241-248.  
 Yamamoto H, Takagi M. Clinicopathologic study of the postoperative maxillary cyst. *Oral Surg Oral Med Oral Pathol.* 1986;62:544-548.

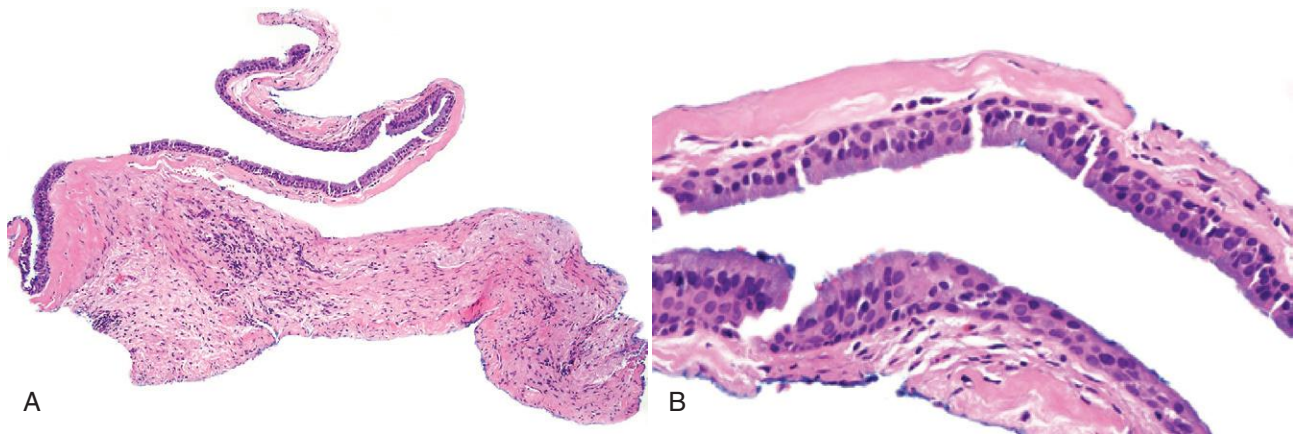


**FIGURE 16-58.** Surgical ciliated cyst. Unilocular radiolucency of the right maxilla in a patient with a history of surgery at that site. (Courtesy of Dr. Jeffrey Stone, private practice, Lowell, Mass.)





**FIGURE 16-59.** Surgical ciliated cyst. **A**, Cyst lined by uniformly thin epithelium with mild chronic inflammation. **B**, Cyst lined by ciliated pseudostratified columnar epithelium with many mucous cells; mild chronic inflammation.



**FIGURE 16-60.** Surgical ciliated cyst. **A**, Cyst lined by uniformly thin epithelium with mild chronic inflammation. **B**, Cyst lined by cuboidal and columnar epithelium with mucous cells; mild chronic inflammation and thickened basement membrane zone.

## MEDIAN PALATAL (PALATINE) CYST

This is an extremely rare cyst; its existence has been questioned. Bona fide examples are too posteriorly located to represent odontogenic or nasopalatine duct cysts as some suggest.

### Clinical Findings

- Cyst occurs in the fourth decade, with a 4:1 male predilection; swelling occurs in the midline of the palate posterior to, and not in communication with, the contents of the nasopalatine foramen (Fig. 16-61).

### Etiopathogenesis and Histopathologic Features

The lining arises from entrapped epithelium during fusion of the lateral palatal shelves.

- The cyst is lined by ciliated, pseudostratified columnar or uniformly thin nonkeratinized, stratified squamous epithelium.

### Differential Diagnosis

- Posterior extension of the nasopalatine duct cyst should be considered, but this communicates with the nasopalatine foramen.
- If it is parakeratinized and fulfills the histologic criteria for a keratocystic odontogenic tumor (odontogenic keratocyst), then it is likely a posterior extension of a primordial cyst of a mesiodens.

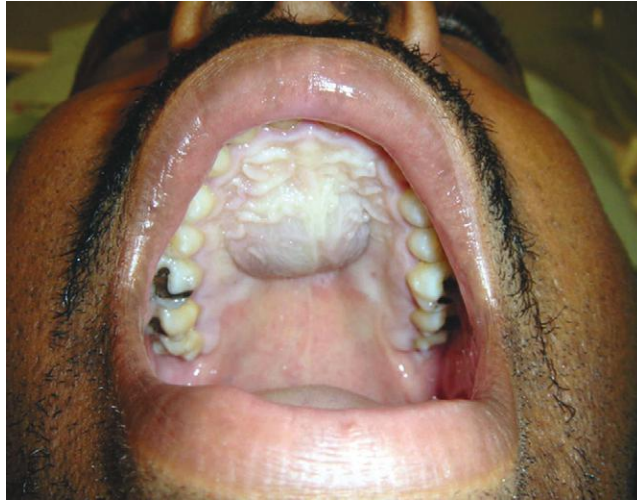### Management and Prognosis

- Enucleation is curative.

### REFERENCES

- Gingell JC, Levy BA, DePaola LG. Median palatine cyst. *J Oral Maxillofac Surg.* 1985;43:47-51.
- Manzon S, Graffeo M, Philbert R. Median palatine cyst: case report and review of literature. *J Oral Maxillofac Surg.* 2009;67:926-930.





**FIGURE 16-61.** Median palatal cyst. Swelling of the midline of the palate posterior to the nasopalatine foramen. (From Manzon S, Graffeo M, Philbert R. Median palatal cyst: case report and review of literature. *J Oral Maxillofac Surg.* 2009;67:926-930.)

## ANEURYSMAL BONE CYST

Aneurysmal bone cyst, simple bone cyst, and Stafne bone cavity are pseudocysts that are not lined by epithelium.

### Clinical Findings

- Ninety percent of those affected are younger than age 30; there is swelling of the face (sometimes rapid); the lesion manifests as an uniloculated or more often multiloculated, expansile radiolucency with a sclerotic rim of reactive bone and delicate intralésional trabeculae; the mandible is usually affected (75% to 90%) (Fig. 16-62); fluid level from hemorrhage is noted on imaging studies and aspiration yields blood.
- The lesion may occur secondary to another condition, such as fibrous dysplasia, ossifying fibroma, or other intraosseous neoplasms.

### Etiopathogenesis and Histopathologic Features

The etiology is unknown, although trauma and local alteration of blood supply have been postulated as possible triggers. Extracranial lesions show translocations associated with chromosomes 16q22 and 17p13 in one third of cases. Primary aneurysmal bone cyst may have a different etiology from secondary lesions.

- Variably-sized, blood-filled spaces are surrounded by fibrous and granulation tissue and macrophages focally rimmed by multinucleated giant cells; fresh hemorrhage and siderophages are noted (Fig. 16-63); reactive or residual bone is a frequent finding and should not be overdiagnosed as a synchronous fibro-osseous lesion; 10% of lesions perforate the cortex.

### Differential Diagnosis

- Central giant cell granuloma and giant cell lesions of Noonan and Noonan-like giant cell lesion syndromes do not contain large blood-filled spaces, although it may be difficult to see these in a curetted specimen.
- Cherubism has specific clinical, radiographic, and genetic findings.

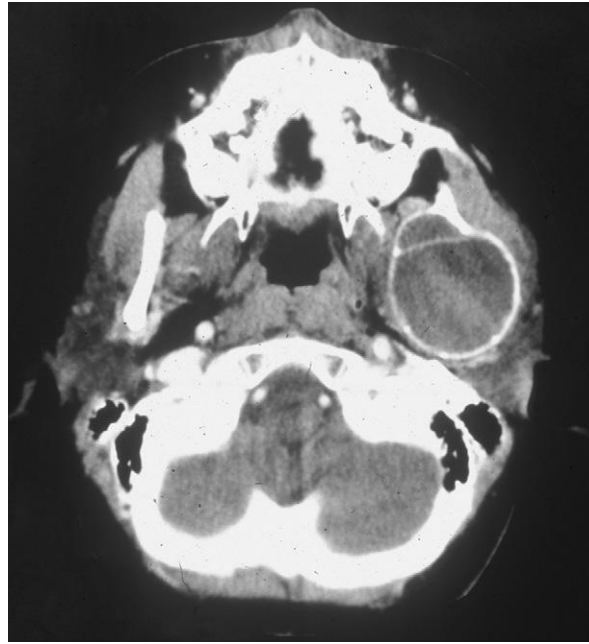
### Management and Prognosis

- Curettage, excision, resection, and percutaneous sclerotherapy are treatment modalities; recurrence in 10% to 15% of cases is likely from incomplete removal; rarely, cases regress spontaneously.

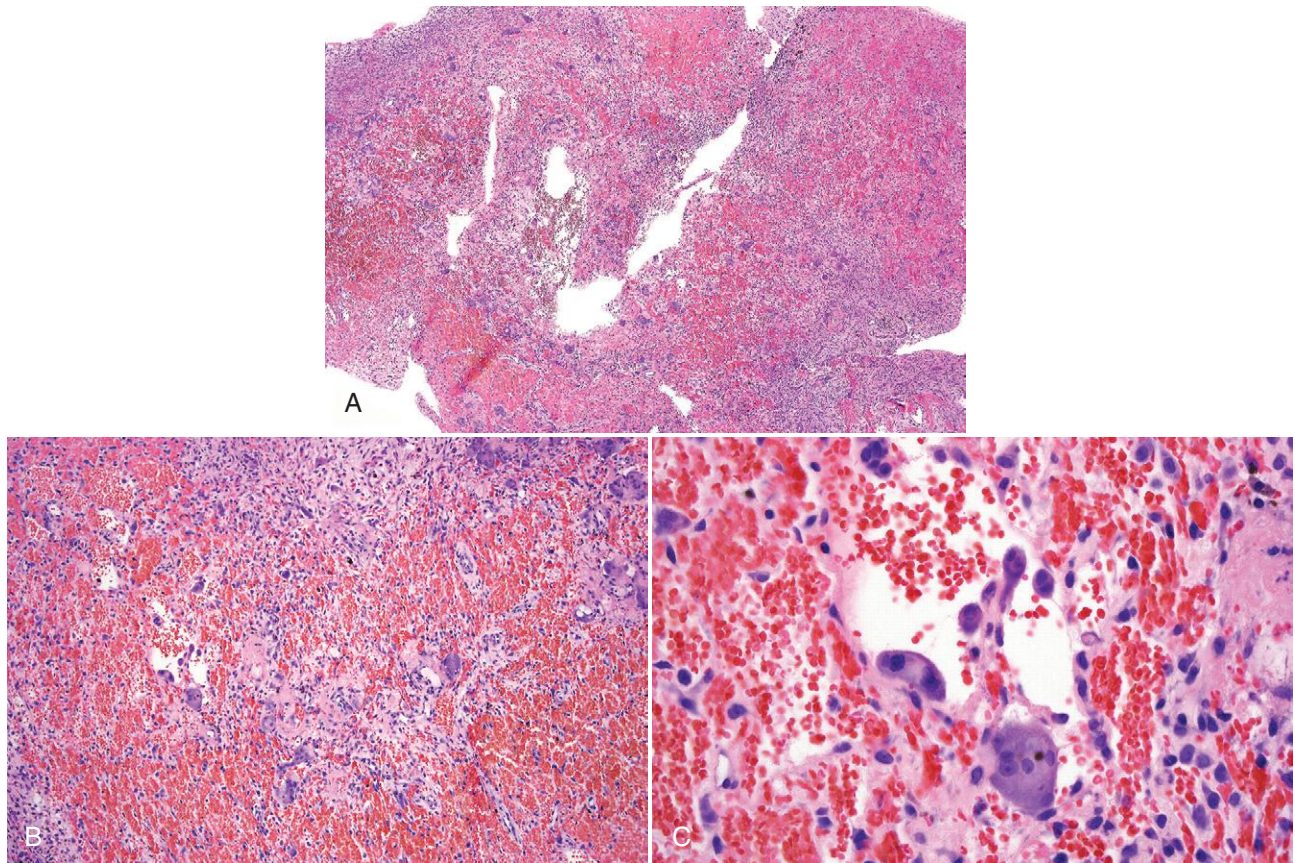
### REFERENCES

- Althof PA, Ohmori K, Zhou M, et al. Cytogenetic and molecular cytogenetic findings in 43 aneurysmal bone cysts: aberrations of 17p mapped to 17p13.2 by fluorescence in situ hybridization. *Mod Pathol.* 2004;17:518-525.
- Barnes L, Eveson J, Reichart P, Sidransky D, eds. *Pathology and Genetics of Head and Neck Tumors.* Lyon, France: IARC Press; 2005.
- Cottalorda J, Bourelle S. Current treatments of primary aneurysmal bone cysts. *J Pediatr Orthop B.* 2006;15:155-167.
- Dubois J, Chigot V, Grimard G, et al. Sclerotherapy in aneurysmal bone cysts in children: a review of 17 cases. *Pediatr Radiol.* 2003;33:365-372.
- Fennessy BG, Vargas SO, Silvera MV, et al. Paediatric aneurysmal bone cysts of the head and neck. *J Laryngol Otol.* 2009;123:635-641.
- Motamedi MH, Navi F, Eshkevari PS, et al. Variable presentations of aneurysmal bone cysts of the jaws: 51 cases treated during a 30-year period. *J Oral Maxillofac Surg.* 2008;66:2098-2103.
- Sun ZJ, Zhao YF, Yang RL, Zwahlen RA. Aneurysmal bone cysts of the jaws: analysis of 17 cases. *J Oral Maxillofac Surg.* 2010;68:2122-2128.





**FIGURE 16-62.** Aneurysmal bone cyst. Biloculated expansile radiolucency of left mandibular ramus. (Courtesy of Dr. Charles E. Tomich, Indiana University School of Dentistry, Indianapolis, Ind.)



**FIGURE 16-63.** Aneurysmal bone cyst. **A**, Cystlike spaces surrounded by fibrous and granulation tissue containing many multinucleated giant cells. **B**, Extensive hemorrhage with small cystlike spaces. **C**, Giant cells rimming cystlike spaces. (A, Courtesy of Dr. Harry Kozakewich, Harvard Medical School, Boston, Mass.)



## SIMPLE BONE CYST (TRAUMATIC BONE CYST, IDIOPATHIC BONE CAVITY)

### Clinical Findings

- Seventy-five percent of cysts are seen in the first two decades with a slight male predilection; 75% are in the mandibular molar-premolar area, and it is rare in maxilla; unilocular radiolucency measuring up to several centimeters sometimes scallops between the roots of teeth (Fig. 16-64); surgeon will report presence of serosanguineous fluid or empty cavity with only small wisps of tissue clinging to the walls; patients rarely recall an associated history of trauma.
- This condition is associated with long-standing cementoosseous dysplasia.

### Etiopathogenesis and Histopathologic Features

The most widely accepted theory is that trauma causes a hematoma that leads to venous stasis and bone

ischemia, but for unknown reasons, bone remodeling does not occur.

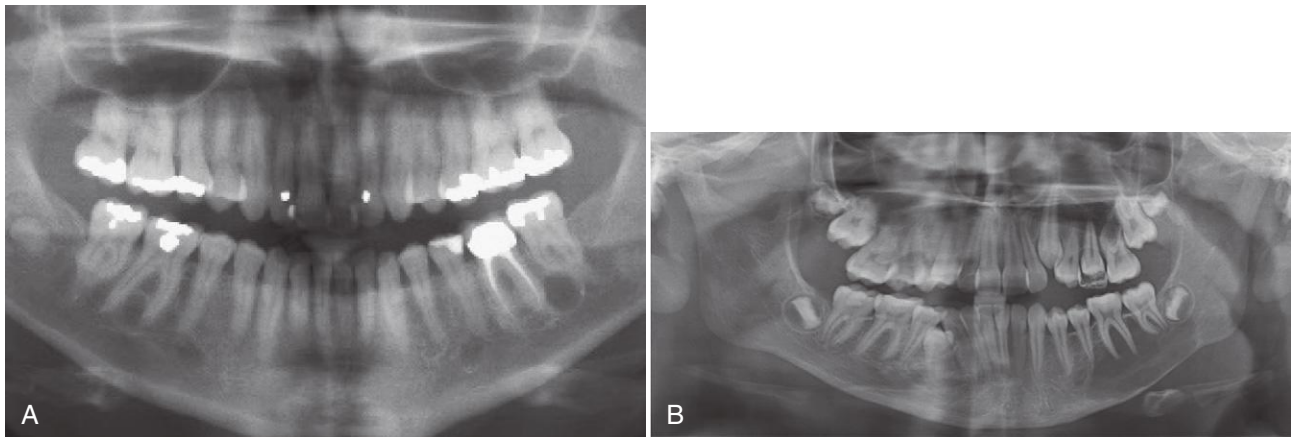
- Small fragments of fibrovascular tissue, hemorrhage, and bone fragments or calcified debris disproportionate to the size of the clinical lesion are present (Fig. 16-65).

### Management and Prognosis

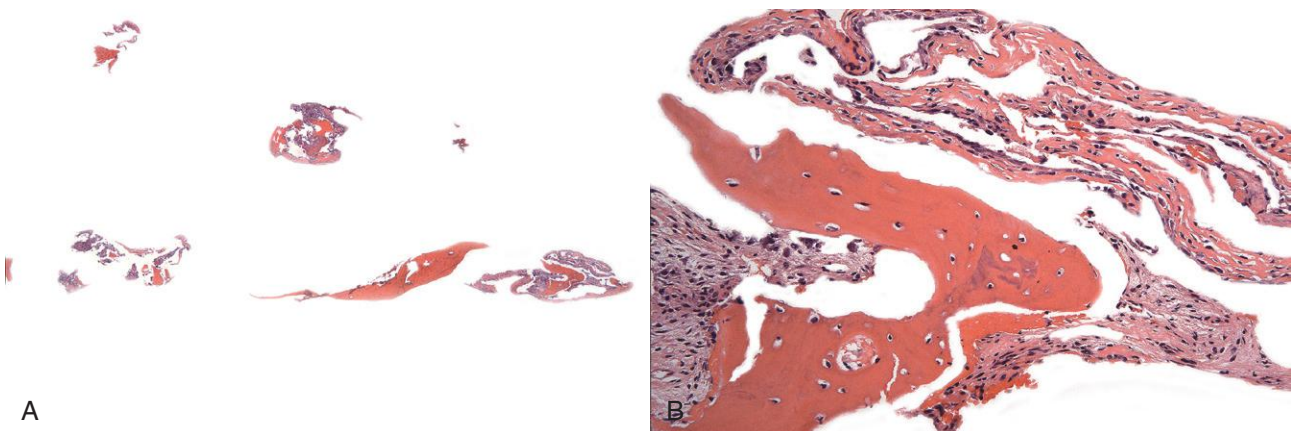
- Curettage to induce clot and granulation tissue formation with subsequent reorganization to form bone is recommended treatment; 20% to 25% of cases recur, usually within the first 3 years of treatment.

### REFERENCES

- Harnet JC, Lombardi T, Klewansky P, et al. Solitary bone cyst of the jaws: a review of the etiopathogenic hypotheses. *J Oral Maxillofac Surg.* 2008;66:2345-2348.
- Suei Y, Taguchi A, Tanimoto K. Simple bone cyst of the jaws: evaluation of treatment outcome by review of 132 cases. *J Oral Maxillofac Surg.* 2007;65:918-923.
- White S, Pharoah M. *Oral Radiology: Principles and Interpretation.* 6th ed. St. Louis: Mosby; 2009.



**FIGURE 16-64.** Simple bone cyst. **A**, Unilocular radiolucency between left mandibular first and second molar. **B**, Large well-demarcated radiolucency in left posterior mandible, scalloping between roots of teeth. (Courtesy of Dr. Bonnie Padwa, Harvard School of Dental Medicine, Boston, Mass.)



**FIGURE 16-65.** Simple bone cyst. **A**, Small fragments of fibrovascular tissue and bone curretted from the walls of an empty cavity at surgery. **B**, Fibrovascular tissue and viable bone.



## STAFNE BONE CAVITY (LINGUAL SALIVARY GLAND DEPRESSION)

### Clinical Findings

- Occurs in fifth to seventh decade; 6:1 male predilection; well-demarcated radiolucency 0.5 to 2 cm in diameter; most common location in the lingual posterior mandible beneath inferior alveolar canal (85% of cases), anterior mandible (12%), and lingual ramus (2%); asymptomatic and discovered on routine radiography (Fig. 16-66)

### Etiopathogenesis and Histopathologic Features

Entrapped lobe of the sublingual or submandibular (rarely parotid) salivary gland exerts pressure on the cortex of the mandible, leading to pressure resorption.

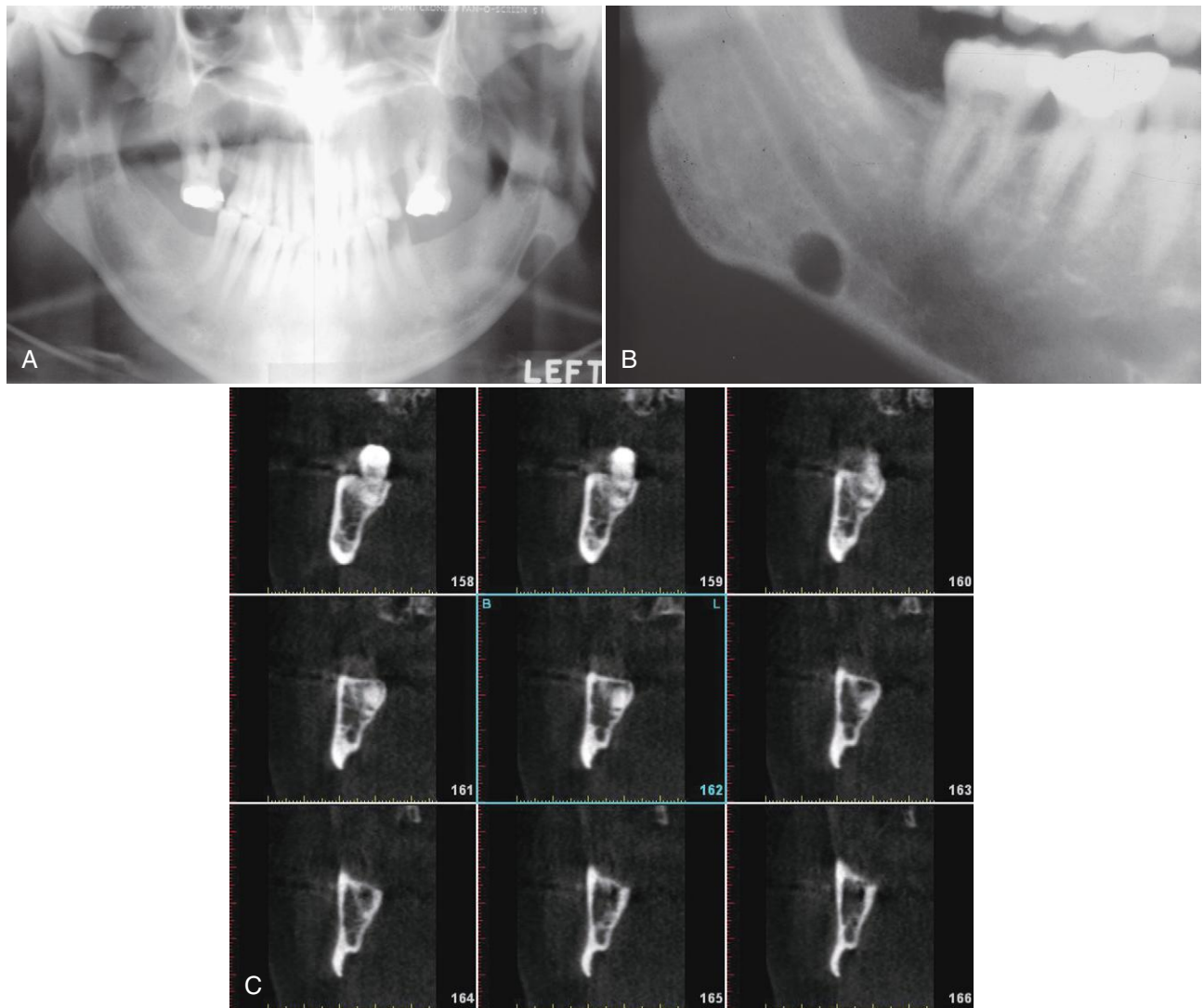
- Tissue consists of lobules of normal seromucinous glands.

### Management and Prognosis

- Lesion is well visualized and diagnostic in three-dimensional imaging studies; biopsy is not indicated.

### REFERENCES

- Bornstein MM, Wiest R, Balsiger R, Reichart PA. Anterior Stafne's bone cavity mimicking a periapical lesion of endodontic origin: report of two cases. *J Endod.* 2009;35:1598-1602.
- Philipsen HP, Takata T, Reichart PA, et al. Lingual and buccal mandibular bone depressions: a review based on 583 cases from a world-wide literature survey, including 69 new cases from Japan. *Dentomaxillofac Radiol.* 2002;31:281-290.
- White S, Pharoah M. *Oral Radiology: Principles and Interpretation.* 6th ed. St. Louis: Mosby; 2009.



**FIGURE 16-66.** Stafne bone cavity. **A**, Circumscribed radiolucency at the inferior border of the mandible, beneath the inferior alveolar canal. **B**, Circumscribed radiolucency beneath the inferior alveolar canal. **C**, CT scans show lingual depression just beneath inferior alveolar canal. (**A** and **C**, Courtesy of Dr. Bernard Friedland, Harvard School of Dental Medicine, Boston, Mass; **B**, Courtesy of Dr. George Wysocki, London, Ontario, Canada.)



This page intentionally left blank



## APPENDIX A

# PHARMACOLOGIC THERAPY FOR COMMON MUCOSAL CONDITIONS

Medication	How to Prescribe
<b>Topical Immunosuppressive Agents</b>	
Triamcinolone 0.1% dental paste* (not appropriate for diffuse lesions)	Apply to affected site 3–4 times a day; methylcellulose is an effective covering agent, although steroid is only medium strength
Fluocinolone 0.05% gel	Dry area, apply to affected site 3–4 times a day; no food or drink for 20 min after
Clobetasol 0.05% gel	OR
Betamethasone 0.05% gel	Place gel in stent and wear for 15–30 min, 2–3 times a day
Tacrolimus 0.1% ointment	
Dexamethasone elixir 0.5 mg/5mL	Dispense 300 mL; swish 5 mL (dexamethasone, tacrolimus or cyclosporine), or
Prednisolone syrup (15 mg/5mL)	5–15 mL (prednisolone) for 3 min (timed) and spit out, 3–4 times a day; no
Tacrolimus solution (5 mg/mL)	food or drink for 20 min after
Cyclosporine (100 mg/mL)	
Topical tetracycline (0.25%) or minocycline (0.2%) aqueous solution	Dispense 300 mL; swish 5–15 mL for 3 min (timed) and spit out, 3–4 times a day; no food or drink for 20 min after
Nasal sprays used orally (such as fluticasone, betamethasone, and budesonide)	1–2 puffs two to three times daily
Intralesional steroid injection with triamcinolone	5–10 mg triamcinolone per cm <sup>2</sup> of ulceration
<b>Systemic Immunosuppressive Therapy<sup>†</sup></b>	
Prednisone	1.0 mg/kg to begin for 7–10 days with a rapid taper over 2–3 weeks
Pentoxifylline (especially for aphthous ulcers)	400–800 mg three times daily
Hydroxychloroquine (especially for lichen planus)	200–400 mg daily; macular pigmentary change may lead to visual impairment
Dapsone (especially for mucous membrane pemphigoid)	25 mg to begin, increasing to 75–100 mg daily; anemia (even more serious hemolytic anemia) is significant side effect
Mycophenolate mofetil (especially for pemphigus)	500–1500 mg twice daily; myelosuppression is a side effect
Colchicine (especially for aphthous ulcers)	0.6 mg once or twice daily; myelosuppression is side effect
Azathioprine	1–2 mg/kg daily; myelosuppression and liver toxicity are significant side effects
Thalidomide (especially for aphthous ulcers)	50–100 mg 2–3 times a day to begin; begin taper to maintenance dose (which may be weekly) or discontinue completely; drowsiness and paresthesia are significant side effects
<b>Topical Pain Medications</b>	
Viscous lidocaine 2%	Swish and spit out 5–15 mL, 3–4 times a day for pain
Benzydamine hydrochloride 0.15%	
Dyclonine hydrochloride 1%	

\*Methylcellulose adhesive base can be mixed with the other stronger topical steroids.

<sup>†</sup>Topical therapy should be started concomitantly with systemic therapy.



This page intentionally left blank



## APPENDIX B

# ANTIFUNGAL THERAPY

Medication	How to Prescribe
Nystatin 100,000 units/mL*	Dispense 300 mL; swish and spit out (or swallow) 5 mL 3–4 times a day for 7–10 days
Nystatin pastilles 200,000 units/pastille	Dissolve 1–2 pastilles in mouth 3–4 times a day for 7–10 days
Amphotericin B suspension 100 mg/mL	Dispense 300 mL; swish and spit out 5 mL 3–4 times a day for 7–10 days
Amphotericin 10 mg lozenges	Dissolve 1–2 tablets in mouth 3–4 times a day for 7–10 days
Clotrimazole 10 mg troches*	Suck on one troche 3–5 times a day for 7–10 days (troches do not dissolve if there is prominent hyposalivation)
Ketoconazole 200–400 mg daily	Take 1 or 2 tablets twice a day for 7–10 days
Miconazole 50 mg daily	Dissolve in mouth once a day for 7–10 days
Fluconazole 100–200 mg daily	Fluconazole: use as directed for 3–4 days (depending on the severity of the infection);
Itraconazole 100–200 mg daily	long-term therapy may lead to resistance to fluconazole. Culture and sensitivity
Voriconazole 200 mg bid	should be performed and itraconazole, voriconazole, and posaconazole are
Posaconazole 100 mg daily	alternatives; may be taken 1–2 times weekly for prophylaxis if on long-term
	immunosuppressive therapy.
Mycostatin/triamcinolone cream	Apply to corners of mouth tid or qid for angular cheilitis
Miconazole oral gel	Paint onto denture base tid and wear denture; add erythromycin gel if there is
Miconazole cream with/without hydrocortisone	residual lesion because <i>Staphylococcus aureus</i> may be involved.
Iodoquinol/hydrocortisone 1% cream	
Denture soaks:	Soak denture in solution overnight. Dentures should never be worn overnight.
Nystatin 100,000 U/mL	
Chlorhexidine digluconate 0.12–2%	
3% sodium hypochlorite diluted in water (1:10)	
2% sodium benzoate	

\*Contains cariogenic sugars and may lead to caries if used long term.



This page intentionally left blank



# INDEX

## A

Acanthosis nigricans, 61f  
 Acinar atrophy, 279f  
 Acinar hyperplasia, 283, 283f  
 Acinic cell adenocarcinoma, 313–314, 314f–315f  
 Actinomycosis, 35–36, 36f–37f  
 Adenocarcinoma. *see also* carcinoma  
   acinic cell, 313–314, 314f–315f  
   clear cell, 316, 317f–318f  
   not otherwise specified, 318, 319f  
   polymorphous low-grade, 309–310, 310f–313f  
 Adenoid cystic carcinoma, 305–306, 306f–309f  
 Adenoid squamous cell carcinoma, 254, 255f  
 Adenoma, 11  
   canalicular, 293, 294f–295f  
   cyst-, 295  
   pleomorphic, 286–287, 287f–293f  
 Adenomatoid hyperplasia, 283, 283f  
 Adenomatoid odontogenic tumor, 353, 354f–355f  
 Adenosis, sclerosing polycystic, 284, 285f  
 Adenosquamous cell carcinoma, 256, 256f–257f  
 Adult rhabdomyoma, 134, 134f  
 Adults, gingival cysts of, 79  
 Aggressive giant cell lesion, 398  
 Aggressive ossifying fibroma, 385–386, 388f, 393f–394f  
 Alcohol consumption, 243–244  
 Alveolar ridge, lymphangioma of the, 19  
 Amalgam tattoo, 185  
 Ameloblastic carcinoma, 358f  
 Ameloblastic carcinoma, 357  
 Ameloblastic fibroma, 365–366, 366f–367f  
 Ameloblastic fibro-odontoma, 368, 368f–370f  
 Ameloblastic fibro-odontoma, 368  
 Ameloblastoma, 346f–350f  
 Ameloblastoma, peripheral, 84, 85f  
 Ameloblastoma, 345  
 Anatomy, oral cavity, 1  
 Ancient schwannoma, 124f  
 Aneurysmal bone cyst, 428, 429f  
 Angioleiomyoma and leiomyoma, 131, 131f  
 Antifungal therapy, 435  
 Antimalarial medications, 189  
 Antineutrophil cytoplasmic autoantibody (ANCA)-associated vasculitides, 183  
 Anuglar cheilitis, 38  
 Apical and lateral radicular cysts, 320–321  
 apical radicular cyst, 323f–324f, 327f  
   at apex of maxillary first molar, 326f  
   sinus inflammatory polyp, 326f  
 Apostematosa, cheilitis glandularis, 275  
 Areca nut, 227–228, 243–244  
 Aspergillosis, 42, 45f  
 Atrophy, acinar, 279f  
 Autoimmune conditions, 173–174  
   autoimmune sialadenitis, 280  
   lichen planus/lichenoid mucositis, 165–167  
 Autoimmune conditions  
   autoimmune sialadenitis, 280, 281f–282f  
 Autoimmune sialadenitis, 280, 281f–282f

## B

Basal cell hyperplasia, 229f, 234f  
 Basaloid squamous cell carcinoma, 250, 251f–252f  
 B-cell lymphoma, 414f  
 Behçet disease, 137–138  
 Benign alveolar ridge keratosis, 218, 219f–221f  
 Benign epithelial hyperplasia  
   leukoedema, 212f  
   morsicato mucosae oris, 216f–218f  
 Benign hyperkeratoses, 231  
 Benign lymphoepithelial cyst, 20, 21f–22f  
 Benign migratory glossitis, 158, 159f–160f  
 Benign migratory stomatitis, 159f  
 Benign salivary gland neoplasms, 286–287  
   canalicular adenoma, 293  
   cystadenoma, 295  
   intraductal papilloma, 299  
   inverted ductal papilloma, 300  
   pleomorphic adenoma and myoepithelioma, 286–287  
   sialadenoma papilliferum, 298  
 Betel leaf, 227–228  
 Biopsy, punch, 6f  
 Birth control pills, 189  
 Bisphosphonate-related osteonecrosis and osteoradionecrosis, 417–419, 418t, 420f–422f  
 Bite fibroma, 63–64  
 Blisters, frictional, 145  
 Blisters  
   pemphigus vulgaris and, 179f  
   recurrent oral erythema multiforme and, 163f  
 Bone cavity, Stafne, 431, 431f  
 Bone cyst  
   aneurysmal, 428, 429f  
   simple, 395f, 430  
 Bone, Paget disease of, 396, 397f  
 botryoid odontogenic cyst, 335f  
 Bowen disease, 241  
 Brain and gastrointestinal heterotopias, 17  
 Buccal mucosa, 3f  
 Buerger disease, 276  
 Bulimia, 276  
 Bulky atypical squamous proliferation with dysplasia, 235f  
 Bulky epithelial proliferation, 234f

## C

Calcifying cystic odontogenic tumor, 362, 363f–364f  
 Calcifying epithelial odontogenic tumor, 351f–353f  
 Calcium hydroxylapatite filler, 153f  
 Calculus, salivary, 270, 272–273, 273f–275f  
 Caliber-persistent labial artery, 114, 114f  
 Canalicular adenoma, 293, 294f–295f  
 Candidiasis, 38, 39f–41f, 231  
 Candidosis. *see* Candidiasis  
 Cannon white sponge nevus, 7–8, 8f  
 Carcinoma. *see also* adenocarcinoma  
   acinic cell adeno-, 313–314  
   adenoid cystic carcinoma, 305–306  
   adenoid cystic, 306f–309f  
   adenoid squamous cell, 254, 255f

## Carcinoma (*cont'd*)

adenosquamous cell, 256, 256f–257f  
 ameloblastic, 357, 358f  
 -associated oropharyngeal and tonsillar nonkeratinizing, 253f–254f  
 basaloid squamous cell, 250, 251f–252f  
 clear cell odontogenic, 360–361, 361f  
 cuniculate, 262f–263f  
 cuniculatum, 262  
 cystic squamous cell, 263f  
 ex pleomorphic adenoma of the upper lip, 293f  
 human papillomavirus-associated oropharyngeal and tonsillar nonkeratinizing squamous cell carcinoma, 253f–254f  
 human papillomavirus-associated oropharyngeal and tonsillar nonkeratinizing, 252  
 in situ, 239f  
 mucoepidermoid carcinoma, 301–302, 302t, 303f–305f  
 mucoepidermoid, 332f  
 papillary squamous cell, 259, 259f–260f  
 polymorphous low-grade adeno-, 309–310  
 primary intraosseous squamous cell, 358–359, 359f–360f  
 sarcomatoid squamous cell, 247, 248f–250f  
 squamous cell, 243–244, 245f–247f  
 verrucous, 257, 258f  
 Cementoblastoma, 379, 379f–381f  
 Cemento-osseous dysplasia, 395f  
 Cemento-osseous fibroma, 388f  
   central, 388f, 392f  
 Cemento-ossifying fibroma, 385–386  
 Cementum, 1, 5f  
 Central cemento-ossifying fibroma, 388f, 392f  
 Central giant cell granuloma, 398, 399f–400f  
 Central giant cell lesion, 398  
 Central giant cell reparative granuloma, 398  
 Central odontogenic fibroma, 373, 373f–374f  
 Cheilitis glandularis, 275, 276f  
 Cherubism, 401, 401f–402f  
 Chondrosarcoma, 407–408  
 Choristomas, osseous and cartilaginous, 14  
 Chondrosarcoma, 408f–410f  
 Chronic gingivitis, 145  
 Chronic graft-*versus*-host disease, 167f–168f, 173f  
 Chronic obstructive sialadenitis, 267f  
 Circumvallate papillae, 3f  
 Clear cell adenocarcinoma, 316, 317f–318f  
 Clear cell odontogenic carcinoma, 360–361, 361f  
 Clofazimine, 189  
 Coccidioidomycosis, 42, 43f  
 Collagenous periodontal ligament, 5f  
 Condyloma acuminatum, 53–54, 55f, 59f–60f  
 Congenital conditions. *See* Developmental and congenital conditions  
 Congenital granular cell epulis, 13  
 Congenital granular cell tumor, 13, 13f–14f  
 Contact desquamation, 213, 213f  
 Contact stomatitis, nonspecific irritant, 143  
 Crevicular epithelium, 5f  
 Cribiform adenocarcinoma of the tongue, 313f



- Crohn disease  
 orofacial granulomatosis and, 154–155, 155f–156f  
 pyostomatitis vegetans and, 157  
 ulcerative conditions and, 137–138
- Cuniculate carcinoma, 262, 262f–263f
- Cyclic neutropenia, 137–138
- Cyst of the incisive papilla, 25, 25f–26f
- Cystadenoma, 295, 295f–297f
- Cystic legions  
 cyst of the incisive papilla, 25f–26f  
 dermoid, 24f  
 epidermoid, 24f  
 lymphoepithelial, 21f–22f  
 nasolabial cyst, 27f  
 palatal and gingival cysts of the neonate, 25f
- Cystic lesions, 20  
 salivary duct cyst, 270
- Cystic squamous cell carcinoma, 263f
- Cysts, gingival  
 of the adult, 79, 80f–82f  
 of the neonate, 25, 25f
- cysts, jaw, 320, 322f
- Cysts, nonodontogenic, 424  
 aneurysmal bone cyst, 430  
 aneurysmal bone, 428, 429f  
 median palatal cyst, 427, 428f  
 nasopalatine duct, 424, 425f–426f  
 simple bone, 430, 430f  
 surgical ciliated, 426, 426f–427f
- Cysts, odontogenic, 320  
 apical and lateral radicular cyst and periapical granuloma, 320–321, 324f, 326f–327f  
 botryoid, 335f  
 calcifying, 362  
 classification of jaw, 322f  
 dentigerous, 328–329, 329f–333f  
 developing tooth and, 320, 322f  
 developmental, 328–329, 329f–331f, 333f, 337f  
 giant cell hyaline rings, 321, 325f  
 in a globulomaxillary location, 337, 337f  
 inflammatory, 320–321  
 lateral periodontal, 333, 334f–335f  
 mandibular buccal bifurcation, 327, 328f  
 orthokeratinized odontogenic, 336f  
 orthokeratinized odontogenic, 335  
 primordial, 338, 338f–339f
- Cysts, salivary duct, 270, 270f–272f
- Cysts, simple bone, 395f
- Cytomegalovirus infection, 51–52, 52f–53f
- D**
- Darier disease, 10, 10f
- dental papilla, 332f
- Dentifrice-induced desquamation, 213f
- Dentigenic ghost cell tumor, 365f
- Dentigerous cyst, 328–329, 329f–333f
- Dentin, 5f
- Dentinogenic ghost cell tumor, 362
- Denture-associated inflammatory fibrous hyperplasia, 88, 89f–90f
- Dermoid cysts, 23, 24f
- Desmoplastic fibroma, 402–403, 403f
- Desquamative gingivitis, 175f, 178f
- Developmental and congenital conditions, 26f  
 congenital granular cell tumor, 13, 13f–14f  
 cyst of the incisive papilla, 25, 25f–26f  
 cystic legions, 20, 21f–22f, 24f–27f  
 Darier disease, 10, 10f  
 diffuse white lesions, 7–8, 8f–9f  
 epidermoid and dermoid cysts, 23, 24f  
 fordycce granules, 12f  
 gastrointestinal and brain heterotopias, 17, 18f  
 gingival fibromatosis, 15–16, 16f  
 hereditary benign intraepithelial dyskeratosis, 9, 9f  
 leiomyomatous hamartoma, 20, 20f  
 lingual thyroid, 19, 19f  
 lymphangioma of the alveolar ridge in neonates, 19  
 nasolabial cyst, 26, 27f  
 nodular or tumor-like lesions, 11
- Developmental and congenital conditions  
 (*cont'd*)  
 oral lymphoepithelial cyst, 20, 21f–22f  
 osseous and cartilaginous choristomas, 14  
 osteolipomatous choristoma, 15f  
 palatal and gingival cysts of the neonate, 25, 25f  
 sebaceous hyperplasia, 12f–13f  
 warty dyskeratoma, 10, 11f  
 white sponge nevus, 8f
- Developmental cysts, 328–329  
 dentigerous, 328–329  
 lateral periodontal, 333  
 odontogenic cyst in a globulomaxillary location, 337  
 orthokeratinized odontogenic, 335  
 primordial, 338
- developmental odontogenic cyst, 337f
- Diagnosis and management, mucosal disease, 2, 3f–6f
- Diffuse white legions, 8f–9f
- Diffuse white lesions, 7–8
- Diffuse/multifocal gingival hyperplasia, 76–77, 77f–78f
- Discoid lupus erythematosus, 182f
- Dysplasia, 230–232  
 bulky atypical squamous proliferation with, 235f  
 fibrous, 385–386, 387f, 389f–390f  
 focal cemento-osseous, 385–386, 387f, 390f–391f  
 human papillomavirus-associated apoptotic, 242f–243f  
 human papillomavirus-associated apoptotic, 241  
 hyperorthokeratosis with minimal-to-mild dysplasia, 237f  
 hyperorthokeratosis with moderate epithelial, 237f  
 hyperparakeratosis with, 234f  
 mild epithelial, 238f  
 mild, 237f  
 moderate epithelial, 238f  
 moderate-to-severe epithelial, 240f  
 multifocal cemento-osseous, 388f, 395f  
 submucous fibrosis with, 229f  
 verrucous hyperplasia with, 235f–236f
- Dysplastic melanocytic nevus, 203
- E**
- Ectatic duct, 273f–274f
- Ectomesenchymal chondromyxoid tumor of the tongue, 97–98, 98f–99f
- Embryonal rhabdomyoma, 136f
- Embryonal rhabdomyosarcoma, 135
- Enamel, tooth, 1
- Eosinophilic globules, 266f
- Eosinophilic ulcer of tongue, 140–141
- Epidermoid cyst, 24f
- Epidermoid cysts, 23
- Epithelial dysplasia, 238f, 240f  
 hyperorthokeratosis with moderate, 237f  
 hyperparakeratosis and severe, 239f  
 moderate-to-severe, involving excretory duct, 240f
- Epithelial hyperplasia, 67f, 71f, 222f
- Epithelial inclusion cysts, 23
- Epithelial tumors without ectomesenchyme  
 adenomatoid odontogenic tumor, 353  
 ameloblastic carcinoma, 357  
 ameloblastoma, 345  
 calcifying, 351  
 clear cell odontogenic carcinoma, 360–361  
 keratocystic odontogenic tumor, 340–341  
 primary intraosseous squamous cell carcinoma, 358–359  
 squamous, 355–356
- Epithelium  
 crevicular, 5f  
 squamous, 3f  
 surface, 5f
- Epulis fissuratum, 88
- Erythema areata migrans, 158
- Erythema multiforme, 161–162  
 recurrent oral, 162f–163f
- Erythema of the upper labial mucosa, 167f–168f
- Erythematous candidiasis, 38, 39f–40f
- Erythematous lichen planus, 167f–168f
- Erythroleukoplakia, 230  
 nonhomogenous, 232f  
 of the palate, 234f  
 proliferative, 233f
- Erythroplakia, 230–232
- Ewing sarcoma, 411, 415f
- Excretory duct, moderate-to-severe epithelial dysplasia involving, 240f
- Exogenous pigmentation, 185
- Exostoses and tori, 382–383, 383f–384f
- Extraosseous odontogenic neoplasms, 82–83, 83f–85f
- F**
- Familial gigantiform cementoma, 385–386, 389f
- Fibroepithelial hyperplasia, 89f
- Fibroepithelial polyps, 63–64
- Fibroma, 63–64, 64f–68f, 70f  
 aggressive ossifying, 385–386, 388f, 393f–394f  
 ameloblastic, 365–366, 366f–367f  
 cemento-osseous, 388f, 392f  
 cemento-ossifying, 385–386  
 central odontogenic, 373, 373f–374f  
 desmoplastic, 402–403, 403f  
 gingival, 70f–71f, 105f  
 peripheral odontogenic, 83f–84f  
 peripheral ossifying, 70f, 72f–73f  
 sclerotic, 66f
- Fibro-odontoma, ameloblastic, 368
- Fibro-osseous lesions, 385–386, 385t, 387f
- Fibrosis, submucous, 227–228, 228f
- Fibrous dysplasia, 385–386, 387f, 389f–390f
- Fibrous lesions, 63–64, 64f–68f, 70f
- Fibrovascular polyps, 63–64
- Filiform, 3f
- Focal cemento-osseous dysplasia, 385–386, 387f, 390f–391f
- Follicular cyst, 328–329, 329f–332f
- Foot  
 lichen planus on, 167f–168f
- Fordyce granules, 11, 12f
- Foreign body  
 gingivitis, 148  
 granulomas, 150–151, 151f–153f
- Frictional blisters, 145
- Frictional/facitital keratoses, 51f, 214
- Frictional/facitital keratoses, 65f
- G**
- Gastrointestinal and brain heterotopias, 17, 18f
- Geographic tongue, 158
- Giant cell fibroma, 63–64, 64f, 67f, 70f
- Giant cell granuloma, 74f
- giant cell hyaline rings, 321, 325f
- Gingiva, keratinized, 3f
- Gingiva  
 Kaposi sarcoma on the maxillary, 116f
- Gingival ctsts  
 of the adult, 79, 80f–82f  
 of the neonate, 25, 25f
- Gingival fibromatosis, 15–16, 16f
- Gingival fibrous hyperplasia, 78f
- Gingival lichen planus, 170f
- Gingival masses, 3f, 68–69, 70f–71f
- Gingivitis  
 chronic, 145  
 desquamative, 175f, 178f  
 erythematous lichen planus and, 167f–168f  
 foreign body, 148  
 ligneous, 78f–79f  
 plasma cell, 164f–165f  
 ulcerative, 175f
- Globulomaxillary location, odontogenic cyst in a, 337
- Gorlin cyst, 362
- Graft-versus-host disease, 165
- Graft-versus-host disease, chronic, 167f–168f, 173f
- Granular cell odontogenic tumor, 377, 377f–378f
- Granular cell tumor, 127, 128f–129f



- Granulation tissue and mucocele, 266f–268f  
 Granuloma gravidarum, 71f  
 Granuloma  
   central giant cell reparative, 398  
   central giant cell, 398, 399f–400f  
   eosinophils within, 156f  
   foreign body, 150–151, 151f–153f  
   in salivary gland, 157f  
   lipid, 152f  
   nonnecrotizing, 156f–157f  
   periapical, 320–321, 324f, 326f–327f  
   poly-L-lactic acid, 152f  
   pyogenic, 106, 107f–109f  
   silicone, 153f  
   traumatic ulcerative, 140–141  
 Granulomatosis  
   orofacial, 154–155, 155f–156f  
   Wegener, 183, 183f–184f  
 Granulomatous infiltrate  
   lichenoid mucositis with, 171f  
 Granulomatous inflammation, 150–151, 151f  
   in the lamina propria, 156f  
   Wegener granulomatosis and, 184f  
 Granulomatous lichenoid mucositis, 167f–168f  
 Graphite tattoo, 188  
 gutta percha, 324f
- H**  
 Hair follicle  
   ruptured, 151f  
 Hairy leukoplakia, 48–49, 49f–51f  
 Hairy tongue, 218f  
 Heck disease, 53–54, 55f, 60f, 241  
 Hemangioma, infantile, 76f  
 Hematinic deficiencies, 137–138  
 Hematopoietic bone marrow defect, 423, 423f–424f  
 Hereditary benign intraepithelial dyskeratosis, 9, 9f  
 Herpes simplex virus (HSV), 47f–48f  
   recurrent oral erythema multiforme and, 162f  
 Herpesvirus infections, 45–46, 47f–48f  
 Heterotopias, gastrointestinal and brain, 17  
 Heterotopic brain tissue, 18f  
 Heterotopic gastrointestinal cyst, 18f  
 Histiocytosis, Langerhans cell, 416, 416f–417f  
 Histoplasmosis, 42, 44f  
 HIV/AIDS, 48, 51  
 Kaposi sarcoma and, 115  
   syphilis and, 61  
   ulcerative conditions and, 137–138  
 Homogeneous leukoplakia, 232f  
 Human papillomavirus  
   -associated apoptotic dysplasia, 241, 242f–243f  
   -associated oropharyngeal and tonsillar nonkeratinizing squamous cell carcinoma, 252, 253f–254f  
   -related benign lesions, 53–54  
 Human papillomavirus related benign lesions, 55f–61f  
 Hyalinizing clear cell adenocarcinoma, 316, 317f–318f  
 Hyaluronic acid filler, 154f  
 Hypermelanosis, postinflammatory, 193  
   lichen planus with, 170f  
 Hyperorthokeratosis, 65f, 231  
   benign alveolar ridge keratosis, 219f–220f  
   nicotinic stomatitis, 227f  
   nonspecific benign reactive keratoses, 222f  
   with gingival lichen planus, 170f  
   with lichen planus, 170f  
   with lichenoid mucositis, 171f–172f  
   with minimal-to-mild dysplasia, 237f  
   with moderate epithelial dysplasia, 237f  
 Hyperparakeratosis, 216f–217f, 221f  
   with dysplasia, 234f  
   and papillary epithelial hyperplasia, 243f  
   and severe epithelial dysplasia, 239f  
   smokeless tobacco lesions, 225f  
 Hyperparakeratosis, 234f, 239f  
   with lichen planus, 169f  
   with lichenoid mucositis, 171f
- Hyperplasia  
 adenomatoid, 283, 283f  
 basal cell, 229f, 234f  
 denture-associated inflammatory fibrous, 89f–90f  
 diffuse/multifocal gingival, 76–77, 77f–78f  
 epithelial, 67f, 71f, 158f, 169f, 173f, 175f  
 fibroepithelial, 89f  
 gingival fibrous, 78f  
 hyperparakeratosis and papillary epithelial, 243f  
 juvenile localized spongiotic gingival, 33f–34f  
   with dysplasia, verrucous, 235f–236f  
 Hyperplastic candidiasis, 38  
 hyperplastic dental follicle, 330f  
 Hyperplastic lingual tonsil, 22f–23f  
 Hypersensitivity reactions, nonspecific, 160, 161f
- I**  
 Idiopathic bone cavity, 430  
 Idiopathic orofacial granulomatosis, 156f  
 IgA disease, linear, 175f  
 IgG deposition  
   mucous membrane pemphigoid and, 176f  
   pemphigus vulgaris and, 180f  
 Imitanib, 189  
 Immune-mediated conditions, 158  
 Immunosuppressive therapy, 433  
 Incisive canal cyst, 424  
 Incisive papilla, cysts of the, 25, 25f–26f  
 Infancy, melanotic neuroectodermal tumor of, 207  
 Infantile hemangioma, 76f  
 Infectious conditions  
   actinomycosis, 35–36, 36f–37f  
   candidiasis, 38, 39f–41f  
   cytomegalovirus infection, 51–52, 52f–53f  
   hairy leukoplakia, 48–49, 49f–51f  
   herpesvirus infections, 45–46, 47f–48f  
   human papillomavirus-related benign lesions, 53–54  
   human papillomavirus-related benign lesions, 55f–61f  
   infectious granulomatous inflammation, 42, 43f–45f  
   syphilis, 61, 62f  
 Infectious granulomatous inflammation, 42, 43f–45f  
 Inflammation  
   granulomatous, 151f, 184f  
 Inflammation  
   granulomatous, 150–151, 151f  
   infectious granulomatous, 42  
   nonspecific conditions, 143  
 Inflammatory gingival nodules, 68–69  
 inflammatory odontogenic cysts, 320–321. *see also* odontogenic cysts  
   apical and lateral radicular cyst and periapical granuloma, 320–321  
   mandibular buccal bifurcation, 327  
 Inflammatory papillary hyperplasia of the palate, 28, 28f–30f  
 Inflammatory salivary gland disorders  
   adenomatoid hyperplasia, 283, 283f  
   autoimmune sialadenitis, 280, 281f–282f  
   cheilitis glandularis, 276f  
   cheilitis, 275  
   chronic obstructive sialadenitis, 267f  
   mucocele, 264–265, 265f–269f  
   necrotizing sialometaplasia, 276–277, 277f–278f  
   salivary duct cyst, 270, 270f–272f  
   sclerosing polycystic adenosis, 284, 285f  
   sialolith, 272–273, 273f–275f  
   subacute necrotizing sialadenitis, 278–279, 279f  
 Intraductal papilloma, 299, 300f–301f  
 Intraosseous lesions, nonodontogenic  
   aneurysmal bone cyst, 428, 430  
   central giant cell granuloma, 398  
   cherubism, 401  
   chondrosarcoma, 407–408  
   desmoplastic fibroma, 402–403  
   fibro-osseous, 385–386
- Intraosseous lesions, nonodontogenic (*cont'd*)  
 hematopoietic bone marrow defect, 423  
 langerhans cell histiocytosis, 416  
 median palatal cyst, 427  
 myospherulosis, 422  
 nasopalantine duct cyst, 424  
 nonodontogenic cysts and cystlike, 424  
 osteonecrosis and osteomyelitis, 417–419  
 osteosarcoma, 403–404  
 Paget disease of bone, 396  
 plasma cell myeloma, 411  
 simple bone cyst, 430  
 Stafne bone cavity, 431  
 surgical ciliated cyst, 426  
 tori and exostoses, 382–383  
 Invasive squamous cell carcinoma, 233f  
 Inverted ductal papilloma, 300, 301f  
 Irritation fibroma, 63–64
- J**  
 Jaw  
   osteonecrosis and osteomyelitis of, 417–419, 418t  
 jaw cysts, 320, 322f  
 Juvenile localized spongiotic gingival hyperplasia, 33, 33f–34f
- K**  
 Kaposi sarcoma, 115  
   on the maxillary gingiva, 116f  
   on the tongue, 116f  
   spindle cells and, 116f–117f  
 Karatoconjunctivitis sicca, 181  
 Karyopyknosis, 225f  
 Keratinized gingiva, 3f  
 Keratinizing squamous cell carcinoma, 246f–247f  
 Keratinocyte edema, 216f  
 Keratoacanthomatous pattern, well-differentiated squamous cell carcinoma, 261f  
 Keratocystic odontogenic tumor, 340–341, 343f–344f  
 Keratoses  
   benign alveolar ridge, 218  
   frictional/factitial, 51f, 214  
   frictional/factitial, 65f  
   nonspecific benign, 221  
 Keratosis follicularis, 10, 10f
- L**  
 Lamina propria, 228f–229f  
 Langerhans cell histiocytosis, 416, 416f–417f  
 Lateral periodontal cyst, 333, 334f–335f  
 Leiomyoma and angioleiomyoma, 131, 132f  
   vascular, 132f–133f  
 Leiomyomatous hamartoma, 20, 20f  
 Leukodema, 211f–212f  
 Leukoedema, 210–211  
 Leukoplakia, 230–232  
   homogeneous, 232f  
   nonhomogeneous, 232f  
 Lichen planus, 165–167, 167f–170f, 231  
   direct immunofluorescence study of, 172f  
   gingival, 170f  
   postinflammatory hypermelanosis and, 193  
   with postinflammatory hypermelanosis, 170f  
 Lichenoid mucositis, 165–167, 172f, 241f  
   cinnamic aldehyde-associated, 173f  
   granulomatous, 167f–168f  
   with granulomatous infiltrate, 171f  
   with reactive epithelial atypia, 241f  
 Ligneous gingivitis, 78f–79f  
 Linear IgA disease, 175f  
 Linear IgG deposition, 176f  
 Lingual salivary gland depression, 431  
 Lingual thyroid, 19, 19f  
 Lip, adenoid squamous cell carcinoma of, 255f  
 Lip  
   carcinoma ex pleomorphic adenoma of the upper, 293f  
   cheilitis glandularis of, 276f  
   mucocele on lower, 265f  
   neurofibroma of lower, 120f  
   pyogenic granuloma of, 108f



- Lipid granuloma, 152f  
 Lipocytic lesions, 90  
 Lipoma, 90, 91f–94f  
 Localized leukoplakia, 230  
 Lupus erythematosus, 181–182, 182f, 280  
 Lymphangioma  
   circumscriptum, 117, 118f–119f  
   of the alveolar ridge in neonates, 19  
 Lymphatic malformation, 118f–119f  
   of the tongue, 118f  
 Lymphatic malformation, 117  
 Lymphoepithelial cyst, 21f  
 Lymphoma in Sjögren syndrome, 282f  
 Lypocytic lesions, 91f–94f
- M**
- Malformation  
   lymphatic, 117  
   varix and venous lake, 109  
 Malignant salivary gland neoplasms, 301–302  
   acinic cell adenocarcinoma, 313–314  
   adenocarcinoma, not otherwise specified, 318  
   adenoid cystic carcinoma, 305–306  
   clear cell adenocarcinoma, 316  
   mucoepidermoid carcinoma, 301–302  
   polymorphous low-grade adenocarcinoma, 309–310  
 Mandibular buccal bifurcation cyst, 327, 328f  
 Masson tumor, 112f  
 Median palatal cyst, 427, 428f  
 Median rhomboid glossitis, 38, 41f  
 Melanoacanthoma, 196  
 Melanocytic pigmentation, 191  
 Melanoma, mucosal, 203  
 Melanotic neuroectodermal tumor of infancy, 207  
 MEN-2B  
   plexiform neuroma in patient with, 122f  
 Mesenchymal tumors, 373  
   cementoblastoma, 379  
   central odontogenic fibroma, 373, 373f–374f  
   granular cell odontogenic tumor, 377  
   odontogenic myxoma, 375, 375f–376f  
 Metastases to the gingiva, 87, 88f  
 Metastatic renal cell carcinoma, 88f  
 Migratory glossitis  
   benign, 159f–160f  
 Migratory stomatitis, 158  
   benign, 159f  
 Mild contact injury, 210–211  
 Mild dysplasia, 237f  
 Mild epithelial dysplasia, 238f  
 Minimally keratinizing squamous cell carcinoma, 246f  
 Minocycline, 189  
 Mixed epithelial and ectomesenchymal tumors, 362, 363f–365f  
   ameloblastic fibroma, 365–366  
   ameloblastic fibro-odontoma, 368  
   calcifying cystic odontogenic tumor, 362  
   odontoma, 370–371  
 Moderate epithelial dysplasia, 238f  
 Moderate-to-severe epithelial dysplasia involving excretory duct, 240f  
 Morsicatio mucosae oris, 214, 215f–218f  
 Mouth  
   benign migratory stomatitis of the floor of, 159f  
   pemphigus vulgaris in, 178f  
 Mucin, 266f–267f, 269f  
 Mucinosis, oral focal, 103  
 Mucocele, 264–265, 265f–268f  
   organizing, 268f  
   superficial, 269f  
 Mucoepidermoid carcinoma, 301–302, 303f–305f, 332f  
   parameters for grading, 302t  
 Mucosa  
   gingival, 3f  
   normal, 4f  
 Mucosal lesions  
   anatomy, 1  
   basic guidelines, 2–3  
   diagnosis and management, 2, 3f–6f  
   teeth and, 1–2
- Mucosal melanoma, 203  
 Mucositis, lichenoid, 165–167, 172f, 241f  
   cinnamic aldehyde-associated, 173f  
   granulomatous, 167f–168f  
   with granulomatous infiltrate, 171f  
 Mucous acini, 5f  
 Mucous glands, 5f  
 Mucous membrane  
   pemphigoid, 173–174, 175f–176f  
   plasmacytosis, 163  
 Multifocal cemento-osseous dysplasia, 385–386, 388f, 395f  
 Multiple myeloma, 411, 412f–415f  
 Muscle tumors, 131  
 Muscles  
   venous malformation and, 113f  
 Mycetoma, 45f  
 Myeloma, plasma cell, 411, 412f–415f  
 Myoepithelioma, 286–287, 292f  
   spindle cell, 291f  
 Myofibroma, 94–95, 95f–96f  
 Myospherulosis, 422, 423f  
 Myxoma, odontogenic myxoma, 375f–376f  
 Myxoma, odontogenic, 375
- N**
- Nasoalveolar cyst, 26, 27f  
 Nasolabial cyst, 26, 27f  
 Nasopalantine duct cyst, 424, 425f–426f  
 Necrotizing sialadenitis, 278–279, 279f  
 Necrotizing sialometaplasia, 276–277, 277f–278f  
 Neonates  
   lymphangioma of the alveolar ridge in, 19  
   palatal and gingival cysts of, 25, 25f  
 Neoplasms, peripheral odontogenic, 82–83  
 Neoplasms, salivary gland  
   acinic cell adenocarcinoma, 313–314, 314f–315f  
   adenocarcinoma, not otherwise specified, 318, 319f  
   adenoid cystic carcinoma, 305–306, 306f–309f  
   benign, 286–287  
   canalicular adenoma, 293, 294f–295f  
   clear cell adenocarcinoma, 316, 317f–318f  
   cystadenoma, 295, 295f–297f  
   intraductal papilloma, 299, 300f–301f  
   inverted ductal papilloma, 300  
   malignant, 301–302  
   mucoepidermoid carcinoma, 301–302, 302t, 303f–305f  
   pleomorphic adenoma and myoepithelioma, 286–287, 287f–293f  
   polymorphous low-grade adenocarcinoma, 309–310, 310f–313f  
   sialadenoma papilliferum, 298, 298f–299f  
 Nerve fibers  
   in plexiform neuroma in patient with MEN-2B, 122f  
   with traumatic neuroma, 120f  
 Neural tumors, 119  
   neurofibroma of lower lip, 120f  
 Neuroectodermal pigmentation, 207  
 Neurofibroma, 121  
 Neurofibroma  
   of lower lip, 120f  
   spindle cells in, 121f–122f  
 Neuroma  
   solitary circumscribed, 125  
   traumatic, 119, 120f  
 Nicotinic stomatitis, 226, 226f–227f  
 Nodular fasciitis, 97f, 250f  
 Nodular or tumor-like lesions  
   congenital granular cell tumor, 13f–14f  
   fordyce granules, 12f  
   gingival fibromatosis, 16f  
   leiomyomatous hamartoma, 20f  
   lingual thyroid, 19f  
   osteolipomatous choristoma, 15f  
   sebaceous hyperplasia, 12f–13f  
 Nodular or tumor-like lesions, 11  
   gingival, 68–69  
   lipocytic, 90  
 Nomenclature, tooth, 2  
 Nonaggressive giant cell lesion, 398
- Nonhomogeneous leukoplakia, 232f  
 Nonhomogenous erythroleukoplakia, 232f  
 Noninfectious papillary lesions, 30f  
   inflammatory papillary hyperplasia of the palate, 28, 28f–29f  
   juvenile localized spongiotic gingival hyperplasia, 33, 33f–34f  
   verruciform xanthoma, 30, 31f–33f  
 Nonkeratinized gingiva, 3f  
 Nonleukoplakias. *See* Reactive keratotic lesions  
 Nonodontogenic cysts and cystlike lesions, 424, 425f–426f  
 Nonodontogenic intraosseous lesions  
   aneurysmal bone cyst, 428, 429f, 430  
   central giant cell granuloma, 398, 399f–400f  
   cherubism, 401, 401f–402f  
   chondrosarcoma, 407–408, 408f–410f  
   desmoplastic fibroma, 402–403, 403f  
   fibro-osseous, 385–386, 385t, 387f–395f  
   hematopoietic bone marrow defect, 423, 423f–424f  
   Langerhans cell histiocytosis, 416, 416f–417f  
   median palatal cyst, 427  
   myospherulosis, 422, 423f  
   nasopalantine duct cyst, 424, 425f–426f  
   nonodontogenic cysts and cystlike, 424, 425f–426f  
   osteonecrosis and osteomyelitis, 417–419, 418t, 420f–422f  
   osteosarcoma, 403–404, 405f–407f  
   Paget disease of bone, 396, 397f  
   plasma cell myeloma, 411, 412f–415f  
   simple bone cyst, 430, 430f  
   Stafne bone cavity, 431, 431f  
   surgical ciliated cyst, 426, 426f–427f  
   tori and exostoses, 382–383, 383f–384f  
 Nonspecific benign keratoses, 221  
 Nonspecific benign reactive keratoses, 222f  
 Nonspecific hypersensitivity reactions, 160, 161f  
 Nonspecific inflammatory conditions, 143  
 Nonspecific irritant contact stomatitis, 143  
 Numbering system, tooth, 2, 6f
- O**
- Obstructive sialadenitis, 282f  
 Odontogenic cysts, 320  
   apical and lateral radicular cyst and periapical granuloma, 320–321, 324f, 326f–327f  
   botryoid, 335f  
   classification of jaw, 322f  
   dentigerous, 328–329, 329f–331f  
   developing tooth and, 320, 322f  
   developmental, 328–329, 329f–331f, 333f, 337f  
   giant cell hyaline rings, 321, 325f  
   in a globulomaxillary location, 337, 337f  
   inflammatory, 320–321  
   lateral periodontal, 333, 334f–335f  
   mandibular buccal bifurcation, 327, 328f  
   orthokeratinized odontogenic, 335, 336f  
   primordial, 338, 338f–339f  
   sinus inflammatory polyp, 326f  
 Odontogenic keratocyst, 340–341  
 Odontogenic myxoma, 375, 375f–376f  
 Odontogenic tumors  
   adenomatoid, 353, 354f–355f  
   ameloblastic carcinoma, 357  
   ameloblastic fibroma, 365–366, 366f–367f  
   ameloblastic fibro-odontoma, 368, 368f–370f  
   ameloblastic, 358f  
   ameloblastoma, 345, 346f–350f  
   calcifying cystic, 362, 363f–364f  
   calcifying epithelial, 351, 351f–353f  
   cementoblastoma, 379, 379f–381f  
   central odontogenic fibroma, 373, 373f–374f  
   classification of, 342f  
   clear cell odontogenic carcinoma, 360–361, 361f  
   epithelial tumors without ectomesenchyme, 340–341  
   granular cell, 377, 377f–378f  
   keratocystic, 343f–344f  
   mesenchymal, 373, 373f–376f

- Odontogenic tumors (*cont'd*)  
 mixed epithelial and ectomesenchymal, 362, 363f-365f  
 odontogenic myxoma, 375, 375f-376f  
 odontoma, 370-371, 371f-372f  
 primary intraosseous squamous cell carcinoma, 358-359, 359f-360f  
 squamoid, 356f-357f  
 squamous, 355-356
- Odontoma, 370-371, 371f-372f
- Oncocytic sialocyst, 271f-272f
- Oncocytic sialocytosis, 297f
- Oral cavity  
 anatomy, 1  
 diagnosis and management, 2, 3f-6f  
 metastases to the, 87  
 oral mucosa, 1, 2t  
 teeth, 1-2
- Oral erythema multiforme  
 recurrent, 162f-163f
- Oral focal mucinosis, 103, 104f-105f
- Oral hygiene and diffuse/multifocal gingival hyperplasia, 76-77
- Oral lichen simplex chronicus, 218
- Oral lupus erythematosus, 182f
- Oral lymphoepithelial cyst, 20, 21f-22f
- Oral melanocytic nevus, 198
- Oral melanotic macule, 191
- Oral mucosa, 1, 2t
- Orofacial granulomatosis with Crohn disease, 154-155, 155f-156f
- Orofacial granulomatosis, 155f  
 idiopathic, 156f
- Oropharyngeal nonkeratinizing squamous cell carcinoma, 252, 253f-254f
- orthokeratinized odontogenic cyst, 335, 336f
- Osseous and cartilaginous choristomas, 14
- Osteitis deformans, 396, 397f
- Osteoblastoma, 395f
- Osteogenic sarcoma, 403-404, 405f-407f
- Osteolipomatous choristoma, 15f
- Osteomyelitis, 417-419, 418t, 420f-422f
- Osteonecrosis, 417-419, 418t, 420f-422f
- Osteoporotic bone marrow defect, 423, 423f-424f
- Osteosarcoma, 403-404, 405f-407f
- P**
- Paget disease of bone, 396, 397f
- Pain medications, topical, 433
- Palantine cyst, 428f
- Palatal cysts of the neonate, 25, 25f
- Palate, erythroplakia of the, 234f
- Palate, inflammatory papillary hyperplasia of the, 28, 28f-30f
- Palate  
 pemphigus vulgaris on, 178f
- Palisaded encapsulated neuroma, 125, 125f-126f
- papilla, dental, 332f
- Papillary cystadenoma, 295
- Papillary oncocytic cystadenoma, 297f
- Papillary squamous cell carcinoma, 259f-260f  
 in situ, 259, 261f
- Papilloma  
 intraductal, 299, 300f-301f  
 inverted ductal, 300, 301f  
 squamous, 55f-57f
- Paracoccidioidomycosis, 42, 43f
- Parakeratin, 224f
- Parakeratosis, 81f
- Parameters for grading mucoepidermoid carcinoma, 302t
- Paraneoplastic pemphigus, 180-181, 181f
- Parulis, 75f-76f
- Pathominia mucosae oris, 214
- Pemphigoid, mucous membrane, 175f-176f  
 direct immunofluorescence of, 176f  
 treatment, 176f
- Pemphigoid, mucous membrane, 173-174
- Pemphigus  
 paraneoplastic, 180-181, 181f  
 vulgaris, 177, 178f-180f
- Periapical actinomycosis, 36f-37f
- Periapical granuloma, 320-321, 324f, 326f-327f
- Periapical granuloma, 320-321
- Peripheral ameloblastoma, 84, 85f
- Peripheral calcifying cystic odontogenic tumor, 86, 86f-87f
- Peripheral dentinogenic ghost cell tumor, 86f-87f
- Peripheral odontogenic fibroma, 83f-84f
- Peripheral odontogenic neoplasms, 82-83, 83f-85f
- Pharmacologic therapy  
 antifungal, 435  
 for common mucosal conditions, 433
- Phycomycoses, 42
- Pigmented lesions  
 dysplastic melanocytic nevus and mucosal melanoma, 203  
 exogenous pigmentation, 185  
 graphite tattoo, 188  
 medication-induced, 189  
 melanoacanthosis, 196  
 melanocytic, 191  
 neuroectodermal, 207  
 oral melanocytic nevus, 198  
 oral melanotic macule, 191  
 postinflammatory hypermelanosis, 193
- Pindborg tumor, 351, 351f-353f
- Plasma cell myeloma, 412f-415f
- Plasma cell  
 gingivitis, 164f-165f  
 myeloma, 411  
 orificial mucositis, 163  
 stomatitis, 163
- Pleomorphic adenoma, 286-287, 287f-293f
- Pleomorphism, 229f
- Plexiform neuroma  
 in patient with MEN-2B, 122f
- Plummer-Vinson syndrome, 243-244
- Poly-L-lactic acid granuloma, 152f
- Polymorphous low-grade adenocarcinoma, 309-310, 310f-313f
- polyps, sinus inflammatory, 326f
- Postinflammatory hypermelanosis, 193
- lichen planus with, 170f
- Postoperative maxillary cyst, 426, 426f
- Primary intraosseous squamous cell carcinoma, 358-359, 359f-360f
- Primordial cyst, 338, 338f-339f
- Proliferative erythroleukoplakia, 233f
- Proliferative leukoplakia, 230
- Pseudoacantholysis  
 pemphigus vulgaris and, 180f
- Pseudomembranous candidiasis, 39f-40f
- Punch biopsy, 6f
- Pyogenic granuloma, 70f, 72f, 106, 107f-108f.  
*see also* Vascular lesions  
 of lip, 108f  
 of the hard palatal mucosa, 107f  
 of the upper vermilion, 107f  
 reactive fibrovascular polyp, 107f  
 sclerosing, 109f
- Pyosotmatitis vegetans, 157, 157f-158f
- R**
- Radicular cysts, apical and lateral, 320-321
- Ranula, 265f
- Raynaud disease, 276
- Reactive epithelial atypia, lichenoid mucositis with, 241f
- Reactive fibrovascular polyps, 107f
- Reactive keratotic lesions  
 benign alveolar ridge keratosis, 218  
 contact desquamation, 213  
 frictional/faciatal keratoses, 214  
 leukoedema, 210-211  
 mild contact injury, 210-211  
 morsicatio mucosae oris, 214  
 nicotinic stomatitis, 226  
 nonspecific benign keratoses, 221  
 submucous fibrosis, 227-228  
 tobacco-related lesions, 223  
 white lesions, 210
- Reactive/inflammatory gingival nodules, 68-69
- Recrudescant varicella zoster infection, 48f
- Recurrent aphthous ulcers, 137-138
- Renal cell carcinoma, 88f
- rest of Malassez, 320, 322f
- Rest of Serres, 4f
- Rests of Serres, 80f
- Rhabdomyoma, adult, 134, 134f
- Rhabdomyoma, embryonal, 136f
- Rhabdomyosarcoma, embryonal, 135
- Rheumatoid arthritis, 280
- Riga-Fede disease, 140
- Ruptured hair follicle, 151f
- Russell bodies  
 with plasma cell gingivitis, 165f
- S**
- Salivary calculus, 272-273, 273f-275f
- Salivary duct cyst, 270, 270f-272f
- Salivary gland disorders  
 adenomatoid hyperplasia, 283, 283f  
 autoimmune sialadenitis, 280, 281f-282f  
 cheilitis glandularis, 276f  
 cheilitis, 275  
 chronic obstructive sialadenitis, 267f  
 mucocele, 264-265, 265f-269f  
 necrotizing sialometaplasia, 276-277, 277f-278f  
 salivary duct cyst, 270, 270f-272f  
 sclerosing polycystic adenosis, 284, 285f  
 sialolith, 272-273, 273f-275f  
 Stafne bone cavity, 431  
 subacute necrotizing sialadenitis, 278-279, 279f
- Salivary gland neoplasms  
 acinic cell adenocarcinoma, 313-314, 314f-315f  
 adenocarcinoma, not otherwise specified, 318, 319f  
 adenoid cystic carcinoma, 305-306, 306f-309f  
 benign, 286-287  
 canalicular adenoma, 293, 294f-295f  
 clear cell adenocarcinoma, 316, 317f-318f  
 cystadenoma, 295, 295f-297f  
 intraductal papilloma, 299, 300f-301f  
 inverted ductal papilloma, 300  
 malignant, 301-302  
 mucoepidermoid carcinoma, 301-302, 302t, 303f-305f  
 pleomorphic adenoma and myoepithelioma, 286-287, 287f-293f  
 polymorphous low-grade adenocarcinoma, 309-310, 310f-313f  
 sialadenoma papilliferum, 298, 298f-299f
- Salivary gland  
 granulomas in, 157f
- Salivary retention cyst, 270
- Sarcoidosis, 157f
- Sarcoma  
 chondro-, 407-408, 408f-410f  
 Ewing, 411, 415f  
 Kaposi (*See* Kaposi sarcoma)  
 osteogenic, 403-404, 405f-407f
- Sarcomatoid squamous cell carcinoma, 248f-249f  
 nodular fasciitis, 247, 250f
- Schwannoma, 123, 123f-124f  
 ancient, 124f
- Sclerosing polycystic adenosis, 284, 285f
- Sclerosing pyogenic granuloma, 109f
- Sclerotic fibroma, 63-64, 66f
- Sebaceous hyperplasia, 11, 12f-13f
- Serous acini, 5f
- Sialadenitis  
 autoimmune, 280, 281f-282f  
 chronic obstructive, 267f  
 obstructive, 282f  
 subacute necrotizing, 278-279, 279f
- Sialadenoma papilliferum, 298, 298f-299f
- Sialocyst, 270  
 oncocytic, 271f-272f
- Sialocytosis, oncocytic, 297f
- Sialolith, 272-273, 273f-275f
- Sialometaplasia, necrotizing, 276-277, 277f-278f
- Silicone granuloma, 153f
- Simple bone cyst, 395f, 430, 430f
- sinus inflammatory polyps, 326f
- Sjögren syndrome, 280, 281f-282f



- Skin, spherulocystic disease of, 422, 423f
- Skin  
 pemphigus vulgaris on, 178f
- Smokeless tobacco lesion, 223, 224f–225f
- verrucous carcinoma and, 257
- Smoker's melanosis, 193
- Solitary circumscribed neuroma, 125, 125f–126f
- Solitary fibrous tumor, 100, 100f–103f
- Spherulocystic disease of skin, 422
- Spherulocystic disease of skin, 423f
- Spherulocytosis, 422, 423f
- Spindle cell lesions, 119, 120f
- Spindle cell lipoma, 92f–93f
- Spindle cell myoepithelioma, 291f
- Spindle cells  
 Kaposi sarcoma and, 116f–117f  
 leiomyoma, 132f  
 neurofibroma, 121f–122f  
 schwannoma, 124f  
 solitary circumscribed neuroma, 125f–126f  
 subgemmal neurogenous plaque, 130f  
 vascular leiomyoma, 133f
- Squamous cell carcinoma, 243–244, 245f  
 adeno-, 256  
 adenoid, 254, 255f  
 basaloid, 250, 251f–252f  
 cuniculate carcinoma and, 262  
 cystic, 263f  
 human papillomavirus-associated  
 oropharyngeal and tonsillar  
 nonkeratinizing, 252, 253f–254f  
 invasive, 233f  
 minimally keratinizing, 246f  
 papillary, 259, 259f–261f  
 primary intraosseous, 358–359  
 sarcomatoid, 247, 248f–250f  
 well-differentiated keratinizing, 246f–247f
- Squamous epithelium, 3f
- Squamous odontogenic tumor, 355–356, 356f–357f
- Squamous papillomas, 53–54, 55f–57f
- Stafne bone cavity, 431, 431f
- Stent  
 mucous membrane pemphigoid treatment  
 with, 176f
- Stevens-Johnson syndrome, 180
- Stomatitis  
 contact, 143  
 glandularis, 275  
 granulomatous lichenoid, 167f–168f  
 migratory, 158, 159f  
 nicotinic, 226  
 plasma cell, 163
- Stromal eosinophils, 140–141
- Subacute necrotizing sialadenitis, 278–279, 279f
- Subepithelial nerve plexus, 129–130, 130f
- Subgemmal neurogenous plaque, 129–130, 130f
- Submucous fibrosis, 227–228, 228f–229f
- Suboptimal fixation artifact  
 pemphigus vulgaris and, 180f
- Sulfur granule, 37f
- Superficial mucocele, 269f
- Surface epithelium, 5f
- Surgical ciliated cyst, 426, 426f–427f
- Syphilis, 61, 62f
- Systemic hyalinosis, 17f
- Systemic immunosuppressive therapy, 433
- Systemic lupus erythematosus, 182f
- T**
- Taste buds, 5f
- Tattoo  
 amalgam, 185  
 graphite, 188
- Teeth  
 anatomy, 1–2, 5f  
 development, 321f  
 nomenclature, 2  
 numbering system, 2, 6f
- Tetracycline, 189
- Thrombus  
 venous lake malformation with, 111f–112f
- Thrush, 38
- Thyroid, lingual, 19, 19f
- Tobacco-related lesions, 223  
 smokeless tobacco, 223, 224f–225f  
 squamous cell carcinoma, 243–244
- Tongue  
 cribriform adenocarcinoma of, 313f  
 dorsum, 4f  
 ectomesenchymal chondromyxoid tumor of  
 the, 97–98, 98f–99f  
 eosinophilic ulcer of, 140–141  
 geographic, 158  
 granular cell tumor on, 128f  
 Kaposi sarcoma on the, 116f  
 lichen planus on, 167f–168f  
 lymphatic malformation of the, 118f  
 pemphigus vulgaris on, 178f  
 subgemmal neurogenous plaque in, 130f  
 varix and venous malformation of the, 110f
- Tonsillar nonkeratinizing squamous cell  
 carcinoma, 252
- Tonsillar nonkeratinizing squamous cell  
 carcinoma, 253f–254f
- tooth  
 development, 320  
 rest of Malassez, 320, 322f
- Topical immunosuppressive agents, 433
- Topical pain medications, 433
- Tori and exostoses, 382–383, 383f–384f
- Trauma and frictional blisters, 145
- Traumatic bone cyst, 430
- Traumatic neuroma, 119, 120f
- Traumatic ulcerative granuloma, 140–141
- Traumatic ulcers, 137–138
- Tumor of infancy, melanotic  
 neuroectodermal, 207
- Tumors (fibrous, gingival, and miscellaneous),  
 65f  
 denture-associated inflammatory fibrous  
 hyperplasia, 89f–90f  
 diffuse/multifocal gingival hyperplasia,  
 77f–78f  
 ectomesenchymal chondromyxoid tumor of  
 the tongue, 98f–99f  
 fibrous lesion, 64f–68f, 70f  
 gingival cyst of the adult, 80f–82f  
 gingival mass, 70f–71f  
 lipocytic lesion, 91f–94f  
 metastases to the gingiva, 88f  
 myofibroma, 95f–96f  
 oral focal mucinosis, 104f–105f  
 peripheral ameloblastoma, 85f  
 peripheral calcifying cystic odontogenic,  
 86f–87f  
 peripheral odontogenic neoplasm, 83f–84f  
 solitary fibrous, 100f–103f  
 of uncertain histogenesis, 98f–99f  
 uncommon, 95f, 97f
- Tumors (fibrous, gingival, and  
 miscellaneous). *See also* Carcinoma  
 denture-associated inflammatory fibrous  
 hyperplasia, 88  
 diffuse/multifocal gingival hyperplasia,  
 76–77  
 ectomesenchymal chondromyxoid tumor of  
 the tongue, 97–98  
 fibrous lesion, 63–64  
 gingival cyst of the adult, 79  
 gingival mass, 68–69  
 lipocytic lesion, 90  
 metastases to the gingiva, 87  
 myofibroma, 94–95  
 of uncertain histogenesis, 97–98  
 oral focal mucinosis, 103  
 peripheral ameloblastoma, 84  
 peripheral calcifying cystic odontogenic,  
 86  
 peripheral odontogenic neoplasm, 82–83  
 solitary fibrous, 100  
 uncommon, 94–95
- Tumors (odontogenic)  
 adenomatoid, 353, 354f–355f  
 ameloblastic, 358f  
 ameloblastic carcinoma, 357  
 ameloblastic fibroma, 365–366, 366f–367f
- Tumors (odontogenic) (*cont'd*)  
 ameloblastic fibro-odontoma, 368,  
 368f–370f  
 ameloblastoma, 345, 346f–350f  
 calcifying cystic, 362, 363f–364f  
 calcifying epithelial, 351, 351f–353f  
 cementoblastoma, 379, 379f–381f  
 central odontogenic fibroma, 373,  
 373f–374f  
 classification of, 342f  
 clear cell odontogenic carcinoma, 360–361,  
 361f  
 epithelial tumors without ectomesenchyme,  
 340–341  
 granular cell, 377, 377f–378f  
 keratocystic, 340–341, 343f–344f  
 mesenchymal, 373, 373f–376f  
 mixed epithelial and ectomesenchymal,  
 362, 363f–365f  
 odontogenic myxoma, 375, 375f–376f  
 odontoma, 370–371, 371f–372f  
 primary intraosseous squamous cell  
 carcinoma, 358–359, 359f–360f  
 squamous, 355–356, 356f–357f
- Tumors (vascular, neural, and muscle). *See also*  
 Carcinoma  
 adult rhabdomyoma, 134, 134f  
 angioleiomyoma, 131f  
 caliber-persistent labial artery, 114, 114f  
 embryonal rhabdomyoma, 136f  
 embryonal rhabdomyosarcoma, 135  
 granular cell, 127, 128f–129f  
 Kaposi sarcoma, 115, 116f–117f  
 leiomyoma and angioleiomyoma, 131  
 leiomyoma, 132f–133f  
 lymphatic malformation, 117, 118f–119f  
 Masson, 112f  
 muscle, 131  
 neural, 119  
 neural tumors, 120f  
 neurofibroma, 120f–122f, 121  
 schwannoma, 123, 123f–124f  
 solitary circumscribed neuroma, 125,  
 125f–126f  
 subgemmal neurogenous plaque, 129–130,  
 130f  
 varix and venous malformation, 109, 110f  
 vascular lesions, 106
- U**
- Ulcerative conditions, 137–138  
 pyostomatitis vegetans, 157, 157f  
 recurrent oral erythema multiforme, 162f
- Ulcerative gingivitis, 175f
- V**
- Varicella zoster virus, 46, 48f
- Varix and venous malformation, 109, 110f
- Vascular leiomyoma, 132f–133f
- Vascular lesions, 106
- Venous anomaly malformation, 109, 110f,  
 113f
- Venous lake malformation, 109, 110f–111f  
 with thrombus, 111f–112f
- Verocay bodies, 124f
- Verruca vulgaris, 53–54, 55f, 57f–58f
- Verruciform xanthoma, 30, 31f–33f
- Verrucous carcinoma, 257, 258f  
 cuniculate carcinoma and, 262
- Verrucous hyperplasia with dysplasia,  
 235f–236f
- Von Ebner glands, 4f
- W**
- Warty dyskeratoma, 10, 11f
- Wegener granulomatosis, 183, 183f–184f
- Well-differentiated keratinizing squamous cell  
 carcinoma, 246f–247f
- Well-differentiated papillary squamous cell  
 carcinoma, 259f
- White lesions, 210
- White sponge nevus, 7–8, 8f
- Z**
- Zygomycosis, 42, 44f